



**A Comparative Study of Male Germ Cell Production in Two Australian
Conilurine Rodents, the Plains Rat, *Pseudomys australis* and Hopping
Mouse, *Notomys alexis***

Eleanor J Peirce

Department of Anatomical Sciences
Medical School
University of Adelaide
South Australia

A thesis submitted for the degree of Doctor of Philosophy at the University of Adelaide
January, 2000

Table of Contents

Abstract		vii
Declaration		ix
Acknowledgments		xi
Publications		xiii
Chapter 1	Background Literature and Research Proposal	
1.1	Introduction	1
1.2	Development of the Male Reproductive System in Mammals	1
1.2.1	Establishment of Gonadal Cell Populations and Differentiation of the Testes	1
1.2.2	Differentiation of the Genital Duct System and Accessory Glands	3
1.2.3	Fetal Growth and Development of the Testes	4
1.2.4	Postnatal and Pubertal Development and Growth of the Testes	5
1.3	Structure of the Male Reproductive System in Adult Mammals	9
1.3.1	The Testes	9
1.3.1.1	Seminiferous Tubules	9
1.3.1.2	Interstitial Tissue	10
1.3.2	The Genital Duct System	14
1.3.2.1	Ductuli Efferentes	15
1.3.2.2	Epididymis	15
1.3.2.3	Vas Deferens	19
1.3.3	Accessory Glands	21
1.4	Cell Types in the Seminiferous Tubules	22
1.4.1	Peritubular Myoid Cells	23
1.4.2	Sertoli Cells	23
1.4.3	Germ Cells	27
1.4.3.1	Spermatogonia	27
1.4.3.2	Spermatocytes	27
1.4.3.3	Spermatids	29
1.5	Spermatogenesis	31
1.5.1	Cellular Associations, Cycles, and Waves, of the Seminiferous Epithelium	32
1.5.2	Duration of Spermatogenic Cycles	34
1.5.3	Sperm Production	38
1.5.3.1	Testis Size and Sertoli Cell Number	39
1.5.3.2	Germ Cell: Sertoli Cell Ratio	40
1.5.3.3	Spermatogonial Mitoses	41
1.5.3.4	Cell Loss during Spermatogenesis	45

1.6	Sperm Maturation	47
1.6.1	Transit Times through the Epididymis and Vas Deferens	47
1.6.2	The Epididymal Microenvironment	49
1.6.3	Changes in Sperm during Epididymal Transit	51
1.6.4	Sperm Storage in the Cauda Epididymides	52
1.7	Ejaculation and Sperm Deposition	55
1.8	The Australian Rodents	56
1.8.1	The Australian Hydromyine Rodents	56
1.8.2	Diversity in Reproductive Anatomy	57
1.9	Research Proposal	58
1.9.1	General Aims and Objectives	59
1.9.2	Specific Questions	59
Chapter 2 General Materials and Methods		
2.1	Animals	61
2.2	Preparation of Tissues for Light & Transmission Electron Microscopy	62
Chapter 3 Organisation of the Seminiferous Epithelium		
3.1	Introduction	65
3.2	Materials and Methods	66
3.2.1	Tissue Preparation and Photomicrography	66
3.2.2	Guidelines for the Identification of Cellular Associations	66
3.3	Results	68
3.3.1	Descriptions of Spermatogonia and Spermatocytes	68
3.3.2	Cellular Associations/Cycle Stages of the Plains Rat, <i>Pseudomys australis</i>	70
3.3.3	Seminiferous Epithelium of the Hopping Mouse, <i>Notomys alexis</i>	76
3.3.3.1	Comments on the Application of Staging Criteria	76
3.3.3.2	Cellular Associations/Cycle Stages of the Hopping Mouse	78
3.3.3.3	Non-conforming Cellular associations in the Hopping Mouse	80
3.4	Discussion	81
3.4.1	Comparisons with Laboratory Rodent Species	81
3.4.2	Comparisons with Primates	84
3.4.3	How is Synchronous Germ Cell Development Achieved?	85
3.5	Summary	86
Chapter 4 Frequency of Cycle Stages		
4.1	Introduction	87
4.2	Materials and Methods	88
4.2.1	Animals and Tissue Preparation	88

4.2.2	Frequency of Stages of the Cycle of the Seminiferous Epithelium	88
4.2.3	Statistical Analysis of Frequency Data	89
4.3	Results	91
4.3.1	Observed Stage Frequency	91
4.3.2	Variation in Stage Frequency Between Animals	92
4.3.3	Incidence of 'Multi-stage' Cross-sectional Profiles in the Hopping Mouse	93
4.4	Discussion	94
4.4.1	Stage Frequency	95
4.4.2	Incidence of Multi-stage Tubular Cross Sections	96
4.5	Summary	97
Chapter 5 Duration of the Cycle of the Seminiferous Epithelium		
5.1	Introduction	99
5.2	Materials and Methods	99
5.2.1	Animals	99
5.2.2	Tissue Preparation and Autoradiography	100
5.2.3	Analysis of Autoradiographic Sections	100
5.3	Results	102
5.3.1	Duration of the Cycle of the Seminiferous Epithelium	102
5.3.2	Duration of the Cycle Stages and Life Span of Spermatogenic Cell Types	109
5.4	Discussion	111
5.4.1	Cycle Duration	111
5.4.2	Life Span of Spermatogenic Cells	114
5.4.3	Duration of Spermatogenesis	114
5.5	Summary	115
Chapter 6 Daily Sperm Production		
6.1	Introduction	117
6.2	Materials and Methods	118
6.2.1	Determination of the Time Divisor	118
6.2.2	Determination of Sperm Production	119
6.3	Results	120
6.3.1	Time Divisor	120
6.3.2	Numbers of Spermatids per Animal and Daily Sperm Production	120
6.4	Discussion	122
6.5	Summary	129

Chapter 7 Epididymis and Vas Deferens - Gross Anatomical and Microscopical Structure

7.1	Introduction	131
7.2	Materials and Methods	132
7.2.1	Light Microscopy	132
7.2.2	Electron Microscopy	133
7.3	Results	133
7.3.1	Macroscopic Appearance of the Excurrent Ducts	133
7.3.2	Light and Electron Microscopical Appearance of the Excurrent Ducts	135
7.3.2.1	Ductuli Efferentes	135
7.3.2.2	Ductus Epididymidis	135
7.3.2.3	Vas Deferens	145
7.4	Discussion	148
7.4.1	Gross Anatomy	148
7.4.2	Ductuli Efferentes	149
7.4.3	Ductus Epididymidis	150
7.4.4	Vas Deferens	156
7.5	Summary	160

Chapter 8 Epididymis and Vas Deferens - Sperm Transit, Distribution and Storage

8.1	Introduction	161
8.2	Materials and Methods	161
8.2.1	Determination of Sperm Transit	161
8.2.1.1	Autoradiographic Tracking of Spermatozoa	161
8.2.1.2	Transit Time as Determined from Extra-gonadal Sperm Reserves and DSP	162
8.2.2	Sperm Distribution and Storage	162
8.2.2.1	General Method	162
8.2.2.2	Distribution of Spermatozoa Within the Sperm Storage Areas	163
8.3	Results	163
8.3.1	Transit Time	163
8.3.2	Distribution of Spermatozoa Within the Sperm Storage Areas	165
8.4	Discussion	169
8.4.1	Duration of Sperm Transit	169
8.4.2	Pattern of Sperm Distribution and Storage	172
8.5	Summary	174

Chapter 9	General Discussion and Conclusions	
9.1	Variation in Mammalian Testis Size	177
9.2	What Causes Variation in Testis Size?	179
9.2.1	Selection Pressures	179
9.2.2	Relationships with Breeding System and Sperm Competition	179
9.2.3	Genetic, Physiological, Endocrinological & Morphological Considerations	180
9.3	Testis Size as it Relates to the Dynamics of Sperm Production	182
9.4	Determinants of Testis Size in the Hopping Mouse - An Enigma!	183
9.5	Organisation of the Seminiferous Epithelium and Germ Cell Dynamics	185
9.6	Efficiency of Sperm Production	189
9.7	Sperm Transit and Storage	191
9.7.1	Duration of Epididymal Transit	192
9.7.2	Sites and Conditions of Sperm Storage in the Hopping Mouse	193
9.8	Summary of Results and Conclusions	194
9.9	Future Directions	196
	Appendix	197
	References	199

Abstract

In eutherian mammals, the size of the testes and number of spermatozoa produced and stored in the excurrent ducts vary widely between species, with the hydromyine rodents of Australia exhibiting a greater range of interspecific variation than any other closely related group of species. This study compared the efficiency of germ cell production and sperm storage capacity in the extra-testicular ducts of two arid zone species, the plains rat *Pseudomys australis* and the spinifex hopping mouse, *Notomys alexis*, that have vast differences in testes size and number of stored spermatozoa.

In the plains rat, the seminiferous tubules occupied 94% of the total testicular volume. Eleven germ cell associations were identified with a single association being present in a tubule cross-section. By contrast, in the hopping mouse the seminiferous tubules comprised only 85% of testicular volume. Eight cellular associations were identified and were confined to small regions of the seminiferous epithelium, such that a multi-stage tubule cross-section was sometimes evident. In the plains rat, the duration of the spermatogenic cycle was calculated to be 11.2 days, spermatogenesis 44.8 days, and mean sperm production 26×10^6 sperm/g testis/day or 40×10^6 sperm/animal/day. By contrast, in the hopping mouse the duration of the spermatogenic cycle was 14 days, spermatogenesis around 56 days, and average sperm production only 9.8×10^6 sperm/g testis/day or 0.5×10^6 sperm/animal/day.

In the plains rat the epithelium of the caput and corpus epididymides displayed features (long stereocilia, numerous vesicles and vacuoles) indicative of absorption and secretion, whereas the cauda had a low epithelium surrounding a wide lumen filled with spermatozoa, suggesting storage. The vas deferens had a thick muscular coat, particularly towards its urethral end. The duration of sperm transit through epididymis and vas deferens averaged 10.1 days, with 2.3 days spent in the caput and corpus, 6.9 days in the cauda, and 0.9 days in the vas. The number of sperm present ranged from 360 to $1,890 \times 10^6$ per side of the tract, with >94% of these, representing around 40 day's production by the testes, located in the paired caudae epididymides and <6% in the vasa deferentia.

In the hopping mouse, fewer structural specialisations were observed along the length of the epididymis. From the caput to the cauda region, there was a gradual decrease in the height of the principal cells and their stereocilia and a gradual reduction in the number of vesicles and vacuoles, although the Golgi became more prominent. Luminal diameter was relatively constant, apart from an increase in the cauda region. The urethral segment of the vas deferens showed extensive mucosal infoldings and had a very thin muscle coat. Sperm

transit time averaged 5.6 days, with less than one day required by sperm to pass through the caput and corpus epididymides, 3.1 days in the cauda epididymidis and 1.6 days in the vas deferens. The total number of spermatozoa stored ranged from 0.8 to 3.1×10^6 per side of the tract, with as many as 57% of these located in the vasa deferentia in some animals. Furthermore, total sperm stores per animal in the excurrent ducts represented only 4-5 day's production by the testes.

In conclusion, the structural organisation of the testes, epididymides and vasa deferentia of the plains rat, the kinetics of sperm production, epididymal sperm transit and storage are similar to the pattern previously described in common laboratory rodents. By contrast, in the hopping mouse, the organisation of the testicular seminiferous epithelium, kinetics of sperm production, and storage were very different and, in fact, more reminiscent of that of humans. The low number of epididymal spermatozoa in the latter species is in part a consequence of small testes containing relatively less sperm producing tissue, coupled with a lower efficiency of sperm production and a longer duration of spermatogenesis. Furthermore, transit of spermatozoa through the extra-testicular ducts is more rapid and cauda epididymal storage capacity is low, although some additional sperm are stored in the vasa deferentia. While the significance of such a reproductive strategy remains to be elucidated, it is evident that selective forces for maximising testis size and sperm numbers appear to have become relaxed in the hopping mouse, and that vast differences in the dynamics of germ cell production and storage have evolved in these two conilurine desert rodents.

Declaration

This work contains no material which has been accepted for the award of any other degree or diploma in any university or other tertiary institution, and to the best of my knowledge and belief, contains no material previously published or written by another person, except where due reference has been made in the text.

I give consent to this copy of my thesis, when deposited in the University Library, being available for loan and photocopying.

Eleanor Peirce

January 2000

Handwritten text, likely bleed-through from the reverse side of the page, running vertically along the right edge.

Acknowledgments

I sincerely thank my supervisor, Associate Professor Bill Breed for all his encouragement, assistance and advice over the extended period it has taken me to complete this thesis. Thank you for the many discussions, the useful comments, the many hours spent reading the various drafts of the text, and especially for your faith in me that I would complete the task. Bill, your persistence has finally paid off!

I also thank Mr Brett Henderson, Department of Statistics for advice and assistance with the analysis of stage frequency data, Chris Leigh, Gail Hermanis and Nadia Gagliardi, Department of Anatomical Sciences for various technical assistance, and the staff at CEMMSA for assistance with electron microscopy. Thanks again to Chris Leigh and to Dale Caville, Department of Pathology, for assistance with the production of the photographic plates in this thesis.

Thank you to Professor Brian Setchell for his constructive comments on the text and to Gail Hermanis and Jenny Peirce for proof reading of the final manuscript.

To the members of the Department of Anatomical Sciences, and particularly the Reproductive Biology group, thanks for your interest in my research, and for your friendship.

Finally, to my husband Chris, and daughter Courtney, thanks for putting up with me over the last few years. Your love, support and understanding have been very much appreciated.

Publications

Papers

Peirce, EJ and Breed, WG (1987) Cytological organization of the seminiferous epithelium in the Australian rodents *Pseudomys australis* and *Notomys alexis*. Journal of Reproduction and Fertility **80**:91-103.

Peirce, EJ and Breed, WG (1989) Light microscopical structure of the excurrent ducts and distribution of spermatozoa in the Australian rodents *Pseudomys australis* and *Notomys alexis*. Journal of Anatomy **162**:195-213.

Peirce, EJ and Breed, WG (1990) Organization of testicular interstitial tissue of an Australian rodent, the spinifex hopping mouse, *Notomys alexis*. Cell and Tissue Research **260**:469-477.

Conference Communications

Peirce, EJ and Breed, WG (1985) Sperm production in the Australian rodents, *Pseudomys alexis* and *Notomys alexis*. Society for the Study of Fertility Annual Conference 1985 Program and Abstracts of Papers. A102.

Peirce, EJ and Breed, WG (1998) A pilot study to determine the validity of the optical disector method for cell quantitation in testes of Australian rodents. Australian Mammal Society 1998 Conference Program and Abstracts. A81.

Chapter 1 Background Literature and Research Proposal



1.1 Introduction

This thesis attempts to shed some light on the role of the testes and to a lesser extent the epididymides and vasa deferentia, in determining the number of spermatozoa produced and stored, by a male before ejaculation. By way of background, this chapter presents an overview of the literature pertaining to the development, structure and function of the male reproductive system in mammals. The structural organisation of the mammalian testes and the events involved in the production of spermatozoa by them is emphasised, along with the role of the epididymides and vasa deferentia in the transit and storage of spermatozoa. Special reference is made to rodents and, in particular, to the interspecific differences in the parameters of male reproductive function among the hydromyine rodents of Australia. The latter part of the chapter then provides an outline of the aims and objectives of my research. To avoid repetition, details of the supply and care of animals, ethics approvals and techniques routinely used in the preparation of materials are provided as Chapter 2.

1.2 Development of the Male Reproductive System in Mammals

The reproductive system of male mammals consists of the paired testes and their associated ducts (ductuli efferentes, epididymis and vas deferens) and the accessory sex glands. Before considering the structure and function of these organs in sexually mature, adult, males, their embryological differentiation, development and growth will be briefly summarised.

1.2.1 Establishment of Gonadal Cell Populations and Differentiation of the Testes

The determination of genetic sex and subsequent normal development of the testes, is dependent upon expression of specific autosomal genes, as well as genes located on the X and Y sex chromosomes (Desjardins, 1978; Harley, 1993; Koopman, 1995). Although genetic sex is determined at the time of conception, it takes a number of days or weeks, depending on the species, before differentiation of the paired indifferent gonads into testes (or ovaries) occurs.

In mammals differentiation and development of the testes are closely associated with the development of the mesonephric and metanephric ducts, of which the latter give rise to the ureters and are accompanied by the metanephric blastema that differentiates into the

definitive kidney (Romer and Parsons, 1986). Initial differentiation of the indifferent gonads involves a thickening of the coelomic epithelium adjacent to the medio-ventral aspect of each mesonephros (Sadler, 1981). This is followed by the invasion of epithelial cells into the intervening mesenchyme, thus giving rise to the genital ridges (Larsen, 1993). Primordial germ cells (PGCs), which are the precursors to spermatogonia (and oogonia), migrate from the yolk sac, via the dorsal mesentery, to the genital ridges by amoeboid action, possibly in response to the secretion of chemotactic factors (Witschi, 1948; Chiquoine, 1954; Mintz, 1957; Heath, 1978; Eddy *et al.*, 1981). Upon their arrival, the PGCs come to reside within the coelomic epithelium or the mesenchyme between the mesonephros and the coelomic epithelium (Byсков, 1982). The cells of the coelomic epithelium then form aggregations that give rise to the primary sex cords, within which the PGCs become incorporated.

The differentiation of the indifferent gonad into a testis occurs in response to the expression of a gene on the Y sex chromosome, the testis-determining factor or TDF (George and Wilson, 1994; Graves, 1994). Studies in humans involving analysis of the phenotypic sex of individuals lacking different sections of the Y sex chromosome, narrowed the location of the TDF gene to the short arm of this chromosome (Page *et al.*, 1987; Palmer *et al.*, 1989) and later to a 35-kilobase region directly beneath the pseudoautosomal region at the tip of the short arm (Sinclair *et al.*, 1990). Screening of the DNA from the identified region revealed the presence of several sequences with the characteristics of genes, of which only one was specific to males. This base sequence, named SRY (for the sex-determining region on chromosome Y) was suggested to be the TDF gene (Sinclair *et al.*, 1990). Furthermore, human XY individuals lacking the SRY region or having a mutation in it were found to be phenotypically female (Berta *et al.*, 1990; Jäger *et al.*, 1990). Similar studies in the laboratory mouse also identified a gene beneath the pseudoautosomal region on the short arm of the Y chromosome that was expressed at the time of differentiation of the testes (Gubbay *et al.*, 1990; Koopman *et al.*, 1990). Direct evidence that SRY is the primary determinant of testis differentiation, however, was provided by the development of testes in transgenic, chromosomally female mice, in response to the introduction into embryos of the Sry gene as a partial transgene (Koopman *et al.*, 1991).

The exact action of the SRY gene in determining the development of a testis remains to be determined, however, it has been proposed that it acts as the master switch to direct the expression of a cascade of genes that results in testicular development (George and Wilson, 1994). Alternatively, it might act as a suppressor of ovary-differentiating genes, thus allowing testis-differentiating genes to act (Graves, 1994). The idea that SRY acts as a suppressor gene appears to be favoured by certain investigators, as it has been found that

the amino acid sequence of the SRY protein between humans, laboratory mice and marsupials is not highly conserved, even in the HMG box region (Graves, 1994). Graves (1994) argues that if the SRY protein was a transcription factor stimulating the expression of other genes, its sequence would be expected to be constrained and hence show minimal interspecific variation. This is due to the necessity of binding a specific DNA sequence and binding to particular proteins involved in that expression. As a suppressor protein, however, the amino acid sequence may not be as important in blocking transcription of target genes, since the bulk of the protein could merely act to saturate a locality, thereby preventing other transcription factors from binding (Graves, 1994).

In response to the SRY signal, the cortical parts of the primary sex cords degenerate, whereas the somatic cells of the medullary parts differentiate into precursors of the Sertoli cells (Larsen, 1993). Hence contact of the primary sex cords with the coelomic epithelium is lost, the rudimentary seminiferous tubules (seminiferous cords) containing two cell populations, the presumptive Sertoli cells and the gonocytes, are formed and a testis differentiates from the indifferent gonad. Furthermore, a portion of the peripheral mesenchymal tissue encapsulates the seminiferous cords and condenses, giving rise to the tunica albuginea of the testis (Gier and Marion, 1970).

Fetal Leydig cells are distinguishable several days following differentiation of the indifferent gonads into testes (Gier and Marion, 1970). They appear to differentiate from cells within the mesenchymal tissue between the seminiferous cords (Roosen-Runge and Anderson, 1959; Vergouwen *et al.*, 1991). The number and endocrine activity of the fetal Leydig cells increases progressively up to birth and the secretion of testosterone by them contributes to masculinisation of the extra-testicular duct system (Desjardins, 1981; Wilson, 1994). Around the time of birth the Leydig cell population regresses; it is reactivated at puberty at which time it re-differentiates and matures into the adult Leydig cell population (Setchell, 1978; Gondos, 1980).

1.2.2 Differentiation of the Genital Duct System and Accessory Glands

Accompanying testicular differentiation and development, is the development of the extra-testicular duct system and the accessory glands. In early embryos of both sexes, two sets of ducts that ultimately give rise to the male and female reproductive tracts, the Wolffian and Mullerian ducts, are present. The Wolffian ducts, which give rise to the male reproductive tract, develop from the excretory ducts of the mesonephric kidney system and are anatomically connected to the indifferent gonad (Wilson, 1994). The Mullerian (paramesonephric) ducts that develop into the female tract, arise as longitudinal invaginations of the coelomic epithelium on the anterolateral surface of each genital ridge

and run approximately parallel to each mesonephric duct (Setchell, 1978).

After differentiation of the indifferent gonad into a testis and formation of the seminiferous cords in response to SRY, Sertoli cells secrete a glycoprotein, Mullerian-inhibiting hormone (MIH) that suppresses development of the Mullerian ducts (Josso, 1974). In response to testosterone secreted by Leydig cells of the fetal testis, the Wolffian duct develops into the epididymis, vas deferens, ampulla and seminal vesicles (Setchell, 1978; George and Wilson, 1994). The cranial portion of the newly formed epididymis connects to the seminiferous cords via the ductuli efferentes and rete testis, which differentiate from the few remaining excretory tubules of the mesonephric kidney rather than the mesonephric duct (Roosen-Runge, 1961a; Gondos, 1980; Sadler, 1985). Such an origin of the ductuli efferentes has been confirmed by immunohistochemical studies in which the ductuli are the only epididymal segment to show a positive reaction to antibodies raised against kidney (Linder, 1971; Croisille, 1981). The prostate and bulbourethral glands develop from the endoderm and mesoderm of the urogenital sinus or urethra (Setchell *et al.*, 1994). In the absence of endocrine signals from the testis, a female pattern of development of the genital ducts occurs (Jost, 1953).

1.2.3 Fetal Development and Growth of the Testes

The seminiferous cords of fetal testes contain predominantly Sertoli cells, with relatively few germ cells present (Clermont and Perey, 1957). The Sertoli cells of the fetal testes are largely located adjacent to the boundary tissue within the seminiferous cords, whereas the gonocytes (male germ cells) are located centrally (Pelliniemi and Niemi, 1969; Wartenberg, 1989). Although morphologically dissimilar to their counterparts in the adult testis, these Sertoli cells can be recognised by their polygonal shape, the radial orientation of their cytoplasm and variable shape of their nuclei (de Kretser and Kerr, 1994). By contrast the gonocytes are large, round cells with pale staining cytoplasm and a prominent nucleolus (Clark and Eddy, 1975).

Prior to birth the gonocytes undergo a defined period of mitotic activity, which in the laboratory rat and laboratory mouse, occurs between days 14-16 post coitum (Hilscher *et al.*, 1974; Vergouwen *et al.*, 1991). A reduction in the average number of germ cells per cross section of seminiferous cord around the time of birth suggests that many of these gonocytes degenerate, although elongation of the seminiferous cords (due to mitosis of somatic cells) probably also reduces germ cell density (Clermont and Perey, 1957; Beaumont and Mandl, 1963). Studies in laboratory rodents have shown that expansion of the Sertoli cell population also begins in the fetal period and steadily increases until just before birth (Nagy, 1972; Orth, 1982). Mitotic activity then gradually declines resulting in

a static population of non-dividing Sertoli cells by day 10-12 in the laboratory mouse (Steinberger and Steinberger, 1977; Kluin *et al.*, 1984) and day 14-16 in the laboratory rat (Steinberger and Steinberger, 1971; Orth *et al.*, 1988). This is then followed by a maturational phase, during which the Sertoli cells develop intercellular tight junctions and attain adult function (Gondos and Berndtson, 1993).

A number of studies have implicated follicle-stimulating hormone (FSH) in the perinatal expansion of the Sertoli cell population. It was noted that the maximum binding of FSH within the testes corresponds to the period of maximum Sertoli cell proliferation just prior to birth (Warren *et al.*, 1984). A more direct line of evidence comes from studying the mitotic activity of Sertoli cells in culture. It has been shown that the addition of FSH to cultures enhances Sertoli cell mitotic activity (Griswold *et al.*, 1977; Solari and Fritz, 1978), whereas treatment with FSH antiserum dramatically reduces it (Orth, 1984). However, observations that the number and steroidogenic activity of fetal Leydig cells reach a peak at around the same time as maximal Sertoli cell mitosis (Lording and de Kretser, 1972; Orth and Weisz, 1980) have led to speculation of a paracrine relationship between these two cell populations as well. Hence it is possible that factors mediated via Leydig cell activity may also contribute to the regulation of Sertoli cell number *in utero* and immediately following birth (de Kretser and Kerr, 1994).

Unlike gonocytes in the ovary, germ cells of the testes do not normally enter meiosis until around the time of puberty, despite having the capacity to do so in fetal life (Byskov, 1982). The stimulus for the entry of fetal germ cells into meiosis in the female has been ascribed to the actions of meiosis-inducing substance (MIS), secreted by cells derived from the mesonephros (Byskov, 1979). In males, however, there is a meiosis-preventing substance (MPS) within the seminiferous cords that opposes this action (Byskov, 1978; 1979; 1982) and it has been proposed that the entry of male germ cells into meiosis is dependent on the relative concentrations of the two substances.

1.2.4 Postnatal and Pubertal Development and Growth of the Testes

The pattern of postnatal development of the seminiferous cords of mammals varies considerably and is related to the time interval that elapses between birth and the acquisition of full spermatogenic and androgenic function at puberty. In small species that mature rapidly and have short reproductive life spans, such as laboratory rodents, Sertoli cell and germ cell maturation proceeds from birth onwards, ie. spermatogenesis effectively commences within the first few days of life (de Kretser and Kerr, 1994). By contrast, in larger domestic species and primates, including humans, a period of minimal growth and maturation (prespermatogenic period) occurs between birth and the onset of puberty

(Nistal and Paniagua, 1984).

In the laboratory rat, the duration of spermatogenesis, which is the development of a spermatozoon from a stem spermatogonium, is 48 days (Clermont *et al.*, 1959) and spermatozoa have been noted in the lumina of seminiferous tubules as early as day 50 post-partum (Lee *et al.*, 1975). By contrast, in the human, little testicular development takes place between birth and around 10 years of age (Muller and Skakkebaek, 1983). At this time gonocytes resume mitotic divisions to form spermatogonia that migrate towards the basement membrane of the seminiferous cords, thereby taking up their adult position. Subsequently there is intense developmental activity within the germ cell line, resulting in the progressive appearance of successively more mature generations of germ cells over a period of several years. This spermatogenic activity is, however, accompanied by considerable degeneration of the germ cells produced and very few, if any, reach maturity in the early stages of puberty. The full establishment of spermatogenesis and release of spermatozoa from human testes normally occurs between 11 and 14 years of age (Winter and Faiman, 1972; Marshall, 1978).

As mentioned in Section 1.2.3, expansion of the Sertoli cell population, at least in laboratory rodents, continues for several weeks following birth and is dependent upon the actions of FSH, secreted by the anterior pituitary (Nagy, 1972; Orth, 1982). Evidence now indicates that the duration of this postnatal proliferative phase, prior to Sertoli cell maturation, is also influenced by thyroid hormones. Experiments show that rats made hypothyroid at birth have delayed Sertoli cell development at 21 days of age, as is evident from their lack of development of cytoplasmic lipid droplets and the absence of a lumen in the seminiferous tubules (Francavilla *et al.*, 1991). Furthermore, these cells retain their mitotic capabilities past the usual 14-16 days post partum. In both laboratory rats and laboratory mice made hypothyroid at birth, proliferation of Sertoli cells continues until about day 25 (van Haaster *et al.*, 1992; Joyce *et al.*, 1993). Conversely, treatment of neonatal Sertoli cells in culture with triiodothyronine inhibits mitosis and stimulates maturation, as indicated by increased levels of expression of mRNAs for secretory proteins including inhibin (Cooke *et al.*, 1994; Bunick *et al.*, 1994; Jannini *et al.*, 1995) and increased androgen receptor expression (Arambepola *et al.*, 1998). Likewise, administration of triiodothyronine to laboratory rats during the neonatal period accelerates tubular lumen formation and leads to elevated serum inhibin levels compared to control animals, both of which are indicative of maturation of the Sertoli cells (van Haaster *et al.*, 1993).

Sertoli cell maturation includes the acquisition of metabolic and synthetic activities by the cells and modifications to their morphology (Bardin *et al.*, 1994). Several of the most

noticeable developmental events are:

- a) the structural transformation of essentially spherical Sertoli cells into ones with an elaborate array of cytoplasmic projections, capable of maintaining cellular contact with the rapidly expanding germ cell population,
- b) the establishment of bands of tight junctions between adjacent Sertoli cells, giving rise to the blood-testis barrier and
- c) the development of a lumen within the seminiferous cords to form the seminiferous tubules.

Prior to the onset of spermatogenesis, Sertoli cells and germ cells are approximately the same size and have no apparent pattern of organisation within the seminiferous cords. With the rapid expansion of the germ cell population, however, the Sertoli cells undergo considerable enlargement and structural reorganisation in order to maintain cellular contact with each germ cell (Gondos and Berndtson, 1993). The Sertoli cells undergo elongation in a direction perpendicular to the basal lamina and their apical cytoplasm extends inward, while the bases of the cells become anchored to the periphery of the cords (Fawcett, 1975a). As the successive germ cell generations arise and the seminiferous epithelium takes on a stratified appearance, further elongation of Sertoli cells occurs and irregularly shaped cytoplasmic processes that envelop the germ cells develop. This sequence of development appears to be similar in the majority of mammalian species (Flickinger, 1967; Chevalier, 1978; Nistal *et al.*, 1982; van Vorstenbosch *et al.*, 1984; Sinowitz and Amselgruber, 1986; Kelly *et al.*, 1991). Accompanying the increase in Sertoli cell size are transformations of nuclear appearance and extensive development of cytoplasmic organelles, particularly smooth endoplasmic reticulum, Golgi complexes, mitochondria (Gondos and Berndtson, 1993) and cytoskeletal elements (Paranko *et al.*, 1986; Russell *et al.*, 1989a).

In the laboratory rat, formation of tight junctions between Sertoli cells that constitute the blood-testis barrier begins at about day 15 post-partum, coinciding with the cessation of Sertoli cell mitosis and is completed between days 16 and 19 (Vitale *et al.*, 1973; Gilula *et al.*, 1976). The complete functional maturation of the blood-testis barrier, however, takes considerably longer. A functional barrier to water soluble markers develops more slowly and at a later age than that to electron-opaque markers and correlates more closely with enlargement of the tubular lumen, than with formation of the inter-Sertoli cell junctions (Setchell *et al.*, 1988). Furthermore, formation of the blood-testis barrier does not occur synchronously along the entire length of a seminiferous tubule, but appears to be correlated with the establishment of spermatogenesis and in particular the stage of meiosis reached by the germ cells, since an effective barrier is only observed in areas containing pachytene primary spermatocytes (Bergmann and Dierichs, 1983). Formation of the

barrier is not, however, dependent on the presence of germ cells. Tight junctions still form in testes depleted of germ cells after irradiation *in utero* (Hatier *et al.*, 1982) and are present in animals with impaired fertility due to missing germ cell generations (Bardin *et al.*, 1994). Rather, it is thought that the formation of intercellular junctions is at least partly dependent on adequate stimulation of the Sertoli cells by FSH (Fritz, 1978; Posalaky *et al.*, 1981). Furthermore, it is probable that meiosis can not successfully proceed past the pachytene primary spermatocyte stage unless there is a functional blood-testis barrier. Since the haploid germ cells (secondary spermatocytes and spermatids) are located on the adluminal side of the blood-testis barrier, the barrier might provide protection to them, against the body's immune system (Sharpe, 1994). In addition, the ionic and protein composition of the adluminal compartment is significantly different from that of the basal compartment (Hinton and Setchell, 1993) and may contribute to the maintenance of cellular integrity.

In humans, tight junction formation between Sertoli cells is initiated early in childhood, but establishment of the blood-testis barrier is not completed until 11-14 years of age. The latter coincides with pubertal testicular development and the establishment of spermatogenesis (Furuya *et al.*, 1978; Gondos and Berndtson, 1993).

Formation of a tubular lumen occurs in conjunction with the establishment of the blood-testis barrier and reflects the metabolic and secretory activity of the Sertoli cells (Russell *et al.*, 1989a). Although fetal Sertoli cells synthesise and secrete Mullerian-inhibiting hormone (Donahoe *et al.*, 1976; 1977), there is a dramatic increase in the range of biochemical activity attributable to neonatal and pubertal Sertoli cells. These secrete androgen binding protein (ABP) (Tindall *et al.*, 1975; Rich *et al.*, 1983), inhibin (Steinberger and Steinberger, 1976; Le Gac and de Kretser, 1982) and growth factors (Skinner *et al.*, 1989; Bellvé and Zheng, 1989) and express receptors for FSH and testosterone (Gondos and Berndtson, 1993). Much of their metabolic activity, either directly, or indirectly via modulation of other testicular functions, influences the establishment and subsequent regulation of spermatogenesis (Means *et al.*, 1976; Sharpe, 1994).

The establishment of spermatogenesis at puberty is primarily under the control of gonadotrophins secreted by the anterior pituitary and androgens secreted by the testicular Leydig cells (Fritz, 1978; Sharpe, 1994). Luteinising hormone (LH) stimulates the Leydig cells within the interstitial tissue to synthesise and secrete testosterone, which in turn acts on the seminiferous tubules to support germ cell development. Receptors for testosterone have been found in both Sertoli cells (Tindall *et al.*, 1977) and in some maturational stages of germ cells (Wright and Frankel, 1980; Vornberger *et al.*, 1994). Follicle stimulating

hormone (FSH) acts directly on the seminiferous epithelium by binding to receptors on the plasmalemmae of both Sertoli cells and spermatogonia (Means *et al.*, 1976; Orth and Christensen, 1977; 1978). It also enhances the secretion of testosterone by increasing the number of LH receptors on Leydig cells and the synthesis and secretion of ABP by Sertoli cells (Louis and Fritz, 1979; Hall *et al.*, 1990). As puberty proceeds, the responsiveness of Sertoli cells to FSH declines and their responsiveness to testosterone increases, as is evident from the effects of these hormones on the secretion of seminiferous tubule fluid (Jegou *et al.*, 1982), ABP (Danzo *et al.*, 1990) and androgen-regulated proteins (Sharpe *et al.*, 1992). Hence, the control of spermatogenesis switches from primarily FSH during its establishment, to testosterone in adulthood and it is thought that the secretion of ABP during puberty may be important for this change to occur (Sharpe, 1994).

1.3 Structure of the Male Reproductive System in Adult Mammals

1.3.1 The Testes

The testes of sexually mature, adult, mammals are organised into two structurally separate, but functionally inter-related compartments, the seminiferous tubules and the interstitial tissue. Each testis is encapsulated by a tough fibrous covering, the tunica albuginea, with the innermost portion being continuous with the connective tissue of the interstitial compartment. Although this basic organisation is common to the testes of all mammalian species, there is interspecific variation in the organisation of the interstitial tissue and in the relative volume of the testes occupied by each of the two compartments.

1.3.1.1 Seminiferous Tubules

The seminiferous tubules occupy the major proportion of the testes and are the site of sperm production. Seminiferous epithelium, comprised of the maturing germ cells and the somatic Sertoli cells, forms the walls of the tubules, which surround a central lumen. A circumferential band of tissue, the peritubular tissue that consists of four different layers, demarcates the outer boundary of each tubule. The innermost layer of the peritubular tissue forms a basement membrane and is comprised of extracellular glycoproteins (Clermont, 1958). A layer of myoid cells connected to each other by desmosomes (Leeson and Leeson, 1963; Ross, 1967) is external to it. External to the myoid cells is a connective tissue layer containing predominantly collagen-like fibres and a second cellular layer is outermost (Bustos-Obregon, 1976a,b; Hermo *et al.*, 1977; Christl, 1990). In rodents, the cells of the outermost layer of the peritubular tissue appear identical to the endothelial cells lining the lymphatic sinusoids of the interstitial tissue (Clermont, 1958; Gardner and

Holyoke, 1964). The peritubular tissue provides mechanical support to the seminiferous epithelium, assists in movement of spermatozoa through the tubule lumen via peristaltic contraction of the myoid cells (Roosen-Runge, 1951; Clermont, 1958; Palombi *et al.*, 1992), restricts the passage of macromolecules between the interstitial tissue and tubules (Kormano, 1967) and possibly acts as a source of precursor cells for Leydig cell development (de Kretser and Kerr, 1994).

In most mammalian species, the seminiferous tubules occur as tortuous loops, with both ends opening via the tubuli recti into the rete testis. The terminal segments of the seminiferous tubules have a modified epithelial lining devoid of germ cells and comprised of Sertoli-like cells only (Dym, 1974; Osman, 1978; Osman and Ploen, 1979). The number of seminiferous tubules per testis is variable, ranging from less than five in several dasyurid marsupials (Woolley, 1975) to around 30 in the laboratory rat (Clermont and Huckins, 1961) and many more in farm animals and humans. In eutherian mammals, the diameter of the seminiferous tubules is relatively constant, ranging between 200 μm and 300 μm (Setchell 1978). Their total length, however, is much more variable, ranging from a few metres in small rodents to around 6,000 metres in the boar and over 10,000 metres in the ram (Bascom and Osterud, 1925; Asdell, 1964). In general, such differences in the total length of the tubules reflect differences in testis size. By contrast the seminiferous tubules of some marsupials, particularly the dasyurids and peramelids, are considerably shorter and wider than those of most eutherians (Woolley, 1975; Kerr and Hedger, 1983), although the significance of these differences is unknown.

1.3.1.2 Interstitial Tissue

The testicular interstitial tissue occupies the spaces between the seminiferous tubules. It is essentially a connective tissue that contains all of the blood vessels, lymph vessels and nerves of the testicular parenchyma as well as the Leydig cells (Fawcett *et al.*, 1969; Fawcett *et al.*, 1973; Clark, 1976). The Leydig cells are responsible for the synthesis and secretion of the testicular androgens and exhibit ultrastructural features consistent with this function (Christensen and Gillim, 1972). Leydig cell structure has been investigated in detail in a range of mammalian species and, while there is interspecific diversity in structure, all Leydig cells contain an extensive network of smooth endoplasmic reticulum, numerous mitochondria and Golgi complexes and variable amounts of lipid (Christensen, 1975; de Kretser and Kerr, 1994).

The spatial relationship between the Leydig cells, the blood and lymph vessels of the interstitial tissue and the walls of the seminiferous tubules, varies markedly among mammals. However, in a comparative study Fawcett *et al.* (1973) found that interstitial

tissue organisation in all of the 14 mammalian species they investigated could be assigned to one of three general categories as follows.

In category 1 species, typified by laboratory rodents, a network of lymphatics occupies the bulk of the intertubular area and the Leydig cells are usually clustered around blood capillaries. This category can be subdivided into those species in which the lymphatics possess a complete endothelial lining that separates the lymph from adjacent Leydig cells and blood capillaries, such as the guinea pig (Fig.1.1a) and chinchilla and those in which the endothelial lining is discontinuous and Leydig cells are in direct contact with the lymphatic spaces, eg. laboratory rat (Fig.1.1b) and laboratory mouse. In all of these species, the amount of interstitial tissue is relatively small. For example, it comprises around 7-16% of total testicular volume in the laboratory rat (Roosen-Runge, 1955a; Fichna and Malendowicz, 1975; Mori and Christensen, 1980), 11% in the laboratory mouse (Mori *et al.*, 1982) and 12% in the guinea pig (Mori *et al.*, 1980).

The ram (Fig. 1.1c), bull, elephant, hyrax, monkey and human belong to category 2 of Fawcett *et al.* (1973). In these species, the interstitial tissue is comprised of abundant connective tissue, rich in interstitial fluid. Randomly scattered clusters of Leydig cells, along with several discrete lymphatic vessels and blood capillaries, are contained within each interstitial area, however, the Leydig cells are not always in the immediate vicinity of the vessels. The interstitial tissue also contributes a greater percentage to the total testicular volume, comprising around 35-40% in humans (Johnson *et al.*, 1980a, 1986; Johnson, 1986b).

The interstitial tissue of category 3 species is dominated by abundant, closely-packed, Leydig cells, which comprise between 20% and 60% of the total testicular volume (Fawcett, 1973; van Straaten and Wensing, 1977; Johnson and Neaves, 1981; de Kretser and Kerr, 1994). There is little obvious connective tissue, although occasional, small blood and lymphatic vessels are interspersed among the Leydig cells. Due to their sheer abundance, many of the Leydig cells are located at great distances from the nearest blood and lymph vessels. Species displaying this organisation of the interstitial tissue include the domestic boar (Fig.1.1d), wart hog, zebra, naked mole rat, opossum (Fawcett *et al.*, 1973) and a variety of Australian marsupials including bandicoots (Setchell, 1977), possums, several species of *Antechinus* and the koala (de Kretser and Kerr, 1994).

The differences in interstitial tissue composition and organisation as categorised by Fawcett and his co-workers (1973) generally occur between representative species in different orders of mammals, although their study did not attempt any categorisation that reflected the relationships between species, nor did it distinguish which was the ancestral

Figure 1.1. Patterns of organisation of testicular interstitial tissue in mammals. Fawcett *et al.*, 1973).

Fig. 1.1a Category 1 organisation. Guinea Pig. Leydig cells are clustered around the blood vessels and are completely separated from the extensive lymphatic sinusoids by an endothelium.

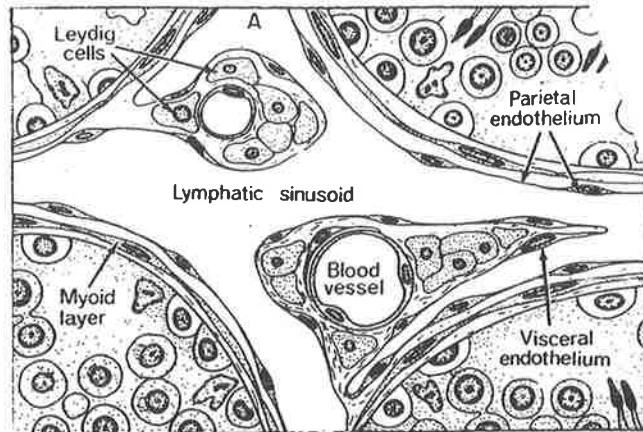


Fig. 1.1b Category 1 organisation. Rat. Organisation is similar to that of the guinea pig, but groups of Leydig cells are in direct contact with lymph, due to an incomplete endothelial cell layer delimiting the lymph space.

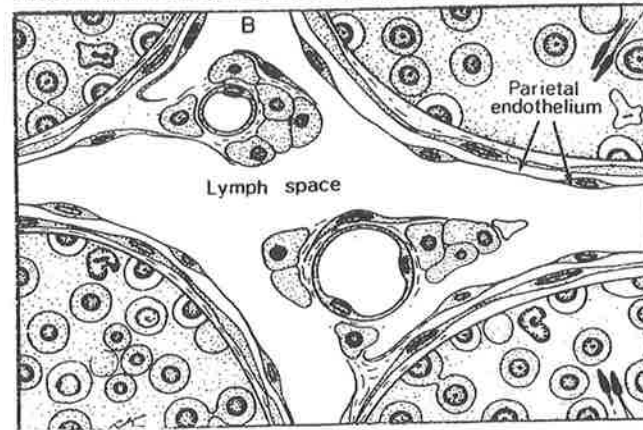


Fig. 1.1c Category 2 organisation. Ram. Groups of Leydig cells, which are not always close to blood vessels, are interspersed in a loose connective tissue.

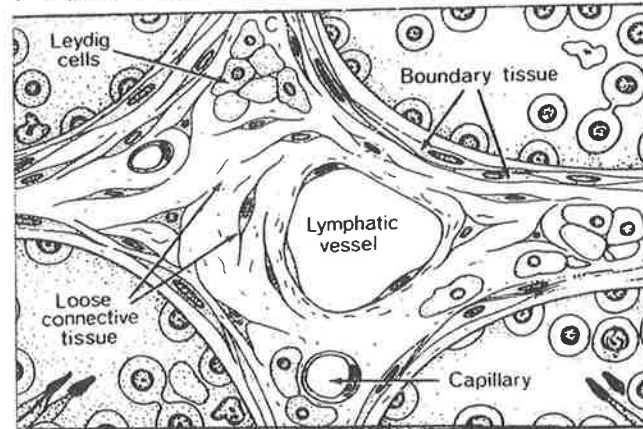
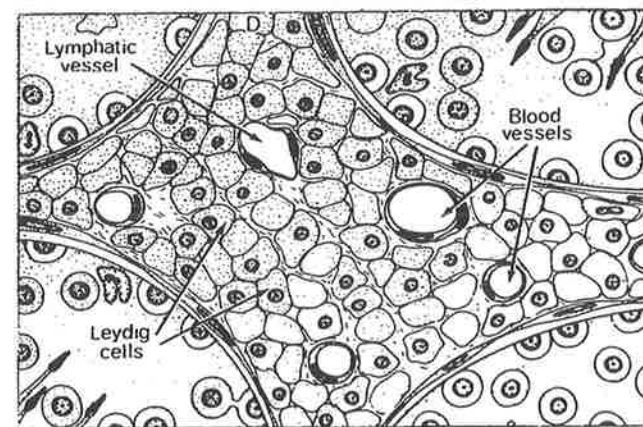


Fig. 1.1d Category 3 organisation. Boar. The interstitial tissue is dominated by numerous, closely-packed, Leydig cells. Blood and lymph vessels are small and inconspicuous.



and which was the derived type of interstitial tissue. Attempts were made, however, to explain the different organisations of the interstitial tissue in terms of possible differences in the functional operation of the tissue. It was suggested that interstitial tissue organisation may vary according to the nutritional requirements and fluid secretion of the seminiferous epithelium, the partitioning of androgen between the lymph and blood, the rate of lymph flow and the efficiency with which a critical concentration of androgen can be maintained around the seminiferous tubules (Fawcett *et al.*, 1973; Fawcett, 1973). It has been proposed that the relative paucity of Leydig cells in category 2 species, coupled with their distance from the blood and lymph vessels, indicates that androgens secreted by the Leydig cells must diffuse through the oedematous connective tissue in order to gain access to the venous system and the seminiferous tubules (de Kretser and Kerr, 1994). Similarly, in category 1 species, the rich network of peritubular lymphatics might act as a sink as a consequence of the slow passage of lymph within them, thereby maintaining a critical concentration of androgens within the testis that is readily available to the seminiferous tubules (Peirce and Breed, 1990). Possible explanations as to why there is an abundance of Leydig cells in type 3 species, however, are more enigmatic. A huge volume of Leydig cells might be necessary to compensate for inefficient mechanisms of androgen delivery to the seminiferous tubules, or a relative insensitivity of the seminiferous epithelium to the androgens produced, however, these suggestions have been deemed unlikely (Fawcett *et al.*, 1973; Fawcett, 1973). An alternative suggestion is that abundant Leydig cells may be required to meet systemic demands for secretions other than testosterone, such as hormone-binding globulins and pheromones (Fawcett *et al.*, 1973). That the testes of boars and stallions, which both possess abundant, Leydig cell-rich interstitial tissue, secrete high concentrations of weak oestrogens (Setchell and Cox, 1982; Setchell *et al.*, 1983) provides circumstantial evidence in support of this suggestion. Similarly, in *Antechinus* an abundance of Leydig cells might be linked to high levels of androgen-dependent aggression and courtship behaviour (Kerr and Hedger, 1983).

Within the hydromyine rodents of Australia considerable interspecific variability is evident in the relative volume and composition of the testicular interstitial tissue. In *Pseudomys* species that have relatively large testes (>1% of body mass), including *P. australis*, *P. desertor* and *P. nanus*, interstitial tissue is sparse and comprises less than 8% of testicular volume (Breed, 1982a). Their Leydig cells occur in groups that are clustered around small blood vessels or partially abut onto lymphatic spaces, ie. Category 1 arrangement of Fawcett *et al.*, (1973). A similar volume and pattern of interstitial tissue organisation is observed in several species, *P. novaehollandiae* and *P. shortridgei*, with a small relative testes size (~0.5% of body mass), however, in other species including *P. apodemoides*, *P. delicatulus* and *P. hermannsburgensis*, a very different situation is observed. In these species, the interstitial tissue is dominated by abundant, lipid-rich Leydig cells and

contains sparsely distributed blood vessels and lymphatic spaces and little connective tissue (Category 3 organisation). Furthermore, between 28% and 35% of total testicular volume is comprised of interstitial tissue (Breed, 1982a; 1997). In *Notomys* species, interstitial tissue generally comprises between 10% and 20% of testicular volume and characteristics of both Category 1 and Category 3 organisation are evident in different areas of the interstitial tissue within one species, *Notomys alexis* (Breed, 1982a; Peirce and Breed, 1990).

In most mammalian species, appreciable numbers of leukocytes, particularly mast cells and macrophages, also occur in the interstitial tissue (Nistal *et al.*, 1984; Niemi *et al.*, 1986). Recently, it has been suggested that these cells play an important role in testicular homeostasis and are as necessary for the normal regulation of testicular function as Leydig and Sertoli cells (Hedger, 1997). In addition to their participation in tissue remodelling, immunological surveillance and immunoregulation, evidence suggests that testicular macrophages develop a trophic interaction with Leydig cells, whereby they influence Leydig cell development and steroidogenesis and, in turn, their activity and number are regulated by Leydig cells (Hedger, 1997; Schlatt *et al.*, 1999). Establishment of the adult Leydig cell population and macrophage proliferation within the testes of pubertal laboratory rats have been shown to coincide (Hardy *et al.*, 1989; Hutson, 1990; Raburn, *et al.*, 1993). Furthermore, Leydig cells do not proliferate and differentiate in immature laboratory rat testes in the absence of functional macrophages (Gaytan *et al.*, 1994). Yet other studies conducted on adult rat testes indicate that Leydig cell secretions, either directly or indirectly, regulate the number of both testicular macrophages and mast cells (Wang *et al.*, 1994, Duckett *et al.*, 1997).

1.3.2 The Genital Duct System

Transport of spermatozoa from their site of production in the testicular seminiferous tubules to the site of insemination within the female reproductive tract involves their passage through the male genital duct system. The initial, intratesticular, portion of the duct system, the rete testis, is continuous with the terminal portions of the seminiferous tubules via short, narrow tubuli recti, which have a similar lining to that of the rete testis (Osman and Plöen, 1978). The rete proper takes the form of a network of interconnected channels that is somewhat variable in location, ranging from just below the testicular tunica albuginea immediately adjacent to the epididymis in humans, monkeys and the laboratory rat (Roosen-Runge, 1961b; Dym, 1976; Roosen-Runge and Holstein, 1978), to centrally within the testis in the cat (Viotto *et al.*, 1991). The rete testis, in turn, connects to the ductuli efferentes that leave the testis and drain into a single, highly convoluted duct, the epididymis, which later straightens and becomes the vas deferens.

1.3.2.1 Ductuli Efferentes

In mammals the number of tubules that comprise the ductuli efferentes ranges from a single tubule in the opossum (Maruch *et al.*, 1989), to between 10 and 20 in the macaque, ram, boar, stallion and bull (Ramos and Dym, 1977; Hemeida *et al.*, 1978; Hees *et al.*, 1987). Between two and nine efferent ductules have been reported in the laboratory rat (Cooper and Jackson, 1972; Lewis-Jones *et al.*, 1982; Gutroff *et al.*, 1992) and five to 15 in humans (Roosen-Runge and Holstein, 1978; Nistal and Paniagua, 1984; Saithoh *et al.*, 1990). In all species, the ductuli become increasingly convoluted as they near the epididymal duct to form the coni vasculosi, but their total length depends on the relative proximity of the epididymis to the testis. In the laboratory rat, the ductuli efferentes are comparatively long since the epididymis is only loosely attached to the testis, whereas in domestic animals, where there is a closer association of the testis and epididymis, the efferent ductules are correspondingly shorter (Setchell *et al.*, 1994). The walls of the ductuli efferentes are comprised of an epithelium, supported by a thin layer of connective tissue and smooth muscle containing peritubular blood capillaries (Robaire and Hermo 1988).

The ductuli efferentes are unique in that they are the only region of the male reproductive tract to contain ciliated cells in their epithelium. Becker (1856, 1857; cited in Ilio and Hess, 1994) was the first to suggest that the ciliated cells assist in the movement of spermatozoa into the epididymal duct, although they are now thought also to be involved in endocytosis of material from the tubular lumen (Herms *et al.*, 1985; Robaire and Herms, 1988). A second cell type, the non-ciliated, columnar, principal cell, is interspersed between the slightly shorter ciliated cells of the epithelium. Its ultrastructural features, namely numerous apical microvilli, supranuclear vesicles, coated pits and lysosomes are indicative of a role in the uptake of particulate material (endocytosis) and the resorption of fluid during the passage of the luminal contents towards the epididymis (Hamilton, 1975; Herms and Morales, 1984; Jones and Jurd, 1987; Robaire and Herms, 1988). Such functions have been confirmed by tracking the fate of radioactive substances introduced into the luminal environment (Robaire and Herms, 1988).

1.3.2.2 Epididymis

The mammalian epididymis lies adjacent to the testis, extending from its cranial to its caudal pole. Its duct is highly coiled and forms a series of segments that are incompletely delineated by fine septae of connective tissue, with the entire organ being surrounded by a capsule. Variable amounts of intertubular connective tissue occupy the spaces between the coils of the duct and contain the blood and lymphatic vessels and the nerves of the

epididymis. Further connective tissue anchors the epididymis to the tunica albuginea of the testis. In some rodent species, including the laboratory rat and laboratory mouse, adipose tissue accumulates around the ductuli efferentes and their connections to the epididymal duct, forming an epididymal fat pad (Hamilton, 1975).

Macroscopically, the duct of the epididymis can be loosely divided into caput (head), corpus (body) and cauda (tail) regions, according to its orientation relative to the position of the testis. The term caput epididymidis, however, is sometimes also used to collectively refer to the anatomical region containing the ductuli efferentes and the initial segment into which they drain, in addition to the first (proximal) section of the epididymal duct proper (Reid and Cleland, 1957). Histological studies show that, within species, variation in the microscopic structure of the epididymal duct is not necessarily correlated with the gross anatomical divisions and several different duct morphologies may occur within the one anatomical region (Nicander, 1957a,b; Glover and Nicander, 1971; Nicander and Glover, 1973). Furthermore, segments of the epididymal duct displaying a similar histological appearance are not confined to the same anatomical region in different mammalian species (Glover and Nicander, 1971). Consequently, a number of schemes have been proposed for dividing the epididymis into different segments on the basis of either, characteristics of the epididymal epithelium or, functional considerations (Nicander, 1957a,b; Reid and Cleland, 1957; Nicander and Glover, 1973; Hoffer and Karnovsky, 1981). However, a lack of consistency in the application of terminology and variations in the locations of segments between species has led to a certain amount of confusion within the literature when comparing findings between different studies.

One of the earlier studies to note regional differences in the histological structure of the epididymal duct was that of Benoit (1926). He noted that the segment of the epididymis into which the ductuli efferentes empty has a distinct histological appearance, which is common to a range of mammalian species. This region is generally referred to as the initial segment and is usually considered a separate anatomical region from the caput epididymidis (Setchell *et al.*, 1994; Serre and Robaire, 1998). It is characterised by a tall epithelium of predominantly principal cells possessing long, straight, stereocilia and few spermatozoa in the duct lumen (Benoit, 1926).

Detailed descriptions of the structural characteristics of various regions of the epididymis are available for many species including the rabbit (Nicander, 1957a; Jones *et al.*, 1979), rat (Reid and Cleland, 1957; Zunke and Gossrau, 1981) and the stallion, ram and bull (Nicander, 1957b). In most of these studies the epididymal duct has been divided into between six and 12 zones, according to differences based around the height of the epididymal epithelium, the diameter of the duct lumen and changes in the nuclear and

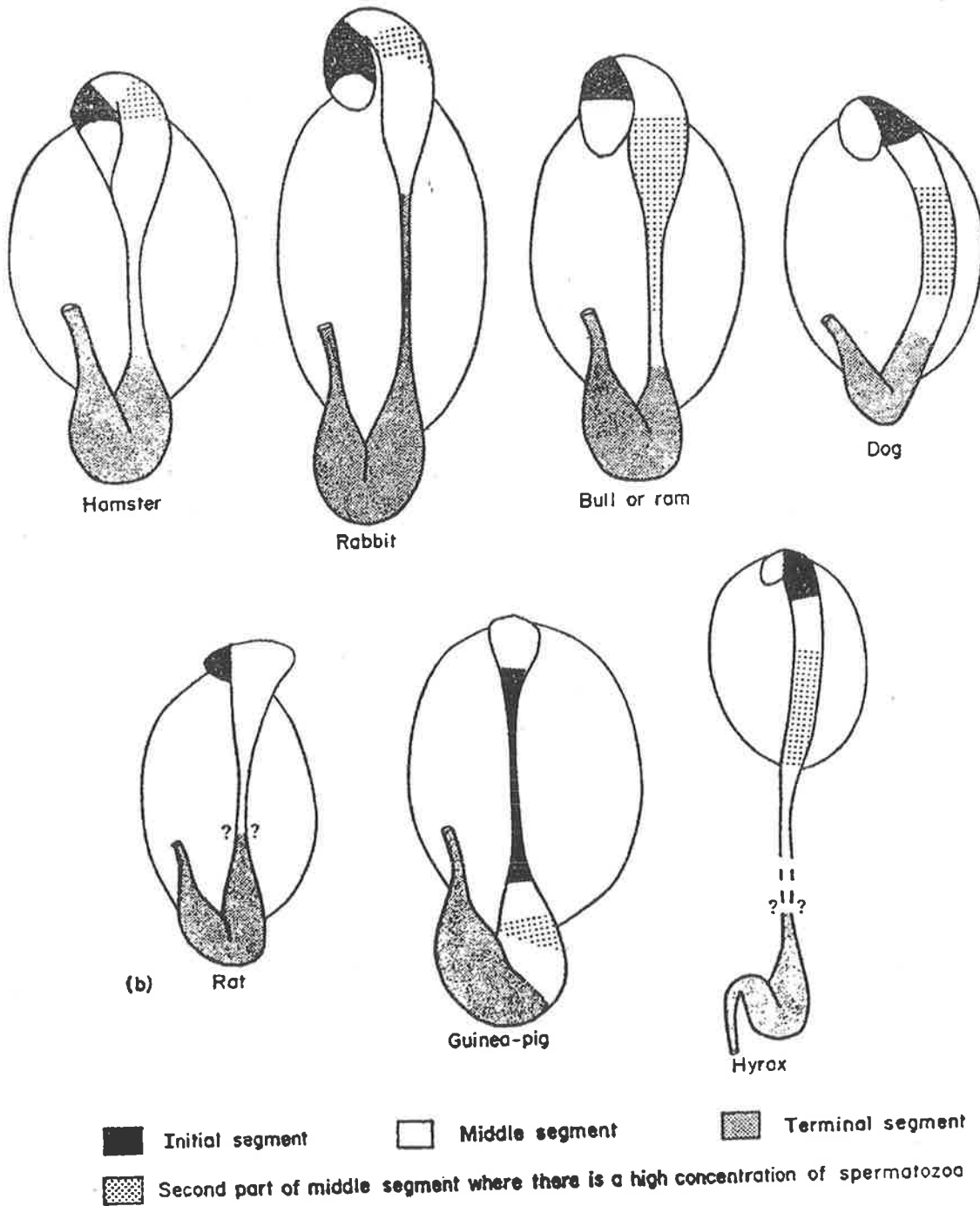
cytoplasmic features of the principal cells. Difficulties, however, have arisen with the subdivisions used in these studies, due to the gradual nature of changes along the length of the epididymal duct and the problem of exactly where to place the boundaries between zones. Consequently, small differences in criteria between studies have led to the emergence of quite different segmental patterns (Hamilton, 1975), some of which are not easily explained in terms of duct function.

A much simpler scheme for subdividing the epididymis, based around functional as well as histological criteria was proposed by Glover and Nicander (1971). They divided the mammalian epididymis into three segments, an initial segment, a middle or intermediate segment and a terminal segment. In their scheme, the initial and middle segments were defined as those regions of the epididymal duct concerned with sperm maturation. Structurally, the initial segment was identified as having long straight stereocilia extending from an epithelium of tall columnar (principal) cells containing apical multivesicular bodies and micropinocytotic vesicles. This corresponds to the initial segment as originally described by Benoit (1926). By comparison, the middle segment was described as having a wider lumen to its duct, stereocilia that were usually bent rather than straight and prominent supranuclear vacuoles within the principal cells. In addition, the portion of the middle segment closer to the terminal segment contained a greater concentration of spermatozoa. The terminal segment was suggested to act primarily as the site of sperm storage. Its characteristics included a low epithelium displaying a few short stereocilia, that surrounded a wide lumen packed with spermatozoa. Multivesicular bodies and micropinocytotic vesicles within the epithelial cells were sparse in comparison with the epithelium of the middle segment.

Glover and Nicander (1971) suggested that their classification scheme could be applied to the epididymides of a wide variety of mammals. This appears to be the case for the species they investigated, although the position and extent of each epididymal segment has been shown to vary between the different mammalian species (Glover and Nicander, 1971; Nicander and Glover, 1973; see also Fig.1.2). Furthermore, the segments generally do not correspond to the caput, corpus and cauda anatomical regions, although in a marsupial, the tamar wallaby, a close correlation between the initial, middle and terminal segments and the caput, corpus and cauda regions has been shown (Jones *et al.*, 1984).

One feature that is apparent from histological and cytological studies of the epididymis is the complex structural organisation of its epithelium. In addition to principal cells, which are by far the most common epithelial cell type along the entire length of the epididymal duct (Hamilton, 1975; Robaire and Hermo, 1988), other cell types including clear, basal, halo, apical, narrow and mitochondria-rich cells (Reid and Cleland, 1957; Hamilton, 1975;

Figure 1.2. Sub-division of the epididymis into initial, middle and terminal segments in a variety of mammalian species. Segments were defined on the basis of functional considerations, as well as histological and cytological criteria. (From Glover and Nicander, 1971).



Robaire and Hermo, 1988; Palacios *et al.*, 1991; Adamali and Hermo, 1996) have been recognised in different species. The functions of these cells are varied. Principal cells play a major role in modification of the luminal microenvironment via both secretion and absorption (Robaire and Hermo, 1988), with their functions under the control of dihydrotestosterone (Robaire and Viger, 1995). Basal cells may play a role in endocytic uptake of material from the epididymal interstitium (Hamilton, 1975) or act as a type of macrophage (Yeung and Cooper, 1994). Clear cells participate in the removal of material from the epididymal lumen (Moore and Bedford, 1979) and in phagocytosis of cytoplasmic droplets of spermatozoa (Hermo *et al.*, 1988), while halo cells are thought to play an immunological role, perhaps as intraepithelial lymphocytes (Dym and Romrell, 1975; Wang and Holstein, 1983; Robaire and Hermo, 1988; Robaire and Viger, 1995). The roles of narrow and apical cells are speculative; it has been suggested that narrow cells are the precursors of clear cells and are involved in the breakdown of endocytosed protein (Robaire and Hermo, 1988; Adamali and Hermo, 1996). The presence of the glutathione S-transferase (GST)-P enzyme in apical cells on the other hand, has led to the suggestion that these cells play a role in the protection of spermatozoa from attack by 'electrophiles' (electron scavenging radicals) within the luminal environment (Adamali and Hermo, 1996). An alternative view is that apical cells merely represent a variant of the principal cell, since morphologically the two cell types are identical in appearance (Sun and Flickinger, 1980; Robaire and Hermo, 1988), however, this now appears less likely as these two cell types have been shown to express different proteins (Adamali and Hermo, 1996).

The various cell types within the epididymal epithelium have been shown to vary in their relative abundance and distribution along the length of the duct and between species (Hamilton, 1975; Robaire and Hermo, 1988). Narrow cells are restricted to the initial segment (Adamali and Hermo, 1996; Serre and Robaire, 1998), whereas clear cells tend to be located further along the duct in the zones corresponding to the lower corpus and cauda epididymides (Hamilton, 1975; Robaire and Hermo, 1988). Such a distribution of cell types supports the concept of regional specialisation of epididymal function. The composition of the epididymal luminal fluid also varies regionally further supporting this concept (see section 1.6.2).

1.3.2.3 Vas Deferens

The vas deferens is a continuation of the epididymal duct beginning in the region of the cauda from where the duct straightens and in scrotal mammals, heads toward the inguinal canal. Its gross anatomical appearance is relatively constant from species to species, although its overall length varies. In the laboratory rat the vas deferens is around 6 cm in

length (Hamilton and Cooper, 1978), whereas in humans the length is closer to 25 cm (Setchell *et al.*, 1994). While this portion of the duct system was once thought to act merely as a muscular conduit connecting the epididymis to the ejaculatory duct and urethra that are involved in expulsion of spermatozoa during ejaculation, it is now accepted that its epithelial lining contributes to regulation of the local luminal environment via both secretion and absorption (Setchell *et al.*, 1994).

As with the epididymis, the vas deferens is comprised of an epithelium supported by a lamina propria, external to which are circularly and longitudinally oriented layers of smooth muscle. In many species, regional variations in the histology of the duct are apparent and include differences in the thickness of the muscle coat, luminal diameter, luminal shape and vascular and nerve supply (Hamilton, 1975; Hamilton and Cooper, 1978; Hamilton, 1990). The muscle coat of the vas deferens generally undergoes a dramatic increase in thickness approximately mid-way along its length, which is accompanied by an increase in the luminal diameter of the duct. In the rat, the luminal shape also varies from round or oval in cross section at the epididymal end of the duct, to stellate, with between two and six folds of the mucosa extending into the lumen towards the urethra (Hamilton and Cooper, 1978). In several species of Australian rodent, the mucosal folds are even more extensive, with some infoldings passing from one side of the duct lumen to the other (Breed, 1986).

The epithelium of the vas deferens is highly differentiated in terms of its cellular structure (Hoffer, 1976; Hamilton and Cooper, 1978; Ramos, 1979; Kennedy and Heidger, 1979). It contains a predominance of principal cells which, in the rat and monkey, increase in height towards the urethral end of the duct (Hamilton, 1990). Basal cells, similar to those of the epididymis and pencil cells also occur and in the human vas deferens, mitochondrion-rich cells have also been described (Hoffer, 1976; Paniagua *et al.*, 1981).

In some species, the terminal portion of the vas deferens closest to the urethra is expanded and forms an ampulla (Price and Williams-Ashman, 1961; Mann and Lutwak-Mann, 1981, Setchell *et al.*, 1994) or gland of the vas deferens (Cooper and Hamilton, 1977). The epithelium of this region is highly secretory (Setchell *et al.*, 1994) and it has been suggested that in males of a few mammalian species including the stallion, jackass and zebra, it may serve as an accessory site of sperm storage (Niemi, 1965; Kennedy and Heidger, 1979; Mann and Lutwak-Mann, 1981), in addition to its role as an important secretory tissue. In the laboratory rat, the epithelium of the terminal portion of the vas deferens has been shown to contain nests of phagocytic cells that remove defective spermatozoa (Cooper and Hamilton, 1977).

1.3.3 Accessory Glands

In mammals, the accessory glands include the vesicular glands (seminal vesicles) and ampullary glands (mentioned in section 1.3.2.3 above), which originate from the Wolffian duct and are associated with the vas deferens and the prostate and bulbourethral glands, derived from the urogenital sinus, that drain into the urethra. Collectively, these glands provide the secretions that, along with those of the epididymis, constitute seminal plasma. Seminal plasma serves as a transport fluid that contains metabolic substrates utilised by spermatozoa during their transit to and deposition within the female reproductive tract at ejaculation. In most murid rodents, secretions from the vesicular and coagulating glands also contribute to the formation of a copulatory plug within the vagina following ejaculation (Gotterer *et al.*, 1955), which may be necessary for the passage of sperm through the cervix (Blandau, 1945; Pang *et al.*, 1979).

Structurally, all of the accessory glands have characteristics in common, although their gross anatomical form, epithelial organisation and the chemical nature of secretions is gland specific (Mann, 1964). In general, the accessory glands are compound tubulo-alveolar glands with a large surface area of secretory epithelium supported by underlying connective tissue and smooth muscle (Price and Williams-Ashman, 1961). Secretory activity is androgen dependent, with the epithelial cells releasing their secretions into glandular lumina where they are stored until ejaculation (Price and Williams-Ashman, 1961; Hamilton, 1990). Large variations occur, however, between different orders of mammals, in both the gross morphology of individual accessory glands and the actual complement of glands that are present (Hamilton, 1990; Setchell *et al.*, 1994).

Prostate glands are present in all male mammals with the possible exception of monotremes (Price and Williams-Ashman, 1961). They range in form from diffuse collections of acini within the connective tissue surrounding the urethra, eg. disseminate prostate of sheep, goats and marsupials, to discrete organs located external to the urethral wall, eg. dog and rodents (Price and Williams-Ashman, 1961). In the bull and boar, both forms of prostatic tissue are present (Setchell *et al.*, 1994). The prostate also varies in its anatomical shape. It is carrot or heart shaped in marsupials (Roger and Hughes, 1973; Noguiera *et al.*, 1985) and 'lobed' in a variety of eutherian mammals (Price and Williams-Ashman, 1961). Rodents display a wide range of variation in the size and shape of their prostates, with several clearly defined lobes being present in the laboratory rat, laboratory mouse and hamster (Jesik *et al.*, 1982; Hamilton, 1990). These lobes are generally named according to their position relative to the urethra, hence dorsal, ventral and lateral lobes have been described for the laboratory rat (Jesik *et al.*, 1982), although the dorsal and lateral lobes may be incompletely separated and hence are sometimes termed the

dorsolateral prostates (Hamilton, 1990). In the guinea pig, dorsal and lateral lobes of the prostate are present, but there is no ventral lobe (Wang and Tse, 1981). The coagulating glands of rodents (rats, mice, hamsters and guinea pigs) are also considered to be part of the prostate gland complex (Ortiz *et al.*, 1956; Price and Williams-Ashman, 1961). This has been supported by observations of histological and ultrastructural similarities between the two glands (Price *et al.*, 1955; Dahl *et al.*, 1973).

Vesicular glands are absent from monotremes, marsupials, carnivores and cetaceans (Roger and Hughes, 1973; Hamilton, 1990), as well as from some species of primates and lagomorphs (Price and Williams-Ashman, 1961). In the laboratory rat and guinea pig, the paired vesicular glands appear externally as simple bag-shaped structures, however, the internal architecture is comprised of highly infolded villous-like projections of the mucosa (Setchell *et al.*, 1994). Interspecific variation in vesicular gland structure relates primarily to size, the degree of ramification of the duct system and lobulation of the secretory tissue (Hamilton, 1990). Epithelial features are generally similar between species (Aumuller, 1979).

The number, size and complexity of bulbourethral glands is highly variable between species. Usually, a single pair of compact glands is present, but as many as three pairs have been observed in marsupials including the hairy-nosed wombat, brown antechinus and tammar wallaby (Roger and Hughes, 1973; Brooks *et al.*, 1978). Bulbourethral glands are absent in marine mammals and some carnivores (Eckstein and Zuckerman, 1956). The glandular alveoli are lined with mucous secreting cells and are connected via ducts to the urethra in the vicinity of the bulb of the penis (Nielsen, 1976).

A particularly unusual complement of accessory glands, unlike that of other rodents, is present in several species of Australian hopping mice within the genus *Notomys* (Breed, 1982a, 1986). These species have bulbourethral glands and unusually large ventral prostates, but their seminal vesicles, dorsolateral prostates, ampullary and coagulating glands are vestigial (Breed, 1982a). It has been suggested that reduction in the size of the latter glands is the reason for the absence of a large vaginal plug post-coitum in females of these species (Breed, 1986, 1997).

1.4 Cell Types in the Seminiferous Tubules

Within the testicular seminiferous tubules, two distinct cell populations, the somatic Sertoli cells and the germ cells, form the seminiferous epithelium. In sexually mature adult males, a number of generations of germ cells that are morphologically and functionally

distinct from each other, namely, spermatogonia, primary and secondary spermatocytes and spermatids are present within the testes at any one point in time and have a layered arrangement within the tubules. The least differentiated cells, the spermatogonia lie closest to the basement membrane, whereas the most differentiated cells, the spermatids, surrounding the tubular lumen (Courot *et al.*, 1970). In addition to the Sertoli cells, a second somatic cell population, the myoid cells, is associated with the tubules. It forms a major component of the boundary tissue delineating the tubule wall and along with the Sertoli cell population, supports the germ cells and coordinates and regulates their development during spermatogenesis.

1.4.1 Peritubular Myoid Cells

Myoid cells are the predominant cellular component of the peritubular tissue and are separated from the cells within the seminiferous epithelium by a basement membrane (Clermont, 1958; Dym and Fawcett, 1970). Multiple layers of myoid cells are present within the boundary tissue of some primate species including humans and monkeys (Hermo *et al.*, 1977), although in rodents only a single layer of cells is generally present (Setchell *et al.*, 1994). Since myoid cells contain contractile factors similar to those in muscle cells (Kormano and Hovatta, 1972), their major role appears to be generating the force that drives the movement of fluid and spermatozoa through the seminiferous tubules towards the rete testis (Russell *et al.*, 1989a,b). There is also evidence, however, that myoid cells play a role in regulating the passage of molecules from the interstitial compartment of the testis to the seminiferous tubules (Kormano, 1967; Dym and Fawcett, 1970). In the laboratory rat numerous coated pits and pinocytotic vesicles have been observed associated with the plasma membranes and within the cytoplasm of myoid cells (Leeson and Leeson, 1963; Dym and Fawcett, 1970). In addition, myoid cells may influence the activity of Sertoli cells, since interactions between these two cell types, including influences on the secretion of specific proteins and deposition of the extracellular matrix, have been demonstrated in culture (Tung and Fritz, 1980; Skinner *et al.*, 1985; Skinner and Fritz, 1985).

1.4.2 Sertoli Cells

Sertoli cells, which are the supporting or sustentacular cells of the seminiferous epithelium, are named after Enrico Sertoli (1865) who first noted their existence and described their appearance. In normal adult testes, they reside among the germ cells, extending the entire epithelial height from the basement membrane to the tubule lumen (Schulze, 1974; Fawcett 1975a; Russell, 1999) and comprise between 14% and 43% of epithelial volume depending on the species (Russell *et al.*, 1990b). Unlike most other cell

types, the general morphology of Sertoli cells cannot be readily deduced from routine light microscopic sections, due to their complex shape and indistinct cell boundaries. They can, however, be identified by an indented nucleus containing a prominent nucleolus that often has a tripartite appearance (Fawcett, 1975a; Russell, 1993). The earliest descriptions of Sertoli cells were based on the appearance of dissociated cells after treatment of the testes with mercuric chloride. These early descriptions of Sertoli cells as being irregular, cylindrical or conical cells with branches that extend apically or laterally and encircle other cells (Sertoli, 1865; translated by Setchell, 1984; Brown, 1885) have been proven to be extremely accurate. Subsequent electron microscopic studies in which individual Sertoli cells have been reconstructed from serially sectioned profiles, confirm they have a complex three-dimensional form (Wong and Russell, 1983; Weber *et al.*, 1983; Russell *et al.*, 1986) that complements the shapes of the adjacent germ cells. Electron microscopy has also revealed specialised sites of attachment between the surfaces of adjacent Sertoli cells (Fawcett *et al.*, 1970; Dym and Fawcett, 1970). Furthermore, various structural features of Sertoli cells are continually changing in coordination with changes in germ cell morphology during spermatogenesis (Elftman, 1950; Kerr and de Kretser, 1975; Kerr *et al.*, 1984; Bugge and Plöen, 1986; Kerr, 1988).

Adjacent Sertoli cells have been shown to exhibit a network of tight (occluding) junctions between their basolateral surfaces just above the level of the least mature germ cell type, the spermatogonia (Dym and Fawcett, 1970). These junctions form the structural basis of the blood-testis barrier (Fawcett *et al.*, 1970) and effectively divide the seminiferous epithelium into two separate functional compartments, a basal compartment which is readily exposed to blood-borne molecules capable of crossing the peritubular boundary tissue and an adluminal compartment containing the more developmentally advanced germ cell types that are effectively isolated from direct exposure to these molecules. Hence, adluminally located germ cells rely, at least in part, upon Sertoli cells for nutrient delivery (Vilar *et al.*, 1962), supply of growth factors and waste disposal (Pelletier and Byers, 1992). A difference in the physiological environment between the two intratubular compartments is maintained by the transient formation of a third intermediate compartment that allows the movement of maturing germ cells from the basal to the adluminal compartment whilst still maintaining an effective barrier (Dym and Fawcett, 1970). This is achieved via the formation of new inter-Sertoli cell tight junctions below the level of early primary spermatocytes prior to disassembly of the ones above them (Russell, 1977a, 1978; Byers *et al.*, 1993).

The cytological features of Sertoli cells are relatively similar for a range of mammalian species (Dym, 1973; Fawcett, 1975a; Chemes *et al.*, 1977; de Kretser *et al.*, 1981; Sinowatz and Amselgruber, 1988) and include cisternae of both smooth and rough

endoplasmic reticulum, mitochondria, Golgi complexes, lysosomes and residual bodies, cytoskeletal elements, glycogen and variable quantities of lipid (Fawcett, 1975a; Russell, 1993). No secretory granules, however, are evident despite the cell's well-documented secretory functions (Griswold, 1993). Although the array of organelles and inclusions within Sertoli cells is unremarkable, the compartmentalised nature of their cytoplasmic distribution points to regional specialisations of cellular function related to differential secretion and the differing physiological and structural requirements of the adjacent germ cell types (Russell, 1993). Several examples of regional structure-function relationships are given below.

Smooth endoplasmic reticulum (SER) is often concentrated in the apical processes of Sertoli cells, adjacent to sites of attachment to elongating spermatids (Clermont *et al.*, 1980). It is continuous with the endoplasmic reticulum surrounding the bulbous portions of Sertoli-spermatid tubulobulbar complexes, which are specialised projections of elongated spermatids and the overlying Sertoli cell plasmalemma that invaginate into the Sertoli cell cytoplasm (Russell and Clermont, 1976; Russell, 1999). These latter structures may anchor the spermatids to the epithelium (Russell and Clermont, 1976) or alternatively facilitate the removal of redundant cytoplasm from spermatids (Russell, 1979a). It has been postulated that the apically located SER acts to transfer material from the cellular processes to the body of the Sertoli cell following phagocytosis of tubulobulbar complexes at spermiation (Russell, 1993).

Cytoskeletal elements (actin filaments, intermediate filaments and microtubules) also have compartmentalised distributions within the Sertoli cell, related to specific functions. At the interfaces between two Sertoli cells and between a Sertoli cell and a spermatid, hexagonal arrays of actin filaments are often observed directly beneath the Sertoli cell plasmalemma and are bordered on their cytoplasmic aspect by a cistern of endoplasmic reticulum (Flickinger and Fawcett, 1967; Dym and Fawcett, 1970). These structures, known as ectoplasmic specialisations (Russell, 1977b), are specific to Sertoli cells and have been suggested to play a role in intercellular adhesion and maintenance of the structural integrity of the seminiferous epithelium (Grove and Vogl, 1989; Vogl *et al.*, 1993). Actin has also been shown to be a major component of tubulobulbar complexes (Russell, 1979; Vogl *et al.*, 1985). Intermediate filaments, which are of the vimentin type (Franke *et al.*, 1979), tend to be concentrated in the base of the Sertoli cell around the nucleus. They also radiate towards attachment sites at the cell's periphery, which are of several different types including desmosome-like and hemidesmosome-like structures and ectoplasmic specialisations (Vogl *et al.*, 1993). These filaments are postulated to play a role in positioning the nucleus and anchoring cells to each other (Lazarides, 1980; Vogl *et al.*, 1993). By contrast, microtubules are located apical to the nucleus and are aligned

parallel to the long axis of the cell (Fawcett, 1975a). This arrangement is considered as a result of the determination of cell shape and the translocation of organelles and of germ cells towards the luminal direction by the Sertoli cells (see review by Vogl *et al.*, 1993).

As stated earlier in this section, Sertoli cell morphology varies cyclically in association with changes in the complement and degree of development of the adjacent germ cells during spermatogenesis. Such cyclical changes of Sertoli cell morphology include variations in:

- a) the overall three-dimensional configuration of the cell (Elftman, 1950; Morales and Clermont, 1993), which is influenced by the types of germ cells associated with it. Two broad categories of Sertoli cell shape, type A and type B have been recognised. Type A Sertoli cells are those that have elongate spermatids within deep cytoplasmic crypts, whereas in type B cells, crypts are shallow or absent due to the apical movement of the spermatids to the lumen in preparation for their release from the epithelium (Wong and Russell, 1983; Russell *et al.*, 1986).
- b) cell volume and surface-to-volume ratio (Bugge and Plöen, 1986; de Franca *et al.*, 1993).
- c) the distribution and abundance of various cytoplasmic constituents including lipid (Kerr and de Kretser, 1975; Kerr *et al.*, 1984), endoplasmic reticulum, lysosomes, Golgi complexes and mitochondria (Kerr, 1988).
- d) the position and shape of the nucleus (Elftman, 1950; Kerr, 1988).

It is also well documented that the functional activity of Sertoli cells varies cyclically in accordance with particular spermatogenic events (Parvinen, 1982, 1993; Parvinen *et al.*, 1986). For example, in the laboratory rat, phagocytic activity is maximal at stage IX of the spermatogenic cycle at which time residual bodies of released spermatids are degraded by lysosomes of the Sertoli cells (Morales *et al.*, 1986). The synthesis and secretion of a range of proteins and growth factors also show cyclical peaks and troughs of activity (Ritzen *et al.*, 1982; Wright *et al.*, 1983; Pineau *et al.*, 1990) and furthermore, the responsiveness of Sertoli cells to the actions of FSH and androgens varies cyclically and is strongly influenced by the surrounding spermatogenic cells (Parvinen, 1982, 1993; Parvinen *et al.*, 1986; Allenby *et al.*, 1991). Hence, it can be seen that structure and function of Sertoli cells is intimately associated with and modulates the structure and function of the various germ or spermatogenic cells and vice versa.

1.4.3 Germ Cells

1.4.3.1 Spermatogonia

The least mature germ cells are the spermatogonia which are found exclusively along the basement membrane of the seminiferous tubules, within the basal compartment. Two classes of spermatogonia are present within the seminiferous tubules, undifferentiated stem spermatogonia and differentiating spermatogonia that are committed to entering spermatogenesis (see section 1.5.3.3). Differentiating spermatogonia are diploid cells that undergo a set number of mitotic divisions that is species specific, prior to the formation of preleptotene primary spermatocytes. They can be divided into three morphological types, A, Intermediate (In) and B, on the basis of their nuclear shape and the quantity of heterochromatin within their nuclei (de Rooij, 1983). Typically, type A spermatogonia are large cells with ovoid nuclei whose long axes lie parallel to the basement membrane of the tubules. Their nuclear chromatin is generally described as 'homogeneous and dust-like' (Setchell, 1978). By contrast, In and type B spermatogonia tend to have slightly less ovoid to rounded nuclei and increased amounts of heterochromatin along the nuclear envelope, hence their chromatin is described as 'crust-like' (Courot *et al.*, 1970), with the most pronounced accumulations of chromatin occurring in type B spermatogonia (Setchell, 1978). The basal surfaces of all spermatogonia are generally flattened along the basal lamina, whereas those surfaces in contact with the surrounding Sertoli cells are rounded (Russell *et al.*, 1990a).

1.4.3.2 Spermatocytes

Preleptotene primary spermatocytes are formed by the final spermatogonial division and are the last spermatogenic cell type to go through the S-phase of the cell cycle (Russell *et al.*, 1990a). Although similar in morphology to type B spermatogonia, they are slightly smaller in size, have less chromatin along the nuclear envelope and fewer protrusions of the chromatin towards the centre of the nucleus (Russell and Frank, 1978). Following replication of their DNA primary spermatocytes enter the long prophase of meiosis in which genetic recombination occurs, prior to two rapid cell divisions, resulting in the production of four haploid spermatids. Over the duration of the meiotic prophase, the primary spermatocytes undergo a gradual morphological transition that includes changes in cell size, nuclear size and the degree of coiling of the nuclear DNA (Russell and Frank, 1978). These latter changes in the appearance of the spermatocyte nucleus form the basis for subdividing the meiotic prophase into phases, as follows:

preleptotene → leptotene → zygotene → pachytene → diplotene.

The leptotene phase signals the real beginning of the meiotic prophase and commences when the crust-like chromatin of the preleptotene primary spermatocytes becomes finely filamentous or thread-like, due to spiralisation and contraction of the DNA into individual chromosomes (Russell *et al.*, 1990a). At this time the cells take on a more rounded form as they move away from the base of the seminiferous tubule (Russell, 1977a; 1978) and subsequently pass into the adluminal compartment. During zygotene, analogous chromosomes form pairs that are attached via synaptonemal complexes. Hence, the chromatin threads appear thicker than those of the leptotene phase do when viewed by light microscopy. Nucleoli are also more prominent than in leptotene cells (Setchell, 1978). Pachytene cells have by far the longest life span (typically 1.5-2 weeks) of any mammalian primary spermatocyte type (Courot *et al.*, 1970), however, they are also the most susceptible to damage from testicular heating (Waites and Ortavant, 1968; Setchell, 1978, 1998). During pachytene, chromosomes are fully condensed, individual chromatids are visible and crossing over between paired chromosomes occurs, resulting in a unique combination of the genetic material, distinct from that of the individual's somatic cells. During the latter half of the pachytene phase, there is also a rapid increase in the size of the cells and their nuclei (Russell and Frank, 1978) and hence the chromosomes appear to be more widely distributed within the nucleus (Russell *et al.*, 1990a). Synthetic capacity of the cells also increases (Monesi, 1965), the nucleoli enlarge and a sex vesicle may become visible (Solari and Tres, 1967). The diplotene phase of primary spermatocyte development is brief and occurs when the nucleus has reached maximum size. The synaptonemal complex between homologous chromosomes dissipates except at chiasmata and tetrads are formed which separate during diakinesis (Setchell, 1978).

In contrast to the long meiotic prophase, the meiotic divisions occur rapidly. At meiosis I, one chromosome of each homologous pair is distributed to each of the two secondary spermatocytes formed. There is no prophase between meiosis I and meiosis II, hence the second meiotic division (of the secondary spermatocyte) follows within hours of the first, resulting in one chromatid from each chromosome separating into each of the haploid spermatids (Clermont, 1972; Steinberger and Steinberger, 1975).

The secondary spermatocytes formed by the first meiotic division are intermediate in size between the primary spermatocytes and early round spermatids. Although morphologically similar to early round spermatids, their nuclei generally contain several patches of more intensely staining chromatin and one or two nucleoli (Setchell, 1978; de Kretser and Kerr, 1994).

1.4.3.3 Spermatids

The spermatids formed by the second meiotic division are morphologically unremarkable, spherical cells containing a centrally placed spherical nucleus. They are about 30% smaller in size than secondary spermatocytes which they resemble morphologically (Russell *et al.*, 1990a). Within their cytoplasm is a well-developed Golgi complex, a pair of centrioles and numerous mitochondria that are either dispersed throughout the cytoplasm or lie adjacent to the plasmalemma (Russell *et al.*, 1990a; de Kretser and Kerr, 1994). The transformation of these round spermatids into highly differentiated, species specific, spermatozoa is known as spermiogenesis and involves the simultaneous occurrence of a number of morphogenic processes including the development of an acrosome, the development of a flagellum, condensation and elongation of the nucleus, mitochondrial reorganisation and removal of excess cytoplasm made redundant by the reshaping process of the cell (Courot *et al.*, 1970; Clermont, 1972; Setchell, 1978; Russell *et al.*, 1993; Sharpe, 1994). Numerous descriptions of spermiogenesis, at both the light and electron microscopic levels, are available for a range of mammalian species (Leblond and Clermont, 1952b; Clermont and Leblond, 1955; Oakberg, 1956a; Clermont, 1963; Plöen, 1971; Holstein, 1976; Lalli and Clermont, 1981; Plöen *et al.*, 1979; Russell *et al.*, 1990a), as well as several review articles covering the subject in detail (Fawcett, 1975b; Meistrich, 1993; de Kretser and Kerr, 1994). Hence, only the major morphological changes of spermiogenesis will be summarised here.

The acrosome of the spermatid originates from the Golgi complex, which elaborates a number of small proacrosomal granules that coalesce to form a single acrosomal granule. The acrosomal granule and its vesicle migrate towards the nucleus and become associated with the nuclear envelope from where the vesicle spreads over the nuclear surface. The extent of coverage of the nucleus by the acrosome varies widely between species, ranging from 25% to 60% and in some species it also extends beyond the nucleus to form an apical segment (Fawcett, 1970; Fawcett, 1975b; de Kretser and Kerr, 1994). Following formation of the acrosome, the Golgi complex migrates caudally and is eventually included in the residual cytoplasm detached from the spermatozoon at spermiation (Fawcett and Phillips, 1969a; Fawcett *et al.*, 1971).

As the acrosome is forming, the position of the nucleus changes from central to eccentric, with the nuclear pole covered by the acrosome placed closest to the plasmalemma. This repositioning is accompanied by the progressive condensation of the nuclear chromatin, although the degree of condensation and its timing in relation to other events of spermiogenesis varies between species, eg. nuclear condensation occurs subsequent to nuclear elongation in the rat and mouse (Meistrich, 1993), but the two processes appear to

occur simultaneously in the dog (Russell *et al.*, 1990a). Concomitant with nuclear condensation are changes to the nuclear proteins that stabilise chromatin structure. The histones of round spermatid nuclei are replaced by transitional proteins and eventually protamines (Meistrich, 1989).

The other major nuclear event is its reshaping. In rodents there are dramatic changes to the nuclear and head shape of the spermatid from spherical to a highly asymmetrical falciform shape, whereas in other species such as the human and domestic animals, the final nuclear shape is more spatulate (Setchell, 1982). Exactly how nuclear reshaping is brought about is still open to debate, however, several possibilities have been put forward:

- a) Nuclear shaping is brought about by the manchette, a network of microtubules that appear transiently within the spermatid cytoplasm and extend from the nuclear ring to surround the caudal aspect of the nucleus. It was noted that the manchette appears at the time when nuclear elongation and shaping occur, hence a causal relationship was proposed (Clark, 1967).
- b) Nuclear shaping and sperm head shape are the result of a genetically controlled pattern of chromatin condensation and aggregation of nuclear proteins (Fawcett *et al.*, 1971).

More recent studies tend to suggest that a combination of genetically controlled inherent nuclear components and external influences may play a role in determining the final nuclear shape of spermatids (Meistrich, 1993). This is based on data from a range of investigations. DNA, chromatin structure and nuclear proteins probably contribute to some aspects of nuclear shape by providing resistance to external pressures, but no convincing evidence exists to suggest that they are the sole or major determinants of nuclear shape (Meistrich, 1993). On the other hand, abnormal manchette development is associated with deformed nuclear shape in *azh/azh* mutant mice (Meistrich *et al.*, 1990). Likewise, manipulation of microtubular elements within the spermatid cytoplasm also suggests some input from the manchette (Russell *et al.*, 1991), however, the mechanism by which this occurs is still to be elucidated. Finally, shaping forces may be transmitted from subacrosomal actin filaments within the spermatid, or from cytoskeletal elements of the surrounding Sertoli cell, indirectly via the acrosome, to the nucleus (Meistrich, 1993).

The tail of the spermatid arises from the centrioles, which migrate to a position beneath the plasmalemma, opposite to the pole where the acrosome is developing. The distal centriole is oriented perpendicular to the cell's surface and gives rise to the axoneme of the tail and the proximal centriole lies at right angles to it (de Kretser, 1969; Fawcett and Phillips, 1969b). The tail develops as an elongation of the axoneme (nine outer doublet microtubules surrounding an inner pair of single microtubules) covered by the plasmalemma that protrudes from the spermatid. At the base of the tail, however, a ring-

like structure, the annulus, attaches the plasmalemma to the distal centriole so that when the spermatid cytoplasm moves distally, a canal is formed between the cytoplasmic lobes and the spermatid tail. As the axoneme continues to elongate, the dense outer fibre complex arises in continuity with and external to the outer doublet microtubules (Fawcett and Phillips, 1969b). Below the level of the annulus, the fibrous sheath (circumferential rib-like structures joined at intervals to two fibrous columns formed from dense fibres three and eight) surround the dense fibres in the principal piece and above it the mitochondria of the spermatid come to surround the dense outer fibres in a helical fashion late in spermiogenesis after dissolution of the manchette (Fawcett *et al.*, 1971) to form the middle piece of the tail. Concurrently with tail development, the proximal centriole gives rise to a sheet of dense material that develops into the capitulum or connecting piece that attaches the tail to the nucleus at the implantation fossa on the caudal nuclear surface (Setchell, 1978).

The cellular reorganisation of the spermatid during spermiogenesis results in a large quantity of redundant cytoplasm and organelles and it has been estimated that around 75% of all spermatid cytoplasm is eliminated (Sprando and Russell, 1987). A reduction in the amount of cytoplasm occurs via water elimination during spermatid elongation (Sprando and Russell, 1987) and loss via tubulobulbar complexes (Russell and Clermont, 1976; Russell, 1979b; Russell and Malone, 1980). Most of the excess cytoplasm and organelles are removed, however, after their displacement caudally within the cell, which is possibly facilitated by the manchette (Fawcett *et al.*, 1971). A cytoplasmic lobe then forms at the junction between the head and tail of the spermatid and invaginates into the Sertoli cell. This cytoplasmic lobe or residual body is pinched off from the spermatid at its release from the seminiferous epithelium (Fawcett and Phillips, 1969a). It remains embedded in the cytoplasm of the Sertoli cell (Sapsford *et al.*, 1969) which subsequently phagocytoses it (Kerr and de Kretser, 1974). The final small amount of excess cytoplasm remains attached to the released spermatozoon as a cytoplasmic droplet that migrates from the neck region to the junction of the middle and principal pieces of the tail, from where it is removed during epididymal transport.

1.5 Spermatogenesis

The process by which undifferentiated cells of the germ line (spermatogonial stem cells) are transformed into the highly differentiated spermatozoa is known as spermatogenesis (Clermont, 1972; Barratt, 1995). The general arrangement of spermatogenesis is essentially the same in all mammals and can be divided into three phases through which all germ cells pass sequentially over time. These are:

- a) a proliferative phase during which germ cells undergo rapid, successive divisions that increase the size of the cell population available to enter meiosis. The actual number of cell divisions between division of the spermatogonial stem cell and meiosis determines the potential number of spermatozoa that can be produced by males and varies between species (Clermont, 1962, 1963; Amann, 1981; Paniagua *et al.*, 1987a). By way of example, in the laboratory rat, the pre-meiotic cell population is increased by one thousandfold during the proliferative phase, whereas only a fourfold increase in the germ cell population is achievable by subsequent phases of spermatogenesis (Russell *et al.*, 1990a).
- b) meiosis. Each primary spermatocyte should, theoretically, give rise to four haploid, spermatids, however, cellular degeneration always accompanies the meiotic divisions, thereby reducing the overall cell yield (Roosen-Runge, 1973).
- c) cytodifferentiation or spermiogenesis. During this phase, each of the round haploid germ cells is transformed into the species-specific form of the spermatozoon that is structurally equipped to reach and fertilise the egg. As summarised previously, this transformation includes development of an acrosome, elongation and condensation of the nucleus, formation of a flagellum and removal of surplus organelles and cytoplasm as residual bodies (Courot *et al.*, 1970; Clermont, 1972; Setchell, 1978; Russell *et al.*, 1990a; Sharpe, 1994; de Kretser and Kerr, 1994).

1.5.1 Cellular Associations, Cycles and Waves of the Seminiferous Epithelium

As early as the 1880s it was observed that in the testes, germ cells at different stages of spermatogenesis surround the lumen of the seminiferous tubule in layers and combine to form discrete groups, or cellular associations, of constant composition (Brown, 1885; Benda, 1887; von Ebner, 1888). It was also noted that at any one time, a number of such cellular associations can be seen in cross sections of a seminiferous tubule and along its length (von Ebner, 1871; Brown, 1885; Benda, 1887; von Ebner, 1888; Regaud, 1901). These observations gave rise to the concepts of the cycle and the wave of the seminiferous epithelium. It was postulated that, within any given area of a seminiferous tubule, the various cellular associations succeed each other in an ordered sequence over time. Furthermore, it was suggested that the sequence repeats itself indefinitely, resulting in a 'spermatogenic cycle' of the epithelium (Brown, 1885; Benda, 1887; von Ebner, 1888; Regaud, 1901). Hence, the cycle of the seminiferous epithelium was defined as 'that series of changes occurring in a given area of the seminiferous epithelium between two successive appearances of the same cellular association' (Leblond and Clermont, 1952a), with each individual cellular association representing a stage of the cycle of the seminiferous epithelium. It was also postulated that at any one point in time, a similar spatial arrangement of cellular associations occurs. Thus, the wave of the seminiferous

epithelium was defined as a complete sequence of all cellular associations arranged consecutively along the length of a tubule (von Ebner, 1888). In each wave, successive cellular associations occupy a discrete segment of the tubule (Benda, 1887; Regaud, 1901). Subsequent studies have shown, however, that waves are often incomplete and reversals in the order of segments, known as modulations, commonly occur within waves (Curtis, 1918; Perey *et al.*, 1961; Hochereau, 1963a). Hence, the definition of a wave of the seminiferous epithelium has been modified to include any modulations occurring within the complete sequence of cellular associations along the length of a tubule (Russell *et al.*, 1990a).

Despite these early insights into the relationship between the static appearance of the seminiferous epithelium and the dynamic spermatogenic process, the full significance of such a relationship as the basis for understanding the kinetics of spermatogenesis was not fully recognised until the 1950s when a number of qualitative and quantitative investigations of the seminiferous epithelium were conducted in rodents and artiodactyls (Roosen-Runge and Giesel, 1950; Leblond and Clermont, 1952a,b; Oakberg, 1956a,b; Ortavant, 1958). Other studies involving the labelling of germ cells with radioactive tracers including adenine-8- C^{14} (Sirlin and Edwards, 1955, 1958), ^{32}P (Ortavant, 1956) and 3H -thymidine (Clermont *et al.*, 1959; Hochereau *et al.*, 1964) confirmed that germ cells undergoing spermatogenesis progress through the various cellular associations in a cyclical manner during their development. Since then, numerous authors have described cellular associations in a range of mammalian species (see Clermont, 1972, Russell *et al.*, 1990). These studies, with the exception of those on the human (Clermont, 1963; Heller and Clermont, 1963, 1964; Schulze and Rehder, 1984) and several other primate species (Clermont and Antar, 1973; Chowdhury and Steinberger, 1976; Chowdhury and Marshall, 1980; de Rooij *et al.*, 1986), confirm a similar organisation of the seminiferous epithelium in the majority of mammals. Features in common include:

- a) the occurrence of cellular associations of fixed composition, that is, only cells at specific points in their development are observed together in the seminiferous epithelium,
- b) a segmental arrangement of consecutive cellular associations in waves, along the length of seminiferous tubules, or a spiral arrangement of cellular associations around the tubular wall in some primate species and
- c) the presence of a single cellular association per seminiferous tubular cross section (except in humans and some other primates).

Despite these features in common, there is variation in the number and generational composition of cellular associations (stages of the cycle of the seminiferous epithelium) between species. Part of this variation arises as a result of the application of methods

based on different sets of criteria when defining the boundaries between cellular associations (Roosen-Runge and Giesel, 1950; Leblond and Clermont, 1952a; Foote *et al.*, 1972; Clermont, 1972; Swierstra *et al.*, 1974; Berndtson, 1977). In mammals, identification of cellular associations or cycle stages generally follows one of two schemes. The first scheme, known as the 'tubular morphology' system (Berndtson, 1977), is based on changes in the shape of spermatid nuclei, the degree of maturation (meiotic stage) of spermatocytes and the relative position of each germ cell generation and in particular the elongate spermatids, within the seminiferous epithelium. The second scheme, known as the acrosomal system, is based on changes in nuclear morphology and the shape of the acrosome of maturing spermatids following staining with periodic acid-fuchsin sulphurous acid (PA-FSA) (Leblond and Clermont, 1952b). Application of the different schemes has thus resulted in the identification of varying numbers of cellular associations even in the one species. For example, in the laboratory rat, 10 (Brown, 1885), six (Benda, 1887), 12 (von Ebner, 1888), eight (Roosen-Runge and Giesel, 1950) and 14 (Leblond and Clermont, 1952a,b) associations respectively, were recognised in thick, paraffin-embedded testis sections. More recently, 14 cellular associations were described for the rat, based on spermatid appearances in perfusion fixed, plastic-embedded tissues (Hess, 1990; Russell *et al.*, 1990a).

Interspecific variability in the composition of cellular associations, however, may also reflect species differences in the timing of developmental events of spermatogenesis and in the final form of the spermatid. For example, mitosis of type A to give rise to intermediate spermatogonia occurs in stage II-III in the rat and stage I in the mouse, using the same staging criteria (Russell *et al.*, 1990a).

1.5.2 Duration of Spermatogenic Cycles

The duration of the cycle of the seminiferous epithelium and its stages has been determined in numerous mammalian species (see reviews by Courot *et al.*, 1970; Clermont, 1972; Russell *et al.*, 1990a; Sharpe, 1994). As is evident from Table 1.1, cycle duration varies markedly between species and even between different strains within the one species. For example, cycle duration in three strains of rat is reported to differ, being $12.0 \pm \text{SD } 0.2$ days in the Sherman rat (Clermont *et al.*, 1959), $12.9 \pm \text{SD } 0.3$ days in the Sprague-Dawley rat (Clermont and Harvey, 1965) and a constant 13.3 days in the Wistar rat (Huckins, 1965). More recently, however, cycle duration in Sprague-Dawley rats ($12.49 \pm \text{SEM } 0.05$ days) and feral Brown/Norway rats ($12.44 \pm \text{SEM } 0.06$ days) has been found to be remarkably similar (Rosiepen *et al.*, 1994). Hence it was suggested that the variation in cycle duration between strains could, in part, arise as a consequence of the method of its calculation. In the above studies, calculation of cycle duration is based upon

the frequency of occurrence of stages of the cycle of the seminiferous epithelium, in conjunction with the tracking of labelled germ cells. Stage frequency, in turn, is based on the ability to recognise particular cycle stages, therefore, differences in recognition of cycle stages by different investigators, could have accounted for subsequent differences in cycle duration between strains (Hess *et al.*, 1990; Rosiepen *et al.*, 1994).

Another method for determining cycle duration is to monitor the rate of disappearance and/or recovery of germ cell types within the seminiferous epithelium following X irradiation (Shaver, 1953; Oakberg, 1956b; de Rooij *et al.*, 1986). Using this method, duration of the cycle of the seminiferous epithelium in the C3H mouse was estimated to be 8.63 days (Oakberg, 1956b). A value of 8.62 days was later obtained for the same mouse strain using ^3H -thymidine labelling and autoradiographic tracking of germ cells (Clermont and Trott, 1969). In the rhesus monkey however, values obtained for cycle duration using the two methods were different, being 9.5 days with the ^3H -thymidine labelling method (Barr, 1973) and 10.5 days as calculated from the depletion of germ cells from the seminiferous epithelium following X-irradiation (de Rooij *et al.*, 1986). This difference was, however, explained by a slight error in interpretation of the position of the label front in stages VII and VIII of the seminiferous epithelium in the former study. When the most advanced labelled cells were considered to be the preleptotene primary spermatocytes of stage VIII rather than stage VII, the cycle duration (10.3-10.6 days) was found to be the same for the two methods (de Rooij *et al.*, 1986).

It is unlikely, however, that interspecific variation in cycle duration can be attributed to differences in calculation methods or interpretation of data between investigators. Results from numerous studies show that despite similarities in the organisation of the seminiferous epithelium between mammals (as outlined in section 1.5.1), each species has its own characteristic composition of cellular associations (Russell *et al.*, 1990a). Furthermore, the frequency with which each of these cellular associations or cycle stages occurs within tubular cross sections at any one point in time is also species specific (Courot *et al.*, 1970; Clermont, 1972; Sharpe, 1994). Stage composition and frequencies for strains within a species are, however, similar (Clermont *et al.*, 1959; Clermont and Harvey, 1965; Clermont and Trott, 1969).

Within mammals, the duration of the cycle of the seminiferous epithelium ranges from 6.7 days in the bank vole (Grocock and Clarke, 1976) to 17.3 days in the white-belly opossum (Queiroz and Nogueira, 1992). Closely related species generally appear to have cycles of similar duration, although this is not always the case. For example, as can be seen in Table 1.1, the cycle duration in humans (16 days) is considerably longer than that of other primates (9.5-11.6 days). Such interspecific differences in the duration of the

Table 1.1
Duration of the Cycle of the Seminiferous Epithelium and Spermatogenesis of
Mammalian Species for which data have been Calculated

Species	Cycle Length (Days)	Duration of spermatogenesis (Days)	Reference
<u>Rodentia</u>			
Laboratory rat, <i>Rattus rattus</i>			
- Sherman strain	12.0	48	Clermont <i>et al.</i> (1959)
- Sprague-Dawley strain	12.9	51.6	Clermont & Harvey (1965)
	12.49		Rosiepen <i>et al.</i> (1994)
- Wistar strain	13.3	53.2	Huckins (1965)
	12.8		Hilscher & Hilscher (1969)
Brown/Norway rat, <i>Rattus norvegicus</i>	12.44		Rosiepen <i>et al.</i> (1994)
bandicoot rat, <i>Bandicota bengalensis</i>	10.0	40.0	Sinha Hikim <i>et al.</i> (1985)
Laboratory mouse, <i>Mus musculus</i>			
- C3H strain	8.63	34.5	Oakberg (1956b)
	8.62	35	Clermont and Trott (1969)
- Swiss strain	8.88	35	Clermont and Trott (1969)
Syrian/golden hamster, <i>Mesocricetus auratus</i>	8.74	35	Clermont and Trott (1969)
	9.0		de Rooij (1968)
Chinese hamster, <i>Cricetulus griseus</i>	17.0		Oud & de Rooij (1977)
guinea pig, <i>Cavia porcellus</i>	8.45	33.8	Noller <i>et al.</i> (1977a)
vole, <i>Microtus agrestis</i>	7.9	36.6	Grocock & Clarke (1976)
prairie vole, <i>Microtus ochrogaster ochrogaster</i>	7.17	28.68	Schuler & Gier (1976)
bank vole, <i>Clethrionomys glareolus</i>	6.7	31.0	Grocock & Clarke (1976)
<u>Lagomorpha</u>			
rabbit, <i>Orytolagus cuniculus</i>	10.7	42-47	Amann <i>et al.</i> (1965)
	10.9	51.8	Swiestra & Foote (1965)
<u>Primates</u>			
Human, <i>Homo sapiens</i>	16	64	Heller & Clermont (1963)
	16	74	Heller & Clermont (1964)
baboon, <i>Papio cynocephalus</i>	10.2	39	Barr, (1973)
olive baboon, <i>Papio anubis</i>	11	42	Chowdhury & Steinberger (1976)
rhesus monkey, <i>Macaca mulatta</i>	9.5	36	Barr (1973)
	10.5		de Rooij <i>et al.</i> (1986)
squirrel monkey, <i>Saimiri sciureus</i>	10.2	39	Barr (1973)
African green monkey, <i>Cercopithecus sabaeus</i>	10.2	39	Barr (1973)
Monkey, <i>Macaca arctoides</i>	11.6	44	Clermont & Antar (1973)
Monkey, <i>Macaca speciosa</i>	11.6	44	Antar (1971)
Monkey, <i>Macaca fascicularis</i>	9.3		Dang (1971)
	10.5	42	Fouquet & Dadoune (1986)

Table 1.1 continued
Duration of the Cycle of the Seminiferous Epithelium and Spermatogenesis of
Mammalian Species for which data have been Calculated

Species	Cycle Length (Days)	Duration of spermatogenesis (Days)	Reference
<u>Carnivora</u>			
dog, <i>Canis canis</i>	13.6		Foote <i>et al.</i> (1972)
coyote, <i>Canis latrans</i>	13.6	54.4	Kennelly (1972)
blue fox, <i>Alopex lagopus</i>	12.0	48	Berg <i>et al.</i> (1990)
<u>Artiodactyla</u>			
Bali cattle, <i>Bos sondaicus</i>	11.75		McCool (1989)
Bull, <i>Bos taurus</i>	13.5	55	Amann (1962)
	13.5		Hochereau <i>et al.</i> (1964)
	13.5		Ross & Entwistle (1979)
zebu, <i>Bos indicus</i>	14.0	56	Cardoso & Godinho (1983)
bull/zebu cross, <i>B. taurus</i> x <i>B. indicus</i>	13.41		Salim & Entwistle (1982)
buffalo, <i>Bubalus bubalis</i>			
- riverine strain	8.6	38	Sharma & Gupta (1980)
- swamp strain	8.74		Mc Cool <i>et al.</i> (1989)
ram, <i>Ovis aries</i>	10.4	49	Hochereau <i>et al.</i> (1964)
boar <i>Sus sufa</i>	8.6	34.4	Swierstra (1968a)
<u>Perissodactyla</u>			
Stallion, <i>Equus equis</i>	12.2	49	Swierstra <i>et al.</i> (1974)
<u>Edentata</u>			
nine-banded armadillo, <i>Dasybus novemcinctus</i>	8.15	32.6	Torres <i>et al.</i> (1981)
<u>Chiroptera</u>			
grey-headed fruit bat, <i>Pteropus poliocephalus</i>	16.0		McGuckin & Blackshaw (1987)
<u>Marsupialia</u>			
white-belly opossum, <i>Didelphis albiventris</i>	17.3	69.2	Queiroz and Nogueira (1992)
Tammar wallaby, <i>Macropus</i> <i>eugenii</i>	17		Setchell & Carrick (1973)
Bennett's wallaby, <i>Macropus rufogriseus</i>	16		Setchell & Carrick (1973)
brushtailed possum, <i>Trichosurus vulpecula</i>	15		Setchell & Carrick (1973)

spermatogenic cycle (and of spermatogenesis) have implications for sperm production. Since spermatogenesis generally takes about four cycles in most mammalian species, for any given time period, an individual with a shorter duration of spermatogenesis will produce more sperm than one with a longer duration of spermatogenesis (Johnson, 1986b; 1995). A knowledge cycle duration and of the timing of particular spermatogenic events is also useful for evaluating the effects of various treatments and drugs on germ cells.

1.5.3 Sperm Production

The total number of spermatozoa produced per day by the two testes of an individual is known as the index of sperm production or daily sperm production, DSP (Amann, 1970a; 1981) and is highly variable among individual males, both within a species and between species. For any individual (or species) it is apparent that a range of variables influences the number of spermatozoa produced per unit time. These include:

- a) the size of the testes.
- b) the relative proportion of the testicular tissue devoted to sperm production.
- c) the number of Sertoli cells and their supportive capacity.
- d) the duration of spermatogenesis (see section 1.5.2.2).
- e) the size of the spermatogonial pool committed to entering spermatogenesis (number of mitoses of differentiating spermatogonia).
- f) the ability of developing germ cells to successfully complete their maturation into spermatozoa.

Furthermore sperm production may vary seasonally within certain species.

The variables affecting sperm production fall into two categories, those that relate to the overall capacity or ability of an individual to produce sperm, (eg. testis size, amount of seminiferous epithelium, number of Sertoli cells, duration of spermatogenesis, spermatogonial number) and hence determine the theoretical maximum sperm output and those that influence the efficiency of sperm production, regardless of potential capacity. The latter include the supportive capabilities of Sertoli cells and the amount of germ cell degeneration (Johnson, 1995). These various parameters will be discussed in greater detail below.

1.5.3.1 Testis Size and Sertoli Cell Number

It is obvious that an individual with large testes will produce more sperm than one with small testes, provided that the composition of the testes is similar in both. Numerous studies have found a high correlation between daily sperm production and testicular weight for continuous breeders (Kirton *et al.*, 1967; Lambiase and Amann, 1969; Amann *et al.*,

1976; Amann, 1981; Berndtson and Thompson, 1990) and for seasonal breeders during the breeding season (Johnson *et al.*, 1994). However, as pointed out in section 1.3 of this chapter, the relative volume of the testes occupied by the sperm producing seminiferous tubules (as opposed to interstitial tissue) varies between species, ranging from less than 33% in the woodchuck (Russell *et al.*, 1990b), to 40-60% in humans (Johnson *et al.*, 1980a; Russell *et al.*, 1990b) and around 90% in laboratory rodents (Roosen-Runge, 1955a; Fichna and Malendowicz, 1975; Mori *et al.*, 1982). Huge interspecific variations have also been noted in the relative testicular volume of seminiferous tubules between species of Australian rodents (Breed, 1982a; 1997). Consequently, a testis containing a greater proportion of seminiferous tubules and particularly of seminiferous epithelium, is capable of producing more spermatozoa than one of the same size with relatively less seminiferous epithelium (Kennelly, 1960, cited in Amann, 1970a; Johnson *et al.*, 1980a; Johnson *et al.*, 1994). Furthermore, various data show that a highly positive relationship exists between the number of Sertoli cells contained within the seminiferous tubules and both testis size and DSP (Sharpe, 1994).

Analyses of adult testis weights, Sertoli cell numbers and DSP indicate large positive correlations between absolute Sertoli cell number and DSP and absolute Sertoli cell number and testis weight in humans (Johnson *et al.*, 1984b; Cortes *et al.*, 1987) and bulls (Berndtson *et al.*, 1987a,b). Within a species, those individuals with a greater absolute number of Sertoli cells have larger testes and produce more spermatozoa than their counterparts with fewer Sertoli cells. A positive relationship between Sertoli cell number and both adult testis size and sperm production has also been confirmed by studies in which Sertoli cell numbers have been manipulated during the proliferative phase of their development (see also section 1.2.4). In the laboratory rat, inhibition of Sertoli cell proliferation neonatally results in fewer Sertoli cells, reduced testicular weight and reduced sperm output in adulthood (Orth *et al.*, 1988). By contrast, prolongation of the proliferative period results in increased Sertoli cell numbers, increased testicular weight and increased sperm output of adult laboratory rats (Cooke, 1991; Cooke and Meisami, 1991; Cooke *et al.*, 1991; Cooke *et al.*, 1992; van Haaster *et al.*, 1992). It should be noted that the manipulation of Sertoli cell numbers has no effect on the spermatogenic process or on the quality of spermatozoa, just on the numbers of spermatozoa produced (Sharpe, 1994). Hence all of these data point to the absolute Sertoli cell number per individual as being an important determinant of spermatogenic potential, which is the maximum possible number of spermatozoa that can be produced by that individual. Actual production, however, may be much lower than potential production, due to variations in the support capacity of Sertoli cells and differences in the amount of germ cell loss.

Given that the size of the testes, the relative proportion of tubular tissue and the number of Sertoli cells vary between species, as does the duration of spermatogenesis, it is difficult to make meaningful comparisons between individuals or species of actual sperm production, without standardisation of these parameters. Therefore, for comparative purposes, sperm production is often expressed as an index of the efficiency of sperm production. The most common index of sperm production that can be applied across individuals or species is DSP/g testis (Amann, 1970a). Values of DSP/g testis have been determined from, either quantitative testicular histology (Swierstra, 1968b, 1971; Orgebin-Crist, 1968), or the enumeration of resistant spermatid nuclei in testicular homogenates (Amann and Lambiase, 1969; Amann *et al.*, 1976; Robb *et al.*, 1978; Blanchard and Johnson, 1997a). Raw cell counts per unit weight/volume are determined and then corrected for the lifespan of the cell (which varies between species). Using these methods average DSP/g testis in human males was found to be around $3\text{--}4.3 \times 10^6$ (Amann and Howards, 1980; Johnson *et al.*, 1980a,b), compared to $10\text{--}13 \times 10^6$ in bulls (Amann 1981), $11\text{--}19 \times 10^6$ in stallions (Amann, 1981; Blanchard and Johnson, 1997b), $21\text{--}24 \times 10^6$ in rats (Johnson *et al.*, 1980a; Amann, 1981), 23×10^6 in rhesus monkeys (Amann *et al.*, 1976) and 26.5×10^6 in rabbits (Orgebin-Crist, 1968). Hence, these results indicate a much lower spermatogenic efficiency of human testes compared to those of other mammals.

1.5.3.2 Germ Cell: Sertoli Cell Ratio

It is well documented that each Sertoli cell can support only a finite number of germ cells through their development into spermatozoa (Russell and Peterson, 1984; Russell *et al.*, 1990; Berndtson and Thompson, 1990). Therefore the ratio of germ cells to Sertoli cells and in particular the elongate spermatid to Sertoli cell ratio, provides another measure of the relative efficiency of sperm production in mammals. A direct relationship has been shown between the germ cell to Sertoli cell ratio and daily sperm production within horses. Stallions with low daily sperm production have a reduction in the ratio of all germ cell types to Sertoli cells (18.6 cf. 25.4 germ cells per Sertoli cell), but in particular, have fewer elongated spermatids (5.2 cf. 9.6) per Sertoli cell, than stallions with high DSP (Blanchard and Johnson, 1997b). A higher rate of germ cell degeneration (lower yield) between early and late primary spermatocytes and round to elongated spermatids in low compared to high DSP animals is apparent from the data presented and it was suggested to be due to, either a compromised ability of the Sertoli cells to support germ cell maturation, or the presence of defects in germ cells that predispose them to degeneration (Blanchard and Johnson, 1997b).

Large interspecific differences in germ cell to Sertoli cell ratios have also been documented and generally concur with estimations of the relative efficiency of sperm

production of various species as measured by values of DSP/g testis (Amann, 1981; Russell and Peterson, 1984; Sharpe, 1994). In the human, the ratio of elongate spermatids to Sertoli cells is between two and four (Rowley and Heller, 1971; Skakkebaek and Heller, 1973; Skakkebaek *et al.*, 1973, Sharpe, 1994), compared to 8.4-10.3 in the rat (Wing and Christensen, 1982; Russell and Peterson, 1984) more than 10 in the stallion (Johnson, 1986a), hamster, gerbil and guinea pig (Russell and Peterson, 1984) and 12.2 in the rabbit (Russell and Peterson, 1984). In the rhesus monkey, cynomolgous monkey and the orang-utan (which are the only other primate species for which germ:Sertoli cell data are available), each Sertoli cell supports 5.9, 8.2 and 5.7 elongate spermatids respectively (Russell and Peterson, 1984; Sharpe, 1994). Similarly, the ratio of all germ cells to Sertoli cells is 16.6:1 in the laboratory rat (Wing and Christensen, 1982) and 28.5:1 in the stallion (Johnson, 1986a), but only 13.3 in the human (Skakkebaek and Heller, 1973). These latter data, however, were not all derived via the same methods and hence probably do not take into account species differences in the relative size and/or volume of the various germ and Sertoli cells. Nevertheless, humans are clearly the least efficient species at producing spermatozoa, regardless of how efficiency is measured.

1.5.3.3 Spermatogonial Mitoses

Another factor that affects spermatogenic potential is the actual supply of type B spermatogonia ready to enter meiosis. It is apparent that the number of type B spermatogonia determines the number of primary spermatocytes. Hence a larger number of mitoses of differentiating spermatogonia will result in a larger pool of primary spermatocytes and the production of more spermatozoa, than if fewer mitoses occur (Roosen-Runge, 1969). Furthermore, it will also allow for a certain amount of cell wastage without compromising sperm production to any great degree. In species such as the laboratory rat, laboratory mouse and hamster, there is an ample supply of type B spermatogonia (Huckins, 1978a,b; Huckins and Oakberg, 1978; de Rooij and Lok, 1987), however, this is not the case for some primate species (Sharpe, 1994). Before outlining the possible consequences of such differences in spermatogonial supply, stem cell renewal and proliferation of spermatogonia will first be discussed.

Within the seminiferous epithelium at any one point in time, several generations of type A spermatogonia, produced by successive mitoses, are present. All of these of type A spermatogonia, however, are morphologically similar and can only be distinguished from each other on the basis of their topographical arrangement and the timing of cell divisions (de Rooij, 1983). Some of these spermatogonia are retained as stem cells, while others undergo a sequence of successive divisions (proliferative spermatogonia), before giving rise to the differentiating spermatogonia that are committed to becoming spermatozoa.

Exactly how stem and proliferative spermatogonia transform into differentiating spermatogonia whilst simultaneously renewing their own population has been a topic of debate. Several different models of spermatogonial proliferation and stem cell renewal have been proposed from studies of the laboratory rat and laboratory mouse (see Russell *et al.*, 1990a; de Rooij and Dissel-Emiliani, 1997).

The first model of spermatogonial renewal divides type A spermatogonia into two groups, an actively renewing population comprised of types A_1 - A_4 spermatogonia and a 'reserve stem cell' population, designated A_0 spermatogonia (Clermont and Bustos-Obregon, 1968; Clermont and Hermo, 1975). According to this model, A_0 spermatogonia do not normally contribute to the A_1 spermatogonial population and are only activated to divide if there is significant spermatogonial loss from the epithelium. By contrast, types A_1 - A_4 spermatogonia retain stem cell properties, thereby enabling type A_4 spermatogonia to give rise to both A_1 and I_n spermatogonia (Fig. 1.3a).

In the alternative model of spermatogonial renewal, undifferentiated type A spermatogonia are classified as isolated/single (A_{is}), paired (A_{pr}) or aligned (A_{al}) spermatogonia according to their topographical arrangement and it was proposed that the isolated spermatogonia are the functional stem cells (Huckins, 1971; Oakberg, 1971; de Rooij 1973). According to this model (Fig. 1.3b), division of an A_{is} spermatogonium results in roughly equal proportions of daughter cells that either, a) migrate away from each other and become two new stem cells, ie A_{is} spermatogonia, or b) form a pair interconnected by a cytoplasmic bridge, ie. become A_{pr} spermatogonia. The A_{pr} spermatogonia divide further to form A_{al} spermatogonia, thereby creating a pool of undifferentiated spermatogonia available to commence spermatogenesis. In the laboratory rat and laboratory mouse, a single stem spermatogonium may undergo a sequence of four divisions, as up to 16 A_{al} spermatogonia, all connected by cytoplasmic bridges, have been observed in whole-mounted seminiferous tubules (Huckins, 1978a). The A_{al} spermatogonia in turn differentiate (no cell division is involved) into the A_1 spermatogonia, which are the first generation of differentiating spermatogonia, committed to undergoing a set number of divisions before entering meiosis (Huckins, 1971; Oakberg, 1971). Whereas types A_{is} , A_{pr} and A_{al} spermatogonia occur in all seminiferous tubules, the differentiating spermatogonia, types A_1 - A_4 , I_n and B, are confined to areas of tubules containing specific cellular associations or stages of the cycle of the seminiferous epithelium (see section 1.5.1).

Figure 1.3. Proposed models of stem cell renewal and spermatogonial proliferation and differentiation in adult testes.

Fig. 1.3a Model proposed by Clermont and Bustos-Obregon, (1968) and Clermont and Hermo, (1975) for the laboratory rat.

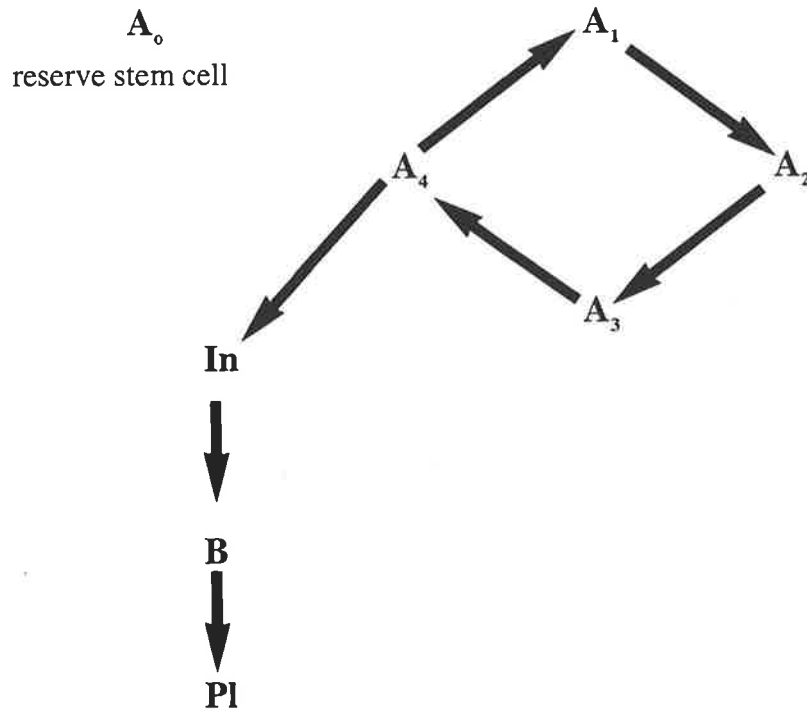
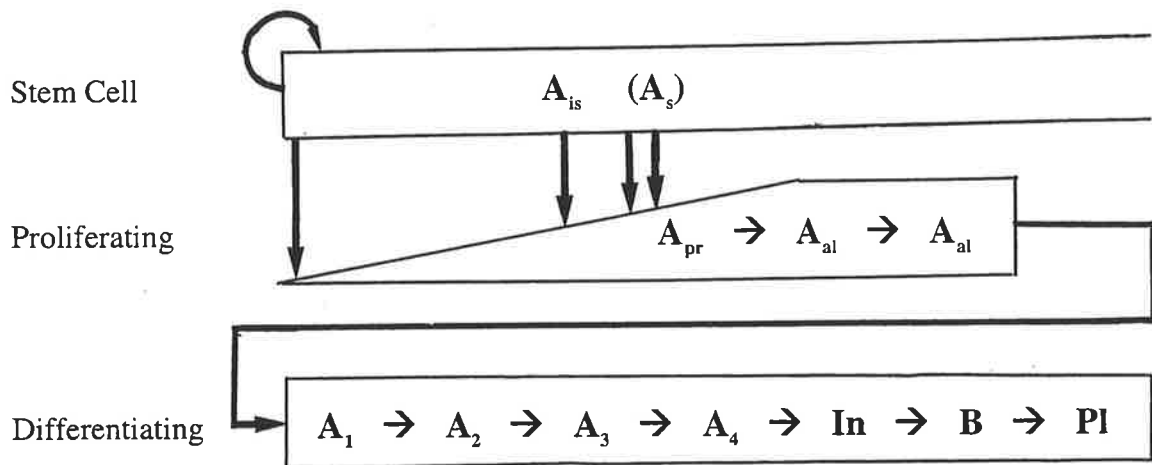


Fig. 1.3b Model proposed by Huckins, (1971) for the laboratory rat and Oakberg, (1971) for the laboratory mouse. PI = preleptotene primary spermatocyte.

Spermatogonial Compartment



In the model of Clermont and Bustos-Obregon (1968) the A_0 spermatogonia are equivalent to the A_{is} and A_{pr} spermatogonia of Huckins (1971), with the A_{a1} representing spermatogonia out of phase with the types A_1 - A_4 spermatogonia in their pattern of division. Various experimental findings (see review by de Rooij and Dissel-Emiliani, 1997) point to the model proposed by Huckins (1971) for the laboratory rat and Oakberg (1971) for the laboratory mouse, as being the more likely explanation of how spermatogonial renewal occurs. For example, in the normal testis, the A_{is} and A_{pr} spermatogonia display cycles of activity (Huckins, 1971; Lok *et al.*, 1983) which is not consistent with activation only in response to spermatogonial depletion. Similarly, differences in cell cycle properties and sensitivity to radioactivity between proliferating A_{a1} spermatogonia and A_1 - A_4 spermatogonia support them being different types of cells (Huckins, 1971; Lok and de Rooij, 1983a,b; Van der Meer *et al.*, 1992a, b).

The number of generations of differentiating spermatogonia (those spermatogonia committed to becoming spermatozoa) is species specific and governs both the potential number of type B spermatogonia and the strategies that are available to maintain sperm production at or near optimal levels. Six divisions of differentiating spermatogonia occur in the laboratory rat, laboratory mouse and Chinese hamster (Clermont and Leblond, 1953; Oakberg 1956b; Clermont, 1962; Oud and de Rooij, 1977; Kluin *et al.*, 1884), but only between two and four in primates (Clermont, 1969, 1972; Clermont and Antar, 1973; Cavicchia and Dym, 1978; Fouquet and Dadoune, 1986). Even with no spermatogonial degeneration, the maximum number of type B spermatogonia able to enter meiosis in primates is one quarter that of the rat (ie. 2^4 cf. 2^6 differentiated spermatogonia produced per proliferative spermatogonium).

Not all of the differentiating spermatogonia produced by the testes of the laboratory rat, laboratory mouse and hamster, however, survive through the mitotic divisions to become type B, with spermatogonia in excess of a predetermined number undergoing degeneration (Huckins, 1978b; Huckins and Oakberg, 1978; de Rooij and Lok, 1987). Furthermore this degeneration appears to be directly controlled by the numerical density of spermatogonia (de Rooij and Lok, 1987). Hence it has been suggested that excess production followed by selective removal of differentiating spermatogonia is a way of tailoring the number of germ cells to the carrying capacity of the Sertoli cell (Sharpe, 1994). Conversely, in primates, including the human, there is no surplus of differentiating spermatogonia, due to there being fewer spermatogonial divisions (Rowley *et al.*, 1971; Clermont, 1972). Although Ad, Ap and B spermatogonial populations have been recognised, only the type B population is classified as being committed to differentiation (de Rooij *et al.*, 1989), with the other two populations considered as reserve stem cells and renewing (proliferative) spermatogonia respectively (Fouquet and Dadoune, 1986). Consequently, density

dependent degeneration of spermatogonia is not observed (Clermont and Leblond, 1959; Clermont, 1972; de Rooij *et al.*, 1989). However, since the number of type B spermatogonia available to enter meiosis is more limited to begin with, any degeneration of spermatogonia and particularly of type B generations, limits, if not reduces, spermatogenic potential.

A range of factors within the tubular environment probably plays a role in modulating the number of differentiating spermatogonia about to enter meiosis. It has been shown that in monkeys, administration of FSH leads to a subsequent increase in the numbers of type B spermatogonia, spermatocytes and spermatids, via increasing the number of Ap but not Ad spermatogonia (van Alphen *et al.*, 1988; Weinbauer and Nieschlag, 1991). Likewise in rodents, FSH may play a role in regulating the proliferation of differentiated spermatogonia, or in reducing the degeneration of these cells (Chemes *et al.*, 1979; Russell *et al.*, 1987). In contrast, inhibin secreted by Sertoli cells appears to negatively regulate the number of differentiating spermatogonia by suppressing their mitoses (van Dissel-Emiliani *et al.*, 1989). In the adult testis, the secretion of bioactive inhibin by Sertoli cells appears to be modulated by surrounding germ cells, particularly elongate spermatids (Pineau *et al.*, 1990; Allenby *et al.*, 1991). Hence, Sharpe (1994) has speculated that the number of maturing germ cells associated with a Sertoli cell within the seminiferous epithelium ultimately determines the maximum number of type B spermatogonia that enter into meiosis. This fits with observations that depletion of elongate spermatids is associated with increased plasma levels of FSH and decreased levels of inhibin (Pineau *et al.*, 1989, 1990; Allenby *et al.*, 1991). Such conditions could then lead to an increase in the number of differentiated spermatogonia via either (1) modulating spermatogonial stem cell multiplication, as in primates, or (2) modulating the survival of differentiated spermatogonia, as in rodents (Sharpe, 1994). Numerous other factors have also been postulated to be involved in spermatogonial regulation, however, with the most likely ones being vitamin A, interleukin-1, c-kit and activin (see Sharpe, 1994; de Rooij *et al.*, 1997 for reviews).

1.5.3.4 Cell Loss during Spermatogenesis

From the previous discussions, it is by now obvious that actual sperm production is always less than what is theoretically possible due to germ cell loss during spermatogenesis and that this degeneration is a common feature of the mammalian testis under normal conditions (Barr *et al.*, 1971; Roosen-Runge, 1973; Zuckerman *et al.*, 1978; Huckins, 1978b; Johnson and Thompson, 1983; Kerr, 1992; de Kretser and Kerr, 1994). Furthermore, cell loss has been shown to occur during all three phases of spermatogenesis, although particular germ cells types are more susceptible to degeneration than others. For

example, considerable degeneration of types A₂, A₃, and A₄ spermatogonia at the time of mitosis (Oakberg, 1956a; Clermont, 1962) and primary and secondary spermatocytes during the meiotic divisions (Barr *et al.*, 1971; Russell and Clermont, 1977; Kerr, 1992) has been recorded. Reductions of between 11% and 75% in the potential number of spermatogonia in laboratory rodents have been suggested (Oakberg, 1956a; Clermont, 1962; Huckins, 1978), as well as a further 2-27% decline in the number of early spermatids from expected values based on the number of late primary spermatocytes (Roosen-Runge, 1955b; Oakberg, 1956a; Clermont, 1962; Swierstra and Foote, 1963; Russell *et al.*, 1987). In humans, germ cell degeneration during the meiotic divisions is even more pronounced, ranging from a 39% to a 45% shortfall in the actual number of early spermatids from that expected (Barr *et al.*, 1971; Johnson *et al.*, 1983; Johnson *et al.*, 1984a; Johnson *et al.*, 1992). By contrast, the amount of germ cell degeneration during spermiogenesis is either largely unknown or insignificant in comparison to that of the earlier phases of spermatogenesis (Amann, 1962; Johnson *et al.*, 1981; Lebovitz and Johnson, 1983).

The reasons for spontaneous germ cell loss during normal spermatogenesis remain obscure, however, generally accepted theories include that it eliminates cells with abnormal chromosomes (Oakberg, 1956a; Clermont, 1962) or that have developed improperly (Sinha Hikim *et al.*, 1997) and provides a mechanism whereby germ cell numbers are matched to the carrying capacity of the Sertoli cell population (Huckins, 1978a). Recent evidence suggests that spermatogenic cells in excess of the support capacity of the Sertoli cells are removed via apoptosis (Blanco-Rodriguez and Martinez-Garcia, 1996a). In cases of degeneration associated with cell divisions, evidence from a study in which testes were exposed to conditions of mild hypothermia suggests that disruption of the microtubules of the spindle apparatus and subsequent failure of the cell to pass the spindle-assembly checkpoint may induce the apoptotic cell death (Blanco-Rodriguez and Martinez-Garcia, 1997a).

Testicular insult is also known to increase the incidence of degeneration of particular germ cell types. For example, heating of ram testes to 40°C for 150 minutes increases the amount of degeneration of pachytene primary spermatocytes (Waites and Ortavant, 1968). Similar findings of degeneration of pachytene spermatocytes and/or round spermatids have also been reported for other species following exposure of the testes to heat (Gasinska and Hill, 1990; Lue *et al.*, 1998; Setchell 1998). Likewise, hormone deprivation results in germ cell loss, which may be stage-specific (Russell and Clermont, 1977; Bartlett *et al.*, 1986; Sinha Hikim and Swerdloff, 1993). In laboratory rats, the initial effect of application of a gonadotrophin-releasing hormone antagonist (GnRH-A) that selectively inhibits the secretion of LH and FSH, is selective degeneration of the preleptotene and

pachytene primary spermatocytes and step 7 and 19 spermatids of stage VII of the cycle of the seminiferous epithelium (Sinha Hikim and Swerdloff, 1993). [This is in contrast to the findings of a study by Kerr (1992) in which it was reported that spontaneous loss of germ cells in the normal adult rat testis is least likely as the cells pass through stage VII.] After oestradiol treatment, cell loss is greatest in stages IV-X of the spermatogenic cycle (Blanco-Rodriguez and Martinez-Garcia, 1996b, 1997b). In all of these situations, the mechanism of cell death is known to involve apoptosis (Sinha Hikim *et al.*, 1995; Billig *et al.*, 1995; Brinkworth *et al.*, 1995; Henriksen *et al.*, 1995; Sinha Hikim *et al.*, 1997; Lue *et al.*, 1998).

1.6 Sperm Maturation

Sperm maturation is the term given to the process that occurs within the epididymis by which a spermatozoon becomes fully competent to fertilise an egg (Brooks, 1981; Moore, 1995; Moore and Akhondi, 1996). At the time that spermatozoa leave the testis they are not motile, nor are they capable of fertilisation (Bedford, 1979; Amann *et al.*, 1993). Rather they undergo considerable modification during epididymal transit that culminates in the acquisition of progressive motility, the ability to recognise, bind to and penetrate the zona pellucida and the ability to fuse with the oolemma (Bedford, 1975; Cooper, 1986; Moore, 1990a). Wide-ranging evidence indicates that both maturation and subsequent storage of spermatozoa depend on their interactions with the epididymal epithelium and their exposure, over an adequate time frame, to factors that are present within the epididymal luminal microenvironment (see subsequent sections for details).

1.6.1 Transit Times through the Epididymis

The time taken for spermatozoa to travel through the male genital duct system has been determined for a range of mammals including the laboratory rat (Robb *et al.*, 1978), laboratory mouse (Meistrich, 1975; Dadoune and Alfonsi, 1984), hamster (Amann *et al.*, 1976), rabbit (Orgebin-Crist, 1965; Amann *et al.*, 1965) and guinea pig (Frenkel *et al.*, 1973), as well as for several primate and common domestic animal species (Swierstra, 1968a; Gebauer *et al.*, 1974b; Amann *et al.*, 1976; Courot, 1981). In general, transit of the entire epididymis by spermatozoa takes a mean period of 6-14 days depending on species (Orgebin-Crist, 1962; 1965; Amann *et al.*, 1965; Amann, 1981; Bedford and Hoskins, 1990), although in the human it is more rapid, ranging from two to six days (Johnson and Varner, 1988). Determinations of transit time have involved: a) tracking the progression of labelled spermatozoa through the duct system and b) dividing extra-gonadal sperm reserves by the daily sperm production rate of the attached testis.

Various studies have found that the duration of sperm transit through the caput and corpus epididymides is relatively uniform (2-5.5 days) for most mammalian species (Rowley *et al.*, 1970; Amann *et al.*, 1976). Since the caput and corpus regions of the epididymis are associated with the acquisition of motility and fertilizing capacity by spermatozoa (Bedford, 1975; Cooper, 1986; Moore, 1990a), at least two day's exposure of spermatozoa to the environment of these regions may be required for maturation to occur. In several non-human mammals the requirement for at least minimal exposure of spermatozoa to the proximal regions of the epididymis in order to attain fertilising ability is supported by evidence from ligation and "bypass" experiments (see Moore, 1995). It has been shown that passage through at least the initial segment and proximal caput epididymidis is required for rabbit spermatozoa to successfully fertilize an oocyte (Bedford, 1967; Orgebin-Crist, 1967) and, although passage through the distal caput and proximal corpus regions is not obligatory for sperm maturation, fertility is reduced in rabbits and rats where these regions of the epididymis are surgically bypassed (Temple-Smith *et al.*, 1989; Temple-Smith *et al.*, 1998).

A possible exception to the above is the human, where cases of pregnancy have been reported in couples where a) the male has undergone a high-level vasoepididymal bypass, ie. connection of the vas deferens towards the testicular end of the epididymis (Schoysman and Bedford, 1986; Silber, 1988, 1989) and b) spermatozoa aspirated from the proximal caput epididymidis have been used in conjunction with assisted reproductive technologies (Temple-Smith *et al.*, 1985; Silber *et al.*, 1988). Such findings, however, do not conclusively show that the epididymal environment is not required for the normal maturation of spermatozoa in the human. It has been pointed out that in cases of epididymal bypass, fertility is reduced when the site of the anastomosis is close to the testis, compared with that when more distal regions of the tract are involved (Moore, 1995). Furthermore, the epididymides of patients presenting for bypass procedures are pathological and the environment created following surgery is abnormal, both of which might in some way promote sperm maturation (Moore, 1995, 1996). Similarly, aspirated spermatozoa used in conjunction with assisted reproductive technologies do not encounter the normal physiological barriers to conception such as cervical mucus, the utero-tubal junction and oocyte vestments including the zona pellucida (Moore, 1996). Therefore, they may be able to bring about fertilisation without having undergone the maturational processes associated with reaching and recognising the oocyte *in vivo*.

Interspecific variation in the time taken for spermatozoa to pass through the entire epididymis is primarily related to the length of sperm storage in the cauda, which varies from 5-14 days (Amann *et al.*, 1976). The time spent by spermatozoa in the cauda epididymidis is a function of both its storage capacity (ie. the distensibility of the duct) and

daily sperm production by the testis (Amann *et al.*, 1976; see also section 1.6.4). In sexually active males, the number of spermatozoa stored in the cauda epididymidis and vas deferens declines with increased frequency of ejaculation (Almquist and Amann, 1961; Lambiase and Amann, 1969). Similarly, transit through the cauda epididymidis is shorter in sexually active as compared to sexually rested animals (Orgebin-Crist, 1962; Amann *et al.*, 1974), by up to about 20% (Setchell, 1991).

The duration of sperm transit through the vas deferens, has generally not been addressed, probably for the reasons that: a) when spermatozoa reach the caudae epididymides they are usually available for ejaculation and hence traverse the vas deferens rapidly at this time and b) the vasa deferentia do not contain significant numbers of spermatozoa in the majority of mammalian species. Even in species such as the stallion where it has been suggested that the ampullae of the vasa deferentia act as an accessory sperm storage site (Mann and Lutwak-Mann, 1981), only around 11% of extra-gonadal spermatozoa are located in the vasa and ampullae and constitute sufficient spermatozoa for a single ejaculate at most (Gebauer *et al.*, 1974b). This may not be the case in several species of shrew, however, where up to 20% (0.5 million of a total of 2.5-3.4 million per tract) of spermatozoa are found in a gland (Bedford *et al.*, 1994) or swelling (Bedford *et al.*, 1998) of the vas deferens. In these species, the vas deferens may constitute the primary source of spermatozoa in an ejaculate, since it has been shown that the number of spermatozoa in these regions closely approximates the number inseminated at coitus (Bedford *et al.*, 1994). Hence, cauda epididymal spermatozoa may not form part of the ejaculate, except when the frequency of ejaculation is high, but might gradually replenish the spermatozoa in the storage regions of the vas deferens in the period after ejaculation (Bedford *et al.*, 1998). Investigation of sperm transit through the vas deferens of species which have an accessory site of sperm storage, therefore, appears to be warranted.

1.6.2 The Epididymal Microenvironment

The epididymal microenvironment to which spermatozoa are exposed during transit has been described as complex, due to sequential changes in its fluid composition (and sperm concentration) along the length of the duct (Turner, 1991). Epididymal luminal fluid originates from the rete testis via the ductuli efferentes (Setchell *et al.*, 1994), however, as it makes its way through the duct it is progressively modified through the resorption of ions and water (Wong, 1990; Hinton and Palladino, 1995) and the addition and removal of specific proteins and glycoproteins (Turner *et al.*, 1979; Wong *et al.* 1981; Olson and Hinton, 1985; Jones, 1987; Chaturapanich *et al.*, 1992).

Fluid modification generally occurs as a consequence of androgen-dependent activities of the epididymal epithelium, which include transport, synthesis and secretion (Orgebin-Crist *et al.*, 1975; Wong and Yeung, 1977; Vreeburg *et al.*, 1990). Some protein synthesis and secretion by the epithelium, however, persists in the absence of androgens (Holland *et al.*, 1992). Conversely, administration of testosterone to castrated laboratory rats at doses found in the circulation or in epididymal fluid does not maintain the level of activity of some enzymes (eg. nuclear 5 α -reductase) within the epididymis (Robaire *et al.*, 1977; Robaire, 1979). This and other evidence from efferent duct ligation and orchidectomy experiments (Fawcett and Hoffer, 1979), has implicated factors from the testis that access the epididymis via the luminal fluid (in addition to androgens) in the regulation of epithelial cell function and hence the epididymal luminal microenvironment (Robaire and Hermo, 1988).

Up to 90% of fluid entering the epididymis is resorbed in the efferent ductules and initial segment in some species (Crabo, 1965; Levine and Marsh, 1971; Djakiew and Jones, 1982b; Robaire and Hermo, 1988). This is facilitated by passive movement of Na⁺ into the epithelial cells from the lumen, followed by its transport across the basal plasmalemmae of the cells into the interstitium (Hinton and Palladino, 1995). Regional variations in the luminal electrolyte concentration and pH of luminal fluid have been shown to occur, with a decrease in the Na⁺ concentration and an increase in K⁺ from the caput region towards the cauda epididymidis (Levine and Marsh, 1971; Levine and Kelly, 1978; Wong *et al.*, 1978).

In addition to its role in water and ion transport, the epididymal epithelium contributes to the luminal microenvironment via the absorption and secretion of numerous proteins, glycoproteins and small organic molecules (Turner *et al.*, 1979; Brooks, 1981; Jones and Clulow, 1987; Robaire and Hermo, 1988; Vreeburg *et al.*, 1990; Hinton and Palladino, 1995). Suggestions of epithelial involvement in determination of the composition of the luminal microenvironment were initially based on observations of the structural characteristics of the epithelial cells (Fawcett, 1975; Robaire and Hermo, 1988) coupled with reports of the disappearance of proteins from the luminal fluid between the initial segment and more distal segments of the epididymis (Turner, 1979; Dacheux and Voglmayr, 1983). More substantial evidence for involvement of the epididymal epithelium in contributing to the composition of the luminal microenvironment was provided by tracer studies in which it was shown that labelled sugars or amino acids incorporated into (glyco)proteins synthesised by principal cells were secreted into the lumen (Kopecny and Peck, 1977; Flickinger, 1981, 1983, 1985). Finally, immunohistochemical studies have shown that antibodies raised against sperm surface antigens also bind to proteins in the epididymal fluid and to epididymal epithelial cells, further supporting epithelial involvement in determining the luminal microenvironment

(Moore *et al.*, 1994).

While the roles of particular proteins and other molecules within the luminal microenvironment have not been determined with any degree of certainty, it is well accepted that the overall composition of the epididymal fluid is responsible for sperm maturation (Hinton and Palladino, 1995; Cooper, 1998). A range of proteins has been shown to become associated with the sperm plasmalemma (Brooks and Tiver, 1983, 1984; Tezon *et al.*, 1985; Vreeburg *et al.*, 1992; Tulsiani *et al.*, 1993; Moore *et al.*, 1994; Kirchhoff and Hale, 1996), whereas other luminal components probably catalyse reactions that alter the epididymal micro-environment or spermatozoa (Cooper, 1998).

1.6.3 Changes in Sperm during Epididymal Transit

Sperm maturation is coincident with both morphological and biochemical alterations which are generally complete by the time the spermatozoa reach the lower regions of the corpus epididymidis or the segment of the cauda epididymidis proximal to enlargement of the luminal diameter of the duct (Bedford, 1975; Orgebin-Crist *et al.*, 1975; Yanagimachi *et al.*, 1985; Cooper, 1986; Robaire and Hermo, 1988). In some species, however, modifications that are not associated with the acquisition of fertilising ability, eg. stabilising events that might prolong storage life of spermatozoa, probably also occur in the cauda epididymidis (see section 1.6.4).

In most eutherian mammals morphological alterations to spermatozoa in the epididymis are minimal. The most obvious event is shedding of the cytoplasmic droplet after its movement from the neck, along the midpiece of the tail, towards the annulus (Dott and Dingle, 1968; Cummins and Glover, 1970; Amann *et al.*, 1982), but in several species slight changes in the form of the acrosome also occur (Fawcett and Hollenberg, 1963; Bedford and Nicander, 1971; Jones *et al.*, 1974). One exception in eutherians is the South African red veld rat, *Aethomys chrysophilus* in which dramatic remodelling of the acrosome occurs during epididymal transit. Spermatozoa in the caput epididymidis have a long anteriorly projecting apical segment (AS) of the acrosome, whereas in those located in the cauda epididymidis the AS is flexed caudad and lies alongside the nucleus (Breed *et al.*, 1988). By contrast, in a number of marsupials marked alterations to sperm structure, particularly the acrosome and tail, occur during epididymal transit. In the tammar wallaby and brush-tailed possum, a reduction in the size of the acrosome and formation of the midpiece fibre network of the tail take place within the epididymis (Cummins, 1976; Temple-Smith and Bedford, 1976; Temple-Smith, 1994; Setiadi *et al.*, 1997; Lin and Rodger, 1999). The orientation of the sperm nucleus relative to the tail also changes in some species, from the T-shape characteristic of immature spermatozoa to a spear-like

form (Cummins, 1976; Temple-Smith and Bedford, 1976; Harding *et al.*, 1976, 1979).

The bulk of maturational changes to spermatozoa involve biochemical modifications, which arise as a result of a) pre-programmed cleavage/modification of integral molecules within the spermatozoon, b) activation of pre-existing switches controlling sperm metabolism and/or c) the incorporation of molecules from the epididymal environment into the spermatozoon (Amann *et al.*, 1993). While some of these modifications bring about stabilisation of the nucleus, the bulk relate to alterations of the sperm plasmalemma, associated with either the acquisition of motility, or the ability to interact with an egg.

During epididymal transit, the possibility of damage to or instability within the sperm nucleus in response to environmental factors needs to be minimised. Decondensation of the nucleus, however, must be able to occur once the spermatozoon reaches an egg in the female reproductive tract. Stabilisation of the nuclear chromatin is brought about via increased oxidation of protein bound -SH groups to -S-S- as sperm pass along the epididymis (Calvin and Bedford, 1971; Bedford and Calvin, 1974). It has been shown that the nuclei of spermatozoa from the cauda epididymidis are more resistant to decondensation when treated with strong detergents and/or disulphide reducing agents, eg. sodium dodecyl sulphate (SDS) alone, or SDS + dithiothreitol, than those of spermatozoa from the caput or corpus regions (Bedford, 1975; Bedford and Hoskins, 1990).

Variability in the number and type of proteins, glycoproteins and other molecules associated with the plasmalemma of spermatozoa between the caput and cauda epididymides has been well documented (Kohane *et al.*, 1980; Wong and Tsang, 1982; Zeheb and Orr, 1984; Vreeburg *et al.*, 1992; Tulsiani *et al.*, 1993; see also reviews by Cooper, 1986, 1992, 1998; Turner, 1991; Amann *et al.*, 1993). Based on data from immunocytochemical studies, it is now generally accepted that sperm surface changes in glycoprotein result from both the acquisition of new molecules obtained from the epididymal environment (Lea *et al.*, 1978; Brown *et al.*, 1983; Zeheb and Orr, 1984; Smith *et al.*, 1986; Jones, 1998) and from the modification or translocation of existing sperm surface molecules from one membrane domain to another (Hamilton *et al.*, 1986; Bedford and Hoskins, 1990; Thaler and Cardullo, 1995; Jones, 1998).

1.6.4 Sperm Storage in the Cauda Epididymides

In scrotal mammals, the majority of sperm storage occurs in the caudae epididymides subsequent to their maturation in the more proximal regions of the ducts. Throughout their storage, spermatozoa must maintain their viability if they are to be successful at fertilisation, hence they are stored in a quiescent, non-motile state (Wyker and Howards,

1977; Bedford and Hoskins, 1990), despite them having attained the capacity for movement. For any given species, the number of spermatozoa stored in the caudae epididymides has probably evolved in a manner consistent with its reproductive strategy, ie. its social and mating behaviour, copulatory frequency and the number of spermatozoa in a typical ejaculate (Amann *et al.*, 1993). The conditions that facilitate sperm storage, determine its duration and contribute to the maintenance of sperm viability during storage, however, have not been fully elucidated, although a number of likely contributing factors have been proposed.

The location of the caudae epididymides in the scrotum along with the testes has given weight to suggestion that sperm storage, as well as sperm production, is temperature dependent. In considering the evolutionary significance of the scrotum, it has been suggested that migration of the sperm storage region of the epididymis to a cooler location, rather than descent of the testes, might have been the driving force behind scrotal development (Bedford, 1978a,b). The lower temperature of the cauda epididymidis possibly facilitates sperm storage by reducing sperm membrane fluidity, thereby making membranes less labile and more stable (Moore, 1996). Lower concentrations of androgens in the cauda epididymal environment, however, have also been proposed to contribute to stability of sperm membranes (Moore, 1995). Regardless of how it is achieved, membrane stability, particularly over the acrosome, is important in preventing spermatozoa from undergoing premature reactions in the epididymis that would compromise their success in fertilising an oocyte within the female tract following ejaculation. A second proposal is that a cooler environment reduces the rate of respiration of spermatozoa in the scrotal cauda epididymidis (Djakiew and Cardullo, 1986). This in turn increases the availability of oxygen in the duct lumen and increases the capacity to maintain and hence store a larger number of spermatozoa per unit volume of the cauda epididymidis (Djakiew and Cardullo, 1986). In addition, temperature-dependent secretory factors from the epididymal epithelium might also act to stabilise sperm membranes, thereby maximising sperm survival and the length of time they can be stored (Esponda and Bedford, 1986). These factors would then need to be reversed within the female reproductive tract.

By contrast, increasing the temperature of the caudae epididymides to body temperature might suppress the synthesis and secretion of macromolecules that normally bind to the sperm surface, thereby compromising sperm stability (Bedford and Yanagimachi, 1991). This premise is based on observations that in the laboratory rat, the protein profile of the cauda epididymal environment is changed following exposure to increased temperatures (Esponda and Bedford, 1986; Esponda *et al.*, 1990). In the rabbit, however, it has been proposed that membrane stability is enhanced by factors secreted prior to spermatozoa reaching the storage areas of the duct. The mid to lower segments of the corpora

epididymides have been shown to secrete a factor, designated acrosome stabilising factor (ASF), that coats the sperm surface over the acrosome and is capable of suppressing the fertilising ability of capacitated spermatozoa exposed to it (Thomas *et al.*, 1984, 1986).

Elevated epididymal temperature has been proposed as a possible reason for the lower number of stored spermatozoa and reduced length of storage in the human compared to other scrotal species (Bedford, 1991a). This suggestion is based on observations that in the laboratory rat and rabbit, abdominal temperature reduces cauda epididymal sperm storage capacity by decreasing the time required for sperm to pass through the duct (Bedford, 1978b). Faster sperm transit is, however, at least partly due to a reduction in the total length and luminal diameter of the duct (Bedford, 1978b; Foldsey and Bedford, 1982). Secondly, sperm storage capacity may be reduced as a result of reduced water and ion transport by the epididymal epithelium in response to an elevation in temperature, thereby decreasing caudal sperm concentration (Wong *et al.*, 1982; Rasweiler and Bedford, 1982).

The maintenance of spermatozoa in a quiescent state appears to be important in ensuring their successful storage. By the time spermatozoa reach the cauda epididymides, their concentration has increased considerably, due to absorption of the bulk of the luminal fluid. Hence it has been proposed that increased viscosity of the epididymal fluid in the cauda epididymides may lead to mechanical immobilisation of spermatozoa (Usselman and Cone, 1993), thereby minimising their respiration rate and prolonging their viability. This is clearly not the case in humans, however, as cauda epididymal fluid is not viscous (Turner and Reich, 1985). An alternative view is that the low ionic composition and high K^+/Na^+ ratio of the cauda epididymal fluid (Turner *et al.*, 1977; Turner and Reich, 1985), resulting from its sequential modification as it flows through the epididymal duct, induces quiescence. Yet another suggestion is that low reactivity of stored spermatozoa is due to interactions between a quiescence factor and the spermatozoon's acidic intracellular pH (Acott and Carr, 1984).

That the cauda epididymal environment somehow induces quiescence in spermatozoa which facilitates their successful storage and that this process is linked to epididymal temperature, is supported by observations that the time required for capacitation of hamster spermatozoa is reduced following their storage at abdominal temperature (Bedford and Yanagimachi, 1991). Spermatozoa taken from a cauda epididymidis withdrawn into the abdominal cavity were shown to undergo capacitation and fertilise cumulus free eggs 30-45 minutes sooner than control spermatozoa stored in a scrotal cauda (Bedford and Yanagimachi, 1991).

1.7 Ejaculation and Sperm Deposition

The propulsion of spermatozoa through the male reproductive tract during the ejaculatory process results from the coordinated, peristaltic contraction of the smooth muscle surrounding the duct of the cauda epididymidis and vas deferens. This is accompanied by contraction of the smooth muscle surrounding the accessory sex glands which brings about the release of their secretions. The ejaculatory process involves two phases, emission during which seminal fluid is deposited into the urethra and ejaculation whereby semen passes through the urethra and expulsion from the male tract occurs (Benson, 1994). In general, seminal emission appears to be mediated via stimulation of sympathetic pathways that innervate the lower regions of the male reproductive tract and accessory glands via the hypogastric nerve (Cross and Glover, 1958). Ejaculation may also involve contraction of the perineal striated musculature, which, in the human, is controlled via somatic innervation (Benson, 1994).

There is little mixing of spermatozoa with the secretions of the accessory glands until after the semen has left the male reproductive tract. This is a consequence of a temporal sequence among the various organs (epididymis, vesicular glands, prostate) in the release of their secretions (Amelar and Hotchkiss, 1965; Tauber *et al.*, 1975; Setchell *et al.*, 1994). A 'sperm-rich fraction of the semen is normally ejected along the urethra prior to release of the glandular secretions in the human (Moore, 1995) and hence mixing of components may only occur in the female tract subsequent to semen deposition. Mixing of spermatozoa with the accessory gland secretions is accompanied by activation of the metabolic activity of the spermatozoa. Such activation may arise in response to either the provision of specific activating factors, or dilution of inhibitory factors to which spermatozoa were exposed in the epididymal microenvironment (Brooks, 1990). Mixing of secretions of the various glands in the female tract probably also facilitates coagulation and liquefaction of the semen. While the biological purpose of this phenomenon has not been resolved in the human (Luke and Coffey, 1994), in certain murid rodent species the formation of a solid postcopulatory plug via coagulation of the seminal plasma in the female tract might either facilitate the passage of spermatozoa through the cervix into the uterus (Blandau, 1945; Pang *et al.*, 1979), or convey a reproductive advantage to the first male to inseminate a female by blocking insemination by subsequent males (Gomendio *et al.*, 1998).

1.8 The Australian Rodents

Among eutherian mammals, one of the most successful and widespread groups includes the rodents, which have exploited a broad spectrum of food sources and hence ecological niches (Vaughan, 1986). The order Rodentia constitutes around half of all extant mammalian species (Strahan, 1995) and repeated rodent radiations have occurred throughout all continents except Antarctica, with parallel evolution of similar features occurring in different evolutionary lineages. Consequently, the taxonomy of Rodentia is confused but the most widely accepted classification schemes are those of Simpson (1945) and Carleton and Musser (1984). The classification of the Australian rodents outlined in this thesis follows that of Watts and Aslin (1981).

1.8.1 The Australian Hydromyine Rodents

Among the Australian mammals, the rodents have been categorised, relative to marsupials, as 'the late invaders' (Lee *et al.*, 1981) due to their more recent arrival on this land mass. All native Australian rodent species belong to the family Muridae which has been subdivided into two subfamilies, the Murinae and the Hydromyinae. Ancestors of the Hydromyinae arrived in Australia from South-East Asia around 6-8 million years ago (Watts and Baverstock, 1995), whereas the Murinae arrived more recently than the early ancestors of the hydromyines, with a suggested arrival time of about one million years ago (Simpson, 1961; Watts and Aslin, 1981).

Most Australian rodent genera and species belong to the subfamily Hydromyinae and fall into the tribes Hydromyini, Uromyini, Conilurini and Anisomyini (Strahan, 1995). By contrast, the only genus occurring within the Murinae is that of *Rattus* (Lee *et al.*, 1981; Strahan, 1995), apart from the house mouse which arrived in Australia with colonisation by Europeans. The suggested phylogenetic relationships within and between the Australian murids have largely been based on chromosomal similarities (Baverstock *et al.*, 1981; 1983) and serological criteria (Watts and Baverstock, 1995), although sperm morphology has also been used (Breed, 1984). Within the Hydromyinae, there is no universally accepted phylogenetic tree, as various studies have arrived at different conclusions according to the criteria used in the analyses (Baverstock *et al.*, 1981; Watts *et al.*, 1992; Watts and Baverstock, 1995). It is now generally accepted, however, that *Pseudomys* and *Notomys* form a monophyletic clade to the exclusion of most of the other genera except for *Mastacomys*. Chromosomal studies have shown that these genera share a reciprocal translocation between chromosomes 1 and 2 (Baverstock, 1984).

Of the hydromyine tribes, the Conilurini is the largest and most widely distributed in

Australia and includes species in the arid zone. Only two species of the Hydromyini occur in Australia, both of which are aquatic. The Uromyini includes two genera that are restricted to the wetter areas of the northern and eastern Australian coasts (Watts and Aslin 1981) and within Anisomyini a single species, *Pogonomys*, occurs in rainforests of Northern Queensland (Strahan, 1995).

1.8.2 Diversity in Reproductive Anatomy

Numerous aspects of the reproductive biology of male conilurine rodents have been investigated in our laboratory. Studies have included comparative analyses of:

- a) the morphology of the extra-testicular ducts, accessory sex glands and penes (Breed, 1980, 1981a, 1981b, 1982a, 1986; Morrissey and Breed, 1982),
- b) the size and structural organisation of the testes (Breed, 1982a, 1997; Peirce and Breed, 1987),
- c) sperm morphology (Breed and Sarafis, 1979; Breed, 1980, 1983b), and
- d) epididymal sperm numbers and distribution (Breed, 1986, 1997; Peirce and Breed, 1989).

Perhaps the most striking feature of all of these studies is the huge interspecific diversity in the entire range of reproductive parameters within this rodent group. For example, within the genus *Pseudomys*, testes mass relative to body mass ranges from 0.5-3.6% (Breed, 1997) and a full complement of accessory sex glands is present but their relative size varies (Breed, 1982a, 1986), as does epididymal sperm number (Breed, 1985a, 1997). By contrast, in the majority of *Notomys* species, the testes are minute and are accompanied by vestigial accessory glands, apart from the ventral prostates and low numbers of spermatozoa within the extra-testicular ducts (Breed, 1982a, 1986, 1997; Peirce and Breed, 1987, 1989). In addition, features of the reproductive tract of *Notomys* females that are complementary to those of the males, have also been observed (Breed, 1985b, 1990b).

Furthermore, diversity in male reproductive parameters is not confined to differences between species. Considerable intraspecific variability in testis size, sperm morphology and sperm numbers has been observed within one species of *Notomys*, *N. alexis*. In this species there are four main morphological variants of the sperm head, but many bizarre forms are also evident, both within an ejaculate and between the ejaculates of different individuals (Breed and Sarafis, 1983; Suttle *et al.*, 1988).

1.9 Research Proposal

In spite of the investigations outlined above, there are many gaps in our knowledge of male reproductive biology of this group of mammals, including the causes of the interspecific variations observed in the various reproductive parameters. While the previous studies have shown that the plains rat *Pseudomys australis* and hopping mouse *Notomys alexis* represent the opposite ends of the spectrum in murids with respect to testis size and numbers of spermatozoa within the epididymis and the vas deferens (Breed, 1982a, 1986, 1997; Breed and Sarafis, 1979), no data are available on the dynamics of germ cell production, the average numbers of germ cells in the testes, or the relationship between sperm production and extra-testicular sperm storage capacity. Furthermore, in addition to the minute size of the testes and low sperm numbers, the hopping mouse, *N. alexis* exhibits a reproductive tract anatomy that appears to be unique among mammals. The epididymides are relatively short, the vasa deferentia contain little muscle in their walls and their distal segments have a wide diameter and display a highly infolded mucosal lining that extends across the entire lumen of the duct (Breed, 1986; Peirce and Breed, 1989). Moreover, as many as 60% of the total number of stored spermatozoa of some males are present within these distal regions of the vasa deferentia, although this is highly variable between individuals (Breed, 1981b, 1986; Peirce and Breed, 1989).

It should also be noted that these closely related hydromyine rodents represent naturally occurring species that exhibit extreme divergence in an entire suite of reproductive parameters including not only testis size and sperm numbers, but also accessory sex gland arrangement (Breed, 1981a; 1986) and the quantity and organisation of the testicular interstitial tissue (Breed, 1982a; Peirce and Breed, 1990). That these findings are not due to data being obtained from individuals subjected to pathological conditions in the laboratory is shown by the occurrence of similar data for wild-caught animals during times of reproductive activity (Breed, 1990a). Such interspecific variation between closely related species is therefore, perhaps unique among mammals.

All of the factors outlined above raise issues about the reproductive strategies of male hydromyine rodents and why such widespread variation between closely related species should have arisen. Clearly, more detailed investigations of the basic reproductive biology of these species, including the factors influencing sperm production and storage are required before such questions can be satisfactorily answered. How efficient is germ cell production? What is the rate at which it occurs? How rapidly do spermatozoa pass through the epididymis? When and where does sperm maturation and storage occur? These are just some of the questions that will be investigated in this thesis.

1.9.1 General Aims and Objectives

This thesis attempts to compare the relationships between testis size, the efficiency of germ cell production and sperm storage capacity in two species of hydromyine rodents, the plains rat, *Pseudomys australis* and the spinifex hopping mouse, *Notomys alexis*. A comparative study of aspects of the structure and function of the testes, epididymides and vasa deferentia of these two species therefore been undertaken, to determine:

- the composition and organisation of the testicular seminiferous epithelium.
- the number, frequency of occurrence and duration of cellular associations within the seminiferous epithelium.
- the duration of spermatogenesis.
- the daily rate of sperm production.
- the microscopical structure of the ductus epididymidis and vas deferens.
- the duration of transit and distribution of spermatozoa, through the extra-testicular duct system.

1.9.2 Specific Questions

For each of the two species, specific questions were posed in order to achieve the stated aims and objectives. These questions, which are addressed in the following chapters of this thesis, are:

- What is the proportion of the testes that is devoted to the production of spermatozoa?
- How is the testicular seminiferous epithelium organised?
- What length of time does it take for a stem spermatogonium to develop into a spermatozoon?
- What is the level of efficiency of sperm production by the seminiferous epithelium?
- What are the structural features of the extra-testicular duct system and how do these features relate to the capacity for sperm maturation and storage?
- What is the extra-testicular sperm storage capacity and where are spermatozoa stored?
- What is the duration of sperm transit through the excurrent ducts?

Chapter 2 General Materials and Methods

2.1 Animals

The use of animals for the research reported in this thesis was approved by the Animal Ethics Committee of the University of Adelaide. All aspects of the research were conducted in the Department of Anatomical Sciences under ethics approval numbers M/066/90A, M/81/92C, S/45/95 and S/63/98.

Plains rats, *Pseudomys australis*, and hopping mice, *Notomys alexis*, were obtained from colonies bred in the Medical School animal house, University of Adelaide, or from local suppliers in the greater Adelaide region. Animals from these sources were in part descendants of animals supplied to the University of Adelaide in the early 1970s by Dr PR Baverstock and Dr CHS Watts of the Gilles Plains Field Station, Institute of Medical and Veterinary Science, Adelaide and in part from animals captured in the southern Northern Territory during the 1970s and early 1980s by Dr. WG Breed, Department of Anatomical Sciences. Further animals were supplied by the Victorian Department of Fisheries and Wildlife. No additions to the colony have occurred since the mid 1980s. In addition to the sources of animals described above, reproductive tracts were obtained from five male hopping mice captured on Curtin Springs Station, NT, in August 1984 and from animals of both species supplied by the Evolutionary Biology Unit, South Australian Museum.

Male plains rats and hopping mice were weaned at approximately 30-35 days of age and thereafter maintained in groups of four or five in standard rat (41 x 28 x 15 cm) or mouse (40 x 20 x 25 cm) cages until the time of their use. Proven breeding males were obtained directly from breeding groups (one male paired with one or two females). All animals were fed a diet of mouse cubes (Milling Industries, Mile End, SA) supplemented with mixed seed and fresh apple and carrot twice weekly. Water was available at all times. The colonies were housed under regulated temperature conditions of 18-25°C and a lighting regimen of either 12 hours light: 12 hours dark, or 14 hours light: 10 hours dark. Both the temperature and lighting conditions adopted fell within the ranges encountered by animals of these species in the wild.

Plains rats and hopping mice both occur in the arid zone (Watts and Aslin, 1981; Strahan, 1995), although the preferred habitat of plains rats is grassland or low shrubland vegetation of gibber plains and claypans (Watts and Aslin, 1974; 1981) in contrast to the spinifex dominated sand dune country which is inhabited by hopping mice (Finlayson, 1940, Strahan, 1995). Measurements of ambient and burrow temperatures taken at various times

throughout the year (Lee *et al.*, 1984) indicate that hopping mice are subjected to a temperature range of 16-33°C while foraging or within their burrows. The day length encountered by these animals in the wild varies and depends on the season and the location of individuals within the species geographical range, but for Alice Springs (123°56'S, 137°52'E, which is approximately mid-latitudinal range for this species of hopping mouse), maximum and minimum day lengths are 13 hours 39 minutes light, 10 hours 21 minutes dark and 10 hours 40 minutes light, 13 hours 20 minutes dark respectively. Since reproductively active animals have been collected at all times of the year (Breed, 1982b, 1990a; 1992), the effect of this variation in photoperiod and temperature on gonadal activity in the natural environment is probably negligible provided abundant food resources are available. This is further supported by the fact that our laboratory colonies breed continually throughout the year under the conditions in which they are maintained.

2.2 Preparation of Tissues for Light and Transmission Electron Microscopy.

Animals were anaesthetised with pentobarbitone sodium (Nembutal, Bomac Laboratories, Asquith, NSW) at a dose rate of 6.0 mg/10 g body weight and fixed by vascular perfusion through the left ventricle of the heart (Forssmann *et al.*, 1977). The vascular system was initially rinsed with heparinised physiological saline containing 2.5% polyvinyl pyrrolidone and 0.5% procaine hydrochloride until the outflow of blood had ceased, followed by infusion of 3% paraformaldehyde/3% glutaraldehyde in 0.1M phosphate buffer (pH 7.2) containing 2.5% polyvinyl pyrrolidone for 5-10 minutes. The testes and/or epididymides and vasa deferentia were removed and cut into 1 mm cubes. Representative samples of these tissues were collected and further fixed by immersion for one to four hours. They were subsequently rinsed in 0.1 M-phosphate buffer, pH 7.2, post-fixed in 1% osmium tetroxide, dehydrated through a graded series of alcohols, cleared in propylene oxide and embedded in Spurr's or TAAB TK3 epoxy resin (TAAB Laboratories, Berkshire). Blocks were polymerised at 60°C for at least 48 hours. Thick plastic sections (0.5-1.0 μm) were cut using a Reichert-Jung Ultracut ultramicrotome with a glass knife and stained with 0.025% toluidine blue in 0.5% sodium tetraborate before viewing under an Olympus BHT-2 or Vanox light microscope. Areas of interest were selected from the thick plastic sections, the blocks trimmed and ultra-thin sections of silver/gold interference colours (70-90 μm) were cut using a diamond knife (Diatome Ltd., Bienne, Switzerland). Sections were collected onto copper/palladium grids (200 mesh) and stained with 2% uranyl acetate in 70% alcohol, followed by lead citrate (Reynolds, 1963). Sections were viewed on a JEOL 100S or Phillips CM100 transmission electron microscope.

For autoradiographic studies, tissues were prepared for paraffin embedding. Testes and genital tracts (epididymides and vasa deferentia) were removed and immersion fixed in Bouin's solution. They were then dehydrated in a series of alcohols, cleared in safsolv (Ajax Chemicals, Adelaide) and infiltrated with molten paraffin wax, using a Shandon Duplex Processor, before embedding in fresh paraffin wax (Paraplast Plus) using a Tissue Tek II wax dispenser. Blocks were sectioned at 5-7 μm using a Leitz Lab Tek rotary microtome, sections were floated onto a warm water bath, collected onto glass slides coated with "subbing" solution (0.005% gelatin, 0.0005% chrome alum in distilled water) and dried in an oven at 37-40°C for 24 hours. Sections were subsequently taken to water and either processed for autoradiography, or stained with one of several stains (see the methods sections of later chapters for details).

Handwritten notes in the right margin, including a vertical line and some illegible text.

Chapter 3 Organisation of the Seminiferous Epithelium

3.1 Introduction

The organisation of the seminiferous epithelium has been studied extensively in a number of rodents including the laboratory rat (Leblond and Clermont, 1952a,b; Hess, 1990; Russell *et al.*, 1990a) and laboratory mouse (Oakberg, 1956a,b; Russell *et al.*, 1990a), however, only limited information is available for species of Australian rodents. The only study within the literature of the cytological organisation of the seminiferous epithelium of Australian rodents is one that was conducted within our laboratory. In this study, the seminiferous epithelium of both the plains rat and the hopping mouse was arbitrarily divided into eight cellular associations (Peirce and Breed, 1987). From this study, however, it is not possible to conclusively determine the degree of similarity between the organisation of the seminiferous epithelium in these and common laboratory rodent species, for several reasons. Firstly, the scheme adopted for the identification of cellular associations in the Australian rodents, the tubular morphology scheme (Berndtson, 1977), is not the same as that used in the majority of laboratory rodent studies, making species comparisons somewhat difficult. Secondly, the criteria that were chosen for defining the boundaries between adjacent cellular associations may not have been entirely appropriate, since these criteria were initially devised for use with thick paraffin-embedded, PAS-stained, tissue sections rather than the thin plastic-embedded, toluidine blue-stained, tissue sections employed in the study.

Despite the limitations of Peirce and Breed's (1987) original study, several interspecific differences in organisation of the seminiferous epithelium among Australian rodents and between laboratory and native Australian species are evident. Whereas the organisation of plains rat testes appears to be similar to that of laboratory rodents, anomalies are apparent in hopping mouse testes. Individual cellular associations appear more varied in their composition and occupy smaller regions of the epithelium within a tubule (Peirce and Breed, 1987). These findings are supported by a study of transillumination patterns along the length of seminiferous tubules (Pollanen and Breed, 1991) in which patterns similar to those of the laboratory rat are seen in the plains rat, but hopping mouse tubules lack a clear transillumination pattern. Thus, in the latter species, a difference in the arrangement of cellular associations along the length of the seminiferous tubules has been suggested.

Due to the limitations of the previous study (Peirce and Breed, 1987) and refinement of identification criteria that are better suited to the use of thin plastic sections (Russell *et al.*, 1990a; Hess, 1990), it was decided to reinvestigate the organisation of the seminiferous

epithelium in the plains rat and hopping mouse. The aims of the present study therefore are to:

- identify criteria in thin plastic sections of plains rat and hopping mouse testes that delimit the boundaries between cellular associations,
- describe the resultant cellular associations as a basis for further investigation of spermatogenesis,
- ascertain whether the composition of hopping mouse cellular associations is as variable as previously suggested, given a sharper delineation of boundaries between associations and
- compare the organisation of the seminiferous epithelium in the plains rat and hopping mouse with that of the laboratory rat and laboratory mouse.

3.2 Materials and Methods

3.2.1 Tissue Preparation and Photomicrography

Testicular tissue was collected from sexually mature male plains rats and hopping mice of various ages ranging from three months to five years and prepared for embedding in epoxy resin as described in Chapter 2. Tissue sections were cut on an ultramicrotome at a thickness of 0.5-1 μ m, stained with toluidine blue in borate buffer and viewed under an Olympus BH-2 or Vanox microscope fitted with planapochromatic objective lenses. Regions of the seminiferous epithelium showing various appearances of the cellular associations were photographed using Kodak Tech-Pan film.

3.2.2 Guidelines for the Identification of Cellular Associations

To facilitate the comparison of plains rat and hopping mouse cellular associations with those of laboratory rodents, this study adopted and modified where necessary, the staging scheme and criteria initially used by Leblond and Clermont (1952a) to identify cellular associations of the rat seminiferous epithelium. In the rat, 14 cellular associations could be identified in thick paraffin sections of testes stained with PAS-FSA, on the basis of the appearance of spermatids during the first 14 steps of spermiogenesis (Leblond and Clermont, 1952a). This staging scheme was subsequently refined by Russell *et al.* (1990a) for use with toluidine blue stained plastic sections.

In the present study, descriptions of individual cellular associations and the selection of staging criteria are based on features of the seminiferous epithelium common to the majority of animals of the species. Testes displaying features that suggest disturbances of

spermatogenesis, eg. reduced height of the seminiferous epithelium, decreased tubular diameter, a depletion of germ cell numbers, or the predominant presence of Sertoli cells, were excluded from the study. The guidelines a) to f) listed below were also applied to take into account species differences in seminiferous epithelial organisation and a reduction in the ability to visualise entire cells due to the short plane of focus when using thin (1 μm) plastic, as opposed to thick (5-7 μm) paraffin, sections.

- a) Only round spermatids that were sectioned through the Golgi and/or developing acrosomal system (approximately 10-20% of all early round spermatids per tubular cross section) were used for determining which stage of the cycle of the seminiferous epithelium was depicted by a particular cellular association. Some hopping mouse cellular associations, however, occupied small areas of the seminiferous epithelium (as little as 1/5 of a tubular cross section) and contained as few as 8-10 round spermatids, most of which were not appropriately oriented for determining the cycle stage. In such cases, stage identification was based on the appearance of the one or two spermatids sectioned through the Golgi region, in conjunction with the appearances of the other cell types (spermatogonia, spermatocytes) comprising the cellular association.
- b) When cell types characteristic of two different cellular associations were present in the same tubular cross section, stage identification was based on the appearance of the younger generation of spermatids and in particular, taking note of the most common acrosomal form present (as per Russell *et al.*, 1990a).
- c) Where boundaries between cycle stages, as designated by Russell *et al.*, (1990a), could not be determined consistently, ie. when spermatids with characteristics of two consecutive stages occurred together, these stages were grouped into a single stage. [For example, Russell *et al.* (1990a) combined stages II and III of Leblond and Clermont (1952a), because spermatids at both steps 1 and 2 of spermiogenesis were consistently intermingled within a particular area of the epithelium.] New boundaries between stages were defined when there were clear differences in the development of spermatids. For example, the extent of spread of the acrosome over the nucleus of round spermatids, used to distinguish between stages III and IV, was different between the laboratory rat (40°, Russell *et al.*, 1990a), plains rat (60°) and hopping mouse (70°).
- d) In the plains rat, all tubular cross sections containing meiotic figures and/or secondary spermatocytes were classified as a single cellular association even if there was intermingling of a few diplotene primary spermatocytes or early round spermatids. In the hopping mouse, meiotic figures and/or secondary spermatocytes rarely occupied more than 50% of a tubular cross sectional profile, with the remaining area at either the preceding or following stage of the seminiferous epithelial cycle. Hence, these tubules were classified as containing two (or more) cellular associations.

- e) In the plains rat, the generation of primary spermatocytes remaining subsequent to the onset of the meiotic divisions was designated as pachytene, although they were not readily distinguishable morphologically from the late zygotene spermatocytes of the previous stage.
- f) New criteria were defined for the boundaries between those cellular associations in testes of plains rats and hopping mice that contained a single generation of spermatids. This was necessary because of differences in the progression of elongation of the spermatid head and its final shape in these species, compared with the laboratory rat and laboratory mouse.

3.3 Results

The testicular seminiferous epithelium of both the plains rat and hopping mouse was organised into cellular associations that were visible in longitudinal and transverse sections of seminiferous tubules. In addition to the supporting Sertoli cells, which extended the entire height of the seminiferous epithelium from the basal lamina to the tubular lumen, each cellular association was composed of:

- a) one or two generations of spermatogonia in contact with the basal lamina at the base of the seminiferous tubule,
- b) one or two generations of primary and/or secondary spermatocytes at varying points through meiosis, occupying the central band of the epithelium and
- c) one or two generations of spermatids located closest to the tubular lumen.

Before the composition of the individual cellular associations of each species is presented in detail, the morphological characteristics of spermatogonia and spermatocytes of the plains rat and hopping mouse will be described.

3.3.1 Descriptions of Spermatogonia and Spermatocytes

The various generations of spermatogonia and spermatocytes in the plains rat and hopping mouse are morphologically similar, hence a single description of their characteristics is given.

Spermatogonia

Type A spermatogonia were present in all cellular associations. These cells were characterised by a very pale, homogeneously stained, oval nucleus containing little or no dense chromatin and up to several nucleoli. Several shallow patches of chromatin were

sometimes attached to the nuclear envelope. The basal plasmalemmae of type A spermatogonia showed extensive contact with the basal lamina and were flattened against it. The various populations of type A spermatogonia displayed a similar morphology and could be distinguished from each other only by noting the cellular association in which mitoses of spermatogonia occurred. In the plains rat, mitotic figures of type A spermatogonia were observed in stages VI, VIII and IX (refer to Fig. 3.1), whereas in the hopping mouse they were observed in stages IV and VII (Fig. 3.13).

Intermediate spermatogonia were similar in appearance to type A, except that the number and depth of the chromatin patches attached to the nuclear envelope were greater and nucleoli were more abundant. Nuclei of intermediate spermatogonia were generally less oval (slightly narrower and taller) than those of type A spermatogonia.

Type B spermatogonia were more rounded than the preceding spermatogonial types and tended to have less of their basal plasmalemma in contact with the basal lamina. Their nuclei were round rather than oval in section and displayed large numbers of intensely stained chromatin clumps along the nuclear envelope, some of which extended towards the centre of the nucleus. Their nuclear matrix was finely granular and tended to stain slightly darker than that of intermediate spermatogonia. A prominent central nucleolus was often observed.

Primary Spermatocytes

Preleptotene spermatocytes were rounder than type B spermatogonia and displayed minimal contact with the basal lamina. Late preleptotene spermatocytes had completely lost contact with the basal lamina. Nuclei were morphologically similar to those of type B spermatogonia, although they appeared smaller and the chromatin located beneath the nuclear envelope tended to be more diffuse. The nuclear matrix of older preleptotene spermatocytes (in stage VI of plains rat and stage IV of hopping mouse) appeared speckled or flecked rather than granular as in early preleptotene and type B spermatogonia.

Fine thread-like strands of chromatin characterised the nuclei of leptotene spermatocytes. Transversely sectioned threads appeared as small 'spots' and several nucleoli were generally visible. Little contrast was evident between the chromatin threads and nuclear matrix.

Zygotene spermatocytes were slightly larger and showed thicker strands of chromatin than leptotene spermatocytes. Nucleoli were rarely seen. Relatively unstained regions of nuclear matrix between the chromatin threads contrasted with their intense staining.

Pachytene spermatocytes were round to oval with a round, centrally located nucleus. In young pachytene spermatocytes, large chromatin patches or blotches occupied much of the nucleus; but in successive cellular associations distinct regions of nuclear matrix became increasingly evident between the condensing chromosomes. Both the cells and their nuclei progressively increased in size and became more elongated. A prominent, round nucleolus that stained more intensely than the chromatin was often seen in the nuclei.

Diplotene spermatocytes were indistinguishable from the most mature pachytene spermatocytes. Separation of the chromosomes, definitive of the diplotene stage, could not be visualised. The nucleoli of late pachytene and diplotene spermatocytes of the cellular association immediately prior to the meiotic divisions sometimes showed a light-staining round core.

Secondary Spermatocytes

Secondary spermatocytes were similar in appearance to early (step 1) round spermatids, although they were generally about 30% larger. Their round nuclei contained small, irregular flecks of chromatin and one or two round nucleoli superimposed on the 'fluffy' or 'cloud-like' appearance of the nuclear matrix. (In comparison, the nuclear matrix of round spermatids was generally more 'grainy' in appearance).

3.3.2 Cellular Associations/Cycle Stages of the Plains Rat, *Pseudomys australis*

Germ cells at all stages of the spermatogenic process were present within the seminiferous tubules of the plains rat testis and were organised into 11 cellular associations, each representing a stage of the cycle of the seminiferous epithelium. A comparison of the 11 cellular associations in the plains rat with the 14 cellular associations in the laboratory rat is provided in Table 3.1. The criteria used in the identification of cellular associations in the plains rat, which are based predominantly on the appearance of the younger spermatid generation, are presented in Table 3.2. Stage I of the cycle of the seminiferous epithelium was defined as the cellular association commencing at the completion of the second meiotic division, with the appearance of the newly formed round spermatid population. [In schemes where the cellular associations are based on tubular morphology, stage 1 commences at the completion of release of the elongate spermatid population from the seminiferous epithelium.] A cycle map outlining all of the cell types present in each cellular association is provided in Fig. 3.1.

Figure 3.1 Cycle Map, Plains Rat

Map of the cycle of the seminiferous epithelium of the plains rat, *Pseudomys australis* showing phases of germ cell development. The vertical columns, designated by Roman numerals, depict the cellular associations, each of which represents a stage of the cycle. The equivalent cycle stages in the laboratory rat (as per Russell *et al.*, 1990a) are given in brackets. One cycle corresponds to a complete series of the 11 cellular associations. The developmental progression of a cell is followed horizontally until the right hand border of the cycle map is reached. The cell progression then continues at the left hand side of the cycle map one row up. The cycle map ends with the release of spermatids from the seminiferous epithelium, ie. spermiogenesis. By convention, the cellular association at the left hand side of the cycle map (stage I) depicts the newly formed round spermatids (following division of secondary spermatocytes) that have not yet developed an acrosome.

The symbols used designate specific phases of germ cell development as follows:

- A type A spermatogonium
- A_m mitosis of type A spermatogonia
- _mIn mitosis giving rise to intermediate spermatogonia
- In intermediate spermatogonium
- In_m mitosis of intermediate spermatogonia
- B type B spermatogonium
- B_m mitosis of type B spermatogonia
- Pl preleptotene primary spermatocyte
- L leptotene primary spermatocyte
- Z zygotene primary spermatocyte
- P pachytene primary spermatocyte
- Di diplotene primary spermatocyte
- _m2^o_m meiotic divisions of diplotene primary spermatocytes and secondary spermatocytes, giving rise to early round spermatids
- 1-16 developmental steps of spermatids during spermiogenesis

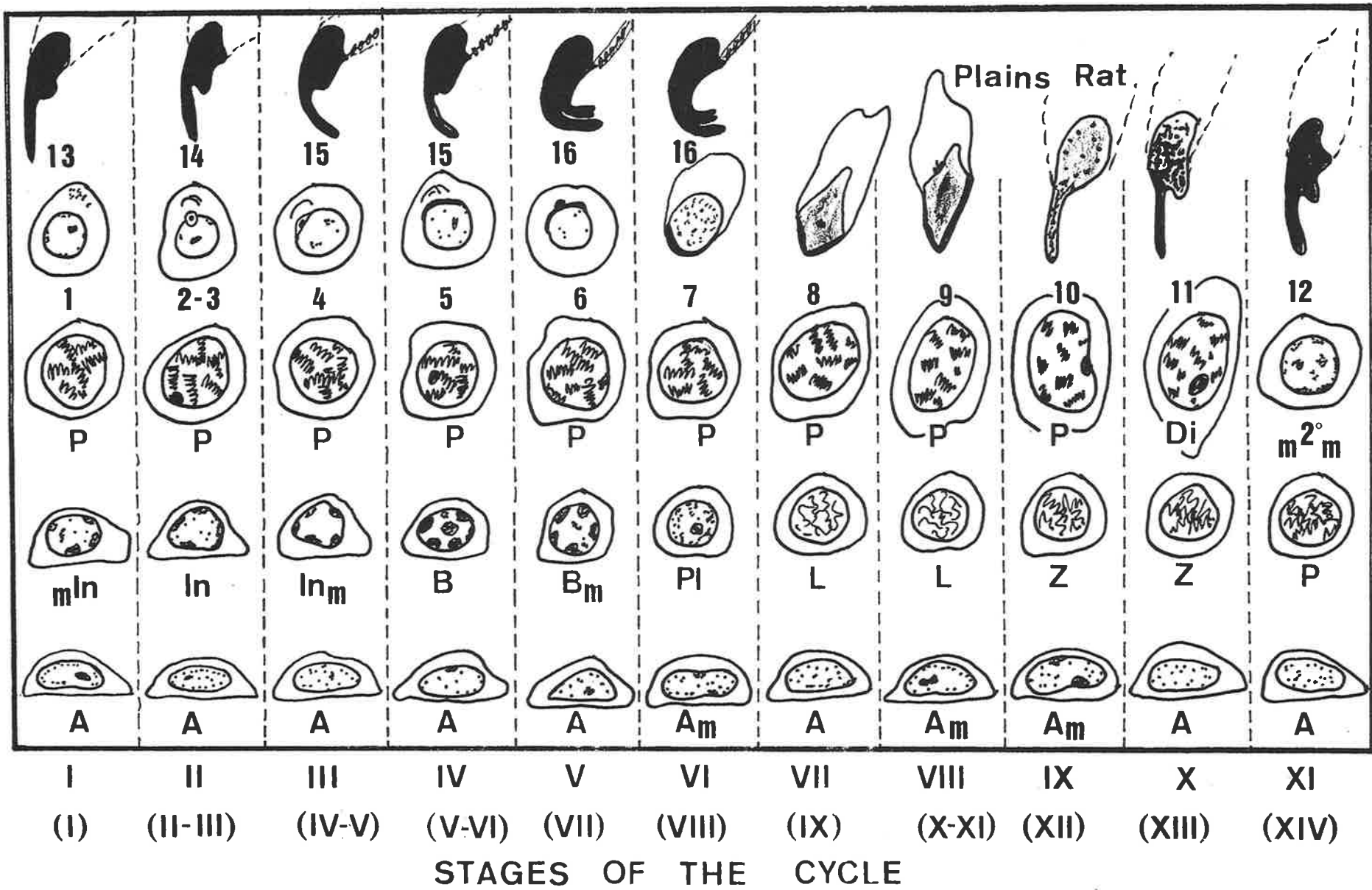


Table 3.1**Comparison of the Classification of Cellular Associations in the Plains Rat, Hopping Mouse, Laboratory Rat and Laboratory Mouse**

Species	Cellular Association/Stage of the Cycle of the Seminiferous Epithelium													Total No. of Associations
Laboratory rat*	I	II-III	IV	V	VI	VII	VIII	IX	X	XI	XII	XIII	XIV	14
Laboratory mouse*	I	II-III	IV	V	VI	VII	VIII	IX	X	XI	XI	XI	XII	12
Plains rat	I	II	III	III-IV	IV	V	VI	VII	VIII	VIII	IX	X	XI	11
Hopping mouse	I	II	III	III-IV	IV	IV	V	VI	VI	VII	VII	VII	VIII	8

* Data for the laboratory rat and mouse are taken from Russell *et al.* (1990a)

Cellular associations were defined according to the characteristics of the younger spermatid generation. For each species, the cellular associations containing spermatids at equivalent steps in their development are aligned vertically.

Table 3.2

Criteria used to Identify Cellular Associations in the Plains Rat, *Pseudomys australis*
(based predominantly on the appearances of the younger spermatid generation)

STAGE	CRITERIA
I	Begins with the completion of the second meiotic division. Ends immediately prior to the appearance of a proacrosomal granule and/or vesicle. No acrosomal system is visible in round spermatids, which are smaller than secondary spermatocytes.
II	Begins with the first appearance of a proacrosomal granule in the spermatid cytoplasm. Ends when the acrosomal vesicle, containing a large granule, forms a small concavity in the nuclear envelope.
III	Begins with the acrosomal granule touching the vesicular surface adjacent to the nucleus; nuclear concavity has flattened. Ends when the flattened acrosomal vesicle has become hemispherical and dense acrosomal material is seen adjacent to the nuclear envelope. Angle subtended by the spread of the acrosome does not exceed 60°.
IV	From spread of the acrosome over the nuclear envelope of greater than 60° to an acrosomal angle of 120°. Elongated spermatids are located more adluminally than in previous stages.
V	Angle subtended by the acrosome is greater than 120°. Nucleus is eccentric within the cytoplasm, but acrosomal pole of the nucleus does not touch the plasma membrane. By the end of this stage, elongated spermatids line the tubular lumen.
VI	Acrosome is in contact with the plasma membrane of the spermatid nucleus. Ends before the spermatid nucleus becomes distorted. Slight bilateral flattening of the nucleus may be evident, but nuclear symmetry is retained.
VII	Spermatid nuclei are asymmetrical and the nuclear envelope distal to the acrosome is bilaterally flattened. Most of the acrosome covers the dorsal nuclear surface with a small amount over the apical aspect. Nuclear shape is more variable than in stage VI. Ends prior to sharp angulation of the nucleus between its caudal and ventral and/or dorsal aspects.
VIII	Begins with the caudal nuclear surface forming a sharp angle with the ventral and/or dorsal surfaces. Apex of the nucleus covered by the acrosome curves ventrally to form a hook. Little or no condensation of the nuclear chromatin is evident, as gauged by the intensity of nuclear staining.
IX	Dorsal surface of the sperm head shows increased curvature and the hook is elongated. Staining intensity of the chromatin is greater, but is not uniform throughout the nucleus.
X	Entire spermatid nucleus stains densely. A lighter staining projection may be seen on the ventral aspect of the spermatid head. Ends immediately prior to the appearance of any primary spermatocytes at metaphase of meiosis I.
XI	Includes the presence of metaphase, anaphase or telophase of meiosis I, or secondary spermatocytes, or any of the phases of meiosis II.

Cross sections of plains rat seminiferous tubules displayed a single cellular association only. No variations were seen in cellular composition or morphology of the same cycle stage between different tubular cross sections of the same animal, or between animals.

Stage I

Stage I contained type A spermatogonia, pachytene spermatocytes, round and elongate spermatids. Occasionally, mitotic figures and intermediate spermatogonia were seen in late stage I, although they were more commonly a feature of early stage II. The youngest spermatids were round cells with round nuclei and lacked definitive distinguishing characteristics. A prominent perinuclear Golgi was evident in round spermatids late in stage I, but proacrosomal elements could not be detected with light microscopy. Groups of elongate spermatids occurred within deep crypts of Sertoli cells, between the round spermatids (Fig. 3.2).

Stage II

Type A spermatogonia, mitotic figures and intermediate spermatogonia were present along with pachytene spermatocytes, round and elongate spermatids. Mitotic figures were generally observed in those stage II cross sections in which the round spermatids contained a discernible proacrosomal granule in their cytoplasm, adjacent to the Golgi. Later in stage II, a rounded acrosomal vesicle containing a prominent granule was positioned on the nuclear envelope adjacent to the Golgi, indenting it slightly. The granule was not in contact with the vesicular membrane. Elongate spermatids were similar in their position and morphology to those of stage I spermatids (Fig. 3.3).

Stage III

Types A, intermediate and B spermatogonia, mitotic figures and pachytene spermatocytes were all seen in stage III tubules. The acrosomal granule of round spermatids was in contact with the surface of the acrosomal vesicle overlying the nucleus. The amount of the nuclear envelope covered by the acrosome progressively increased and the depression of the acrosome into the nucleus became shallower. The acrosomal vesicle then formed a straight edge with the nucleus, which in the latter part of the stage became hemispherical. The angle of spread of the acrosome over the nucleus, which was determined by estimating the angle formed between lines projected from the margins of the acrosomal vesicle through the centre of the nucleus, approached 60° . The acrosomal granule, although flattened, was clearly visible approximately mid-way along the acrosome. Elongate spermatids were positioned more adluminally than in the previous stage, in crypts of the Sertoli cells (Fig. 3.4).

Stage IV

Types A and B spermatogonia and pachytene spermatocytes formed the basal layers of the epithelium. The spread of the acrosome over the nuclear surface of round spermatids was greater than in the previous stage with the angle subtended by the acrosome ranging from 60° to 120° . The Golgi, when visible, was seen near the lateral margin of the acrosome. Most elongate spermatids were located at about the level of the most luminal layer of round spermatids (Fig. 3.5).

Stage V

Types A and B spermatogonia, mitotic figures and preleptotene spermatocytes were scattered along the basal lamina. Pachytene spermatocytes occurred above them within the epithelium. The angle subtended by the acrosome of round spermatids exceeded 120° . In some instances a slight indentation of the nucleus, the marginal fossa, was seen at the rim of the acrosome. Contact of the flagellum with the caudal surface of the nucleus was also sometimes observed. The position of the nucleus within the spermatid was either central or eccentric with the acrosomal pole closer to the plasmalemma. The heads of elongate spermatids were generally located adluminal to the round spermatids. Late in the stage they surrounded the lumen (Fig. 3.6), or occasionally were absent, with the spermatids having been released from the epithelium. When the latter had occurred, only cytoplasmic bodies lined the tubular lumen.

Stage VI

Type A spermatogonia, preleptotene and pachytene spermatocytes were present. The round spermatid nucleus and its acrosome had made contact with the plasmalemma and the cytoplasm appeared as an elongated column extending caudally from the nucleus towards the tubular lumen. Most spermatid nuclei appeared slightly ovoid and their acrosomes were oriented towards the base of the tubule. Occasionally, a flagellum extending from the caudal aspect of the nucleus was observed. The elongate spermatid population lined the lumen and the majority of spermatid heads were seen either above the level of the cytoplasmic bodies, or in the tubular lumen (Fig. 3.7). Spermiation was generally completed during this stage.

Stage VII

Very early in stage VII the transition from preleptotene to leptotene spermatocytes occurred. Spermatid nuclei had begun to elongate and change shape. Early in the stage, their nuclear surfaces distal to the acrosome were markedly flattened. The nuclei then appeared asymmetrical, with the acrosome lying predominantly on one elongated surface, except for a small region covering the apical aspect of the nucleus. The manchette could

Plate 1 Cellular Associations of Plains Rat Seminiferous Tubules.
Stages I - IV

Figure 3.2

The presence of round spermatids (R) with no discernible acrosomal constituents identifies the cellular association as being **Stage I** of the cycle of the seminiferous epithelium.

A = type A spermatogonium, P = pachytene primary spermatocyte, E = elongate spermatid, Se = Sertoli cell nucleus.

bar = 10 μm

Figure 3.3

Stage II. A vesicle containing an acrosomal granule (arrows) is clearly visible in contact with the nucleus of round spermatids.

In = intermediate spermatogonium, P = pachytene primary spermatocyte, E = elongate spermatid.

bar = 10 μm

Figure 3.4

Stage III is identified by flattening of the acrosomal vesicle on the nucleus of the round spermatids (arrows).

Se = Sertoli cell nucleus, In = intermediate spermatogonium, B = type B spermatogonium, P = pachytene spermatocyte, E = elongate spermatid.

bar = 10 μm

Figure 3.5

The acrosome of the round spermatids (R) has spread between 60° and 120° over the nuclear surface, indicative of **Stage IV**.

Se = Sertoli cell nucleus, B = type B spermatogonium, P = pachytene primary spermatocyte, E = elongate spermatid.

bar = 10 μm

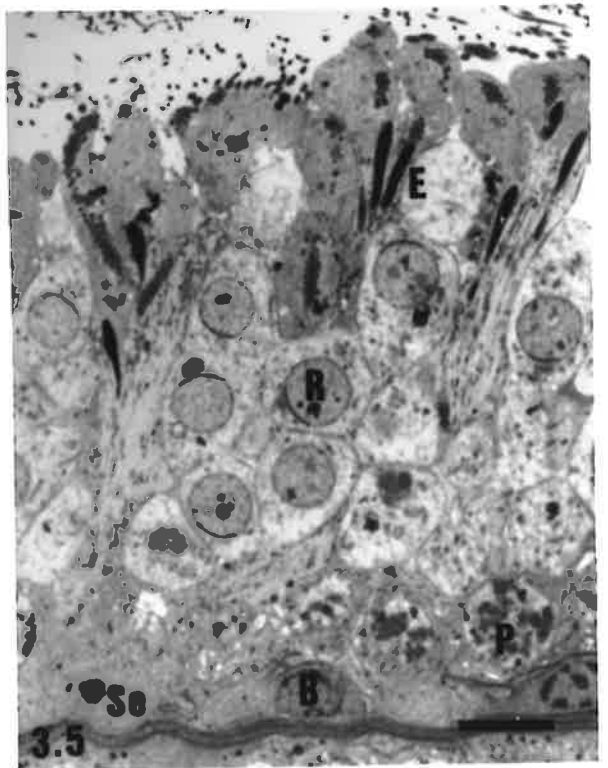
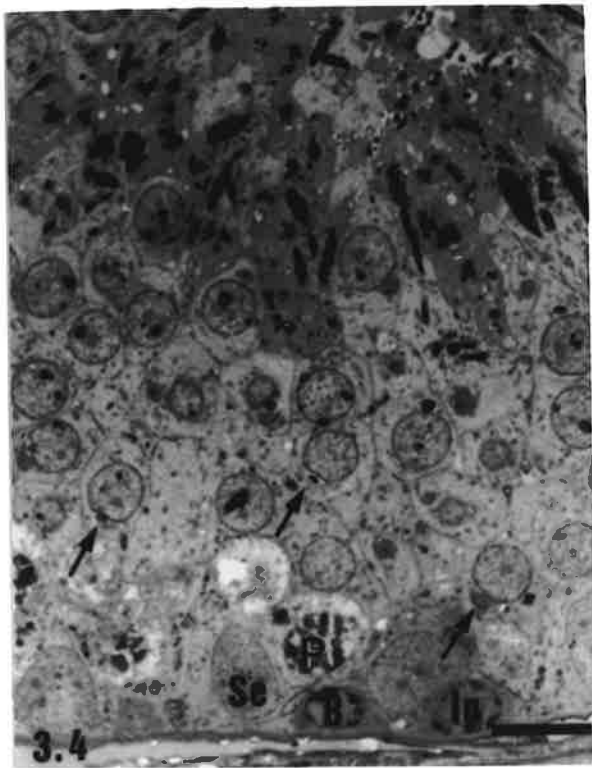
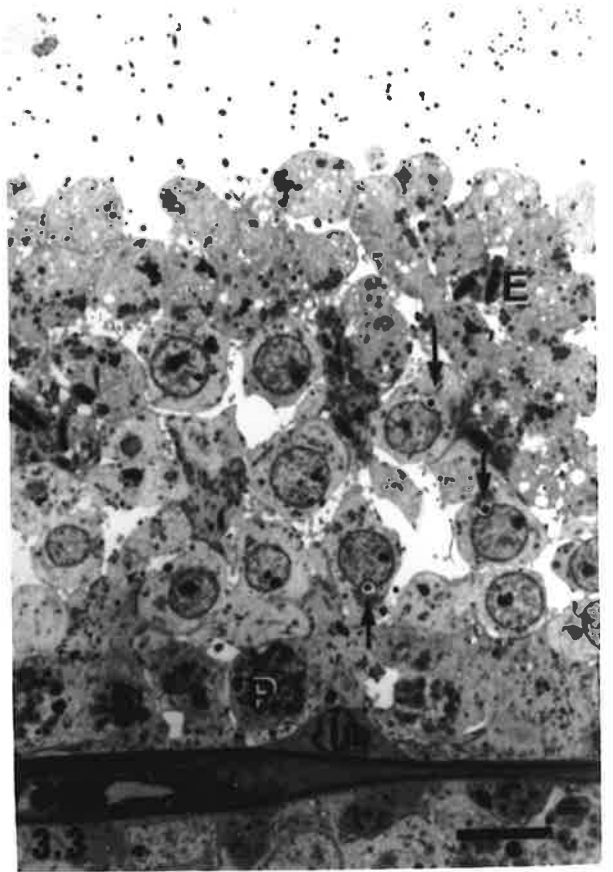
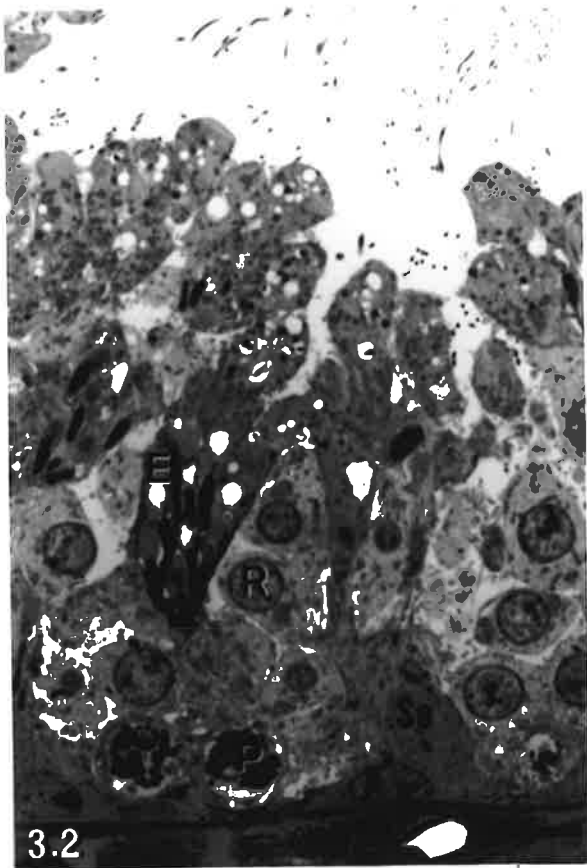


Plate 2 Cellular Associations of Plains Rat Seminiferous Tubules.
Stages V - VIII

Figure 3.6

Stage V. The acrosome has spread more than 120° over the nuclear surface of the round spermatids (R) and the nucleus occupies an eccentric position within the cell. Elongate spermatids (E) line the lumen.

m = mitosis of a spermatogonium, P = pachytene primary spermatocyte.

bar = 10 μm

Figure 3.7

Stage VI. The acrosome of round spermatids (R) is in contact with the plasmalemma. The nuclei of the round spermatids have elongated slightly but are still symmetrical. Spermiation is not complete; several elongate spermatids (small arrows) are located along the luminal surface of the epithelium, above a residual body (asterisk).

Pl = preleptotene primary spermatocyte, P = pachytene primary spermatocyte.

bar = 10 μm

Figure 3.8

Stage VII. The nuclei of the spermatid population (R) show bilateral flattening and a loss of symmetry. Several residual bodies (asterisks) of the elongate spermatids released during stage VI are located on the luminal surface of the epithelium.

Se = Sertoli cell nucleus, Pl = primary spermatocyte in transition from preleptotene to leptotene, P = pachytene primary spermatocyte.

bar = 10 μm

Figure 3.9

Stage VIII. The nuclei of the spermatid population have elongated and sharp angles are visible between the caudal and ventral surfaces of the nucleus (arrow). The acrosome lies predominantly over the dorsal nuclear surface.

SE = Sertoli cell nucleus, L = leptotene primary spermatocytes, P = pachytene primary spermatocyte.

bar = 10 μm

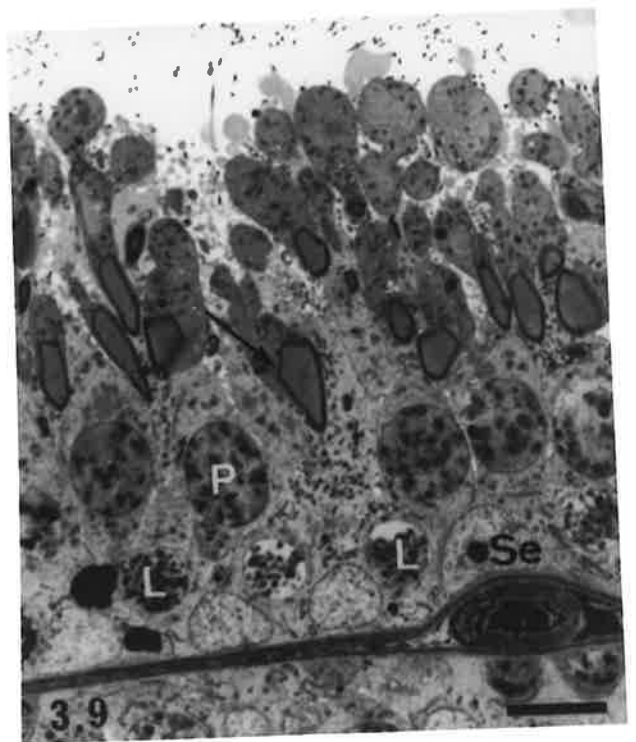
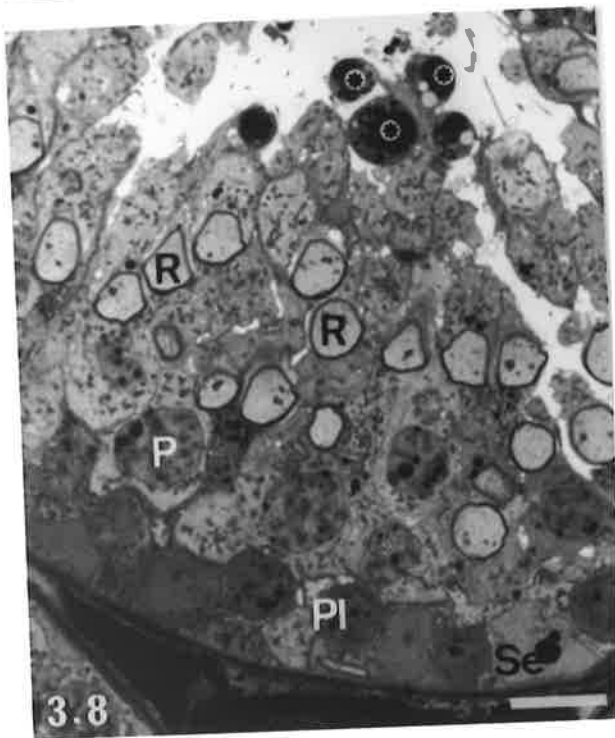
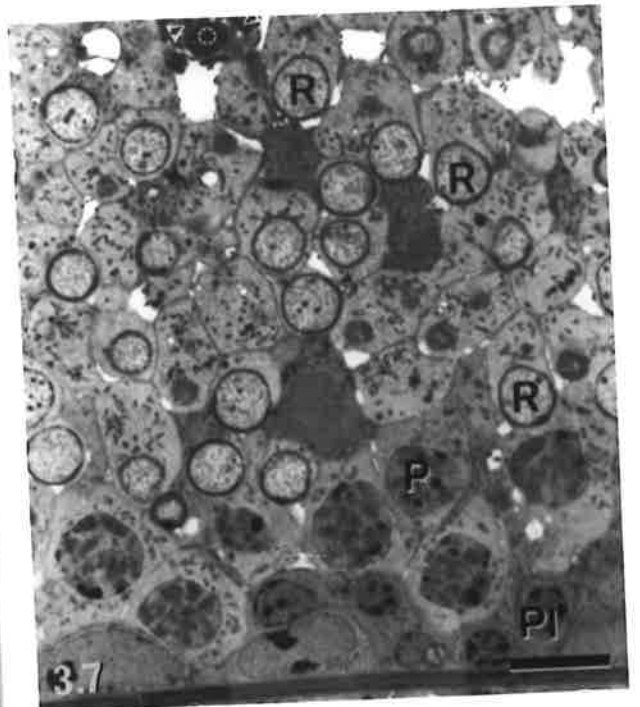
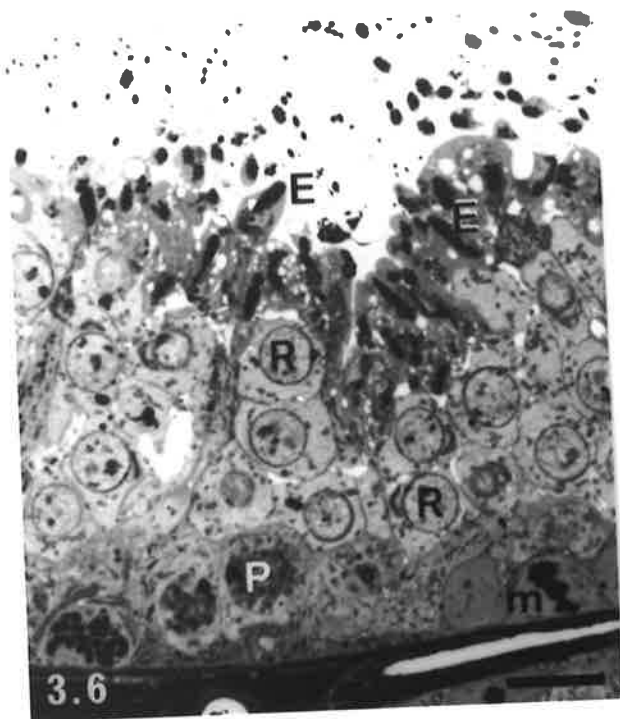


Plate 3 Cellular Associations of Plains Rat Seminiferous Tubules.
Stages IX - XI

Figure 3.10

Stage IX. An elongated hook (arrow) is visible extending from the apex of the spermatid head. Condensation of chromatin is not uniform within the nuclei of spermatids.

A = type A spermatogonium, Z = zygotene primary spermatocyte, P = pachytene primary spermatocyte.

bar = 10 μm

Figure 3.11

Stage X. Elongate spermatid nuclei (E) show intense staining.

Se = Sertoli cell nucleus, A = type A spermatogonium, Z = zygotene primary spermatocyte, P = pachytene/diplotene primary spermatocyte.

bar = 10 μm

Figures 3.12a-c

Stage XI is characterised by any of meiosis I figures, secondary spermatocytes or meiosis II figures.

bar = 10 μm

12a. In stage XIa, the majority of the diplotene primary spermatocyte generation have entered meiosis I (mI).

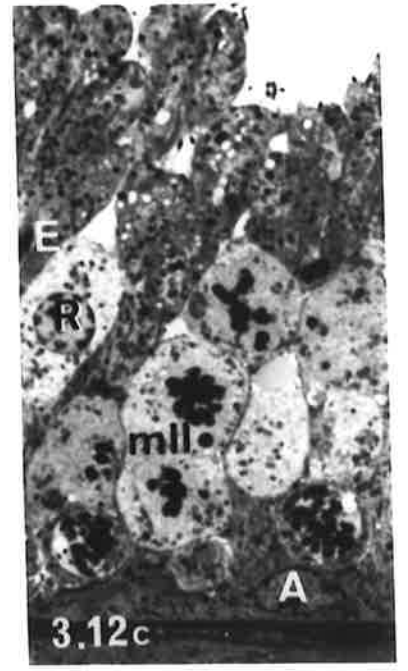
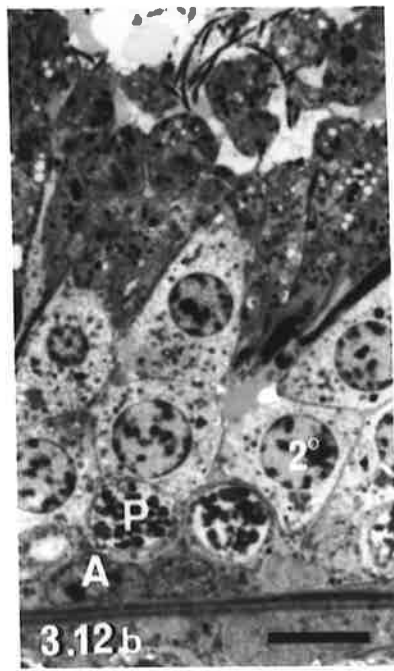
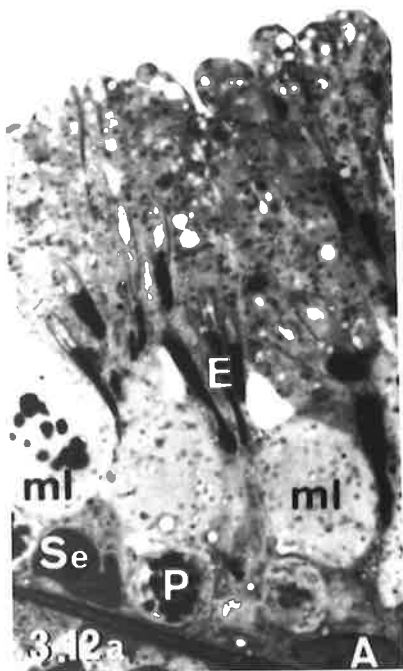
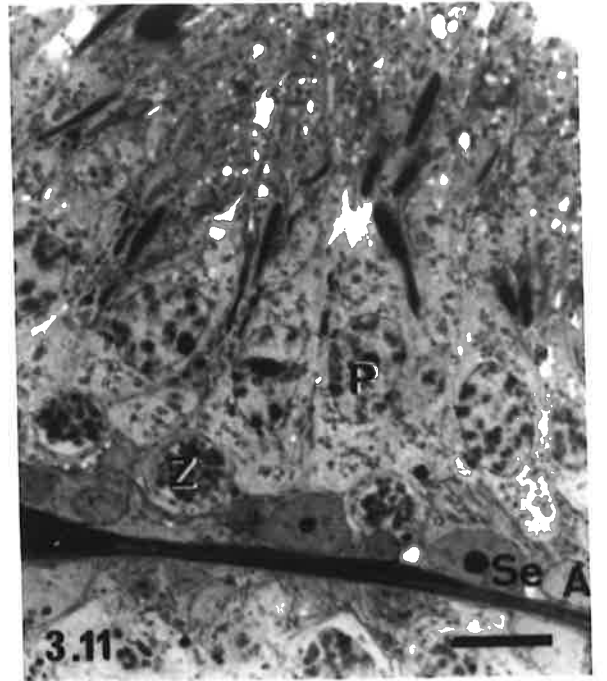
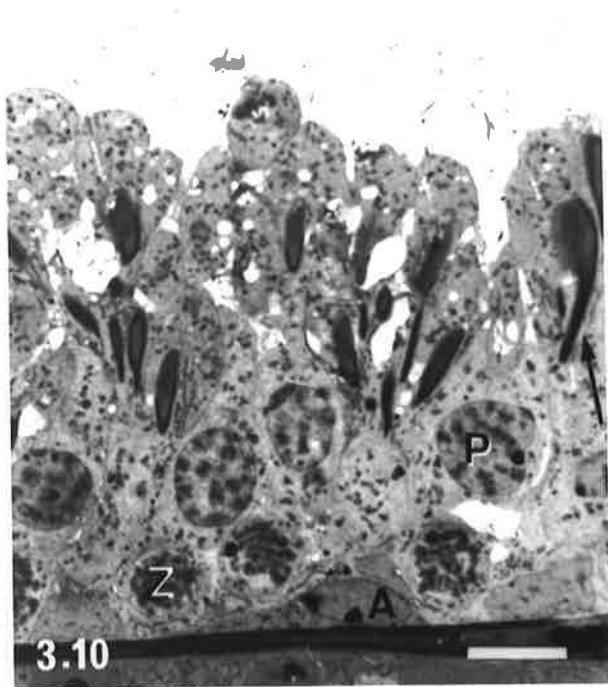
A = type A spermatogonium, P = pachytene primary spermatocyte (younger spermatocyte generation), E = elongate spermatid, Se = Sertoli cell nucleus.

12b. In stage XIb, secondary spermatocytes (2°) are the distinguishing feature.

A = type A spermatogonium, P = pachytene primary spermatocyte.

12c. In stage XIc, secondary spermatocytes have progressed to meiosis II (mII).

A = type A spermatogonium, R = early round spermatid, E = elongate spermatid.



be seen extending from the margins of the acrosome in some spermatids (Fig. 3.8). Type A spermatogonia and pachytene spermatocytes completed the association.

Stage VIII

Type A spermatogonia, leptotene and pachytene spermatocytes were present. Some elongation of the spermatid head had occurred, but little nuclear condensation was evident. In appropriate orientations, it could be seen that the caudal surface of the spermatid nucleus had formed sharp angles with the dorsal and ventral surfaces. The dorsal angle was situated near the rim of the acrosome, whereas the ventral angle was close to the attachment of the flagellum into the sperm head. The apex of the nucleus covered by acrosome curved in a ventral direction, giving rise to a hook shape. Most of the spermatid cytoplasm was located caudal to the nucleus along the flagellum (Fig. 3.9).

Stage IX

Type A spermatogonia, zygotene and pachytene spermatocytes were observed. Condensation of spermatid nuclei, as inferred by increased intensity of staining of chromatin, had occurred, but was not uniform throughout the entire nucleus. In appropriate planes of section, the dorsal surface of the spermatid head showed a sweeping curve. The hook, extending ventrally from the apex of the spermatid head, had elongated (Fig. 3.10).

Stage X

Type A spermatogonia, zygotene, pachytene and diplotene spermatocytes were present. Elongate spermatids were less scattered within the epithelium and groups of these spermatids were evident in some tubular cross sections. The spermatid nuclei were uniformly stained and staining intensity was such that the acrosome and nucleus could not easily be distinguished from one other (Fig. 3.11).

Stage XI

Type A spermatogonia and late zygotene/early pachytene spermatocytes were present. The older generation of primary spermatocytes had entered the first meiotic division. Metaphase and anaphase figures of meiosis I, along with secondary spermatocytes and meiosis II figures were observed. Cells in meiosis I were on average 30% larger than those of meiosis II and their chromosomes were generally more prominent. Elongate spermatids occurred in discrete groups above the level of mitotic figures, or between secondary spermatocytes.

Stage XI could usually be divided into three distinct sub-stages. During stage XIa, the majority of diplotene spermatocytes were at metaphase or anaphase of meiosis I (Fig.

3.12a); secondary spermatocytes were the distinguishing feature of stage XIb (Fig. 3.12b), while stage XIc contained meiosis II figures and occasional early round spermatids (Fig. 3.12c). Occasionally, cells at all three points in meiosis were observed adjacent to each other.

3.3.3 Seminiferous Epithelium of the Hopping Mouse, *Notomys alexis*

Eight cellular associations were identified in the seminiferous epithelium of the hopping mouse, according to the criteria presented in Table 3.3. The relationship between these 8 cellular associations and the 14 associations in the laboratory rat is shown in Table 3.1. The most common cellular composition of each association in the hopping mouse is illustrated in the cycle map (Fig. 3.13). As in the plains rat, cellular associations contained one or several generations of each of spermatogonia, spermatocytes and spermatids but, the morphological types that were observed together in any particular cellular association were more variable. Hence, some areas of the seminiferous epithelium could not be easily assigned to a particular cellular association.

3.3.3.1 Comments on the Application of Staging Criteria

Despite the application of predetermined criteria (Table 3.3) for identifying cellular associations, boundaries between certain cycle stages could not always be ascertained with confidence in the hopping mouse. At some interfaces between cellular associations either, spermatids that displayed morphologies characteristic of two consecutive stages were intermixed within the epithelium, or the spermatids displayed morphologies intermediate between two consecutive stages. In the former case, stage identification was based on the predominant spermatid morphology, although this may have been seen in as few as two or three cells. In the latter case, the morphologies and locations of the other germ cell types (spermatogonia and spermatocytes) present were considered before a stage identification was made.

Identification of cellular associations was further hampered because the use of thin ($1\mu\text{m}$) plastic sections meant that fewer cellular characteristics were visible for any particular spermatid sectioned. Hence, characteristics unique to a particular stage in spermatid development, such as the degree of acrosomal development, were not consistently visible for each cellular profile in thin plastic sections. Other characteristics, such as the degree of nuclear condensation and/or shaping and elongation of the spermatid head, were not reliable indicators of the cycle stage as they varied widely between adjacent spermatids. Likewise, within the seminiferous epithelium, the position of elongate spermatids ranged from deep within crypts of Sertoli cells, to the luminal surface, within the same tubular

cross section. Finally, staining with a monochromatic dye, toluidine blue, resulted in acrosomal features of late step elongate spermatids being indistinguishable from the condensed chromatin of the nucleus, hence this was not useful as a criterion for determining cycle stage.

Table 3.3
Criteria used to Identify Cellular Associations in the Hopping Mouse, *Notomys alexis*
 (based predominantly on the appearances of the younger spermatid generation)

STAGE	CRITERIA
I	No acrosomal system is seen in round spermatids, which are smaller than secondary spermatocytes.
II	Proacrosomal granules* and/or an acrosomal granule are seen in the spermatid cytoplasm. Rounded acrosomal vesicle indents the nuclear envelope.
III	Acrosomal vesicle is flattened over the nuclear envelope and the acrosomal granule is situated centrally along the flattened surface. Ends when the flattened acrosomal vesicle forms a hemisphere over the nuclear envelope. Angle subtended by the spread of the acrosome over the nucleus does not exceed 70°.
IV	Angle subtended by the spread of the acrosome over the nuclear surface is greater than 70°. Nucleus is eccentrically located, but its acrosomal pole is not in contact with the plasma membrane.
V	Spermatid nucleus is in contact with the plasma membrane. Nucleus is round or slightly ovoid. Lateral surfaces may be slightly flattened, but no significant distortion of nuclear shape or tapering of the caudal nuclear pole is evident.
VI	Spermatid nucleus is bilaterally flattened and tapers caudally. A wide range of nuclear shapes is evident, but the apico-caudal dimension of the nucleus is less than twice its width.
VII	Nuclear length is greater than twice its width. Nuclear condensation, as gauged by intensity of staining, is variable. Diplotene spermatocytes have not entered the meiotic divisions.
VIII	Meiotic metaphase, anaphase or telophase of meiosis I, or secondary spermatocytes, or any of the phases of meiosis II occur.

* Proacrosomal granules are extremely small and not readily visible by light microscopy in thin plastic sections.

3.3.3.2 Cellular Associations/Cycle Stages of the Hopping Mouse

While most cross sections of hopping mouse seminiferous tubules displayed a single cellular association, multi-stage tubular cross sections containing between two (Fig. 3.14) and five cellular associations (Fig. 3.15) were observed, confirming the previous report of Peirce and Breed (1987). The proportion of cross sections containing more than one association varied between animals. [Details of the frequency with which this variation occurred are reported in Chapter 4 of this thesis.] Furthermore, adjacent cellular associations did not always represent consecutive stages of the cycle of the seminiferous epithelium (see Figs 3.15 and 3.16).

Stage I

Types A and B spermatogonia and occasional mitotic figures (divisions of intermediate spermatogonia) were observed at the base of the tubule, with pachytene spermatocytes located above them. The younger population of spermatids had round, centrally located nuclei with few distinguishing features. A prominent perinuclear Golgi was observed in late stage I round spermatids. Elongate spermatids occupied a variable position in the epithelium, ranging from within crypts of Sertoli cells deep within the epithelium (Fig. 3.17), to above the level of the round spermatids.

Stage II

Types A and B spermatogonia and pachytene spermatocytes were similar to those of stage I. A distinct acrosomal granule and/or vesicle was seen in the cytoplasm of round spermatids adjacent to the Golgi or indenting the spermatid nucleus. The acrosomal vesicle appeared rounded and the granule was centrally located within the vesicle (Fig. 3.18). Elongate spermatids were variable in their location.

Stage III

Types A and B spermatogonia and preleptotene spermatocytes occupied the basal epithelium and mitotic figures were occasionally seen. Adluminally there were pachytene spermatocytes. The portion of the nuclear envelope of round spermatids in contact with the acrosome had resumed a hemispherical shape, the acrosomal vesicle had collapsed over the nucleus and the angle subtended by the spread of the acrosome was less than 70° (Fig. 3.19). Elongate spermatids were generally located luminal to the round spermatids, but a few were still in deep crypts of Sertoli cells.

Stage IV

Type A spermatogonia were present. Most early spermatocytes were in transition between preleptotene and leptotene. Their nuclei had thread-like chromatin indicative of leptotene,

Figure 3.13 Cycle Map, Hopping Mouse

Map of the cycle of the seminiferous epithelium of the hopping mouse, *Notomys alexis* showing phases of germ cell development. The vertical columns, designated by Roman numerals, depict the cellular associations, each of which represents a stage of the cycle. The equivalent cycle stages in the laboratory rat (as per Russell *et al.*, 1990a) are given in brackets. One cycle corresponds to a complete series of the eight cellular associations. The developmental progression of a cell is followed horizontally until the right hand border of the cycle map is reached. The cell progression then continues at the left hand side of the cycle map one row up. The cycle map ends with the release of spermatids from the seminiferous epithelium, ie. spermiation. By convention, the cellular association at the left hand side of the cycle map (stage I) depicts the newly formed round spermatids (following division of secondary spermatocytes) that have not yet developed an acrosome.

The symbols used designate specific phases of germ cell development as follows:

- A type A spermatogonium
- A_m mitosis of type A spermatogonia
- A_mIn mitosis of type A spermatogonia giving rise to intermediate spermatogonia
- In_m mitosis of intermediate spermatogonia
- B type B spermatogonium
- B_m mitosis of type B spermatogonia
- Pl preleptotene primary spermatocyte
- L leptotene primary spermatocyte
- Z zygotene primary spermatocyte
- P pachytene primary spermatocyte
- Di diplotene primary spermatocyte
- _m2°_m meiotic divisions of diplotene primary spermatocytes and secondary spermatocytes, giving rise to early round spermatids
- 1-12 developmental steps of spermatids during spermiogenesis

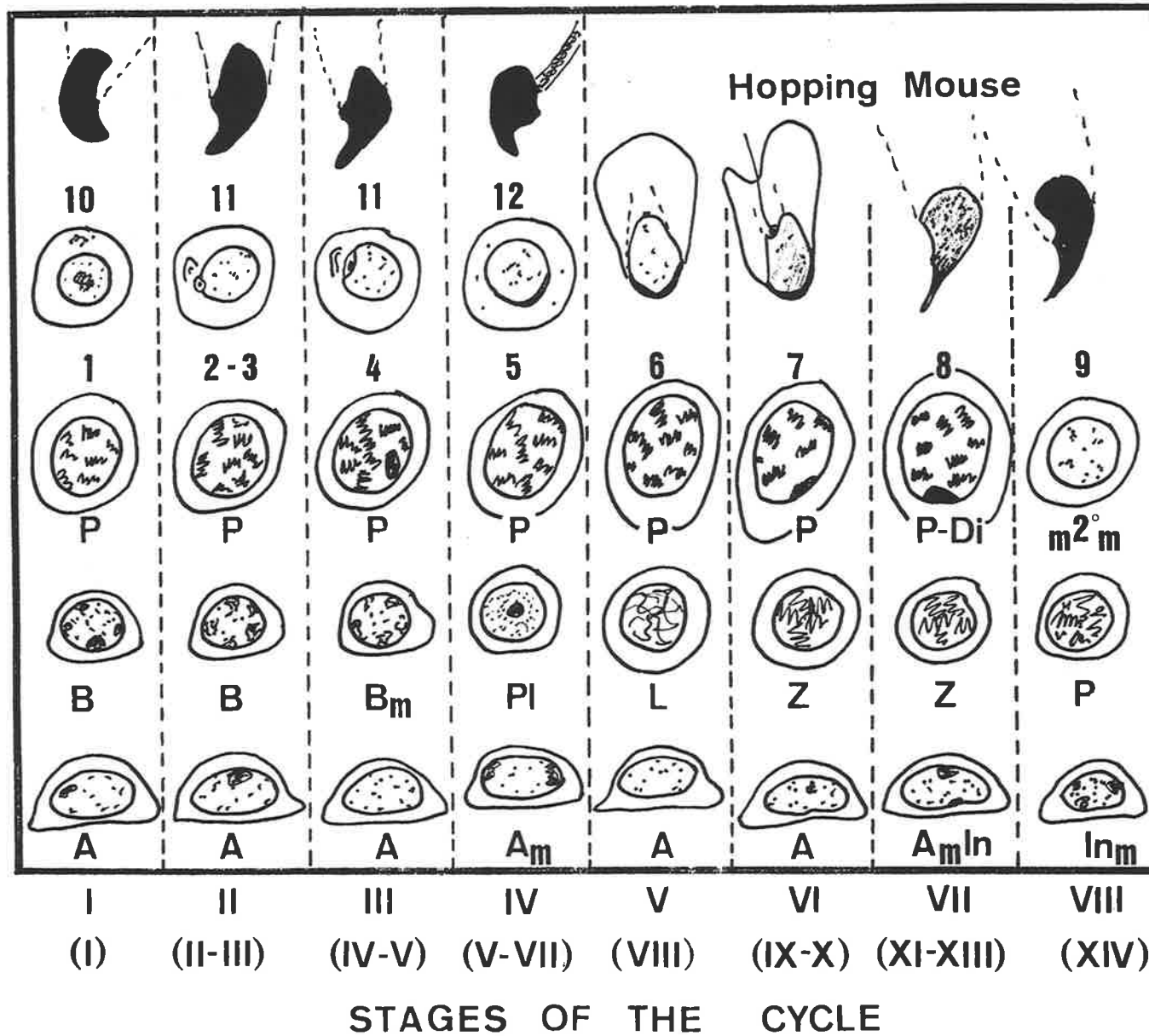


Plate 4 Hopping Mouse Seminiferous Tubules.

Illustration of the occurrence of more than one cellular association (stage of the cycle of the seminiferous epithelium) in the same tubular cross section.

Figure 3.14

Stages V and VI are present in the same cross section. In the portion of the tubule marked V the nuclei of the spermatids are round, whereas in the portion marked VI there is considerable variability in nuclear shape of the spermatid population.

bar = 25 μm

Figure 3.15

Tubular cross section showing cellular associations at stages V, VI and VII of the cycle of the seminiferous epithelium. Note that consecutive cycle stages are not necessarily adjacent to each other within the cross section. An area of epithelium at stage V of the spermatogenic cycle is interposed between two areas at stage VII. This might indicate that there is a spiral, rather than a segmental arrangement of cellular associations along the length of a seminiferous tubule in the hopping mouse.

bar = 25 μm

Figure 3.16

Tubular cross section showing two non-consecutive cellular associations, stages IV and VI of the cycle of the seminiferous epithelium. The acrosomal poles of the round spermatid nuclei in the region marked IV are not in contact with the plasmalemmae of the cells. The elongate spermatid population, however, is no longer present within the epithelium. This situation might reflect a slight lag in the timing of development of the round spermatids in the area marked IV, relative to other cell types within the association and relative to the spermatids in the area marked VI.

bar = 25 μm

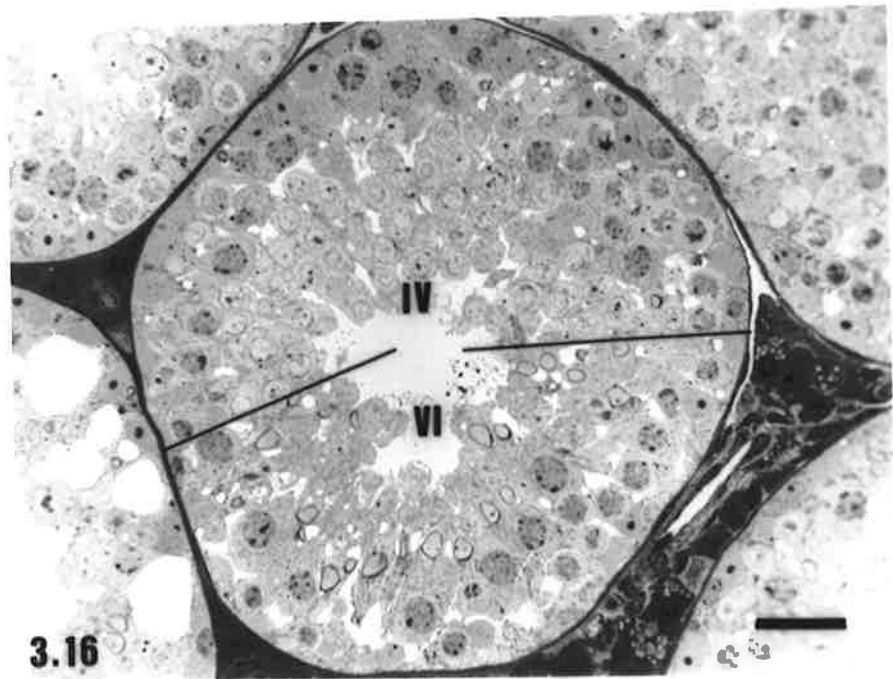
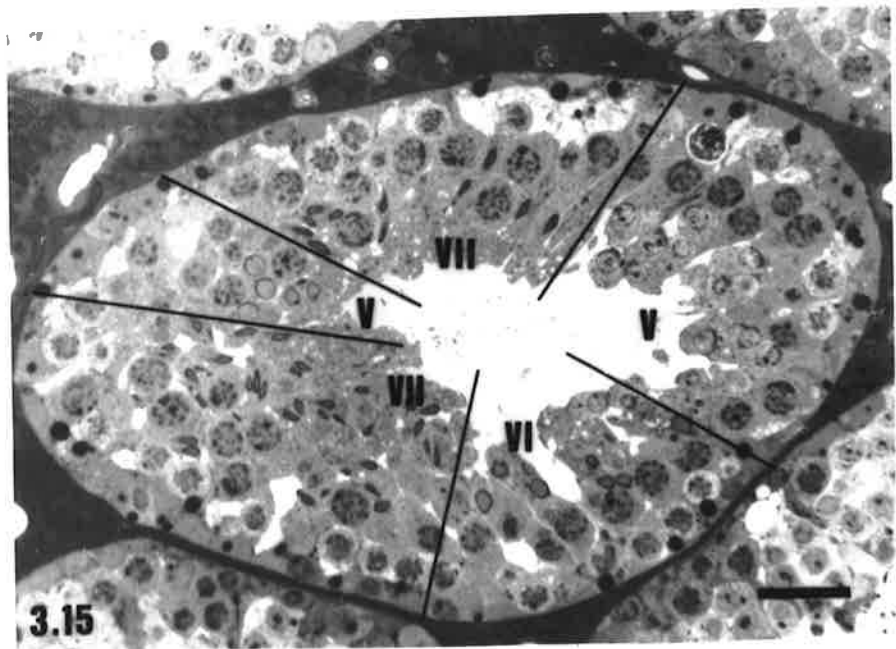
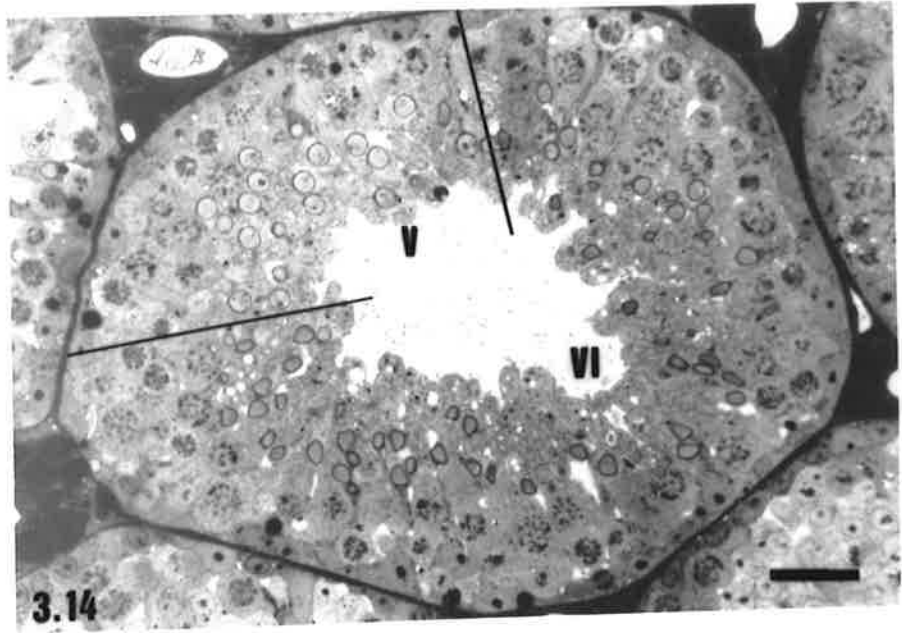


Plate 5 Cellular Associations of Hopping Mouse Seminiferous Tubules.
Stages I - IV

Figure 3.17

The presence of round spermatids with no discernible acrosomal constituents identifies the cellular association as being **Stage I** of the cycle of the seminiferous epithelium. B = Type B spermatogonia, P = pachytene primary spermatocytes, R = round and E = elongate spermatids.

bar = 10 μm

Figure 3.18

The presence of an acrosomal granule in contact with the spermatid nucleus (arrow) identifies **Stage II** of the cycle of the seminiferous epithelium. Se = Sertoli cell nucleus, B = type B spermatogonium, P = pachytene primary spermatocyte, E = elongate spermatids.

bar = 10 μm

Figure 3.19

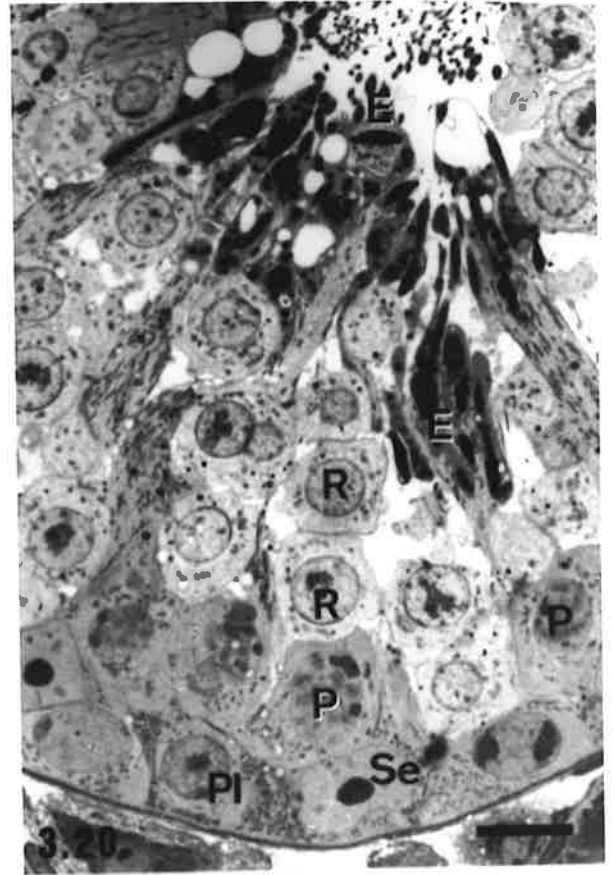
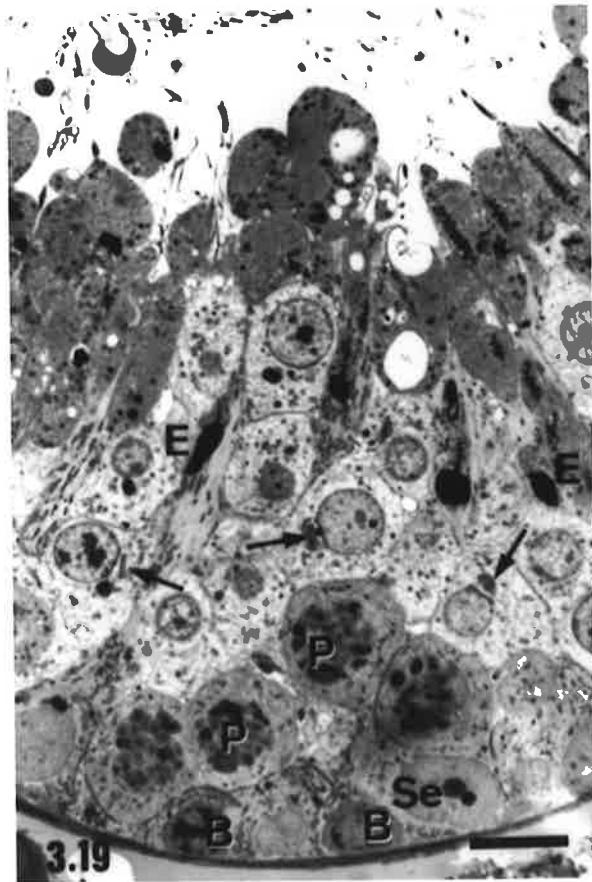
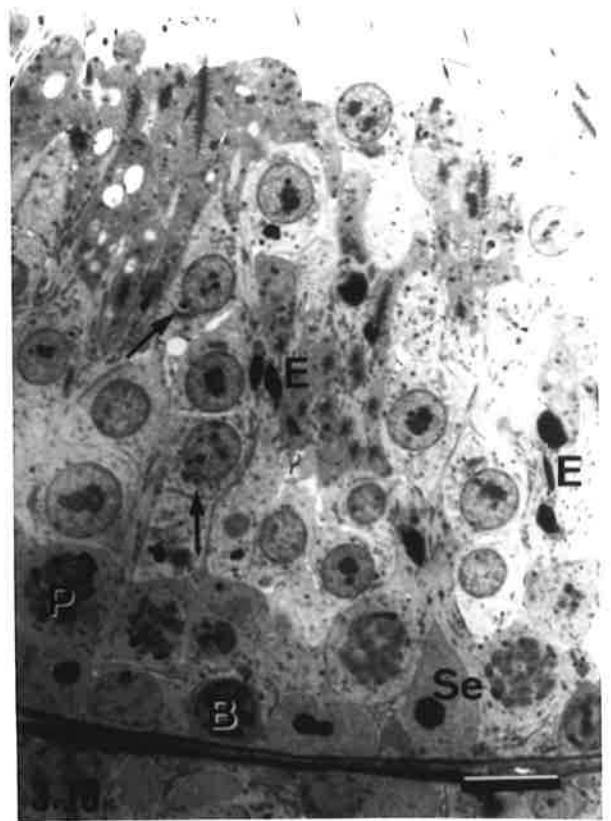
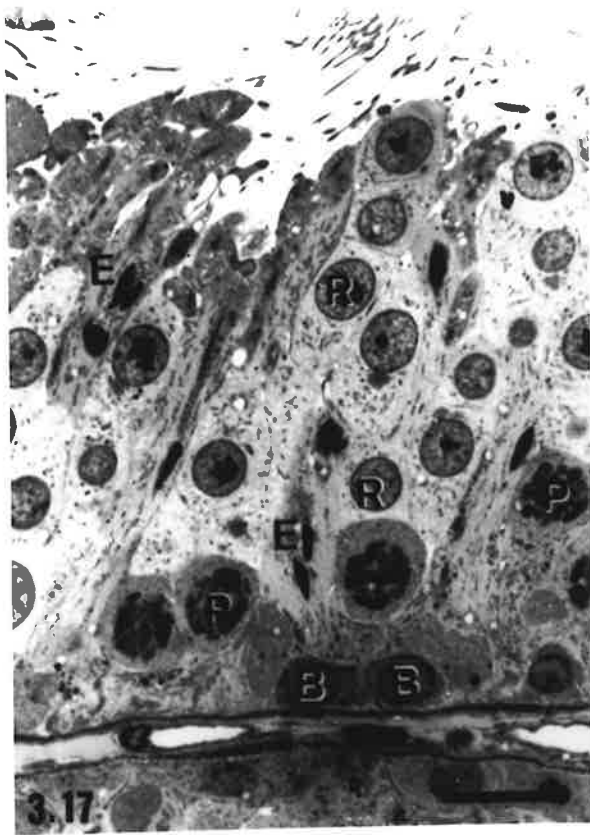
Stage III is identified by flattening of the acrosomal vesicle on the nucleus of the round spermatids (arrows). Se = Sertoli cell nucleus, B = type B spermatogonia, P = pachytene primary spermatocytes, E = elongate spermatids.

bar = 10 μm

Figure 3.20

Stage IV. The spread of the acrosome over the nucleus of the round spermatids (R) exceeds 70° but the acrosomal pole of the nucleus has not made contact with the plasmalemma. Depicted are a Sertoli cell nucleus (Se), an early primary spermatocyte nucleus in the transition phase from preleptotene to leptotene (Pl), pachytene primary spermatocytes (P) and elongate spermatids (E) above the level of the other germ cell types, prior to their release from the epithelium.

bar = 10 μm



but nucleoli were still obvious. Some of these cells had moved away from the tubular basal lamina. Typical leptotene spermatocytes were present in a few cross sections at this cycle stage. Pachytene spermatocytes were larger than in earlier stages of the cycle. Spread of the acrosome over the nucleus in round spermatids had exceeded 70°. Spermatid nuclei were eccentrically located within the cytoplasm, with their acrosomal pole close to, but not in contact with the plasmalemma. Elongate spermatids either lined the tubular lumen (Fig. 3.20), or had been released from the epithelium. Spermiation appeared to occur near the end of this stage; because tubules containing leptotene spermatocytes rarely contained elongate spermatids.

Stage V

Type A spermatogonia, leptotene and pachytene spermatocytes were present. Mitotic figures of spermatogonia were occasionally seen. The acrosomal membrane of round spermatids was in contact with the plasmalemma and slight elongation of the nucleus had occurred, but neither gross distortion of nuclear shape, nor caudal tapering, was evident (Fig. 3.21). The manchette was visible within the spermatid cytoplasm. Occasionally, release of the elongate spermatid population had not been completed by stage V and a few elongate spermatids lined the tubular lumen in some sections. More commonly, cytoplasmic bodies of released spermatids were present along the adluminal epithelial surface.

Stage VI

Type A spermatogonia, zygotene and pachytene spermatocytes were observed. Spermatid nuclei were bilaterally flattened and tapered towards the caudal nuclear pole; sectional profiles of the nucleus varied widely between cells, but the ratio of the apico-caudal dimension of the nucleus to its width was less than two (Fig. 3.22).

Stage VII

Types A and intermediate spermatogonia, zygotene, pachytene and diplotene spermatocytes were present. The heads of spermatids were highly variable in shape; the length of their nuclei was greater than twice the width when sectioned in the caudo-apical plane. Nuclear condensation was also highly variable, but the nuclei tended to be more intensely stained than those in the previous stage (Fig. 3.23).

Stage VIII

Stage VIII was characterised by the presence of meiotic figures of meiosis I and II and/or by secondary spermatocytes (Fig. 2.24); diplotene spermatocytes and early round spermatids were normally seen in conjunction with them. Types A and intermediate spermatogonia and pachytene spermatocytes occupied the basal third of the epithelium and

elongate spermatids were located adluminally. The latter cells displayed varying degrees of condensation of their nuclear chromatin; most nuclei were intensely stained but a few had pale staining indicative of spermatids of earlier cycle stages.

3.3.3.3 Non-conforming Cellular Associations in the Hopping Mouse

In most hopping mouse testes, areas of seminiferous epithelium were observed where the composition of the cellular association did not correspond to any of the eight cycle stages described above. Most of these areas of the seminiferous epithelium fell into one of four categories:

- a) The younger generations of germ cells (spermatogonia and spermatocytes) were in developmental phase with each other, but their degree of development was either behind or ahead of that typical of the cycle stage suggested by the appearance of the younger spermatid population. For example, primary spermatocytes at the preleptotene/leptotene transition phase of development (indicative of early stage IV) were sometimes seen in association with other germ cell generations typical of late stage V to early stage VI of the cycle of the seminiferous epithelium (Fig. 3.25).
- b) The spermatid population displayed heterogeneous development. A range of spermatid morphologies, spanning several spermiogenic steps and indicative of consecutive stages of the spermatogenic cycle, was evident within a small area of the epithelium (Fig. 3.26).
- c) An entire generation of germ cells was absent from the cellular association (Figs 3.27, 3.28).
- d) Spermatids displayed characteristics that were inconsistent with those normally seen within the cellular association. These characteristics included increased cell and nuclear size (Fig.3.29) and unusual shapes of the acrosome, with two nuclei sometimes sharing a single acrosome (Fig.3.30).

In addition to the above categories, occasional tubular cross sections were observed in which the epithelial architecture was grossly distorted from that typical of the majority of the epithelium. The height of the epithelium in these cross sections was often reduced, fewer germ cells and greater numbers of degenerating cells were evident and large, multinucleated germ cells were sometimes featured. The majority of surrounding tubular cross sections, however, usually displayed normal morphology and all cellular associations were observed within the testes.

Plate 6 Cellular Associations of Hopping Mouse Seminiferous Tubules.

Stages V - VIII

Figure 3.21

In **Stage V**, the nuclei of the spermatid generation are in contact with the plasmalemmae of the cells. The elongate spermatid generation have been released from the epithelium. m = mitosis of a spermatogonium, L = leptotene primary spermatocyte, P = pachytene primary spermatocyte.

bar = 10 μ m

Figure 3.22

Stage VI. Nuclei of the spermatids are flattened and taper caudally (arrows). Some condensation of the nuclear chromatin has occurred. A = type A spermatogonium, Z = zygotene primary spermatocyte, P = pachytene primary spermatocyte.

bar = 10 μ m

Figure 3.23

Stage VII. The nuclei of the spermatid population have elongated and their nuclei stain intensely, indicative of nuclear condensation. A = type A spermatogonium, Z = zygotene primary spermatocyte, D = diplotene primary spermatocyte, E = elongate spermatid.

bar = 10 μ m

Figure 3.24

The presence of meiotic figures of primary spermatocytes (m) and a secondary spermatocyte (2°), signifies **Stage VIII**. Se = Sertoli cell nuclei, In = intermediate spermatogonium, P = pachytene primary spermatocyte.

bar = 10 μ m

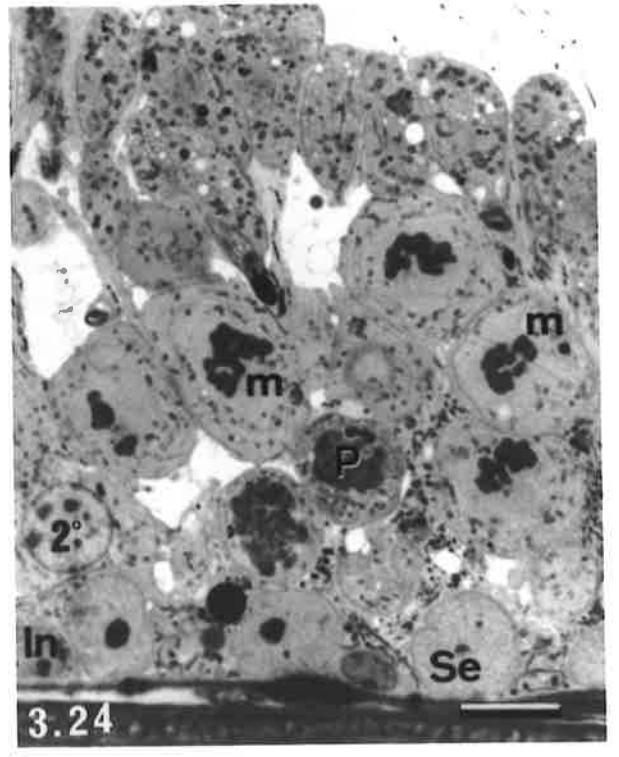
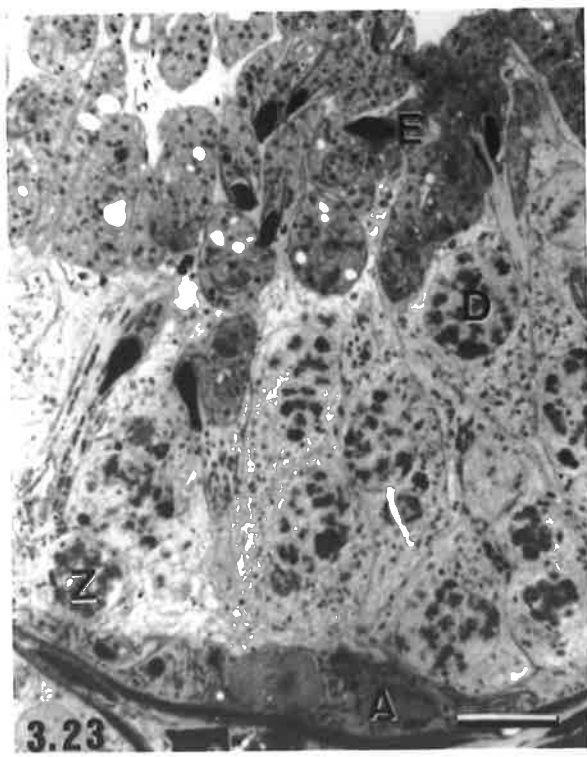
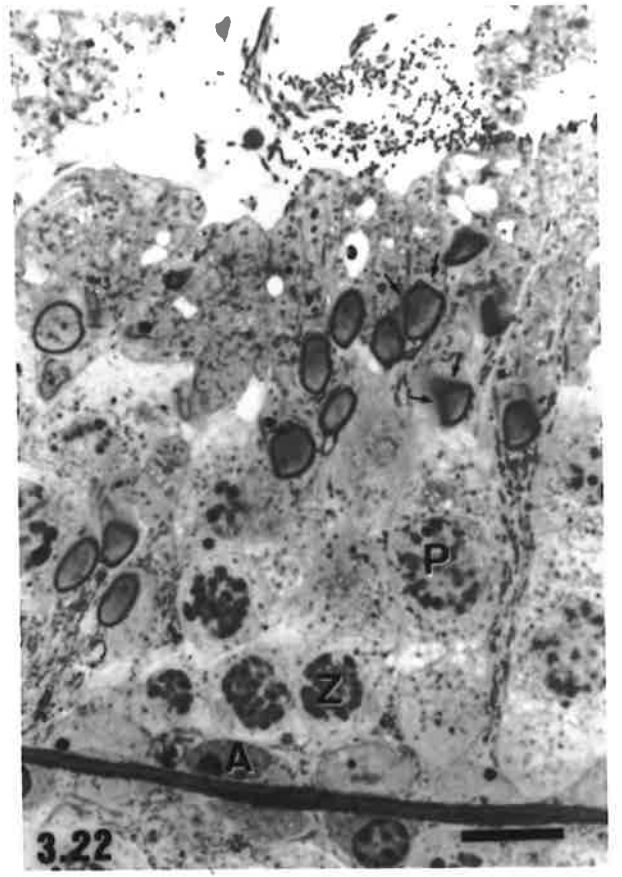
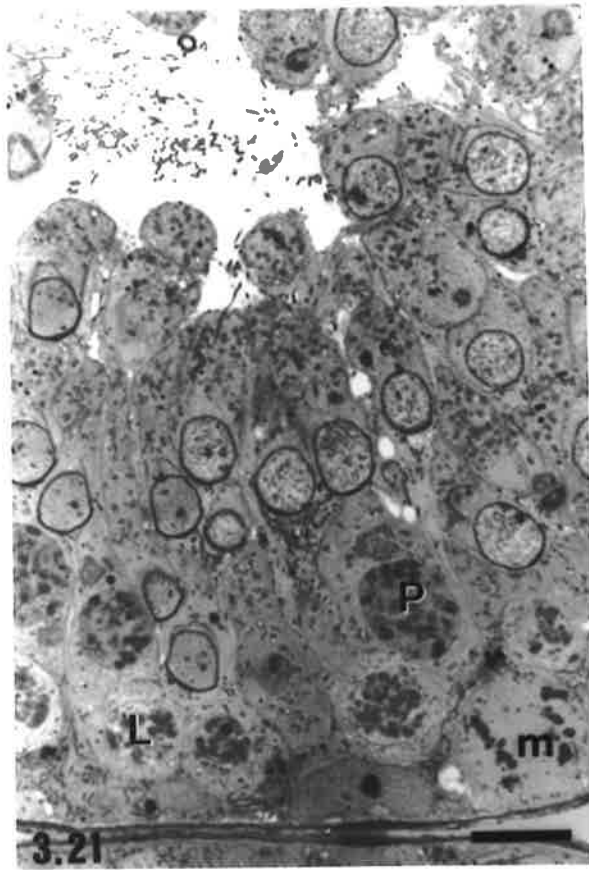


Plate 7 Non-conforming Cellular Associations in the Hopping Mouse.

Figure 3.25

Atypical cellular association in which development of the younger generation of primary spermatocytes is not in synchrony with that of the spermatid population. The younger spermatocyte population (arrowheads) is at the preleptotene/leptotene transition stage, usually seen during early stage IV of the cycle of the seminiferous epithelium, whereas the acrosomal pole of the nucleus of the round spermatids is in contact with the plasmalemma (indicated by arrows) and nuclear shape is slightly distorted, indicative of late stage V to early stage VI of the cycle.

bar = 10 μm

Figure 3.26

Heterogeneous development of the round spermatid population within a confined area of the seminiferous epithelium. Individual round spermatids show acrosomal development equivalent to stages II, III and IV of the cycle of the seminiferous epithelium respectively.

1 = acrosomal development typical of stage II round spermatids.

2 = acrosomal development typical of stage III round spermatids.

3 = acrosomal development typical of stage IV round spermatids.

Features of the other cell populations, including the position of the elongate spermatids, are indicative of late stage III - stage IV.

bar = 10 μm

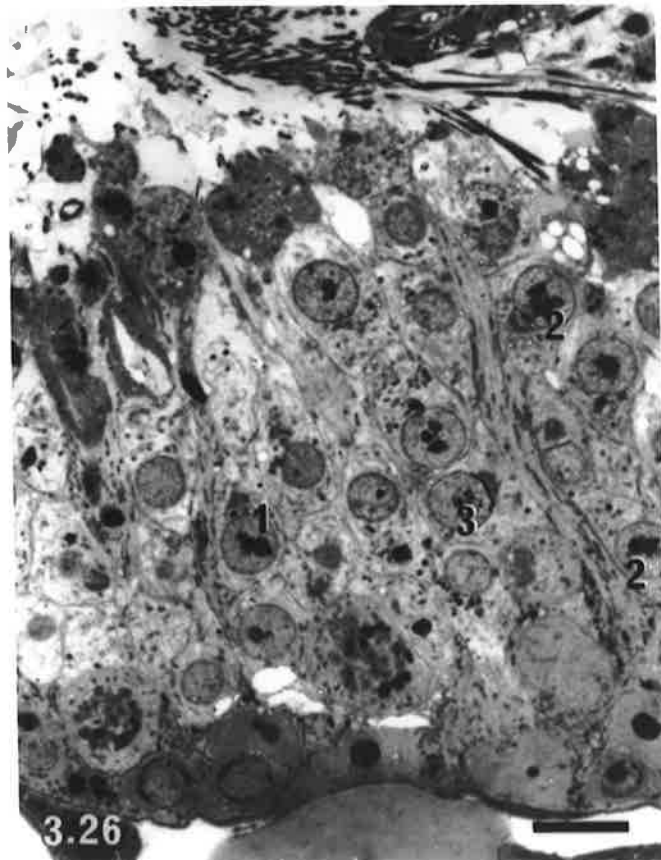
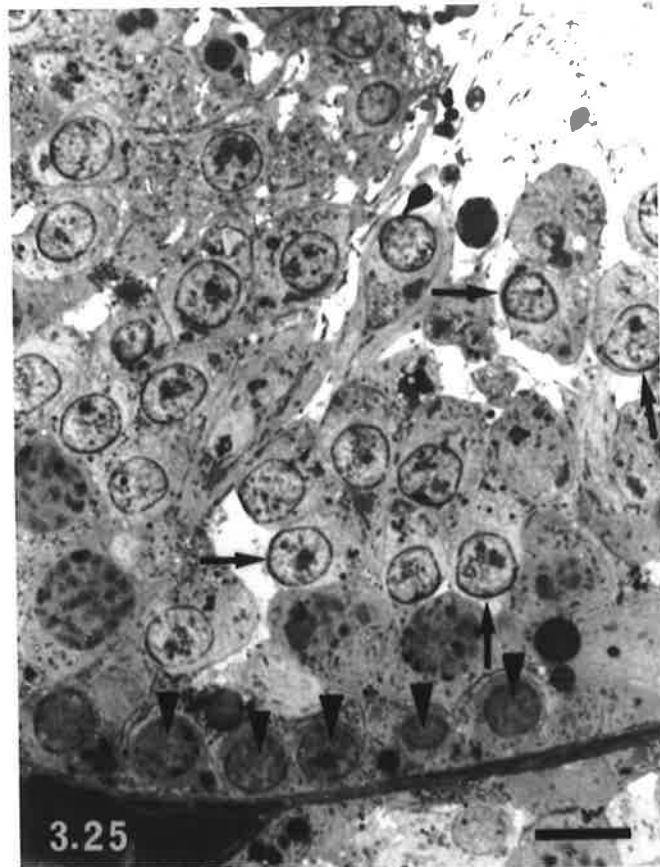


Plate 8 Non-conforming Cellular Associations in the Hopping Mouse.

Figures 3.27-3.28 Cellular associations in which one entire generation of germ cells is absent from the epithelium.

Figure 3.27

Stage I tubule cross section in which the pachytene primary spermatocyte generation is absent. (Compare to Fig. 3.17).

bar = 10 μm

Figure 3.28

Stage VII tubule cross section in which the diplotene primary spermatocyte generation is absent. (Compare to Fig. 3.23).

bar = 10 μm

Figures 3.29-3.30 Cellular associations displaying anomalous development of spermatids.

Figure 3.29

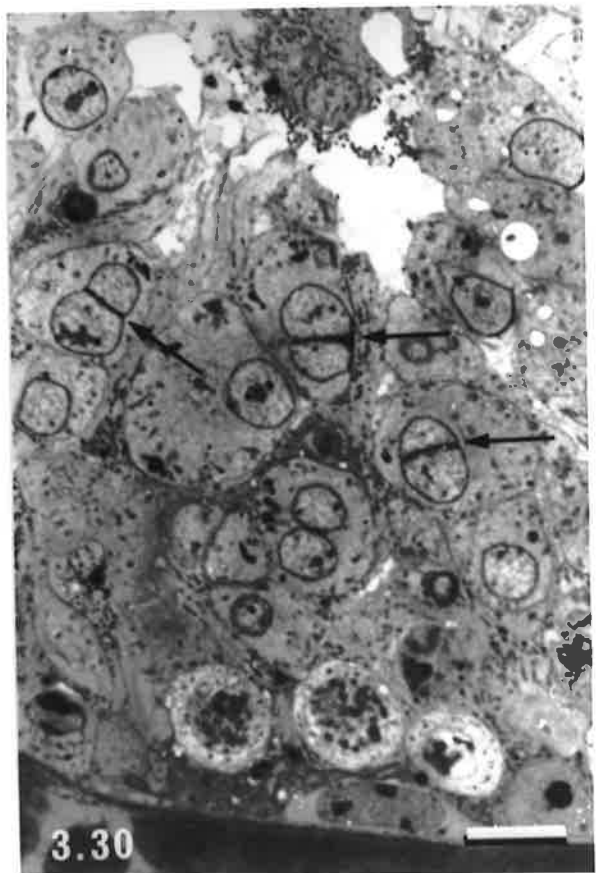
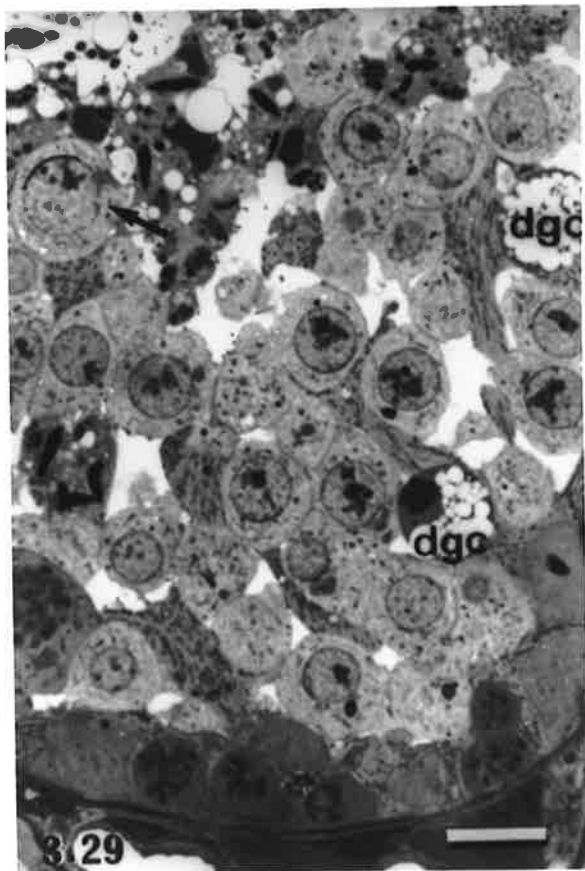
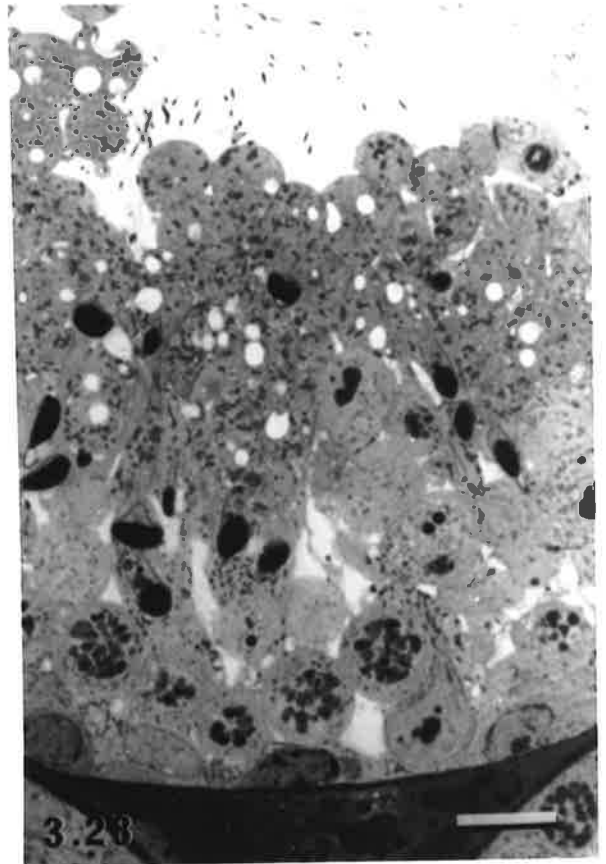
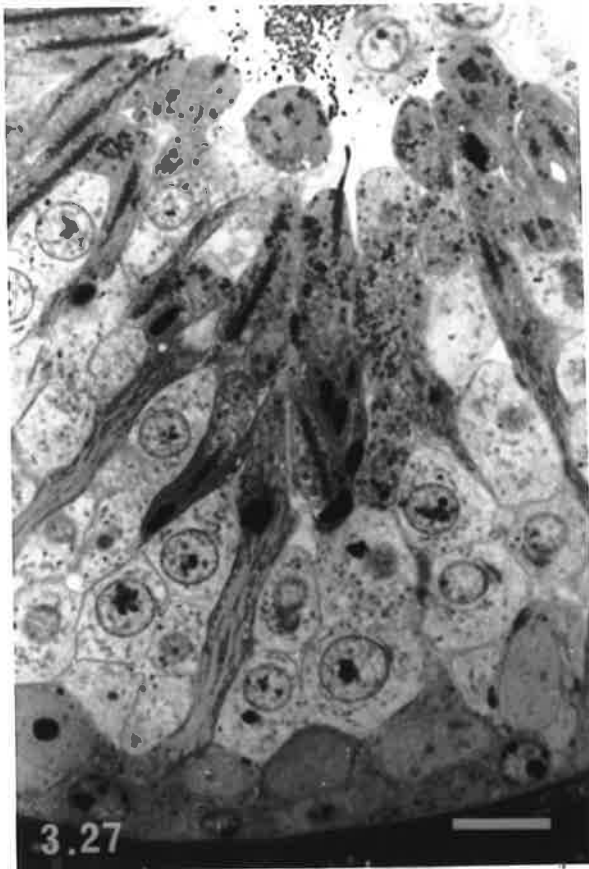
A round spermatid with an abnormally large nucleus (arrow) is present. Note also the presence of several degenerating germ cells (dgc).

bar = 10 μm

Figure 3.30

An area of the seminiferous epithelium containing binucleate spermatids. The two nuclei share a single acrosome (arrows).

bar = 10 μm



3.4 Discussion

3.4.1 Comparisons with Laboratory Rodent Species

Plains Rat

In the majority of species of rodent including the laboratory rat (Leblond and Clermont, 1952a; Russell *et al.*, 1990a), laboratory mouse (Oakberg, 1956a,b; Russell *et al.*, 1990a), golden hamster (Clermont, 1954; Miething, 1998), guinea pig (Clermont, 1960), Indian gerbil field rat, *Tatera indica* (Bilaspuri and Kaur, 1994) and viscacha, *Lagostomus maximus* (Munoz *et al.*, 1998) the seminiferous epithelium is organised into discrete cellular associations of fixed composition that occupy relatively large segments of a tubule. The present study confirmed that the organisation of the seminiferous epithelium in the plains rat conforms to this general plan. Using criteria based on the appearance of the spermatid population, ie. the steps in spermiogenesis, 11 cellular associations were recognised in this species, compared to 14 described for the laboratory rat (Leblond and Clermont, 1952a; Russell *et al.*, 1990a) and 12 for the laboratory mouse (Oakberg, 1956a,b; Russell *et al.*, 1990a). Differences between these three species in the number of cellular associations is largely due to interspecific variation in the events leading to the final shape of the spermatid head. For example, Russell *et al.* (1990a) defined the boundary between stages IV and V of the spermatogenic cycle in the laboratory rat and laboratory mouse as the point at which the angle subtended by the flattened acrosomal vesicle over the nucleus of round spermatids was 40°. This same demarcation point could not be applied to plains rat round spermatids since spread of the acrosome over a convex nucleus was never less than 60°. This may indicate that in plains rat spermatids, the acrosomal vesicle flattens and spreads over the nucleus more rapidly than that in the laboratory rat or laboratory mouse.

The degree of ease with which particular spermatid features could be identified in sections may also have limited the number of recognisable cellular associations. With thin (0.5-1 μm) plastic sections investigators do not have the benefit of three dimensionality provided by thicker (5-7 μm) paraffin embedded sections when identifying particular cellular features. In the plains rat it was not possible to differentiate between late spermatid steps on the basis of variation in curvature of their dorsal surfaces, as was used in the laboratory rat (Leblond and Clermont, 1952a; Russell *et al.*, 1990a). Likewise, proacrosomal granules could not be consistently detected, due to the reduced likelihood of them being included in the individual thin plastic sections. Hence, for several criteria, where two cellular associations were recognised in the seminiferous tubules of the laboratory rat, only

one could be identified in the plains rat. For example, stage VIII in the plains rat corresponds to stages X and XI in the laboratory rat (see Table 3.1).

Regardless of the staging criteria used, subtle differences in the composition of cellular associations were evident between the laboratory rat, laboratory mouse and plains rat, which are likely to reflect interspecific differences in the timing of spermatogenic events. Such timing differences are not surprising since the length of the spermatogenic cycle varies between species, ranging from 7.2 days in the prairie vole (Schuler and Gier, 1976) to 16 days in the human (Heller and Clermont, 1963) and around 17 days in the Chinese hamster (Oud and de Rooij, 1977) and several species of marsupial, including Bennett's wallaby, *Macropus rufogriseus* (Setchell and Carrick, 1973) and the white-belly opossum, *Didelphis alviventris* (Queiroz and Nogueira, 1992). Interspecific differences in composition of cellular associations included the locations where spermatogonia in mitotic divisions were observed. In the plains rat, mitotic divisions giving rise to intermediate spermatogonia occurred in the same association as in the laboratory mouse (stage II), whereas in the laboratory rat they occurred slightly earlier in the cycle, corresponding to the cellular association in which no acrosomal elements could be seen in the cytoplasm of the round spermatids (stage I). Release of elongated spermatids into the tubular lumen occurred in a cellular association of similar composition in all of the three species.

Whereas the use of thin plastic sections of the seminiferous epithelium in this study has resulted in greater resolution of cellular detail, it has also highlighted the occurrence of intermixing of cell types peculiar to two different cellular associations at the boundaries between them. Cells with features in transition from one cellular association to the next, indicative of the continuous nature of spermatogenesis, were also observed. Using plastic embedded tissues, Hess (1990) reported an incidence of >20% transitions between some cellular associations in the laboratory rat seminiferous epithelium. Hence small deviations in the cellular composition of associations from their typical appearances are probably a normal manifestation of spermatogenesis in all species.

Hopping Mouse

Since the plains rat and hopping mouse are more closely related to each other than either is to either the laboratory rat or laboratory mouse, it might be expected that their seminiferous epithelial organisation would be similar. The plains rat and hopping mouse share a reciprocal translocation between chromosomes 1 and 2 (Baverstock *et al.*, 1983) which, presumably, occurred in a common ancestor of the two species subsequent to their ancestor's divergence from the Murinae, to which the laboratory rat and laboratory mouse belong. Observations from the present study, however, indicate that, whereas the

plains rat has many features in common with the laboratory rodent species, the hopping mouse shares few similarities with any of these species, as far as organisation of the seminiferous epithelium is concerned. Anomalies of the seminiferous epithelium in the hopping mouse include both the composition of individual cellular associations and their arrangement within the seminiferous tubules.

The arrangement of cellular associations in the hopping mouse was such that up to 17.3% of tubular cross sections in some individuals contained more than one association (see Table 4.3, Chapter 4 of this thesis). Such an occurrence implies that each association occupies a smaller area of epithelium, which in turn may indicate that the factors responsible for coordinating spermatogenic development in a particular area of epithelium are capable of exerting their effects over short distances only. Alternatively, in the hopping mouse, fewer spermatogonial divisions may occur and/or greater numbers of spermatogonia may not survive to enter into meiotic prophase. Hence resultant generations of spermatocytes and spermatids are considerably smaller in size than those of the other rodent species investigated so far and in turn, occupy smaller regions of the seminiferous epithelium. A lower observed incidence of spermatogonial mitoses and a higher observed incidence of degenerating cells in sections of hopping mouse tubules, lend support to this theory.

The composition of individual cellular associations of the hopping mouse varied in a number of ways. Sometimes one generation of germ cells was out of phase with the other generations of a particular cellular association, with the appearance of these cells typically being that of the preceding, or subsequent, stage of the cycle. Occasionally an entire cell generation appeared to be missing from an association, which may either reflect a lack of spermatogonial divisions during a particular cycle, or be a consequence of the death of an entire cell lineage, or the bulk of the cells within it, such that no cells of a particular type are encountered within a thin section of tissue. Adjacent spermatids often displayed vast differences in the amount of shaping and elongation of the head region and the degree of nuclear condensation (the range of variation observed was typical of that seen over three consecutive cellular associations in the laboratory rat). The occurrence of spermatids deep within the seminiferous epithelium in the same quadrant of a tubular cross section as those about to be released into the tubular lumen was also commonly observed.

The above observations point to the likelihood that developmental events of spermatogenesis in the hopping mouse may not be as tightly synchronised as in other rodent species. Less well defined cellular associations may simply reflect a looser synchrony of development of adjacent germ cell generations, with perhaps the only cells having a coordinated rate of development being those that are derived from the same stem

spermatogonium, ie. clonal groups linked by cytoplasmic bridges. Spatial regulation of the tubular environment and hence spermatogenesis, may also be more localised in the hopping mouse than in other species. Whatever the cause, such a huge range of variation within an association in, for example, in spermatid head shape, is real and not merely a consequence of the cells being sectioned in different planes. The occurrence of hopping mouse epididymal sperm displaying four or five different morphologies in significant numbers and many more morphologies with less frequency (Breed and Sarafis, 1983; Suttle *et al.*, 1988), supports this latter point.

Mixing of cellular associations at their boundaries was also evident in the hopping mouse testis. Whether this occurs with greater frequency in this species than in others such as the laboratory rat (Hess, 1990) is difficult to judge quantitatively. It may be that this feature is simply more obvious in the hopping mouse because individual associations occupy smaller areas of the seminiferous epithelium, hence more boundaries exist where there is mixing and are likely to be sampled during sectioning.

3.4.2 Comparisons with Primates

Both the anomalies in the composition of cellular associations and the smaller areas occupied by an individual cellular association in the hopping mouse are reminiscent of male germ cell organisation in the seminiferous tubules of the human (Clermont, 1963; Schulze and Rehder, 1984, Schulze *et al.*, 1986) and baboon (Chowdhury and Steinberger, 1976; Chowdhury and Marshall, 1980). In these species, upwards of 50% of tubular cross sections show two or more cellular associations. Why the appearance of the seminiferous epithelium in these species and to a lesser extent in the hopping mouse, is less organised than that of most other mammalian species, despite spermatogenesis being similar, remains to be satisfactorily explained. Schulze and Rehder (1984) reported that despite its seemingly irregular appearance, the seminiferous epithelium in humans has a complex, ordered, organisation of germ cells which is based on the geometry of spirals. In fact they believe that this arrangement of germ cells can explain epithelial organisation in all species and that the actual seminiferous epithelial organisation observed in a species arises as a consequence of the size of its cellular cohorts. Large cellular cohorts within a cellular association occupy large areas of seminiferous epithelium such as entire tubular cross section, or a distinct length of tubule. Hence a typical cellular association model fits with an underlying spiral arrangement of germ cells.

It is suggested that the occurrence of 'inappropriate' germ cells, ie. cells out of synchrony in their development with the other germ cell generations, within a cellular association may result from the asynchronous division of spermatogonia within a small region of the

seminiferous epithelium. The asynchronous division of morphologically similar spermatogonia has been shown in humans (Chowdhury and Steinberger, 1977) and is speculated to occur in baboons (Chowdhury and Marshall, 1980). If subsequent cellular development occurs normally, then small differences in timing of cell divisions would result in increased variability in the cell types present in at least some cellular associations.

3.4.3 How is Synchronous Germ Cell Development Achieved?

The mechanisms underlying the relative synchrony (or in the case of the hopping mouse, lack of it) exhibited by different cell types of a cellular association could not be elucidated in the present study. Several hypotheses for the control of synchronous development within cellular associations have been proposed, but remain to be comprehensively tested. They include:

- a) Sertoli cells regulate the timing of germ cell development. Numerous studies have shown that there is a close association between the plasma membranes of germ and Sertoli cells, including the occurrence of specialised junctional complexes (Fawcett, 1975a; Russell, 1977b, 1979a). Furthermore, the appearance and function of Sertoli cells vary over the spermatogenic cycle similar to that of germ cells (Elftman, 1950; Parvinen, 1993; Russell, 1993), although the causal relationship between the two cycles is not known.
- b) The synchronous development of an older generation of germ cells may have a cascade effect on what is occurring within a younger generation (Russell *et al.*, 1990a). It has been speculated that such a phenomenon could explain the movement of the more mature germ cells towards the tubular lumen (Russell, 1977a). However, mutual interactions between different generations of germ cells as a means of maintaining their relative synchronisation does not appear to occur. Experimental investigations have shown that the pattern of coordination of the remaining germ cell populations within a cellular association remains following elimination of a single generation by heat (Chowdhury and Steinberger, 1964), irradiation (Dym and Clermont, 1970) or the administration of toxic chemicals (Bartlett *et al.*, 1988).
- c) Periodic stimuli may simultaneously activate different developmental events in populations of cells in a particular locality (Russell *et al.*, 1990a), although the nature of these stimuli and how they act remain to be elucidated.

Recently, transplantation of stem spermatogonia of one species into the testes of another has been used to examine which cell population(s) within the seminiferous tubules, - germ cells or Sertoli cells, determines the organisational pattern of the epithelium and the rate at which germ cell development proceeds during spermatogenesis (França *et al.*, 1998). It was found that spermatogonia of the laboratory rat transplanted into the testis of a

laboratory mouse interacted with mouse Sertoli cells (Russell and Brinster, 1996) and populated the seminiferous epithelium in a manner characteristic of laboratory rat spermatogenesis, in terms of both the epithelial organisation and the timing of cell cycle events (França *et al.*, 1998). The most advanced labelled rat germ cells within the testes of experimental animals 12.9-13 days following ^3H -thymidine administration were pachytene spermatocytes at stage VI-VIII of the spermatogenic cycle, whereas the most advanced labelled mouse germ cells in the same testes were spermatocytes in meiotic division or young spermatids. These results therefore indicate that the germ cell genotype and not that of the Sertoli cell, is the dominant factor in controlling the structural organisation of the seminiferous epithelium and in regulating events within the spermatogenic cycle.

2.5 Summary

This study confirms and extends previous findings (Peirce and Breed, 1987) that organisation of the seminiferous epithelium in the plains rat is typical of the general pattern documented for laboratory rodents. Well-defined cellular associations of stable composition were present and occupied relatively long segments of longitudinally sectioned seminiferous tubules. Tubular cross sections displayed a single cellular association. Several subtle variations in the composition of cellular associations between the plains rat and laboratory rodent species were observed, which may relate to small differences in the timing of spermatogonial divisions and the life spans of individual cell types between species.

By contrast, organisation of the seminiferous epithelium in the hopping mouse was clearly more variable than that of both the plains rat and common laboratory rodent species. Fewer cellular associations could be identified, their composition was more variable, some regions of the seminiferous epithelium could not be assigned to an association with any degree of certainty and individual associations occupied smaller areas of the epithelium.

Chapter 4 Frequency of Cycle Stages

4.1 Introduction

In Chapter 3 it was established that the seminiferous epithelium of plains rat and hopping mouse testes is organised into a number of distinct cellular associations (11 and eight respectively), each of which represents a stage of the cycle of the seminiferous epithelium. These cycle stages are observed with varying frequency and for mammals, it has been shown that the frequency of each cycle stage is constant between sections within the same testis and even the same species (Hochereau, 1963). Frequency data, therefore, can be used to estimate the relative duration of each particular cycle stage, since the abundance of any particular cellular association in sections will be directly related to its relative length, provided that the tissue examined is representative of the entire testis and the sample size is sufficiently large to exclude sampling bias (Clermont and Trott, 1969). Hess *et al.*, (1990) concluded that, in the laboratory rat, analysis of a minimum of 200 tubule cross sections per testis is necessary to give an accurate estimation of individual stage frequencies.

The frequency of individual stages of the cycle of the seminiferous epithelium differs between species of mammals, but is reported to be constant between individuals within the same species or strain (Hochereau, 1963; Courot *et al.* 1970; Berndtson, 1977). By contrast, in an earlier study of the seminiferous epithelium of the hopping mouse it was found that there was considerable inter-animal variation in the observed frequency of particular cycle stages (Peirce and Breed, 1987). This may have been due to insufficient sampling, since only about 100 tubular cross sections per hopping mouse were examined. Similarly, in the laboratory rat, between-study differences in stage frequency have been reported (Leblond and Clermont, 1952b; Clermont and Harvey, 1965; Chapin *et al.*, 1984; McDonald and Scothorne, 1988; Hess *et al.*, 1990), which may relate in part to variability in the application of criteria used to define the cycle stages, as well as to insufficient numbers of animals, or seminiferous tubule cross sections per testis being sampled. In both of the above situations, however, the possibility exists that stage frequency within a species is not constant and that natural variation in stage frequency does in fact occur between individuals. In fact, Hess *et al.*, (1990) reported significant inter-animal variation in the frequencies of stages I, II, IV, VI, VIII and XIII of the cycle of the seminiferous epithelium in Sprague-Dawley strain rats, that could not be attributed to insufficient sampling or the misidentification of cycle stages.

Unlike the situation in most mammalian species, but similar to that in humans (Clermont, 1963; Schulze and Rehder, 1984; Schulze *et al.*, 1986) and several species of primates (Chowdhury and Steinberger, 1976; Chowdhury and Marshall, 1980), the hopping mouse has been found to have some cross-sectional profiles of the seminiferous tubules with more than one cellular association (see Peirce and Breed, 1987 and Chapter 3 of this thesis).

In this chapter, data on the frequency of each cellular association/cycle stage in cross sectional profiles of plains rat and hopping mouse seminiferous tubules are presented. These data will later be used for calculations of the duration of the cycle of the seminiferous epithelium and spermatogenesis (see Chapter 5). The possibility that natural, biological, variation in the frequency of individual cycle stages occurs within each species is also examined, as is the incidence of cross-sectional profiles of hopping mouse seminiferous tubules that contain two or more cellular associations.

4.2 Materials and Methods

4.2.1 Animals and Tissue Preparation

Testes from 12 plains rats and 18 hopping mice, previously prepared for an investigation of the organisation of the seminiferous epithelium were used. Tissues were processed for light microscopy as described in section 2.2 of Chapter 2 and 1-1.5 μm sections were cut on a Sorval ultramicrotome and stained with toluidine blue in borate buffer.

4.2.2 Frequency of Stages of the Cycle of the Seminiferous Epithelium

Sections of testes were examined under an Olympus BH-2 microscope fitted with planapochromatic objectives, at either 400x or 1000x magnification (N.A. 0.95 or 1.4 respectively). Cellular associations within the testicular seminiferous epithelium were identified using the criteria and guidelines described for each species in Chapter 3 and each cross-sectional profile of a tubule was classified according to the cycle stage(s) present within it. For both plains rats and hopping mice, approximately 200 tubular cross sections per animal, taken from at least 4 testicular locations, were scored, which as indicated above, is the minimum number of tubules recommended by Hess *et al.*, (1990). A total of 2059 tubules were scored for the plains rat and 3157 tubules for the hopping mouse. Obliquely sectioned profiles were scored only if the diameter of the long axis of the tubule was <40% greater than the short axis. Profiles displaying damage resulting from tissue processing were not included in the counts, due to difficulty in stage identification in such cases. In instances where cross sections of hopping mouse seminiferous tubules contained

more than one cycle stage, each stage was assigned a score corresponding to the fraction of the cross-sectional profile occupied by it. The number of cross sections displaying more than one cellular association was also recorded for each animal. Data from four hopping mice were subsequently excluded from analysis due to gross abnormalities of their seminiferous epithelial organisation. These abnormalities, which were present in nearly all of the seminiferous tubule sections from these animals, included a reduced seminiferous epithelial height (<50% of average height), the persistent absence of entire spermatocyte and/or spermatid generations and a high incidence (>5 cells per tubular cross section) of degenerating germ cells or cells with atypical morphology, eg. multinucleated germ cells.

For each animal, the frequency of each cycle stage was determined by dividing the count for that stage by the total number of tubular profiles counted. Mean stage frequency (\pm S.D.) was then determined for each species (plains rat $n = 12$, hopping mouse $n = 14$).

4.2.3 Statistical Analysis of Frequency Data

Statistical analysis was undertaken to determine whether there was constancy among animals within each species in the observed frequencies of particular cellular associations. Initial analysis was based on the assumption that, for any animal, seminiferous tubules have an independent proportion ' p_j ' of cross-sectional profiles being in stage j of the cycle of the seminiferous epithelium. Therefore, it follows that the number of tubular cross-sectional profiles in stage j for the i th animal can be considered as being a binomial variate with parameters N_i and p_j , where N_i is the total number of tubular profiles sampled for the i th animal, or

$$n_{ij} \sim \text{Bin}(N_i, p_j)$$

Hence, for the plains rat, $i = 1, \dots, 12$ (12 animals sampled) and $j = 1, \dots, 11$ (11 cycle stages) and for the hopping mouse, $i = 1, \dots, 14$ (14 animals sampled) and $j = 1, \dots, 8$ (8 cycle stages). From these assumptions, confidence intervals (Table 4.1) for the expected proportion of observations for each cycle stage were determined. These intervals were based on there being no more than a 5% chance of an individual falling outside of the interval for any particular stage, if there is homogeneity in stage frequency between animals. Observed frequencies of each stage were then scrutinised for each animal to determine whether they fell within the confidence limits. The occurrence of values falling outside the limits indicated variation between individuals in stage frequency, ie. that the frequency of a stage(s) is not constant within the species.

When setting the confidence limits in the above analysis, the p_j used (mean number of observations in stage j for all animals sampled within a species) was an estimate and was itself subject to random variation. Therefore, a generalised linear model was fitted to the observed frequency data and a Pearson's χ^2 - test of independence was performed on a table of frequency by animal data (plains rat: 12 x 11 table, 110 degrees of freedom; hopping mouse 14 x 8 table, 91 degrees of freedom). For each species, the stage variable was subsequently partitioned into 'stage j ' and 'not stage j ', thereby enabling determination of whether there were differences between animals in the frequency of stage j . The p -values were obtained by comparing the χ^2 value for the stage to a χ^2 distribution with 11 or 13 degrees of freedom for the plains rat and hopping mouse respectively. Values of $p < 0.05$ were deemed to indicate a significant difference between animals in the frequency of a stage.

Table 4.1
Upper and Lower Confidence Limits[†] ($p < 0.05$) of Stage Frequency[‡] for the Plains Rat, *Pseudomys australis* and the Hopping Mouse, *Notomys alexis*

Cycle Stage	Plains Rat (11 cycle stages)		Hopping Mouse (8 cycle stages)	
	lower limit	upper limit	lower limit	upper limit
I	9.70	27.50	7.84	22.07
II	0.02	10.00	1.87	12.02
III	1.54	13.67	4.44	16.71
IV	0.38	10.96	15.93	33.09
V	7.39	24.05	5.07	17.76
VI	0.97	12.39	3.83	15.67
VII	0.86	12.14	6.70	20.35
VIII	1.76	14.14	2.81	13.84
IX	3.97	18.38		
X	2.39	15.42		
XI	0.68	11.70		

[†] Limits derived from frequency data presented in Tables 4.2 and 4.3.

[‡] Method of derivation assumes that stage frequency is constant within a species.

4.3 Results

4.3.1 Observed Stage Frequency

The observed frequency of each of the 11 cellular associations of the plains rat, as determined by staging all tubular cross sections within randomly chosen sections of testis, are presented in Table 4.2. Stage I occurred with the greatest mean frequency (18.60%) and stage II with the least mean frequency (5.01%). Corresponding data for the eight cellular associations of the hopping mouse are presented in Table 4.3. In the hopping mouse, stage IV had the highest mean frequency (24.51%), whereas stage II was observed least often (6.95%).

Table 4.2
Observed Frequencies (%) of the Stages in the Cycle of the Seminiferous Epithelium in the Plains Rat, *Pseudomys australis*

Animal Code (n = 12)	Cycle Stage											Total Tubules
	I	II	III	IV	V	VI	VII	VIII	IX	X	XI	
Pa 3/2/1	15.58	10.55	7.54	6.03	17.59	5.03	5.53	8.04	8.54	7.04	8.54	199
Pa 3/2/2	22.56	7.18	7.18	5.64	15.90	7.18	8.21	5.13	10.77	4.62	5.64	195
Pa 3/2/3	14.78	4.43	6.40	5.42	18.23	5.91	5.42	8.87	11.33	0.99	18.23	203
Pa18/11/1	21.50	3.00	6.00	7.00	15.50	9.00	7.00	7.50	12.00	9.50	2.00	200
Pa18/11/2	19.17	2.59	8.81	4.66	18.13	5.18	3.63	5.18	18.65	10.36	3.63	193
Pa18/11/3	23.59	3.59	5.13	3.08	14.87	7.69	9.23	7.69	8.72	10.26	6.15	195
Pa 94	14.62	4.62	9.23	3.85	15.38	10.77	4.62	6.92	13.85	10.00	6.15	130
Pa 3/2/4	12.88	6.06	9.85	11.36	7.58	3.79	4.55	13.64	11.36	11.36	7.58	132
Pa 9/12/1	20.79	6.44	8.42	6.93	14.85	4.95	7.92	7.43	6.44	9.90	5.94	202
Pa 5/2/9	19.48	3.90	3.90	7.79	16.88	9.74	7.14	7.14	9.74	7.79	6.49	154
Pa 5/2/4	17.32	1.57	10.24	4.72	25.20	6.30	3.94	3.94	12.60	12.60	1.57	127
Pa EP 7	20.93	6.20	8.53	1.55	8.53	4.65	10.85	13.95	10.08	12.40	2.33	129
Mean	18.60	5.01	7.60	5.67	15.72	6.68	6.50	7.95	11.17	8.90	6.19	
S.D.	3.49	2.44	1.95	2.51	4.54	2.21	2.26	3.06	3.08	3.36	4.40	

Total number of seminiferous tubule cross sections examined across all animals was 2059.

Table 4.3
Observed Frequencies (%) of the Stages in the Cycle of the Seminiferous Epithelium
and Incidence of 'Multi-stage' Tubular Cross Sections in the Hopping Mouse,
Notomys alexis.

Animal Code (n = 14)	Cycle Stage								Total Tubules	Multi-stage cross-sections	% Multi-stage cross-sections
	I	II	III	IV	V	VI	VII	VIII			
Na Ex 1	10.05	8.97	7.07	26.63	12.64	8.42	17.39	8.83	184	24	13.04
Na Ex 262	19.61	6.06	5.39	25.25	11.36	12.82	11.64	7.86	297	27	9.09
Na Ex 191	16.89	9.84	7.71	19.28	17.69	12.23	9.71	6.65	188	27	14.36
Na 9/1/1	13.53	7.51	13.94	35.25	8.15	5.78	9.29	6.56	183	22	12.02
Na 9/1/2	12.64	6.69	12.27	22.30	8.55	12.92	16.17	8.46	269	17	6.32
Na 9/1/5	13.22	5.74	10.55	27.25	8.09	11.37	13.01	10.76	244	31	12.70
Na 9/1/6	17.40	3.43	8.33	26.72	8.70	6.37	21.45	7.60	204	19	9.31
Na 19/1/1	15.20	6.66	12.19	19.85	14.70	9.92	12.56	8.92	199	29	14.57
Na 19/1/3	16.01	6.14	8.77	19.74	13.63	9.03	15.86	10.82	228	30	13.16
Na 19/1/5	18.23	7.34	14.91	22.02	7.26	10.28	13.65	6.31	218	33	15.14
Na 20/1/3	10.75	7.62	10.84	23.03	14.16	10.66	15.65	7.29	279	34	12.19
Na 20/1/5	15.68	7.50	14.32	23.18	9.66	10.34	13.86	5.45	220	38	17.27
Na 18/11/1	15.60	9.05	13.10	27.86	12.26	8.33	4.52	9.29	210	18	8.57
Na 8/12/1	14.53	4.70	8.65	24.79	12.93	8.01	14.64	11.75	234	34	14.53
Mean	14.95	6.95	10.57	24.51	11.41	9.75	13.53	8.32			12.13
S.D.	2.73	1.72	2.98	4.21	3.10	2.22	4.06	1.87			3.01

Total number of seminiferous tubule cross sections examined across all animals was 3157.
 Total number of multi-stage tubular cross sections was 383.

4.3.2 Variation in Stage Frequency Between Animals

Statistical analysis of stage frequency data revealed that in five of 12 plains rats, values of the observed frequency of one or more cycle stages fell outside of the 95% confidence limits for the particular cycle stage, constructed on the assumption that stage frequency is independent of the animal. A lower than expected frequency was observed for stage X (Pa 3/2/3) and higher than expected frequencies for stages II (Pa 3/2/1), IV (Pa 3/2/4), V (Pa 5/2/4), IX (Pa 18/11/2) and XI (Pa 3/2/3). This suggests that there may be differences between animals in the frequency of particular stages of the cycle of the seminiferous epithelium. However, because the values of p_j used in constructing the confidence limits were subject to their own random variation, these differences may not be biologically meaningful. Therefore, a χ^2 analysis was performed after partitioning cycle stages into 'stage j ' and 'not stage j '. It revealed a significant difference in the observed frequency of stages II, V, VIII, IX, X and XI ($p < 0.05$) between individual plains rats (Table 4.4), from that expected for a χ^2 distribution with 11 degrees of freedom.

In the hopping mouse, only one of 14 animals had an observed stage frequency outside of the 95% confidence limits as listed in Table 4.1. This was animal Na 18/11/1, in which the 4.52% frequency of stage VI was less than the lower limit of 6.70%. A significant difference ($p < 0.05$) in the observed frequency of stages III, IV, V and VII between animals was, however, indicated by the χ^2 analysis (see Table 4.4), compared to the expected values of a χ^2 distribution with 13 degrees of freedom.

Table 4.4
Values of χ^2 and p when Stage Frequency Data is Partitioned into 'Stage j' and 'Not Stage j'.

Cycle Stage	Plains Rat (11 cycle stages)		Hopping Mouse (8 cycle stages)	
	χ^2 value	p-value [†]	χ^2 value	p-value [‡]
I	14.847	0.190	18.342	0.145
II	24.513	0.011	12.459	0.490
III	9.458	0.580	29.473	0.006
IV	18.524	0.070	24.620	0.026
V	22.762	0.019	25.986	0.017
VI	13.357	0.271	16.283	0.234
VII	14.361	0.214	38.970	0.000
VIII	20.159	0.043	12.829	0.461
IX	20.005	0.045		
X	28.459	0.003		
XI	66.388	0.000		

† P values obtained by comparing the χ^2 value to a χ^2 distribution with 11 degrees of freedom

‡ P values obtained by comparing the χ^2 value to a χ^2 distribution with 13 degrees of freedom

Values in bold indicate significant between-animal variation in stage frequency.

4.3.3 Incidence of 'Multi-stage' Cross-sectional Profiles in the Hopping Mouse

In the hopping mouse an average of 12.13% (range 6.3–17.3%) of tubular cross-sections contained more than one cellular association (Table 4.3), however, multiple cellular associations were never observed in cross sections of plains rat seminiferous tubules. Most 'multi-stage' cross sections contained two cellular associations (see Figs 3.14 and 3.16, Chapter 3), but up to three associations, each occupying several small, localised areas of the tubular wall were sometimes observed (see Fig. 3.15, Chapter 3). Furthermore, the cellular associations observed in multi-stage cross sections were not always consecutive stages in the cycle of the seminiferous epithelium (Figs 3.15 and 3.16, Chapter 3). Most commonly, areas of the seminiferous epithelium at stage V were interposed between two areas within the same tubular cross section showing stage VII development. In addition, cellular associations were observed in the hopping mouse in which one of the generations of germ cells was either out of synchrony with the others (see Figs 3.26 and 3.26, Chapter 3), or absent altogether (Figs 3.27 and 3.28, Chapter 3). Such associations were classified

according to the appearance of the early spermatid population, or when this population was absent, on the basis of the positions and appearances of the other cell populations present.

4.4 Discussion

Assessments of the kinetics of spermatogenesis often rely on a knowledge of the mean relative frequency of cellular associations in cross sections of seminiferous tubules, in conjunction with the tracking of germ cells during spermatogenic development (Clermont and Trott, 1969; Courot *et al.*, 1970; Clermont, 1972). Kinetic data include the duration of the cycle of the seminiferous epithelium, the duration of spermatogenesis and the life spans of individual germ cell types. Frequency determinations are based on the assumption that when testis morphology is examined at a single point in time, a cellular association representing a cycle stage of long duration will be observed more frequently than one of short duration (Clermont and Trott, 1969). However, for an analysis of tubular morphology to accurately reflect the kinetics of spermatogenesis, certain conditions need to be adhered to during data collection.

Firstly, calculation of stage frequency requires that cellular associations can be consistently recognised in tissue sections, since misidentification of cellular associations may alter quantitation of the stage means and hence influence interpretation of kinetics (Hess *et al.*, 1990). Secondly, the system of sampling must be representative of the tissue and the species as a whole. Accurate determination of the mean frequency of individual cycle stages in a species therefore requires that relatively large minimum numbers of tubules per testis are counted in a representative number of animals. It was argued by Hess *et al.*, (1990) that when fewer than 100 tubules per testis are counted (eg. 50 or 25), each observation contributes proportionately more to the stage frequency and differences of a single observation dramatically shift the frequency data of those associations with a low mean frequency of occurrence. Furthermore, these investigators found that the amount of variance in their data decreased to a greater extent by increasing the number of animals sampled, than by increasing the number of tubules per animal scored, notwithstanding the sampling of a minimum of 200 tubules per animal. Hence, the guidelines as proposed by Hess *et al.* (1990) were adopted for the present study and data were collected from at least 12 animals per species, which was the minimum number recommended when assessing all cycle stages in the laboratory rat.

4.4.1 Stage Frequency

It has previously been reported that the relative frequency of stages of the cycle of the seminiferous epithelium is constant between animals within the same species or strain (Hochereau, 1963; Courot *et al.* 1970; Berndtson, 1977). The results obtained in the present study, however, suggest that there is variability among individuals of both the plains rat and the hopping mouse, in the frequency of certain cycle stages. In the plains rat, inter-animal variation in stage frequency at greater than the 0.05 level was detected for stages II, V, VIII, IX, X and XI. These stages correspond to the cellular associations in which:

- a) proacrosomal granules are elaborated and the acrosomal vesicle becomes associated with the spermatid nucleus (stage II),
- b) the extent of coverage of the acrosome over the nucleus of the round spermatids exceeds 120° , but the acrosomal pole of the nucleus has not yet made contact with the cell's plasmalemma (stage V) and,
- c) angulation and shaping of the spermatid head and condensation of the nucleus occurs (stages VIII-XI).

In the hopping mouse, intraspecific variability in stage frequency was detected for stages III, IV, V and VII of the cycle ($p < 0.05$). Stages III-V are characterised by the spread of the acrosome over the nucleus of the round spermatid population and stage VII by nuclear condensation within the spermatids. These results suggest that the events associated with spermatid development (outlined above) proceed at slightly different rates in different individuals.

In a previous study, variability in stage frequency was reported among hopping mice, but not among plains rats (Peirce and Breed, 1987), however, the method used for analysis of the cellular associations was different than that employed in the present study. In the former investigation, at least part of the variability in hopping mouse data may have been attributable to inconsistencies in stage recognition, resulting from the less rigid organisation of the seminiferous epithelium in this species and/or to insufficient sampling as only 100 tubules per animal were scored. By contrast, the division of the cycle of the seminiferous epithelium in the plains rat into eight associations, compared to the 11 of the current study could have masked inter-animal variability in this species, because reducing the number of stages may pool stages with high and low levels of variability in frequency, resulting in less likelihood of detecting animal to animal differences (Hess *et al.*, 1990). It is clear that, in the present study, variability in stage frequencies among individuals cannot be attributed to non-representative sampling, or the misidentification of stages or inconsistencies in stage recognition, since predetermined criteria were consistently applied when staging tubules. Furthermore, additional guidelines were taken into consideration in

situations where transitions between stages were apparent.

This study found, however, that, in both species, many tubular cross sections within a given region of a testis contained the same cellular association or that preceding or following it in the cycle of the seminiferous epithelium. This phenomenon has also been observed in the testes of the laboratory mouse (Redi, 1986) and blue fox (Berg *et al.*, 1990) and has been suggested as reflecting the tight coiling of the seminiferous tubules in a particular area of the testis, resulting in numerous sections through the same segment of seminiferous tubule. Alternatively, it might indicate that there is localised extratubular control over the spermatogenic process, ie. that a functional relationship exists between the extratubular compartment and the seminiferous tubules of a portion of the testis that brings about spatial coordination of spermatogenic development (Redi, 1986). It is unlikely that the occurrence of such 'clusters' of cellular associations has contributed to frequency variations between animals in this study because approximately 200 tubular cross sections per animal, at many sites within the testes, were scored. The results obtained, therefore, probably accurately reflect the degree of variability in stage frequency and hence relative duration of spermatogenic events in the plains rat and hopping mouse.

Despite claims that stage frequency is constant among individuals within a species (Hochereau, 1963; Courot *et al.* 1970; Berndtson, 1977), some natural variation should be expected on the basis of seminiferous epithelial organisation. It is known that, in the laboratory rat, the length of a tubular segment occupied by a given cellular association varies widely within the wave of the seminiferous epithelium, as does the total length of waves (see Table 1 of Perey *et al.* 1961). Furthermore, due to the occurrence of modulations (reversals in the order of stages) within waves, there is no correlation between the length of segments occupied by a particular cycle stage and stage frequency per tubular cross section (Perey *et al.*, 1961). Hence, differences between individuals in the number of stage modulations per wave of the seminiferous epithelium will result in intraspecific variations in stage frequency. It is for these reasons that mean frequencies from a large number of evaluations per individual have been used to determine stage duration in time (Clermont and Trott, 1969).

4.4.2 Incidence of Multi-stage Tubular Cross Sections

In the present study, an average of 12.1% (range 6.3–17.3%) of hopping mouse tubular cross sections contained more than one cellular association, which is somewhat lower than the figure of 20% previously reported (Peirce and Breed, 1987). The discrepancy in values can be explained, however, by taking into account differences in the criteria used to define individual cellular associations between the two studies. According to the criteria

employed in the present study, spermatids with morphologies representative of slightly different points in spermiogenesis in the one area of the seminiferous epithelium were defined as belonging to the same cellular association in some cases. For example, the shape of the spermatid nucleus in stage VI ranges from predominantly ovoid with slight bilateral flattening and tapering of the caudal pole (early stage VI appearance), to extensively elongated (late stage VI appearance). In the previous study, spermatids with these two different appearances were classified as belonging to two different cellular associations and hence contributed to the higher incidence of multi-stage tubular cross sections. Nevertheless, the present study confirms the occurrence of multi-stage tubular cross sections in the hopping mouse, unlike that in the plains rat, laboratory rat or laboratory mouse. Hence the hopping mouse is clearly different in this respect from other rodent species in which only one cellular association is consistently seen in a tubule cross section. Furthermore, the occurrence of multi-stage tubular cross sections in the hopping mouse suggests a different organisation of the seminiferous epithelium in this species from that of other rodent species.

The observation of multiple cellular associations within a single tubular cross sectional profile in the hopping mouse is similar to that in the seminiferous tubules of humans and the baboon, *Papio anubis* (Chowdhury and Steinberger, 1976; Schulze and Rehder, 1984; Chowdhury and Marshall, 1980; Schulze *et al.*, 1986). More than one cellular association per tubular cross section has also been reported in the dog (Russell *et al.*, 1990), although no data on frequency of occurrence were provided. As mentioned in Chapter 3, a spiral rather than a segmental arrangement of cellular associations along the length of seminiferous tubules was shown to be consistent with the occurrence of multi-stage tubular cross sections and the non-consecutive spatial arrangement of some cellular associations within those cross sections in the human (Schulze and Rehder, 1984; Schulze *et al.*, 1986). Perhaps a similar situation exists in the hopping mouse.

4.5 Summary

The frequency of the stages in the cycle of the seminiferous epithelium was determined in the plains rat and hopping mouse. Despite the use of protocols designed to minimise variability due to sampling error and inconsistencies in the recognition of cycle stages, between animal differences in the frequency of certain cycle stages were observed in both species. Hence, the results in this chapter clearly indicate that there is natural diversity in the frequency of cycle stages between individual plains rats and hopping mice. Such differences might reflect slight variations in the timing of particular developmental events of spermatogenesis between individual animals within a species. In the hopping mouse, an

average of 12.1% of tubular cross sections contained more than one cellular association. Therefore, in this species, there is also a different spatial arrangement of cellular associations within the seminiferous tubules from that observed in laboratory rodent species described to date.

Chapter 5 Duration of the Cycle of the Seminiferous Epithelium

5.1 Introduction

The duration of the cycle of the seminiferous epithelium varies according to species (Table 1.1, pages 36-37) and is one of the factors that influences a species' potential for sperm production. For any given time frame, it follows that a species with a short spermatogenic cycle has the potential to produce greater numbers of spermatozoa than one with a long cycle, provided all other sperm production parameters are similar. In Chapter 4 of this thesis, the relative frequency of stages of the spermatogenic cycle in the plains rat and hopping mouse were determined from analysis of cross sections of the seminiferous tubules. The aim of this chapter is to utilise these data to determine the duration of the cycle of the seminiferous epithelium in these species. This will then enable determination of the absolute duration of individual cycle stages and the various maturational events in spermatogenesis, as well as provide the basis for estimation of the duration of spermatogenesis.

5.2 Materials and Methods

5.2.1 Animals

A total of 20 adult male plains rats and 20 adult male hopping mice were given a single intraperitoneal injection of [methyl-³H]thymidine (specific activity 43 Ci/mmol; Amersham, Buckinghamshire, UK) at a dose rate of 1-1.5 μ Ci per gram of body weight. Animals were subsequently sacrificed by an overdose of pentobarbitone sodium (Nembutal Abbott-Ceva Chemicals, Hornsby, NSW) or carbon dioxide asphyxiation at intervals as follows:

Plains rats:

Two animals were sacrificed at each of 1 hour, 1 day 1 hour, 3 days 22 hours, 7 days 1 hour, 9 days 1 hour and 12 days 3.83 hours and 3 animals were sacrificed at 13 days 1 hour following ³H-thymidine injection. One animal was sacrificed at each of 4 days 1 hour, 5 days 1 hour, 15 days 0.33 hours, 15 days 1.5 hours and 16 days 1 hour.

Hopping mice:

Three animals were sacrificed at 1 hour following ^3H -thymidine administration and 2 animals at each of 3 days 22 hours, 7 days 1 hour, 8 days, 12 days 3.83 hours, 13 days 1 hour, 14 days 1 hour, 15 days 0.33 hours and 16 days 1 hour. One animal was sacrificed 26 days after injection.

5.2.2 Tissue Preparation and Autoradiography

Testes were removed at sacrifice and fixed by immersion in either EM fixative (3% formaldehyde/3% glutaraldehyde) for 24 hours or Bouin's fluid overnight. Whole testes (hopping mice) or transverse slices of testicular tissue (plains rats) were then rinsed thoroughly in 0.2M phosphate buffer, or a lithium carbonate solution to remove picric acid (Bouin's fixed tissue), processed routinely for paraffin embedding and sectioned at 5 μm . Tissue sections were taken to water and coated with Kodak NTB-2 nuclear track emulsion (Eastman Kodak, Rochester, New York), or Ilford K2 nuclear research emulsion (Ilford, Australia) diluted with an equal volume of double-distilled water, via the dipping method. Briefly, slides were dipped into the emulsion and held vertically for 1-2 seconds to allow excess emulsion to drain into a paper tissue. The backs of slides were wiped and slides were dried flat by placing them section-side up in a light proof metal cabinet for 24 hours at 20°C. They were then transferred to light-tight black plastic boxes containing desiccant and stored at 4°C in a refrigerator during the exposure period. After intervals of time ranging from 4-12 weeks, batches of slides were developed and fixed before staining with either haematoxylin and eosin, or Harris' haematoxylin only.

5.2.3 Analysis of Autoradiographic Sections

Tritiated thymidine is incorporated into cells that are in the process of replicating their DNA at the time of label administration. The cells within the seminiferous epithelium that incorporate the label, therefore, are types A, intermediate and B spermatogonia in preparation for their mitoses and preleptotene primary spermatocytes immediately prior to entering the meiotic prophase.

For each section of testis, the germ cell populations within the seminiferous tubules that were labelled were noted and the position within the cycle of the seminiferous epithelium of the most advanced of these populations with respect to spermatogenesis, was determined. In most cases, the most advanced labelled cell type was present in two or three consecutive cellular associations. Therefore, a more exact location of the label front was determined by estimating the proportion of labelled tubular cross sections at the cycle



stage in which the most mature spermatogenic cells displaying labelling were present¹. The actual percentage of tubules at a particular cycle stage containing labelled cells (see Clermont and Trott, 1969) was not calculated in this study because some tissue sections, particularly those of the hopping mouse, contained very few cross sections of tubules on which to base counts.

Sections of testes from animals sacrificed at different times following incorporation of ³H-thymidine into their DNA were compared and the developmental progression through the cycle of the seminiferous epithelium of the most advanced labelled cells during the time interval was recorded. Estimates of cycle duration were based on both the initial point of labelling and on intermediate points of labelling as observed in animals exposed to ³H-thymidine for different periods of time. The mean frequency of cycle stages for each species as determined in Chapter 4 was used in calculations of the duration of one cycle of the seminiferous epithelium as follows:

$$\text{Duration of 1 cycle} = x/y$$

where x = known time interval between the two appearances of labelled cells at times A and B.

y = relative proportion of one cycle travelled by the labelled cells in x days (ie. the sum of the stage frequencies between the two occurrences of labelled cells at times A and B).

Once the duration of one cycle of the seminiferous epithelium was known the duration of individual cycle stages was estimated and the life span of spermatogenic cell types calculated by determining the extent of their occurrence in the various cellular associations.

¹ Not all cells of a population at a particular cycle stage will necessarily be labelled. Some of them may have been at a slightly later (or earlier) point in their development when the label was administered, and had finished (or not yet started) replicating their DNA during the time interval in which the label was available for incorporation. Therefore, the percentage of labelled tubules at the stage of the cycle containing the labelled cell front provides an estimate of how far through that stage the cells have travelled in the elapsed time interval.

5.3 Results

5.3.1 Duration of the Cycle of the Seminiferous Epithelium

Plains Rat

In the plains rat, the exact location of the most developmentally advanced labelled cells in animals sacrificed at the same time interval following ^3H -thymidine administration was somewhat variable (Fig.5.1a, 5.1b). One hour after ^3H -thymidine injection, the most advanced labelled cells were preleptotene primary spermatocytes at the end of stage V of the cycle, or leptotene primary spermatocytes at the beginning of stage VI. One day 1 hour following injection the most advanced labelled cells were leptotene primary spermatocytes at stage VIII and after 3 days 22 hours, these were zygotene primary spermatocytes of stage X (Fig. 5.2). By 9 days 1 hour following administration of the label, pachytene primary spermatocytes of either stages IV or V were the most advanced labelled cells (Figs 5.3a, 5.3b) and by 12 days 3.83 hours, pachytene primary spermatocytes of stage VI-VII were the most advanced cells labelled. Thus, these cells had progressed through greater than one cycle of the seminiferous epithelium in the 12 days subsequent to incorporation of the ^3H -thymidine. The position of the most advanced labelled cells for each time interval following ^3H -thymidine injection is shown in Table 5.1.

Estimates of cycle duration using the initial point of labelling are given in Table 5.1 and those using intermediate points of labelling are given in Table 5.2. From all combinations of data for a time interval of greater than 2.5 days, cycle duration in the plains rat was estimated to be 11.86 ± 2.80 days (mean \pm S.D.). Time intervals shorter than two days were considered too short for a reliable estimate of cycle length to be made. This was because a small variation in identification of the position of the label front between the two labelled cell populations could give rise to a large error in the estimated cycle length, due to the calculation methods used. Values for the estimated cycle duration generated from several other combinations of data (marked with an asterisk in Table 5.2) were found to be significantly longer than the majority of values obtained (see discussion section for a possible explanation of why this might have occurred). When these values were excluded from calculation of the mean cycle duration, it was found to be **11.16 ± 1.57 days** (calculated from 134 combinations of data).

Plate 9 Autoradiographic Labelling of Plains Rat Seminiferous Tubules

The position of the most advanced labelled cell type within the seminiferous epithelium of two different animals one hour following ^3H -thymidine administration is shown.

Figure 5.1a

Animal 1. The most advanced cells showing labelling with ^3H -thymidine (indicated by arrows) are the preleptotene primary spermatocytes of stage V.

Bar = 25 μm

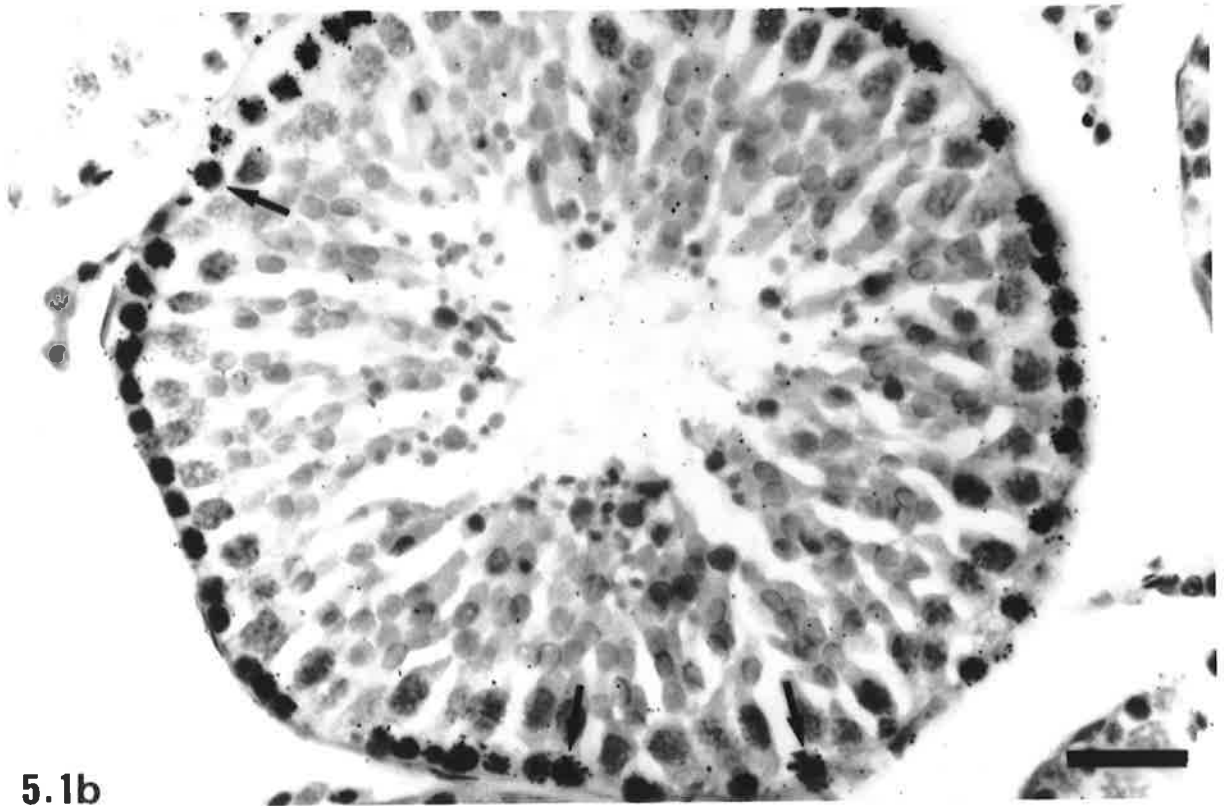
Figure 5.1b

Animal 2. The most advanced cells showing labelling (indicated by arrows) are the leptotene primary spermatocytes of stage VI.

Bar = 25 μm



5.1a



5.1b

Plate 10 Autoradiographic Labelling of Plains Rat Seminiferous Tubules

Figure 5.2

Three days 22 hours following ^3H -thymidine administration. The most advanced labelled cell type present is the zygotene primary spermatocyte population of stage X.

Bar = 25 μm

Figure 5.3

Nine days 1 hour following ^3H -thymidine administration. In two different animals, the most advanced labelled cell type present is the pachytene primary spermatocyte population of IV (Fig. 5.3a) and stage V (Fig. 5.3b) respectively.

Bars = 25 μm

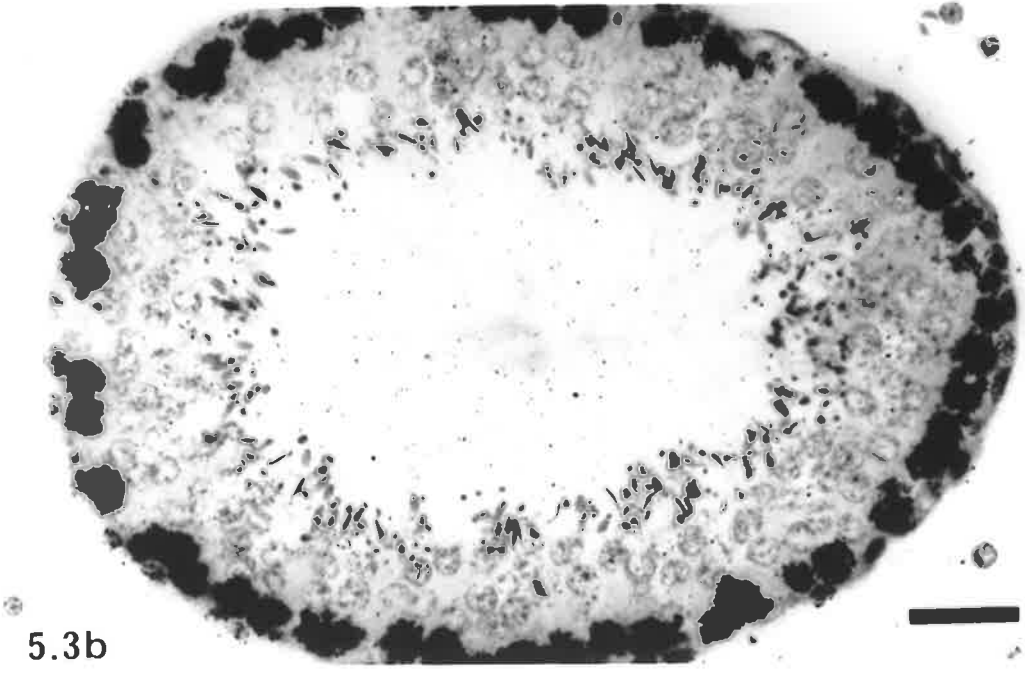
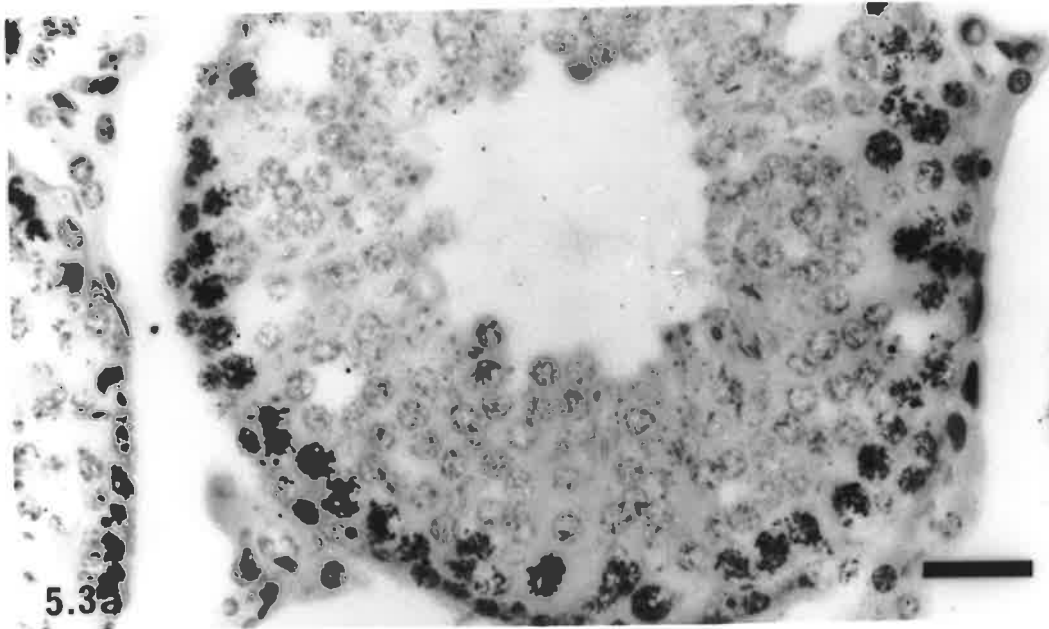
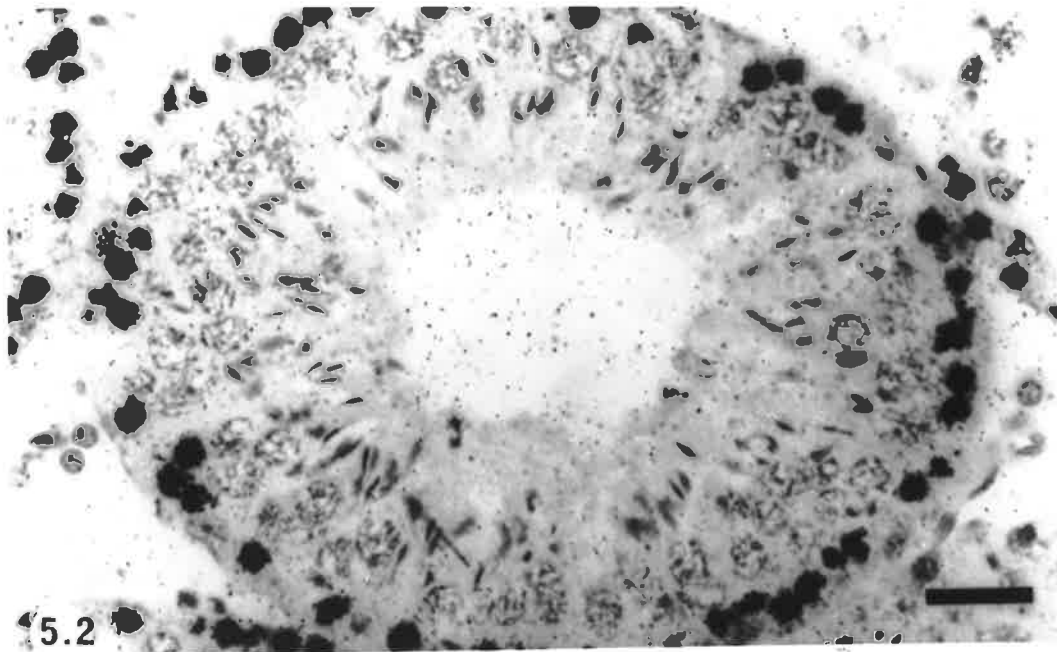


Table 5.1
Estimates of the Duration of the Cycle of the Seminiferous Epithelium in the Plains Rat,
Pseudomys australis, based on Initial Point of Labelling with ³H-thymidine

Time after injection of ³ H-thymidine	Most advanced labelled cells in the seminiferous epithelium		Interval since labelling as preleptotene or leptotene spermatocytes		
	Cell type	Stage & estimated % of tubules at that stage containing labelled cells	Number of cycles traversed	Time elapsed (days)	Duration of one cycle (days)#
1 hour	preleptotene primary spermatocyte	stage V, 100%	-	-	-
1 hour	leptotene primary spermatocyte	stage VI, 50%	-	-	-
1 day 1 hour	leptotene primary spermatocyte	stage VIII, 25%	0.152	1	6.58†
			0.118		8.47†
3 days 22 hours	zygotene primary spermatocyte	stage X, 50%	0.368	3.88	10.54
			0.334		11.62
3 days 22 hours	zygotene primary spermatocyte	stage X, 100%	0.412	3.88	9.42
			0.379		10.24
4 days 1 hour	zygotene primary spermatocyte	stage XI, 50%	0.443	4	9.03
			0.410		9.76
5 days 1 hour	pachytene primary spermatocyte	stage I, 10%	0.485	5	10.31
			0.459		10.89
7 days 1 hour	pachytene primary spermatocyte	stage III, 100%	0.786	7	8.91
			0.753		9.30
7 days 1 hour	pachytene primary spermatocyte	stage IV, 50%	0.814	7	8.60
			0.781		8.96
9 days 1 hour	pachytene primary spermatocyte	stage IV, 100%	0.843	9	10.68
			0.809		11.12
9 days 1 hour	pachytene primary spermatocyte	stage V, 50%	0.921	9	9.77
			0.888		10.14
12 days 3.83 hrs	pachytene primary spermatocyte	stage VII, 25%	1.050	12.12	11.54
			1.083		11.19
12 days 3.83 hrs	pachytene primary spermatocyte	stage VI, 50%	1.000	12.12	12.12
			1.033		11.73
13 days 1 hour	pachytene primary spermatocyte	stage VIII, 25%	1.152	13	11.28
			1.118		11.63
13 days 1 hour	pachytene primary spermatocyte	stage VIII, 50%	1.172	13	11.09
			1.138		11.42
13 days 1 hour	pachytene primary spermatocyte	stage VIII, 90%	1.203	13	10.81
			1.170		11.11
15 days 0.33 hrs	pachytene primary spermatocyte	stage X, 100%	1.412	14.99	10.61
			1.379		10.87
15 days 1.5 hrs	pachytene primary spermatocyte	stage X, 100%	1.412	15.02	10.64
			1.379		10.89
16 days 1 hour	secondary spermatocyte	stage XI, 50%	1.443	16	11.09
			1.410		11.35

Estimates of cycle duration are based on the progression of the label from its occurrence in preleptotene and leptotene spermatocytes of stages V and VI of the cycle respectively at 1 hour following administration of ³H-thymidine. Additional estimates, based on intermediate points of labelling, are shown in Table 5.2

† Intervals shorter than 2.5 days were considered too short for a reliable estimate of cycle length and have been excluded from calculations of the mean cycle duration.

Table 5.2

Estimates of the Duration of the Cycle of the Seminiferous Epithelium in the Plains Rat, *Pseudomys australis*, based on Intermediate Point of Labelling with ^3H -thymidine

Position of most advanced labelled cells at time A and % of tubule x-sections labelled	Position of most advanced labelled cells at time B and % of tubule x-sections labelled	Time interval between A and B (days)	Number of cycles traversed	Calculated duration of one cycle (days)	
leptotene stage VIII, 25% (x2)‡	zygotene stage X, 50%	2.88	0.216	13.33	
	zygotene stage X, 100%	2.88	0.260	11.08	
	zygotene stage XI, 50%	3.00	0.252	11.90	
	pachytene stage I, 10%	4.00	0.341	11.73	
	pachytene stage III, 100%	6.00	0.634	9.46	
	pachytene stage IV, 50%	6.00	0.662	9.06	
	pachytene stage IV, 100%	8.00	0.602	13.29	
	pachytene stage V, 50%	8.00	0.635	12.60	
	pachytene stage VI, 50%	11.12	0.931	11.94	
	pachytene stage VII, 25%	11.12	0.882	12.61	
	pachytene stage VIII, 25%	12.00	1.000	12.00	
	pachytene stage VIII, 50%	12.00	1.020	11.76	
	pachytene stage VIII, 90%	12.00	1.052	11.41	
	pachytene stage X, 100%	13.97	1.260	11.09	
	pachytene stage X, 100%	14.02	1.260	11.13	
zygotene stage X, 50%	secondary stage XI, 50%	15.00	1.291	11.62	
	pachytene stage III, 100%	3.12	0.419	7.45	
	pachytene stage IV, 50%	3.12	0.447	6.98	
	pachytene stage IV, 100%	5.12	0.475	10.78	
	pachytene stage V, 50%	5.12	0.554	9.24	
	pachytene stage VI, 50%	8.24	0.682	12.08	
	pachytene stage VII, 25%	8.24	0.716	11.51	
	pachytene stage VIII, 25%	9.12	0.784	11.63	
	pachytene stage VIII, 50%	9.12	0.804	11.34	
	pachytene stage VIII, 90%	9.12	0.836	10.91	
	pachytene stage X, 100%	11.09	1.045	10.61	
	pachytene stage X, 100%	11.14	1.045	10.66	
	secondary stage XI, 50%	12.12	1.076	11.26	
	zygotene stage X, 100%	pachytene stage III, 100%	3.12	0.374	8.34
		pachytene stage IV, 50%	3.12	0.402	7.76
pachytene stage IV, 100%		5.12	0.431	11.88	
pachytene stage V, 50%		5.12	0.509	10.06	
pachytene stage VI, 50%		8.24	0.621	13.27	
pachytene stage VII, 25%		8.24	0.671	12.28	
pachytene stage VIII, 25%		9.12	0.740	12.32	
pachytene stage VIII, 50%		9.12	0.760	12.00	
pachytene stage VIII, 90%		9.12	0.791	11.53	
pachytene stage X, 100%		11.09	1.000	11.09	
pachytene stage X, 100%		11.14	1.000	11.14	
secondary stage XI, 50%		12.12	1.031	11.76	
zygotene stage XI, 50%		pachytene stage III, 100%	3.00	0.343	8.75
		pachytene stage IV, 50%	3.00	0.371	8.09
		pachytene stage IV, 100%	5.00	0.400	12.50
	pachytene stage V, 50%	5.00	0.478	10.46	
	pachytene stage VI, 50%	8.12	0.590	13.76	
	pachytene stage VII, 25%	8.12	0.640	12.69	
	pachytene stage VIII, 25%	9.00	0.709	12.69	
	pachytene stage VIII, 50%	9.00	0.729	12.35	

Table 5.2 continued
Estimates of the Duration of the Cycle of the Seminiferous Epithelium in the Plains
Rat, *Pseudomys australis*, based on Intermediate Point of Labelling with ³H-thymidine

Position of most advanced labelled cells at time A and % of tubule x-sections labelled	Position of most advanced labelled cells at time B and % of tubule x-sections labelled	Time interval between A and B (days)	Number of cycles traversed	Calculated duration of one cycle (days)	
zygotene stage XI, 50%	pachytene stage VIII, 90%	9.00	0.760	11.84	
	pachytene stage X, 100%	10.97	0.969	11.32	
	pachytene stage X, 100%	11.02	0.969	11.37	
	secondary stage XI, 50%	12.00	1.000	12.00	
pachytene stage I, 10%	pachytene stage IV, 100%	4.00	0.350	11.43	
	pachytene stage V, 50%	4.00	0.429	9.32	
	pachytene stage VI, 50%	7.12	0.541	13.16	
	pachytene stage VII, 25%	7.12	0.591	12.05	
	pachytene stage VIII, 25%	8.00	0.659	12.14	
	pachytene stage VIII, 50%	8.00	0.697	11.48	
	pachytene stage VIII, 90%	8.00	0.710	11.27	
	pachytene stage X, 100%	9.97	0.920	10.84	
	pachytene stage X, 100%	10.02	0.920	10.89	
	secondary stage XI, 50%	11.00	0.950	11.58	
pachytene stage III, 100%	pachytene stage VI, 50%	5.12	0.247	20.73*	
	pachytene stage VII, 25%	5.12	0.297	17.24*	
	pachytene stage VIII, 25%	6.00	0.366	16.38*	
	pachytene stage VIII, 50%	6.00	0.386	15.38*	
	pachytene stage VIII, 90%	6.00	0.417	14.39*	
	pachytene stage X, 100%	7.97	0.626	12.73	
	pachytene stage X, 100%	8.02	0.626	12.81	
	secondary stage XI, 50%	9.00	0.657	13.70	
	pachytene stage IV, 50%	pachytene stage VI, 50%	5.12	0.219	23.38*
		pachytene stage VII, 25%	5.12	0.269	19.03*
pachytene stage VIII, 25%		6.00	0.337	17.80*	
pachytene stage VIII, 50%		6.00	0.357	16.81*	
pachytene stage VIII, 90%		6.00	0.389	15.42*	
pachytene stage X, 100%		7.97	0.598	13.33	
pachytene stage X, 100%		8.02	0.598	13.41	
secondary stage XI, 50%		9.00	0.629	14.31	
pachytene stage IV, 100%		pachytene stage VI, 50%	3.12	0.191	16.34
		pachytene stage VII, 25%	3.12	0.240	13.00
	pachytene stage VIII, 25%	4.00	0.309	12.94	
	pachytene stage VIII, 50%	4.00	0.329	12.16	
	pachytene stage VIII, 90%	4.00	0.360	11.11	
	pachytene stage X, 100%	5.97	0.569	10.49	
	pachytene stage X, 100%	6.02	0.569	10.57	
	secondary stage XI, 50%	7.00	0.522	13.41	
	pachytene stage V, 50%	pachytene stage VI, 50%	3.12	0.112	27.86*
		pachytene stage VII, 25%	3.12	0.162	19.26*
pachytene stage VIII, 25%		4.00	0.230	17.39*	
pachytene stage VIII, 50%		4.00	0.250	16.00*	
pachytene stage VIII, 90%		4.00	0.281	14.23*	
pachytene stage X, 100%		5.97	0.491	12.16	
pachytene stage X, 100%		6.02	0.491	12.26	
secondary stage XI, 50%		7.00	0.600	11.67	
pachytene stage VII, 25%		pachytene stage X, 100%	2.85	0.395	7.22
		pachytene stage X, 100%	2.90	0.395	7.34
	secondary stage XI, 50%	3.88	0.360	10.78	

Table 5.2 continued
Estimates of the Duration of the Cycle of the Seminiferous Epithelium in the Plains Rat, *Pseudomys australis*, based on Intermediate Point of Labelling with ³H-thymidine

Position of most advanced labelled cells at time A and % of tubule x-sections labelled	Position of most advanced labelled cells at time B and % of tubule x-sections labelled	Time interval between A and B (days)	Number of cycles traversed	Calculated duration of one cycle (days)
pachytene stage VI, 50%	pachytene stage X, 100%	2.85	0.379	7.52
	pachytene stage X, 100%	2.90	0.379	7.65
	secondary stage XI, 50%	3.88	0.410	9.46
pachytene stage VIII, 25%	secondary stage XI, 50%	3.00	0.298	10.07
pachytene stage VIII, 50%	secondary stage XI, 50%	3.00	0.277	10.83
pachytene stage VIII, 90%	secondary stage XI, 50%	3.00	0.245	12.24

* Values indicated by an asterisk were excluded from calculation of mean cycle duration.

‡ (x2) indicates that the position of the most advanced labelled cells was observed in two animals.

Hopping Mouse

In all three animals sacrificed at one hour post ³H-thymidine injection, leptotene primary spermatocytes at the beginning of stage V were the most advanced labelled cells. At 13 days 1 hour, pachytene primary spermatocytes at stage IV were labelled (Fig. 5.4) and by 26 days round spermatids of stage IV were labelled (Fig. 5.5). The position of the most advanced labelled cells at each time following ³H-thymidine injection is shown in Table 5.3. As in the plains rat, the absolute duration of the cycle of the seminiferous epithelium in the hopping mouse was calculated from both initial (Table 5.3) and intermediate (Table 5.4) points of ³H-thymidine labelling. Using all combinations of data with a time interval of greater than 2.5 days (n = 141), cycle duration in the hopping mouse was estimated to be **14.04 ± 3.44 days** (mean ± S.D.). Hence, the cycle of the seminiferous epithelium in the hopping mouse is both longer and more variable in its duration than that of the plains rat.

Plate 11 Autoradiographic Labelling of Hopping Mouse Seminiferous Tubules

Figure 5.4

Thirteen days one hour following ^3H -thymidine administration. Pachytene primary spermatocytes of stage IV are the most advanced labelled cell type present within the seminiferous tubules.

Bar = 25 μm

Figure 5.5

Twenty-six days following ^3H -thymidine administration. Round spermatids of stage IV are the most advanced labelled cell type present within the seminiferous tubules.

Bar = 25 μm

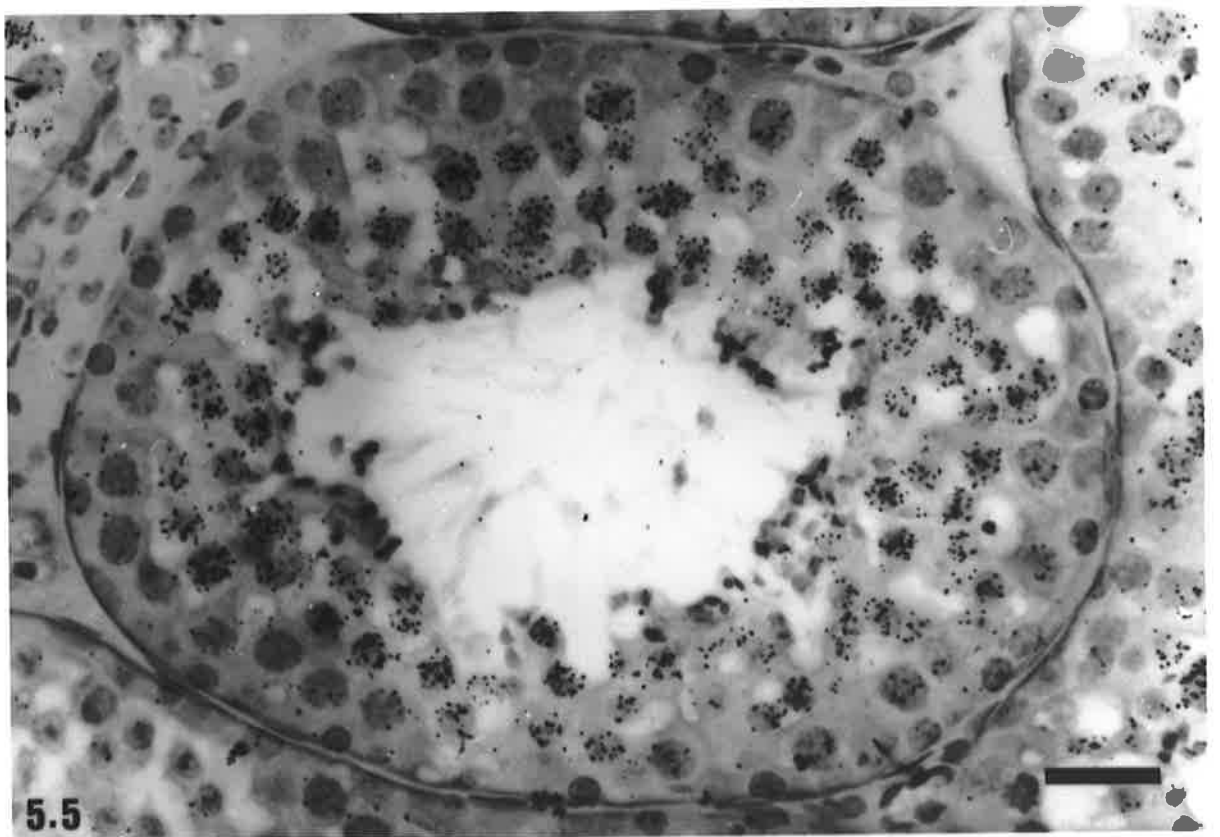
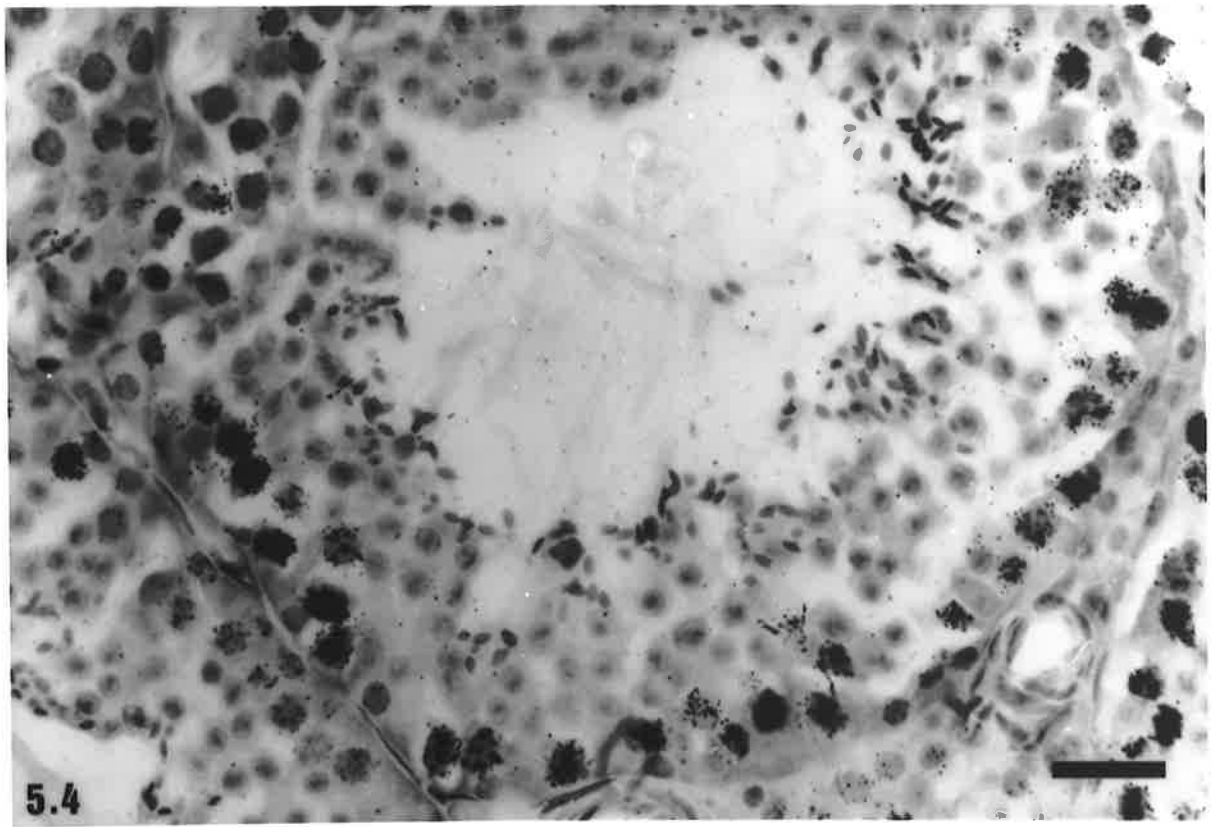


Table 5.3
Estimates of the Duration of the Cycle of the Seminiferous Epithelium in the Hopping Mouse, *Notomys alexis*, based on Initial Point of Labelling with ³H-thymidine

Time after injection of ³ H-thymidine	Most Advanced labelled cells in the seminiferous epithelium		Interval since labelling as leptotene spermatocytes		Duration of one cycle (days)#
	Cell type	Stage & estimated % of tubules at that stage containing labelled cells	Number of Cycles Traversed	Time elapsed (days)	
1 hour	leptotene primary spermatocyte	stage V, 25% (x3)‡	-	-	-
3 days 22 hrs	zygotene primary spermatocyte	stage VII, 50%	0.251	3.88	15.46
3 days 22 hrs	zygotene primary spermatocyte	stage VII, 20%	0.21	3.88	18.48
7 days 1 hour	pachytene primary spermatocyte	stage I, 10%	0.417	7	16.78
7 days 1 hour	pachytene primary spermatocyte	stage I, 50%	0.476	7	14.71
8 days	pachytene primary spermatocyte	stage III, 20% (x2)‡	0.642	7.96	12.40
12 days 3.83 hrs	pachytene primary spermatocyte	stage IV, 70%	0.898	12.12	13.50
12 days 3.83 hrs	pachytene primary spermatocyte	stage IV, 90%	0.947	12.12	12.80
13 days 1 hour	pachytene primary spermatocyte	stage IV, 100%	0.972	13	13.37
13 days 1 hour	pachytene primary spermatocyte	stage IV, 100%	0.972	13	13.37
14 days 1 hour	pachytene primary spermatocyte	stage V, 70%	1.051	14	13.32
15 days 0.33 hrs	pachytene primary spermatocyte	stage VI, 30%	1.115	14.99	13.44
15 days 0.33 hrs	pachytene primary spermatocyte	stage VI, 10%	1.095	14.99	13.69
16 days 1 hour	pachytene primary spermatocyte	stage VI, 50%	1.134	16	14.11
26 days	round spermatid	stage IV, 80%	1.923	25.96	13.50

Estimates of cycle duration are based on the progression of the label from its occurrence in leptotene spermatocytes of stage V of the cycle at 1 hour following administration of the tracer. Additional estimates, based on intermediate points of labelling, are shown in Table 5.4.

‡ (x3) and (x2) indicate that the position of the most advanced labelled cells was observed in three or two different animals respectively.

Table 5.4

Estimates of the Duration of the Cycle of the Seminiferous Epithelium in the Hopping Mouse, *Notomys alexis*, based on Intermediate Points of Labelling with ^3H -thymidine

Position of most advanced labelled cells at time A and % of tubule x-sections labelled	Position of most advanced labelled cells at time B and % of tubule x-sections labelled	Time interval between A and B (days)	Number of Cycles Traversed	Calculated duration of one cycle (days)	
zygotene stage VII, 50%	pachytene stage I, 10%	3.12	0.166	18.80	
	pachytene stage I, 50%	3.12	0.226	13.81	
	pachytene stage III, 20%	4.08	0.391	10.43	
	pachytene stage IV, 70%	8.24	0.647	12.73	
	pachytene stage IV, 90%	8.24	0.696	11.84	
	pachytene stage IV, 100% (x2)‡	9.12	0.721	12.65	
	pachytene stage V, 70% (x2)‡	10.12	0.801	12.63	
	pachytene stage VI, 30%	11.09	0.864	12.84	
	pachytene stage VI, 10%	11.09	0.845	13.12	
	pachytene stage VI, 50% (x2)‡	12.12	0.884	13.71	
zygotene stage VII, 20%	round spermatid stage IV, 80%	22.08	1.672	13.21	
	pachytene stage I, 10%	3.12	0.206	15.15	
	pachytene stage I, 50%	3.12	0.266	11.73	
	pachytene stage III, 20%	4.08	0.434	9.40	
	pachytene stage IV, 70%	8.24	0.688	11.98	
	pachytene stage IV, 90%	8.24	0.737	11.18	
	pachytene stage IV, 100% (x2)‡	9.12	0.761	11.98	
	pachytene stage V, 70% (x2)‡	10.12	0.841	12.03	
	pachytene stage VI, 30%	11.09	0.905	12.25	
	pachytene stage VI, 10%	11.09	0.885	12.53	
pachytene stage I, 10%	pachytene stage VI, 50% (x2)‡	12.12	0.924	13.12	
	round spermatid stage IV, 80%	22.08	1.712	12.90	
	pachytene stage IV, 70%	5.12	0.481	10.64	
	pachytene stage IV, 90%	5.12	0.530	9.66	
	pachytene stage IV, 100% (x2)‡	6.00	0.555	10.81	
	pachytene stage V, 70% (x2)‡	7.00	0.635	11.02	
	pachytene stage VI, 30%	7.97	0.710	11.23	
	pachytene stage VI, 10%	7.97	0.683	11.68	
	pachytene stage VI, 50% (x2)‡	9.00	0.718	12.53	
	round spermatid stage IV, 80%	18.96	1.506	12.59	
pachytene stage I, 50%	pachytene stage IV, 70%	5.12	0.422	12.13	
	pachytene stage IV, 90%	5.12	0.471	10.87	
	pachytene stage IV, 100% (x2)‡	6.00	0.495	12.12	
	pachytene stage V, 70% (x2)‡	7.00	0.575	12.17	
	pachytene stage VI, 30%	7.97	0.650	12.26	
	pachytene stage VI, 10%	7.97	0.623	12.80	
	pachytene stage VI, 50% (x2)‡	9.00	0.658	13.68	
	round spermatid stage IV, 80%	18.96	1.446	13.11	
	pachytene stage III, 20% (x2)‡	pachytene stage IV, 70%	4.16	0.256	16.24
		pachytene stage IV, 90%	4.16	0.305	13.64
pachytene stage IV, 100% (x2)‡		5.04	0.330	15.27	
pachytene stage V, 70% (x2)‡		6.04	0.410	14.73	
pachytene stage VI, 30%		7.01	0.473	14.82	
pachytene stage VI, 10%		7.01	0.454	15.44	
pachytene stage VI, 50% (x2)‡		8.04	0.493	16.31	
round spermatid stage IV, 80%		18.00	1.281	14.15	

Table 5.4 continued
Estimates of the Duration of the Cycle of the Seminiferous Epithelium in the Hopping Mouse, *Notomys alexis*, based on Intermediate Points of Labelling with ³H-thymidine

Position of most advanced labelled cells at time A and % of tubule x-sections labelled	Position of most advanced labelled cells at time B and % of tubule x-sections labelled	Time interval between A and B (days)	Number of Cycles Traversed	Calculated duration of one cycle (days)
pachytene stage IV, 70%	pachytene stage VI, 30%	2.85	0.217	13.13
	pachytene stage VI, 10%	2.85	0.197	14.47
	pachytene stage VI, 50% (x2)‡	3.85	0.237	16.24
	round spermatid stage IV, 80%	13.84	1.025	13.50
pachytene stage IV, 90%	pachytene stage VI, 30%	2.85	0.168	16.96
	pachytene stage VI, 10%	2.85	0.148	19.26
	pachytene stage VI, 50% (x2)‡	3.85	0.188	20.48
	round spermatid stage IV, 80%	13.84	0.976	14.18
pachytene stage IV, 100% (x2)‡	round spermatid stage IV, 80%	12.96	0.951	13.63
pachytene stage V, 70% (x2)‡	round spermatid stage IV, 80%	11.96	0.638	18.75
pachytene stage VI, 10%	round spermatid stage IV, 80%	10.99	0.827	13.29
pachytene stage VI, 30%	round spermatid stage IV, 80%	10.99	0.808	13.60
pachytene stage VI, 50% (x2)‡	round spermatid stage IV, 80%	9.96	0.788	12.64

‡ (x2) indicates that the position of the most advanced labelled cells was observed in two different animals.

5.3.2 Duration of the Cycle Stages and Life Span of Spermatogenic Cell Types

Plains Rat

Knowing the duration of the cycle of the seminiferous epithelium to be on average 11.16 days in the plains rat, it was then possible calculate the duration of each of the 11 stages from their relative frequencies (Table 5.5). The life span of spermatocytes and spermatids was also calculated from their occurrence in the different cycle stages. The life span of primary spermatocytes was 17.9 days (approximately 1.6 cycles), while that of secondary spermatocytes was less than 0.7 days. Spermatids with round nuclei had a life span of 7.0 days and those with elongated nuclei 10.8 days. Thus, spermiogenesis in this species takes approximately 17.8 days.

Table 5.5
Frequency (mean \pm S.D.) and Duration of the Stages of the Cycle of the Seminiferous Epithelium in the Plains Rat, *Pseudomys australis*.

Stage	I	II	III	IV	V	VI	VII	VIII	IX	X	XI	Total
Frequency (%)	18.60	5.01	7.60	5.6	15.72	6.68	6.50	7.95	11.17	8.90	6.19	100
	\pm 3.49	\pm 2.44	\pm 1.95	\pm 2.51	\pm 4.54	\pm 2.21	\pm 2.26	\pm 3.06	\pm 3.08	\pm 3.36	\pm 4.40	
Duration (days)*	2.08	0.56	0.85	0.62	1.75	0.75	0.73	0.89	1.25	0.99	0.69	11.16

* Duration of stages is based on a mean cycle duration of 11.16 days.

Hopping Mouse

The duration of each of the 8 stages of the cycle of the seminiferous epithelium, as calculated from their relative frequencies, is presented in Table 5.6. Primary spermatocytes had an estimated life span of 24.4 days (approximately 1.7 cycles), secondary spermatocytes 1.2 days, round spermatids 10.3 days and elongated spermatids 12.6 days. Spermiogenesis was estimated to take about 22.9 days.

Table 5.6
Frequency (mean \pm S.D.) and Duration of the Stages of the Cycle of the Seminiferous Epithelium in the Hopping Mouse, *Notomys alexis*.

Stage	I	II	III	IV	V	VI	VII	VIII	Total
Frequency (%)	14.95	6.95	10.57	24.51	11.41	9.75	13.53	8.32	100
	\pm 2.73	\pm 1.72	\pm 2.98	\pm 4.21	\pm 3.10	\pm 2.22	\pm 4.06	\pm 1.87	
Duration (days)*	2.10	0.98	1.48	3.44	1.60	1.37	1.90	1.17	14.04

* Duration of stages is based on a mean cycle duration of 14.04 days.

5.4 Discussion

5.4.1 Cycle Duration

Results of the present study indicate that the duration of the cycle of the seminiferous epithelium in the hopping mouse ($14.04 \pm \text{S.D. } 3.44$ days) is considerably longer and more variable than that of the plains rat ($11.16 \pm \text{S.D. } 1.57$ days). In most other rodent species for which data are available, the spermatogenic cycle generally takes between eight and 13 days (see Table 1.1, page 36), although it ranges in length from 6.7 days in the bank vole (Grocock and Clarke, 1976) to 17 days in the Chinese hamster (Oud and de Rooij, 1977). Hence, in the plains rat the cycle duration is typical of that recorded for rodents, including common laboratory murid species, but for the hopping mouse it is somewhat longer. In fact, the only mammalian species for which the duration of the cycle of the seminiferous epithelium is longer than the hopping mouse are the Chinese hamster (Oud and de Rooij, 1977), human (Heller and Clermont, 1963, 1964), grey-headed fruit bat (McGuckin and Blackshaw, 1987) and several species of marsupials (Setchell and Carrick, 1973; Queiroz and Nogueira, 1992).

In the present study, calculation of cycle duration was based on the progression, in a given time interval, of labelled cells from point A to point B, as determined using pairs of different animals. This method assumes that the label is incorporated at the same point in time and progresses at the same rate in all of the animals used in the comparisons. Such an assumption, however, may not necessarily be correct and could provide a potential source of error in calculations. In the present study, estimates of cycle duration of the plains rat consistently ranged from 8.6 to 12.7 days and those of the hopping mouse were even more variable, ranging from around 10 days to 16 days, depending on the particular combinations of animals used. Previous studies of other species using the same methods of calculation as the present study have not reported the same degree of variability in estimated cycle length (Swierstra and Foote, 1965; Swierstra *et al.*, 1974; Rosiepen *et al.*, 1994). These studies may, however, have selected time intervals where the exact position of the most advanced labelled cells was easily identifiable (eg. intervals may have been chosen such that the position of the most advanced labelled cells correspond to a cycle stage of short duration). In the present study, the location of the label front was not readily predictable, due to a paucity of kinetic data for these species and hence many different time intervals were used in calculations of cycle duration.

The degree of intraspecific variability in the duration of the cycle of the seminiferous epithelium has been investigated in some detail in laboratory (Sprague-Dawley strain) and feral (Brown/Norway) rats (Rosiepen *et al.*, 1994). In this study, it was found that the

length of the spermatogenic cycle is remarkably constant and similar in intact laboratory rats (12.49 ± 0.05 days, $n = 13$, mean \pm SEM) and feral rats (12.44 ± 0.06 days, $n = 8$). Similar cycle durations (laboratory: 12.54 ± 0.02 days, $n = 9$, mean \pm SEM; feral: 12.48 ± 0.02 days, $n = 4$) were also obtained for groups of hemicastrate rats, where one testis of each animal was removed one hour post-labelling and acted as the reference point for calculations of the duration of the spermatogenic cycle in that animal. It was found that, for these groups of hemicastrate animals, the coefficient of variation of the estimated cycle duration was three times lower than for the groups of intact animals (Rosiepen *et al.*, 1994). These data suggest therefore, that a more accurate estimation of cycle duration for a species is obtainable if each animal acts as its own reference point for the progression of the label in a known time interval. Thus, variation in the cycle duration within a species, generated through the comparison of labelling positions in two different animals, can be eliminated.

For both species of Australian rodents, it was found that the progression of the labelled germ cells within a given time interval following label administration varied between animals, i.e. the most advanced labelled cell types of animals sacrificed at identical times following ^3H -thymidine administration were different. In the two plains rats sacrificed one hour post ^3H -thymidine injection, the most advanced labelled cells were preleptotene primary spermatocytes at the end of stage V and leptotene primary spermatocytes at the beginning of stage VI of the cycle respectively. Seven days 1 hour following ^3H -thymidine injection the most advanced labelled cells in two different plains rats were pachytene primary spermatocytes of late stage III and mid stage IV respectively, while at 13 days 1 hour, the label front in three plains rats had progressed to pachytene primary spermatocytes of early, mid and late stage VIII respectively. Similarly, in the hopping mouse, labelling had progressed to differing positions within the cycle in pairs of animals killed at 7 days 1 hour, 12 days 3.83 hours and 15 days 0.33 hours following ^3H -thymidine administration (Table 5.2). These findings suggest that, in both species, the rate of development of germ cells during spermatogenesis varies between animals, resulting in intraspecific variability in the duration of the spermatogenic cycle. Alternatively, individual animals might differ in their ability to deliver and/or incorporate the label into germ cells replicating their DNA. Further investigations are required to determine which of these scenarios is more likely and data from greater numbers of animals per time interval should be analysed. Nevertheless, the suggestion that slight differences in the rate of development of germ cells between animals is responsible for intraspecific variability in cycle duration in the plains rat and hopping mouse is supported by the occurrence of considerable inter-animal variation in stage frequencies as reported in Chapter 4 of this thesis.

The amount of intraspecific variability in the duration of the spermatogenic cycle might be related to the degree of genetic heterogeneity between individuals. Most species of laboratory rodents have undergone extensive inbreeding in order to standardise particular phenotypic traits and hence are presumably relatively homogeneous in their genetic constitution (Berndtson and Thompson, 1990). Likewise, many farm species have been specifically bred to maximise particular characteristics including sperm production and fertility. The plains rats and hopping mice utilised in the present investigation, however, were only a few generations removed from the wild population. Hence, it is possible that the variability in cycle duration in these species may, in part, reflect a greater genetic heterogeneity than either laboratory rodents or domesticated species.

Notwithstanding the above suggestion, the duration of the cycle of the seminiferous epithelium is largely constant between adult individuals of a species (Oakberg, 1956b; Courot *et al.*, 1970; Go *et al.*, 1971; Clermont, 1972) and it is now known from transplantation experiments that the rate of spermatogenesis is regulated by germ cell genotype rather than influences of supporting Sertoli cells (França *et al.*, 1998). Other experimental data indicate that the rate of development of germ cells and hence cycle duration are not influenced by hormone levels (Courot *et al.*, 1970). A similar cycle duration was observed in control animals and animals subjected to hypophysectomy, hypophysectomy coupled with the administration of testosterone or gonadotrophins (Clermont and Harvey, 1965; Go *et al.*, 1971), or unilateral orchidectomy (Noller *et al.*, 1977b). Several studies, however, indicate that spermatogenesis proceeds at a faster rate in pubertal than in sexually mature animals (Clermont and Perey, 1957, Kluin *et al.* 1982; van Haaster and de Rooij, 1993; Miething, 1998). Deceleration in the rate of spermatogenesis to adult values coincided temporally with descent of the testes to the inguinal region, leading to the suggestion that lower temperatures may increase the duration of spermatogenesis (van Haaster and de Rooij, 1993). Further evidence in support of this suggestion was provided by the results of a study on the effects of long-term exposure to increased testicular temperature. In this study, the rate of spermatogenesis was increased by 13% over control values in adult laboratory mice immediately following placement of the testes into the abdominal cavity, ie. experimental cryptorchidism and to a lesser degree in animals housed at elevated temperatures (Meistrich *et al.*, 1973). The only other reports of inter-animal variation in cycle duration of adult animals relate to small differences in cycle length after exposure to toxic chemicals (Chapin *et al.*, 1984; Creasy *et al.*, 1985; Rosiepen *et al.*, 1995). In these situations, however, normal intercellular relationships within the seminiferous epithelium were disrupted by the selective removal of particular germ cell types. Therefore, the suggestion of considerable naturally-occurring interspecific variability in cycle duration in

sexually mature adult animals, such as those used in the present study, appears to be novel.

The possibility that, in the hopping mouse, part of the variability in the duration of the spermatogenic cycle might be due to variations of testicular temperature merits investigation. In this species, the position of the testes varies widely between individuals, ranging from within a perianal swelling, to inguinal and even lower abdominal, hence it is feasible that testes of different individuals are subjected to different temperatures, which may in turn bring about differences in testicular germ cell kinetics.

5.4.2 Life Span of Spermatogenic Cells

The duration of the meiotic phase of spermatogenesis (including the meiotic divisions), as compared to the spermiogenic phase, is generally relatively similar between species of mammals (Courot *et al.*, 1970), although there is no consistent trend within the rodent group. In the laboratory mouse the lengths of the two phases are roughly equal, but in the laboratory rat spermiogenesis takes about five days longer than the meiotic prophase (Russell *et al.*, 1990a). The plains rat is similar to the laboratory mouse in that both phases of spermatogenesis have the same duration (17.9 cf. 17.8 days), but in the hopping mouse spermiogenesis is slightly shorter than meiosis. It was noted previously that there appeared to be a difference in the timing of release of spermatids and of the life span of the round spermatids between the plains rat and hopping mouse (Peirce and Breed, 1987). The present study has shown that the life span of round spermatids in hopping mouse is around three days longer than in the plains rat.

5.4.3 Duration of Spermatogenesis

No exact means of estimating the duration of the entire process of spermatogenesis is possible from the present study, since the scheme of spermatogonial renewal in the plains rat and hopping mouse has not been determined. For mammalian species, several different starting points of spermatogenesis have been suggested. These are:

- a) the cell division giving rise to the stem spermatogonium which initiates the spermatogenic series (Ortavant, 1958 in Courot *et al.*, 1970).
- b) the point in time at which type A spermatogonia undergo the first of the divisions leading to the production of spermatocytes, ie. the first division of differentiating spermatogonia (Clermont, 1972).

Using the latter definition, the starting point of spermatogenesis should coincide with an increase in the number of type A spermatogonia present within a cycle stage. Numbers of

spermatogonia were not counted in the present study, but autoradiographs of plains rat seminiferous tubules 1 hour post ^3H -thymidine administration showed labelled type A spermatogonia in stages V-VI, VII and IX of the spermatogenic cycle. These locations were similar to those in which spermatogonial divisions were observed in plastic-embedded testes of the plains rat. Since the earliest observed division of type A spermatogonia occurs in stage VI of the cycle and since spermiation is also completed during stage VI; spermatogenesis in the plains rat lasts approximately 4 cycles, or about 44.6 days. In the hopping mouse, the earliest point in the cycle in which divisions of type A spermatogonia were noted was stage IV. Spermiation is generally completed late in stage IV or early in stage V. Hence, spermatogenesis in this species is estimated to also take about 4 cycles, or 56.2 days, which is considerably longer than in the plains rat and most other rodent species.

5.5 Summary

The duration of the cycle of the seminiferous epithelium and of spermatogenesis were determined in the plains rat and hopping mouse. In the plains rat, mean cycle duration was 11.16 days, compared to 14.04 days in the hopping mouse. Based on the occurrence of four cycles of the seminiferous epithelium between mitosis of the first of the differentiating spermatogonia and spermiation, spermatogenesis was estimated to take 44.6 days in the plains rat and 56.2 days in the hopping mouse.

Considerable intraspecific variation in the duration of the spermatogenic cycle and the timing of events in spermatogenesis were detected in the hopping mouse and to a lesser extent in the plains rat. This is in contrast to the situation in other species of rodents, where cycle duration between adult individuals within a species is constant (Hochereau, 1963).

Chapter 6 Daily Sperm Production

6.1 Introduction

The Australian hydromyine rodents show considerable diversity in their reproductive anatomy (see section 1.8.2, Chapter 1), with the plains rat and hopping mouse occupying opposite ends of the spectrum with respect to testis size (Breed, 1982a; Peirce and Breed, 1987). In addition, vastly different numbers of spermatozoa have been recovered from the genital duct systems of these species. Approximately $476 \pm 35 \times 10^6$ sperm were found in the epididymides of the plains rat, as compared with only about $1.9 \pm 1.3 \times 10^6$ sperm in the genital ducts of the hopping mouse (Breed, 1982a, 1986; Peirce and Breed, 1987; Breed *et al.*, 1991). In the latter species, up to 50% of total sperm numbers in some individuals were recovered from the vasa deferentia (Peirce and Breed, 1987). The question therefore arises as to what gives rise to the vastly different sperm numbers in the genital ducts of the plains rat and hopping mouse. There are a number of possible explanations, including:

- a) Differences in sperm numbers merely reflect differences in testis size between the two species, ie. the greater number of sperm in the caudæ epididymides of the plains rat results from the larger testes (and hence greater amount of spermatogenic tissue) in this species as compared with the hopping mouse.
- b) Differences in sperm numbers relate to different abilities of the testes of the two species to produce spermatozoa, ie. the seminiferous epithelium of plains rats is more efficient in producing sperm.
- c) Differences in sperm numbers relate to different abilities of the cauda epididymides (and vasa deferentia in the hopping mouse) to store spermatozoa, ie. the excurrent ducts of the hopping mouse are less capable of storing sperm produced by the testes. In the ram it was found that storage efficiency of the caudæ epididymides increases with age and it was suggested that this was related to an improved contractile mechanism in older as compared with younger rams (Abdou *et al.*, 1978).
- d) Differences in epididymal sperm numbers relate to a combination of some or all of the above factors.

In this chapter, the influences of testis size and the efficiency of sperm production on sperm numbers will be investigated by determining DSP and DSP/g testis (Amann, 1970b, Johnson, 1986b) for each species. Determination of DSP/g testis allows a direct comparison of spermatogenic efficiency between species as it nullifies differences in sperm numbers resulting primarily from differences in the size of their testes. The third possibility, that differences in epididymal sperm numbers reflect variable storage capacity

of the epididymides, will be addressed in Chapter 8 of this thesis.

6.2 Materials and Methods

Sperm production was determined via the testicular homogenisation method. This method utilises the fact that at some point during spermiogenesis, the nuclei of elongated spermatids become resistant to physical destruction and hence can be enumerated in testicular homogenates by haemocytometric techniques (Amann, 1970a). Following determination of a time divisor, which is the number of day's production represented by the homogenisation-resistant spermatid nuclei (Almquist and Amann, 1961), daily sperm production per animal and daily sperm production per gram of testicular tissue were estimated.

6.2.1 Determination of the Time Divisor

In order to determine the stages of the cycle of the seminiferous epithelium represented by spermatids resistant to homogenisation, comparisons were made of sections and homogenates of testes taken from the same individuals following incorporation of ^3H -thymidine into the DNA of germ cells and subsequent autoradiographic visualisation (Orgebin-Crist, 1968). Sexually mature plains rats and hopping mice ($n=5$ per species) were given a single intraperitoneal injection of ^3H -thymidine at a dose rate of $2 \mu\text{Ci/g}$ body weight. One plains rat and one hopping mouse were sacrificed at each of 31 days, 31 days 17 hours, 32 days 12 hours, 35 days, 5 hours and 37 days following ^3H -thymidine injection. These times were estimated to correspond to the intervals required for the cells initially incorporating the ^3H -thymidine into their DNA to advance through the cycle of the seminiferous epithelium and become the elongated spermatids of the various stages, as based on a cycle duration of approximately 14 days¹.

Following sacrifice, the testes of each animal were removed and weighed. One testis was fixed in 3% paraformaldehyde/3% glutaraldehyde fixative, processed for embedding in paraffin and $5 \mu\text{m}$ sections were cut and mounted on glass slides. The other testis was homogenised in 10-50 ml of fluid containing 150mM NaCl, 0.05% (vol./vol.) Triton X-100 and 3.8mM NaN_3 (Amann and Lambiase, 1969) for two minutes using an Ultra-turrax TP18-10 blender. Aliquots of the homogenate were smeared onto clean microscope slides

¹ Estimations of the time divisor and duration of the cycle of the seminiferous epithelium were carried out at the same time. Consequently the time intervals at which it was hoped that elongated spermatids would be labelled were based on a preliminary estimate of a cycle duration of 14 days in both species. While this estimate was subsequently found to be accurate for the hopping mouse, in the plains rat cycle duration was found to be 11.16 days. Nevertheless, labelling of elongated spermatids at various stages of the cycle of the seminiferous epithelium was observed in plains rat testes at the times intervals used.

and allowed to air dry. Smears were subsequently fixed in a 1:1 solution of ether:ethanol for 30 minutes. Slides of both the tissue sections and homogenate smears were coated for autoradiography, using the same batch of liquid emulsion for all slides, as described in Chapter 5. Following development and staining with haematoxylin only (homogenate smears) or haematoxylin and eosin (testis sections), sections and smears of the same individuals were compared to determine which spermatid populations were resistant to homogenisation. The time divisor was calculated as being the sum of the relative duration's of the cycle stages as seen in tissue sections, which corresponded to the labelled resistant spermatid nuclei in testicular homogenates taken from the same animal, multiplied by the duration of one cycle of the seminiferous epithelium.

6.2.2 Determination of Sperm Production

Determinations of sperm production were obtained from 12 sexually mature plains rats and 18 sexually mature hopping mice, aged between three and 10 months². Animals were sacrificed via pentobarbitone sodium (Nembutal) overdose or carbon dioxide asphyxiation and body weights were recorded. Testes were removed, weighed and one or both were subsequently homogenised in 10-50 ml of fluid containing 150mM NaCl, 0.05% (vol./vol.) Triton X-100 and 3.8mM NaN₃ (Amann and Lambiase, 1969) for two minutes using an Ultra-turrax TP18-10 blender. Elongated spermatid nuclei that were resistant to the homogenisation process were counted in 10 haemocytometer chambers each of 0.1 mm³ volume and an average count per volume was determined. The number of spermatid nuclei per testis sample was calculated as the average haemocytometer count, multiplied by the total homogenate volume and any dilution factor of the original homogenate volume prior to counting. Sperm production per gram of testis was determined by dividing the total sperm count in the homogenate by the weight of the testicular tissue homogenised. Spermatid counts per animal, or per gram of testicular tissue were converted to daily sperm production per animal, or per gram of testicular tissue by dividing by a time divisor of 4.44 days for the plains rat and 6.95 days for the hopping mouse (see section 6.3.1 for the derivation of these values).

² Animals include the five plains rats and five hopping mice used in determining the time divisors. Samples of the testicular homogenates from each animal were counted as described.

6.3 Results

6.3.1 Time Divisor

In the plains rat, spermatid nuclei resistant to testicular homogenisation were observed to correspond to the elongated spermatids of stages II to VI of the cycle of the seminiferous epithelium. The relative duration of these stages (from Table 4.2, Chapter 4) is $5.01 + 7.60 + 5.67 + 15.72 + 6.68 = 39.78\%$ of one cycle of the seminiferous epithelium. Since one cycle has a duration of 11.16 days (Chapter 5), the total duration of stages II to VI is $0.3978 \times 11.16 = 4.44$ days. Hence the spermatid nuclei resistant to homogenisation in the plains rat represent 4.44 day's production of spermatozoa.

In the hopping mouse, spermatid nuclei resistant to testicular homogenisation corresponded to the elongated spermatids of stages I to IV of the cycle of the seminiferous epithelium. However, while in tissue sections approximately 50% of the elongated spermatids in stage I did not show labelling with ^3H -thymidine, no unlabelled spermatid nuclei were observed in the corresponding testicular homogenate. This suggests that not all stage I elongated spermatids are resistant to homogenisation. The time divisor was therefore estimated to correspond to the duration of stages II to IV plus 50% of the duration of stage I, ie. $6.95 + 10.57 + 24.51 + [0.5 \times 14.95]$, or a total of 49.51% of the duration of one cycle of the seminiferous epithelium (see Table 4.3, Chapter 4). Based on a cycle duration of 14.04 days (Chapter 5) in the hopping mouse, the time divisor was hence estimated to be 6.95 days.

6.3.2 Numbers of Spermatids per Animal and Daily Sperm Production

The number of spermatids resistant to homogenisation in both testes of individual plains rats ranged from 52 to 241×10^6 ($177.6 \pm 51.0 \times 10^6$, mean \pm S.D., Table 6.1). This represented a daily sperm production per animal of between 11.7 and 54.3×10^6 , giving an average production of $40.0 \pm 11.5 \times 10^6$ sperm per animal per day. Daily sperm production per gram of testicular tissue ranged from 7.1 to 34.6×10^6 , however, only one of the 17 animals for which data were collected produced less than 21×10^6 sperm per gram of testis per day. Mean DSP/g testis was $25.7 \pm 6.5 \times 10^6$ (mean \pm S.D.) and the average weight of the paired testes of plains rats was 1.57 ± 0.26 grams (mean \pm S.D., Table 6.1).

In the hopping mouse, paired testis weight ranged from 28.9 to 80.0 mg and averaged 51.5 ± 16.5 mg (mean \pm S.D.; Table 5.2). The number of spermatids resistant to testicular homogenisation ranged from 1.5 to 7.4×10^6 ($3.89 \pm 1.46 \times 10^6$, mean \pm S.D.), representing a mean daily sperm production per animal of $0.51 \pm 0.24 \times 10^6$ (range 0.24 to

1.06×10^6 , Table 6.2). Only two animals of the 18 for which data were collected produced more than one million sperm per day. Daily sperm production per gram of testis averaged $9.8 \pm 2.4 \times 10^6$ (mean \pm S.D., range 7.2 to 16.4×10^6 , Table 6.2). Based on these data, individual hopping mice produce, on average, around 75 times fewer spermatozoa per day than plains rats (0.51×10^6 vs 40.1×10^6) and spermatogenic efficiency of the plains rat testis is about 2.6 times that of the hopping mouse testis ($25.7 \pm 6.5 \times 10^6$ vs $9.8 \pm 2.4 \times 10^6$, mean \pm S.D.).

Table 6.1
Paired Testes Weight, Spermatid Numbers, Daily Sperm Production per Animal
and Daily Sperm Production per Gram of Testicular Tissue in the Plains Rat,
Pseudomys australis.*
 (n = 17)

Paired Testes Weight (g)	No. of Spermatids/ Testes ($\times 10^6$)	DSP/Animal ($\times 10^6$)	DSP/g Testis ($\times 10^6$)
1.64	52.0	11.7	7.1
1.97	218.0	49.1	24.9
1.96	207.0	46.6	23.8
1.06	101.0	22.7	21.5
1.66	209.2	47.1	28.4
1.58	182.9	41.2	26.1
1.80	203.4	45.8	25.5
1.68	194.6	43.8	26.1
1.87	175.4	39.5	21.1
1.47	209.4	47.2	32.1
1.21	149.8	33.7	27.9
1.44	136.3	30.7	21.3
1.56	236.9	53.4	34.2
1.57	241.0	54.3	34.6
1.43	214.0	48.2	33.7
1.53	167.0	37.6	24.6
1.18	122.0	27.5	23.3
1.57 ± 0.26 (mean \pm S.D.)	177.6 ± 51.0 (mean \pm S.D.)	40.1 ± 11.5 (mean \pm S.D.)	25.7 ± 6.5 (mean \pm S.D.)

* Calculations of daily sperm production used a time divisor of 4.44 days (see text).

Table 6.2
Paired Testes Weight, Spermatid Numbers, Daily Sperm Production per Animal
and Daily Sperm Production per Gram of Testicular Tissue in the Hopping Mouse,
Notomys alexis.*

(n = 18)

Paired Testes Weight (mg)	No. of Spermatids/ Testes (x 10 ⁶)	DSP/Animal (x 10 ⁶)	DSP/g Testis (x 10 ⁶)
62.4	7.10	1.02	16.4
36.9	2.36	0.34	9.2
23.4	1.76	0.25	10.8
37.0	2.16	0.31	8.4
40.9	2.76	0.40	9.7
28.9	1.50	0.22	7.5
59.9	3.94	0.57	9.5
58.9	2.96	0.42	7.2
49.1	2.93	0.42	8.7
33.7	1.79	0.26	7.6
66.0	4.19	0.60	9.1
40.7	2.45	0.35	8.7
47.0	4.08	0.59	12.5
72.0	4.26	0.61	8.5
80.0	5.46	0.79	9.8
57.0	3.46	0.50	8.7
57.2	3.80	0.55	9.6
75.6	7.40	1.06	14.1
51.5 ± 16.5 (mean ± S.D.)	3.58 ± 1.70 (mean ± S.D.)	0.51 ± 0.24 (mean ± S.D.)	9.8 ± 2.4 (mean ± S.D.)

* Calculations of daily sperm production used a time divisor of 6.95 days (see text).

6.4 Discussion

Relatively few data are available on sperm production in rodents, apart for the laboratory rat (Robb *et al.*, 1978; Johnson *et al.*, 1980a, Johnson and Neaves, 1983; Johnson, 1986b) and hamster (Amann 1981). Most studies have focused on sperm production in the rabbit (Amann and Lambiase, 1969; Amann, 1970b), humans (Amann and Howards, 1980; Johnson *et al.*, 1980a, 1980b; Amann, 1981; Johnson *et al.*, 1986; Johnson and Neaves, 1986) and domesticated farm species including the bull (Amann, 1962; Amann and Almquist, 1962; Amann *et al.*, 1974), boar (Swierstra, 1968b, 1971; Okwun *et al.*, 1996), ram (Ortavant, 1959; Amann *et al.*, 1976; Amann, 1981) and stallion (Gebauer *et al.*, 1974; Johnson *et al.*, 1994; Blanchard and Johnson, 1997a). The available sperm production data for mammalian species are presented in Table 6.3. Measurement of sperm production in the plains rat and hopping mouse, therefore, adds to the available data pool for rodents, which at the present time is small.

Table 6.3
Daily Sperm Production in Mammals*

Species	Paired Testes Weight (g)	Daily Sperm Production		Reference
		by both testes ($\times 10^9$)	per gram of testis ($\times 10^6$)	
<u>Laboratory Rat</u>				
- Sprague-Dawley	3.5	0.071	21.1	Johnson <i>et al.</i> (1980a)
	3.5	0.067	20.5	Johnson and Neaves (1983)
- Wistar	3.7	0.086	23.7	Robb <i>et al.</i> (1978)
	3.2	0.082	25.0	Johnson (1986b)
<u>Hamster</u>	3.0	0.074	24	Amann <i>et al.</i> (1976); Amann (1981)
<u>Rabbit</u>				
	2.8	0.015	26.5	Orgebin-Crist (1968)
	4.9	0.785	48.6	Amann and Lambiase (1969)
	6.2	0.239	40	Amann (1970)
	6.4	0.160	25	Amann (1981)
<u>Bull</u>				
- dairy	748	13.1	17.5	Almquist and Amann (1961)
	672	11.49	17.1	Amann and Almquist (1962)
	725	7.5	12	Amann <i>et al.</i> (1976)
- Shorthorn	359	5.3	16.9	Swierstra (1966)
- Holstein	300	3.4	11.5	Amann <i>et al.</i> (1974)
- Hereford	650	5.9	10	Amann (1981)
- Charolais	775	8.9	13	Amann (1981)
<u>Boar</u>				
	720	16.2	23	Amann (1981)
- Yorkshire	698	16.5	25.1	Swierstra (1968, 1971)
- Lacombe	780	17.8	24.3	Swierstra (1968, 1971)
- Whitecross	498	12.5	24.8	Okwun <i>et al.</i> (1996)
- Meishan	247	6.0	24.5	Okwun <i>et al.</i> (1996)
- West African	133	2.6	21.7	Okwun <i>et al.</i> (1996)
<u>Stallion</u>				
	430	7.8-8.1	19.3-22.3	Gebauer <i>et al.</i> (1974)
	340	5.3	16	Amann <i>et al.</i> (1976); Amann (1981)
	300	3.4	19	Johnson (1986b)
	210-432	2.36-4.24	10.8-19.1	Blanchard and Johnson (1997b)
<u>Ram</u>				
	450	5.5	12.2	Ortavant (1959)
	500	9.5	21	Amann <i>et al.</i> (1976); Amann (1981)
<u>Buffalo</u>				
	277	4.0	14	Amann (1981)
<u>Dog</u>				
	38	0.037-0.059	11.7-16.7	Olar <i>et al.</i> (1983)
<u>Rhesus monkey</u>				
	49	1.1	23	Amann <i>et al.</i> (1976), Amann (1981)
<u>Human</u>				
	32.2	0.045-0.207	4.3	Amann and Howards (1980)
	33.2	0.091	3.1	Johnson <i>et al.</i> (1980a)
	36.4	0.053	1.6	Johnson <i>et al.</i> (1980b)
	34	0.125	4.4	Amann (1981)
	41.2	0.239	5.8	Johnson <i>et al.</i> (1983)
	40-44	0.160-0.242	4.6-6.2	Johnson <i>et al.</i> (1984a)
	38-47	0.121-0.250	3.8-6.0	Johnson <i>et al.</i> (1986)
	32	0.192	6.0	Johnson (1986b)
	36.9	0.086	5.5	Johnson and Varner (1988)

* Data taken from the literature as indicated. Calculations of DSP were based on either, the enumeration of resistant spermatids in testicular homogenates, or quantitative testicular histology.

Measurements of sperm production are normally based on cell counts within testicular homogenates, or histological sections, although indirect methods such as estimating production based on daily sperm output (DSO) have also been used, particularly for domesticated farm species (see Amann, 1970a; Berndtson, 1977). The usual parameters of sperm production include the number of spermatids per testis or per gram of testicular tissue, daily sperm production (DSP) per testis or per animal and daily sperm production per gram of testicular tissue. Apart from DSP/g testis, these parameters do not allow direct comparison of spermatogenic efficiency between species because they do not acknowledge the contributions to sperm number of differences in absolute testis size, or in the number of days' production of spermatids represented within a particular sample. The influences of variations in the duration of spermatogenesis, the life span of spermatogenic cell types and the ability of particular cell types to withstand investigative procedures also need to be considered when determining sperm production. Hence, caution must be applied when comparing sperm production data across species or from different studies. For example, a greater sperm number within a sample from an individual of one species, compared with that of a second individual of another species may merely reflect a quicker rate of production from a larger bulk of tissue in the first sample, rather than any biological difference in absolute spermatogenic efficiency.

In the present study, sperm production was expressed as daily sperm production per gram of testicular tissue. DSP/g testis can be regarded as an indicator of the efficiency of spermatogenesis, since to a large extent, the influence of differences in testis size on the numbers of spermatozoa produced by different species or individuals is negated. In the plains rat, a DSP/g testis of $25.7 \pm 6.5 \times 10^6$ sperm (mean \pm S.D.) was comparable with data from most other mammalian species studied to date, but was about two and a half times that of the hopping mouse ($9.8 \pm 2.4 \times 10^6$, mean \pm S.D.) and up to seven times that of humans (see Table 6.3), who are regarded as having a low efficiency of sperm production (Amann and Howards, 1980; Johnson *et al.*, 1980a). While these values take into account absolute differences in testis size between the plains rat and hopping mouse, differences in the relative composition of testes between species, must also be considered if an accurate indication of spermatogenic efficiency is to be achieved. In the plains rat, approximately 94% of total testicular volume is comprised of the seminiferous tubules in which spermatogenesis occurs, compared with around 85% in the hopping mouse (Peirce and Breed, 1987). Hence in the hopping mouse, there is a somewhat smaller percentage of the total testicular parenchyma contributing to the production of spermatozoa. If the species difference in the proportion of seminiferous tubular tissue between plains rat and hopping mouse testes is taken into account when estimating spermatogenic efficiency, then DSP/g seminiferous tubule in the plains rat is 27.4×10^6 sperm, compared with 11.6×10^6 in the

hopping mouse³, making the plains rat about twice as efficient at producing sperm as the hopping mouse. These latter values, however, still do not take into account possible species differences in the proportion of the seminiferous tubules occupied by the developing germ cells as opposed to Sertoli cells, peritubular tissue and the tubular lumen.

Two methods are commonly used to determine DSP/g testis, enumeration of spermatid nuclei in testicular homogenates and quantitation of various spermatogenic cell types in histological sections of the testis (Amann, 1970a; Berndtson, 1977). These methods gave comparable values of DSP/g testis in the rat, but in humans, a DSP/g testis value almost three times greater was found using the histometric as opposed to the homogenisation method (Johnson *et al.*, 1980a). Furthermore, no overlap of DSP values was observed between the two methods, suggesting that some type of systematic bias towards artificially high or low estimations, may occur from using one of the two methodologies (Johnson *et al.*, 1980a). One possible source of error in estimating DSP using the homogenisation method relates to determination of the time divisor, i.e., the number of day's production of spermatozoa represented by the resistant spermatids in the homogenate.

It has generally been assumed that spermatids resistant to the homogenisation process are the elongated spermatids with a shape characteristic of the mature spermatozoon, which occur in the several stages of the cycle of the seminiferous epithelium immediately prior to spermiation (Amann, 1970a, 1981; Berndtson 1977). Concern has been expressed, however, that the spermatids that are resistant to homogenisation may vary from species to species (Amann, 1970a). Therefore in the present study, pulse labelling with ³H-thymidine was used to determine the stages of the cycle of the seminiferous epithelium that contained elongated spermatids resistant to homogenisation. Labelling of elongated spermatids in tissue sections was matched with labelling of resistant spermatid nuclei in testicular homogenates from the same animal (Orgebin-Crist, 1968). This enabled an accurate estimation of the number of days' production represented by the labelled, resistant spermatids in the homogenate. In the plains rat, spermatids resistant to homogenisation were those of stages II-VI which comprised 39.78% of one cycle of the seminiferous epithelium. As calculated in Chapter 5, one cycle of the seminiferous epithelium in the plains rat lasts for 11.16 days, hence resistant spermatids represented 4.44 day's production of spermatozoa. This value for the time divisor was considerably shorter than a previously estimated value of 7.83 days, used to determine DSP/g testis in an earlier study of sperm numbers in the plains rat (Breed *et al.*, 1991). The shorter time divisor in the present study resulted not only from a shorter length of the cycle of the seminiferous

³ Values were determined by dividing the average DSP per gram testis for each species by the relative proportion of the testes occupied by the seminiferous tubules, i.e., plains rat 25.8×10^6 divided by 0.94 = 27.4×10^6 sperm per gram of seminiferous tubule, hopping mouse 9.9×10^6 divided by 0.85 = 11.6×10^6 sperm per gram of seminiferous tubule.

epithelium (11.16 days, Chapter 4 cf. 12.1 days, Breed *et al.*, 1991), but also from a different system of classification of the stages of the cycle of the seminiferous epithelium (Chapter 3) to that previously used (see Peirce and Breed, 1987). Hence, in the present study, the point at which spermatids became resistant to testicular homogenisation was identified with a greater degree of accuracy, due to the spermatogenic cycle being divided into a greater number of stages (Chapter 3) of relatively shorter duration (Chapter 4).

In the hopping mouse, variable nuclear condensation was noted in the elongated spermatids of some cycle stages, particularly stages VII, VIII and, to a lesser extent, stage I. In humans, it has been suggested that spermatids with less condensed nuclei may not be resistant to homogenisation and consequently the time divisor used to determine DSP values may be an over estimation of the number of days' production represented by the resistant spermatids (Johnson *et al.*, 1981; Amann, 1981), thereby contributing to a low efficiency of sperm production. From pulse labelling of hopping mouse elongated spermatids in the present study, it appears that regardless of their degree of nuclear condensation, no elongated spermatids of stages VII and VIII and only about 50% of stage I spermatids are resistant to homogenisation. Hence spermatids that are resistant to homogenisation in the hopping mouse are predominantly those of stages II, III and IV, along with late stage I, of the spermatogenic cycle and represent 6.95 day's production of spermatozoa. The longer time divisor in the hopping mouse, compared with the plains rat, reflects in part, the longer duration of the cycle of the seminiferous epithelium in this species (14.04 days cf. 11.16 days). In addition, estimation of the time divisor in the hopping mouse may not be as accurate as that of the plains rat, due to the spermatogenic cycle being divided into fewer cellular associations of relatively longer duration in the former species. A more sensitive classification system, however, could not be used because of the high degree of variability in composition of cellular associations in the hopping mouse (see Chapter 3).

The homogenisation method of determining DSP/g testis provides no insight into possible reasons for the lower efficiency of sperm production in the hopping mouse, compared with the plains rat and most other species. Correlations between the efficiency of sperm production and tissue features have, however, been uncovered by histometric investigations of the testes, ie. quantitation of cell types and tissue volumes from analysis of tissue sections (Amann 1970a). In humans, a low efficiency of spermatogenesis was associated with missing generations of spermatocytes and spermatids within the seminiferous epithelium and a lower number of spermatocytes and spermatids within a cellular association (Johnson *et al.*, 1992). Furthermore, with increasing age, a decrease in absolute spermatogenic efficiency per individual and per gram of testis was found to be linked to a decline in the total volume of seminiferous tubules (Johnson *et al.*, 1986;

Johnson, 1986b) and an increase in the thickness of tubular boundary tissue (Johnson *et al.*, 1986). Similar morphometric investigations of germ cell numbers and tissue proportions in the plains rat and hopping mouse are required to provide some indication of the possible causes of differences in the efficiency of sperm production in these species.

Classical histometric methods for determining spermatogenic efficiency are, however, much more time intensive than testicular homogenisation and are subject to their own inaccuracies, eg. there is no accurate way to correct for volumes of irregularly shaped cells such as elongated spermatids (Berndtson, 1977; Amann, 1981). Calculations using less mature germ cells such as spermatocytes or to a lesser extent round spermatids, may overestimate sperm production if degeneration of more mature germ cell types occurs before spermatogenesis is completed (Berndtson, 1977; Amann, 1981; Johnson, 1985). Studies have found a reduction in spermatocyte numbers during the meiotic divisions (Barr *et al.*, 1971) and degeneration of spermatids in humans (Zuckerman *et al.*, 1978) and other mammalian species, particularly during nuclear elongation, has been noted (Courot *et al.*, 1970). In the hopping mouse, degenerating germ cells have been observed at all stages of spermatogenesis, including at various points during the process of spermatid elongation (unpublished observations), although the extent of this cell loss has not been quantified.

Recently, optical dissection of tissue sections has provided a relatively rapid means of accurately quantifying irregularly shaped cells such as elongate spermatids (Wreford, 1995). Using this approach, numerical densities and absolute numbers of various germ and Sertoli cells per testis were determined in laboratory rats and monkeys (Simorangkir *et al.*, 1995; Meachem *et al.*, 1996; Zhengwei *et al.*, 1997). The absolute number of elongate spermatids in tissue sections can subsequently be used to calculate DSP/g testis, if testis weight and the life span of the elongate spermatids are known. Preliminary data on the absolute numbers of germ cells and Sertoli cells per testis have now been collected for one plains rat and two hopping mice, using the optical disector method (Peirce and Breed, 1998). Based on these data, DSP/g testis in the plains rat was 27.92×10^6 /g testis/day. This value is similar to the mean DSP/g testis of 25.7×10^6 , as determined by the testicular homogenisation method. Values of DSP/g testis for the two hopping mice were 12.2×10^6 and 21.4×10^6 respectively, compared with a mean value of 9.8×10^6 (range $7.2-16.4 \times 10^6$) as determined by the testicular homogenisation method. The DSP value for the second of the hopping mice is somewhat higher than has been determined for other individuals of this species. Nevertheless, these data are in general agreement with the results presented in this thesis and indicate that the testes of the hopping mouse are less efficient in the production of spermatozoa than those of the plains rat.

Another measure of the efficiency of sperm production is the ratio of germ to Sertoli cells within the seminiferous epithelium (see section 1.5.3.2, Chapter 1). The ratios of both spermatocytes and spermatids per Sertoli cell, as determined from cell counts using the optical disector method and subsequent calculation of absolute numbers of various germ cell types and Sertoli cells per testis, in the hopping mouse were less than half those of the corresponding cell types in the plains rat (data presented in Appendix 1). Elongate spermatid-Sertoli cell ratios for both species were lower than those reported for various mammals by Russell and Peterson (1984), however, different methods for calculating ratios were used in the two studies and hence the data are not directly comparable. Russell and Peterson (1984) based their ratios on counts of the number of elongate spermatids associated with type A configuration (Wong and Russell, 1983) Sertoli cells, as observed in sections viewed with the electron microscope. Type A Sertoli cells are, however, only one distinct sub-population of Sertoli cells that are characterised by deep recesses containing elongate spermatids (Wong and Russell, 1983). There are also Type B Sertoli cells that have shallow recesses containing elongate spermatid heads only and immediately following spermiation, certain Sertoli cells have no elongate spermatids associated with them. These latter sub-populations of Sertoli cells were not sampled by Russell and Peterson (1984). For the plains rat and hopping mouse, ratios represent the average number of elongate spermatids per Sertoli cell for the entire Sertoli cell population within the testes.

From the present study it is clear that variability in both absolute testis size and the efficiency of testicular tissue in producing spermatozoa, contribute to the vast differences in epididymal sperm numbers observed between the plains rat and hopping mouse. However, interspecific differences in the capacity of the epididymides to store spermatozoa may also affect the number of spermatozoa present within the excurrent ducts. Various studies have indicated that daily sperm production by the testes is independent of epididymal sperm reserves (Amann, 1970; Amann *et al.*, 1976; Robb *et al.*, 1978). Similarly, in adult laboratory rats, little correlation was found between epididymal sperm reserves and DSP in both control males and those that had been treated with 6-propyl-2-thiouracil (PTU) during the neonatal period (Cooke *et al.*, 1991). Transient administration of PTU has been shown to increase testis size, daily sperm production and epididymal sperm numbers in adults (Cooke and Meisami, 1991; Cooke *et al.*, 1991). It has also been reported that sperm numbers in the caudae epididymides and total sperm numbers per epididymis are lower in 'depressed' men than normal men, even though DSP is similar in both groups (Amann and Howards, 1980). This suggests that numbers of spermatozoa in the epididymides do not provide an accurate reflection of DSP/testis, at least, in humans (Johnson *et al.*, 1980).

6.5 Summary

Mean daily sperm production per animal in the plains rat was $40.1 \pm 11.5 \times 10^6$ (mean \pm S.D.), compared with only $0.51 \pm 0.24 \times 10^6$ (mean \pm S.D.) in the hopping mouse. When the vast difference in paired testes size between the two species was taken into account, a DSP/g testis value of $25.7 \pm 6.5 \times 10^6$ (mean \pm S.D.) was obtained for the plains rat, compared with $9.8 \pm 2.4 \times 10^6$ (mean \pm S.D.) for the hopping mouse. Therefore, the vastly greater number of sperm in the genital ducts of the plains rat, compared with the hopping mouse, results not only from the much larger testes in this species, but also from a greater efficiency of sperm production. Limited data on germ:Sertoli cell ratios in the two species also suggest that each hopping mouse Sertoli cell supports less than half the number of spermatocytes and spermatids of its counterpart in the plains rat.

Daily sperm production per gram of testicular tissue in the plains rat was comparable to that of other mammalian species including the laboratory rat. Efficiency of spermatogenesis in the hopping mouse, however, was low, being less than half that of other mammals apart from bulls, dogs and humans.

A combination of factors including small testes, a smaller proportion of testicular seminiferous tubules, a longer duration of the cycle of the seminiferous epithelium and hence of spermatogenesis and a lower efficiency of spermatogenesis, ie. fewer sperm produced per gram of seminiferous epithelium, all contribute to the lower numbers of sperm in the epididymides and vasa deferentia of the hopping mouse. Which events in spermatogenesis are less efficient, however, remain to be determined. Likewise, the possibility that the hopping mouse has a lower capacity for sperm storage in the epididymis, resulting in the faster passage of spermatozoa through the duct system, requires investigation.

Chapter 7 Epididymis and Vas Deferens: Gross Anatomical and Microscopical Structure¹

7.1 Introduction

After their release from the testicular seminiferous epithelium, spermatozoa begin their journey from the site of their production, to the site of insemination and for the lucky few, fertilization of an oocyte. Much of this journey involves transit of the male excurrent duct system, the ductuli efferentes, ductus epididymidis and vas deferens.

It has long been accepted that, in addition to acting as a transit route, the epididymis plays a pivotal role in the post-testicular maturation and storage of spermatozoa (Bedford, 1975; Hamilton, 1975). Spermatozoa released from the testes are non-motile and unable to fertilize an oocyte (Bedford, 1979; Turner 1991) and it is only during passage through the caput and corpus to the cauda epididymidis that these abilities are acquired (Bedford, 1966, 1967; Orgebin-Crist, 1967, 1969; Cooper, 1986). Furthermore, the acquisition of motility and fertilising ability is related to the functions of the epididymal epithelium, including its absorption, synthesis and secretion of (glyco)proteins, which create an appropriate, supportive, luminal microenvironment for spermatozoal maturation and storage (Bedford, 1975, 1979; Courot, 1981; Orgebin-Crist and Fournier-Delpech, 1982; Hinton, 1990; Turner, 1991). As mentioned in section 1.3.2.2 of Chapter 1, a number of different epithelial cell types are found within the epididymal epithelium and contribute to the composition of the epididymal luminal environment via their absorptive and secretory capabilities. Similarly, differences in the distribution and activity of these cells along the length of epididymal duct contribute to the functional specialisation of the various regions (Bedford, 1975; Moore, 1990; Setchell *et al.*, 1994).

While those regions of the epididymal duct closer to the testis are primarily concerned with sperm maturation (Glover and Nicander, 1971), the region leading into the vas deferens is involved in the storage of spermatozoa, with more than 60% of the total sperm population of the excurrent ducts located in this region in some species (Amann, 1981). Hence the latter region generally has a wider luminal diameter and a lower epithelial height than the remainder of the duct (Nicander, 1957a, 1957b; Flickinger, *et al.*, 1978; Jones and Clulow, 1994).

¹ The results in this chapter on the light microscopical structure of the epididymis and vas deferens have been published in Peirce, EJ and Breed, WG (1989) Light microscopical structure of the excurrent ducts and distribution of spermatozoa in the Australian rodents *Pseudomys australis* and *Notomys alexis*. *Journal of Anatomy* 162:195-213.

The vas deferens is not generally recognised as a site of sperm storage in mammals and the sperm located within it are usually considered to reflect a 'spill over' from the main sperm store in the cauda epididymidis (Glover and Nicander, 1971). In a few species, however, it has been suggested that moderate numbers of spermatozoa are stored in the vas deferens or the ampulla, close to the urethra (Niemi, 1965; Kennedy and Heidger, 1979; Mann and Lutwak-Mann, 1981).

As mentioned previously in the background literature, the plains rat has very high numbers of spermatozoa within the epididymides and vasa deferentia, whereas by contrast, the epididymides of the hopping mouse contain relatively low sperm numbers (Breed 1982a, 1986; Breed *et al.*, 1991). In addition, the lumen of the vas deferens of the hopping mouse progressively increases in diameter from about mid-way along the duct, towards its urethral end and contains a high percentage of the total number of spermatozoa in the excurrent ducts in some individuals (Breed, 1981b, 1986), a far higher percentage than that previously documented for hamsters and rabbits (Amann *et al.*, 1976). These findings therefore suggest differences in the cellular composition, structure and/or function of the epithelium of the various regions of the excurrent ducts in the hopping mouse from those found in the plains rat and common laboratory rodents. The aim of this chapter therefore, is to:

- describe the gross anatomical and microscopical structure of the epididymis and vas deferens of the plains rat and hopping mouse and
- document interspecific differences in structure along the length of the excurrent ducts and particularly of those regions associated with sperm storage.

The latter of these aims will utilise an electron microscopical investigation of the epithelium of the cauda epididymides and vasa deferentia to determine whether there are any ultrastructural features of the vas deferens that might relate to a sperm storage function.

7.2 Materials and Methods

7.2.1 Light Microscopy

Tissues from the epididymides and vasa deferentia of ten plains rats and ten hopping mice were obtained after fixation via vascular perfusion and were processed for plastic embedding (see section 2.2, page 62). Samples of tissue were taken from various locations within the caput, corpus and cauda epididymides and at known intervals along the length of the vasa deferentia. Thick sections (0.5-1.0 μm) were cut from these samples, stained

with toluidine blue and viewed with an Olympus BH-2 or Vanox microscope. They were subsequently analysed for a) details of the appearance of the duct along its length within each species and b) interspecific differences in the appearance of the duct at similar locations. Measurements of luminal diameter and epithelial cell height were taken for all of the sampled locations within the epididymis and vas deferens. The thickness of the smooth muscle layer of the wall of the vas deferens was also recorded. For each location sampled, at least 10-20 measurements of each parameter were recorded for a minimum of four animals per species and data were presented as the mean value \pm S.D.

7.2.2 Electron Microscopy

Ultrathin sections of areas of interest, as identified from the thick plastic sections, were cut, stained as previously described (section 2.2, page 62) and examined with a Phillips CM100 TEM.

The vasa deferentia of two hopping mice were processed for scanning electron microscopy (SEM). For this, tissues were fixed by immersion in routine EM fixative (see page 62) for 24 hours, post-fixed in 1% osmium tetroxide and dehydrated by passing through a graded series of acetones. The samples were then critical point dried in CO₂ in a Balzers Union Critical Point Dryer, mounted on SEM stubs using double sided tape, coated with 20nm carbon/palladium and examined at 20kV with a Phillips 500 SEM.

7.3 Results

7.3.1 Macroscopic Appearance of the Excurrent Ducts

The general morphological appearance of the excurrent ducts of the plains rat and hopping mouse was similar to that documented for other rodents. Upon dissection, the ductuli efferentes, caput, corpus and cauda regions of the epididymis and the vas deferens could be distinguished macroscopically (Figs 7.1a and 7.2a).

In both species, the ductuli efferentes arose from the extra-testicular portion of the rete testis. Initially the ductules were relatively straight but they became increasingly convoluted as they passed from the testis, through the epididymal fat pad towards the ductus epididymidis. A distinct coni vasculosi was not evident in either species. At the head of the epididymis the ductuli converged to form a superolateral cap over the initial segment of the epididymal duct, into which they drained.

The ductus epididymidis, which was closely apposed to the testis and passed latero-posteriorly to it, consisted of a single, highly tortuous, tubule arranged into segments. Each segment was delimited by connective tissue septae that were continuous with the connective and adipose tissue of the epididymal fat pad surrounding the organ. Beneath the caudal pole of the testis, the epididymis expanded in size, the duct changed direction and increased in diameter before straightening to become the vas deferens. Macroscopically, the vas deferens could be divided into an epididymal and a urethral segment on the basis of differences in the overall diameter of the duct (Figs 7.1b and 7.2b) and, in the plains rat, the thickness of the duct wall.

Plains Rat

The ductuli efferentes consisted of six or seven closely associated tubules. The ductus epididymidis was highly coiled and arranged into distinct lobes or segments separated by connective tissue septae, especially in the caput and corpus regions. A distance of between 4.5 cm and 6 cm separated the caput and caudal flexures of the epididymis. The length of the vas deferens was 3.6 ± 0.4 cm (mean \pm S.D., n=10 animals). Approximately 1.1-1.8 cm from the junction with the cauda epididymidis the thickness of the muscle coat of the vas deferens increased and contributed to an overall increase in the circumference of the duct. An expanded ampullary region at the terminal end of the vas deferens was not seen in the plains rat.

Hopping Mouse

In male hopping mice, the ductuli efferentes were comprised of four tubules running in two pairs separated by intervening connective and adipose tissue before converging at the head of the epididymis. Relatively little coiling of the epididymal duct was evident and, in the corpus region, the duct zigzagged back and forth across the width of the organ. Segmentation of the epididymis was not as distinct as it was in the plains rat and the caudal region was poorly developed. A distance of about 1.5 cm separated the caput and caudal flexures. An abrupt increase in the circumference of the vas deferens occurred about two fifths of the distance between the duct's connections with the cauda epididymidis and the ejaculatory duct. This point was used to divide the vas deferens into epididymal and urethral segments (Fig. 7.2b). The total length of the vas deferens was 2.7 ± 0.4 cm (mean \pm S.D., n=12), with the epididymal segment comprising on average 1.1 ± 0.3 cm. The terminal end of the vas deferens did not display an expanded ampullary region and unlike in the plains rat, there was no apparent increase in the thickness of the muscle coat of the urethral segment as compared with the epididymal segment.

Plate 12 Anatomy of the Male Reproductive Tract in the Plains Rat

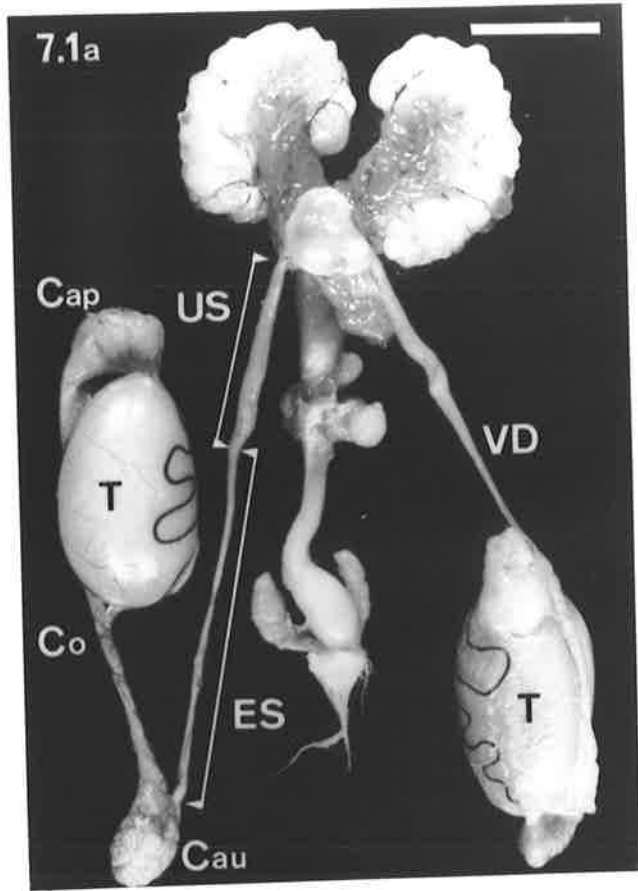
Figure 7.1a

Dissection showing the gross anatomy of the male reproductive system of the plains rat. The epididymis is closely apposed to the testis (T) and caput (Cap), corpus (Co) and cauda (Cau) regions are clearly discernible. The ductuli efferentes (not distinguishable in the micrograph) connect the rete testis at the cranial pole of the testis to the initial segment of the epididymis (see Fig. 7.1b). The vas deferens (VD) shows epididymal (ES) and urethral (US) segments that differ macroscopically in the overall diameter of the duct.

bar = 10 mm

Figure 7.1b

Schematic diagram, based on Fig.7.1a, of the plains rat epididymis and vas deferens showing the subdivisions utilised in descriptions of the microstructure of the tract. The initial segment (IS) is confined to a small region of the caput epididymidis, with the remainder of the caput and the entire corpus epididymidis corresponding to the middle segment, which was further divided into three regions, M1, M2 and M3. The terminal segment (TS) corresponds to the cauda epididymidis. Within region M3 of the middle segment and the terminal segment the numbers 1 and 2 indicate the general locations from which measurements of epithelial height and luminal diameter, as shown in Table 7.1 on page 139, were taken. The vas deferens is divided into epididymal (ES) and urethral (US) segments on the basis of an overall increase in diameter of the duct and thickness of the muscle coat. DE = ductuli efferentes.



7.1b

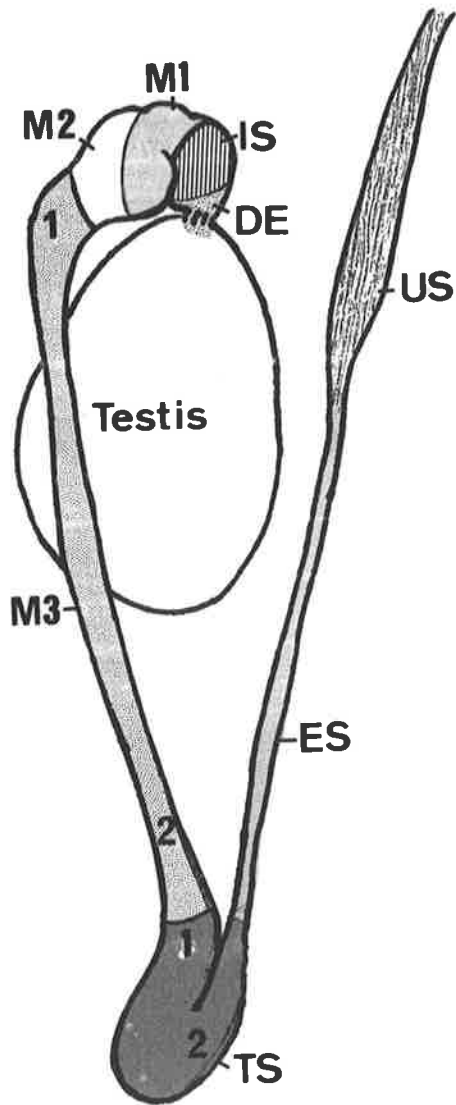


Plate 13 Anatomy of the Male Reproductive Tract in the Hopping Mouse

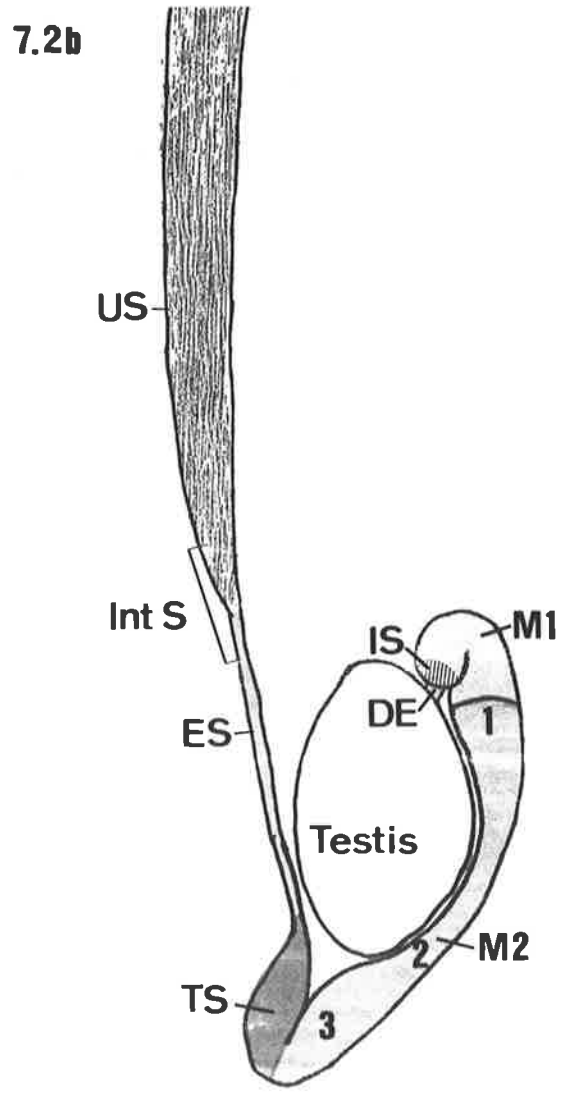
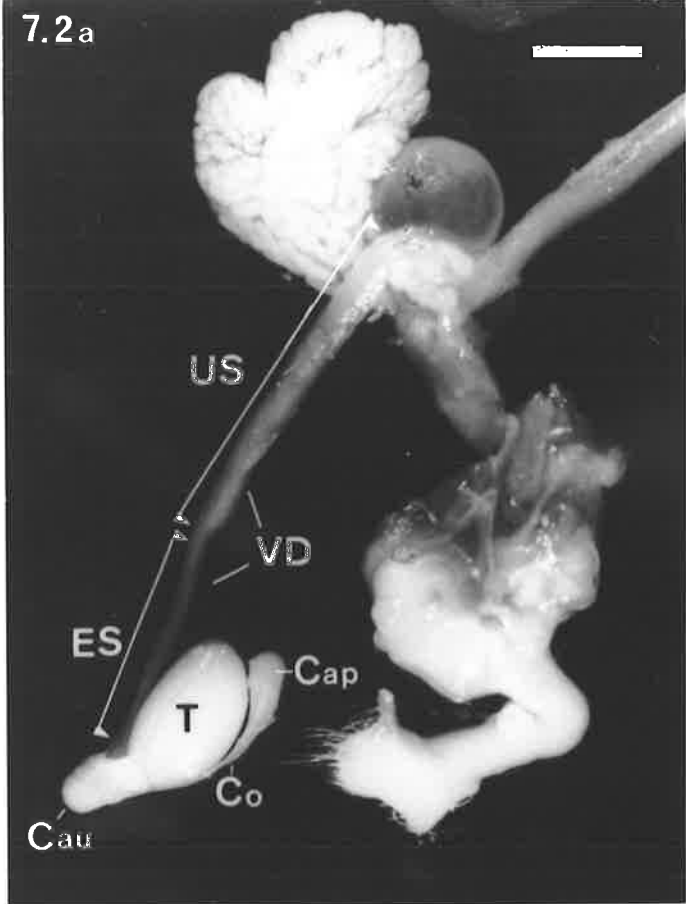
Figure 7.2a

Dissection showing the gross anatomy of the male reproductive system of the hopping mouse. As in the plains rat, caput (Cap), corpus (Co) and cauda (Cau) regions of the epididymis can be identified and lie in close proximity to the testis (T). The epididymal segment (ES) of the vas deferens (VD) extends approximately two fifths of the duct's length, with the remainder of the duct being the urethral segment (US).

bar = 50 mm

Figure 7.2b

Schematic diagram, based on Fig.7.2a, of the hopping mouse epididymis and vas deferens indicating the subdivisions of the tract referred to in the present study. The initial segment (IS) is restricted to the region of the caput epididymidis immediately adjacent to the ductuli efferentes (DE). Region M1 of the middle segment (M1) occupies the remainder of the caput epididymidis and in some individuals, extends into the proximal corpus epididymidis, whereas region M2 of the middle segment (M2) corresponds to the corpus epididymidis and that portion of the cauda epididymidis on the corpus side of the caudal flexure. The general locations from which the measurements of epithelial height and luminal diameter within region M2 of the middle segment were taken (see Table 7.2, page 142) are designated by the numbers 1, 2 and 3. The terminal segment (TS) of the epididymis is located distal to the caudal flexure and is continuous with the vas deferens. Division of the vas deferens into epididymal (ES) and urethral (US) segments is based on an increase in the overall diameter of the duct. For the purposes of investigation of the ultrastructure of the epithelium, the region of the duct surrounding the point where the increase in diameter occurs has been designated the intermediate segment (Int S) of the vas deferens.



7.3.2 Light and Electron Microscopy of the Excurrent Ducts

7.3.2.1 Ductuli Efferentes

In both the plains rat and hopping mouse, the epithelium of the ductuli efferentes was composed of non-ciliated, columnar, principal cells and ciliated cells. The principal cells in the plains rat ductuli efferentes possessed round, basally located, nuclei with a prominent, central, nucleolus and finely granular nucleoplasm. Small accumulations of heterochromatin were present close to the nuclear envelope. Numerous densely-stained granules were evident in the basal and paranuclear cytoplasm, vacuoles and vesicles were observed apically and short (2-3 μm) microvilli extended into the lumen. The ciliated cells were characterised by long, 8-10 μm , cilia arising from intensely stained basal bodies located beneath the apical surfaces of the cells (Fig. 7.3). The cytoplasm of ciliated cells was generally paler staining than that of principal cells and appeared to lack granules and vacuoles. The nucleus was usually smaller in diameter and located in the apical part of the cell closer to the lumen, than the nuclei of principal cells.

The epithelial height of the ductuli efferentes ($17.8 \pm 2.1 \mu\text{m}$, mean \pm S.D., Table 7.1) did not vary greatly in the male plains rat, with ciliated cells being only marginally taller than the principal cells. Consequently the lumen was relatively regular in cross-section and averaged $69.5 \pm 15.9 \mu\text{m}$ in diameter. A discontinuous layer of between one and four smooth muscle cells surrounded each tubule and loose connective tissue occupied the spaces between the tubules.

In the male hopping mouse, the ductuli efferentes had a considerably narrower lumen ($22.6 \pm 7.0 \mu\text{m}$, Table 7.2) than that in the plains rat, which was almost totally occluded by long cilia. The epithelium averaged $18.9 \pm 2.7 \mu\text{m}$ in height and between one and three smooth muscle cells formed an incomplete layer around each ductule. The principal and ciliated cells were similar in appearance to those seen in the plains rat, although in the principal cells, nuclei were more ovoid and clumps of heterochromatin were more prominent within the nucleoplasm (Fig. 7.4). In addition, within the principal cells of the hopping mouse, cytoplasmic granules were smaller, fewer in number and more uniformly distributed throughout the cytoplasm.

7.3.2.2 Ductus Epididymidis

In this study of the plains rat and hopping mouse epididymis, the classification scheme and terminology of Glover and Nicander (1971) were adopted for descriptions of epididymal microstructure. Using this scheme, the ductus epididymidis was subdivided into initial,

middle and terminal segments on the basis of differences relating to:

- a) the cytology of the epididymal epithelium,
- b) the height of the principal cells
- c) the diameter of the lumen of the epididymal duct.

The locations of the initial, middle and terminal segments did not strictly correspond to the anatomical divisions of caput, corpus and cauda epididymidis in either the plains rat (Figs 7.1a, b) or the hopping mouse (Figs 7.2a, b). Furthermore, in the case of the hopping mouse, Glover and Nicander's scheme could not be strictly applied because characteristics definitive of the middle segment were observed in combination with other characteristics definitive of the terminal segment in the same region of the duct.

In both species, the characteristic features of the initial segment were a tall epithelium, long, straight stereocilia extending from the apical surfaces of principal cells and very few spermatozoa within the duct lumen. The middle segment was characterised by a wider lumen than the initial segment and principal cells with abundant supranuclear vacuoles and bent stereocilia, whereas the terminal segment had a low epithelium, short, sparsely distributed stereocilia on its principal cells and a very wide lumen packed with spermatozoa.

In the plains rat, the middle segment was further subdivided into three regions, designated M1, M2 and M3, on the basis of differences in the height of the principal cells and stereocilia and variations in luminal diameter. Prominent supranuclear vacuoles were observed within the principal cells throughout the entire middle segment.

In the hopping mouse, the principal cells of both the middle and terminal segments contained prominent apical vacuoles and vesicles. Therefore, this cytological feature of the principal cells, as used by Glover and Nicander, was not useful in differentiating between the middle and terminal segments in this species. Similarly, the height of the epididymal epithelium and the diameter of the lumen did not vary dramatically along most of the duct's length and hence there was no readily recognisable landmark that could be used to demarcate the junction between the middle and terminal segments. Consequently, the terminal segment was defined as the region of the epididymis having the widest lumen and containing the greatest concentration of spermatozoa (Fig. 7.2b). It was also noted that the terminal segment, as defined for the hopping mouse epididymis, usually corresponded to the portion of the duct where the surrounding smooth muscle layer increased dramatically in thickness. Within the middle segment, two regions, designated M1 and M2, were distinguishable on the basis of a large difference in luminal diameter and an increase in the prominence of Golgi complexes in the supranuclear cytoplasm of the principal cells (see section headed Hopping Mouse for details).

Plains Rat

The initial segment of the plains rat epididymis extended from the ductuli efferentes to the caput flexure (Fig. 7.1b). In this region, the relatively narrow lumen of the duct was lined by an epithelium comprised predominantly of tall principal cells (Fig. 7.5). The height of these cells was $53.7 \pm 3.4 \mu\text{m}$ (Table 7.1) and they possessed small, basally located, nuclei of irregular shape with one or two nucleoli (Fig. 7.6). The cytoplasm was lightly stained and contained variable numbers of elongate mitochondria, small granules and apical vesicles and vacuoles. A slightly paler staining region of cytoplasm was located immediately above the nucleus, which subsequent electron microscopical investigations revealed, contained several Golgi complexes. Extending from the apical surface of the principal cells were 10-15 μm stereocilia that, in the tissue sections, often appeared clumped. Few spermatozoa were observed in the circular lumen, which was $108 \pm 10 \mu\text{m}$ in diameter. Small, flattened basal cells with pale cytoplasm were located near the base of the epithelium. Their nuclei were generally ovoid with the long axes parallel to the basement membrane. Apical cells whose nuclei were located nearer the luminal surface of the epithelium (see Fig. 7.6) were also observed. Their cytoplasm tapered basally and did not appear to extend to the basement membrane. An incomplete layer of smooth muscle, one to three cells thick, surrounded the duct.

Distal to the caput flexure, the morphological appearance of the ductus epididymidis altered, with abundant vesicles and vacuoles occurring in the apical cytoplasm of the principal cells, indicative of the middle segment. This segment was further subdivided into three regions according to the height of the epididymal epithelium, luminal diameter and the density of spermatozoa in the lumen. Regions M1 and M2 were confined to the mid-region of the caput epididymidis, with region M3 encompassing the distal caput and corpus epididymides (see Figs 7.1a, b).

In region M1 of the middle segment, the lumen of the duct was narrow ($81 \pm 13 \mu\text{m}$) densely packed with spermatozoa and lined by an epithelium $31.3 \pm 6.3 \mu\text{m}$ in height (Table 7.1). The principal cells had basal nuclei of irregular shape, with a single nucleolus (Figs 7.7 and 7.8). Numerous small vesicles and larger vacuoles occupied the apical cytoplasm and in many cells a few dense granules were observed in a supranuclear position, usually basal to the vacuoles. Clumps of 8-12 μm long stereocilia extended into the lumen from the apical surfaces of the cells.

A wider lumen and more sparsely distributed spermatozoa were characteristic of region M2 of the middle segment (Fig. 7.9). The lumen was $139 \pm 12 \mu\text{m}$ in diameter and was lined by a slightly lower epithelium of $29.5 \pm 2.7 \mu\text{m}$ (Table 7.1). The nuclei of the

principal cells tended to be more regular in shape and contained a prominent nucleolus. Small granules and a few larger, intensely stained structures, possibly dense bodies, occupied the supranuclear cytoplasm and above them was an area containing few organelles or inclusions (Fig. 7.10). Mitochondria were less obvious, but numerous apical vacuoles were evident. The stereocilia were long but more sparsely distributed than in region M1 of the middle segment.

Region M3 of the middle segment was similar in appearance to region M1, except for the appearance of clear cells within the epithelium, in addition to the principal and basal cells (Fig. 7.11). Initially, the lumen of the duct was narrow, but it increased in diameter with increasing distance from the initial segment, ranging from $100 \pm 8 \mu\text{m}$ adjacent to region M2, to $190 \pm 22 \mu\text{m}$ adjacent to the terminal segment (Table 7.1). The density of spermatozoa in the lumen also increased towards the terminal segment, although epithelial height remained relatively constant at $32.2 \pm 3.9 \mu\text{m}$.

The principal cells possessed basally located nuclei, which formed a relatively uniform band within the epithelium. The nuclei were round in cross-section, had finely granular nucleoplasm and one or two nucleoli (Fig. 7.12a). The apical third to half of the cytoplasm contained numerous small vacuoles and granules were sometimes evident between them and the nucleus. Many elongated mitochondria were scattered throughout the cytoplasm, except in the vicinity of the Golgi complex, below the vacuoles. Near the junction of the middle segment with the terminal segment, the region of the principal cells containing the Golgi complex was more prominent and numerous multivesicular bodies were evident below it (Fig. 7.12b). The stereocilia were shorter, (5-8 μm) and more densely packed.

The clear cells were up to twice the width of the adjacent principal cells and their cytoplasm was filled with granules and vacuoles (Figs 7.12a and 7.12b). Their nuclei were pale staining, centrally located, highly variable in shape and contained one or two nucleoli. In many instances, the nucleus appeared to be distorted by the adjacent granules and vacuoles. The granules, which stained intensely with toluidine blue, occupied a sub-nuclear position, while the vacuoles filled the apical portion of the cell. No apical stereocilia were evident on these cells, however, their cytoplasm and its contents appeared to bulge into the lumen in some areas of the epithelium.

The morphology of the basal cells was similar throughout the entire middle and terminal segments of the epididymis. The cells were flattened to triangular in cross-section, possessed a large ovoid nucleus oriented with its long axis parallel to the basement membrane and had a high nucleus to cytoplasm ratio (see Figs 7.10 and 7.15). The

Plate 14 Ductuli Efferentes of the Plains Rat and Hopping Mouse
Light Microscopic Structure of the Ductus Epididymidis of the Plains Rat

Figure 7.3

Epithelium of the ductuli efferentes of the plains rat showing the distribution of principal (P) and ciliated (C) cells. Principal cells display numerous basal and paranuclear granules and apically located vacuoles.

bar = 10 μm

Figure 7.4

Epithelium of the ductuli efferentes of the hopping mouse. Ciliated cells (C) are interspersed among the more numerous principal cells (P).

bar = 15 μm

Figure 7.5

Initial segment of the plains rat epididymis. A tall epithelium with long stereocilia, surrounds the lumen.

bar = 40 μm

Figure 7.6

Epithelium of the initial segment showing principal (P) and basal (B) cells. A third cell type (A) with a more apically located nucleus is also present.

G = supranuclear region of principal cells containing the Golgi complexes.

bar = 15 μm

Figure 7.7

Region M1 of the middle segment of the epididymis. Epithelial cell height has decreased from that of the initial segment and sperm density within the lumen has increased.

bar = 40 μm

Figure 7.8

Epithelial characteristics of region M1. Note the irregular shape of the principal cell nuclei (N) and an increase in the prominence of small apical vesicles (arrows) and larger vacuoles (arrow heads).

bar = 10 μm

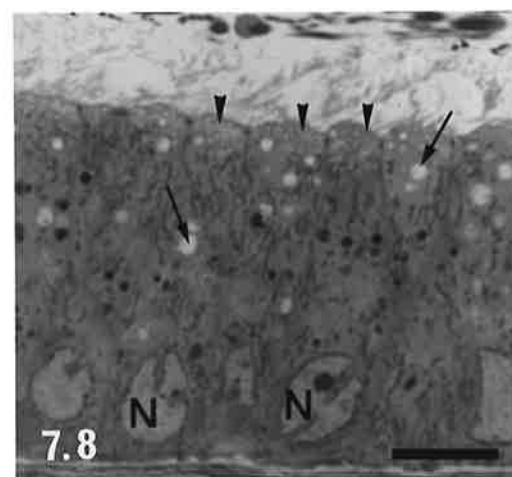
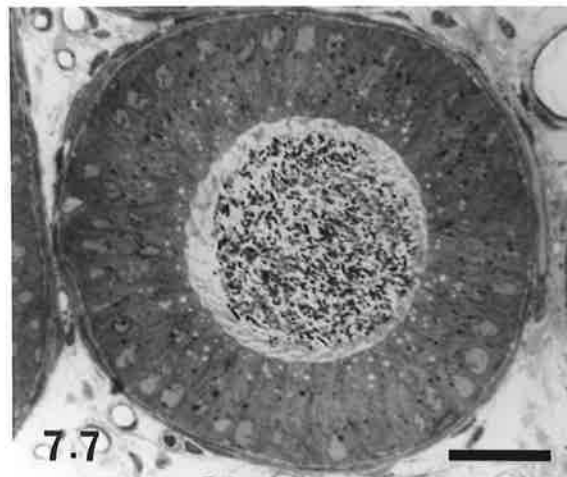
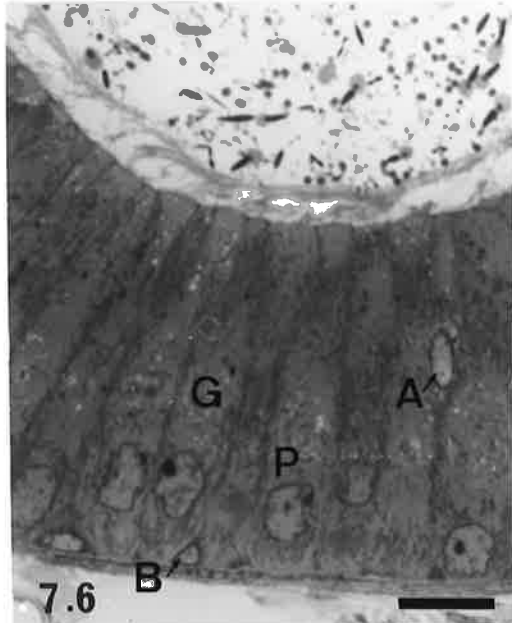
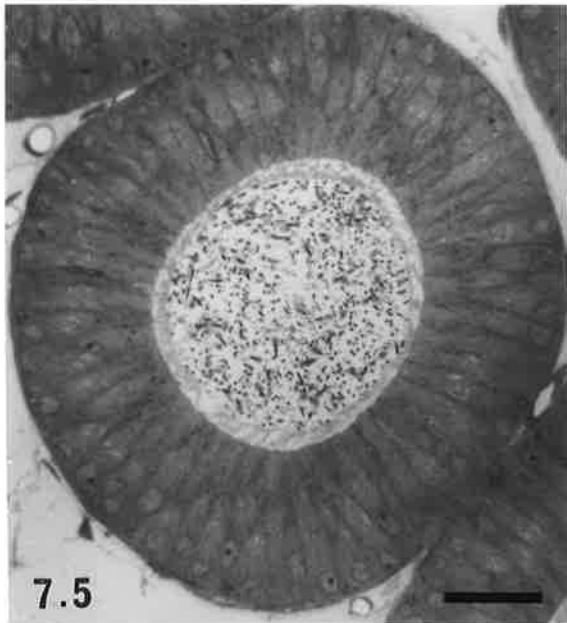
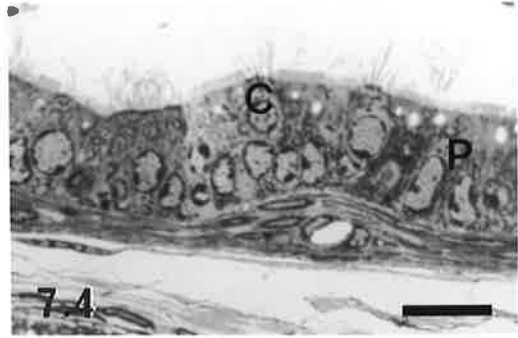
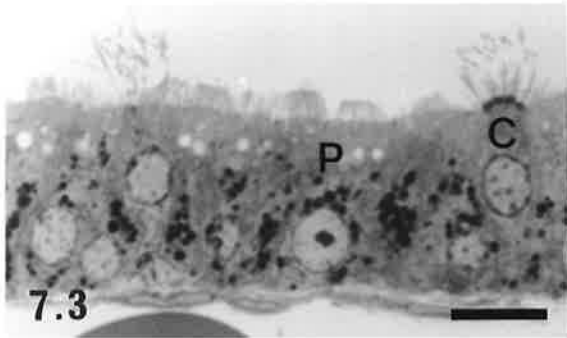


Plate 15 Light Microscopic Structure of the Ductus Epididymidis of the Plains Rat

Figure 7.9

Region M2 of the middle segment of the epididymis. The principal cell nuclei are more regular in shape, the epithelium is slightly lower and the luminal diameter is wider than in region M1.

bar = 40 μm

Figure 7.10

Epithelium of region M2 of the middle segment. Note the prominent, pale-staining region of supranuclear cytoplasm (G) containing the Golgi complexes and a few large apical vacuoles (arrow heads).

bar = 15 μm

Figure 7.11

Region M3 of the middle segment of the epididymis. The diameter of the lumen has decreased, but the height of the epithelium has increased from that of region M2. Several clear cells (Cl) are present within the epithelium.

bar = 40 μm

Figures 7.12a and 7.12b

Epididymal epithelium from sites 1 (Fig. 7.12a) and 2 (Fig. 7.12b) within region M3 of the middle segment (see Fig. 7.1b for the location of these sites). In Fig. 12b the Golgi region (G) is more prominent and multivesicular bodies (M) are present between the Golgi and the nucleus. Note also the typical structure of clear cells (Cl).

bar = 15 μm (both figures)

Figure 7.13

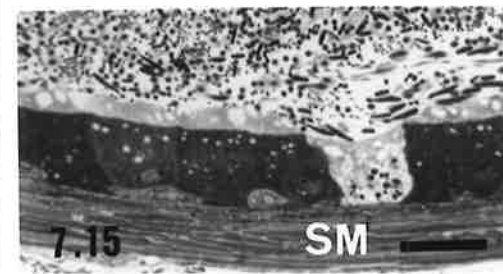
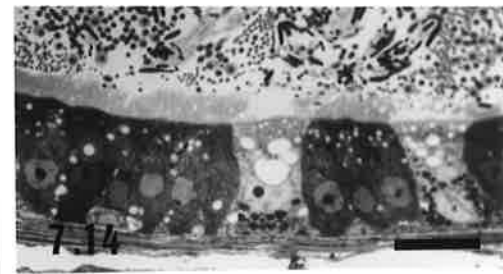
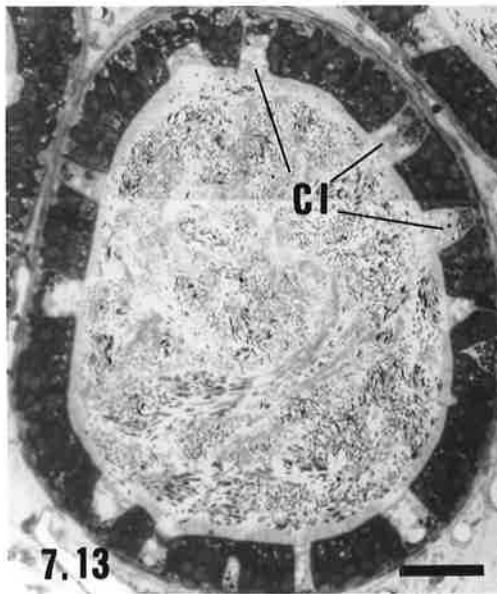
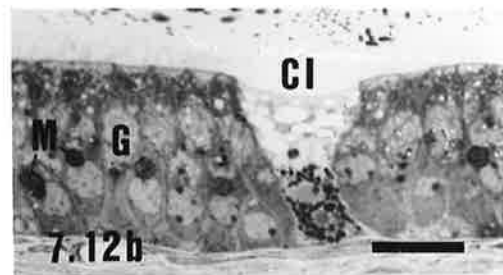
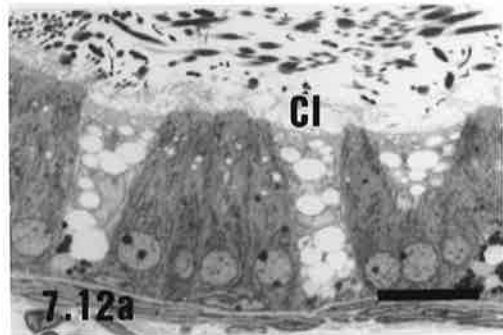
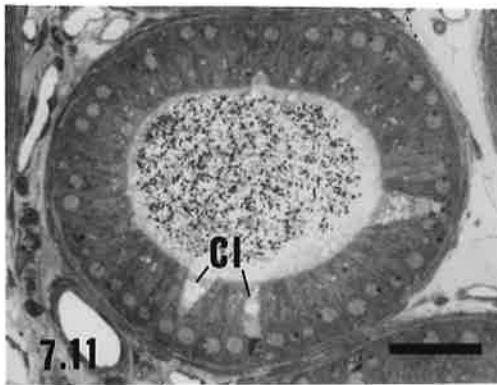

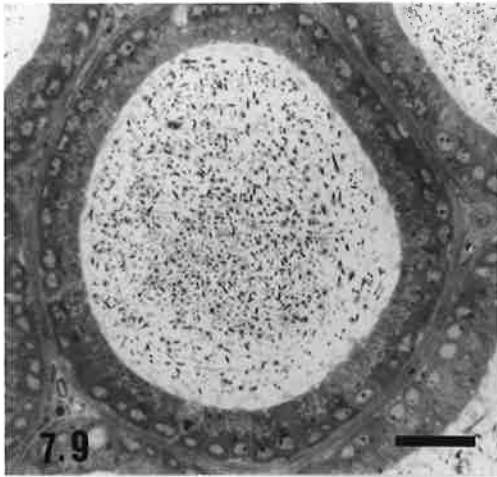
Terminal segment of the epididymis, showing a large increase in the luminal diameter and a high density of spermatozoa within the lumen. Note also an increase in the number of clear (Cl) cells over that of region M3 of the middle segment.

bar = 40 μm

Figures 7.14 and 7.15

Epithelium of the terminal segment of the epididymis. Fig. 7.14 shows features of the epithelium from site 1, proximal to the caudal flexure and Fig. 7.15 from site 2, distal to the caudal flexure (refer to Fig. 7.1b for locations). Note the decrease in the epithelial height and increase in the thickness of the smooth muscle layer (SM) in the latter location.

bar = 20 μm (both figures)



nucleoplasm was pale and in many nuclei several heterochromatic clumps were evident directly beneath the nuclear envelope. The cytoplasm was homogeneous and pale staining with little obvious structure.

In the plains rat, the terminal segment corresponded to the cauda region of the epididymis and its major features were a low epithelium surrounding a wide lumen containing abundant, densely packed, spermatozoa (Fig. 7.13). There was a steady increase in the luminal diameter of the duct of this region from an average of $260 \pm 68 \mu\text{m}$ adjoining region M3 of the middle segment and proximal to the caudal flexure, to $495 \pm 117 \mu\text{m}$ on the vas side of the flexure (Table 7.1). A high concentration of spermatozoa was observed within the lumen throughout the entire terminal segment. The epithelium of the duct proximal to the caudal flexure appeared somewhat similar to that of region M3 of the middle segment, although the principal cells were shorter ($25.7 \pm 5.7 \mu\text{m}$, Table 7.1), contained far fewer vacuoles and did not possess multivesicular bodies or a prominent Golgi region (Fig. 7.14). Stereocilia ranged from 3-6 μm in height and clear cells were more abundant than in the middle segment.

Table 7.1
Height of the Epithelium and Diameter of the Lumen of the Ductuli Efferentes and Ductus Epididymidis of the Plains Rat, *Pseudomys australis*.*

	Height of the Epithelium (μm)	Diameter of Lumen (μm)
<u>Ductuli Efferentes</u>	17.8 ± 2.1	70 ± 16
<u>Epididymis</u> [#]		
Initial Segment	53.7 ± 3.4	108 ± 10
Middle Segment		
region M1	31.3 ± 6.3	81 ± 13
region M2	29.4 ± 2.7	139 ± 12
region M3, site 1 (caput)	32.2 ± 3.9	100 ± 8
region M3, site 2 (distal corpus)	32.2 ± 3.9	190 ± 22
Terminal Segment		
site 1 (adjacent to region M3)	25.7 ± 5.7	260 ± 68
site 2 (adjacent to the vas deferens)	14.9 ± 1.7	495 ± 117

* All figures are means \pm S.D. on at least ten measurements from each site for each of four animals.

The regions of the ductus epididymidis from which measurements were taken are indicated on Fig. 7.1b.

Near the junction of the terminal segment of the epididymis with the vas deferens and distal to the caudal flexure, the duct's epithelium decreased dramatically in height to $14.9 \pm 1.7 \mu\text{m}$ (Table 7.1). Clear cells were less abundant than before the flexure and a 10-15 μm thick band of smooth muscle encircled the duct. The principal cells stained more intensely and did not appear as distinct as in previous regions of the duct, however, small vacuoles were still evident within their cytoplasm (Fig. 7.15).

The ultrastructural appearance of the epididymal epithelium of the terminal segment was examined with the transmission electron microscope. The general features of the principal cells were similar to those documented for other mammalian species (see Robaire and Hermo, 1988). The distribution of organelles in the clear cells, however, differed somewhat from that of the laboratory rat (Hamilton, 1975; Brown and Montesano, 1981), in that the membrane bound bodies (granules of the LM description) were located below the level of the nucleus as compared with a supranuclear position in the laboratory rat.

On the basis of organelle content, three distinct cytoplasmic regions were observed within the principal cells, - apical, supranuclear and basal (Fig. 7.16). Numerous long microvilli (= stereocilia) extended into the lumen from the apical surfaces of the principal cells and coated pits were observed between the bases of the microvilli (Figs 7.17 and 7.18). The most prominent feature of the subjacent apical cytoplasm was an abundance of coated vesicles (Fig. 7.18), although a few smooth vesicles of various sizes were sometimes also evident. Beneath the vesicles were many mitochondria and a small number of pale multivesicular bodies that contained granular electron dense material and tubular profiles (Figure 7.17). Golgi complexes were the predominant feature of the supranuclear region. They were comprised of stacks of up to ten saccules and associated small vesicles (Figs 7.19 and 7.20), with the saccules on the trans face often appearing somewhat dilated. A number of membrane-bound bodies containing moderate to dense staining material and occasional membranous profiles were also observed in the supranuclear region (Figs 7.16, 7.19 and 7.20). These structures were presumed to be lysosomes, since, using frozen sections of the epididymis, acid phosphatase activity was demonstrated in the supranuclear portions of principal cells (unpublished observations). An irregularly shaped nucleus with peripherally located clumps of heterochromatin and often a prominent nucleolus, was located in the basal part of the cell. Below and adjacent to the nucleus was an extensive network of rough endoplasmic reticulum (RER), often with a parallel arrangement of its cisternae (Fig. 7.21). Polysomes, an occasional multivesicular body and mitochondria were also observed in this region. The lateral plasmalemmae of the principal cells were relatively straight and interdigitation of membranes between adjacent cells was not apparent, although a prominent terminal bar was observed between cells, close to their apical boundaries.

Plate 16 Ultrastructure of the Epithelium of the Terminal Segment of the Plains Rat Epididymis

Figure 7.16

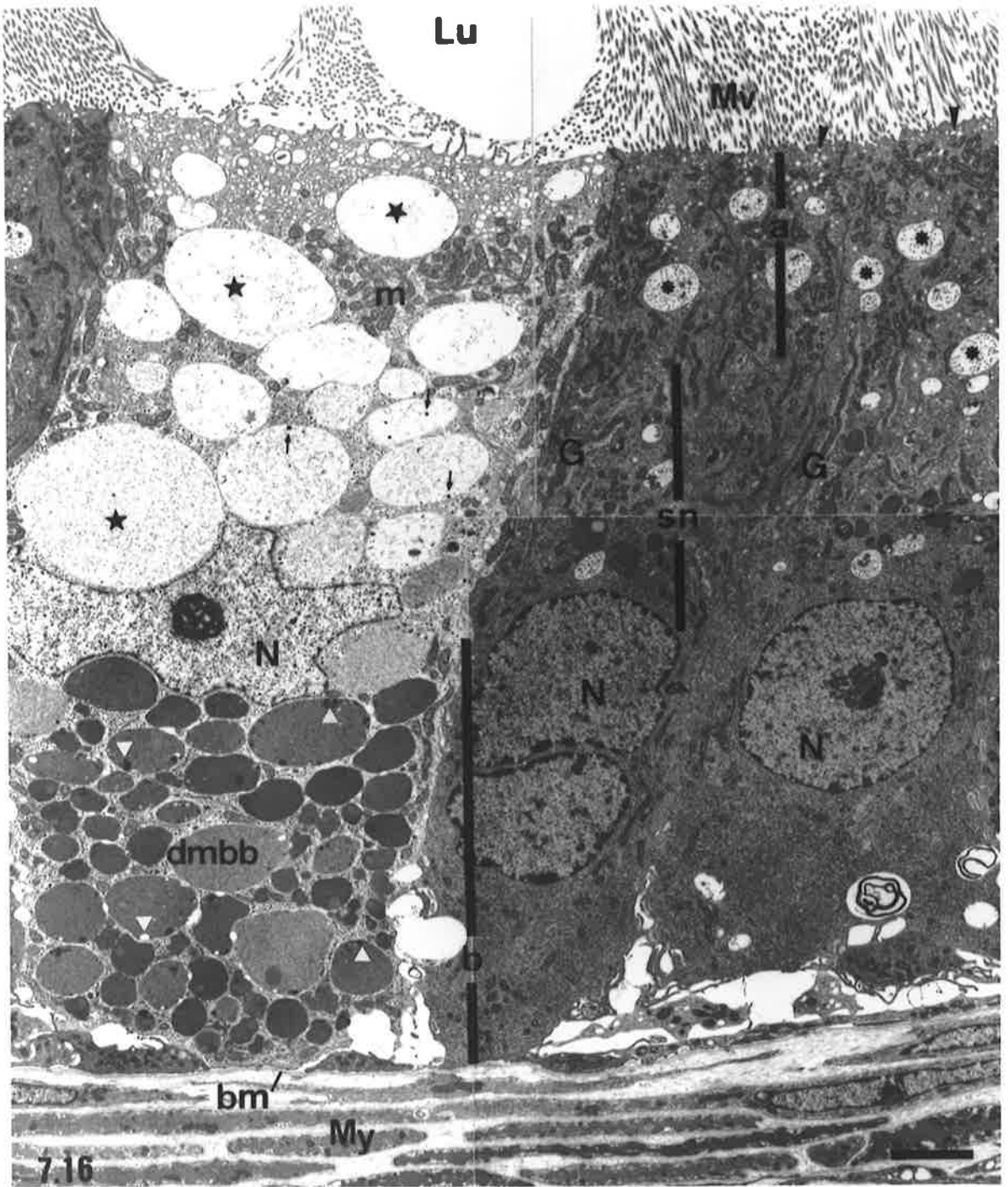
Montage showing the ultrastructural features of principal and clear cells within the epithelium of the terminal segment of the plains rat epididymis.

The principal cells, which have a more electron dense cytoplasm than the clear cell, show well defined apical (a), supranuclear (sn) and basal (b) regions. Numerous microvilli (Mv) extend from the apical surfaces of the cells into the lumen (Lu). Small vesicles (arrowheads) and larger pale-stained multivesicular bodies (asterisks) are located in the apical cytoplasm, whereas Golgi complexes (G) occupy the supranuclear region. The nucleus (N) resides in the basal region, along with an extensive network of endoplasmic reticulum.

The clear cell, unlike the neighbouring principal cells, has few microvilli extending into the lumen. Its apical cytoplasm contains numerous small, smooth-surfaced vesicles and mitochondria (m). Large vacuoles (stars) containing variable amounts of a floccular material and occasional small particles (small arrows) occupy the bulk of the supranuclear region, whereas the basal region is filled with membrane bound bodies of variable size and electron density. Many of the membrane bound bodies show smaller particles or vacuoles within them (white triangles).

dmdb = dense membrane bound body, Bm = basement membrane, My = myoid cell layer.

bar = 2 μ m



**Plate 17 Ultrastructure of Principal Cells within the Terminal Segment of the Plains
Rat Epididymis**

Figure 7.17

Apical regions of two principal cells of the terminal segment of the plains rat epididymis. Multivesicular bodies (mvb) showing a pale-stained matrix containing spherical and flattened tubular profiles (small arrows) are evident within the cytoplasm, along with mitochondria (m) and small vesicles. A few coated pits (arrowheads) can be seen between the microvilli.

bar = 5 μm

Figure 7.18

High power electron micrograph of the region of a principal cell directly beneath the apical plasmalemma, showing a predominance of coated pits (cp) and coated vesicles (cv). Few smooth surfaced vesicles are evident.

bar = 1 μm

Figures 7.19 and 7.20

Supranuclear region of a principal cell. The cytoplasm contains many Golgi complexes (G) comprised of stacks of closely spaced cisternae and associated small vesicles. Between the Golgi are mitochondria (m) and heterogeneously stained lysosomes (L), some of which contain lipid (asterisk, Fig. 7.19) or whorls of membranes (arrows, Fig. 7.20). Immediately adjacent to the nucleus (N) are several strands of endoplasmic reticulum (ER) sparsely studded with ribosomes.

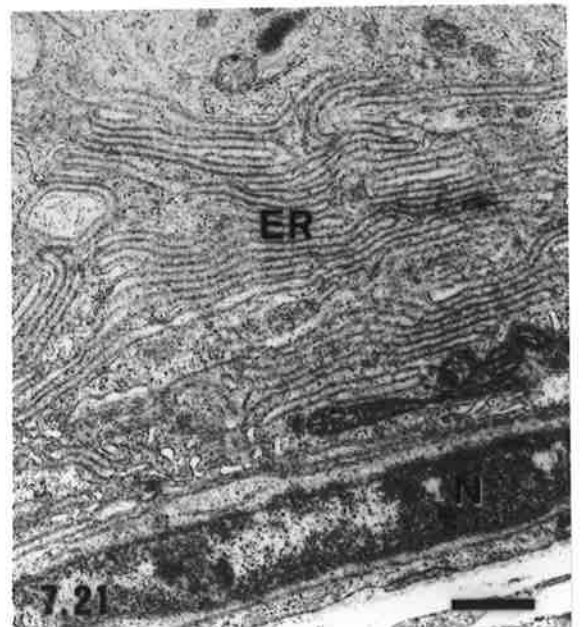
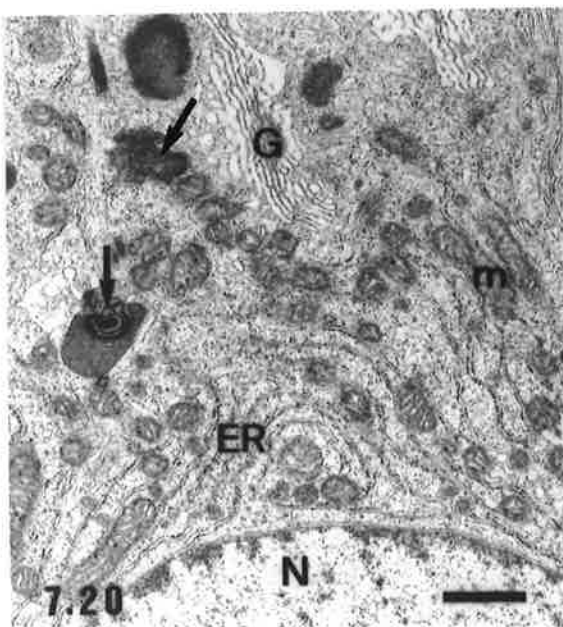
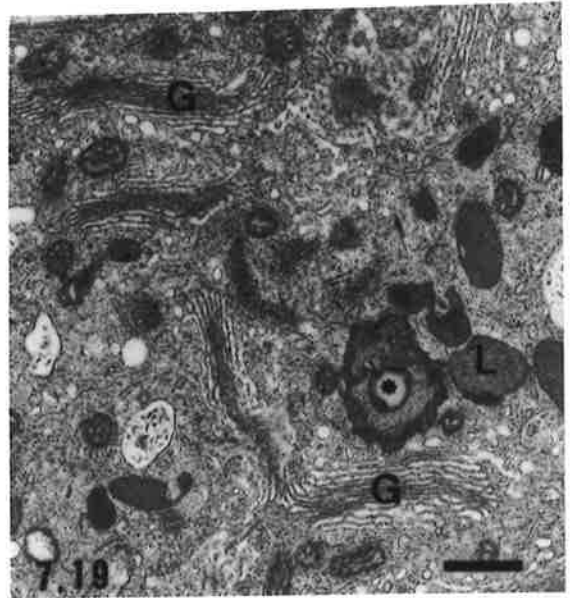
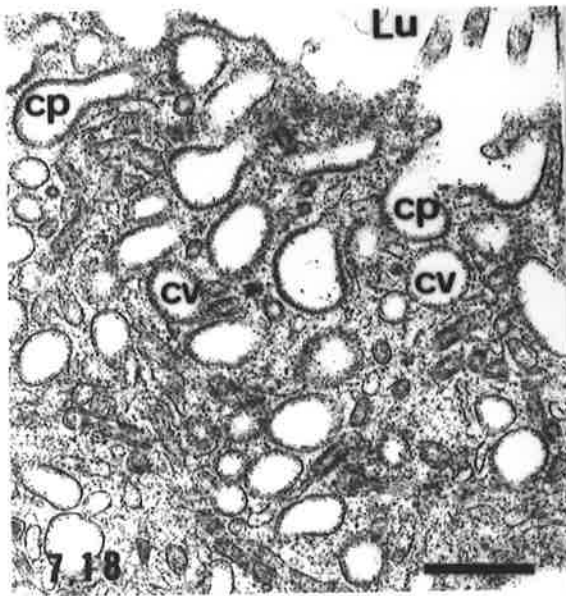
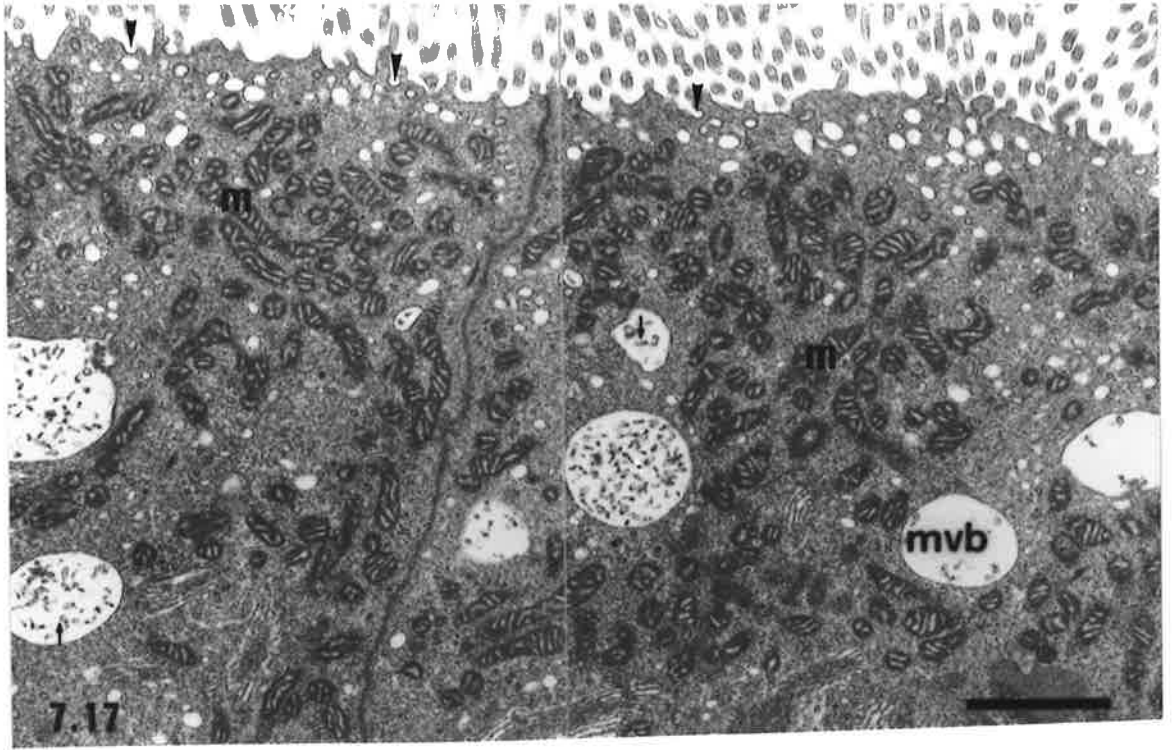
Both figures, bar = 2 μm

Figure 7.21

Basal region of a principal cell. The main feature of this region is an extensive network of rough endoplasmic reticulum (ER) arranged in relatively parallel arrays.

N = nucleus of a basal cell.

bar = 2 μm



The clear cells of the terminal segment of the epididymis were characterised by a supranuclear region dominated by numerous pale-stained vacuoles containing variable amounts of a floccular material, a few small, electron dense, particles and occasional membranous structures (Fig. 7.16). Mitochondria, small numbers of polysomes and sparse RER were also present in this area. A few short microvilli extended into the lumen from the apical plasmalemma and numerous small uncoated vesicles were located directly beneath the apical cell surface. Membrane bound bodies of variable shape, size and electron density (referred to as granules in the LM descriptions) filled the cytoplasm below the level of the nucleus, which was highly irregular in shape and often appeared to be distorted by the vacuoles and densely stained, membrane bound, bodies. The matrix of the majority of the membrane bound bodies was homogeneous, with small particles and membranous profiles, similar to those observed within the large vacuoles, embedded within it. There was no evidence of lipid in plains rat clear cells.

Hopping Mouse

The histological appearance of the hopping mouse epididymis varied somewhat between individuals, although a similar range of features was common to all individuals examined. The luminal diameter of the epididymis increased gradually along the length of the duct, except in the cauda epididymidis adjacent to the vas deferens, where there was a twofold increase in diameter. The heights of the epididymal epithelium and stereocilia were relatively constant throughout the duct, apart from in the initial segment where they were considerably taller (refer to Table 7.2). Fewer spermatozoa than in the plains rat were observed for all portions of the hopping mouse epididymis, round cells (predominantly immature germ cells and leucocytes) were relatively common within the lumen and polymorphonuclear leucocytes frequently occurred amongst the cells of the epithelium. Apart from the initial segment and region M1 of the middle segment, a similar range of ultrastructural features of the principal cells were observed throughout the remainder of the epididymis.

In the hopping mouse, the initial segment occupied a much smaller proportion of the epididymis, (Fig. 7.2b) than was observed in the plains rat. It was composed of 10-15 closely packed cross-sectional profiles through the duct and was located directly beneath the ductuli efferentes at the cranial pole of the epididymis. As in the plains rat, the initial segment was partially separated from the remainder of the epididymal duct by a thin connective tissue septum. The height of the epithelium was slightly less than that of the corresponding segment in the plains rat, with the principal cells averaging $47.2 \pm 4.8 \mu\text{m}$ in height (Table 7.2) and possessing numerous long ($\sim 15 \mu\text{m}$) stereocilia. The nuclei of the principal cells were pale and highly irregular in outline and a distinct pale-staining

supranuclear region devoid of granules and vesicles, (and which electron microscopy subsequently revealed to contain the Golgi complexes) was evident (Figs 7.22 and 7.23). The remainder of the apical cytoplasm contained numerous small vesicles and granules. Cells with apically located nuclei were occasionally observed within the epithelium. Relatively few spermatozoa were present within the lumen of the epididymal duct, which averaged $51 \pm 7 \mu\text{m}$ in diameter (Table 7.2) and was surrounded by a layer of one to three smooth muscle cells external to the epithelium.

Adjacent to the initial segment the luminal diameter of the epididymis decreased significantly to only $34 \pm 7 \mu\text{m}$ and epithelial height also decreased. This signified the beginning of region M1 of the middle segment, which occupied the remainder of the caput epididymidis and extended into the corpus epididymidis in some individuals (Fig. 7.2b). The principal cells of the epithelium within this region were relatively uniform in appearance (Fig. 7.24), in contrast to those in the remainder of the middle and terminal segments, where morphology was somewhat variable. In addition to the principal cells, basal cells and occasional narrow cells with irregularly shaped nuclei (Fig. 7.24) were also observed.

Table 7.2
Height of the Epithelium and Diameter of the Lumen of the Ductuli Efferentes and Ductus Epididymidis of the Hopping Mouse, *Notomys alexis*.*

	Height of the Epithelium (μm)	Diameter of Lumen (μm)
<u>Ductuli Efferentes</u>	18.9 ± 2.7	23 ± 7
<u>Epididymis[#]</u>		
Initial Segment	47.2 ± 4.8	51 ± 7
Middle Segment		
region M1	24.2 ± 8.7	34 ± 7
region M2, site 1	24.2 ± 2.4	61 ± 6
region M2, site 2	28.8 ± 4.1	68 ± 8
region M2, site 3	24.2 ± 3.8	82 ± 15
Terminal Segment	21.2 ± 6.2	153 ± 39

* All figures are means \pm S.D. on at least ten measurements from each site for each of four animals.

The regions of the ductus epididymidis from which measurements were taken are indicated on Fig. 7.2b.

Plate 18 Light Microscopic Structure of the Epididymis of the Hopping Mouse.

Note the marked differences in structure and sperm abundance, as compared with the corresponding segments of the plains rat epididymis (Plates 13 and 14).

Figure 7.22

Initial segment of the hopping mouse epididymis. Luminal diameter is considerably narrower than that of the corresponding segment in the plains rat (refer to Fig. 7.5).

bar = 40 μm

Figure 7.23

Epithelium of the initial segment. A paler supranuclear region (G) containing the Golgi complexes is evident.

bar = 10 μm

Figure 7.24

Region M1 of the middle segment of the epididymis showing the decrease in diameter of the epididymal duct and shorter epithelium as compared with the initial segment.

bar = 40 μm

Figure 7.25

Epithelium of region M1 of the middle segment showing large vacuoles (arrows) in the principal cells.

bar = 15 μm

Figure 7.26

Region M2 of the middle segment of the epididymis. The micrograph shows the appearance of the duct at site 2 (lower corpus epididymidis) as indicated on Fig. 7.2b.

bar = 40 μm

Figures 7.27 and 7.28


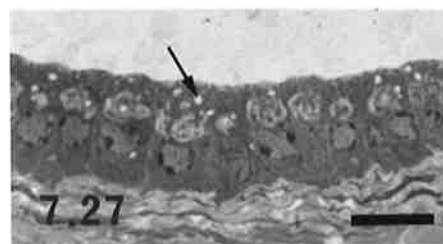
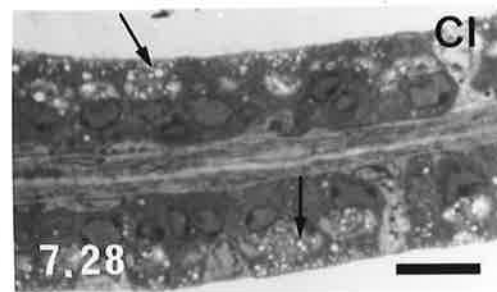
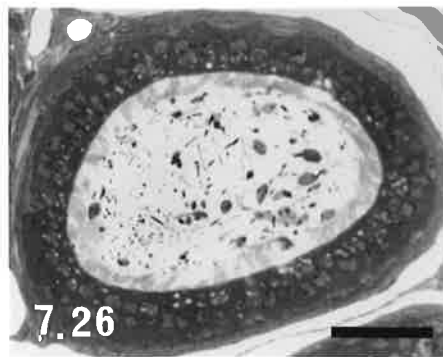
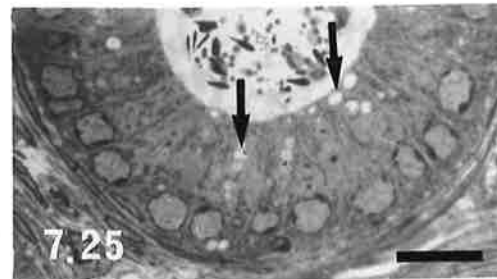
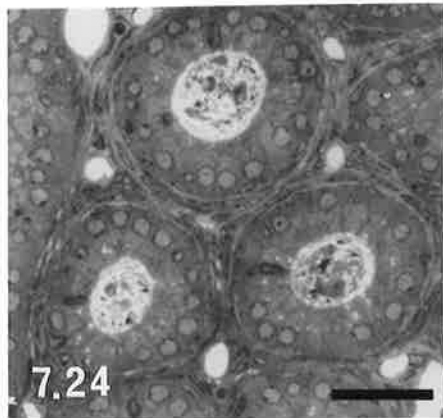
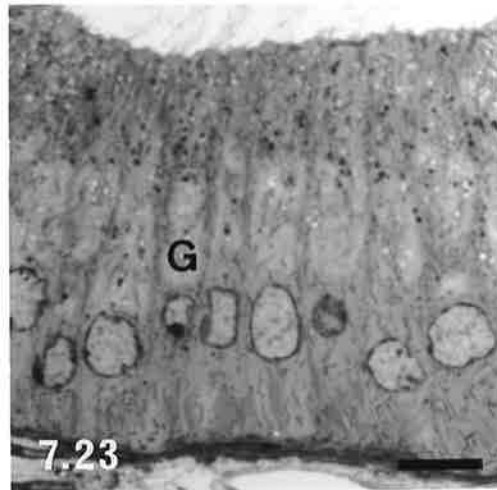
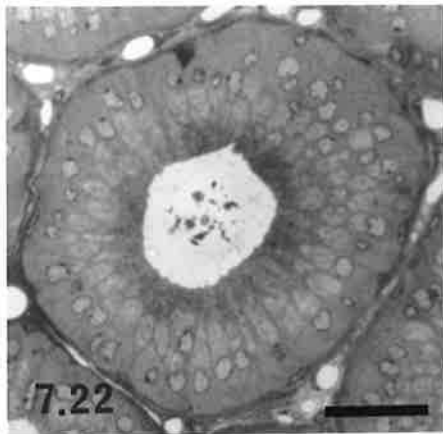
Epithelium at two different locations within region M2 of the middle segment. Fig. 7.27 is from site 2, whereas Fig. 7.28 is from site 3. Note the pale-stained supranuclear cytoplasm of the principal cells and the numerous apical vacuoles (arrows), particularly in Fig. 7.28. (Cl) = clear cell.

bar = 15 μm (both figures)

Figure 7.29

Epithelium of the terminal segment of the epididymis. Note the similarities to that of region M2 of the middle segment, apart from an increase in thickness of the smooth muscle (SM) layer.

bar = 15 μm



The basal cells were similar in appearance to those described in the plains rat epididymal epithelium and had ovoid nuclei that occupied most of their pale cytoplasm. The principal cells averaged $24 \pm 8 \mu\text{m}$ in height (Table 7.2) and possessed round, basally located, nuclei containing a nucleolus and accumulations of heterochromatin beneath the nuclear envelope. Variable numbers of large vacuoles occupied the apical cytoplasm and occasionally extended downwards to the level of the cell's nucleus (Fig. 7.25). Small, intensely stained granules, similar to those in the principal cells of the initial segment, were also observed in the cytoplasm in some individuals, but were absent from others. The cytoplasm of the principal cells was relatively uniformly stained and a distinct supranuclear Golgi region was not observed. Long stereocilia of up to $15 \mu\text{m}$ in length extended into the lumen and a band of smooth muscle of between one and three cell's thickness encircled the duct.

An abrupt change in the morphology of the epithelial principal cells, which was accompanied by an increase in the diameter of the epididymal lumen, designated the beginning of region M2 of the middle segment. This usually occurred in the vicinity of the junction between the caput and corpus epididymides (Fig. 7.2b). In region M2, the principal cell nuclei were less regular in shape than in region M1, contained larger clumps of heterochromatin and occupied a more variable position within the cell, ranging from basal to central in location (Fig. 7.26). Numerous small and large vacuoles filled the apical cytoplasm and a pale region was evident above the nucleus (Fig. 7.27). Granules were seen in some cells, but these were generally sparse. In some individuals the stereocilia had a brush border appearance while in others they appeared to be less densely distributed and bent at an angle to the apex of the cells.

Clear cells were not as common in the hopping mouse as in the plains rat epididymal epithelium and were first observed about midway through region M2 of the middle segment. Their morphology was similar to that seen in the plains rat, with granules and vacuoles filling most of the cytoplasm. In hopping mouse clear cells, however, the pale staining nucleus was more variable in position, granules were distributed throughout the cytoplasm and did not stain as intensely with toluidine blue and vacuoles were smaller than those seen in plains rat clear cells. The cells themselves were narrower in diameter and not as easily distinguishable from the principal cells within the epithelium (Fig. 7.27).

In the latter half of region M2 of the middle segment (and in the terminal segment), the apical cytoplasm of the principal cells contained an abundance of small vacuoles, although a few granules were also observed in a small number of cells. The supranuclear cytoplasm generally appeared as a prominent unstained area in contrast to the basophilia of the para- and sub-nuclear regions (Fig. 7.28) and was shown by electron microscopy to contain an

extensive network of Golgi complexes. The principal cell nuclei were variable in position and shape, ranging from highly irregular to basically round and contained a nucleolus and several clumps of heterochromatin. Their nucleoplasm was finely granular.

The terminal segment of the hopping mouse epididymis was defined by a marked increase in the diameter of the duct lumen to $153 \pm 39 \mu\text{m}$ in comparison to $82 \pm 15 \mu\text{m}$ of the adjacent portion of the middle segment (Table 7.2) and corresponded to the portion of the cauda epididymidis on side of the caudal flexure connecting to the vas deferens (Fig. 7.2b). The epithelium and the stereocilia decreased in height slightly to $21.4 \pm 6 \mu\text{m}$ and $5\text{-}10 \mu\text{m}$ respectively and the amount of smooth muscle surrounding the duct markedly increased from three to five fibres, to $10\text{-}15 \mu\text{m}$ in thickness (Fig. 7.29). The outermost smooth muscle fibres appeared much larger than those nearest the duct. The duct did not appear as highly coiled as in other regions of the epididymis, with abundant connective tissue containing blood and lymph vessels occupying the areas between duct profiles.

As in the plains rat, three distinct regions of the cytoplasm, ie. apical, supranuclear and basal, could be identified within the principal cells of the terminal segment of the hopping mouse epididymis. In the hopping mouse, however, the supranuclear region of principal cells was more pronounced, due to the presence of many well developed Golgi complexes, pale multivesicular bodies and occasionally, membrane bound dense bodies. The cisternae of the Golgi were usually dilated and loosely stacked (Figs 7.30 and 7.31). Within the multivesicular bodies, spherical or flattened tubular profiles and aggregates of electron-dense material were observed (Fig. 7.31), whereas the dense bodies has a heterogeneous internal structure that often included membranous components and occasionally, lipid (Fig. 7.32). Coated and uncoated pits and vesicles, along with mitochondria, occupied the apical region of the cytoplasm (Fig. 7.31), although their size and number varied from cell to cell. The apical microvilli (stereocilia) were somewhat sparse in comparison to those of the plains rat. In the basal region of the principal cells, RER often formed a whorl-like pattern (Fig. 7.30) or loosely-spaced, wavy, arrays (Fig. 7.33), with a few cisternae encircling the nucleus. The nucleus generally presented a highly irregular profile and scattered mitochondria were observed basally, between the cisternae of RER. Contact of the principal cells with the basal lamina was often via cytoplasmic processes that penetrated between the basal cells of the epithelium.

In the hopping mouse, clear cells were few in number and could not be as easily distinguished from the principal cells as in the terminal segment of the plains rat epididymis. The apical plasmalemma presented few microvillous-like processes, pits and vesicles, although large, pale vacuoles, similar to the multivesicular bodies of principal cells, were present in the apical cytoplasm (Figs 7.34 and 7.35). The nucleus was highly

**Plate 19 Ultrastructure of the Epithelium of the Terminal Segment of the Hopping
Mouse Epididymis**

Figure 7.30

Low power electron micrograph showing the appearance of the epithelium of the terminal segment, which is comprised mainly of principal cells. Relatively sparse microvilli extend into the lumen (Lu) from the apical surface of these cells. Vesicles (arrowheads) of various sizes and mitochondria are the main features within the apical cytoplasm, whereas many Golgi complexes (G) predominateⁱⁿ the supranuclear region of the principal cells. Large multivesicular bodies (stars) are scattered throughout several of the cells which have irregularly-shaped nuclei (N). Rough endoplasmic reticulum (RER) is a prominent feature of the basal cytoplasm. A less intensely stained region of cytoplasm, belonging to a basal cell, can be seen between the bases of the principal cells and the basement membrane towards the left of the micrograph.

My = myoid cell, SM = smooth muscle external to the lamina propria of the terminal segment.

bar = 2.5 μ m

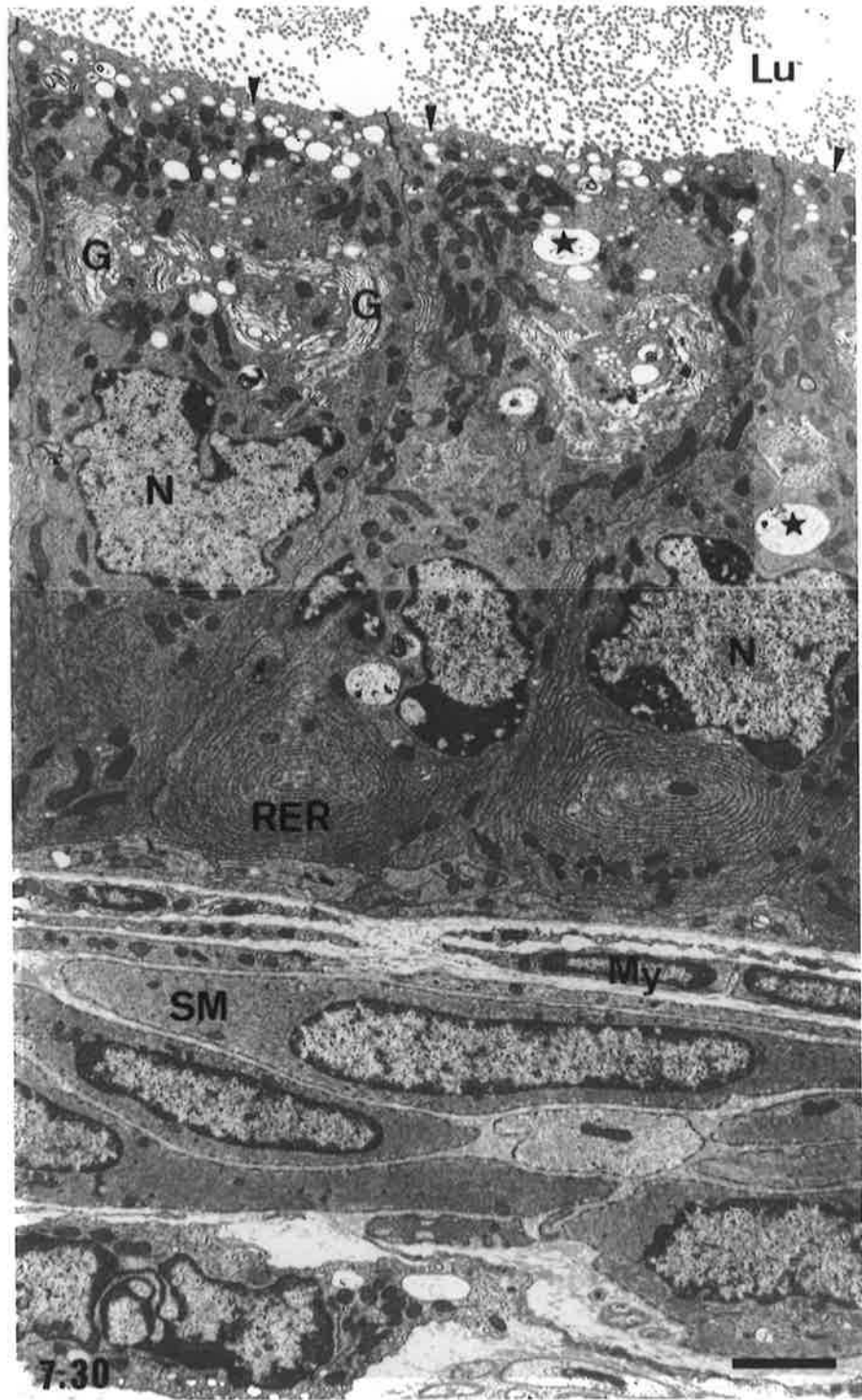


Plate 20 Ultrastructure of Principal Cells within the Terminal Segment of the Hopping Mouse Epididymis

Figure 7.31

Apical and supranuclear regions of a principal cell from the terminal segment of the hopping mouse epididymis. A few pits (p) are in continuity with the apical plasmalemma, between the bases of the microvilli (Mv) and small coated vesicles (cv) and smooth surfaced vesicles (v) are located in the apical cytoplasm between mitochondria. Golgi complexes (G) with dilated cisternae (asterisks) and associated small vesicles are prominent within the supranuclear cytoplasm. Large pale multivesicular bodies (mvp) containing circular (arrow heads) and flattened (arrows) tubular profiles occur above the level of the nucleus (N), which is surrounded by several cisternae of endoplasmic reticulum (ER).

bar = 1 μm

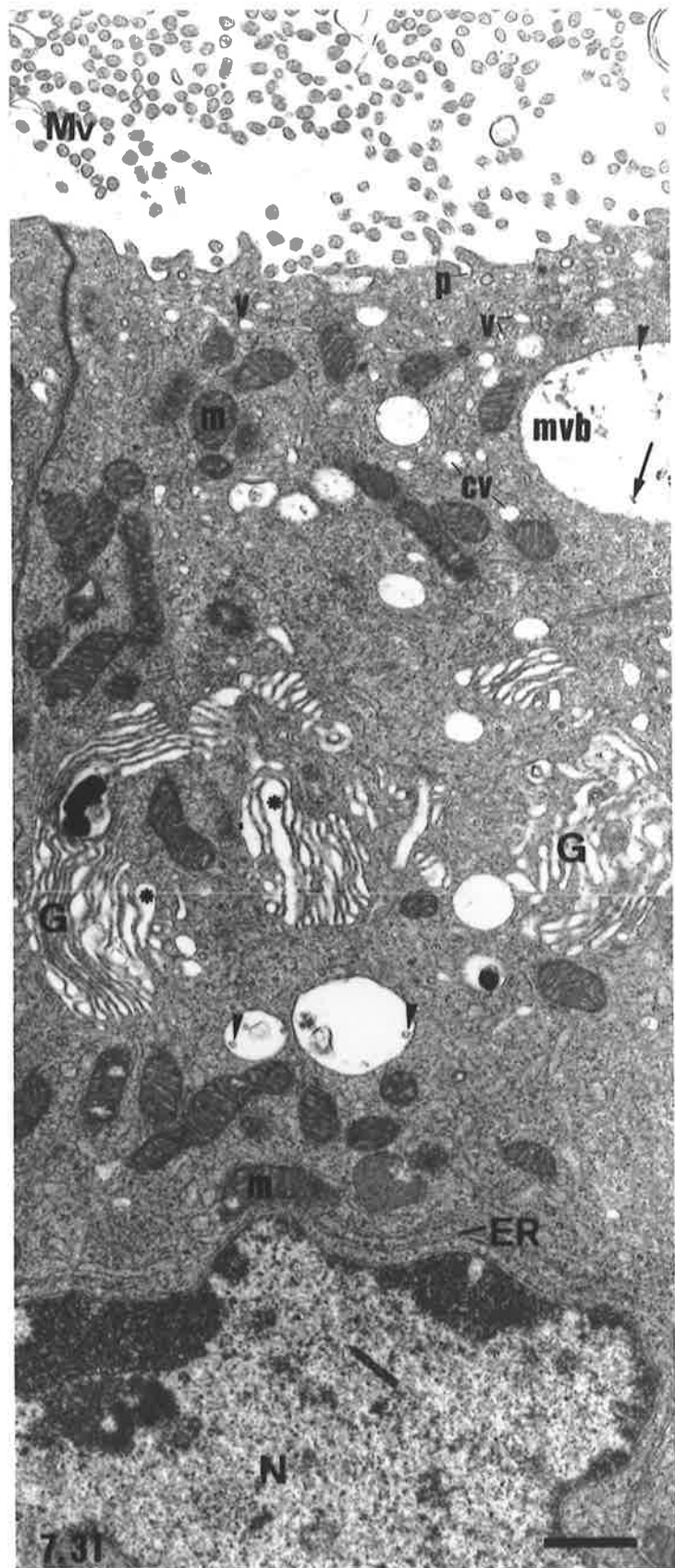


Plate 21 Ultrastructure of Principal Cells within the Terminal Segment of the Hopping Mouse Epididymis

Figure 7.32

High power micrograph of several dense membrane bound bodies situated near the Golgi complexes in the supranuclear cytoplasm of a terminal segment principal cell. The heterogeneous nature of the matrix and the inclusion of lipid droplets (arrows) suggest that these structures are lysosomes.

bar = 0.5 μm

Figure 7.33

Supranuclear and basal regions of a principal cell from the terminal segment of the hopping mouse epididymis. Note again the prominent Golgi complexes (G) within the supranuclear region. Several membrane bound structures containing membranous whorls (arrows) are interspersed among the Golgi. The basal cytoplasm is occupied by a regularly spaced array of rough endoplasmic reticulum (RER), several cisternae of which extend around the nucleus (N). A paler stained basal cell with an elongated nucleus (B) is interposed between the base of the principal cell and the basement membrane (bm).

bar = 1 μm

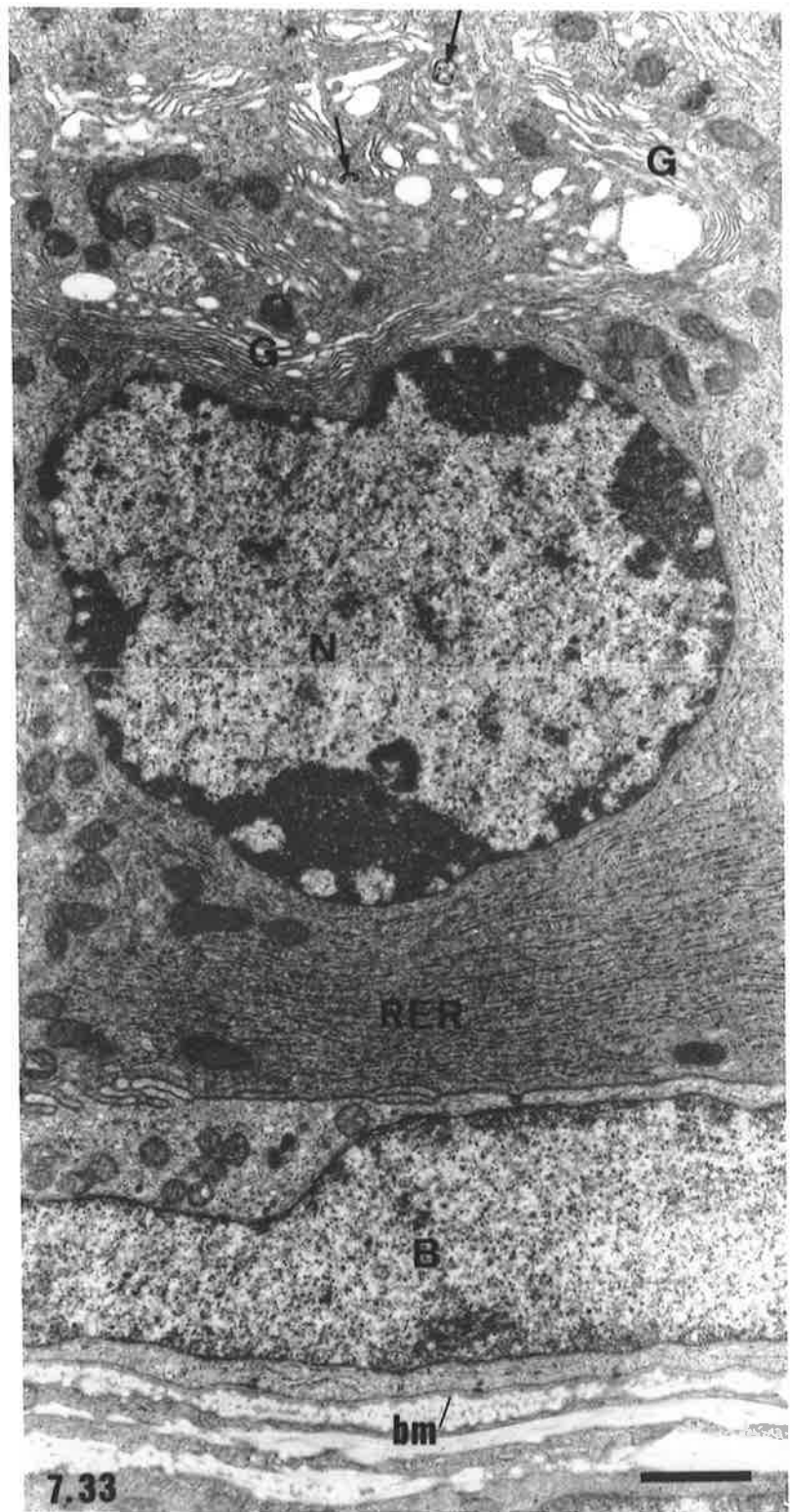
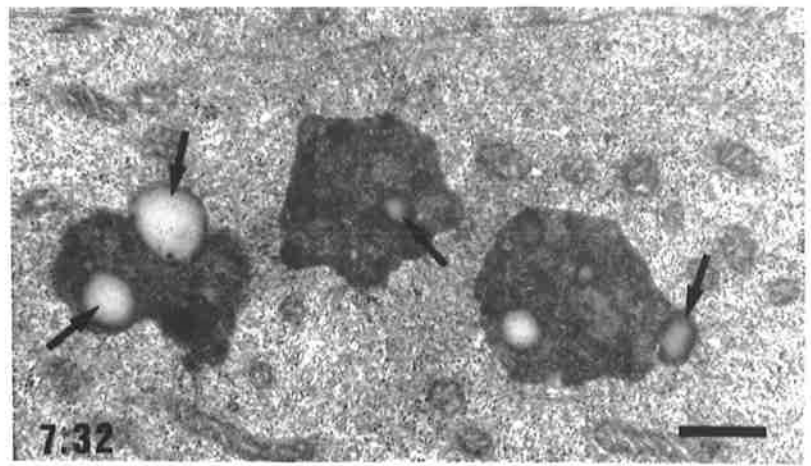


Plate 22 Ultrastructure of Clear Cells within the Terminal Segment of the Hopping Mouse Epididymis

Figure 7.34

A clear cell within the terminal segment epithelium of the hopping mouse epididymis. Note a lack of microvilli on the apical surface of the cell and very few small apical vesicles and large vacuoles in comparison with clear cells of the plains rat terminal segment (refer to Fig. 7.16). The large vacuoles (mvb) in the hopping mouse clear cell are structurally identical to those of the adjacent principal cells of the epithelium (compare with Figs 7.31 and 7.32). Spherical and flattened particles (arrow heads) are contained within them. Electron dense membrane bound bodies are scattered throughout the cytoplasm and several appear to indent the nucleus (N). The cell appears to taper towards the base of the epithelium.

Lu = lumen, PC = principal cell.

bar = 2 μm

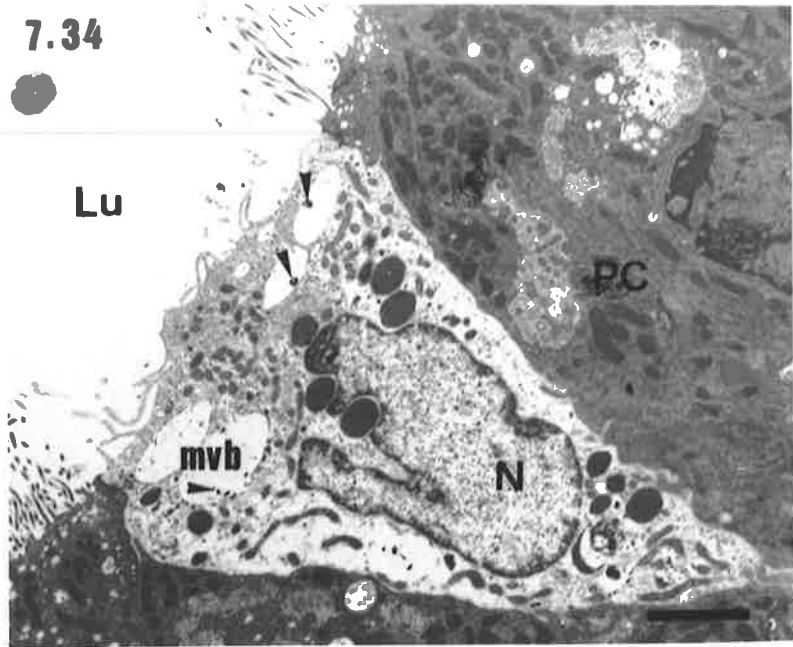
Figure 7.35

Higher power view of a second clear cell of the terminal segment. The cytoplasm of this clear cell is more electron dense than that of the clear cell in Fig. 7.43, hence the cell is not as readily distinguishable from the adjacent principal cells (PC). Mitochondria (m), large vacuoles (mvb) containing dense particles (arrow heads) and dense membrane bound bodies (dmbb) with small inclusions (arrows) are the main features of the cell's cytoplasm. As in the previous clear cell, the nucleus (N) is highly irregular in shape.

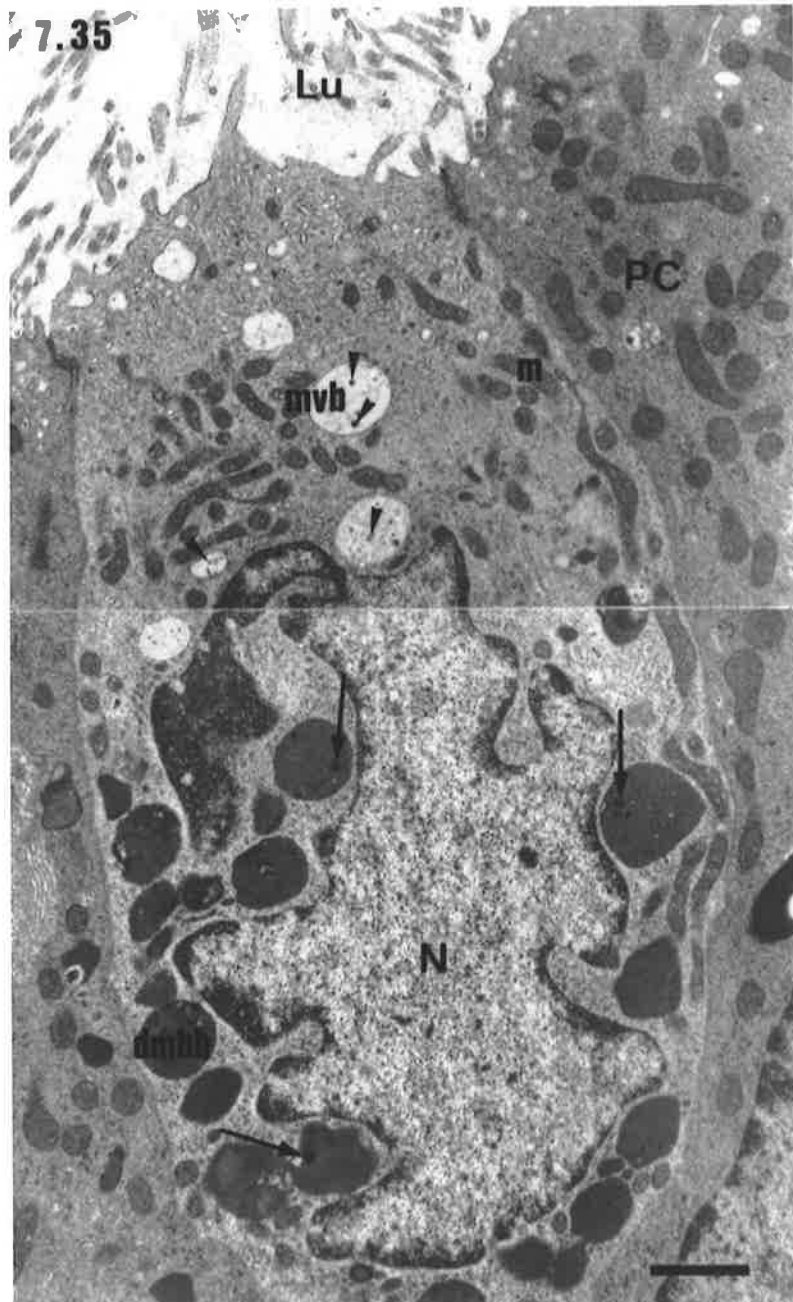
Lu = lumen.

bar = 1 μm

7.34



7.35



irregular in shape and variable in position, ranging from within the basal one third of the cytoplasm, to close to the apical surface of the cell. The large multivesicular bodies and electron dense membrane bound bodies, possibly lysosomes, were the predominant features of the cytoplasm, along with elongated mitochondria. Unlike in the plains rat, where the multivesicular bodies were located above and the electron dense membrane bound bodies below the level of the nucleus, the intracellular distribution of these structures was highly variable in the hopping mouse, with the electron dense membrane bound bodies often scattered throughout the cytoplasm. In many sections, clear cells were observed to taper basally (Fig. 7.34) and appeared to have only a small area of contact with the basal lamina of the epithelium.

7.3.2.3 Vas Deferens

Light Microscopy

In transverse section, the epididymal segment of the vas deferens (refer to Figs 7.1b and 7.2b) of both species presented a round to ovoid lumen surrounded by a columnar epithelium, a thin, highly vascular, lamina propria and a muscle coat of variable thickness arranged into inner circular and outer longitudinal layers (Figs 7.36 and 7.37). In the plains rat, the entire muscle coat, which in the majority of individuals was asymmetrically arranged around the duct lumen, had a width of between 50 μm and 120 μm . In those regions where the thickness of the muscle coat was reduced, the majority of the fibres had a circular orientation, with fewer fibres in the outer longitudinally oriented layer. A more uniformly arranged muscle coat of 60-100 μm in diameter surrounded the epididymal segment of the vas deferens of the hopping mouse (Fig. 7.37).

Marked interspecific differences in luminal shape and muscle coat thickness were observed in the urethral segment of the vas deferens. In the plains rat, between four and eight infoldings of the epithelial lining and the underlying lamina propria occurred and the majority of the spermatozoa within the duct were confined to the central region of the lumen into which the mucosal folds did not penetrate. The muscle was much thicker than that of the epididymal segment and ranged from 160-400 μm in thickness (Fig. 7.38). In the hopping mouse, very extensive folding of the mucosa into the lumen was observed along the entire length of the urethral segment of the vas deferens (Figs 7.39 and 7.40). Commencement of the infolded mucosa (Fig. 7.41) coincided with an abrupt increase in the diameter of the duct lumen approximately two fifths of the distance between the connections of the vas deferens with the epididymis and ejaculatory duct. Scanning electron microscopy (SEM) revealed that these infoldings were comprised of a complex pattern of circular folds and longitudinal ridges that extended almost the entire luminal

width (Figs 7.42 and 7.43). A central region devoid of mucosal folds was not prominent in either transverse (Figs 7.39 and 7.40) or longitudinal (Fig. 7.44) sections of vas deferens, however the presence of a narrow central canal was confirmed from the SEM images (Figs 7.42 and 7.43). The muscle coat of the urethral segment was similar in thickness to that of the epididymal segment (60-115 μm cf. 60-100 μm), except at the terminal end of the vas deferens where it was reduced to 25-50 μm in width (Fig. 7.40). Most of the reduction in thickness was due to a narrower inner circular layer of muscle.

Histologically, the epithelium of the vas deferens was similar to that lining the ductus epididymidis, with basal and principal cells comprising the bulk of the epithelium. Scattered clear cells persisted into the epididymal segment in the plains rat (refer to Fig. 7.36), but very few clear cell were observed in the vas deferens of the hopping mouse and usually only in the region immediately continuous with the terminal segment of the epididymis.

In the plains rat, principal cells increased in height with increasing distance from the connection of the vas deferens with the epididymis and ranged from 15-25 μm in the epididymal segment, to 30-60 μm in the urethral segment. By contrast, the principal cells of the hopping mouse vas deferens were tallest at the junction between the epididymal and urethral segments. In this region they were 45-55 μm in height, as compared with a height of 25-40 μm along the remainder of the length of the duct.

Ultrastructure of Principal Cells of the Plains Rat Vas Deferens

In the plains rat, principal cells from the epididymal segment of the vas deferens (Fig. 7.45) showed many ultrastructural features in common with cells lining the terminal segment of the epididymis, although there was a reduction in the abundance of organelles within the apical and supranuclear cytoplasm. Microvilli extended from the apical surface of the cells and small numbers of coated pits, coated and smooth surfaced vesicles, multivesicular bodies and mitochondria were located in the apical cytoplasm (Fig. 7.46). Golgi complexes were a prominent feature of the supranuclear region of the cells, although they contained fewer saccules than were observed in principal cells of the epididymis. The nucleus was irregular in outline and occupied a central position, below which were located mitochondria and a network of endoplasmic reticulum with fewer ribosomes (Fig. 7.37) than in the corresponding cells of the terminal segment of the epididymis.

With increasing distance from the epididymis, there was a gradual change in the morphology of the principal cells, such that near the terminal end of the vas deferens (Fig. 7.48) differences in structure, compared with the principal cells of the epididymis, were

Plate 23 Vas Deferens of the Hopping Mouse and Plains Rat.

Figure 7.36

Transverse section of the epididymal segment of the plains rat vas deferens rat showing a circular lumen to the duct and the persistence of a few clear cells (arrows) in the epithelial lining.

bar = 150 μm

Figure 7.37

Transverse section of the epididymal segment of the hopping mouse vas deferens. As in the plains rat, the lumen of the duct shows a regular, circular profile.

bar = 100 μm

Figure 7.38

Urethral segment of the vas deferens of the plains rat showing infolding of the epithelium and underlying lamina propria. Note the increase in thickness of the muscle layer as compared with that of the proximal segment shown in Fig.7.36.

CC = central canal of the lumen, LP = lamina propria, SM = smooth muscle layer of the duct wall.

bar = 100 μm

Figure 7.39

Urethral segment of the vas deferens of the hopping mouse showing a highly infolded epithelium and lamina propria. The smooth muscle (SM) of the duct wall is similar in thickness to that of the epididymal segment (Fig. 7.37). Note the absence of a well defined central lumen to the duct.

bar = 100 μm

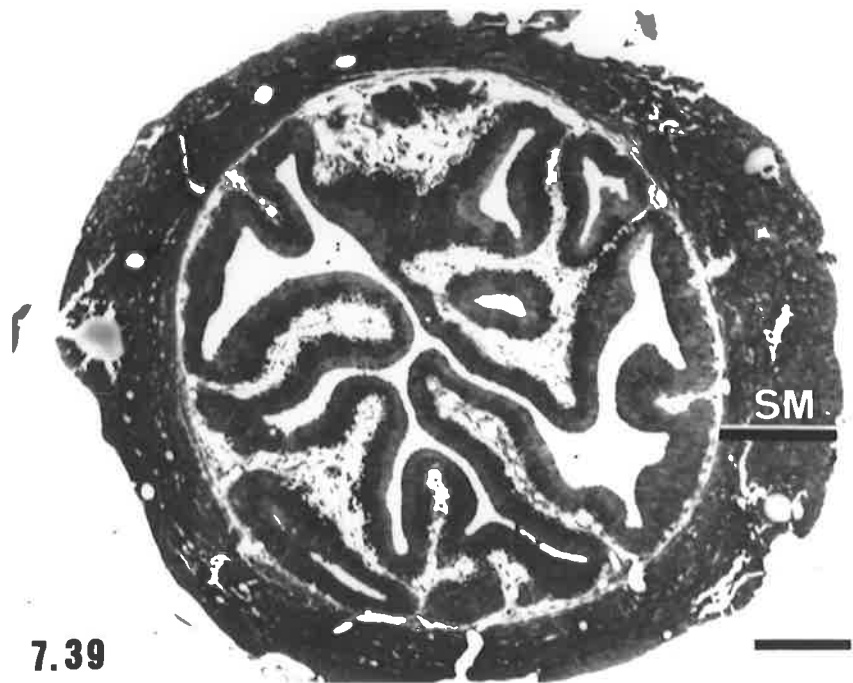
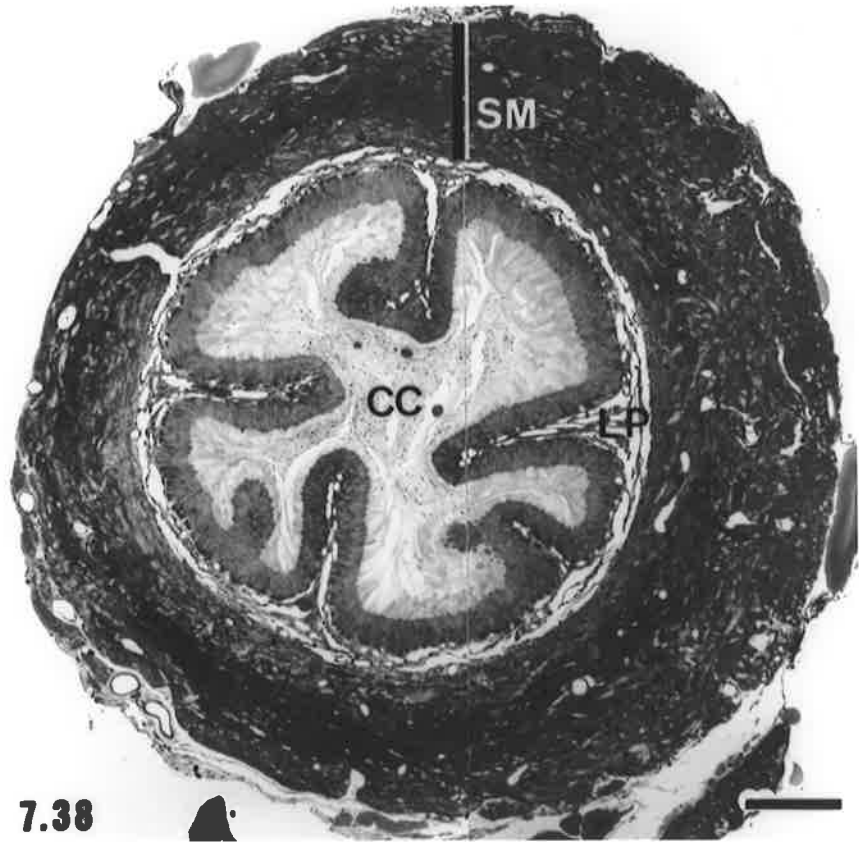
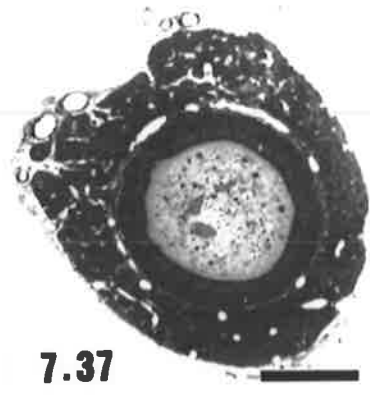
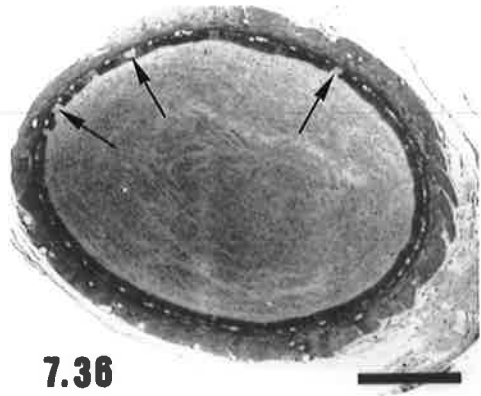


Plate 24 Vas Deferens of the Hopping Mouse

Figure 7.40

Transverse section of the terminal portion of the urethral segment of the vas deferens of the hopping mouse showing extensive infolding of the mucosa and a reduced thickness of the smooth muscle coat (SM) as compared with the epididymal segment and the more proximal portion of the urethral segment (compare with Figs 7.37 and 7.39 respectively).
f = mucosal folds extending into the duct lumen, Ca = capillary network within the lamina propria of the folds.

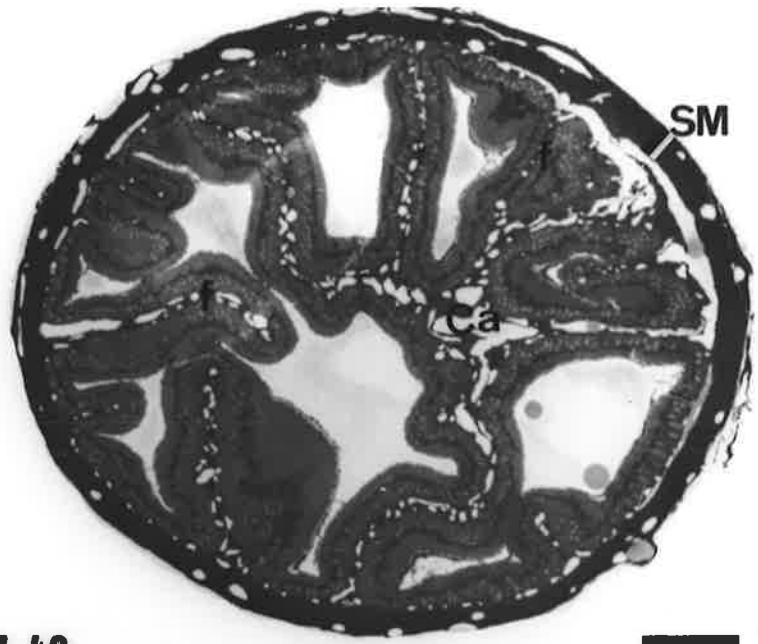bar = 100 μm

Figure 7.41

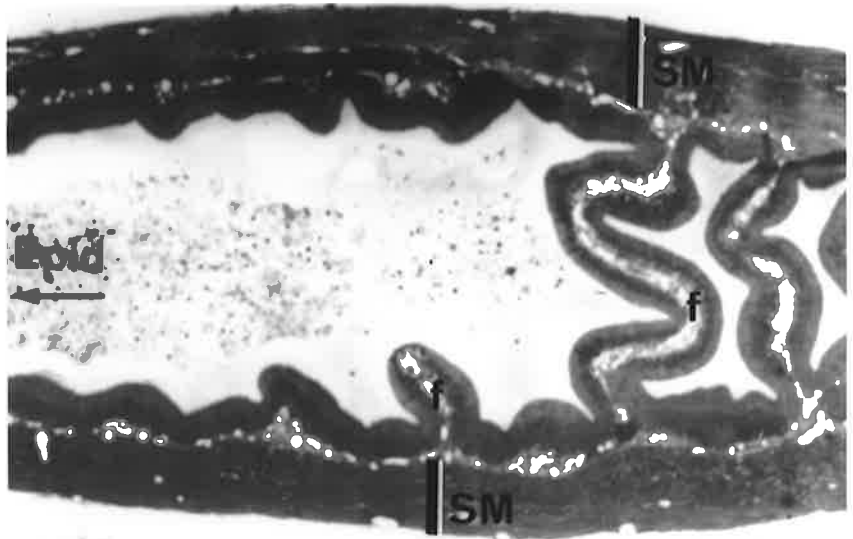
Longitudinal section of the junctional area between the epididymal and urethral segments of the hopping mouse vas deferens where folding of the mucosa into the duct lumen commences. The mucosal folds (f) increase in length and complexity of folding towards the urethral end of the vas deferens.

Epid = epididymal segment, SM = smooth muscle of the duct wall.

bar = 100 μm



7.40



7.41

Plate 25 Vas Deferens of the Hopping Mouse

Figures 7.42 and 7.43

Scanning electron micrographs of the urethral segment of the hopping mouse vas deferens showing transverse (Fig. 7.42) and longitudinal (Fig. 7.43) views of the pattern of mucosal folding into the duct lumen.

f = cut surfaces of the mucosal folds, Lu = lumen of the duct.

bar = 100 μm for both micrographs.

Figure 7.44

Longitudinal section of the urethral segment of the vas deferens showing the complex pattern of folding of the mucosa. A thin core of lamina propria (arrows) supports the epithelium of the folds.

Lu = lumen.

bar = 100 μm

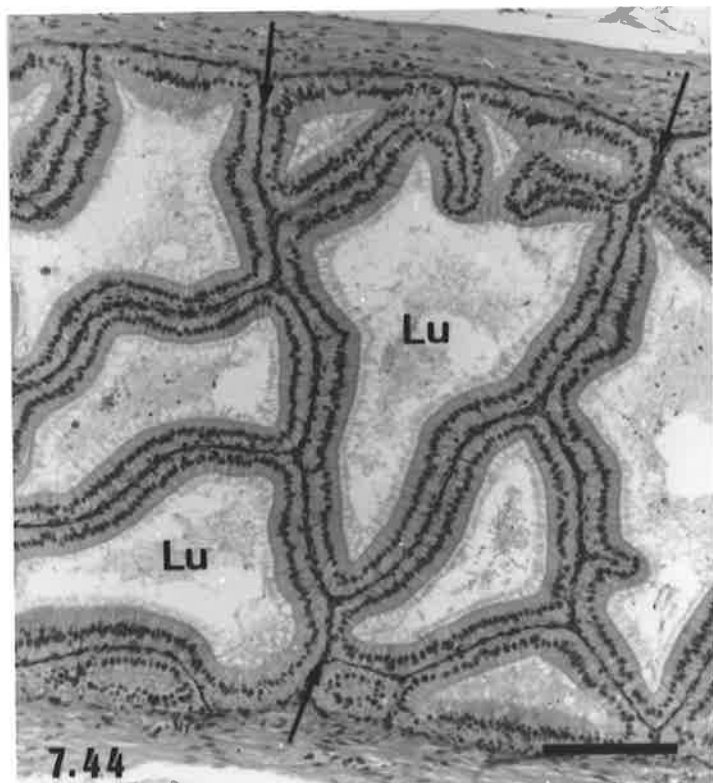
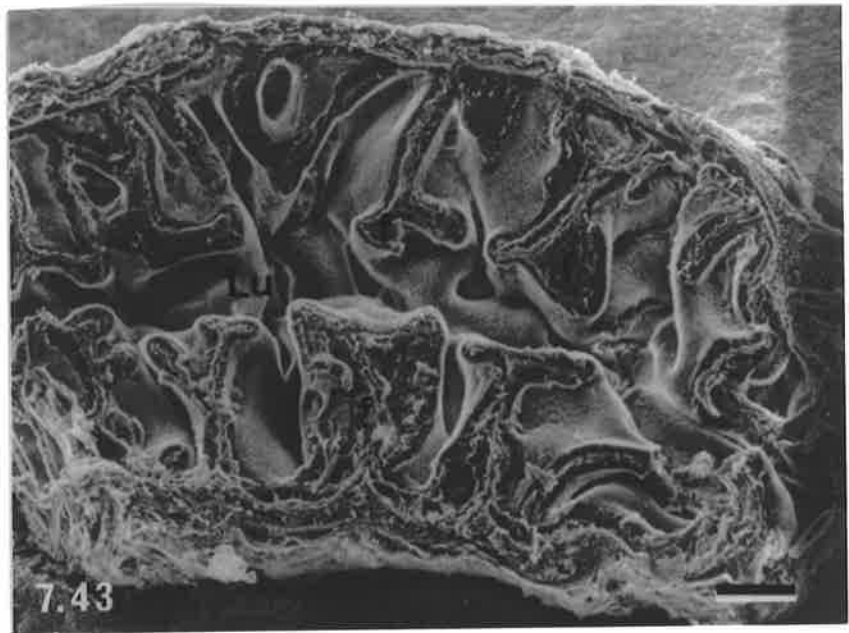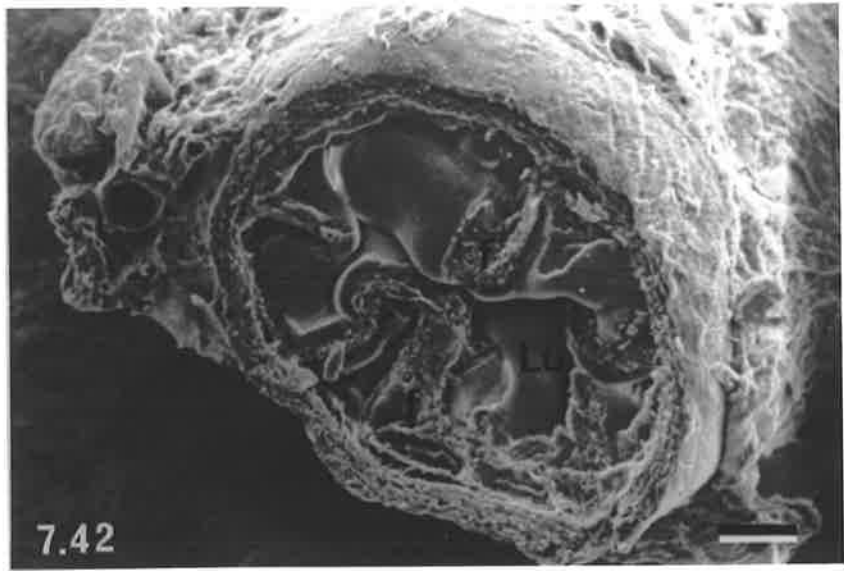


Plate 26 Ultrastructural Features of the Epididymal Segment of the Plains Rat Vas Deferens

Figure 7.45

Low power view of the epithelium of the epididymal segment of the plains rat vas deferens. A clear cell (Cl) containing basally located dense membrane bound bodies (stars) and a basal cell (B) are shown in addition to the principal cells. Microvilli (Mv) extend into the lumen from the apical surfaces of the principal cells and multivesicular bodies (asterisks) are prominent in the apical cytoplasm. Lysosomes with associated lipid (arrows) and rough endoplasmic reticulum (RER) occur in the vicinity of cell's nucleus (N).

LP = lamina propria beneath the epithelium.

bar = 2.5 μm

Figure 7.46

Higher power view of the apical region of a principal cell showing sparse vesicles (arrow heads), pale multivesicular bodies (mvb) containing flattened tubular profiles (arrows) and occasional shallow pits (p) between the microvilli (Mv).

bar = 1 μm

Figure 7.47

Basal region of the epithelium showing an abundance of rough endoplasmic reticulum (RER) below the nucleus (N) of a principal cell and a basal cell (B). Note the elongated cytoplasmic extensions of the basal and lateral surfaces of the principal cell (arrows).

LP = lamina propria.

bar = 1 μm

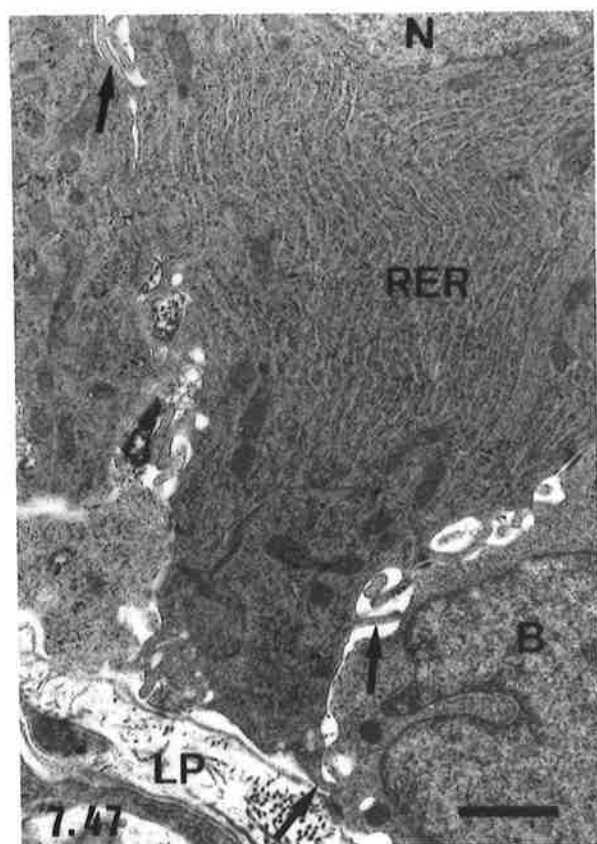
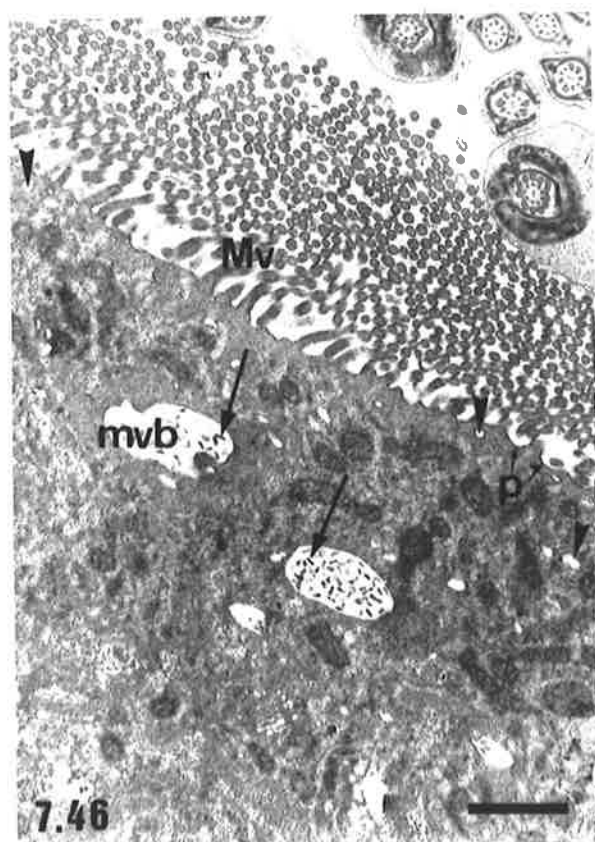
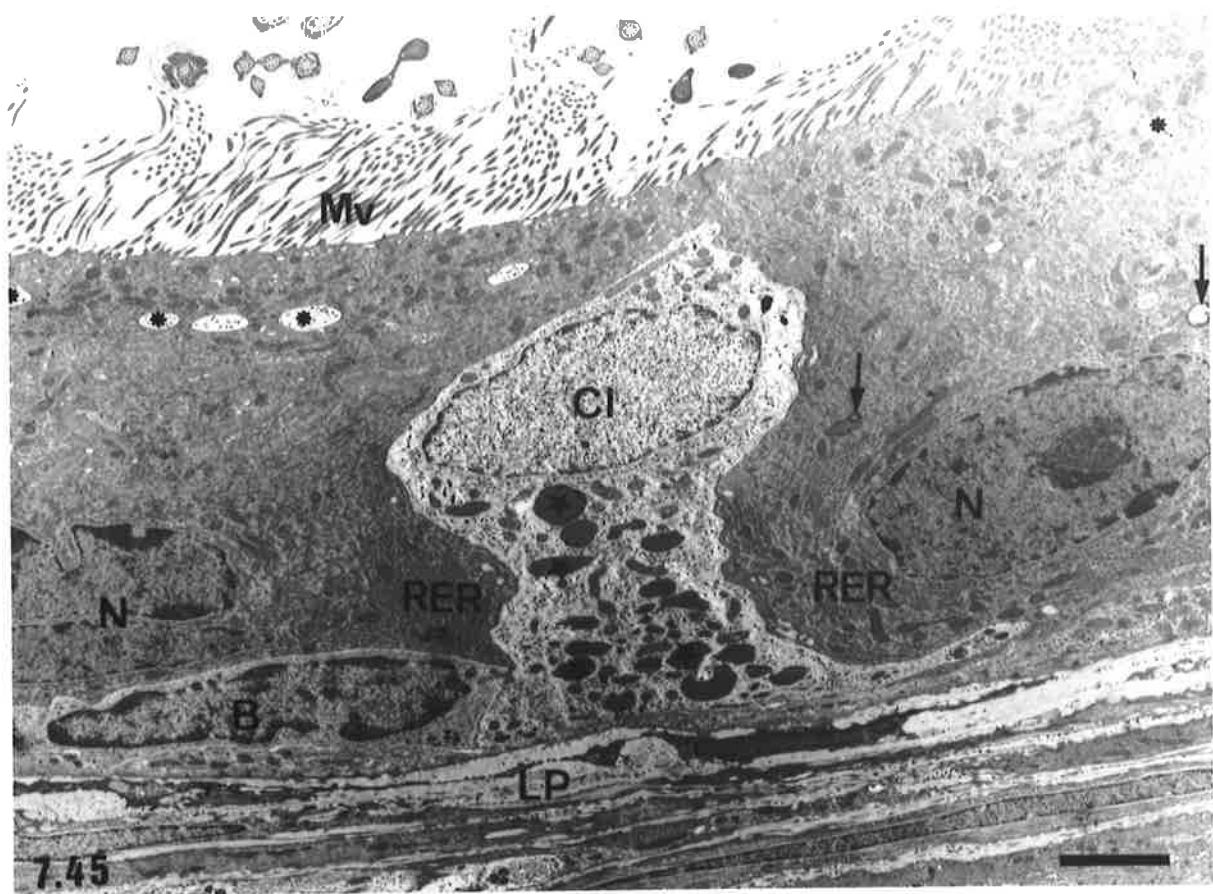


Plate 27 Ultrastructural Features of the Urethral Segment of the Plains Rat Vas Deferens

Figure 7.48

Low power electron micrograph of the epithelium of a mucosal fold of the urethral segment. Several of the principal cells show a band of small vesicles directly beneath the apical plasmalemma (arrow heads). Abundant endoplasmic reticulum (ER) occupies the cytoplasm, generally below the nucleus (N). Microvilli (Mv) extend from the apical surfaces of the principal cells into the lumen (Lu), which contains numerous spermatozoa. sh = sections through a sperm head, t = sections through sperm tail.

bar = 5 μm

Figure 7.49

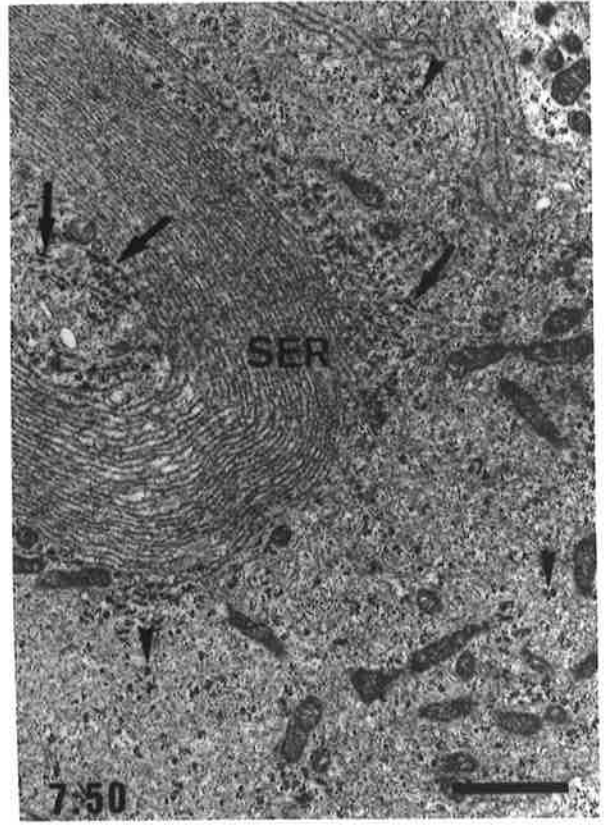
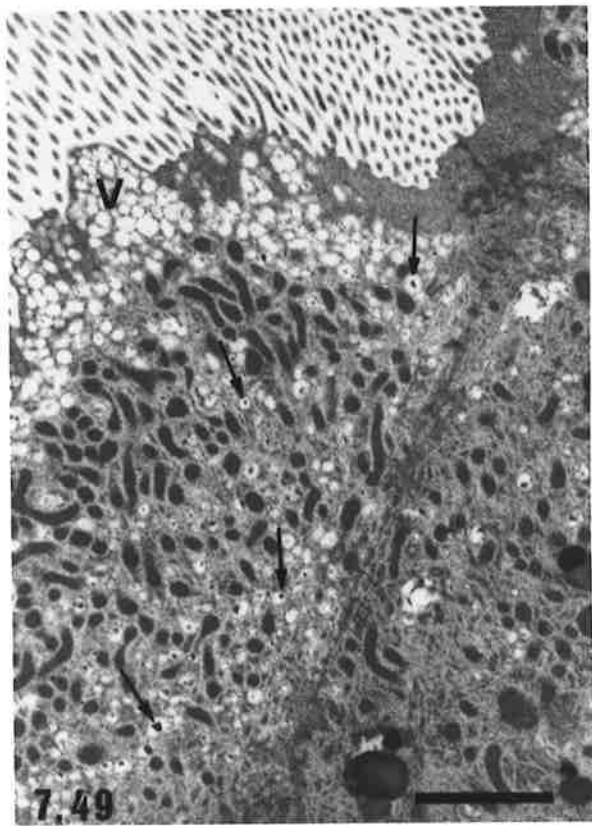
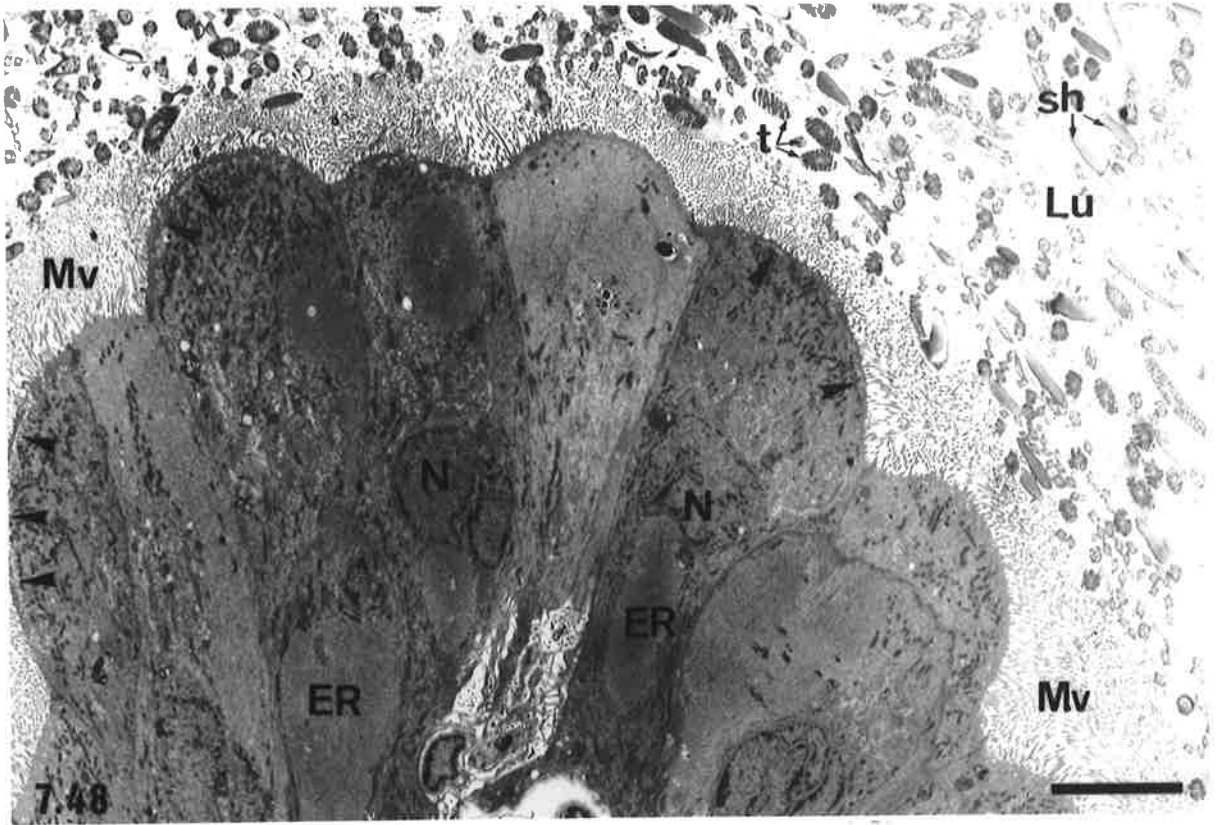
Apical region of a principal cell showing a prominent band of small smooth surfaced vesicles (V) beneath the plasmalemma. Many of the vesicles deeper within the cell's cytoplasm contain small electron dense particles (arrows).

bar = 2 μm

Figure 7.50

Basal region of a principal cell showing a prominent whorl of smooth endoplasmic reticulum (SER), occasional strands of RER (arrows) and numerous clusters of free ribosomes (arrow heads) within the cytoplasm.

bar = 1 μm



obvious. In the urethral segment of the vas deferens, a prominent band of smooth surfaced vesicles was often observed in the apical cytoplasm immediately below the microvilli (Figs 7.48 and 7.49). Below these vesicles were numerous mitochondria and a few membrane bound dense bodies. Golgi complexes were sparse and the nucleus was usually centrally located within the cell. Within the basal cytoplasm, parallel arrays or whorl-like patterns of closely spaced, predominantly smooth, endoplasmic reticulum occurred (Fig. 7.50). These were often accompanied by membrane bound, electron lucent vacuoles and mitochondria close to the basal cell surface.

Ultrastructure of Principal Cells of the Hopping Mouse Vas Deferens

The principal cells of the hopping mouse vas deferens had many ultrastructural features in common with those of the terminal segment of the epididymis, although a large range of variation in the abundance and distribution of organelles between cells within a particular segment of the vas deferens was observed. In the epididymal segment of the duct, apically located vesicles were generally sparse (Figs 7.51 and 7.53), but in a few cells numerous smooth surfaced vesicles formed a distinct band beneath the apical plasmalemma (Fig. 7.52). In most principal cells, mitochondria were abundant in both the apical and basal regions, however, a decrease in the number of multivesicular bodies as compared with principal cells of the terminal segment of the epididymis was generally observed. The multivesicular bodies contained circular and flattened tubular profiles and membranous whorls and structures similar to those in the multivesicular bodies were often seen in the lumen of the vas deferens and associated with the apical surfaces of principal cells. Golgi complexes were less prominent than in the principal cells of the terminal segment of the epididymis, although they were still the major feature of the supranuclear cytoplasm, along with an increased incidence of heterogeneously staining lysosomes containing membranous profiles (Fig. 7.53). In a few cells, moderate amounts of lipid were present in the basal cytoplasm (Fig. 7.51), which also contained an extensive network of RER.

In the region of the vas deferens designated the intermediate segment, where folding of the mucosal lining into the lumen and an increase in the diameter of the duct occurred (see Fig. 7.2b), there was a further reduction in the number of apical pits and vesicles (Figs 7.54-7.56). Mitochondria were, however, numerous, particularly in the apical cytoplasm and a few large multivesicular bodies were situated apical to the Golgi complexes. The Golgi complexes were generally fewer in number and less elaborate in their arrangement than in the epididymal segment of the vas deferens, although a similar distribution of membrane bound dense bodies, some containing small amounts of lipid (Fig. 7.55) was observed. The basal cytoplasm was similar in its organelle content and arrangement to that of the cells lining the more proximal regions of the duct, with rough endoplasmic

reticulum being the predominant cytoplasmic component.

In the urethral segment of the vas deferens, many of the principal cells displayed cytoplasmic protrusions into the lumen, from which extended branched microvilli (Figs 7.57 and 7.58). Similar protrusions of the apical cytoplasm were also observed in the intermediate segment (see Fig. 7.54). Coated pits and vesicles were rare, but a few smooth-surfaced vesicles, occasional small multivesicular bodies and mitochondria were relatively evenly distributed throughout the apical and supranuclear cytoplasm (Figs 7.58-7.60). Occasionally, dense bodies containing a small amount of lipid were observed near the nucleus (Fig. 7.57). Golgi complexes with dilated cisternae (Fig. 7.61) were still a major component of the supranuclear cytoplasm, although they were not as extensive or elaborate as those observed in the principal cells of the terminal segment of the epididymis or the epididymal segment of the vas deferens. Rough endoplasmic reticulum was the predominant component of the cytoplasm below the level of the nucleus. The same types of tubular inclusions and membranous whorls as observed in the previous segments of the vas deferens and the terminal segment of the epididymis were present in the multivesicular bodies. A number of the principal cells had only a small area of contact with the basal lamina, due to the presence of attenuated basal cells (Fig. 7.57) at the base of the epithelium.

7.4 Discussion

7.4.1 Gross Anatomy

The gross anatomy of the excurrent ducts in the plains rat and hopping mouse followed the pattern documented for most other rodents, with five major regions corresponding to the ductuli efferentes, caput, corpus and cauda epididymides and vas deferens distinguishable. As in the laboratory rat (Reid and Cleland, 1957) and laboratory mouse (Benoit, 1926; Abou-Haila and Fain-Maurel, 1984) the epididymal duct of plains rats was highly coiled and arranged into lobules delimited by partial connective tissue septae arising from the capsule surrounding the organ. In hopping mice, however, the epididymis displayed relatively less coiling and no segmentation into lobules was apparent, a situation similar to that found in the common shrew (Suzuki and Racey, 1984) and several marsupial species, including the honey possum (Cummins *et al.*, 1986). These features are probably a reflection of the shorter total length of the epididymal duct in the hopping mouse as compared with other rodent species.

**Plate 28 Ultrastructural Features of the Epididymal Segment of the Hopping Mouse
Vas Deferens**

Figure 7.51

Low power electron micrograph showing the epithelium of the epididymal segment of the vas deferens. Note the structural similarities between the principal cells of this region and the terminal segment of the epididymis (refer to Fig. 7.30). In comparison with the principal cells of the terminal segment, few pits and vesicles are evident within the apical cytoplasm and the number and size of pale multivesicular bodies (asterisks) are reduced, although Golgi complexes (G) remain a prominent feature of the supranuclear region. Small amounts of lipid (arrow heads), not seen in the terminal segment, are present within the basal cytoplasm.

N = nuclei of principal cells, B = basal cell with less electron dense cytoplasm, bm = basement membrane.

bar = 2.5 μm

Figure 7.52

Apical region of a principal cell showing an abundance of smooth-surfaced vesicles (arrows) arranged as a band directly beneath the plasmalemma. Other randomly distributed vesicles are located deeper within the cytoplasm.

bar = 2 μm

Figure 7.53

Apical and supranuclear regions of a principal cell from the epididymal segment of the vas deferens. A few randomly distributed small vesicles (large arrows) are located within the apical cytoplasm in contrast to the band of vesicles evident in Fig. 7.52. Free ribosomes (small arrows) and mitochondria (m) are also present in the apical cytoplasm. Golgi complexes (G) and lysosomes (L) containing membranous inclusions (arrow heads) are the main features of the supranuclear region.

Lu = lumen, N = nucleus.

bar = 1 μm

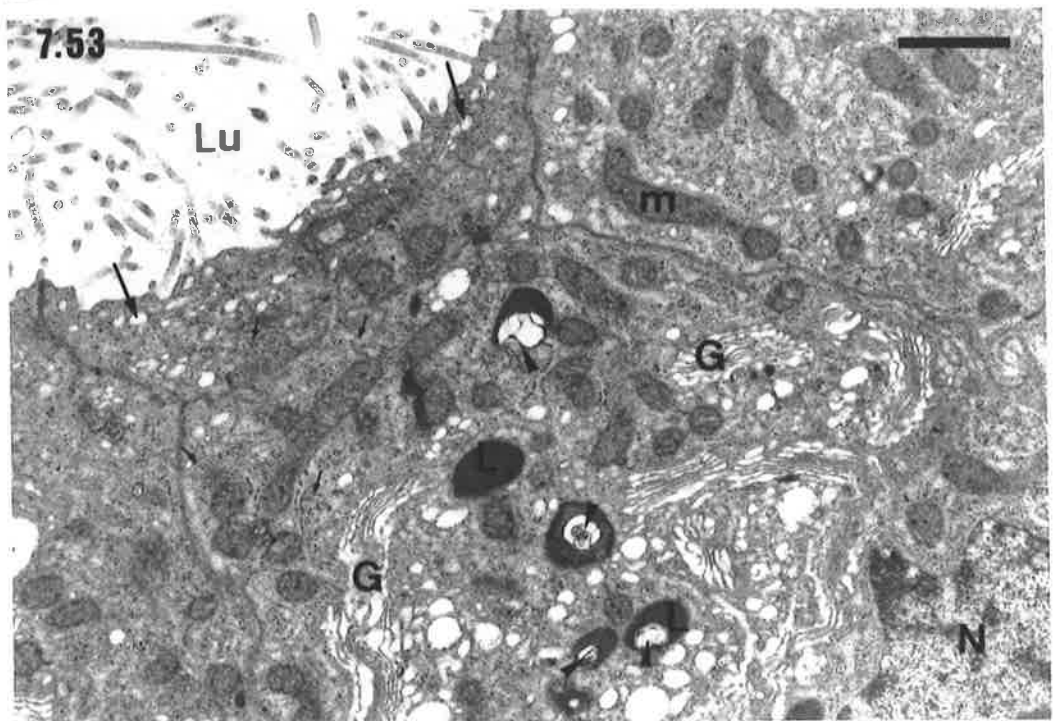
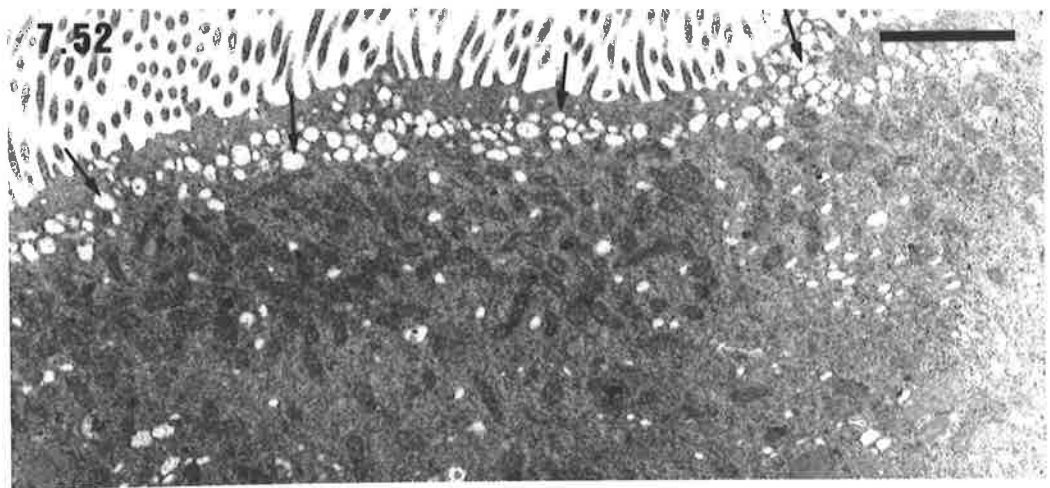
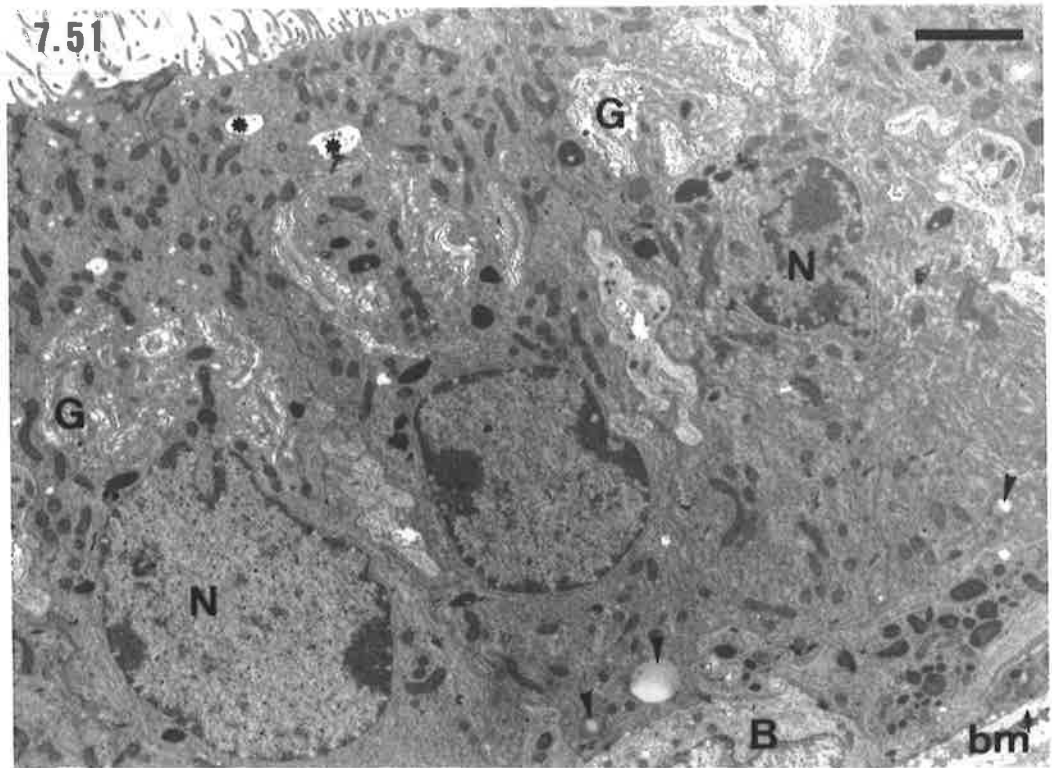


Plate 29 Ultrastructural Features of the Epithelium of the Intermediate Segment of the Hopping Mouse Vas Deferens

Figure 7.54

Low power electron micrograph of the epithelium of the intermediate segment of the vas deferens (= region of the duct where infolding of the mucosa commences, refer also to Fig. 7.2b). The epithelium is comprised of predominantly principal cells and a few basal cells (B). The nuclei (N) of the principal cells are usually within the basal third of the cytoplasm, which also contains abundant endoplasmic reticulum (ER). Golgi complexes (G) are evident in the supranuclear cytoplasm and multivesicular bodies (arrows) are located apically. Several of the principal cells show small projections of the apical cytoplasm (arrow heads) into the lumen (Lu) of the duct.

Ca = capillary of the lamina propria.

bar = 5 μm

Figure 7.55

Apical and supranuclear regions of a principal cell. Apical pits and vesicles are not prominent although mitochondria (m), multivesicular bodies (asterisks) and areas of smooth endoplasmic reticulum (ER) are apparent. Several electron dense bodies (L), presumed to be lysosomes, are adjacent to the Golgi complexes (G) in the vicinity of the cell's nucleus (N). Lipid (arrow) is contained within one of these lysosomes, in addition to its electron dense material.

bar = 2 μm

Figure 7.56

High power view of the apical region of a principal cell. Note again the paucity of pits and vesicles within the apical cytoplasm, in contrast to the principal cells of the epididymal segment of the vas deferens (Plate 28).

mvb = multivesicular body.

bar = 1 μm

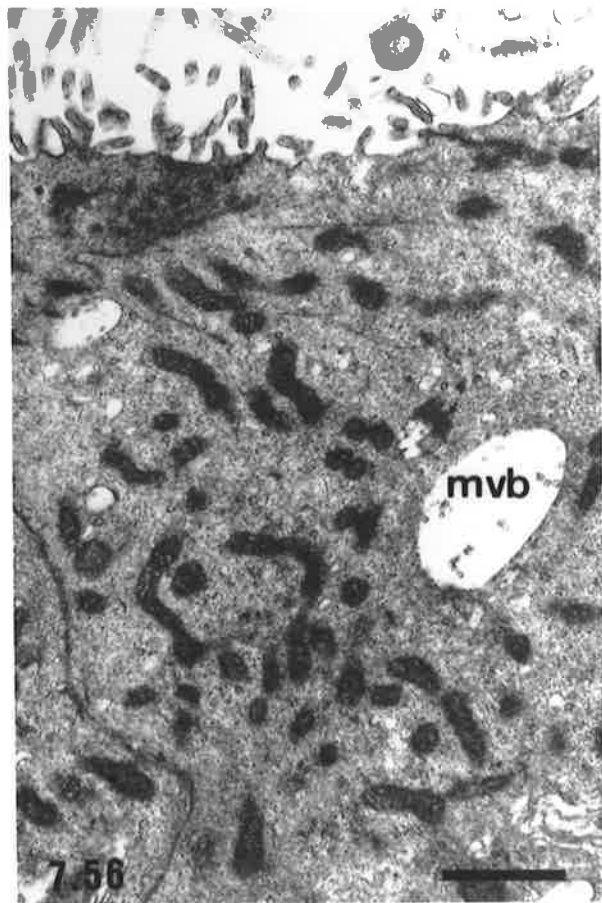
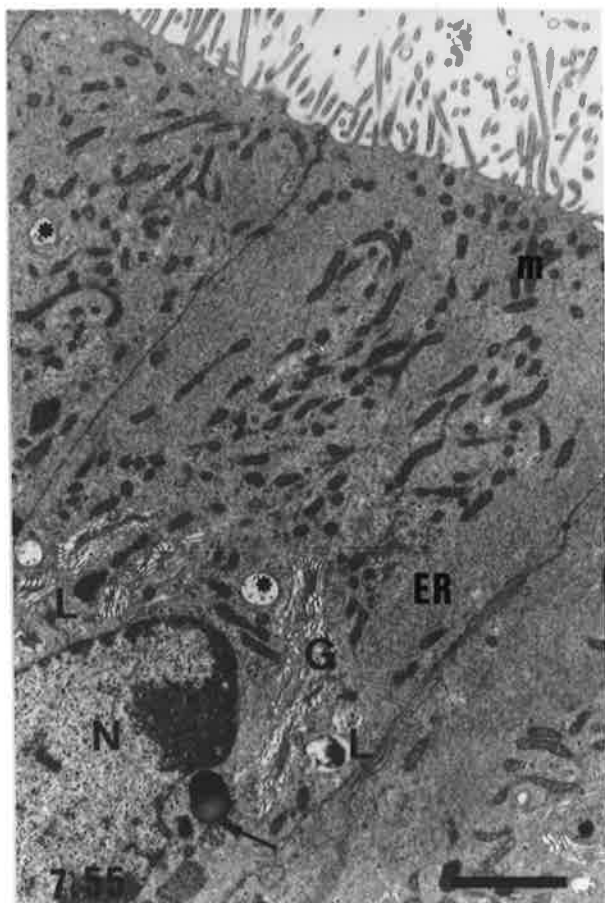



Plate 30 Ultrastructural Features of the Epithelium of the Urethral Segment of the Hopping Mouse Vas Deferens

Figure 7.57

Low power electron micrograph of the epithelium of the urethral segment of the vas deferens. Several basal cells (B) are located at the base of the epithelium. The principal cells are tall and slender with centrally located nuclei (N) and projections of the apical cytoplasm of several of the cells extend into the duct lumen (Lu). Golgi complexes (G) are evident in the supranuclear cytoplasm and small amounts of lipid (arrows) are also located in the vicinity of the nucleus in several of the cells. Whorls or parallel arrays of endoplasmic reticulum (ER) are the predominant feature of the basal cytoplasm.

bar = 5 μm

Figure 7.58

Apical region of a principal cell showing projections of the cytoplasm (CPr) into the lumen (Lu) of the duct. Extending from the cytoplasmic projections are branching microvilli (small arrows). The apical cytoplasm is almost devoid of vesicles but contains several small multivesicular bodies (arrow heads) and many small mitochondria.

bar = 2 μm

Figure 7.59

Apical region of several different principal cells. Unlike the principal cell in Fig. 7.58, these cells do not exhibit projections of their cytoplasm into the lumen (Lu), although their other cytoplasmic features are similar.

G = Golgi complex, N = principal cell nucleus.

bar = 2 μm

Figure 7.60

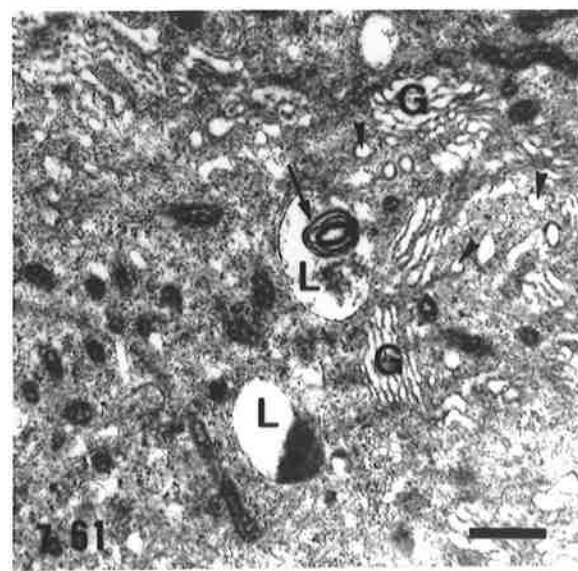
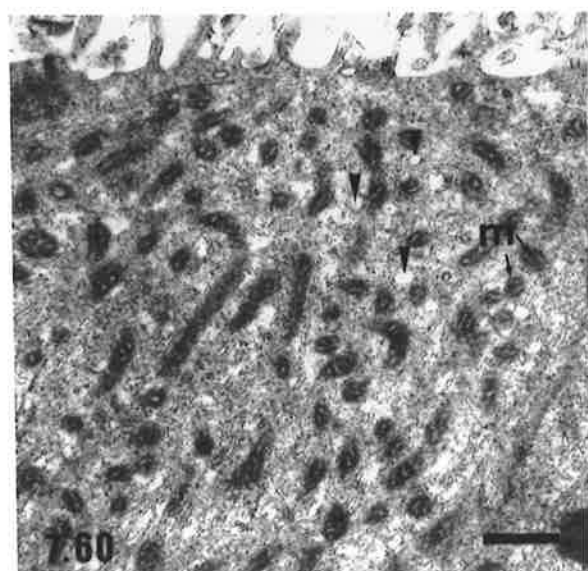
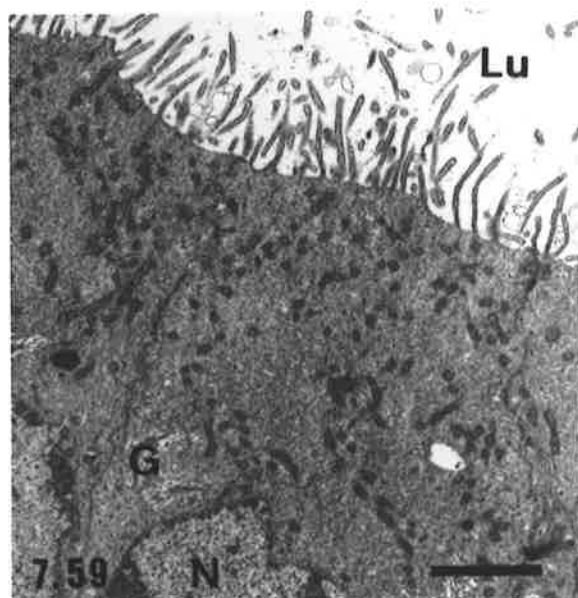
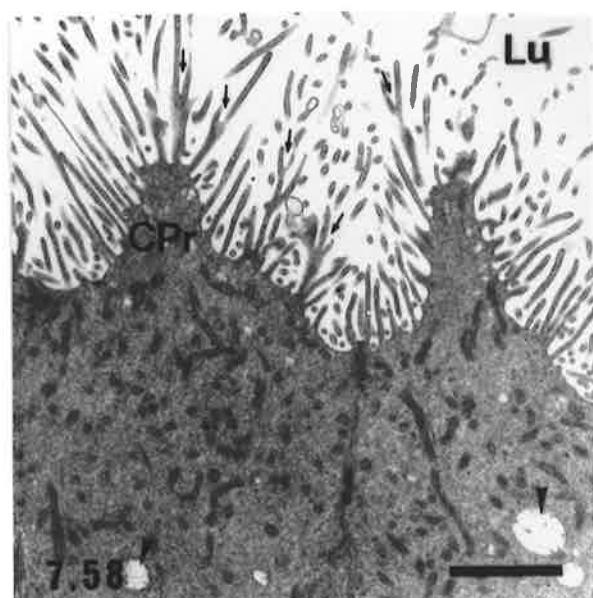
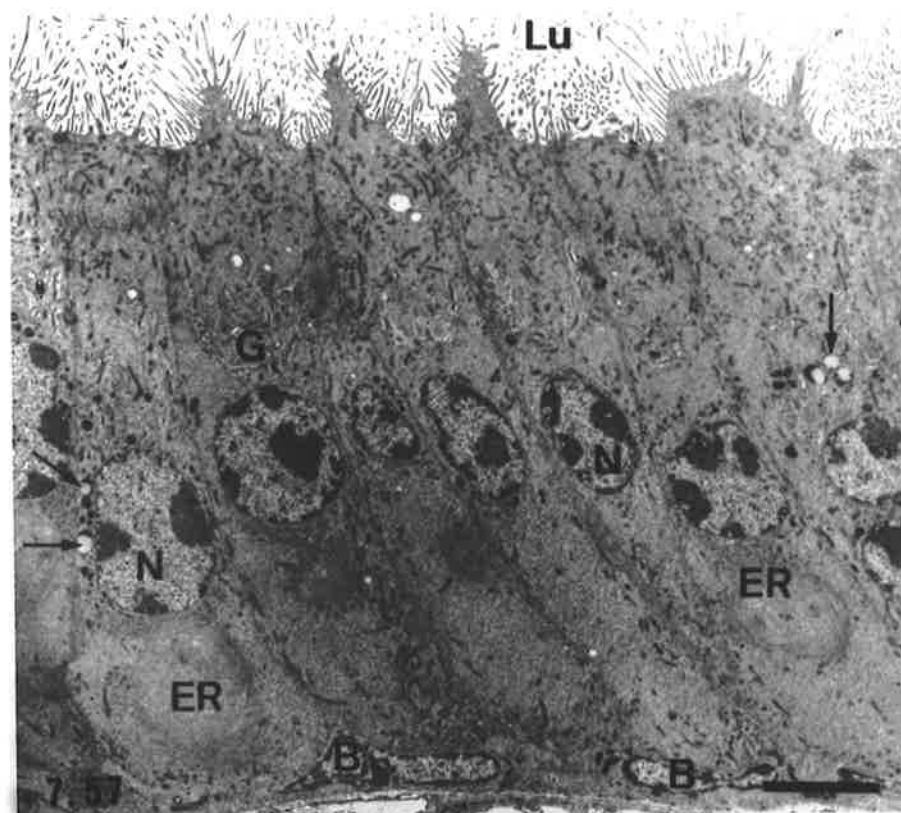
High power view of the apical cytoplasm of a principal cell. Note again the predominance of mitochondria (m) and the relative paucity of vesicles. Several small smooth-surfaced vesicles (arrow heads) are indicated.

bar = 0.5 μm

Figure 7.61

Supranuclear region of a principal cell showing several Golgi complexes (G). Close to the Golgi are smooth-surfaced vesicles (arrow heads) and several membrane-bound bodies (L), possibly lysosomes, containing electron-dense granular material and, in one case, a membranous whorl (arrow).

bar = 0.5 μm



In the plains rat, the gross structure of the vas deferens was similar to that of the laboratory rat (Hamilton and Cooper, 1978), however, in the hopping mouse several striking differences were observed. The entire duct was thin walled, with the luminal contents clearly visible through it when viewed under a dissecting microscope. Furthermore, the amount of muscle in the wall of the urethral segment of the vas deferens did not increase in thickness over that of the epididymal segment and was much less than that seen in other rodents. The terminal portion of the vas deferens did not display an expanded ampullary region in either plains rats or hopping mice. While this is also the case in the laboratory rat (Hamilton and Cooper, 1978), it is in contrast to the situation in the shrew (Suzuki and Racey, 1984), several species of macaques (Ramos, 1979) and many ruminants (Mann, 1964).

Histologically, the excurrent ducts of plains rats and hopping mice had features in common with other species of mammals studied, although certain unusual characteristics were observed, especially in the hopping mouse duct. In fact, certain features of the hopping mouse excurrent ducts were markedly different from those of other hydromyine rodents, apart from most other *Notomys* species (Breed 1986). For example, the duct of the cauda epididymidis was narrower and the epithelial lining lower than that of other hydromyines and the urethral segment of the vas deferens was characterised by a thin muscle coat, extensive infolding of the mucosa into the lumen and shorter principal cells lining the duct. The possible significance of these features will be addressed later in this discussion.

7.4.2 Ductuli Efferentes

The ductuli efferentes of both species were lined by an epithelium of ciliated and non-ciliated, columnar cells similar to those described for the laboratory rat (Hoffer, 1972; Hamilton, 1975; Hermo and Morales, 1984), laboratory mouse (Hoffer, 1972), rabbit (Jones *et al.*, 1979), guinea pig (Hoffer and Greenberg, 1978) and boar (Stoffel and Freiss, 1994). At the light microscopical level, no unusual cytological features were apparent in the epithelium of either species, although the granules and vacuoles in the non-ciliated, columnar cells of hopping mice were generally smaller and fewer in number than has been documented in other species. Tracer studies, in conjunction with electron microscopy of the epithelium of the ductuli in the laboratory rat, hamster and ram have shown that the non-ciliated cells are actively involved in endocytosis (Flickinger *et al.*, 1978; Morales and Hermo, 1983; Hermo and Morales, 1984; Hermo *et al.*, 1986; Veeramachaneni *et al.*, 1990). The vacuoles and vesicles have been implicated in the uptake of fluid and particulate matter from the lumen and the granules have been shown to be lysosomal in nature (Hermo and Morales, 1984; Jones and Jurd, 1987). Hence, in the hopping mouse the smaller size and sparser numbers of these organelles may indicate a lower absorptive

capacity in the ductuli efferentes, or they may reflect a lower output of seminiferous tubule fluid resulting from the small size of the testes in this species as compared with other rodents.

7.4.3 Ductus Epididymidis

In mammals, comparisons of the morphology of the ductus epididymidis between species and even between different studies of the one species, are complicated in that a variety of different criteria have been used to subdivide the organ into various regions. These criteria include gross anatomical, histological and cytological features of the organ, as well as functional considerations. Hoffer and Greenberg (1978) subdivided the guinea pig epididymis into 18 regions on the basis of tubule diameter and natural planes of cleavage created by connective tissue septae arising from the surrounding capsule. On subsequent microscopical examination, however, only seven histologically distinct zones were evident. Similarly, the proximal part of the mouse epididymis was divided into five segments, each corresponding to one or several lobes sharing common structural characteristics (Abou-Haila and Fain-Maurel, 1984). Alternative methods using quantitative and qualitative histological characteristics as the basis for subdividing the epididymal duct, usually result in the recognition of fewer morphologically distinct regions than when lobulation patterns are used. Eight regions or zones have been documented for the rabbit (Nicander, 1957a), six for the stallion, ram and bull (Nicander, 1957b), six (Reid and Cleland, 1957) or nine (Zunke and Gossrau, 1981) for the laboratory rat and five (Takano, 1980) or four (Soranzo *et al.*, 1982) for the laboratory mouse.

Yet another classification system was proposed by Glover and Nicander (1971), who made use of a general structural constancy between species to divide the mammalian epididymis into three major segments, the initial segment (originally described by Benoit in 1926), middle segment and terminal segment. Their classification was based on a combination of histological, cytological and functional characteristics of the duct, with the first two segments being those concerned with sperm maturation and the third segment with sperm storage. Variations in the microscopic appearance of the duct within the middle and terminal segments were used to further subdivide these regions in some species.

Glover and Nicander's (1971) classification has been applied or adapted with variable success to the epididymis of a range of mammalian species. These include the rat (Fawcett and Hoffer, 1979) hamster (Nicander and Glover, 1973), rabbit (Nicander and Plöen, 1979), mole (Suzuki and Racey, 1976), shrew (Suzuki and Racey, 1984), elephant (Jones and Brosnan, 1981) and tammar wallaby (Jones *et al.*, 1984). In a monotreme, the echidna, however, only two histologically distinct segments of the epididymis were identified

(Jones and Djakiew, 1978, Djakiew and Jones, 1981, 1982). The first corresponded to the initial segment of eutherians (Benoit, 1926; Nicander and Glover, 1973; Fawcett and Hoffer, 1979) whereas the second, designated the terminal segment, shared some characteristics with the terminal segment of scrotal mammals (Glover and Nicander, 1971), but differed in that it was involved in apocrine secretion (Djakiew and Jones, 1982). This latter feature may not be as unusual as first thought, however, as there is now increasing evidence that apocrine secretion is a normal phenomenon in the epididymis (Cooper, 1998). The presence, in well fixed epididymal material, of membrane-bound vesicles attached to cells via thin cytoplasmic stalks that extend into the luminal fluid, lends support to a 'pinching off' or apocrine mechanism of epithelial secretion (Fornes and De Rosas, 1991) and was observed in the cauda, as well as the caput regions of the rat epididymidis.

In the present study of the plains rat and hopping mouse, classification of the epididymis according to the scheme and criteria of Glover and Nicander (1971) was attempted as a basis for descriptions of epididymal structure. The scheme was successfully applied to the plains rat epididymis with five histologically distinct regions, corresponding to the initial segment, the middle segment (regions M1-M3) and terminal segment being identified. However, slight departures in epididymal organisation from the standard descriptions of Glover and Nicander (1971) were apparent in several segments of the plains rat epididymis. Firstly, in the initial segment, the supranuclear cytoplasm of the principal cells contained fewer Golgi complexes than were seen in the corresponding cells of the same segment in the hamster (Nicander and Glover, 1973), mole (Suzuki and Racey, 1976) and shrew (Suzuki and Racey, 1984). Secondly, there was an increase in the luminal diameter, coupled with a decrease in sperm density in region M2, ie. the intermediate portion, of the middle segment. By contrast, Glover and Nicander (1971) reported a decrease in luminal diameter and an increase in sperm density in this subsegment for the species they studied. Likewise, in the hamster, a narrower duct, lower epithelium, fewer epithelial vacuoles and a higher concentration of spermatozoa were reported in the central portion of the middle segment as compared with the subsegments either side of it (Nicander and Glover, 1973). Finally, apical vacuoles and dense bodies were more common in the principal cells of region M3 of the middle segment of plains rats as compared with the corresponding region of the epididymis in other species (Glover and Nicander, 1971; Nicander and Glover, 1973; Suzuki and Racey, 1976).

From a functional viewpoint, it appears that in the plains rat, events contributing to sperm maturation, including stabilisation of the nucleus, membrane alterations, shedding of the cytoplasmic droplet and other structural modifications, as well as the acquisition of progressive motility, are essentially completed during transit through the more proximal

regions of the epididymides, thus concurring with Glover & Nicander's suggestion that the initial and middle segments are concerned with these processes. Remodelling of the acrosome and migration of the cytoplasmic droplet of plains rat spermatozoa have been shown to occur in the capita and corpora epididymides (Flaherty, 1986), which together, approximately correspond to the initial and middle segments. Furthermore, stabilisation of spermatozoal structure by disulphide bonds and the acquisition of progressive motility is normally complete by the time spermatozoa enter the lower regions of the corpora or upper regions of the caudae epididymides (Flaherty, 1986), i.e. by the time that the terminal segment is reached. The completion of these processes, in conjunction with structural characteristics, such as an increase in the luminal diameter of the duct and a decrease in the height of the epithelium, are consistent with the terminal segment being a sperm storage site in this species. This is also supported by observations of large numbers of spermatozoa within the duct lumen of this region. In fact, Breed (1986) found that more than 80% of all spermatozoa in the male tract commonly occurred in the cauda epididymides and on average, only about 6% of spermatozoa were located in the vasa deferentia.

In contrast to the plains rat, the epididymis of the hopping mouse did not fit Glover and Nicander's (1971) classification system. Regional distinctions in duct morphology were not as obvious in this species and while there was good correspondence of structure between the initial segment of the hopping mouse and other mammalian species, this could not be said for the remaining epididymal segments, which displayed (a) features dissimilar to both the middle and terminal segments as described by Glover and Nicander and (b) a combination of features from both segments in some regions of the duct. In the hopping mouse, region M1 of the middle segment was generally confined to a small area of the caput epididymidis and was characterised by a narrower diameter of the duct lumen than that documented for any other species. When compared to the plains rat (present study), laboratory rat (Reid and Cleland, 1957), laboratory mouse (Takano, 1980) and rabbit (Nicander, 1957a), the mean luminal diameter of region M1 ($37 \pm 4 \mu\text{m}$) was less than half that of the narrowest portion of the duct in these other species. This may, however, merely relate to the overall smaller dimensions of the hopping mouse testes and epididymides as compared with the other rodents. Notwithstanding this point, differences between the distribution of apical vesicles and vacuoles in the hopping mouse principal cells from what has been documented in other species, were observed. Similar numbers of apical vesicles and vacuoles were seen in both the middle and terminal segments of the hopping mouse and the cytoplasm of the principal cells displayed little other obvious structure that could be used to distinguish between the two segments at the light microscopical (LM) level.

Few differences in the cytology of principal cells were observed between the entire length of region M2 of the middle segment and the terminal segment of the hopping mouse epididymis. Furthermore, a similar cytological appearance was observed for much of the epithelium of the vas deferens. The Golgi complexes were a prominent feature of the supranuclear cytoplasm and in LM preparations, often appeared as a light, unstained region in an otherwise deeply basophilic cytoplasm. Electron microscopy of terminal segment principal cells also indicated the presence of coated and uncoated pits and vesicles, pale multivesicular bodies and variable numbers of membrane bound dense bodies (presumed to be lysosomes) apical to the nucleus and a well developed network of RER in the basal cytoplasm.

Various investigators have suggested that the Golgi is involved in the synthesis of the numerous lysosomes common to the mammalian epididymis (Friend, 1969; Moniem and Glover, 1972) and in the secretion of proteins and other substances (Nicander, 1970; Flickinger, 1979, 1981, 1985, Robaire and Hermo, 1988), particularly when found in combination with a well developed endoplasmic reticulum. Conclusive morphological evidence of a link between the RER and Golgi complexes in the production of a secretory product and the presence of classical secretory granules have not, however, been shown for epididymal principal cells (Hoffer *et al.*, 1973; Hamilton, 1975; Flickinger, 1979), although it has been suggested that smooth-surfaced vesicles may be part of a secretory pathway in these cells (Nicander and Malmquist, 1977; Robaire and Hermo, 1988). A major role for the principal cells in the secretion of proteins and other molecules into the luminal environment of the epididymis is, however, well documented from tracer and immunolocalisation studies (Cooper, 1986, 1998). Conversely, a role for the Golgi complexes in the production of lysosomes fits well with demonstration via the uptake of transferrin and alpha-2-macroglobulin by rat caput principal cells, of an endocytic pathway involving coated pits, coated vesicles, pale multivesicular bodies and membrane bound dense bodies, ie. lysosomes (Djakiew *et al.*, 1984; Djakiew *et al.*, 1985). Hence, in the hopping mouse, the presence of extensive, well developed Golgi complexes, numerous vesicles and multivesicular bodies, membrane bound dense bodies and RER may indicate both active secretory and absorptive functions for the principal cells. In addition, the ultrastructural features linked to absorption and secretion extend over both the middle and terminal segments of the epididymis and into the vas deferens, perhaps suggesting that there is less regional specialisation of epididymal function in the hopping mouse than in other mammalian species. This is in contrast to the majority of studies of epididymal ultrastructure which have reported a predominance of such features in the principal cells of the more proximal regions of the epididymis, particularly the initial segment (Flickinger, 1979; Morales and Hermo, 1983; Abe *et al.*, 1983).

The ultrastructure and distribution of clear cells differed between the plains rat and hopping mouse. Several studies have shown that clear cells are absorptive, more so than principal cells, and play a role in the disposal of the contents of cytoplasmic droplets detached from spermatozoa (Hamilton, 1975; Moore and Bedford, 1979b; Robaire and Hermo, 1988; Hermo *et al.*, 1988). The presence of numerous multivesicular bodies and membrane-bound dense bodies within clear cells support these functions. Membrane bound dense bodies have been identified cytochemically as secondary lysosomes (Robaire and Hermo, 1988). In the hopping mouse there was a general paucity of clear cells in comparison to the plains rat and those that were present did not contain as many multivesicular or membrane-bound dense bodies. Given the persistence of moderate amounts of similar organelles in the principal cells of the terminal segment of the epididymis and the vas deferens, it may be that in the hopping mouse, greater levels of absorption and degradation of cytoplasmic droplets may be undertaken by this cell type. The same types of tubular profiles and membranous inclusions were observed in the duct lumen and the multivesicular bodies of both principal^{and} clear cells in the hopping mouse.

Some caution must be exercised, however, in drawing conclusions about the functional aspects of the epididymis in the present study, from the structural features observed. The present study did not include any quantitation of organelles for the various regions of the duct, hence, subtle variations in the number and intracellular distribution of organelles between regions were not considered. Likewise, it would be prudent to investigate secretory and absorptive activity of the epithelium via tracer studies and analysis of luminal proteins, rather than make claims of specific functions based purely on structural features. Nevertheless clear differences in epididymal structure, which may indicate differences of function, were observed between the hopping mouse and other rodent species including the plains rat.

Part of the reason for a possible reduction in regional specialisation of the epididymis in the hopping mouse may relate to the finding that the epididymal duct is less coiled and shorter in length than in other rodents. A comparison of the length of the epididymis in the hopping mouse and laboratory mouse indicated that the hopping mouse duct was only about one fifth to one quarter of the length of that of the laboratory mouse, ie. 13-15 cm cf. 60-70 cm when the duct is uncoiled (unpublished observations). It may therefore be conceivable that due to the shorter length, modification of the luminal environment via epithelial secretion, resorption of fluid from the lumen and the concentration of spermatozoa is not completed until well into the terminal segment of the epididymis or possibly even the vas deferens in this species.

In addition to the cytology of the principal and clear cells, the terminal segment of the hopping mouse epididymis also differed from that of other rodents in that epithelial and stereocilia heights did not decrease significantly from those of the middle segment. Furthermore, although there was an increase in luminal diameter, it was of a much smaller magnitude than that seen in the laboratory rat (Reid and Cleland, 1957), rabbit (Nicander, 1957a), laboratory mouse (Takano, 1980) or plains rat (present study). It is conceivable, therefore, that the relatively narrow duct diameter and moderate increase in epithelial and stereocilia heights of the hopping mouse terminal segment merely reflect the low numbers of sperm reported in this region (Breed, 1982a, 1986; Peirce and Breed, 1989; Breed *et al.*, 1991; see also Chapter 8 of this thesis).

One factor that may relate to the differences in sperm density between the plains rat and hopping mouse, especially in the lower regions of the epididymides, is the environmental temperature to which the epididymides are exposed. It has been shown that the capacity for sperm storage by the cauda epididymidis is temperature dependent. In fact, it was proposed that the major driving force for the development of the scrotum was the requirement to store spermatozoa at a cooler temperature, rather than the need for a cooler testicular environment (Bedford, 1977, 1978a). Experiments in which the cauda epididymidis, still connected to its scrotal testis, was reflected into the abdominal cavity have shown that abdominal temperature reduces sperm storage capacity by decreasing the transit time of spermatozoa through the duct (Bedford 1978b). A narrower lumen and shorter duct length of the abdominal cauda as compared to the contralateral scrotal cauda in the experimental animals, however, also contributed to the lower sperm counts (Bedford 1978b; Foldsey and Bedford, 1982, Bedford, 1991).

Subsequently, studies using laboratory rats have shown that the mechanism whereby temperature exerts its effect on sperm storage occurs at the level of the epididymal epithelium. Whereas no obvious effects on epithelial ultrastructure were observed by raising the epididymal temperature to that of the abdominal cavity (Rasweiler and Bedford, 1982), water and ion transport functions of the epididymal principal cells were altered (Wong *et al.*, 1982; Rasweiler and Bedford, 1982). Thus, increasing the temperature of the cauda epididymidis resulted in an alteration of the ionic composition of the luminal fluid to which spermatozoa were exposed (Wong *et al.*, 1982). Furthermore, the protein profile of cauda epididymal fluid was also shown to differ after exposure of the epididymis to abdominal temperatures (Esponda and Bedford, 1986; Esponda *et al.*, 1990).

In the hopping mouse the testes and epididymides have been described as perianal (Breed, 1981a) or inguinal (Breed, 1981b) in position, rather than scrotal as is the case in other rodents. In males examined in the present study, the position of the testes and

epididymides was highly variable and ranged from within a shallow perianal swelling close to the body surface, to deep within the lower abdominal region. Furthermore, the majority of the vas deferens was always located within the abdominal cavity. In the hopping mouse therefore, the testes and excurrent ducts are probably subjected to temperatures closer to body temperature than to scrotal temperature and this may consequently have an influence on the sperm storage capacity of the cauda epididymidis. In the laboratory rat, exposure of the cauda epididymidis to body temperature does not appear to have a detrimental effect on its epithelial ultrastructure, however, it was noted that organelles constituted a smaller proportion of the total volume of principal cells subjected to body temperature, as compared with those maintained at scrotal temperature (Rasweiler and Bedford, 1982). In the terminal segment of the hopping mouse epididymis, principal cells also appeared to show a somewhat sparser distribution of organelles, apart from the Golgi, than was observed in the plains rat terminal segment, although morphometric analysis was not undertaken to determine whether this was a real difference.

7.4.4 Vas Deferens

The vas deferens is not generally recognised as having a sperm storage function in most mammals, but where such a function has been suggested, eg. in the stallion, jackass and zebra, it has been attributed to the ampullary region at the terminal (urethral) end of the duct (Mann and Lutwak-Mann, 1981). In the hopping mouse, up to 60% of all spermatozoa in the excurrent ducts of some individuals are found in the vas deferens (Breed, 1981b, 1986), but an expanded terminal ampullary region does not exist in this species. By contrast, a very low percentage of the total number of spermatozoa are located in the vas deferens of the plains rat (Breed, 1986).

In a comparative study of male reproductive tract parameters within the tribes Hydromyini, Uromyini and Conilurini, marked interspecific variability was shown to occur in the structure of the vas deferens and in particular in the urethral segment, with the *Notomys* species showing the most diverse features. In all of the Hydromyini and Uromyini and most of the Conilurini, the urethral half of the vas deferens was characterised by a thick muscle coat and a small number of longitudinal infoldings of the mucosa into the lumen (Breed, 1986). The epididymal segment of the duct, however, invariably presented a regular round to oval luminal profile. Epithelial folds, described as being comprised of two to six longitudinal ridges of tissue extending into the lumen, have been reported in the vas deferens of numerous species (Benoit, 1926; Bern, 1949; Niemi, 1965) and, as in the Australian rodents, appear to be confined to the distal (urethral) segment of the duct (Hamilton and Cooper, 1978; Kennedy and Heidger, 1979). Within

the genus *Notomys*, one species, *N. cervinus*, did not display infolding of the mucosa, although the typical thick muscle coat was observed, whereas two other species, *N. mitchelli* and *N. alexis* had an extremely thin muscle coat and an enlarged duct lumen that was extensively subdivided by infoldings of the epithelium and lamina propria (Breed, 1986). In the present study of the hopping mouse, these infoldings were shown to extend almost the entire width of the lumen, in contrast to the plains rat and laboratory rat where a well-defined central canal devoid of folds and containing the spermatozoa was documented (Hamilton and Cooper, 1978).

The present study, confirms that the plains rat vas deferens shows a similar structural organisation to that of common laboratory rodents but, by contrast, the urethral segment of the hopping mouse vas deferens presents a much more complex pattern of circular folds and longitudinal ridges similar in organisation to the plicae circulares of the small intestine. The lamina propria of these folds was observed to be highly vascularised, with numerous profiles of vessels visible in perfusion-fixed tissue sections. The significance of such extensive mucosal infolding in the urethral segment of the hopping mouse vas deferens is at present unknown, but several theories as to their possible function are worth mentioning.

One possible role of the mucosal folds of the distal vas deferens is related to the requirements for and supply of oxygen to, stored spermatozoa. These parameters are temperature dependent (Djakiew and Cardullo, 1986). In testicond mammals (those mammals in which the testes and epididymides are located within the abdominal cavity) epithelial folds were reported to be present within the sperm storage areas of the epididymal duct. Folding of the epididymal epithelial was observed in the platypus (Carrick and Hughes, 1978), echidna (Jones and Djakiew, 1978; Djakiew and Jones, 1981, 1982), elephant (Jones, 1980; Jones and Brosnan, 1981) and dugong (Marsh and Glover, 1978; Marsh *et al.*, 1984). Due to the abdominal location of the epididymides in all of these species, their temperature would be expected to be higher than that experienced by scrotally located epididymides. Hence, Djakiew and Cardullo (1986) put forward the idea that the epithelial folds of the epididymis in testicond mammals may be an adaptation to increase the flux of oxygen to luminal spermatozoa. The increased oxygen availability would result from the greater number of capillaries and the larger surface area for the diffusion of oxygen into the luminal fluids, provided by the folds, as compared to a circular lumen. It was suggested that such a feature is required because higher temperatures increase the respiration rate of mammalian spermatozoa and decrease the amount of oxygen directly available to them by making it less soluble in fluid (Djakiew and Cardullo, 1986).

Given that most of the vas deferens is located within the abdominal cavity in the hopping mouse, it may be that the mucosal folds facilitate greater oxygen availability, thereby enabling greater numbers of spermatozoa to be stored and remain viable in the vas deferens. This may be necessary to ensure that enough sperm are available for several ejaculations within a short time frame, in light of the low daily sperm production per animal of around 520,000 (260,000 per testis per day; Chapter 5) and only about 3-4 day's production of spermatozoa stored in each cauda epididymidis (see Chapter 8). By contrast, in the plains rat, approximately 25-45 day's production of spermatozoa are stored in the caudae epididymides of an animal (see Chapter 8). The average number of spermatozoa released per fertile ejaculate in these species remains to be determined, however, sperm stores in the hopping mouse appear to be adequate enough to enable at least three successful matings by a single male, as determined by the birth of young, within a seven day period (Breed, 1981a).

Secondly, it is also perplexing that the thickness of the muscle coat of the hopping mouse vas deferens reduces distally (it is only 25-50 μm thick at the terminal end), whereas that of most other species increases in thickness. The muscle coat surrounding the cauda epididymidis and vas deferens has been implicated in the removal of sperm during the emission phase of ejaculation (Hamilton and Cooper, 1978, Kennedy and Heidger, 1979). While Breed (1986) stated that the relatively thin muscle coat in the hopping mouse vas deferens suggests a divergent mechanism for expulsion of sperm from the excurrent ducts at the time of ejaculation, he did not put forward any theories as to what this mechanism might entail. Hence, the question remains as to: 'What provides the necessary force for removal of spermatozoa from the cauda epididymidis and vas deferens during ejaculation, given the thin muscle coat in this species?'

One possibility is that individual muscle fibres of the distal vas deferens of the hopping mouse generate a far greater contractile force than do those of other species, who would therefore, presumably, require a larger bulk of muscle in order to move sperm through the duct. An Honours student, Vivienne Bradtke, in our laboratory investigated the contractility of the smooth muscle of the vas deferens in the plains rat and hopping mouse. When various segments of the vas deferens were stimulated by administration of exogenous noradrenaline in an *in vitro* organ bath model, a much greater force of contraction was generated by muscle of the hopping mouse as compared to the plains rat (Bradtke, 1990). However, it was claimed that contraction of fibres of the longitudinal layer of muscle only was measured and that this layer was almost twice the thickness (and presumably contained a greater number of fibres) in the hopping mouse distal vas deferens, than in the corresponding region of the plains rat. By contrast, the circularly oriented muscle layer of the plains rat distal vas deferens was about 10 times thicker than

that of the hopping mouse (Bradtke, 1990). Hence, there is no conclusive evidence that there is a greater overall contractility of muscle of the hopping mouse vasa deferentia, since the relative contribution of the circularly oriented fibres is unknown. Furthermore, it has been reported that, in addition to adrenergic fibres, purinergic (Sakai et al., 1979), peptidergic (Fauchere, 1982) and cholinergic (Machado et al., 1982) fibres also innervate the vas deferens and may play a role in the control of muscular contractions.

An alternative explanation of how the force required for the removal of spermatozoa may be generated relates back to the mucosal folds of the urethral segment of the hopping mouse vas deferens mentioned earlier. In the rat, capillaries of the mucosal folds of the urethral vas deferens were found to be continuous with a venous plexus that surrounded the mucosa (Hamilton and Cooper, 1978). It was shown that this plexus was supplied by the deferential artery, rather than the spermatic artery and at the termination of the vas, was continuous with the vascular channels of the corpus spongiosum. Hence, it was suggested that the function of the vascular plexus in the mucosal folds and submucosa of the urethral vas deferens was to stiffen the duct during the emission phase of ejaculation (Hamilton and Cooper, 1978). Given the thin muscular coat of the urethral segment of the vas deferens in the hopping mouse, it may be that the extensive mucosal folds in this species provide an extensive vasculature with an erectile function similar to that proposed in the rat. The engorged vessels would hence be capable of providing the rigidity to the duct necessary for the movement of sperm through it at ejaculation, despite it containing less muscle in its wall.

No dramatic differences in the ultrastructure of principal cells were observed between the epididymal and urethral segments of the vas deferens in the hopping mouse. Apart from a gradual reduction in the prominence of the Golgi complexes, the principal cells of the vas deferens were not dissimilar to those of the terminal segment of the epididymis. There was little variation in cell height, no increase in the number or height of microvilli and an abundance of RER was still evident in the basal cytoplasm. This latter feature distinguishes the hopping mouse from the plains rat and the laboratory rat in which the RER is sequentially replaced by SER towards the urethral end of the vas deferens (Flickinger, 1973; Kennedy and Heidger, 1978; Robaire and Hermo, 1988). It has been shown that following castration, a reduction in the amount of RER in principal cells of the rat epididymis occurs, probably in response to androgen withdrawal (Moore and Bedford, 1979a). It may be that the abundance of RER in principal cells along the entire vas deferens in the hopping mouse signifies a greater continued level of secretory activity and metabolic regulation (which is possibly androgen dependent) of the luminal microenvironment by the epithelium in the hopping mouse.

While the above ultrastructural observations perhaps suggest a similar function of the principal cells of the terminal segment of the epididymis and vas deferens, they provide no evidence as to whether the secretions produced by the cells are the same in the various storage areas of the duct. Likewise, nothing can be ascertained about the composition and/or the nature of the modification of the luminal microenvironment by the epithelium in these regions. Therefore, preliminary investigations are now being undertaken to determine how similar or different the luminal environments are between the terminal segment of the epididymis and the epididymal and urethral segments of the vas deferens. Flushes of the luminal fluids from the various regions have been obtained and are being analysed by gel electrophoresis for similarities and differences in protein composition.

7.5 Summary

The gross anatomical and microscopical structure of the male excurrent ducts were examined in two species of Australian rodents the plains rat, *Pseudomys australis* and the hopping mouse, *Notomys alexis*. In the plains rat, the microstructure of the ductus epididymidis and vas deferens was similar to that of common laboratory rodents. By contrast, in the hopping mouse, the structure of the middle and terminal segments of the epididymis differed significantly in that the height of the epithelium and stereocilia did not decrease and luminal diameter did not increase markedly along the length of the duct. Furthermore, the principal cells were remarkably consistent in their ultrastructural features between both of these regions and the vas deferens. The urethral segment of the vas deferens showed extensive mucosal infoldings and lacked a thick muscle coat. The differences in histological structure of the hopping mouse excurrent ducts, as compared with other rodent species, presumably reflect a reduction in specialisation of function of the various regions of the tract in this species. Alternatively, they may be related to exposure to an increased environment temperature as suggested by the more variable anatomical position of the testes and epididymides in the hopping mouse.

Chapter 8 Epididymis and Vas Deferens - Sperm Transit, Distribution and Storage

8.1 Introduction

In the hopping mouse, the distribution of spermatozoa within the extra-testicular genital ducts differs from that observed in other mammalian species including the plains rat, with the vas deferens possibly acting as a major site of sperm storage, since up to 60% of spermatozoa in some individuals are located within it (Breed, 1982a, 1986). In the light of this difference in sperm distribution from what occurs in most species of mammals including laboratory rodents, it might be that the time required for spermatozoa to pass through the epididymis and vas deferens also differs in the hopping mouse. The present study therefore aimed to determine sperm transit times and to further investigate the pattern of distribution and storage of spermatozoa in the epididymis and vas deferens of the plains rat and hopping mouse.

8.2 Materials and Methods

8.2.1 Determination of Sperm Transit

The time taken for spermatozoa to travel through the epididymis and vas deferens in the plains rat and hopping mouse was determined by several methods, namely:

- a) tracking the progress of labelled spermatozoa through the various regions of the duct,
- b) dividing the sperm reserves within a particular region of the duct by the rate of daily sperm production of the attached testis.

8.2.1.1 Autoradiographic Tracking of Spermatozoa

A single intraperitoneal injection of 70 μCi or 40 μCi of [methyl- ^3H]thymidine (dose rate 1-1.5 $\mu\text{Ci/g}$ body weight; specific activity 43 Ci/mmol; Amersham, Buckinghamshire, UK) was administered to each of 19 male plains rats and 19 male hopping mice respectively. One animal was subsequently sacrificed every second day from day 26 to day 64 following ^3H -thymidine administration¹. Reproductive tracts were removed and one side of the tract

¹ This time frame was selected because the length of the cycle of the seminiferous epithelium in the plains rat and hopping mouse was not known at the commencement of the study. However, based on estimations of a cycle length of between 10 and 14 days, and a duration of epididymal transit of 10-15 days, the first appearance of labelled spermatozoa in the various regions of the epididymis and vas deferens was expected to occur between days 30 and 55-60.

with its corresponding testis was fixed in Bouin's fluid for 24 hours, processed, embedded in paraffin wax and sectioned at 5 μm . The other side was divided into caput, corpus and cauda epididymides and vas deferens and smears were prepared from the luminal contents. All smears were fixed for one hour in formaldehyde vapour. Both sections and smears were subsequently coated with photographic emulsion (see section 5.2.2, Chapter 5 for details) and exposed for 6-12 weeks, after which time batches of slides were developed, fixed and stained with Harris's haematoxylin.

8.2.1.2 Transit Time as Determined from Extra-gonadal Sperm Reserves and DSP

Five plains rats and six hopping mice were used. In the plains rat, the left and right hand sides of the excurrent duct system were divided into caput, corpus and cauda epididymides, as well as vas deferens. Sperm reserves were determined for each segment as outlined in section 8.2.2.1. In the hopping mouse, the epididymis was divided into caput plus corpus and cauda segments. The vas deferens was divided into 'epididymal' and 'urethral' segments at the site where the diameter of the duct increased. Transit times were determined from one side of the reproductive tract only, as one testis from each animal was prepared for histological examination. The transit time through the various segments of the excurrent ducts was determined by dividing the number of spermatozoa in the segment by the daily sperm production of the attached testis (see Chapter 6 for details of how DSP was calculated).

8.2.2 Sperm Distribution and Storage

8.2.2.1 General Method

The number and distribution of spermatozoa within the excurrent ducts and in particular the sperm storage areas, were ascertained from sperm counts of the various duct regions. Males were killed either by cervical dislocation or carbon dioxide asphyxiation and their reproductive tracts were removed and cleared of adherent fat, taking care not to redistribute the luminal contents by using undue physical pressure on the removed ducts. The tracts were divided into regions that are described in the subsequent experiments below and each segment was placed in a separate watch glass containing a measured amount of physiological saline or homogenizing fluid (see section 6.2.1, Chapter 6). The epididymides were macerated using forceps and spermatozoa were flushed from the vasa deferentia. The resulting suspensions were gently agitated for 15-30 minutes to ensure the liberation of spermatozoa from the tissue fragments. Suspensions were diluted as necessary and spermatozoa were counted in ten haemocytometer chambers, each of 0.1mm^3 ($0.1\ \mu\text{l}$) volume. The number of spermatozoa in each duct segment was calculated

by multiplying the average sperm count by the initial volume of the suspension and any dilution factor used.

8.2.2.2 Distribution of Spermatozoa within the Sperm Storage Areas

Experiment 1²

Spermatozoa were counted in the caudae epididymides and vasa deferentia of ten plains rats and 12 hopping mice. In an attempt to ascertain the location within the vas deferens that may act as a sperm storage area, the duct was divided into segments as follows:

- a) the vas deferens of 'side A' of the reproductive tract (selected at random) was divided into epididymal and urethral segments of equal length.
- b) the vas deferens of 'side B' of the reproductive tract was divided into two segments (epididymal and urethral) at the site where the diameter of the duct increased. This site corresponded to the beginning of infolding of the duct mucosa and was generally about two fifths of the distance between the cauda epididymidis and the termination of the vas deferens (refer to Figs 7.1b and 7.2b, Chapter 7).

Experiment 2

Spermatozoa were counted in the epididymides and vasa deferentia of six hopping mice. Each side of the tract, which was counted separately, was divided into five segments. The epididymis was divided into caput plus corpus and cauda segments, whereas the vas deferens was divided into an epididymal segment adjoining the cauda epididymidis, a middle segment spanning the region 3mm either side of the site where the diameter of the duct increased and mucosal folding into the lumen began and a urethral segment.

8.3 Results

8.3.1 Transit Time

Plains Rat

The first appearance in the caput epididymidis of spermatozoa labelled with ³H-thymidine occurred in the animal sacrificed 36 days post ³H-thymidine injection. Labelled spermatozoa were not present in the epididymides of animals sacrificed on days 26, 28, 30, 32 or 34 post-injection, although in both the 32 and 34 day animals, the most advanced labelled spermatids in the testes were at the point just prior to their release from the

² The results of this experiment were published in Peirce, EJ and Breed, WG (1989) Light microscopical structure of the excurrent ducts and distribution of spermatozoa in the Australian rodents, *Pseudomys australis* and *Notomys alexis*. *Journal of Anatomy* 162:195-213.

tubules. These spermatids surrounded the lumen of tubular cross sections at stages V and VI of the cycle of the seminiferous epithelium. By day 38, labelled spermatozoa were present in all regions of the corpus epididymidis, but no labelled spermatozoa were seen in the cauda epididymidis. Labelling of spermatozoa in the proximal part of the cauda epididymidis (ie. on the corpus side of the caudal flexure) was first observed on day 42, in the distal cauda epididymidis on day 48 and in the vas deferens on day 56. The first appearance of labelled spermatozoa in the vas deferens, however, may not be a true indication of the time required to reach this portion of the duct, since the animal sacrificed on day 56 was the only individual in which labelling above the background level was observed in sections or smears taken from the vas deferens. From these data, the best estimate of transit time through the epididymis of the plains rat is less than 20 days, although it may be as short as 12 days.

From calculations based on extra-gonadal sperm reserves and DSP, the average time taken by spermatozoa to pass through the epididymis of the plains rat was 0.8 days for the caput, 1.5 days for the corpus and 6.9 days for the cauda (Table 8.1). Transit of the vas deferens averaged 0.9 days. Hence, in sexually rested animals, it takes, on average, 9.2 days for spermatozoa to travel through the epididymis and 10.1 days to traverse the epididymis and vas deferens.

Table 8.1

Transit Time of Spermatozoa through the Excurrent Duct System of the Plains Rat, *Pseudomys australis* as Determined from Sperm Reserves and DSP

Animal	Side of Tract	DSP/testis (x 10 ⁶)	Transit Time of Segment (days)			
			caput epididymidis	corpus epididymidis	cauda epididymidis	vas deferens
Pa 24/3/1	left*	27.00	0.02	0.22	0.96	0.07
Pa 24/3/1	right	26.35	0.99	1.37	9.62	0.66
Pa 24/3/2	left	29.28	0.80	1.16	4.57	0.43
Pa 24/3/2	right	25.00	1.09	1.62	6.02	1.49
Pa 24/3/3	left	23.87	0.48	1.75	7.11	0.61
Pa 24/3/3	right	24.32	0.70	1.43	7.29	1.05
Pa 24/3/4	left	17.12	0.91	1.57	10.74	1.06
Pa 24/3/4	right	20.50	0.71	1.61	10.01	1.31
Pa 24/3/5	left	14.64	0.66	1.23	2.48	0.94
Pa 24/3/5	right	12.84	1.04	1.85	3.76	0.93
Transit time/segment (average ± S.D.)			0.82 ± 0.20	1.51 ± 0.23	6.85 ± 2.91	0.94 ± 0.34
Average transit time of entire duct =			10.12 days			

* Duct system reduced in size and abnormal in morphology, values were excluded from averages.

Hopping Mouse

Testis sections from animals sacrificed on days 40 and 42 post-labelling showed labelled elongate spermatids surrounding the lumen of stage III-IV tubules. Labelled spermatozoa were first observed in the epididymis on day 42 following ^3H -thymidine administration. These spermatozoa were predominantly present within the caput and corpus epididymides, although an occasional labelled spermatozoon was observed in the cauda epididymidis. Greater numbers of spermatozoa were labelled in the cauda epididymidis on day 44 and a few labelling spermatozoa were observed in sections of the vas deferens immediately adjacent to the epididymis on day 46. Both sections and smears of the vas deferens contained labelled spermatozoa in all animals sacrificed from day 48 to day 70. From these results, the minimum time taken by spermatozoa to pass through the epididymis was about 4-6 days. Based on extra-gonadal sperm reserves, average transit time through the caput plus corpus epididymides was 0.9 days, cauda epididymidis 3.1 days and vas deferens 1.6 days (Table 8.2). Hence epididymal transit takes, on average, four days, with spermatozoa taking about 5.6 days to traverse the epididymis and vas deferens in sexually rested individuals.

Table 8.2
Transit Time of Spermatozoa through the Excurrent Duct System of the Hopping Mouse, *Notomys alexis* as Determined from Sperm Reserves and DSP

Animal	DSP/testis ($\times 10^6$)	Transit Time of Segment (days)			
		caput + corpus epididymides	cauda epididymidis	epididymal portion of vas deferens	urethral portion of vas deferens
Na 24/3/1	0.515	1.02	1.82	1.30	0.71
Na 24/3/2	0.170	0.78	3.73	1.48	1.01
Na 24/3/3	0.127	1.11	4.18	0.58	1.82
Na 24/3/4	0.155	1.65	4.50	0.14	0.10
Na 24/3/5	0.198	0.58	2.02	1.83	0.61
Na 24/3/6	0.108	0.44	2.28	0.05	0.12
Transit time/segment (average \pm S.D.)		0.93 \pm 0.44	3.09 \pm 1.18	0.90 \pm 0.75	0.73 \pm 0.64
Average transit time of entire duct = 5.64 days					

8.3.2 Distribution of Spermatozoa within the Sperm Storage Areas

In male plains rats, the number of spermatozoa stored in the caudae epididymides and vasa deferentia ranged from 360 to $1,890 \times 10^6$ spermatozoa per side of the tract. In all individuals, more than 84% (94.6 ± 5.1 mean \pm SD, $n=10$) of all stored spermatozoa were located in the cauda epididymidis and as few as 2% were found in the vas deferens (see

Table 8.3). The portion of the vas deferens closest to the cauda epididymidis contained, on average, twice the number of spermatozoa of the terminal portion, regardless of whether the vas was divided into epididymal and urethral segments or into two portions of equal length (Table 8.3).

Table 8.3		
Distribution and Numbers of Spermatozoa in the Cauda Epididymides and Vasa Deferentia of Sexually Mature Plains Rats, <i>Pseudomys australis</i> and Hopping Mice, <i>Notomys alexis</i>.		
(Mean \pm S.D., range given in parentheses)		
Region of Duct	Number of Spermatozoa Stored ($\times 10^6$)	Percentage of Total Number of Spermatozoa Stored
Plains Rat (n=10)		
<u>Side A*</u>		
cauda epididymidis	845 \pm 318 (282 - 1340)	94.6 \pm 5.9 (80.0 - 98.6)
epididymal segment of vas deferens	26.2 \pm 20.7 (7.9 - 70.8)	3.9 \pm 3.9 (1.2 - 12.2)
urethral segment of vas deferens	11.5 \pm 14.8 (2.4 - 45.0)	1.7 \pm 2.3 (0.2 - 7.8)
<u>Side B#</u>		
cauda epididymidis	827 \pm 426 (339 - 1849)	94.6 \pm 2.1 (84.0 - 98.4)
epididymal segment of vas deferens	26.6 \pm 21.3 (9.8 - 71.8)	3.5 \pm 3.2 (1.1 - 10.2)
urethral segment of vas deferens	12.9 \pm 13.0 (2.4 - 41.4)	1.9 \pm 2.0 (0.3 - 5.9)
Hopping Mouse (n=12)		
<u>Side A*</u>		
cauda epididymidis	0.95 \pm 0.40 (0.44 - 1.62)	56.6 \pm 10.4 (43.2 - 75.6)
epididymal segment of vas deferens	0.49 \pm 0.31 (0.13 - 1.20)	28.4 \pm 11.6 (8.7 - 42.3)
urethral segment of vas deferens	0.25 \pm 0.18 (0.05 - 0.61)	15.3 \pm 10.9 (4.6 - 37.1)
<u>Side B#</u>		
cauda epididymidis	1.05 \pm 0.6 (0.59 - 2.58)	60.3 \pm 10.5 (40.6 - 75.9)
epididymal segment of vas deferens	0.40 \pm 0.23 (0.07 \pm 0.73)	24.3 \pm 12.4 (7.3 - 42.9)
urethral segment of vas deferens	0.27 \pm 0.17 (0.11 - 0.59)	15.5 \pm 7.0 (6.9 - 31.7)

Side A* The vas deferens was divided into two segments (epididymal and urethral) of equal length.

Side B# The vas deferens was divided into epididymal and urethral segments according to morphological features, see page 157.

Values for the number of spermatozoa in the cauda epididymidis are for one side of the reproductive tract only.

In male hopping mice, however, the total number of spermatozoa stored was only $0.8-3.1 \times 10^6$ per side of the tract. The distribution of these spermatozoa between the cauda epididymidis and vas deferens was more variable than in male plains rats and up to 60% of 'stored' spermatozoa were located in the vas deferens in several individuals. Of the spermatozoa in the vas deferens, a higher proportion was located in the urethral segment as compared with the epididymal segment when the duct was divided at the location where its diameter increased. This distribution was reversed, however, when the vas deferens was divided into two segments of equal length, with relatively more spermatozoa occurring in the first (epididymal) half of the duct as opposed to the second (urethral) half (Table 8.3). Consequently, a second series of observations was conducted in an attempt to more precisely locate the site at which most spermatozoa in the vas deferens are 'stored'.

In the second experiment, the vas deferens was divided into three segments, with the intermediate segment spanning the region of the junction between the epididymal and urethral segments, where the duct diameter increased. Each side of the reproductive tract was counted separately. Of the six animals for which spermatozoa were counted, two had very low numbers of spermatozoa in the excurrent ducts (less than 140,000 sperm/animal) and almost no spermatozoa in the tract on one side of the body. Sperm counts for the remaining four animals ranged between $1.1-2.5 \times 10^6$ spermatozoa per side of the tract ($2.4-4.9 \times 10^6$ spermatozoa per animal; Table 8.4). On average, around 29% (range 11-57%) of the total spermatozoa in the cauda epididymidis and vas deferens was located in the vas deferens, with 0.2-21.1% of all stored spermatozoa in the epididymal region of the vas deferens, 1.8-16.7% in the intermediate region and 2.7-21.6% in the urethral region of the duct (Table 8.4). The three animals with the highest sperm counts ($2.7-3.4 \times 10^6$) all had a higher proportion of their total stored spermatozoa located in the vas deferens (31.9-49.4%), compared with the animals with the lower sperm counts. Furthermore, the highest percentage of spermatozoa in the vas deferens was in the urethral region of the duct in two of these animals and in the intermediate region in the remaining animal.

Table 8.4
Distribution and Numbers of Spermatozoa in the Epididymides and Vasa Deferentia of Sexually Mature Hopping Mice, *Notomys alexis*.[†]

(Mean \pm S.D., range given in parentheses)

Region of Duct	Number of Spermatozoa ($\times 10^6$)	Percentage of Total Number of Spermatozoa Stored [‡]
Left hand side of tract		
caput + corpus epididymides	0.30 \pm 0.28 (0.001 – 0.73)	-
cauda epididymidis	0.60 \pm 0.47 (0.02 – 1.20)	71.4 \pm 15.8 (49.2 – 89.4)
epididymal segment of vas deferens	0.12 \pm 0.13 (0.002 – 0.30)	11.7 \pm 9.4 (0.2 – 21.1)
intermediate segment of vas deferens	0.12 \pm 0.17 (0.002 – 0.36)	9.4 \pm 7.9 (1.9 – 20.7)
urethral segment of vas deferens	0.08 \pm 0.08 (0.002 – 0.22)	7.5 \pm 4.0 (3.9 – 12.7)
entire left hand side of tract	1.22 \pm 1.04 (0.025 – 2.48)	
Right hand side of tract		
caput + corpus epididymides	0.36 \pm 0.32 (0.004 – 0.76)	-
cauda epididymidis	0.61 \pm 0.46 (0.01 – 1.11)	71.3 \pm 16.9 (52.2 – 89.7)
epididymal segment of vas deferens	0.10 \pm 0.11 (0.002 – 0.25)	10.1 \pm 5.5 (1.1 – 15.4)
intermediate segment of vas deferens	0.10 \pm 0.10 (0 – 0.26)	6.7 \pm 6.0 (0 – 15.7)
urethral segment of vas deferens	0.17 \pm 0.22 (0 – 0.46)	11.9 \pm 13.25 (0 – 29.5)
entire right hand side of tract	1.34 \pm 1.08 (0.017 – 2.41)	
Total Sperm per Animal (includes both sides of tract)	2.56 \pm 2.10 (0.042 – 4.89)	

[†] Data based on counts from six animals.

[‡] Values are the percentage of the total number of spermatozoa in the cauda epididymidis and entire vas deferens of that side of the tract. Sperm numbers in the caput plus corpus epididymides are not included in calculations.

8.4 Discussion

8.4.1 Duration of Sperm Transit

Results of the present study indicate that transit of spermatozoa through the genital ducts of the hopping mouse is more rapid than in the plains rat or other rodent species. While sperm transit takes about 10 days in the plains rat, which is within the 8-14 day range reported for many other mammalian species (Rowley *et al.*, 1970; Amann *et al.*, 1976; Table 8.5), it is completed in less than six days in the hopping mouse. Furthermore, passage is rapid through the caput and corpus epididymides, which have been implicated in sperm maturation in mammals (Bedford, 1966,1967; Orgebin-Crist, 1967), as well as through the storage regions of the duct. On average, spermatozoa spend less than a day in the caput and corpus epididymides of the hopping mouse, compared with 2.3 days in these regions in the plains rat and between two and 5.5 days in other mammals (Rowley *et al.*, 1970; Amann *et al.*, 1976; Table 8.5).

Several explanations have been put forward for interspecific variation in the duration of sperm transit through the caput and corpus epididymides. In the boar, which has the longest recorded transit time of these regions (Amann *et al.*, 1976), it appears that spermatozoa must pass through the corpus epididymidis before fertilising ability is acquired (Crabo and Hunter, 1975; Hunter *et al.*, 1976). In humans on the other hand, who have a rapid passage of spermatozoa through the caput and corpus epididymides (Amann and Howards, 1980), some degree of sperm maturation appears to occur in the ducts much closer to the testis. Human pregnancies have been reported after high-level epididymovasostomy, where spermatozoa bypass almost the entire epididymis (Schoysman and Bedford, 1986; Silber, 1988, 1989). Transit time might therefore be related to the minimum length of exposure to the epididymal environment, required by spermatozoa, for maturation to occur. In the stallion, the minimum extra-gonadal transit time, as determined by the first appearance of ³H-thymidine labelled spermatozoa in ejaculates was reported to be three to seven days (Gebauer *et al.*, 1974b). Hence these authors suggested that a short minimum transit time might mean:

- a) Spermatozoa are more mature when they leave the testis and hence do not require as much 'modification' in the epididymis as in other species. Therefore, they pass through it more rapidly.
- b) The maturational changes to spermatozoa that occur in the epididymides are more rapid than in other species.
- c) Spermatozoa are ejaculated in a less mature state.

Table 8.5
Species Differences in Transit Time of Spermatozoa through the Mammalian Epididymis

Species	Transit time (days)				Method*	Reference
	Caput	Corpus	Cauda	Total		
laboratory rat	---- 3.4 ----		5.1	8.5	B	Robb <i>et al.</i> (1978)
	---- 3 ----		5.1	8.1	B	Amann <i>et al.</i> (1976)
laboratory mouse	---- 3 ----		5.6-5.8	8.6-8.8		Meistrich (1975)
	---- 3 ----		2	5	A	Dadoune and Alfonsi (1984)
rabbit				6.6-10.6	A	Amann <i>et al.</i> (1965)
	3	1	5-6	9-10	A	Orgebin-Crist (1965)
	2.2	0.8	9.7	12.7	B	Amann <i>et al.</i> (1976)
hamster	---- 2.0 ----		13.6	15.6	B	Amann <i>et al.</i> (1976)
						Hickim & Hoffer (1988)
boar				9-12	A	Swierstra (1968a)
stallion				7.5-11.0	A	Gebauer <i>et al.</i> (1974b)
bull	2.5	0.6	5.2	9.3	B	Amann <i>et al.</i> (1976)
coyote				14	A	Kennelly (1972)
rhesus monkey	1.1	3.8	5.6	10.5	B	Amann <i>et al.</i> (1976)
human				12	A	Rowley <i>et al.</i> (1970)
	0.72	0.71	1.76	3.19	B	Amann and Howards (1980)
plains rat	0.82	1.51	6.85	9.2	B	this study
hopping mouse	---- 0.93 ----		3.09	4	B	this study

* A = tracking the progression of labelled spermatozoa through the duct, B = dividing epididymal sperm reserves by the DSP of the attached testis

Within a species, the slight discrepancies between the values for transit time as obtained by tracking the progression of labelled spermatozoa through the duct and from sperm reserves divided by DSP, may relate to methodological limitations. Interpretation of data from tracking studies is sometimes difficult due to more than one generation of germ cells in the testis incorporating the label. As pointed out in Chapter 5, the tracer substance used in this study, ³H-thymidine, is incorporated into the DNA of several generations of spermatogonia as well as preleptotene primary spermatocytes and hence a number of successive waves of labelled spermatozoa will enter the epididymis. Unless differences in the density of labelling of spermatozoa of these waves are readily identifiable, only the initial appearance

of labelled spermatozoa within a region gives a reliable indication of transit time³. Accurate detection of the time at which this occurs also depends on the selection of sampling intervals of an appropriate length. The two-day interval, which was used in the present study due to limits on the availability of experimental animals, was too long to provide an accurate picture of how rapidly spermatozoa were moved through the caput and corpus regions of the epididymal duct. This was particularly evident in the hopping mouse, since within a two-day interval, the front of labelling advanced from spermatids at the point of release from the testicular seminiferous epithelium to spermatozoa in the cauda epididymidis.

In addition, data on advancement of the label front based on comparisons between individuals, assume that spermatozoa are released from the testis at the same point in time in the various individuals. It has been reported, however, that in the rabbit, labelled spermatozoa are first released from the testes as early as day 28.5 or as late as day 32.5 following injection of ³H-thymidine (Amann and Lambiase, 1969; Amann, 1972). In the plains rat, release of labelled spermatozoa from the seminiferous epithelium and their subsequent appearance in the caput epididymidis was expected to occur approximately 33.5 days following ³H-thymidine administration. This expectation was based on three cycles of the seminiferous epithelium, each of 11.2 day's duration (see Chapter 5), having elapsed between incorporation of label into preleptotene spermatocytes and spermiation. Smears and sections of epididymis from the animal sacrificed on day 34, however, did not contain labelled spermatozoa and the first appearance of labelled spermatozoa in the epididymis was only observed on day 36. This indicates that there may be variability in the timing of sperm transit events between individual plains rats.

Estimates of transit time derived from extra-gonadal sperm reserves and DSP are based on the assumption that all spermatozoa leaving the testis are ejaculated and resorption of spermatozoa by the ducts during transit is negligible. This appears reasonable since investigations of the fate of spermatozoa following vasectomy in a variety of species failed to find evidence of phagocytosis of spermatozoa by the epididymal epithelium (Bedford, 1976). A second assumption on which transit time estimations are based, namely that spermatozoa travel through the epididymis at a constant speed, may not be valid however, because it has been shown that spermatozoa located peripherally in the duct progress more rapidly than centrally located spermatozoa (Orgebin-Crist, 1965). This results in a mixing, particularly in the cauda epididymidis, of sperm populations that have entered the epididymis from the testis at different times. Hence it is probable that some spermatozoa

³ Theoretically, sperm derived from the preleptotene primary spermatocytes that initially incorporated the ³H-thymidine should show the greatest intensity of label in terms of the number of silver grains per cell. Each successive mitotic division of spermatogonia subsequent to label incorporation will result in dilution of labelling intensity by one half, however, differences in intensity of label could not be readily detected in the present study.

pass through the cauda epididymidis more rapidly than do others and there is the potential for over or under-estimating transit time depending on the degree of mixing.

Some of the variability in transit time through the cauda epididymidis within a species probably also reflects the state of sexual activity of the individual. Sperm transit time has been shown to decrease with increased frequency of ejaculation (Orgebin-Crist, 1962; Amann *et al.*, 1974), presumably as a consequence of depleted sperm reserves and ejaculation of less mature spermatozoa in an attempt to maintain adequate numbers of spermatozoa in the ejaculate, capable of bringing about fertilisation. Hence within a species, duration of transit in sexually rested individuals may provide an indication of the maximum time that spermatozoa retain viability in the male tract, whereas that in sexually active males more closely approximates the minimum time required for sperm maturation.

8.4.2 Pattern of Sperm Distribution and Storage

The distribution of spermatozoa in the plains rat epididymis and vas deferens was consistent with the cauda epididymidis being the site of sperm storage. On average, 67% of the total spermatozoa in all regions of the epididymis and vas deferens and more than 80% of spermatozoa in the 'storage' regions were located in the cauda. The higher percentage of spermatozoa in the epididymal as compared with the urethral segment of the vas deferens, particularly in individuals with large caudal sperm reserves, is likely to merely reflect a 'spill over' from the caudal storage area.

The earlier findings of Breed (1981b; 1986) that, in the hopping mouse, absolute numbers of spermatozoa are low and their relative distribution varies between individuals and even between sides of the tract in the same individual, were confirmed. In the present study, in all adult animals, the total number of spermatozoa in the paired excurrent ducts never exceeded 8 million and averaged 3-5 million. The pattern of distribution of spermatozoa within the ducts varied widely even though care was taken to a) ensure that division of the ducts into segments for counting was consistent between individuals and b) minimise any redistribution of spermatozoa within the ducts due to application of pressure during the collection process. It was found that the cauda epididymides are not the only site of sperm storage in this species. Between 25 and 60% of spermatozoa from the lower regions of the tract were present in the vas deferens in some individuals. Subdivision of the vas into two portions of equal length, or into epididymal and urethral segments on the basis of duct morphology, resulted in different numbers of spermatozoa within the various segments. Proportionately more spermatozoa were present in the urethral segment when the vas deferens was divided at the junction where the circular lumen of the more proximal regions of the duct changed to the highly infolded mucosa indicative of the urethral

segment. When the vas deferens was divided into segments of equal length, however, proportionately more spermatozoa were located in the epididymal segment adjoining the cauda epididymidis. Since, on the basis of duct morphology, the epididymal segment extends only about two fifths of the total length of the vas deferens, these results suggest that the region of the vas deferens where the epithelial lining and underlying lamina propria first show infoldings may act as a major additional site of sperm storage. However, such a suggestion may not be valid as considerable natural variation in sperm numbers per segment were observed between individuals. Therefore, in an attempt to clarify the pattern of sperm distribution in the vas deferens, sperm counts were undertaken on a further six animals in which the vas deferens was divided into three parts: a) an epididymal segment, b) an intermediate segment spanning the region 3 mm either side of the morphological junction and c) a urethral segment. From this series of observations, no consistent pattern of sperm distribution was found in the vas deferens. On average, a similar number of spermatozoa was present in the vas deferens as in caput plus corpus regions of the epididymis (22.6% cf. 22.2% respectively), with 55.2% of sperm occurring in the cauda epididymidis. The proportion of spermatozoa in the vas deferens ranged from 8–36% of the total number in the excurrent ducts, or 10–50% of spermatozoa in the 'storage' areas (ie. cauda epididymidis + vas deferens, Table 8.4). The results obtained, however, were difficult to interpret, since two of the six animals had extremely low numbers of spermatozoa (<140,000), of which virtually none were located in the lower regions of the vas deferens. If these animals were disregarded, there appeared to be a trend for the majority of spermatozoa in the vas deferens to be located in the intermediate and/or urethral regions, particularly in the animals with the highest total sperm counts.

The question that arises from the above data is "Why are fewer spermatozoa stored for a shorter period of time in the hopping mouse excurrent ducts?" Possible answers to this question may relate to the environmental conditions provided by the ducts. One reason why the cauda epididymidis in scrotal mammals is able to store large numbers of spermatozoa is because it provides a cool environment that confers stability to sperm membranes by reducing their fluidity (Moore, 1996). Temperature dependent compounds secreted by the cauda epididymal epithelium may also act to stabilize spermatozoa during their storage (Esponda and Bedford, 1986), thereby contributing to the maintenance of sperm viability for an extended time frame. Conversely, exposure of the cauda epididymidis to abdominal temperature reduces its capacity for sperm storage and alters the pattern of secretion by the cauda epididymal epithelium (see section 1.6.4, Chapter 1 and section 7.4.3, Chapter 7). In the hamster it has been shown that spermatozoa stored at abdominal temperature in the cauda epididymidis undergo capacitation in the female tract more rapidly than when they have been stored at scrotal temperature (Bedford and Yanagimachi, 1991). This result further implies that at lower temperatures, the cauda

epididymis may confer stabilising properties to stored spermatozoa. Such properties must be reversed in the female tract before spermatozoa can penetrate an oocyte and therefore the more stable the spermatozoon, the longer it may take to undergo capacitation and the acrosome reaction (Bedford and Yanagimachi, 1991).

In Chapter 7, the possibility that the excurrent ducts of the hopping mouse are exposed to temperatures more closely approaching abdominal temperature than encountered by the ducts of other rodent species was raised. This was based on variability in the observed position of the testes and epididymides between individuals. If this is the case, the higher temperature to which the cauda epididymidis is exposed may destabilise sperm membranes and increase the possibility of their premature demise before they reach the oocyte, if they remain in the male tract for extended periods of time. Therefore, since both DSP and the absolute number of spermatozoa in the excurrent ducts are low, the variability in the site of storage of spermatozoa and their rapid transit through the duct might be part of a strategy to optimise the likelihood of at least some spermatozoa retaining viability long enough to fertilize oocytes in the female tract. If fewer spermatozoa are stored in any one area, there may be the possibility of greater levels of interaction between spermatozoa and the duct epithelium, thereby optimising their potential viability. Another point worth consideration is that there is considerable variability in both nuclear and acrosomal morphology of hopping mouse spermatozoa (Breed and Sarafis, 1983, Suttle *et al.*, 1988). It might therefore be that hopping mouse spermatozoa are inherently less stable and that this instability may provide the impetus for rapid sperm transit. All of these suggestions are, however, purely speculative and remain to be tested.

It is also interesting to note that the hopping mouse, at least superficially, has many characteristics of sperm production and storage in common with humans, including a long spermatogenic cycle, low DSP, meagre sperm reserves and variable sperm morphology. There is also some evidence that in humans a slightly higher proportion of spermatozoa sometimes occurs in the vas deferens, with Amann and Howards (1980) estimating that approximately 14% of the total spermatozoa in the human sperm storage areas are located in the vasa deferentia and ampullae.

8.5 Summary

Sperm transit, distribution and storage in the plains rat is consistent with what has been documented for other mammalian species. Spermatozoa are comparable in number with those of the laboratory rat, are predominantly stored in the caudae epididymides and pass through the duct system in about ten days in sexually rested individuals.

In the hopping mouse, on the other hand, epididymal sperm numbers are low and their distribution within the duct system and between the two sides of the reproductive tract variable, even in the one individual. A high proportion of spermatozoa are located in the vas deferens of some animals and there is some evidence to suggest that these spermatozoa usually occur in the more distal segments of the duct, particularly in individuals with high total sperm counts. Regardless of the site of storage, transit of spermatozoa through the epididymis is completed in less than 4-6 days and a shorter period of time is spent by spermatozoa in both the maturation (<1 day) and storage (3-5 days) areas of the ducts.

Chapter 9 General Discussion and Conclusions

As stated in section 1.9.1 on page 59, the general aim of the present study was to compare the relationships between testis size, the efficiency of sperm production and sperm storage capacity in two Australian hydromyine rodents, the plains rat, *Pseudomys australis* and the hopping mouse, *Notomys alexis*. The research undertaken confirms and extends previous findings from our laboratory that these closely related species appear to have developed highly divergent reproductive strategies, as evident from the vast differences in the size and morphology of their testes and extra-testicular duct systems and the kinetics of germ cell production and storage. Furthermore, it is the hopping mouse that presents the greater number of unusual features with regard to male reproductive function. Suggestions as to the possible reasons for such an unusual suite of characteristics will be considered in the following pages, in the light of what is known from investigations of other mammalian species.

9.1 Variation in Mammalian Testis Size

Examination of the literature reveals that, within mammals, huge differences exist in the size of the testes. Some of the earliest data on variation in testis size were obtained from observations made in primates (Schultz, 1938; Short, 1977, 1979; Harcourt *et al.*, 1981). It was noted that primate testes differ greatly between species, both in their absolute size and relative to body mass (Schultz, 1938). Within the great apes (Pongidae), the chimpanzee (body weight ~47 kg) was found to have relatively large testes (paired weight 120 g), compared with the much larger orangutan (100 kg) and gorilla (200 kg), both of which had considerably smaller testes (paired weights 35 g and 36 g respectively; Short, 1977, 1979). Subsequent studies of a larger number of primate species have shown that the ratio of testes mass to body mass ranges from 0.02% in the gorilla to 3.56% in a small cebid monkey, *Microcebus murinus* (Harcourt *et al.*, 1981; Harcourt *et al.*, 1995).

Similar variation in the absolute and relative mass of the testes has also been documented in other mammalian orders, including rodents and cetaceans and across mammals as a whole (Kenagy and Trombulak, 1986). Furthermore, an allometric relationship has been shown to exist between testes mass and body mass, which predicts that small mammals invest a greater proportion of their body mass and energy expenditure in producing testicular tissue than larger mammals (Kenagy and Trombulak, 1986). Nevertheless even among mammals of similar body mass, considerable variation in testes mass occurs. For example, in small rodents, relative testes mass varies from as little as 0.15% of body mass

in several hopping mouse (*Notomys*) species (Breed, 1982a, 1997) to 7.3% of body mass in the grasshopper mouse, *Onychomys torridus* (Kenagy and Trombulak, 1986) and greater than 8% in the gerbil, *Tatera afra* (Allanson, 1958). This represents approximately a 50-fold difference in relative testes mass! The large range of interspecific variation in relative testes mass in the Rodentia is also evident at the family and genus levels, with both large and small testes relative to body mass occurring in the families Cricetidae and Muridae. Among North American voles (family Cricetidae), relative testes size as indicated by the ratio of testis length to body length, ranges from 0.05 to 0.14, with the largest testes relative to body size occurring in *Microtus pennsylvanicus* and the smallest in *M. californicus* and *M. mexicanus* (Heske and Ostfeld, 1990). The largest testes within murid rodents are found in *Pogonomys macrourus*, where they comprise 5.2% of body mass (Breed, 1997), followed by *Apodemus agrarius*, *Rattus exultans* and *R. rattus*, with testes comprising 4.3-4.6% of body mass (Kenagy and Trombulak, 1986).

Variation in testes mass is not confined to differences between species, intraspecific variation in testes mass has also been found to occur. An analysis of testes mass relative to body mass within three species of rodents, a murid, *Rattus rattus*, a scuirid, *Spermophilus lateralis* and a cricetid, *Peromyscus maniculatus* showed variation of a similar magnitude within each species as between species and genera within the same family (Kenagy and Trombulak, 1986). Similarly, significant differences in relative testes size (testis length/body length) were found among populations of *Peromyscus maniculatus* and *P. leucopus* (Ribble and Millar, 1992) and among human males of different geographic and ethnic origins (Short, 1979, 1984, 1997; Mittwoch, 1988).

Among the mammals, the hydromyine rodents of Australasia (subfamily Hydromyinae) show the most extensive variation in the size of their testes. Three species of the genus *Notomys*, - *N. alexis*, *N. mitchelli* and *N. fuscus* have the smallest recorded testes mass relative to body mass of any rodent species (0.14-0.17%) and the small size of their testes in absolute terms is rivalled only by that of several closely related species, *Pseudomys delicatulus*, *P. pilligaensis* and *P. novaehollandiae* (Breed, 1982a, 1986, 1997). At the opposite end of the scale, other species in the genus *Pseudomys* and also in the genera *Rattus*, *Pogonomys*, *Chiruromys* and *Melomys* have a relative testes mass 20 to 30 times larger (>3.6% of body mass) than that of the *Notomys* species (Breed, 1997). In fact, *Pogonomys macrourus*, with a relative testis mass of around 5% (Breed, 1997), is among those species of mammals with the largest relative testis size so far recorded (Kenagy and Trombulak, 1986). There is also evidence of huge variations in relative testes mass within *Notomys* and some *Pseudomys* species. Among *N. alexis* individuals, relative testes mass ranges from 0.10% to 0.21%, which represents a variation in testes mass relative to body mass of around 30% from the mean value of 0.15% (Breed, 1982).

9.2 What Causes Variation in Testis Size?

It has been shown that among mammals, testis mass bears little relationship to whether the testes are located within the abdominal cavity or a scrotum (Setchell, 1978; Kenagy and Trombulak, 1986). Neither have correlations between testis mass and body form and testis mass and mode of locomotion been found in mammals (Kenagy and Trombulak, 1986). Several explanations, however, have been put forward as to how and why variations in testis size may have arisen. These explanations can be divided into two broad categories, those that approach the question from an evolutionary perspective and those that focus on mechanistic factors operating on the testis and its environment to either directly or indirectly modify testis size. All explanations, however, have as their basis the occurrence of genetic variability among individuals both within and between, species.

9.2.1 Selection Pressures

From an evolutionary perspective, genetic variability enables the occurrence of differential responses to various internal and external forces, resulting in changes in a characteristic(s). The causative forces leading to the differential response between individuals are known as 'selection pressures' (Darwin, 1871). In the case of testis mass, the challenge has been to identify the selection pressures that have led to the observed variation in testes mass in mammals.

9.2.2 Relationships with Breeding System and Sperm Competition

From his observations of the great apes, Short (1977, 1979) proposed that differences in the size of the testes relate to differences in breeding systems. It was noted that the small testes in the gorilla were accompanied by infrequent copulations and a single male breeding system, in which only one male mates with a female in any one oestrus, whereas in the chimpanzee, the large testes correlated with a promiscuous mating system and high copulatory frequency. In the case of the chimpanzee, it was suggested that such a breeding system would advantage males with the highest sperm production and hence the largest testes (Short, 1977, 1979).

Short's idea of a link between testis size and breeding system was subsequently expanded to include intermale sperm competition. In promiscuous species such as the chimpanzee, several males mate repeatedly with the same oestrous females (Tutin, 1980), hence the situation arises where sperm from more than one male are likely to compete within the female tract to fertilise ova. It was therefore hypothesised that selection would favour males that could deposit the largest numbers of sperm in the female tract and that this

would result in selection for maximising the spermatogenic tissue in the testis and hence larger testes (Harcourt *et al.*, 1981).

In summary, these preceding ideas led to the hypothesis that intermale sperm competition and hence the types of breeding system, contribute to interspecific variation in relative testis mass in mammals. In those species with a high copulatory frequency, or where there is competition between the sperm of various males to fertilise a female's ova, selection will favour males with relatively larger testes capable of producing higher numbers of spermatozoa, over those with relatively smaller testes. Conversely, in species with low copulatory frequencies or little or no sperm competition, testes mass would be expected to be small, due to the lack of such selection pressures (Short, 1997). Comparative studies in primates (Harcourt *et al.*, 1981; Harvey and Harcourt, 1984; Møller, 1989; Harcourt *et al.*, 1995), other mammals (Kenagy and Trombulak, 1986), birds (Møller, 1988) and butterflies (Gage, 1994) have subsequently found these relationships to hold for a wide range of species.

9.2.3 Genetic, Physiological, Endocrinological and Morphological Considerations

From a mechanistic viewpoint, genetic control of testis size is a complex and poorly understood process. Several studies carried out on mice point to there being a number of genes located on the autosomes as well as the sex chromosomes, that play a role in the regulation of adult testis size. Hayward and Shire (1974) reported that in CBA/FaCam strain mice, where the testes are much smaller than those of most other mouse strains, around 40% of the reduction in testis size could be attributed to factors on the Y chromosome. The remaining variability was suggested to be due to autosomal factors, or to interactions between the sex chromosomes and autosomes. Herrick and Wolfe (1977) and Hunt and Mittwoch (1987) reported similar findings for other mouse strains. They found that, although genes expressed on the Y chromosome influenced the weight of the testes, the major component of genetic variation leading to differences in testis size between strains appeared to be autosomal. At least two autosomal genes were suggested as playing a role in the control of testis size in C57BL strain mice (Chubb, 1992).

What has remained less clear, however, is how gene expression brings about the observed differences in testis size. Clues as to the mechanisms of action of genes in regulating testis size have been gained from investigations of the physiological and endocrinological environments of testes of various sizes and from examination of associated testicular morphology.

It was observed that, in C57BL/10 strain mice, a proportion of seminiferous tubules displaying apparent abnormalities of spermatogenesis, accompanied the small testes (Shire and Bartke, 1972; Chubb, 1992). Analysis of germ cell numbers showed that the number of type A spermatogonia relative to the number of Sertoli cells was significantly reduced and approximately one third of seminiferous tubules contained low numbers of primary spermatocytes (Shire and Bartke, 1972). This suggested that the smaller testes of this strain, as compared with other mice, might be due to factors that compromise spermatogenic function, leading to fewer germ cells. In particular, it was suggested that the mice might be deficient in androgenic hormones, which could cause a reduction in the number of type A spermatogonia, without significant impairment of the later stages of spermatogenesis (Shire and Bartke, 1972). In a subsequent study of C57BL strain mice, however, spermatogenic function, as measured by the number of spermatids per milligram of testicular tissue, was not significantly decreased in the small-sized testes from that of larger testes (Chubb, 1992). Furthermore, no correlation was found between the proportion of 'abnormal' tubules per testis and testis size and there was no reduction in the weights of the epididymides and seminal vesicles over those of other strains, suggesting that the animals were not androgen deficient (Chubb, 1992). Morphometric analysis of testicular composition did, however, suggest that the number of Sertoli cells per testis was lower (Chubb, 1992). Since each Sertoli cell is capable of supporting a finite number of germ cells only (Russell and Peterson, 1984; Kluin *et al.*, 1984; Berndtson and Thompson, 1990; Sharpe, 1994), a lower absolute number of Sertoli cells will result in less seminiferous epithelium, which, in turn, results in a smaller testis size. The report that the lower testis weight in CBA mice appeared to be due to a reduction in the length of the seminiferous tubules (Hayward and Shore, 1974) also supports the possible occurrence of fewer Sertoli cells in the small testes of this mouse strain.

A second line of evidence that implies a link between Sertoli cell number and adult testis size has centred on elucidating the factors that regulate Sertoli cell proliferation and maturation. FSH has been implicated as a major factor regulating Sertoli cell mitoses in laboratory rats (Cunningham *et al.*, 1978; Orth, 1984; Orth *et al.*, 1984). Hemicastration of neonatal laboratory rats results in hypertrophy of the contralateral testis, presumably in response to elevated levels of FSH and an increase in Sertoli cell numbers (Cunningham *et al.*, 1978). Similarly, transient hypogonadotrophism experiments indicate that FSH influences the mitosis of Sertoli cells (Vogel *et al.*, 1983) and Sertoli cells from immature, but not adult, laboratory rats have been shown to divide in culture in the presence of FSH (Griswold *et al.*, 1977). Further evidence of the role of FSH in influencing testis size is provided by a study of gonadotrophin-deficient laboratory mice, where administration of exogenous FSH during the first two weeks of life, increased Sertoli cell numbers and testis size in adults by 43% (Singh and Handelsman, 1996). A similar increase in adult testis

size following neonatal administration of recombinant FSH was found in laboratory rats (Meachem *et al.*, 1996). The crucial link between FSH, Sertoli cell proliferation and increased testis size in all of these studies is that the elevated FSH levels coincide with the normal period of expansion in the Sertoli cell population. In the laboratory rat and laboratory mouse, mitotic activity of Sertoli cells is maximal prior to birth, declines in the postnatal period and ceases by about day 16-20 postpartum (Steinberger and Steinberger, 1971; Nagy, 1972; Orth, 1982; Wang *et al.*, 1989; Vergouwen *et al.*, 1991), although the timing of mitoses appears to differ in some other mammalian species including the rhesus monkey (Arslan *et al.*, 1993; Marshall and Plant, 1996), sheep (de Reviere *et al.*, 1980) and pig (Kosco *et al.*, 1989).

Other studies have shown that laboratory rats made hyperthyroid at birth exhibit a 50% reduction in adult testis size (Van Haaster *et al.*, 1993) which was attributed to premature cessation of Sertoli cell proliferation and accelerated Sertoli cell maturation. Conversely, neonatal administration of 6-propyl-2-thiouracil (PTU) resulted in prolongation of the period of Sertoli cell replication and a subsequent increase in adult testis size over that of control animals (Joyce *et al.*, 1993, Cooke *et al.*, 1994), despite depressed levels of FSH (Kirby *et al.*, 1992). Hence, these findings suggest that thyroid hormones also play a role in determining testis size by inhibiting neonatal Sertoli cell proliferation and stimulating secretory activity associated with their maturation. This was supported by an altered pattern of expression of mRNAs associated with mitogenesis and the acquisition of secretory activity in neonatally hypothyroid animals (Bunick *et al.*, 1994).

In summary, all of these data point to the absolute number of Sertoli cells present within the testis as being the morphological basis for the determination of mammalian testis size. Sertoli cell numbers, in turn, appear to be governed by the physiological and hormonal environment during the time period in which their replication and early maturation normally occurs. In particular, FSH and thyroid hormones have been shown to play a role in modulating Sertoli cell number and hence the size of the testes, although ongoing research is now implicating additional factors including growth hormone, β endorphin and activin in this regulatory role (see Sharpe, 1994; Boitani *et al.*, 1995).

9.3 Testis Size as it Relates to the Dynamics of Sperm Production

It is apparent from the above discussion that the size of an individual's testes plays a pivotal role in determining how many sperm he has the potential to produce and hence are potentially available for ejaculation and possible fertilisation of an ovum. This is supported by numerous studies which have shown a positive correlation between testis size

and numbers of spermatozoa (Osman and El Azab, 1974; Abdou *et al.*, 1978; Johnson *et al.*, 1991). Nevertheless, despite the fundamental requirement for testes of sufficient size to meet the demand for appropriate numbers of spermatozoa, a range of additional intra- and extra-testicular factors modulates the actual (as opposed to potential) spermatozoal output of an individual or species. These factors include a) the proportion of the testes devoted to sperm production, ie. the amount of seminiferous epithelium as compared with interstitial and capsular tissue, b) the time interval required for completion of the spermatogenic process, c) the efficiency with which the spermatogenic tissue is able to produce spermatozoa (sperm production per gram of parenchyma, or the ratio of germ cells to Sertoli cells and d) the capacity of the individual to store spermatozoa in a viable condition until they are required. Furthermore, several of these factors are in turn influenced by the structural organisation of the testes and the site(s) and duration of sperm storage within the excurrent ducts.

9.4 Determinants of Testis Size in the Hopping Mouse - An Enigma!

Among mammals, hopping mice, (*Notomys* species) have uniquely small testes relative to body mass (Kenagy and Trombulak, 1986) and a correspondingly low number of spermatozoa in their epididymides and vasa deferentia (Breed 1982a; Peirce and Breed, 1989). In light of the previous discussions, such characteristics point to there being little or no intermale sperm competition in hopping mice, consistent with a single male mating system. Hopping mice, however, are highly social animals that, when placed together, tend to huddle as a single group regardless of the sex of the individuals (Happold, 1976). Moreover, it has been shown in our laboratory that all cohabiting adult males of a group have spermatozoa in their cauda epididymides and vasa deferentia and are likely to be fertile at the same time. Therefore when a female comes into oestrus, the potential exists for insemination by more than one male, hence there is the possibility of sperm competition within the female tract (Breed, 1997). If this is the case, then it is the opposite of what is predicted on the basis of the small testis size and low sperm numbers in the hopping mouse.

Although little is known about the breeding system of the hopping mouse in the wild, observations in the laboratory of the interactions of groups of several males and a female over a period of oestrus have indicated that more than one male sometimes mates with a female (Breed, 1990b; Breed and Washington, 1991). This suggests that sperm competition may take place in the female tract. Subsequent experiments to determine the paternity of offspring from electrophoretic markers, however, found no evidence of multiple paternity within a litter, although different males sometimes sired successive

litters (Breed and Adams, 1992). Hence, the available evidence from laboratory bred animals linking testes size and sperm numbers with intermale sperm competition and breeding system in the hopping mouse is at best tenuous.

An alternative explanation for the small relative testes mass in the hopping mouse is that it might arise due to mechanisms that result in highly efficient sperm transport, or that maximise sperm survival in the female tract (Breed, 1997). Such mechanisms could include modifications of female reproductive tract morphology. Unlike most other murid rodents, female hopping mice lack a hard, fibrous cervix (Breed 1985b); hence entry of spermatozoa into the uterus is probably not impeded, as it would be in, for example, the laboratory mouse. Therefore, a greater percentage of inseminated spermatozoa in the hopping mouse may be capable of reaching the upper portions of the female tract. Such an occurrence appears to be supported by the recovery of comparable numbers of spermatozoa in the oviducal isthmus of both the hopping mouse and recently mated laboratory mice (Breed and Washington, 1991). This is despite laboratory mice having much larger testes and presumably inseminating many more spermatozoa. Similarly, suggestions of a causal relationship between the occurrence of sperm storage sites in the isthmus of the oviduct and low production of spermatozoa have been made in marsupials (Bedford *et al.*, 1984; Bedford, 1991b, 1996). In shrews, however, such a relationship between low sperm numbers and the presence of isthmic crypts appears less clear cut. Isthmic crypts are present in the oviducts of the female Asian musk shrew, *Suncus murinus*, the males of which inseminate only around 1×10^6 spermatozoa (Bedford *et al.*, 1994), however, in the common shrew, *Sorex araneus*, which produces and presumably inseminates much greater quantities of spermatozoa, oviducal crypts are also present (Brambell, 1935). It has been suggested that in shrews, the crypts may not have a storage or protective function (which could maximise the likelihood of fertilisation following the insemination of relatively low numbers of spermatozoa), but rather act as sperm traps that may minimise the possibility of polyspermy occurring (Bedford *et al.*, 1997). In the hopping mouse, a few small oviducal crypts are present within the female, but do not appear to contain spermatozoa (Breed, personal communication). The presence of crypts that 'store' spermatozoa may not be necessary, however, since a large copulatory plug that normally traps a large proportion of all the spermatozoa that are inseminated in the region of the vagina and cervix, is not formed in the hopping mouse (Breed, 1997).

By contrast with the hopping mouse, relative testes mass and sperm numbers in the plains rat, *Pseudomys australis*, are large (Breed, 1982a; Peirce and Breed, 1987, 1989; this study) and within the usual range for murid rodents (Kenagy and Trombulak, 1986). Laboratory data have shown that multiple paternity occurs within litters (Breed and

Adams, 1992), consistent with there being intermale sperm competition and a multimale breeding system, which could account for the large testes and high sperm numbers.

9.5 Organisation of the Seminiferous Epithelium and Germ Cell Dynamics

The process of spermatogenesis is remarkably similar between mammals (Courot *et al.*, 1970, Clermont, 1972; Sharpe, 1994) and even between some classes of vertebrates (Roosen-Runge, 1952, 1977). Hence the testicular seminiferous epithelium of most mammalian species displays a similar general organisation in which combinations of germ cells form well defined cellular associations that occupy large areas of a seminiferous tubule and succeed each other in a cyclical manner over time (Leblond and Clermont, 1952a; Clermont, 1972). As a consequence, cross sections through a seminiferous tubule display a single cellular association (Clermont, 1972; Steinberger and Steinberger, 1975). However, in a few species, the most notable of which is the human, cellular associations are less well-defined in their composition and occupy smaller regions of the seminiferous epithelium, such that several cellular associations are often seen within a tubular cross section (Clermont, 1963; Heller and Clermont, 1964; Chowdhury and Marshall, 1980).

In the plains rat and hopping mouse clear differences have been shown to exist in the organisation of the seminiferous epithelium. Although eight different cellular associations were initially identified within the seminiferous tubules of both species, around 20% of tubular cross sections in the hopping mouse contained multiple cellular associations as opposed to a single association in the plains rat (Peirce and Breed, 1987). Furthermore, the cellular composition of hopping mouse associations was reported to be somewhat variable, in comparison to the highly uniform composition observed in the plains rat. Considerable intraspecific variability in the organisation of the seminiferous epithelium in hopping mice was also reported (Peirce and Breed, 1987). In the present study, organisation of the seminiferous epithelium was reinvestigated using more rigidly defined criteria to identify the cellular associations. This was thought necessary because of the possibility that some of the variability observed in the previous study might have been due to misidentification of cellular associations. Apart from 11 rather than eight cellular associations being identified in the plains rat in the present study, the previous findings of Peirce and Breed (1987), including the variability in composition of cellular associations and the presence of multi-stage tubular cross sections in the hopping mouse, were confirmed.

In the present study, the variability in the composition of individual cellular associations was found to be related to a range of phenomena including a) missing generations of germ

cells, b) the presence of a generation of germ cells displaying a morphology not usually seen in combination with that of the other germ cell generations present, c) morphological variation within the round and elongate spermatid populations of an association, and d) anomalous size and shape characteristics of germ cells, particularly spermatids (refer to Figs 3.25-3.30). Several of these unusual morphological features are identical to what is seen in the golden hamster during the establishment of spermatogenesis. In the 30 day old golden hamster, the younger germ cell generations of some cellular associations, i.e. spermatogonia and spermatocytes, showed a developmental level one or more cycle stages in advance of that of the leading spermatid generation (Miething, 1998). Hence it was suggested that an arrest of the normal maturational events was selectively affecting spermiogenesis, thus resulting in non-conformity of germ cell generations within a cycle stage (Miething, 1998). This suggestion of selectively arrested spermatid development was further supported by observations that a) the elongate spermatid population often exhibited a heterogeneous level of development, such that individual spermatids within a cellular association could not all be assigned to the same step of differentiation and b) the regions of the seminiferous epithelium affected contained spermatids with varying degrees of structural deformity, many of which subsequently did not complete spermiogenesis.

A further point of interest from Miething's (1998) investigations was that cessation of maturational arrest of spermatid development and the first appearance of elongate spermatids within the seminiferous epithelium coincided with the onset of 11 β -hydroxysteroid dehydrogenase (11 β -HSD) activity in Leydig cells. This was interpreted as indicating that the onset of spermatid elongation is highly testosterone dependent and that 11 β -HSD is essential in regulating the testosterone output of Leydig cells. That the onset of spermatid elongation is dependent on testosterone is supported by the failure of round spermatids to progress through the elongation process following hypophysectomy (Bartlett *et al.*, 1989) or suppression of LH (O'Donnell *et al.*, 1994). Similarly, a reduction in the number of step 8-9 spermatids follows administration of ethane dimethane sulphate (Cameron *et al.*, 1993) and the presence of androgen receptors within the nuclei of elongate spermatids (Wright and Frankel, 1980; Vornberger *et al.*, 1994) also points to the involvement of testosterone in spermatid development. The role of 11 β -HSD in the regulation of testosterone levels and hence establishment and maintenance of spermatogenesis, is linked to its ability to inactivate glucocorticoids via their oxidation (Monder and Shackleton, 1984). Leydig cells have been shown to possess glucocorticoid receptors (Stalker *et al.*, 1989) and exhibit a glucocorticoid-mediated suppression of androgen biosynthesis (Welsh *et al.*, 1982). Several studies have subsequently shown that 11 β -HSD decreases the intracellular glucocorticoid concentration, thereby protecting Leydig cells against suppression of testosterone synthesis and secretion (Monder *et al.*, 1994a, 1994b).

11 β -Hydroxysteroid dehydrogenase activity and glucocorticoid levels have not been investigated in the hopping mouse, however, measurements of circulating levels of testosterone in some adult males have been shown to be barely above those of females (Breed, 1983). From experiences within our laboratory, it is clear that hopping mice do not respond favourably to stress eg. temperature fluctuations, handling, experimental procedures, therefore, it may be that low level stress is contributing to increased glucocorticoid levels which in turn sporadically interfere with testosterone secretion.. Alternatively, 11 β -HSD activity may be low. Both of these possibilities might result in a less stable environment for spermatogenesis and a higher incidence of organisational variability of the seminiferous epithelium and defects of germ cells and thus are worthy of further investigation.

The anomalous organisation of the seminiferous epithelium in the adult hopping mouse is reminiscent of the situation in the human (Heller and Clermont, 1964) and points to there being less synchronisation of germ cell development and looser control over spermatogenesis in the hopping mouse than in other rodent species. Possibly the only germ cells that develop synchronously within a generation are those derived from the same stem spermatogonium and that are joined by cytoplasmic bridges. The role of cytoplasmic bridges in synchronous development has been confirmed by the biochemical demonstration of the transfer of mRNA among the cells of a clone (Braun *et al.*, 1989). Synchronous development of adjacent, unconnected clones, however, is dependent on signals from the local epithelial environment. Sharpe (1994) postulated that there might be a less homogeneous local environment in areas of seminiferous tubules comprised of a mix of different cellular associations, due to differences in the secretory function of the Sertoli cells surrounding the germ cells in each of the cellular associations. It is known that Sertoli cell activity varies in a cyclical manner according to the germ cell types present within the epithelium (Parvinen *et al.*, 1986; Sharpe *et al.*, 1992; Parvinen, 1993). It is less likely that the presence of particular germ cell types of a cellular association coordinate the developmental activity of their neighbours, since normal development of the remaining cell populations takes place even when a particular population is removed from the epithelium experimentally (Chowdhury and Steinberger, 1964; Dym and Clermont, 1970; Bartlett *et al.*, 1988; Russell *et al.*, 1990a). Similarly, the composition and developmental progression of cellular associations during the establishment of spermatogenesis at puberty proceeds in the same manner as in adult testes (Clermont and Perey, 1957; Miething, 1998), despite the absence of one or more germ cell generations. In the present study, what remains unclear is whether the less organised seminiferous epithelium in the hopping mouse somehow compromises spermatogenic function, leading to less efficient sperm production, or whether a lower efficiency of spermatogenesis manifests itself in a more variable organisation of the seminiferous epithelium.

It is interesting to note that the hopping mouse and human, which both display a 'less organised' seminiferous epithelium, also have a relative testes mass that is below the regression line predicted by the allometric relationship between testes mass and body mass (Kenagy and Trombulak, 1986). Hence in these species, it might be that the apparently less organised seminiferous epithelium, at least in part, simply reflects the small relative testes mass. The total length of the seminiferous tubules is shorter in small testes due to fewer Sertoli cells (Bardin *et al.*, 1988) and presumably, individual cellular associations occupy proportionately shorter segments of the tubules than in large testes. If this is the case, then there is an increased likelihood of sampling areas of the tubules at the boundaries between cellular associations where cell types of adjacent associations may be intermixed. Hence an increased incidence of cellular associations of more variable composition and of tubular cross sections containing multiple cellular associations could be expected. However, in a third species, the olive baboon, *Papio anubis*, which also has an irregular organisation of the seminiferous epithelium, relative testes size was larger than that predicted by body weight (Harvey and Harcourt, 1984). Therefore, the occurrence of poorer organisation of the seminiferous epithelium is probably incidental to testes size and not a consequence of it.

There is evidence to suggest, however, that the observed differences in organisation of the seminiferous epithelium between the plains rat and hopping mouse reflect functional differences in the dynamics of spermatogenesis. Interspecific variations in the frequency of cellular associations and in the duration of the cycle of the seminiferous epithelium are apparent from the present study. In the hopping mouse, the estimated duration of the spermatogenic cycle is around three days longer than that in the plains rat (average duration 14.04 cf. 11.16 days respectively), indicating that it takes an extra 12 days to produce a spermatozoon from a spermatogonium in the former as compared with the latter species. Hence, apart from the Chinese hamster, *Cricetulus griseus* (Oud and de Rooij, 1977), the duration of spermatogenesis in the hopping mouse is longer than that recorded for any other rodent species (refer to Table 1.1, page 36, Chapter 1). Furthermore, interspecific variations in the estimated life spans of germ cell types also point to there being differences in spermatogenesis between the plains rat and hopping mouse.

A significant amount of intraspecific variation was observed in the frequency of particular cellular associations in both species (see Chapter 4). Hess *et al.* (1990) claim that a certain amount of variability in the frequency of particular cycle stages is to be expected because of the spatial organisation of cellular associations within the seminiferous epithelium. In the laboratory rat, it has been shown that the lengths of tubular segments containing a particular cycle stage vary widely within the spermatogenic wave, as do the length and number of waves within a tubule and the number of modulations within a wave (Perey *et*

al., 1961). Furthermore, all of these parameters differ between individuals, so it might be expected that even with extensive sampling of the testis, some of the differences mentioned could be translated into intraspecific variability in frequency of a cycle stage(s). How this relates to the situation in the hopping mouse, which does not have a clear wave of the seminiferous epithelium (Pollanen and Breed, 1991), remains to be determined.

A novel finding in this study was the occurrence of considerable variation in cycle length among individual hopping mice. It is claimed that cycle duration is constant among sexually competent individuals within a species (Oakberg, 1956b; Go *et al.*, 1971; Clermont, 1972), although variability has been observed during the establishment of spermatogenesis at puberty (Kluin *et al.*, 1982; Miething, 1998) and in response to environmental insult (Meistrich *et al.* 1975; Rosiepen, *et al.*, 1995). During puberty, variability in cycle duration between individuals is presumably linked to fluctuations in hormones and paracrine modulators, coupled with differences in the number and level of sensitivity of various receptors and enzymes, all of which result in localised retardation and/or acceleration of specific spermatogenic processes. In the hopping mouse, therefore, variation in cycle duration might also be associated with differences between individuals in their testicular environment and the degree of maturity and responsiveness of their testicular tissue, ie. the ability of the seminiferous epithelium and interstitial tissue to respond to the changing physiological environment, similar to the situation that occurs during puberty.

Alternatively, it could be argued that the seemingly greater variability in stage frequency and cycle duration in the Australian rodent species stems from the fact that the animals sampled are only a few generations removed from the wild and hence are more outbred. Therefore much greater genetic heterogeneity could be expected in these animals than among laboratory rats and laboratory mice or domesticated species. Thus, since there are species and strain differences in cycle length (refer to Table 1.1), one might expect genetic heterogeneity in cycle length in an outbred population of a particular species.

9.6 Efficiency of Sperm Production

While the absolute number of Sertoli cells and hence testis size largely determines the maximum achievable output of spermatozoa per individual, the efficiency of spermatogenesis has a large bearing on the actual numbers of spermatozoa produced. Several different measures of spermatogenic efficiency are routinely reported in the literature - daily sperm production per gram of testis (DSP/g testis) and germ:Sertoli cell ratios. The comparative efficiency of spermatogenesis between mammalian species, as

measured by DSP/g testis varies from an upper limit of 26.5×10^6 in the rabbit (Orgebin-Crist, 1968) to less than 6×10^6 in the human (Amann and Howards, 1980; Johnson *et al.*, 1980a, b; Johnson *et al.*, 1981). Values for other species are given in Table 6.3, Chapter 6. Thus, the testes of plains rats, with a mean DSP/g testis of 25.7×10^6 , are highly efficient in producing spermatozoa, whereas those of the hopping mouse (DSP/g testis 9.8×10^6) are less efficient than the testes of all other mammalian species so far studied, except for humans and possibly bulls and dogs (refer to Table 6.3).

As with DSP/g testis, there are large interspecific differences in the number of germ cells that a Sertoli cell is able to support throughout their development into spermatozoa. Again, humans are the least efficient species as determined by ratio of elongate spermatids to Sertoli cells (Russell and Peterson, 1984). Preliminary data on germ:Sertoli cell ratios in the two Australian species, as determined using the optical disector method (Wreford, 1995) indicate that each Sertoli cell in the hopping mouse is capable of supporting less than half the number of round and elongate spermatids of that of the plains rat (Peirce and Breed, 1998). The ratios of spermatogonia and spermatocytes to Sertoli cells are, however, more similar between the two species. These data must be viewed with caution, however, as only one plains rat and two hopping mice were sampled. Similarly, possible differences in the relative volumes of the various germ cell types between species and how they might influence the ability of Sertoli cells to support a particular number of germ cells were not investigated.

Unpublished qualitative observations of the incidence of degenerating germ cells in the epithelium of the plains rat and hopping mouse support the view that there is a greater rate of germ cell degeneration in the testes of the latter species, particularly of late stage primary spermatocytes and spermatids, which contributes to the lower ratios of the more developmentally mature germ cell types to Sertoli cells and hence low efficiency of spermatogenesis. The selective degeneration and removal from the seminiferous epithelium of germ cells with major chromosomal and/or morphological defects has been postulated as a means of preventing such cells from completing spermatogenesis (Roosen-Runge, 1973) and potentially passing on their defects to the next generation. In species with low spermatogenic efficiency such as the human and hopping mouse, however, selection against 'defective' spermatozoa appears to be lower, as evidenced by a relatively high percentage of spermatozoa that show morphological variability in the epididymides and ejaculate (Skakkebaek *et al.*, 1973; Johnson *et al.*, 1983; Breed and Sarafis, 1983; Suttle *et al.*, 1988). Why a greater proportion of spermatozoa show morphological variability in species with less efficient production is not known, but presumably it relates to the tubular environment to which germ cell populations are exposed during their development.

There is ample evidence in the literature to indicate that testosterone insufficiency may lead to increased germ cell degeneration and less efficient spermatogenesis (see review by Sharpe, 1994), although exactly how this is brought about has not been fully elucidated. It has been shown that not all germ cell types respond in the same manner to intratesticular androgens. For example, the pachytene primary spermatocytes of stages VII-VIII of the spermatogenic cycle in the laboratory rat are particularly sensitive to sub-optimal testosterone concentrations and are the first germ cells to degenerate following testosterone withdrawal (Sharpe *et al.*, 1988, 1992; Ghosh *et al.*, 1991; Kerr *et al.*, 1993). Although androgen receptors have been demonstrated within peritubular and Sertoli cells (Sar *et al.*, 1990, 1993), the consensus is that they are not present in germ cells (Grootegoed *et al.*, 1977; Frankel *et al.*, 1989). Hence, it has been suggested that the effects of testosterone on germ cells are likely to be mediated via other cell types, ie Sertoli cells, although androgen-receptor-independent mechanisms whereby testosterone acts directly on germ cells may also exist (Sharpe, 1994). Various studies have shown that qualitatively normal spermatogenesis can be maintained by sub-normal testosterone levels in a range of species, although spermatogenesis is less efficient, ie, fewer sperm are produced and increased germ cell degeneration occurs (Weinbauer and Nieschlag, 1993; Sharpe, 1994; Johnson, 1995). High levels of testosterone seem to be required to support optimal Sertoli cell function, which in turn allows the maximal number of germ cells to successfully complete spermatogenesis, whereas lower levels of testosterone may not enable Sertoli cells to support as many developing germ cells and hence a lower efficiency of sperm production results. A 'reinforcing effect' of a normal germ cell complement on Sertoli cell function, under optimal conditions of hormonal support has also been suggested, as have similar involvements for other regulatory hormones and peptide including FSH, except that they probably exert their influences at different stages of spermatogenesis (Sharpe, 1994). In the hopping mouse, which like the human appears to have a 'naturally' high level of germ cell degeneration in the cellular associations immediately prior to meiosis, there may be a lack of optimal hormonal support for Sertoli cells to maintain as large a complement of germ cells.

9.7 Sperm Transit and Storage

The morphological characteristics of the epididymis and vas deferens of the plains rat and hopping mouse and how they may relate to the extra-testicular maturation of spermatozoa and to the duration of transit and storage, have been discussed in some detail in Chapters 7 and 8 of this thesis. Several points, however, warrant further consideration.

9.7.1 Duration of Epididymal Transit

In most mammalian species for which data are available, spermatozoa take between two and five days to pass through the caput and corpus epididymides (see Table 8.5, page 170), which are those regions of the duct where sperm maturation is generally considered to occur. By contrast, transit through these regions of the hopping mouse epididymis takes less than one day! In Chapter 8 of this thesis it was suggested that the length of time spent by spermatozoa in the caput and corpus epididymides may reflect the minimum required exposure to the particular microenvironment that facilitates the maturational changes. This suggestion is based on regional differences in the relationships between luminal microenvironment, epididymal epithelium and sperm characteristics in various species.

Regional variations in the epididymal luminal microenvironment are well documented (Turner, 1991; Cooper, 1998) and the morphological and functional characteristics of the epididymal epithelium and its level of activity are major contributors in determining luminal fluid composition. For example, synthesis and secretion of proteins and glycoproteins by the epididymal epithelium vary spatially along the length of the duct (Olson and Hinton, 1985), hence the protein profile within the various regions of the duct differs (Turner *et al.*, 1979; Chaturapanich *et al.*, 1992; Cooper, 1998). Furthermore, the changing pattern of protein secretion correlates with changes to the surface proteins of spermatozoa during their transit (Dacheux *et al.*, 1998). Incorporation of radioactive tracers into proteins has shown that the bulk of secretory activity in the mammalian epididymis usually occurs in the regions adjoining the testis (Chaturapanich *et al.*, 1992, Jones and Clulow, 1994) and in several species approximately 80% of the total epididymal protein secretion is attributable to the epithelium of these regions (Syntin *et al.*, 1996). The cytological features of the epithelial cells in these regions are consistent with a high level of secretory and absorptive activity, in contrast to those of the lower regions of the duct and in particular the cauda epididymidis, which generally display fewer organelles (Robaire and Hermo, 1988).

In the hopping mouse, very little is known of the composition of the epididymal microenvironment and nothing of the level of maturation and fertilising capacity of spermatozoa recovered from different regions of the duct. However, this study has shown that the cytology of the epididymal epithelium differs regionally from that documented in other species including the plains rat (this study), laboratory rat and hamster (Glover and Nicander, 1971; Hamilton, 1975; Robaire and Hermo, 1988). Fewer differences in the distribution and abundance of particular organelles within the principal cells are observed between the middle and terminal segments of the hopping mouse epididymis (see Chapter 7) as compared with the corresponding segments of other species. In particular,

cytological features of principal cells consistent with secretion and absorption extend to the epithelium of the cauda epididymidis, which is generally regarded to be the site of sperm storage. This consistency in epithelial ultrastructure over a greater overall proportion of the duct may indicate that there is less regional specialisation of epididymal function, ie. epithelial regulation of the luminal microenvironment and hence its composition might be more similar between duct regions. Therefore, maturation of spermatozoa within the epididymis may be completed only following transit through at least the proximal part of the cauda epididymidis, which corresponds to a duration of transit of around 2-3 days. This falls within the time frame of minimum exposure to the microenvironment required for sperm maturation, as proposed for other mammalian species. Obviously, for the hopping mouse, more direct evidence is required to validate such a suggestion and could be provided by investigating the composition of the epididymal microenvironment of the various duct regions and the fertilising ability of spermatozoa housed within them.

Notwithstanding the possibility that spermatozoa are not fully mature until they have passed through a much greater proportion of the epididymis, an overall reduction in epididymal transit time in the hopping mouse sets it apart from other rodent species and suggests that the length of epididymal storage of spermatozoa is also short. This study found that spermatozoa take around 3 days to pass through the cauda epididymis, although if the above suggestion is valid, maturational changes may be still occurring during some of this time. By contrast, however, spermatozoa take longer to pass through the vas deferens (1.6 days cf 0.9 days in the plains rat) because, in some animals at least, it acts as an additional site of sperm storage. Nevertheless, the total time taken for spermatozoa to pass through the entire male duct system in the hopping mouse is less than that of epididymal transit in most other species (Table 8.5).

9.7.2 Sites and Conditions of Sperm Storage in the Hopping Mouse

In the hopping mouse, cauda epididymal sperm numbers are low, compared with other rodent species, even in sexually rested males, in which sperm reserves are at maximum levels. Likewise, storage capacity (> 5 day's DSP) is also low, despite allowances being made for the comparatively low rate of DSP. Furthermore, in animals with the highest overall sperm numbers, a significant proportion of these spermatozoa are located in the vas deferens, also suggesting that the caudal region may have reached its full storage capacity. Why sperm storage capacity should be low and the duration of storage (as mentioned in the previous section) short, remain to be determined, however, both of these features may be related to a reduced ability of the luminal environment to maintain spermatozoa in a viable condition for more than several days. The possibility that the epididymides of the hopping mouse are exposed to higher temperatures than those of the plains rat and other

rodents, and the resultant effects of such an exposure on transit time and sperm viability, were discussed in Chapter 8 of this thesis (pages 173-174).

Among rodents, the hopping mouse is somewhat unusual in that a considerable quantity of additional spermatozoa are present in the vasa deferentia as compared with the plains rat, laboratory rat and laboratory mouse. While a similar level of sperm storage to that seen in the hopping mouse occurs in the vasa deferentia of certain shrews, in the latter species the spermatozoa are located in a gland of the vas deferens (Bedford *et al.*, 1994) or a noticeable swelling or bulge of the duct (Bedford *et al.*, 1998). No visible expanded region of the vas deferens is present in the hopping mouse, but the overall diameter of the urethral segment of the duct is wider and the mucosa is thrown into numerous folds. The possible significance of this latter feature was discussed in Chapter 7. In terms of the ultrastructural characteristics of the epithelium, no conclusions can be drawn as to the similarity or otherwise of the storage environment in the urethral segment of the vas deferens as compared with that of the terminal segment of the epididymis. Although both of these regions had ultrastructural features in common, similar features were also observed in the epididymal segment of the vas deferens in which fewer spermatozoa are generally located.

9.8 Summary of Results and Conclusions

This study has investigated the dynamics of sperm production, transit and storage in the plains rat and hopping mouse and their relationships to the size and organisation of the testes and morphology of the epididymides and vasa deferentia. Of the two species, the hopping mouse, *Notomys alexis* is unique among mammals in that it has the smallest testes mass relative to body mass (0.15%) of any species so far recorded (Kenagy and Trombulak, 1986) and few spermatozoa within the epididymides. By comparison, the plains rat, *Pseudomys australis* has large testes relative to body mass and large epididymal sperm stores. Both of these species inhabit the arid zone of Central Australia and live in similar environments. From this study, it was found that the number of spermatozoa present within the epididymides and vasa deferentia of these species is dependent on a suite of structural and functional characteristics of the testes and epididymides, in addition to testis size *per se*. Furthermore, whereas the plains rat displays characteristics that are, in general, typical of those of common laboratory rodents, the hopping mouse shows a divergent set of characteristics that contribute to their low sperm counts. Therefore, in the hopping mouse, the low number of spermatozoa that are recoverable from the epididymides can be linked to:

1. the minute size of the testes. This small testis size, in turn, is related to the presence of fewer Sertoli cells within the seminiferous tubules as compared with the larger testes of plains rats (1.2×10^6 cf 30.5×10^6 Sertoli cells/testis respectively; Appendix 1).
2. a smaller proportion of the total testicular volume contributing to sperm production. Seminiferous tubules comprise only 85% of testicular volume in the hopping mouse, compared with 94% in the plains rat (Peirce and Breed, 1990).
3. a more variable composition of cellular associations within the testicular seminiferous epithelium that occupy smaller spatial regions of a tubule. Hence more than one cellular association is present in around 12% of tubular cross sections. Such an organisation of sperm-producing tissue perhaps reflects a more heterogeneous local environment within the seminiferous tubules and a looser control of spermatogenesis as compared with species such as the plains rat in which individual cellular associations are consistent in composition and occupy large segments of a tubule.
4. a longer cycle of the seminiferous epithelium. The average duration of the spermatogenic cycle in the hopping mouse is 14.04 days, compared with 11.16 days in the plains rat. Hence it is estimated that it takes an extra 12 days to produce a spermatozoon from a spermatogonium in the former as compared with the latter species.
5. a low efficiency of sperm production. The hopping mouse has an average DSP/g testis of 9.8×10^6 , a low capacity of individual Sertoli cells to support developing germ cells (Appendix 1) and a high incidence of cellular degeneration during spermatogenesis. By comparison the plains rat is highly efficient at producing spermatozoa. Average DSP/g testis is 25.7×10^6 and furthermore, comparisons of cell counts of the various germ cell types, corrected for differences in their life spans, suggest there is relatively little germ cell loss during spermatogenesis as compared with the situation in the hopping mouse.
6. a rapid transit of spermatozoa through the epididymis and vas deferens and a low capacity of the extra-testicular duct system for sperm storage. Transit of spermatozoa through those areas of the epididymis generally associated with post-testicular sperm maturation in other mammalian species takes less than one day in the hopping mouse and spermatozoa spend a total of between four and six days within the male tract in sexually rested males. Storage is characterised by a lack of density of spermatozoa in the terminal segment of the epididymides, although there is additional storage in the vasa deferentia, particularly in those individuals with relatively greater numbers of spermatozoa in their tracts. Total sperm reserves, however, represent only 2-4 day's production by the testes. By contrast, in the plains rat, greater than 80% of all spermatozoa are located within the terminal segment of the epididymis and sperm stores exceed 40 day's production by the testes.

A unique feature of sperm storage in the hopping mouse is its variable location. More than half of all spermatozoa have been recovered from the intermediate and urethral segments of the vasa deferentia in some individuals. This is somewhat surprising given the location of the vas deferens within the abdominal cavity and the presumably higher temperature to which it is subjected. The question of possible temperature effects on sperm viability has been raised, although the presence of mucosal folding of the urethral segment may be an adaptation of the vas deferens aimed at maximising the surface area and oxygen supply to spermatozoa located within it for extended periods of time. In addition, variability in the sites of sperm storage is accompanied by variability in the location of the testes and epididymides, which may also be subjected to more variable temperatures.

All of the data presented point to a lack of strong selection for maximising sperm production or storage in the hopping mouse. While it could be suggested that the small testes and low sperm numbers are indicative of a monogamous breeding system, or the absence of intermale sperm competition, the limited information available on breeding system (see section 9.4) appears to contradict this. Hence, although the evolutionary significance of the unique relationship between testes size and the low numbers of spermatozoa produced and stored in the hopping mouse is not fully understood, it demonstrates a high degree of plasticity of the male reproductive system. Clearly there is considerable divergence in this species from what is seen in a range of other mammalian species, including closely related rodents such as the plains rat.

9.9 Future Directions

The present study has only scratched the surface as to why there are such large differences between the plains rat and hopping mouse in the entire range of male reproductive parameters investigated including testis size, seminiferous epithelial organisation, morphology of the epididymides and vasa deferentia, durations of spermatogenesis and sperm transit, sites of sperm storage and numbers of spermatozoa produced and stored. One obvious area in which further investigations could be undertaken is that of determining the type of breeding system in these species and whether or not the female has any role in determining how or when mating occurs. A second area for further investigation relates to the variable position of the hopping mouse testes and epididymides, the effects of different temperatures on these organs and how they influence organ function and sperm numbers. Furthermore, the range of natural variation in the location of the testes and epididymides in the hopping mouse may make it a suitable model for determining the essential requirements of sperm production and storage that have led to the evolution of the scrotum.

Appendix 1 Quantification of Germ and Sertoli Cell Numbers

(As determined using the optical disector method - see Wreford, 1995)

1.1 Cell Number per Testis in the Plains Rat (Data from one animal only)

Absolute cell number per testis (weight 0.822 g)

	(x 10 ⁶)
Sertoli cells	30.5
Type A Spermatogonia	9.5
Type B spermatogonia	16.8
Primary spermatocytes	99.5
Secondary spermatocytes	4.9
Round spermatids	205.8
Elongate spermatids	235.6

Absolute cell number per gram testis

	(x 10 ⁶)
Sertoli cells	37.1
Type A Spermatogonia	11.5
Type B spermatogonia	20.4
Primary spermatocytes	121.0
Secondary spermatocytes	6.0
Round spermatids	250.4
Elongate spermatids	286.5

Ratio Germ:Sertoli cells

Type A Spermatogonia	0.31
Type B spermatogonia	0.55
Primary spermatocytes	3.26
Secondary spermatocytes	0.16
Round spermatids	6.75
Elongate spermatids	7.72

1.2 Cell Number per Testis in the Hopping Mouse (Data from two animals)

Absolute cell number per testis (weight 18-20 mg)

	(x 10 ⁶)
Sertoli cells	1.19
Type A Spermatogonia	0.12
Type B spermatogonia	0.41
Primary spermatocytes	1.54
Secondary spermatocytes	0.11
Round spermatids	2.78
Elongate spermatids	4.64

Absolute cell number per gram testis

	(x 10 ⁶)
Sertoli cells	55.0
Type A Spermatogonia	5.5
Type B spermatogonia	19.3
Primary spermatocytes	75.2
Secondary spermatocytes	5.6
Round spermatids	131.3
Elongate spermatids	208.8

Ratio Germ:Sertoli cells

Type A Spermatogonia	0.10
Type B spermatogonia	0.34
Primary spermatocytes	1.29
Secondary spermatocytes	0.09
Round spermatids	2.34
Elongate spermatids	3.90

References

- Abdou, MSS, Hassun, TM and El-Sawaf, SA** (1978) Testicular and epididymal sperm numbers and related parameters in the developing Awassi ram. Australian Journal of Biological Science **31**:257-266.
- Abe, K, Takano, H and Ito, T** (1983) Ultrastructure of the mouse epididymal duct with special reference to the regional differences of the principal cells. Archivum histologicum japonicum **46**:51-68.
- Abou-Haila, A and Fain-Maurel, MA** (1984) Regional differences of the proximal part of the mouse epididymis: morphological and histochemical characterisation. The Anatomical Record **209**:197-208.
- Acott, TS and Carr, DW** (1984) Inhibition of bovine spermatozoa by caudal fluid: II. Interaction of pH and a quiescence factor. Biology of Reproduction **30**:926-935.
- Adalami, HI and Hermo, L** (1996) Apical and narrow cells are distinct cell types differing in their structure, distribution and functions in the adult rat epididymis. Journal of Andrology **17**:208-222.
- Allanson, M** (1958) Growth and reproduction in the males of tow species of gerbil, *Tatera brantsii* (A Smith) and *Tatera afra* (Grey). Proceedings of the Zoological Society, London **130**:373-396.
- Allenby, G, Foster, PMD and Sharpe, RM** (1991) Evidence that secretion of immunoreactive inhibin by seminiferous tubules from the adult rat testis is regulated by specific germ cell types: Correlation between *in vivo* and *in vitro* studies. Endocrinology **128**:467-476.
- Almquist, JO and Amann, RP** (1961) Reproductive capacity of dairy bulls. II Gonadal and extra-gonadal sperm reserves as determined by direct counts and depletion trials; dimensions and weight of genitalia. Journal of Dairy Science **44**:1668-1678.
- Amann, RP** (1962) Reproductive capacity of dairy bulls. III. The effect of ejaculation frequency, unilateral vasectomy and age on spermatogenesis. The American Journal of Anatomy **110**:49-62.
- Amann, RP** (1970a) Sperm production rates. In The Testis. Vol. 1. AD Johnson, WR Gomes and NL van Demark Eds. Academic Press, New York. pp. 433-482.
- Amann, RP** (1970b) The male rabbit. IV. Quantitative testicular histology and comparisons between daily sperm production as determined histologically and daily sperm output. Fertility and Sterility **21**:662-672.
- Amann, RP** (1981) A critical review of methods for evaluation of spermatogenesis from seminal characteristics. Journal of Andrology **2**:37-58.

- Amann, RP and Almquist, JO** (1962) Reproductive capacity of dairy bulls. VIII. Direct and indirect measurement of testicular sperm production. Journal of Dairy Science **45**:774-781.
- Amann, RP and Howards, SS** (1980) Daily spermatozoal production and epididymal spermatozoal reserves of the human male. Journal of Urology **124**:211-215.
- Amann, RP and Lambiase, JT** (1969) The male rabbit. III. Determination of daily sperm production by means of testicular homogenates. Journal of Animal Science **28**:369-374.
- Amann, RP, Hammerstedt, RH and Veeramachaneni, DNR** (1993) The epididymis and sperm maturation: a perspective. Reproduction, Fertility and Development **5**:361-381.
- Amann, RP, Hay, SR and Hammerstedt, RH** (1982) Yield, characteristics, motility and cAMP content of sperm isolated from seven regions of the ram epididymis. Biology of Reproduction **27**:723-733.
- Amann, RP, Johnson, L, Thompson, DL and Pickett, BW** (1976) Daily spermatozoal production, epididymal spermatozoal reserves and transit time of spermatozoa through the epididymis of the rhesus monkey. Biology of Reproduction **15**:586-592.
- Amann, RP, Kavanaugh, JF, Griel, LC and Volgmayr, JK** (1974) Sperm production of Holstein bulls determined from testicular spermatid reserves, after cannulation of rete testis or vas deferens, and by daily ejaculation. Journal of Dairy Science **57**:93-99.
- Amann, RP, Koefoed-Johnson, HH and Levi, H** (1965) Excretion pattern of labelled spermatozoa and the timing of spermatozoa formation and epididymal transit in rabbits injected with thymidine-3H. Journal of Reproduction and Fertility **10**:169-183.
- Amelar, RD and Hotchkiss, RS** (1965) The split ejaculate: its use in the management of male infertility. Fertility and Sterility **16**:46-60.
- Antar, M** (1971) Duration of the cycle of the seminiferous epithelium and of spermatogenesis in the monkey (*Macaca speciosa*). The Anatomical Record **169**:268-269. (Abstract)
- Arambepola, NK, Bunick, D and Cooke, PS** (1998) Thyroid hormone effects on androgen receptor messenger RNA expression in rat Sertoli and peritubular cells. Journal of Endocrinology **156**:43-50.
- Arslan, M, Weinbauer, GF, Schlatt, S, Shahab, M and Nieschlag, E** (1993) FSH and testosterone, alone or in combination, initiate testicular growth and increase the number of spermatogonia and Sertoli cells in a juvenile non-human primate (*Macaca mulatta*). Journal of Endocrinology **136**:235-243.
- Asdell, SA** (1964) Patterns of Mammalian Reproduction. 2nd Ed. Cornell University Press, New York.
- Aumuller, G** (1979) Prostate Gland and Seminal Vesicles. Springer-Verlag, Berlin.

- Bardin, CW, Cheng, CY, Musto, NA and Gunsalus, GL** (1994) The Sertoli cell. In The Physiology of Reproduction 2nd Ed. Vol. 1. E Knobil and J Neill Eds. Raven Press, New York. pp. 1291-1333.
- Barr, AB** (1973) Timing of spermatogenesis in four non-human primate species. Fertility and Sterility **24**:381-389.
- Barr, AB, Moore, DJ and Paulsen, CA** (1971) Germinal cell loss during human spermatogenesis. Journal of Reproduction and Fertility **25**:75-80.
- Barratt, CLR** (1995) Spermatogenesis. In Cambridge Reviews in Human Reproduction. Gametes. The Spermatozoon. JG Grudzinskas and JL Yovich Eds. Cambridge University Press, Cambridge. pp. 250-267.
- Bartlett, JMS, Kerr, JB and Sharpe, RM** (1986) The effect of selective destruction and regeneration of rat Leydig cells on the intratesticular distribution of testosterone and morphology of the seminiferous epithelium. Journal of Andrology **7**:240-253.
- Bartlett, JMS, Kerr, JB and Sharpe, RM** (1988) The selective removal of pachytene spermatocytes using methoxy-acetic acid as an approach to the study in vivo of paracrine interactions in the testis. Journal of Andrology **9**:31-40.
- Bartlett, JMS, Weinbauer, GF and Nieschlag, E** (1989) Differential effects of FSH and testosterone on the maintenance of spermatogenesis in the adult hypophysectomised rat. Journal of Endocrinology **121**:49-58.
- Bascom, KF and Osterud, HL** (1925) Quantitative studies of the testicle. II. Pattern and total tubule length in the testis of certain common mammals. The Anatomical Record **31**:159-169.
- Baverstock, PR** (1984) Australia's living rodents: a restrained explosion. In Vertebrate Zoogeography and Evolution in Australasia. M Archer and G Clayton Eds. Hesperian Press, Carlisle, WA. pp. 913-920.
- Baverstock, PR, Watts, CHS, Adams, M and Cole SR** (1981) Genetical relationships among Australian rodents (Muridae). Australian Journal of Zoology **29**:289-303.
- Baverstock, PR, Watts, CHS, Gelder, M and Jahnke, A** (1983) G banding homologies of some Australian rodents. Genetica **60**:105-117.
- Beaumont, HM and Mandl, AM** (1963) A quantitative study of primordial germ cells in the male rat. Journal of Embryology and Experimental Morphology **11**:715-740.
- Becker, O** (1856) Über Flimmerepithelium im Nebenhoden des Menschen. Wiener medizinische Wochenschrift **6**:184.
- Becker, O** (1857) Über Flimmerepithelium und Flimmerbewegung im Geschlechtsapparat der Säugethiere und das Menschen. Molschotts Untersuchungen Naturg Menschen Thiere **2**:71-99.
- Bedford, JM** (1966) Development of the fertilizing ability of spermatozoa in the epididymis of the rabbit. Journal of Experimental Zoology **163**:319-330.

- Bedford, JM** (1967) Effect of duct ligation on the fertilizing ability of spermatozoa in the epididymis of the rabbit. Journal of Experimental Zoology **166**:271-282.
- Bedford, JM** (1975) Maturation, transport and fate of spermatozoa in the epididymis. In Handbook of Physiology, Vol. V. Endocrinology. Section 7, Male Reproductive System. D W Hamilton and R O Greep Eds. American Physiological Society, Washington, D.C. pp. 307-317.
- Bedford, JM** (1977) Evolution of the scrotum: The epididymis as the prime mover? In Reproduction and Evolution. JH Calaby and CH Tyndale-Biscoe Eds. Australian Academy of Sciences, Canberra. pp. 171-182.
- Bedford, JM** (1978a) Anatomical evidence for the epididymis as the prime mover in the evolution of the scrotum. The American Journal of Anatomy **152**:483-508.
- Bedford, JM** (1978b) Influence of abdominal temperature on epididymal function in the rat and rabbit. The American Journal of Anatomy **152**:509-522.
- Bedford, JM** (1979) Evolution of the sperm maturation and sperm storage functions of the epididymis. In The Spermatozoon. DW Fawcett and JM Bedford Eds. Urban and Schwarzenberg, Baltimore. pp. 7-21.
- Bedford, JM** (1991a) Effects of elevated temperature on the epididymis and testis: experimental studies. In Temperature and Environmental Effects on the Testis. AW Zorzniotti Ed. Plenum Press, New York. pp. 19-32.
- Bedford, JM** (1991b) The coevolution of mammalian gametes. In A Comparative Overview of Mammalian Fertilization. BS Dunbar and MG O'Rand Eds. Plenum Press, New York. pp 3-35.
- Bedford, JM** (1994) The state and status of the human epididymis. Human Reproduction Update **9**:2187-2199.
- Bedford, JM** (1996) What marsupial gametes disclose about gamete function in eutherian mammals. Reproduction, Fertility and Development **8**:569-580.
- Bedford, JM and Calvin, HI** (1974) The occurrence and possible functional significance of -SS- crosslinks in sperm heads, with particular reference to eutherian mammals. Journal of Experimental Zoology **188**:137-155.
- Bedford, JM and Hoskins, DD** (1990) The mammalian spermatozoon: Morphology, biochemistry and physiology. In Marshall's Physiology of Reproduction, 4th Ed. Vol. 2. GE Lamming Ed. Churchill Livingstone, London. pp. 379-568.
- Bedford, JM and Nicander, L** (1971) Ultrastructural changes in the acrosome and sperm membranes during maturation of spermatozoa in the testis and epididymis of the rabbit and monkey. Journal of Anatomy **108**:527-543.
- Bedford, JM and Yanagimachi, R** (1991) Epididymal storage at abdominal temperature reduces the time required for capacitation of hamster spermatozoa. Journal of Reproduction and Fertility **91**:403-410.

- Bedford, JM, Bernard, RTF and Baxter, RM** (1998) The 'hybrid' character of the gametes and reproductive tracts of the African shrew, *Myosorex varius*, supports its classification in the Crocidosoricinae. Journal of Reproduction and Fertility **112**:165-172.
- Bedford, JM, Cooper, GW, Phillips, DM, and Dryden, GL** (1994) Distinctive features of the gametes and reproductive tracts of the Asian musk shrew, *Suncus murinus*. Biology of Reproduction **50**:820-834.
- Bedford, JM, Mori, T and Oda, S** (1997) Ovulation induction and gamete transport in the female tract of the musk shrew, *Suncus murinus*. Journal of Reproduction and Fertility **110**:115-125.
- Bedford, JM, Rodger, JC and Breed, WG** (1984) Why so many mammalian spermatozoa - a clue from marsupials? Proceedings of the Royal Society of London, Series B **221**:221-233.
- Bellvé, AR and Zheng, W** (1989) Growth factors as autocrine and paracrine modulators of male gonadal functions. Journal of Reproduction and Fertility **85**:771-793.
- Benda, C** (1887) Untersuchungen über den Bau des funktionierenden Samenkanälchens einiger Säugethiere und Folgerungen für die Spermatogenese dieser Wirbelthierklasse. Archiv für Mikroskopische Anatomie und Entwicklungsmech **30**:49-110.
- Benoit, MM** (1926) Recherches anatomiques, cytologiques et histophysiologiques sur les voies excrétoires du testicule chez les mammifères. Contribution à l'étude de quelques problèmes de cytologie générale relatifs à la cellule glandulaire. Archives D'anatomie, D'histologie et D'embryologie (Strasbourg) **5**:173-412.
- Benson, GS** (1994) Male sexual function: erection, emission and ejaculation. In Physiology of Reproduction 2nd Ed. E Knobil and JD Neill Eds. Raven Press, New York. pp. 1489-1506.
- Berg, KA, Clausen, OPF and Huitfeldt, HS** (1990) The spermatogenic cycle in the blue fox (*Alopex lagopus*): relative frequency and absolute duration of the different stages. International Journal of Andrology **13**:315-326.
- Bergmann, M and Dierichs, R** (1983) Postnatal formation of the blood-testis barrier in the rat with special reference to the initiation of meiosis. Anatomy and Embryology **168**:269-275.
- Bern, HA** (1949) The distribution of alkaline phosphatase in the genital tract of male mammals. The Anatomical Record **104**:361-377.
- Berndtson, WE** (1977) Methods for quantifying mammalian spermatogenesis. A review. Journal of Animal Science **44**:818-833.
- Berndtson, WE and Desjardins, C** (1974) The cycle of the seminiferous epithelium and spermatogenesis in the bovine testis. The American Journal of Anatomy **140**:167-180.

- Berndtson, WE and Thompson, TL** (1990) Changing relationships between testis size, Sertoli cell number and spermatogenesis in Sprague-Dawley rats. Journal of Andrology **11**:429-435.
- Berndtson, WE, Igboeli, G and Parker, WG** (1987a) The numbers of Sertoli cells in mature Holstein bulls and their relationship to quantitative aspects of spermatogenesis. Biology of Reproduction **37**:60-67.
- Berndtson, WE, Igboeli, G and Pickett, BW** (1987b) Relationship of absolute numbers of Sertoli cells to testicular size and spermatogenesis in young beef bulls. Journal of Animal Science **64**:241-246.
- Berta, P, Hawkins, JR, Sinclair, AH, Taylor, A, Griffiths, BL, Goodfellow, PN and Fellous, M** (1990) Genetic evidence equating SRY and the testis-determining factor. Nature **348**:448-450.
- Bilaspuri, GS and Kaur, R** (1994) Spermatogenic cells and stages of the seminiferous epithelial cycle in the Indian gerbil field rat, *Tatera indica*. Reproduction, Fertility and Development **6**:699-704.
- Billig, H, Furuta, I, Rivier, C, Tapanainen, J, Parvinen, M and Hseuh, JW** (1995) Apoptosis in testis germ cells: developmental changes in gonadotropin dependence and localization to selective tubule stages. Endocrinology **136**:5-12.
- Blanchard, TL and Johnson, L** (1997a) Determination of daily sperm production in stallion testes by enumeration of germ cells in homogenates. Theriogenology **47**:655-664.
- Blanchard, TL and Johnson, L** (1997b) Increased germ cell degeneration and reduced germ cell:Sertoli cell ratio in stallions with low sperm production. Theriogenology **47**:665-677.
- Blanco-Rodriguez, J** (1998) A matter of death and life: the significance of germ cell death during spermatogenesis. International Journal of Andrology **21**:236-248
- Blanco-Rodriguez, J and Martinez-Garcia, C** (1996a) Spontaneous germ cell death in the testis of the adult rat takes the form of apoptosis: re-evaluation of cell types that exhibit the ability to die during spermatogenesis. Cell Proliferation **29**:13-31.
- Blanco-Rodriguez, J and Martinez-Garcia, C** (1996b) Induction of apoptotic cell death in the seminiferous tubule of the adult rat testis: assessment of the germ cell types that exhibit the ability to enter after hormone treatment. International Journal of Andrology **19**:237-247.
- Blanco-Rodriguez, J and Martinez-Garcia, C** (1997a) Mild hypothermia induces apoptosis in rat testis at specific stages of the seminiferous epithelium. Journal of Andrology **18**:535-539.
- Blanco-Rodriguez, J and Martinez-Garcia, C** (1997b) Apoptosis pattern elicited by oestradiol treatment of the seminiferous epithelium of the adult rat. Journal of Reproduction and Fertility **110**:61-70.

- Blandau, RJ** (1945) On the factors involved in sperm transport through the cervix uteri of the albino rat. The American Journal of Anatomy **77**:253-272.
- Boitani, C, Stefanini, M, Fragale, A and Morena, AR** (1995) Activin stimulates Sertoli cell proliferation in a defined period of rat testis development. Endocrinology **136**:5438-5444.
- Bradtke, V** (1990) The functional morphology of the excurrent duct of the Australian hopping mouse, *Notomys alexis*. Honours Thesis, Department of Anatomy and Histology, University of Adelaide. Adelaide, SA.
- Brambell, FWR** (1935) Reproduction in the common shrew (*Sorex araneus* Linnaeus) 1. The oestrus cycle of the female. Philosophical transactions of the Royal Society of London, Series B **225**:2-49.
- Braun, RE, Behringer, RR, Peschon, JJ, Brinster, RL and Palmiter, RD** (1989) Genetically haploid spermatids are phenotypically diploid. Nature **337**:373-376.
- Breed, WG** (1980) Further observations on spermatozoal morphology and male reproductive tract anatomy of *Pseudomys* and *Notomys* species (Mammalia: Rodentia). Transactions of the Royal Society of South Australia **104**:51-55.
- Breed, WG** (1981a) Unusual anatomy of the male reproductive tract in *Notomys alexis* (Muridae). Journal of Mammalogy **62**:373-375.
- Breed, WG** (1981b) Histology of accessory sex organs and extragonadal sperm reserves in the male hopping mouse, *Notomys alexis*. Archives of Andrology **7**:357-360.
- Breed, WG** (1982a) Morphological variation in the testes and accessory sex organs of Australian rodents in the genera *Pseudomys* and *Notomys*. Journal of Reproduction and Fertility **66**:607-613.
- Breed, WG** (1982b) Control of mammalian and avian reproduction in the Australian arid zone, with special reference to rodents. In Evolution of the Flora and Fauna of Arid Australia. WR Barker and PJM Greenslade Eds. Peacock Publications, Adelaide. pp. 185-190.
- Breed, WG** (1983a) Variation in sperm morphology in the Australian rodent genus, *Pseudomys* (Muridae). Cell and Tissue Research **229**:611-625.
- Breed, WG** (1983b) Sexual dimorphism in the Australian hopping mouse, *Notomys alexis*. Journal of Mammalogy **64**:536-539.
- Breed, WG** (1984) Sperm head structure in the Hydromyinae (Rodentia: Muridae): a further evolutionary development in the subacrosomal space in mammals. Gamete Research **10**:31-44.
- Breed, WG** (1985a) Variation in testis morphology in the Australian rodent genera *Pseudomys* and *Notomys*. In Current Trends in Comparative Endocrinology. B Lofts and WN Holmes Eds. Hong Kong University Press, Hong Kong. pp. 285-287.

- Breed, WG** (1985b) Morphological variation in the female reproductive tract of Australian rodents in the genera *Pseudomys* and *Notomys*. Journal of Reproduction and Fertility **73**:379-384.
- Breed, WG** (1986) Comparative morphology and evolution of the male reproductive tract in the Australian hydromyine rodents (Muridae). Journal of Zoology, London **209**:607-629.
- Breed, WG** (1989) Comparative studies on the reproductive biology of three species of laboratory bred Australian conilurine rodents (Muridae: Hydromyinae). Journal of Zoology, London **217**:683-699.
- Breed, WG** (1990a) Comparative studies on the timing of reproduction and foetal number in six species of Australian conilurine rodents (Muridae: Hydromyinae). Journal of Zoology, London **221**:1-10.
- Breed, WG** (1990b) Copulatory behaviour and coagulum formation in the female reproductive tract of the Australian hopping mouse, *Notomys alexis*. Journal of Reproduction and Fertility **88**:17-24.
- Breed, WG** (1992) Reproduction of the spinifex hopping mouse (*Notomys alexis*) in the natural environment. Australian Journal of Zoology **40**:57-71.
- Breed, WG** (1997) Interspecific variation of testis size and epididymal sperm numbers in Australasian rodents with special reference to the genus *Notomys*. Australian Journal of Zoology **45**:651-669.
- Breed, WG and Adams, M** (1992) Breeding systems of spinifex hopping mice (*Notomys alexis*) and plains rats (*Pseudomys australis*): a test for multiple paternity within the laboratory. Australian Journal of Zoology **40**:13-20.
- Breed, WG and Sarafis, V** (1979) On the phylogenetic significance of spermatozoal morphology and male reproductive tract anatomy in Australian rodents. Transactions of the Royal Society of South Australia **103**:127-135.
- Breed, WG and Sarafis, V** (1983) Variation in sperm head morphology in the Australian rodent, *Notomys alexis*. Australian Journal of Zoology **31**:313-316.
- Breed, WG and Washington, JM** (1991) Mating behaviour and insemination in the hopping mouse, *Notomys alexis*. Journal of Reproduction and Fertility **93**:187-194.
- Breed, WG, Cox, GA, Leigh, CL and Hawkins, P** (1988) Sperm head structure of a murid rodent from South Africa: the red veld rat *Aethomys chrysophilus*. Gamete Research **19**:191-202.
- Breed, WG, Peirce, EJ, Washington, JM and Adams, M** (1991) Testis size, sperm numbers, and breeding system in the conilurine rodents, *Pseudomys australis* and *Notomys alexis*. In Comparative Spermatology 20 Years After. B Baccetti Ed. Serono Symposia Publications Raven Press, New York. Vol. 75. pp. 941-944.

- Brinkworth, MH, Weinbauer, GF, Schlatt, S and Nieschlag, E** (1995) Identification of male germ cells undergoing apoptosis in adult rats. Journal of Reproduction and Fertility **105**:25-33.
- Brooks, DE** (1981) Secretions of proteins and glycoproteins by the rat epididymis: Regional differences, androgen-dependence, and effects of protease inhibitors, procaine, and tunicamycin. Biology of Reproduction **25**:1099-1117.
- Brooks, DE** (1990) Biochemistry of the male accessory glands. In Marshall's Physiology of Reproduction, 4th Ed. Vol. 2, Reproduction in the Male. GE Lamming Ed. Churchill Livingstone, Edinburgh. pp. 569-690.
- Brooks, DE and Tiver, K** (1983) Localization of epididymal secretory proteins on rat spermatozoa. Journal of Reproduction and Fertility **69**:651-657.
- Brooks, DE and Tiver, K** (1984) Analysis of surface proteins of rat spermatozoa during epididymal transit and identification of antigens common to spermatozoa, rete testis fluid and cauda epididymal plasma. Journal of Reproduction and Fertility **71**:249-257.
- Brooks, DE, Gaughwin, M and Mann, T** (1978) Structural and biochemical characteristics of the male accessory organs of reproduction in the hairy-nosed wombat (*Lasiorhinus latifrons*). Proceedings of the Royal Society London Series B **201**:191-207.
- Brown, CR, von Glos, KI and Jones, R** (1983) Changes in plasma membrane glycoproteins of rat spermatozoa during maturation in the epididymis. Journal of Cell Biology **96**:256-264.
- Brown, D and Montesano, R** (1981) Membrane specialization in the rat epididymis. II. The clear cell. The Anatomical Record **201**:477-483.
- Brown, JC and Williams, JD** (1972) A histochemical study of the preputial glands of male laboratory rat and mouse. Acta Anatomica **81**:270-285.
- Brown, HH** (1885) On spermatogenesis in the rat. Quarterly Journal of Microscopic Science **25**:343-370.
- Bugge, HP and Plöen, L** (1986) Changes in the volume of Sertoli cells during the cycle of the seminiferous epithelium in the rat. Journal of Reproduction and Fertility **76**:39-42.
- Bunick, D, Kirby, J, Hess, RA and Cooke, PS** (1994) Developmental expression of testis messenger ribonucleic acids in the rat following propylthiouracil-induced neonatal hypothyroidism. Biology of Reproduction **51**:706-713.
- Bustos-Obregon, E** (1976a) Ultrastructure and function of the lamina propria of human seminiferous tubules. Zeitschrift für Zellforschung und mikroskopische Anatomie **141**:413-425.
- Bustos-Obregon, E** (1976b) Ultrastructure and function of the lamina propria of mammalian seminiferous tubules. Andrologia **8**:179-185.

- Byers, S, Pelletier, R-M and Suáñez-Quian, C** (1993) Sertoli cell junctions and the seminiferous epithelium barrier. In The Sertoli Cell. LD Russell and MD Griswold Eds. Cache River Press, Clearwater. pp. 431-446.
- Byskov, AG** (1978) Regulation of initiation of meiosis in fetal gonads. International Journal of Andrology Supplement 2:29-38.
- Byskov, AG** (1979) Regulation of meiosis in mammals. Annales de Biologie animale, Biochimie et Biophysique 19:1251-1261.
- Byskov, AG** (1982) Primordial germ cells and regulation of meiosis. In Reproduction in Mammals 1. Germ Cells and Fertilization. CR Austin and RV Short Eds. Cambridge University Press, Cambridge. pp. 1-16.
- Calvin, HI and Bedford, JM** (1971) Formation of disulphide bonds in the nucleus and accessory structures of mammalian spermatozoa during epididymal maturation. Journal of Reproduction and Fertility Supplement 13:65-75.
- Cameron, DF, Muffly, KE and Nazian, SJ** (1993) Reduced testosterone during puberty results in a mid-spermiogenic lesion. Proceedings of the Society of Experimental Biology and Medicine 202:457-464.
- Cardoso, FM and Godinho, HP** (1983) Cycle of the seminiferous epithelium and its duration in the zebu, *Bos indicus*. Animal Reproduction Science 5:231-245.
- Carleton, MD and Musser, GG** (1984) Muroid rodents. In Orders and Families of Recent Mammals of the World. S Anderson and JK Jones Jr. Eds. Wiley and Sons, New York. pp. 289-379.
- Carrick, FN and Hughes, RL** (1978) Reproduction in male monotremes. Australian Zoologist 20:211-231.
- Cavicchia, JC and Dym, M** (1978) Ultrastructural characteristics of monkey spermatogonia and preleptotene spermatocytes. Biology of Reproduction 18:219-228.
- Chapin, RE, Dutton, SL, Ross, MD, Sumrell, BM and Lamb, JC** (1984) The effects of ethylene glycol monomethyl ether on testicular histology in F344 rats. Journal of Andrology 5:369-380.
- Chaturapanich, G, Jones, RC and Clulow, J** (1992) Protein synthesis and secretion by the epididymis of the tammar wallaby, *Macropus eugenii* (Marsupialia). Reproduction Fertility and Development 4:533-545.
- Chemes, HE, Dym, M, Fawcett, DW, Javadpour, NJ and Sherins, RJ** (1977) Pathophysiological observations of Sertoli cells in patients with germinal aplasia or severe germ cell depletion. Ultrastructural findings and hormone levels. Biology of Reproduction 17:108-123.
- Chemes, HE, Dym, M and Raj, HGM** (1979) The role gonadotropins and testosterone on initiation of spermatogenesis in the immature rat. Biology of Reproduction 21:241-249.

- Chevalier, M** (1978) Sertoli cell ultrastructure. I. A comparative study in immature, pubescent, adult and cryptorchid pigs. Annales de Biologie animale, Biochimie et Biophysique **18**:1279-1292.
- Chiquoine, AD** (1954) The identification, origin and migration of the primordial germ cells in the mouse embryo. The Anatomical Record **118**:135-146.
- Chowdhury, AK and Marshall, G** (1980) Irregular pattern of spermatogenesis in the baboon (*Papio anubis*) and its possible mechanism. In Testicular Development, Structure and Function. A Steinberger, E Steinberger Eds. Raven Press, New York. pp. 129-137.
- Chowdhury, AK and Steinberger, E** (1964) A quantitative study of the effect of heat on germinal epithelium of rat testes. The American Journal of Anatomy **115**:509-524.
- Chowdhury, AK and Steinberger, E** (1976) A study of germ cell morphology and duration of spermatogenic cycle in the baboon, *Papio anubis*. The Anatomical Record **185**:155-170.
- Christensen, AK** (1975) Leydig cells. Handbook of Physiology, Vol. V. Endocrinology. Section 7, Male Reproductive System. DW Hamilton and RO Greep Eds. American Physiological Society, Washington, DC. pp. 57-94.
- Christensen, AK and Gillim, SW** (1972) The correlation of fine structure and function in steroid-secreting cells, with emphasis on those of the gonads. In The Gonads. WW McKerns Ed. Appleton-Century-Crofts, New York. pp 415-488.
- Christl, HW** (1990) The lamina propria of vertebrate seminiferous tubules: a comparative light and electron microscopic investigation. Andrologia **22**:85-94.
- Chubb, C** (1992) Genes regulating testis size. Biology of Reproduction **47**:29-36.
- Clark, AW** (1967) Some aspects of spermiogenesis in a lizard. The American Journal of Anatomy **121**:369-400.
- Clark, JM and Eddy, EM** (1975) Fine structural observations on the origin and associations of primordial germ cells of the mouse. Developmental Biology **47**:136-155.
- Clark, RV** (1976) Three-dimensional organisation of testicular interstitial tissue and lymphatic space in the rat. The Anatomical Record **184**:203-226.
- Clermont, Y** (1954) Cycle de l'épithélium seminal et mode de renouvellement des spermatogonies chez le hamster. Review of Canadian Biology **13**:208-245.
- Clermont, Y** (1958) Contractile elements in the limiting membrane of the seminiferous tubules of the rat. Experimental Cell Research **15**:438-440.
- Clermont, Y** (1960) Cycle of the seminiferous epithelium of the guinea pig. A method for identification of the stages. Fertility and Sterility **11**:563-573.
- Clermont, Y** (1962) Quantitative analysis of spermatogenesis of the rat: a revised model for the renewal of spermatogonia. The American Journal of Anatomy **111**:111-129.

- Clermont, Y** (1963) The cycle of the seminiferous epithelium in man. The American Journal of Anatomy **112**:35-51.
- Clermont, Y** (1969) Two classes of spermatogonial stem cells in the monkey (*Cercopithecus aethiops*). The American Journal of Anatomy **126**:57-72.
- Clermont, Y** (1972) Kinetics of spermatogenesis in mammals: Seminiferous epithelial cycle and spermatogonial renewal. Physiological Reviews **52**:198-236.
- Clermont, Y and Antar, M** (1973) Duration of the cycle of the seminiferous epithelium and the spermatogonial renewal in the monkey, *Macaca arctoides*. The American Journal of Anatomy **136**:153-166.
- Clermont, Y and Bustos-Obregon, E** (1968) Re-examination of spermatogonial renewal in the rat by means of seminiferous tubules mounted 'in toto'. The American Journal of Anatomy **122**:237-248.
- Clermont, Y and Harvey, SC** (1965) Duration of the cycle of the seminiferous epithelium of normal, hypophysectomized and hypophysectomized-hormone treated albino rats. Endocrinology **76**:80-89.
- Clermont, Y and Hermo, L** (1975) Spermatogonial stem cells in the rat. The American Journal of Anatomy **142**:159-176.
- Clermont, Y and Huckins, C** (1961) Microscopic anatomy of the sex cords and seminiferous tubules in growing and adult male albino rats. The American Journal of Anatomy **108**:79-97.
- Clermont, Y and Leblond, CP** (1953) Renewal of spermatogonia in the rat. The American Journal of Anatomy **93**:475-501.
- Clermont, Y and Leblond, CP** (1955) Spermiogenesis of man, monkey, ram and other mammals as shown by the 'periodic acid-Schiff' technique. The American Journal of Anatomy **96**:229-253.
- Clermont, Y and Leblond, CP** (1959) Differentiation and renewal of spermatogonia in the monkey, *Macacus rhesus*. The American Journal of Anatomy **104**:237-273.
- Clermont, Y and Perey B** (1957) Quantitative study of the cell population of the seminiferous tubules in the immature rat. The American Journal of Anatomy **100**:241-267.
- Clermont, Y and Trott, M** (1969) Duration of the cycle of the seminiferous epithelium in the mouse and hamster determined by means of 3H-thymidine and radioautography. Fertility and Sterility **20**:805-817.
- Clermont, Y, Leblond, CP and Messier, B** (1959) Durée du cycle de l'Épithelium séminal du rat. Archives D'Anatomie Microscopique et de Morphologie Experimentale **48**:37-56.
- Clermont, Y, McCoshen, J and Hermo, L** (1980) Evolution of the endoplasmic reticulum in the Sertoli cell cytoplasm encapsulating the heads of late spermatids in the rat. The Anatomical Record **196**:83-99.

- Cooke, PS** (1991) Thyroid hormones and testis development: A model system for increasing testis growth and sperm production. Annals of the New York Academy of Sciences **637**:122-132.
- Cooke, PS and Meisami, E** (1991) Early hypothyroidism in rats causes increased adult testis and reproductive organ size but does not change testosterone levels. Endocrinology **129**:237-243.
- Cooke, PS, Hess, RA, Porcelli, J and Meisami, E** (1991) Increased sperm production in adult rats after transient neonatal hypothyroidism. Endocrinology **129**:244-248.
- Cooke, PS, Porcelli, J and Hess, RA** (1992) Induction of increased testis growth and sperm production in adult rats by neonatal administration of the goitrogen propylthiouracil (PTU): The critical period. Biology of Reproduction **46**:146-154.
- Cooke, PS, Zhao, Y-D and Bunick, D** (1994) Triiodothyronine inhibits proliferation and stimulates differentiation of cultured neonatal Sertoli cells: Possible mechanism for increased adult testis weight and sperm production induced by neonatal goitrogen treatment. Biology of Reproduction **51**:1000-1005.
- Cooper, ERA and Jackson, H** (1972) The vasa efferentia in the rat and mouse. Journal of Reproduction and Fertility **28**:317-319.
- Cooper, TG** (1986) The Epididymis, Sperm Maturation and Fertilization. Springer Verlag, Berlin.
- Cooper, TG** (1990) In defense of the human epididymis. Fertility and Sterility **54**:965-975.
- Cooper, TG** (1992) Epididymal proteins and sperm maturation. In Spermatogenesis: Fertilization-Contraception. E Nieschlag and UF Habenicht Eds. Springer Verlag, New York. pp. 285-318.
- Cooper, TG** (1998) Interactions between epididymal secretions and spermatozoa. Journal of Reproduction and Fertility Supplement **53**:119-136.
- Cooper, TG and Hamilton, DW** (1977) Phagocytosis of spermatozoa in the terminal region and gland of the vas deferens of the rat. The American Journal of Anatomy **150**:247-268.
- Cortes, D, Müller, J and Skakkebaek, NE** (1987) Proliferation of Sertoli cells during development of the human testis assessed by stereological methods. International Journal of Andrology **10**:598-596.
- Courot, M** (1981) Transport and maturation of spermatozoa in the epididymis of mammals. In Progress in Reproductive Biology. Vol. 8. Karger, Basel pp. 67-79.
- Courot, M, Hochereau-de Reviere, M-T and Ortavant, R** (1970) Spermatogenesis. In The Testis. Vol. 1. AD Johnson, WR Gomes and NL Vandemark Eds. Academic Press, New York. pp. 339-432.
- Crabo, BG** (1965) Studies on the composition of epididymal content in bulls and boars. Acta veterinaria Scandanavica Supplement **5**:1-94.

- Crabo, BG and Hunter, AG** (1975) Sperm maturation and epididymal function. In Control of Male Fertility. JJ Sciarra, C Markland and JJ Speidel Eds. Harper and Row, Haggerstown. pp. 2-23.
- Creasy, DM, Flynn, JC, Gray, TJB and Butler, WH** (1985) A quantitative study of stage-specific spermatocyte damage following administration of ethylene glycol monomethyl ether in the rat. Experimental and Molecular Pathology **43**:321-336.
- Croisille, Y** (1981) Differentiation of the epididymis in birds, with particular reference to the rooster. Progress in Reproductive Biology **8**:1-11.
- Cross, BA and Glover, TD** (1958) The hypothalamus and seminal emission. Journal of Endocrinology **16**:385-395.
- Cummins, JM** (1976) Epididymal maturation of spermatozoa in the marsupial *Trichosurus vulpecula*: change in motility and gross morphology. Australian Journal of Zoology **24**:499-511.
- Cummins, JM and Glover, TD** (1970) Artificial cryptorchidism and fertility in the rabbit. Journal of Reproduction and Fertility **23**:423-424.
- Cummins, JM, Temple-Smith, PD and Renfree, MB** (1986) Reproduction in the male honey possum (*Tarsipes rostratus*: Marsupialia): The epididymis. The American Journal of Anatomy **177**:385-401.
- Cunningham, GR, Tindall, DJ, Huckins, C and Means, AR** (1978) Mechanisms for the testicular hypertrophy which follows hemicastration. Endocrinology **102**:16-23.
- Curtis, GM** (1918) The morphology of the mammalian seminiferous tubule. The American Journal of Anatomy **24**:339-394.
- Dacheux, J-L and Voglmayr, JK** (1983) Sequence of sperm cell surface differentiation and its relationship to exogenous fluid proteins in the ram epididymis. Biology of Reproduction **29**:1033-1046.
- Dacheux, J-L, Druart, X, Fouchecourt, S, Syntin, P, Gatti, J-L, Okamura, N and Dacheux, F** (1998) Role of epididymal secretory proteins in sperm maturation with particular reference to the boar. Journal of Reproduction and Fertility Supplement **53**:99-107.
- Dadoune, J-P and Alfonsi, M-F** (1984) Autoradiographic investigation of sperm transit through the male mouse genital tract after tritiated thymidine incorporation. Reproduction, Nutrition and Developpement **24**:927-935.
- Dahl, E, Kjaerheim, A and Tveter, KJ** (1973) The ultrastructure of the accessory sex organs of the male rat. I. Normal structure. Zeitschrift für Zellforschung und mikroskopische Anatomie **137**:345-359.
- Dang, DC** (1971) Duree du cycle de l'epithelium seminifere du singe crabier, *Macaca fascicularis*. Annales de Biologie Animale, Biochimie et Biophysique **11**:373-377.
- Danzo, BJ, Pavlou, SN and Anthony, HL** (1990) Hormonal regulation of androgen-binding protein in the rat. Endocrinology **127**:2829-2838.

- Darwin, C** (1971) The Descent of Man and Selection in Relation to Sex. John Murray, London.
- de Franca, LR, Ghosh, S, Ye, S-J and Russell, LD** (1993) Surface and surface-to-volume relationships of the Sertoli cell during the cycle of the seminiferous epithelium in the rat. Biology of Reproduction **39**:1215-1228.
- de Kretser, DM** (1969) Ultrastructural features of human spermiogenesis. Zeitschrift für Zellforschung und mikroskopische Anatomie **98**:477-505.
- de Kretser, DM and Kerr, JB** (1994) The cytology of the testis. In The Physiology of Reproduction 2nd Ed. Vol. 1. E Knobil and JD Neill Eds. Raven Press, New York. pp. 1177-1290.
- de Kretser, DM, Kerr, JB and Paulsen, CA** (1981) Evaluation of the ultrastructural changes in the human Sertoli cell in testicular disorders and the relationship of the changes to the serum levels of FSH. International Journal of Andrology **4**:129-144.
- de Reviers, M, Hochereau de Reviers, MT and Blanc, MR** (1980) Control of Sertoli and germ cell populations in the cock and sheep testes. Reproduction Nutrition and Developpement **20**:241-249.
- de Rooij, DG** (1968) Stem cell renewal and duration of the spermatogonial cycle in the goldhamster. Zeitschrift für Zellforschung und mikroskopische Anatomie **89**:133-136.
- de Rooij, DG** (1973) Spermatogonial stem cell renewal in the mouse. I. Normal situation. Cell and Tissue Kinetics **6**:281-287.
- de Rooij, DG** (1983) Proliferation and differentiation of undifferentiated spermatogonia in the mammalian testis. In Stem Cells: Their Identification and Characterisation. CS Potten Ed. Churchill-Livingstone, Edinburgh. pp. 89-117.
- de Rooij, DG and Lok, D** (1987) The regulation of the density of spermatogonia in the seminiferous epithelium of the Chinese hamster. II. Differentiating spermatogonia. The Anatomical Record **217**:131-136.
- de Rooij, DG and van Dissel-Emiliani, FMF** (1997) Regulation of proliferation and differentiation of stem cells in the male germ line. In Stem Cells. CS Potten Ed. Academic Press, London. pp. 283-313.
- de Rooij, DG, van Alphen, MMA and van de Kant, HJG** (1986) Duration of the cycle of the seminiferous epithelium and its stages in the rhesus monkey, (*Macaca mulatta*). Biology of Reproduction **35**:587-591.
- de Rooij, DG, van Dissel-Emiliani, FMF and van Pelt, AMM** (1989) Regulation of spermatogonial proliferation. Annals of the New York Academy of Sciences **564**:140-153.
- Desjardins, C** (1978) Endocrine regulation of reproductive development and function in the male. Journal of Animal Science, Supplement **2**:56-77.

- Desjardins, C** (1981) Endocrine signalling and male reproduction. Biology of Reproduction **24**:1-21.
- Djakiew, D and Cardullo, R** (1986) Lower temperature of the cauda epididymis facilitates the storage of sperm by enhancing oxygen availability. Gamete Research **15**:237-245.
- Djakiew, D and Jones, RC** (1981) Structural differentiation of the male genital ducts of the echidna (*Tachyglossus aculeatus*). Journal of Anatomy **132**:187-202.
- Djakiew, D and Jones, RC** (1982a) Ultrastructure of the ductus epididymidis of the echidna, (*Tachyglossus aculeatus*). Journal of Anatomy **135**:625-634.
- Djakiew, D and Jones, RC** (1982b) Stereological analysis of the epididymis of the echidna, *Tachyglossus aculeatus*, and the Wistar rat. Australian Journal of Zoology **30**:865-875.
- Djakiew, D, Byers, SW and Dym, M** (1984) Receptor-mediated endocytosis of alpha-2-macroglobulin and transferrin in rat caput epididymal epithelial cells *in vitro*. Biology of Reproduction **31**:1073-1085.
- Djakiew, D, Byers, SW, Lewis, DM and Dym, M** (1985) Receptor-mediated endocytosis of alpha-2-macroglobulin by principal cells in the proximal caput epididymidis *in vivo*. Journal of Andrology **6**:190-196.
- Donahoe, PK, Ito, Y, Marfatia, S and Hendren, WH** (1976) The production of Mullerian inhibiting substance by the fetal, neonatal and adult rat. Biology of Reproduction **15**:329-334.
- Donahoe, PK, Ito, Y, Price, JM and Hendren, WH** (1977) Mullerian inhibiting substance activity in bovine fetal, newborn and prepubertal testes. Biology of Reproduction **15**:238-243.
- Dott, HM and Dingle, JT** (1969) Distribution and lysosomal enzymes in the spermatozoa and cytoplasmic droplets of bull and ram. Experimental Cell Research **52**:523-540.
- Duckett, RJ, Hedger, MP, McLachlan, RI and Wreford, NG** (1997) The effects of gonadotropin-releasing hormone immunisation and recombinant follicle-stimulating hormone on the Leydig cell and macrophage populations of the adult rat testis. Journal of Andrology **18**:417-423.
- Dym, M** (1973) The fine structure of the monkey (*Macaca*) Sertoli cell and its role in maintaining the blood-testis barrier. The Anatomical Record **175**:639-656.
- Dym, M** (1974) The fine structure of monkey Sertoli cells in the transitional zone at the junction of the seminiferous tubules with the tubuli recti. The American Journal of Anatomy **140**:1-26.
- Dym, M** (1976) The mammalian rete testis a morphological examination. The Anatomical Record **186**:493-524.

- Dym, M and Clermont, Y** (1970) Role of spermatogonia in the repair of the seminiferous epithelium following X-irradiation of the rat testis. The American Journal of Anatomy **128**:265-282.
- Dym, M and Fawcett, DW** (1970) The blood-testis barrier in the rat and the physiological compartmentation of the seminiferous epithelium. Biology of Reproduction **3**:308-326.
- Dym, M and Romrell, LJ** (1975) Intraepithelial lymphocytes in the male reproductive tract of rats and rhesus monkey. Journal of Reproduction and Fertility **42**:1-7.
- Eckstein, P and Zuckerman, S** (1956) Morphology of the Reproductive tract. In Marshall's Physiology of Reproduction. 3rd Ed. Vol. 1. AS Parkes Ed. Longmans Green, London. pp. 43-155.
- Eddy, EM, Clark, JM, Gong, D and Fenderson, BA** (1981) Origin and migration of primordial germ cells in mammals. Gamete Research **4**:333-362.
- Elftman, H** (1950) The Sertoli cell cycle in the mouse. The Anatomical Record **106**:381-393.
- Esponda, P and Bedford, JM** (1986) The influence of body temperature and castration on the protein composition of fluid in the rat cauda epididymidis. Journal of Reproduction and Fertility **78**:505-514.
- Esponda, P, Regalado, F and Nieto, A** (1990) Effects of temperature and castration on the synthesis of secretory proteins in the rabbit cauda epididymidis. In Fertilization in Mammals. BD Bavister, JM Cummins and ERS Roldan Eds. Serono Symposia, Norwell. p. 416. (Abstract)
- Ewing, LL, Zirkin, BR, Cochran, RC, Kromann, N, Peters, C and Ruiz-Bravo, N** (1979) Testosterone secretion by rat, rabbit, guinea pig, dog and hamster testes perfused *in vitro*: correlation with Leydig cell mass. Endocrinology **105**:1135-1142.
- Fauchere, JL** (1982) A quantitative structure-activity relationship study of the inhibitory action of a series of enkephalin-like peptides in the guinea pig ileum and mouse vas deferens bioassays. Journal of Medicinal Chemistry **25**:1428-1431.
- Fawcett, DW** (1970) A comparative view of sperm ultrastructure. Biology of Reproduction Supplement **2**:90-127.
- Fawcett, DW** (1973) Observations on the organisation of the interstitial tissue of the testis and on the occluding cell junctions in the seminiferous epithelium. Advances in the Biosciences **10**:83-99.
- Fawcett, DW** (1975a) Ultrastructure and function of the Sertoli cell. Handbook of Physiology, Vol. V. Endocrinology. Section 7, Male Reproductive System. DW Hamilton and RO Greep Eds. American Physiological Society, Washington, DC. pp. 21-55.
- Fawcett, DW** (1975b) The mammalian spermatozoon. Developmental Biology **44**:394-436.

- Fawcett, DW and Hoffer, AP** (1979) Failure of exogenous androgens to prevent regression of the initial segments of the rat epididymis after efferent duct ligation and orchidectomy. Biology of Reproduction **20**:162-181.
- Fawcett, DW and Hollenberg, RD** (1963) Changes in the acrosome of guinea pig spermatozoa during passage through the epididymis. Zeitschrift für Zellforschung und mikroskopische Anatomie **60**:276-292.
- Fawcett, DW and Phillips, DM** (1969) Observations on the release of spermatozoa and on changes in the head during passage through the epididymis. Journal of Reproduction and Fertility Supplement **6**:405-418.
- Fawcett, DW, Anderson, WA and Phillips, DM** (1971) Morphogenic factors influencing the shape of the sperm head. Developmental Biology **26**:220-251.
- Fawcett, DW, Heidger, PJ and Leak, LV** (1969) The lymph-vascular system of the interstitial tissue of the testis as revealed by electron microscopy. Journal of Reproduction and Fertility **19**:109-119.
- Fawcett, DW, Leak, LV and Heidger, PJ** (1970) Electron microscopic observations on the structural components of the blood-testis barrier. Journal of Reproduction and Fertility Supplement **10**:105-122.
- Fawcett, DW, Neaves, WB and Flores, MN** (1973) Comparative observations of intertubular lymphatics and the organisation of the interstitial tissue of the mammalian testis. Biology of Reproduction **9**:500-512.
- Fichna, P and Malendowicz, LK** (1975) A karyometric and stereologic study of the effects of gonadotrophin and testosterone on the interstitial gland of the testis of intact and endoxan treated rats. Cell and Tissue Research **164**:411-424.
- Finlayson, HH** (1940) On Central Australian mammals. Part 1. The Muridae. Transactions of the Royal Society of South Australia **64**:125-136.
- Flaherty, SP** (1986) Structural and functional aspects of sperm head morphology in the plains mouse. PhD Thesis, Department of Anatomy and Histology, University of Adelaide. Adelaide, SA.
- Flickinger, CJ** (1967) The postnatal development of the Sertoli cells of the mouse. Zeitschrift für Zellforschung und mikroskopische Anatomie **78**:92-113.
- Flickinger, CJ** (1979) Synthesis, transport, and secretion of protein in the initial segment of the mouse epididymis as studied by electron microscope autoradiography. Biology of Reproduction **20**:1015-1030.
- Flickinger, CJ** (1981) Regional differences in synthesis, intracellular transport, and secretion of protein in the mouse epididymis. Biology of Reproduction **25**:871-883.
- Flickinger, CJ** (1983) Synthesis and secretion of glycoprotein by the epididymal epithelium. Journal of Andrology **4**:157-161.

- Flickinger, CJ** (1985) Radioautographic analysis of the secretory pathway for glycoproteins in principal cells of the mouse epididymis exposed to [³H] fucose. Biology of Reproduction **32**:377-389.
- Flickinger, CJ and Fawcett, DW** (1967) The junctional specialisations of Sertoli cells in the seminiferous epithelium. The Anatomical Record **158**:207-222.
- Flickinger, CJ, Howards, SS and English, HF** (1978) Ultrastructural differences in efferent ducts and several regions of the epididymis of the hamster. The American Journal of Anatomy **152**:557-586.
- Foldsey, RG and Bedford, JM** (1982) Biology of the scrotum. I. Temperature and androgens as determinants of the sperm storage capacity of the rat cauda epididymidis. Biology of Reproduction **26**:673-682.
- Foote, RH, Swiestra, EE and Hunt, WL** (1972) Spermatogenesis in the dog. The Anatomical Record **173**:341-352.
- Fornes, MW and De Rosas, JC** (1991) Interactions between rat epididymal epithelium and spermatozoa. The Anatomical Record **231**:193-200.
- Forssmann, WG, Ito, S, Weihe, E, Aoki, A, Dym, M and Fawcett, DW** (1977) An improved perfusion fixation method for the testis. The Anatomical Record **188**:307-314.
- Fouquet, JP and Dadoune, JP** (1986) Renewal of spermatogonia in the monkey (*Macaca fascicularis*). Biology of Reproduction **35**:199-207.
- França, LR, Ogawa, T, Avarbock, MR, Brinster, RL and Russell, LD** (1998) Germ cell genotype controls cell cycle during spermatogenesis in the rat. Biology of Reproduction **59**:1371-1377.
- Francavilla, S, Cordeschi, G, Diccico, L, Jannini, AE, Palmero, S, Fugassa, E, Loras, B and D'Armiento, MD** (1991) Effect of thyroid hormone on the pre- and post-natal development of the rat testis. Journal of Endocrinology **129**:35-42.
- Franke, WW, Grund, C and Schmid, E** (1979) Intermediate-sized filaments present in Sertoli cells are of the vimentin type. European Journal of Cell Biology **19**:269-275.
- Frankel, AI, Chapman, JC and Wright, WW** (1989) The equivocal presence of nuclear androgen-binding proteins in spermatids and spermatozoa. Journal of Steroid Biochemistry **33**:71-79.
- Frenkel, G, Peterson, RN and Freund, M** (1973) Role of adenine nucleotide and the effect of caffeine and dibutyryl cyclic AMP on the metabolism of guinea pig epididymal spermatozoa. Proceeding of the Society of Experimental Biology and Medicine **144**: 420-425.
- Friend, DS** (1969) Cytochemical staining of multivesicular bodies and Golgi vesicles. Journal of Cell Biology **41**:269-279.

- Fritz, IB** (1978) Sites of actions of androgens and FSH on cells of the seminiferous tubule. In Biochemical Actions of Hormones. G Litwack Ed. Academic Press, New York. pp. 249-281.
- Furuya, S, Kumamoto, Y and Sugiyama, S** (1978) Fine structure and development of Sertoli cell junctions in human testis. Archives of Andrology **1**:211-219.
- Gage, M** (1994) Associations between body size, mating pattern, testis size and sperm lengths across butterflies. Proceedings of the Royal Society of London, Series B **258**:247-254.
- Gardner, PJ and Holyoke, EA** (1964) Fine structure of the seminiferous tubule of the Swiss mouse. I. The limiting membrane, Sertoli cell, spermatogonia and spermatocytes. The Anatomical Record **150**:391-404.
- Gasinska, A and Hill, S** (1990) The effect of hyperthermia on the mouse testis. Neoplasma **37**:357-366.
- Gaytan, F, Bellido, C, Aguilar, E and van Rooijen, N** (1994) Requirement for testicular macrophages in Leydig cell proliferation and differentiation during prepubertal development in rats. Journal of Reproduction and Fertility **102**:393-399.
- Gebauer, MR, Pickett, BW and Swierstra, EE** (1974a) Reproductive Physiology of the stallion: II. Daily production and output of sperm. Journal of Animal Science **39**:732-736.
- Gebauer, MR, Pickett, BW and Swierstra, EE** (1974b) Reproductive Physiology of the stallion: III. Extragonadal transit time and sperm reserves. Journal of Animal Science **39**:737-742.
- George, FW and Wilson, JD** (1994) Sex determination and differentiation. In The Physiology of Reproduction 2nd Ed. Vol. 1. E Knobil and JD Neill Eds. Raven Press, New York. pp. 3-28.
- Ghosh, S, Bartke, A, Grasso, P, Reichert, LE and Russell, LD** (1989) Structural manifestations of the response of the rat Sertoli cell post hypophysectomy: A correlative morphometric and endocrine study. Endocrinology **131**:485-497.
- Ghosh, S, Sinha-Hikim, AP and Russell, LD** (1991) Further observations of stage specific effects seen after short-term hypophysectomy in the rat. Tissue and Cell **23**:613-630.
- Gier, HT and Marion, GB** (1970) Development of the mammalian testis. In The Testis. AD Johnson, WR Gomes and NL Vandemark Eds. Academic Press, New York. pp. 2-45.
- Gilula, NB, Fawcett, DW and Aoki, A** (1976) The Sertoli cell occluding junctions and gap junctions in mature and developing mammalian testis. Developmental Biology **50**:142-168.

- Glover, TD and Nicander, L** (1971) Some aspects of structure and function in the mammalian epididymis. Journal of Reproduction and Fertility, Supplement **13**:39-50.
- Glucksmann, A, Howard, A and Pelc, SR** (1955) Incorporation of ³⁵S-DL-methionine in mouse tissues as indicated by autoradiographs. I. Testis, epididymis and seminal vesicle. Journal of Anatomy **89**:13-18.
- Go, VLW, Vernon, RG and Fritz, IB** (1971) Studies on spermatogenesis in rats. III. Effects of hormonal treatment on differentiation kinetics of the spermatogenic cycle in regressed hypophysectomized rats. Canadian Journal of Biochemistry **49**:768-775.
- Gomendio, M, Harcourt, AH and Roldan, ERS** (1998) Sperm Competition in mammals. In Sperm Competition and Sexual Selection. TR Birkhead and AP Møller Eds. Academic Press, San Diego. pp. 667-751.
- Gondos, B** (1980) Development and differentiation of the testis and male reproductive tract. In Testicular Development, Structure and Function. A Steinberger and E Steinberger Eds. Raven Press, New York. pp. 3-20.
- Gondos, B and Berndtson, WE** (1993) Postnatal and pubertal development. In The Sertoli Cell. LD Russell and MD Griswold Eds. Cache River Press, Clearwater. pp. 115-154.
- Gotterer, G, Ginsberg, D, Schulman, T, Banks, J and Williams-Ashman, HG** (1955) Enzymatic coagulation of semen. Nature, London **176**:1209-1211.
- Graves, JAM** (1994) Mammalian sex-determining genes. In The Differences Between the Sexes. RV Short and E Balaban Eds. Cambridge University Press, Cambridge. pp. 397-418.
- Griswold, MD** (1993) Protein secretion by Sertoli cells: General considerations. In The Sertoli Cell. LD Russell and MD Griswold Eds. Cache River Press, Clearwater. pp.195-200.
- Griswold, MD, Solari, A, Tung, PS and Fritz, IB** (1977) Stimulation by follicle stimulating hormone of DNA synthesis and of mitosis in cultures Sertoli cells prepared from testes of immature rats. Molecular and Cellular Endocrinology **7**:151-165.
- Grocock, CA and Clarke, JR** (1976) Duration of spermatogenesis in the vole (*Microtus agrestis*) and bank vole (*Clethrionomys glareolus*). Journal of Reproduction and Fertility **47**:133-135.
- Grootegoed, JA, Peters, MJ, Mulder, E, Rommerts, FFG and van der Molen, HJ** (1977) Absence of a nuclear androgen receptor in isolated germinal cells of rat testis. Molecular and Cellular Endocrinology **9**:159-167.
- Grove, BD and Vogl, AW** (1989) Sertoli cell ectoplasmic specialisations: a type of actin-associated adhesion junction? Journal of Cell Science **93**:309-323.

- Gubbay, J, Collignon, J, Koopman, P, Capel, B, Economou, A, Münsterberg, A, Vivian, N, Goodfellow, P and Lovell-Badge, R** (1990) A gene mapping to the sex-determining region of the mouse Y chromosome is a member of a novel family of embryonically expressed genes. Nature **346**:245-250.
- Gutroff, RF, Cooke, Ps and Hess RA** (1992) Blind ending tubules and branching patterns of the rat ductuli efferentes. The Anatomical Record **232**:423-431.
- Hall, SH, Conti, M, French, FS and Joseph, DR** (1990) Follicle-stimulating hormone regulation of androgen-binding protein messenger RNA in Sertoli cell cultures. Molecular Endocrinology **4**:349-355.
- Hamilton, DW** (1975) Structure and function of the epithelium lining the ductuli efferentes, ductus epididymidis, and ductus deferens in the rat. In Handbook of Physiology, Vol. V. Endocrinology. Section 7, Male Reproductive System. DW Hamilton and RO Greep Eds. American Physiological Society, Washington, D.C. pp. 259-302.
- Hamilton, DW** (1990) Anatomy of mammalian male accessory reproductive organs. In Marshall's Physiology of Reproduction, 4th Ed. Vol. 2, Reproduction in the Male. GE Lamming Ed. Churchill Livingstone, Edinburgh. pp. 691-746.
- Hamilton, DW and Cooper, TG** (1978) Gross and histological variations along the length of the rat vas deferens. The Anatomical Record **190**:795-810.
- Hamilton, DW, Wenstrom, JC and Baker, JB** (1986) Membrane glycoproteins from spermatozoa: partial characterization of an integral $M_r \sim c24,000$ molecule from rat spermatozoa that is glycosylated during epididymal maturation. Biology of Reproduction **34**:925-936.
- Happold, M** (1976) Social behaviour of the Conilurine rodents (Muridae) of Australia. Zeitschrift für Tierpsychologie **40**:113-182.
- Harcourt, AH, Harvey, PH, Larson, SG and Short, RV** (1981) Testis weight, body weight and breeding system in primates. Nature **293**:55-57.
- Harcourt, AH, Purvis, A and Liles, L** (1995) Sperm competition: mating system, not breeding season, affects testis size of primates. Functional Ecology **9**:468-476.
- Harding, HR, Carrick, FN and Shorey, CD** (1976) Ultrastructural changes in spermatozoa of the brush-tailed possum, *Trichosurus vulpecula* (Marsupialia) during epididymal transit. Part II, The acrosome. Cell and Tissue Research **171**:61-73.
- Harding, HR, Carrick, FN and Shorey, CD** (1979) Special features of sperm structure and function in marsupials. In The Spermatozoon. DW Fawcett and JM Bedford Eds. Urban and Schwarzenberg, Baltimore. pp. 289-303.
- Hardy, MP, Zirkin, BR and Ewing, LL** (1989) Kinetic studies on the development of the adult population of Leydig cells in testes of the pubertal rat. Endocrinology **124**:762-770.

- Harley, VR** (1993) Genetic control of testis determination. In Molecular Biology of the Male Reproductive System. D de Kretser Ed. Academic Press, San Diego. pp. 1-20.
- Harvey, PH and Harcourt, AH** (1984) Sperm competition, testes size, and breeding systems in primates. In Sperm Competition and the Evolution of Animal Mating Systems. RL Smith Ed. Academic Press, New York. pp 589-600.
- Hatier, R, Grignon, G and Touati, F** (1982) Ultrastructural study of seminiferous tubules in the rat after prenatal irradiation. Anatomy and Embryology **165**:425-436.
- Hayward, P and Shire, JGM** (1974) Y chromosome effect on adult testis size. Nature **250**:499-500.
- Heath, JK** (1978) Mammalian primordial germ cells. In Development in Mammals. Vol. 3. MH Johnson Ed. North Holland, Amsterdam. pp. 267-298.
- Hedger, MP** (1997) Testicular leukocytes: what are they doing? Reviews of Reproduction **2**:38-47.
- Hees, H, Wrobel, KH, Kohler, T, Leiser, R and Rothbacher, I** (1987) Spatial topography of the excurrent duct system in the bovine testis. Cell and Tissue Research **248**:143-157.
- Heller, CG and Clermont, Y** (1963) Spermatogenesis in man: an estimate of its duration. Science **140**:184-186.
- Heller, CG and Clermont, Y** (1964) Kinetics of the germinal epithelium in man. Recent Progress in Hormone Research **20**:545-575.
- Hemeida, NA, Sack, WO and McEntee, K** (1978) Ductuli efferentes in the epididymis of boar, goat, ram, bull and stallion. American Journal of Veterinary Research **39**:1892-1900.
- Henriksen, K, Hakovirta, H and Parvinen, M** (1995) Testosterone inhibits and induces apoptosis in rat seminiferous tubules in a stage-specific manner: in situ quantification in squash preparations after administration of ethane dimethane sulfonate. Endocrinology **136**:3285-3291.
- Hermo, L and Morales, C** (1984) Endocytosis in nonciliated epithelial cells of the ductuli efferentes in the rat. The American Journal of Anatomy **171**:59-74.
- Hermo, L, Clermont, Y and Morales, C** (1985) Fluid-phase and adsorptive endocytosis in ciliated epithelial cells of the rat ductuli efferentes. The Anatomical Record **211**:285-294.
- Hermo, L, De Melo, V, Harris, PG and Clermont, Y** (1986) The endocytic apparatus of non-ciliated cells of the ductuli efferentes of the rat. The Anatomical Record **214**:53. (Abstract)
- Hermo, L, Dworkin, J and Oko, R** (1988) Role of epithelial clear cells of the rat epididymis in the disposal of the contents of cytoplasmic droplets detached from spermatozoa. The American Journal of Anatomy **183**:107-124.

- Hermo, L, Lalli, M and Clermont, Y** (1977) Arrangement of connective tissue components in the walls of seminiferous tubules of man and monkey. The American Journal of Anatomy **148**:433-436.
- Herrick, CS and Wolfe, HG** (1977) Effect of the Y-chromosome on testes size in the mouse (*Mus musculus*). Genetics **86**: s27. (Abstract)
- Heske, EJ and Ostfeld, RS** (1990) Sexual dimorphism in size, relative size of testes, and mating systems in North American voles. Journal of Mammalogy **71**:510-519.
- Hess, RA** (1990) Quantitative and qualitative characteristics of the stages and transitions in the cycle of the rat seminiferous epithelium: light microscopic observations of perfusion-fixed and plastic-embedded testes. Biology of Reproduction **43**:525-542.
- Hess, RA, Schaeffer, DJ, Eroschenko, VP and Keen, JE** (1990) Frequency of the stages in the cycle of the seminiferous epithelium in the rat. Biology of Reproduction **43**:517-524.
- Hilscher, W and Hilscher, B** (1969) Autoradiographische Untersuchungen über die Kinetik der Spermatogenese der Wistar-Ratte unter besonderer Berücksichtigung der Spermatocytogenese. Zeitschrift für Zellforschung und mikroskopische Anatomie **96**:625-640.
- Hilscher, B, Hilscher, W, Bühlhoff-Ohnolz, B, Krämer, U, Birke, A, Pelzer, H and Gauss, G** (1974) Kinetics of gametogenesis. I. Comparative histological and autoradiographic studies of oocytes and transitional prospermatogonia during oogenesis and prespermatogenesis. Cell and Tissue Research **154**:443-470.
- Hinton, BT** (1990) The testicular and epididymal luminal amino acid microenvironment in the rat. Journal of Andrology **11**:498-505.
- Hinton, BT and Palladino, MA** (1995) Epididymal epithelium: Its contribution to the formation of a luminal fluid microenvironment. Microscopy Research and Technique **30**:67-81.
- Hinton, BT and Setchell, BP** (1993) Fluid secretion and movement. In The Sertoli Cell. LD Russell and MD Griswold Eds. Cache River Press, Clearwater. pp.249-267.
- Hinton, BT, Palladino, MA, Mattmueller, DR, Bard, D and Good, K** (1991) Expression and activity of gamma glutamyl transpeptidase in the rat epididymis. Molecular Reproduction and Development **28**:40-46.
- Hochereau, MT** (1963a) Étude comparée de la vague spermatogénétique chez le taureau et chez le rat. Annales de Biologie Animale, Biochimie et Biophysique **3**:5-20.
- Hochereau, MT** (1963b) Constance des fréquences relatives des stades du cycle de l'épithélium séminifère chez le taureau et chez le rat. Annales de Biologie Animale, Biochimie et Biophysique **3**:93-102.
- Hochereau, MT, Courot, M and Ortavant, R** (1964) Marquage des cellules germinales du belier et du taureau par injection de thymidine tritiée dans l'artère spermatique. Annales de Biologie Animale, Biochimie et Biophysique **4**:157-161.

- Hoffer, AP** (1972) The fine structure of the ductuli efferentes in mouse and rat. The Anatomical Record **172**:331-332.
- Hoffer, AP** (1976) The ultrastructure of the ductus deferens in man. Biology of Reproduction **14**:425-443.
- Hoffer, AP and Greenberg, J** (1978) The structure of the epididymis, efferent ductules and ductus deferens of the guinea pig. A light microscope study. The Anatomical Record **190**:659-678.
- Hoffer, AP and Karnovsky, ML** (1981) Studies on zonation in the epididymis of the guinea pig. I. Ultrastructural and biochemical analysis of the zone rich in large lipid droplets (Zone II). The Anatomical Record **201**:623-633.
- Hoffer, AP, Hamilton, DW and Fawcett, DW** (1973) The ultrastructure of principal cells and intraepithelial leucocytes in the initial segment of the rat epididymis. The Anatomical Record **175**:169-202.
- Holland, MK, Vreeburg, JMT and Orgebin-Crist, MC** (1992) Testicular regulation of epididymal protein secretion. Journal of Andrology **13**:266-272.
- Holstein, AF** (1976) Ultrastructural observations on the differentiation of spermatids in man. Andrologia **8**:157-165.
- Huckins, C** (1971) The spermatogonial stem cell population in adult rats. 1. Their morphology, proliferation and maturation. The Anatomical Record **169**:533-558.
- Huckins, C** (1965) Duration of spermatogenesis in pre- and post-pubertal Wistar rats. The Anatomical Record **151**:364. (Abstract)
- Huckins, C** (1978a) Spermatogonial intercellular bridges in whole-mounted seminiferous tubules from normal and irradiated rodent testes. The American Journal of Anatomy **153**:97-122.
- Huckins, C** (1978b) The morphology and kinetics of spermatogonial degeneration in adult rats: An analysis using a simplified classification of the germinal epithelium. The Anatomical Record **190**:905-926.
- Huckins, C and Oakberg, EF** (1978) Morphological and quantitative analysis of spermatogonia in mouse testes using whole mounted seminiferous tubules. I. The normal testes. The Anatomical Record **192**:519-528.
- Hunt, SE and Mittwoch, U** (1987) Y-chromosomal and other factors in the development of testis size in mice. Genetical Research, Cambridge **50**:205-211.
- Hunter, RHF, Holtz, W and Henfrey, PJ** (1976) Epididymal function in the boar in relation to the fertilizing ability of spermatozoa. Journal of Reproduction and Fertility **46**:463-466.
- Hutson, JC** (1990) Changes in the concentration and size of testicular macrophages during development. Biology of Reproduction **43**:885-890.
- Ilio, KY and Hess, RA** (1994) Structure and function of the ductuli efferentes: A review. Microscopy Research and Technique **29**:432-467.

- Jäger, RF, Anvret, M, Hall K and Scherer, G** (1990) A human XY female with a frame shift mutation in the candidate testis-determining gene SRY. Nature **348**:452-454.
- Jannini, EA, Ulisse, S and D'Armiento, N** (1995) Thyroid hormone and male gonadal function. Endocrine Review **16**:443-459.
- Jegou, B, Le Gac, F and de Kretser, DM** (1982) Seminiferous tubule fluid, and interstitial fluid production. I. Effects of age and hormonal regulation in immature rats. Biology of Reproduction **27**:590-595.
- Jesik, CJ, Holland, JM and Lee, C** (1982) An anatomic and histologic study of the rat prostate. Prostate **3**:81-97.
- Johnson, L** (1985) Increased daily sperm production in the breeding season of stallions is explained by an elevated population of spermatogonia. Biology of Reproduction **32**:1181-1190.
- Johnson, L** (1986a) A new approach to quantification of Sertoli cells that avoids problems associated with the irregular nuclear surface. The Anatomical Record **214**:231-237.
- Johnson, L** (1986b) Spermatogenesis and aging in the human. Journal of Andrology **7**:331-354.
- Johnson, L** (1995) Efficiency of spermatogenesis. Microscopy Research and Technique **32**:385-422.
- Johnson, L and Neaves, WB** (1981) Age-related changes in the Leydig cell population, seminiferous tubules, and sperm production in stallions. Biology of Reproduction **24**:703-712.
- Johnson, L and Neaves, WB** (1983) Enhanced daily sperm production in the remaining testis of aged rats following hemicastration. Journal of Andrology **4**:162-166.
- Johnson, L and Neaves, WB** (1986) Effect of germ cell loss during spermatogenesis on sperm production in young and older adult men. Biology of Reproduction (Supplement 1) **34**:61. (Abstract)
- Johnson, L and Thompson, DL** (1983) Age-related and seasonal variation in the Sertoli cell population, daily sperm production and serum concentrations of follicle-stimulating hormone, luteinizing hormone and testosterone in stallions. Biology of Reproduction **29**:777-789.
- Johnson, L and Varner, DD** (1988) Effect of daily spermatozoan production but not age on transit time of spermatozoa through the human epididymis. Biology of Reproduction **39**:812-817.
- Johnson, L, Carter, GK, Varner, DD, Taylor, TS, Blanchard, TL and Rembert, MS** (1994) The relationship of daily sperm production with number of Sertoli cells and testicular size in adult horses: role of primitive spermatogonia. Journal of Reproduction and Fertility **100**:315-321.

- Johnson, L, Chaturvedi, PK and Williams, JD** (1992) Missing generations of spermatocytes and spermatids in seminiferous epithelium contribute to low efficiency of spermatogenesis in humans. Biology of Reproduction **47**:1091-1098.
- Johnson, L, Petty, CS and Neaves, WB** (1980a) A comparative study of daily sperm production and testicular composition in humans and rats. Biology of Reproduction **22**:1233-1243.
- Johnson, L, Petty, CS and Neaves, WB** (1980b) The relationship of biopsy evaluations and testicular measurements to over-all daily sperm production in human testes. Fertility and Sterility **34**:36-40.
- Johnson, L, Petty, CS and Neaves, WB** (1981) A new approach to the quantification of spermatogenesis and its application to germinal cell attrition during human spermiogenesis. Biology of Reproduction **25**:217-226.
- Johnson, L, Petty, CS and Neaves, WB** (1983) Further quantification of human spermatogenesis: germ cell loss during prophase of meiosis and its relationship to daily sperm production. . Biology of Reproduction **29**:207-215.
- Johnson, L, Petty, CS and Neaves, WB** (1986) Age-related variation in seminiferous tubules in men, a stereologic evaluation. Journal of Andrology **7**:316-322.
- Johnson, L, Petty, CS, Porter, JC and Neaves, WB** (1984a) Germ cell degeneration during prophase of meiosis and serum concentrations of gonadotropins in young and adult men. Biology of Reproduction **31**:779-784.
- Johnson, L, Varner, DD, and Thompson, DL** (1991) Effect of age and season on the establishment of spermatogenesis in the horse. Journal of Reproduction and Fertility **44**:87-97.
- Johnson, L, Zane, RS, Petty, CS and Neaves, WB** (1984b) Quantification of the human Sertoli cell population: its distribution, relation to germ cell numbers, and age related decline. Biology of Reproduction **31**:785-795.
- Jones, R** (1998) Plasma membrane structure and remodelling during sperm maturation in the epididymis. Journal of Reproduction and Fertility Supplement **53**:73-84.
- Jones, R, Hamilton, DW and Fawcett, DW** (1979) Morphology of the epithelium of the extratesticular rete testis, ductuli efferentes and ductus epididymidis of the adult male rabbit. The American Journal of Anatomy **156**:373-400.
- Jones, R, Von Glos, KI and Brown, CR** (1981) Characterisation of hormonally regulated secretory proteins from the caput epididymidis of the rabbit. Biochemical Journal **196**:105-114.
- Jones, RC** (1980) Luminal composition and maturation of spermatozoa in the genital ducts of the African elephant (*Loxodonta africana*). Journal of Reproduction and Fertility **60**:87-93.

- Jones, RC** (1987) Changes in protein concentration of the luminal fluids along the epididymis of the tammar, *Macropus eugenii*. Journal of Reproduction and Fertility **80**:193-199.
- Jones RC and Brosnan, MF** (1981) Studies of the deferent ducts from the testis of the African elephant, *Loxodonta africana*. I Structural Differentiation. Journal of Anatomy **132**:371-386.
- Jones, RC and Clulow, J** (1987) Regulation of the elemental composition of the epididymal fluids in the tammar, *Macropus eugenii*. Journal of Reproduction and Fertility **81**:583-590.
- Jones, RC and Clulow, J** (1994) Interactions of sperm and the reproductive ducts of the male Tammar wallaby, *Macropus eugenii* (Macropodidae: Marsupialia). Reproduction Fertility and Development **6**:437-444.
- Jones, RC and Djakiew, D** (1978) The role of the excurrent ducts from the testes of testicond mammals. Australian Zoologist **20**:201-210.
- Jones, RC and Jurd, KM** (1987) Structural differentiation and fluid resorption in the ductuli efferentes testis of the rat. Australian Journal of Biological Sciences **49**:79-90.
- Jones, RC and Jurd, KJ** (1987) Structural differentiation and fluid resorption in the ductuli efferentes testis of the rat. Australian Journal of Biological Science **40**:79-90.
- Jones, RC, Hinds, LA and Tyndale-Biscoe, CH** (1984) Ultrastructure of the epididymis of the tammar, *Macropus eugenii*, and its relationship to sperm maturation. Cell and Tissue Research **237**:525-535.
- Jones, RC, Rowlands, IW and Skinner, JD** (1974) Spermatozoa in the genital ducts of the African elephant, *Loxodonta africana*. Journal of Reproduction and Fertility **41**:189-192.
- Josso, N** (1974) Mullerian-inhibiting activity of human fetal testicular tissue deprived of germ cells by *in vitro* irradiation. Pediatric Research **8**:755-758.
- Jost, A** (1953) Problems in fetal endocrinology: the gonadal and hypophyseal hormones. Recent Progress in Hormone Research **8**:379-418.
- Joyce, KL, Porcelli, J and Cooke, PS** (1993) Neonatal goitrogen treatment increases adult testis size and sperm production in the mouse. Journal of Andrology **14**:448-455.
- Kelly, CW, Janecki, A, Steinberger, A and Russell, LD** (1991) Structural characteristics of immature rat Sertoli cells *in vivo* and *in vitro*. The American Journal of Anatomy **192**:183-193.
- Kenagy, GJ and Trombulak, SC** (1986) Size and function of mammalian testes in relation to body size. Journal of Mammalogy **67**:1-22.
- Kennedy, SW and Heidger, PM** (1979) Fine structural studies of the rat vas deferens. The Anatomical Record **194**:159-180.

- Kennelly, JJ** (1960) Spermatogenesis in boars. I. The testicular and epididymal spermatozoa reserves. II. Estimated potential daily production of spermatozoa. M.Sc. Thesis, Cornell University. Ithaca, New York.
- Kennelly, JJ** (1972) Coyote reproduction. I. The duration of the spermatogenic cycle and epididymal sperm transport. Journal of Reproduction and Fertility **31**:163-170.
- Kerr, JB** (1988) An ultrastructural and morphometric analysis of the Sertoli cell during the spermatogenic cycle of the rat. Anatomy and Embryology **179**:191-203.
- Kerr, JB** (1991) Ultrastructure of the seminiferous epithelium and intertubular tissue of the human testis. Journal of Electron Microscopy Technique **19**:215-240.
- Kerr, JB** (1992) Spontaneous degeneration of germ cells in normal rat testis: assessment of cell types and frequency during the spermatogenic cycle. Journal of Reproduction and Fertility **95**:825-830.
- Kerr, JB and de Kretser, DM** (1974) The role of the Sertoli cell in phagocytosis of the residual bodies of spermatids. Journal of Reproduction and Fertility **36**:439-440. (Abstract)
- Kerr, JB and de Kretser, DM** (1975) Cyclic variations in Sertoli cell lipid content throughout the spermatogenic cycle in the rat. Journal of Reproduction and Fertility **43**:1-8.
- Kerr, JB and Hedger, MP** (1983) Spontaneous spermatogenic failure in the marsupial mouse, *Antechinus stuartii* Macleay (Dasyuridae: Marsupialia). Australian Journal of Zoology **31**:445-466.
- Kerr, JB, Mayberry, RA and Irby, DC** (1984) Morphometric studies on lipid inclusions in Sertoli cells during the spermatogenic cycle in the rat. Cell and Tissue Research **236**:699-709.
- Kerr, JB, Millar, M, Maddocks, S and Sharpe, RM** (1993) Stage-dependent changes in spermatogenesis and Sertoli cells in relation to the onset of spermatogenic failure following withdrawal of testosterone. The Anatomical Record **235**:547-559.
- Kirby, JD, Jetton, AE, Cooke, PS, Hess, RA, Bunick, D, Ackland, JF, Turek, F and Schwartz, NB** (1992) Developmental hormonal profiles accompanying the neonatal hypothyroidism-induced increase in adult testis size and sperm production in the rat. Endocrinology **131**:559-565.
- Kirchhoff, C and Hale, G** (1996) Cell to cell transfer of glycosylphosphatidylinositol-anchored membrane proteins during sperm maturation. Molecular Human Reproduction **2**:177-184.
- Kirton, KT, Desjardins, C and Hafs, HD** (1967) Distribution of sperm in male rabbits after various ejaculation frequencies. The Anatomical Record **158**:287-292.
- Kluin, PM, Kramer, MF and de Rooij, DG** (1982) Spermatogenesis in the immature mouse proceeds faster than in the adult. International Journal of Andrology **5**:282-294.

- Kluin, PM, Kramer, MF and de Rooij, DG** (1984) Proliferation of spermatogonia and Sertoli cells in maturing mice. Anatomy and Embryology **169**:73-78.
- Kohane, AC, Cameo, MS, Pineiro, L, Garberi, JC and Blaquier, JA** (1980) Distribution and site of production of specific proteins in the rat epididymis. Biology of Reproduction **23**:181-187.
- Koopman, P** (1995) The molecular biology of *SRY* and its role in sex determination in mammals. Reproduction Fertility and Development **7**:713-722.
- Koopman, P, Münsterberg, A, Capel, B, Vivian, N, and Lovell-Badge, R** (1990) Expression of a candidate sex-determining gene during mouse testis differentiation. Nature **348**:450-452.
- Koopman, P, Gubbay, J, Vivian, N, Goodfellow, P and Lovell-Badge, R** (1991) Male development of chromosomally female mice transgenic for *Sry*. Nature **351**:117-121.
- Kopecny, V and Peck, P** (1977) An autoradiographic study of macromolecular synthesis in epithelium of ductus epididymidis in mouse. II. Incorporation of L-fucose-1-³H. Histochemistry **50**:229-238.
- Kormano, M** (1967) Dye permeability and alkaline phosphatase activity of testicular capillaries in the postnatal rat. Histochemie **9**:327-338.
- Kormano, M and Hovatta, O** (1972) Contractility and histochemistry of the myoid cell layer of the rat seminiferous tubules during postnatal development. Zeitschrift für Anatomie und Entwicklungsgeschichte **137**:239-248.
- Kosco, MS, Loseth, KJ and Crabo, BG** (1989) Development of the seminiferous tubules after neonatal hemicastration in the boar. Journal of Reproduction and Fertility **87**:1-11.
- Lalli, MF and Clermont, Y** (1981) Structural changes of the head components of the rat spermatid during spermatogenesis. The American Journal of Anatomy **160**:419-434.
- Lambiase, JT and Amann, RP** (1969) The male rabbit. V. Changes in sperm reserves and resorption rate induced by ejaculation and sexual rest. Journal of Animal Science **28**:542-549.
- Larsen, WJ** (1993) Human Embryology. Churchill Livingstone, New York.
- Lazarides, E** (1980) Intermediate filaments as mechanical integrators of cellular space. Nature **283**:249-256.
- Lea, OA, Petrusz, P and French, FS** (1978) Purification and localisation of acidic epididymal glycoprotein (AEG): a sperm coating protein secreted by the rat epididymis. International Journal of Andrology Supplement **2**:592-605.
- Leblond, CP and Clermont, Y** (1952a) Definition of the stages of the cycle of the seminiferous epithelium in the rat. Annals of the New York Academy of Science **55**:548-573.

- Leblond, CP and Clermont, Y** (1952b) Spermiogenesis of rat, mouse, hamster, and guinea pig as revealed by the 'periodic acid-fuchsin sulfurous acid' technique. The American Journal of Anatomy **90**:167-215.
- Lebovitz, RM and Johnson, L** (1983) Testicular function of rats following exposure to microwave radiation. Bioelectromagnetics **4**:107-114.
- Lee, AK, Baverstock, PR and Watts, CHS** (1981) Rodents: The late invaders. In Ecological Biogeography of Australia. A Keast Ed. W Junk, The Hague. pp. 1523-1553.
- Lee, AK, Fleming, MR and Happold, M** (1984) Microclimate, water economy and energetics of a desert rodent, *Notomys alexis*. In Arid Australia. HG Cogger and EE Cameron Eds. Australian Museum, Sydney. pp. 315-326.
- Lee, J, Richburg, JH, Younkin, SC and Boekelheide, K** (1997) The FAS system is a key regulator of germ cell apoptosis in the testis. Endocrinology **138**:2081-2088.
- Lee, VWK, de Kretser, DM, Hudson, BH and Wang, C** (1975) Variations in FSH, LH and testosterone levels in male rats from birth to sexual maturity. Journal of Reproduction and Fertility **42**:121-126.
- Leeson, CR and Leeson, TS** (1963) The postnatal development and differentiation of the boundary tissue of the seminiferous tubule of the rat. The Anatomical Record **147**:243-259.
- Le Gac, F and de Kretser, DM** (1982) Inhibin production by Sertoli cell cultures. Molecular and Cellular Endocrinology **28**:487-498.
- Levine, N and Kelly, H** (1978) Measurement of pH in rat epididymis *in vivo*. Journal of Reproduction and Fertility **52**:333-335.
- Levine, N and Marsh, DJ** (1971) Micropuncture studies of the electrochemical aspects of fluid and electrolyte transport in individual seminiferous tubules, the epididymis and vas deferens. Journal of Physiology London **231**:557-570.
- Lewis-Jones, DI, Harrison, RG and MacMillan, EW** (1982) A re-examination of rat ductuli efferentes. The Anatomical Record **203**:461-462.
- Lin, M and Rodger, JC** (1999) Acrosome formation during sperm transit through the epididymis in two marsupials, the tammar wallaby (*Macropus eugenii*) and the brushtail possum (*Trichosurus vulpecula*). Journal of Anatomy **194**:223-232.
- Linder, E** (1971) Fate of a kidney specific mesonephric antigen during the differentiation of the epididymis. Annals of the New York Academy of Science **177**:204-213.
- Lok, D and de Rooij, DG** (1983a) Spermatogonial multiplication in the Chinese hamster. I. Cell cycle properties and synchronization of differentiating spermatogonia. Cell and Tissue Kinetics **16**:7-18.
- Lok, D and de Rooij, DG** (1983b) Spermatogonial multiplication in the Chinese hamster. III. Labelling indices of undifferentiated spermatogonia throughout the cycle of the seminiferous epithelium. Cell and Tissue Kinetics **16**:31-40.

- Lok, D, Jansen, MT and de Rooij, DG** (1983) Spermatogonial multiplication in the Chinese hamster. II. Cell cycle properties of undifferentiated spermatogonia. Cell and Tissue Kinetics **16**:19-29.
- Lording, DW and de Kretser, DM** (1972) Comparative ultrastructural and histochemical studies of the interstitial cells of the rat testis during fetal and postnatal development. Journal of Reproduction and Fertility **29**:261-269.
- Louis, BG and Fritz, IB** (1979) Follicle-stimulating hormone and testosterone independently increase the production of androgen-binding protein by Sertoli cells in culture. Endocrinology **104**:454-460.
- Lue, YH, Sinha Hikim, AP, Leung, A, Baravarian, S, Wang, C and Swerdloff, RS** (1998) Stage-specific hormonal protection against heat-induced germ cell apoptosis in rat. Supplement to Journal of Andrology Vol. 19. Abstract 19, p 29.
- Luke, MC and Coffey, DS** (1994) The male accessory tissues. Structure, androgen action and physiology. In Physiology of Reproduction 2nd Ed. E Knobil and JD Neill Eds. Raven Press, New York. pp. 1435-1487.
- McCool, CJ** (1989) The cycle of the seminiferous epithelium in Bali cattle (*Bos sondaicus*). Journal of Reproduction and Fertility **87**:327-330.
- McCool, CJ, Entwistle, KW and Townsend, MP** (1989) The cycle of the seminiferous epithelium in the Australian swamp buffalo. Theriogenology **31**:399-417.
- McDonald, SW and Scothorne, RJ** (1988) A quantitative study of the effects of vasectomy on spermatogenesis in rats. Journal of Anatomy **159**:219-225.
- McGuckin, MA and Blackshaw, AW** (1987) Cycle of the seminiferous epithelium in the grey-headed fruit bat, *Pteropus poliocephalus*. Australian Journal of Biological Sciences **40**:203-210.
- Machado, CRS, Calixto, SL and Ladosky, W** (1982) Morphological and physiological factors involved in the contractility of the spermatic cord and ductus deferens of the opossum (*Didelphis albiventris*). Journal of Reproduction and Fertility **65**:275-280.
- McLaren, A, Simpson, E, Tomonari, K, Chandler, P and Hogg, H** (1984) Male sexual differentiation in mice lacking H-Y antigen. Nature **312**:552-555.
- Mann, T** (1964) The Biochemistry of Semen and of the Male Reproductive Tract. Methuen, London.
- Mann, T and Lutwak-Mann, C** (1981) Male Reproductive Function and Semen. Springer-Verlag, Berlin.
- Marsh, H, Heinsohn, GE and Glover, TD** (1984) Changes in the male reproductive organs of the dugong, *Dugong dugon* (Serenia: Dugondidae) with age and reproductive activity. Australian Journal of Zoology **32**:721-742.
- Marshall, GR and Plant, TM** (1996) Puberty occurring either spontaneously or induced precociously in rhesus monkey (*Macaca mulatta*) is associated with a marked proliferation of Sertoli cells. Biology of Reproduction **54**:1192-1199.

- Marshall, WA** (1978) Puberty. In Human Growth. Vol. 2. Postnatal Growth. F Falkner and JM Tanner Eds. Plenum Press, New York. pp. 141-181.
- Maruch, SM, Alves, HJ and Machado, CR** (1989) Sympathetic innervation of the reproductive organs of male opossum, *Didelphis albiventris* (Lund, 1841). Acta Anatomica **134**:257-262.
- Meachem, SJ, McLachlan, RI, de Kretser, DM, Robertson, DM and Wreford, NG** (1996) Neonatal exposure of rats to recombinant follicle stimulating hormone increases adult Sertoli and spermatogenic cell numbers. Biology of Reproduction **54**:36-44.
- Means, AR, Fakunding, JL, Huckins, C, Tindall, DJ and Vitale, R** (1976) Follicle-stimulating hormone, the Sertoli cell and spermatogenesis. Recent Progress in Hormone Research **32**:477-522.
- Meistrich, ML** (1975) Alteration of epididymal sperm transport and maturation in mice by oestrogen and testosterone. Nature **258**:145-147.
- Meistrich, ML** (1989) Histone and basic nuclear protein transections in mammalian spermatogenesis. In Histones and Other Basic Nuclear Proteins. LS Hnilica, GS Stein and JL Stein Eds. CRC Press, Boca Raton. pp. 165-182.
- Meistrich, ML** (1993) Nuclear morphogenesis during spermiogenesis. In Molecular Biology of the Male Reproductive System. D de Kretser Ed. Academic Press, San Diego. pp.67-97.
- Meistrich, ML, Eng, VWS and Loir, M** (1973) Temperature effects on the kinetics of spermatogenesis in the mouse. Cell and Tissue Kinetics **6**:379-393.
- Meistrich, ML, Trostle-Weige PK and Russell, LD** (1990) Abnormal manchette development in spermatids of *azh/azh* mutant mice. The American Journal of Anatomy **188**:74-86.
- Miething, A** (1998) The establishment of spermatogenesis in the seminiferous epithelium of the pubertal golden hamster (*Mesocricetus auratus*). Advances in Anatomy, Embryology and Cell Biology. Vol. 140. Springer, Berlin.
- Mintz, B** (1957) Germ cell origin and history in the mouse: genetic and histochemical evidence. The Anatomical Record **127**:335-336.
- Mittwoch, U** (1988) Ethnic differences in testis size: A possible link with the cytogenetics of true hemaphroditism. Human Reproduction **3**:445-449.
- Møller, AP** (1988) Testes size, ejaculate quality and sperm competition in birds. Biological Journal of the Linnean Society **33**:273-283.
- Møller, AP** (1989) Ejaculate quality, testes size and sperm production in mammals. Functional Ecology **3**:91-96.
- Monder, C and Shackleton, CHL** (1984) 11 β -Hydroxysteroid dehydrogenase: fact or fancy? Steroids **44**:383-417.

- Monder, C, Sakai, RR, Miroff, Y, Blanchard, DC and Blanchard, RJ** (1994a) Reciprocal changes in plasma corticosterone and testosterone in stressed male rats maintained in a visible burrow system: evidence for a mediating role of testicular 11 β -hydroxysteroid dehydrogenase. Endocrinology **134**:1193-1198.
- Monder, C, Miroff, Y, Marandici, A and Hardy, MP** (1994b) 11 β -Hydroxysteroid dehydrogenase alleviates glucocorticoid-mediated inhibition of steroidogenesis in rat Leydig cells. Endocrinology **134**:1199-1204.
- Monesi, V** (1965) Synthetic activities during spermatogenesis in the mouse. RNA and protein. Experimental Cell Research **39**:197-224.
- Moniem, KA and Glover, TD** (1972) Comparative histochemical localization of lysosomal enzymes in mammalian epididymides. Journal of Anatomy **111**:437-452.
- Moore, A, Ensrud, KM, White, TW, Frethem, CD and Hamilton, DW** (1994) Rat epididymis-specific sperm maturation antigens. I. Evidence that the 26 kD 4E9 antigen found on rat cauda epididymal sperm tail is derived from a protein secreted by the epididymis. Molecular Reproduction and Development **37**:181-194.
- Moore, HDM** (1990a) The development of sperm-egg recognition processes in mammals. Journal of Reproduction and Fertility Supplement **42**:71-78.
- Moore, HDM** (1990b) The epididymis. In Scientific Foundations of Urology. GD Chisholm and WD Fair Eds. Heinemann Medical, Oxford. pp. 399-410.
- Moore, HDM** (1992) Epididymal control of sperm maturation in mammals. Serono Symposia **94**:63-72.
- Moore, HDM** (1995) Post-testicular sperm maturation and transport in the excurrent ducts. In Gametes. The Spermatozoon. JG Grudzinskas and JL Yovich Eds. Cambridge University Press, Cambridge. pp 140-156.
- Moore, HDM** (1996) The influence of the epididymis on human and animal sperm maturation and storage. Human Reproduction **11**:103-110.
- Moore, HDM and Akhondi, MA** (1996) In vitro maturation of mammalian spermatozoa. Reviews of Reproduction **1**:54-60.
- Moore, HDM and Bedford, JM** (1979a) Short-term effects of androgen withdrawal on the structure of different epithelial cells in the rat epididymis. The Anatomical Record **193**:293-312.
- Moore, HDM and Bedford, JM** (1979b) The differential absorptive activity of epithelial cells of the rat epididymis before and after castration. The Anatomical Record **193**:313-328.
- Morales, C and Clermont, Y** (1993) Structural changes of the Sertoli cell during the cycle of the seminiferous epithelium. In The Sertoli Cell. LD Russell and MD Griswold Eds. Cache River Press, Clearwater. pp. 305-329.

- Morales, C and Hermo, L** (1983) Demonstration of fluid-phase endocytosis in epithelial cells of the male reproductive system by means of horseradish peroxidase-colloidal gold complex. Cell and Tissue Research **230**:503-510.
- Morales, C, Clermont, Y and Nadler, NJ** (1986) Cyclic endocytic activity and kinetics of lysosomes in Sertoli cells of the rat: A morphometric analysis. Biology of Reproduction **34**:207-218.
- Mori, H and Christensen, AK** (1980) Morphometric analysis of Leydig cells in the normal rat testis. Journal of Cell Biology **84**:340-354.
- Mori, H Shimizu, D, Takeda, A, Takioka, Y and Fukunishi, R** (1980) Stereological analysis of Leydig cells in normal guinea pig testis. Journal of Electron Microscopy **29**:8-21.
- Mori, H Shimizu, D, Fukunishi, R and Christensen, AK** (1982) Morphometric analysis of testicular Leydig cells in normal adult mice. The Anatomical Record **204**:333-339.
- Morrissey, BL and Breed, WG** (1982) Variation in external morphology of the glans penis of Australian rodents. Australian Journal of Zoology **30**:495-502.
- Muller, J and Skakkebaek, NE** (1983) Quantification of germ cells and seminiferous tubules by stereological examination of testicles from 50 boys who suffered from sudden death. International Journal of Andrology **6**:143-156.
- Muñoz, EM, Fogal, T, Dominguez, S, Scardapane, L, Guzman, J, Cavicchia, JC and Piezzi, RS** (1998) Stages of the cycle of the seminiferous epithelium of the viscacha (*Lagostomus maximus maximus*). The Anatomical Record **252**:8-16.
- Nagy, F** (1972) Cell division kinetics and DNA synthesis in the immature Sertoli cells of the rat testis. Journal of Reproduction and Fertility **28**:389-395.
- Nicander, L** (1957a) On the regional histology and cytochemistry of the ductus epididymidis in rabbits. Acta Morphologica Neerlando- Scandinavica **1**:99-118.
- Nicander, L** (1957b) Studies on the regional histology and cytochemistry of the ductus epididymidis in stallions, rams, and bulls. Acta Morphologica Neerlando- Scandinavica **1**:337-362.
- Nicander, L** (1970) On the morphological evidence of secretion and absorption in the epididymis. Morphological Aspects of Andrology **1**:121-124.
- Nicander, L and Glover, TD** (1973) Regional histology and fine structure of the epididymal duct in the golden hamster (*Mesocricetus auratus*). Journal of Anatomy **114**:347-364.
- Nicander, L and Malmquist, M** (1977) Ultrastructural observations suggesting merocrine secretion in the initial segment of the mammalian epididymis. Cell and Tissue Research **184**:487-490.
- Nicander, L and Ploen, L** (1979) Studies on regional fine structure and function in the rabbit epididymis. International Journal of Andrology **2**:463-481.

- Nielsen, EH (1976) The bulbourethral gland of the rat. Fine structure and histochemistry. Anatomischer Anzeiger **139**:254-263.
- Niemi, M (1965) The fine structure and histochemistry of the epithelial cells of the rat vas deferens. Acta Anatomica **60**:207-219.
- Niemi, M, Sharpe, RM and Brown, WRA (1986) Macrophages in the interstitial tissue of the rat testis. Cell and Tissue Research **243**:337-344.
- Nistal, M, Abaurrea, MA and Paniagua, R (1982) Morphological and histometrical study on the human Sertoli cell from birth to the onset of puberty. Journal of Anatomy **14**:351-363.
- Nistal, M and Paniagua, R (1984) Testicular and Epididymal Pathology. Thieme-Stratton, New York.
- Nistal, M, Santamaria, L and Paniagua, R (1984) Mast cells in the human testis and epididymis from birth to adulthood. Acta Anatomica **119**:155-160.
- Nogueira, JC, Ribeiro, MG and Campos, PA (1985) Histology and carbohydrate histochemistry of the prostate gland of the Brazilian four-eyed opossum (*Philander opossum*, Linnaeus, 1758). Anatomischer Anzeiger, Jena **159**:241-252.
- Noller, DW, Flickinger, CJ and Howards, SS (1977a) Duration of the cycle of the seminiferous epithelium in the guinea pig determined by tritiated thymidine autoradiography. Biology of Reproduction **17**:532-534.
- Noller, DW, Howards, SS and Flickinger, CJ (1977b) Duration of the seminiferous epithelial cycle in the mature guinea pig: influence of unilateral orchietomy. Fertility and Sterility **28**:998-1002.
- Oakberg, EF (1956a) A description of spermiogenesis in the mouse and its use in analysis of the cycle of the seminiferous epithelium and germ cell renewal. The American Journal of Anatomy **99**:391-413.
- Oakberg, EF (1956b) Duration of spermatogenesis in the mouse and timing of stages of the cycle of the seminiferous epithelium. The American Journal of Anatomy **99**:507-516.
- Oakberg, EF (1971) Spermatogonial stem cell renewal in the mouse. The Anatomical Record **169**:515-532.
- O'Donnell, McLachlan, RI, Wreford, NG and Robertson, DM (1994) Testosterone promotes the conversion of round spermatids between stages VII and VIII of the rat spermatogenic cycle. Endocrinology **135**:2608-2614.
- Okwun, OE, Igboeli, G, Ford, JJ, Lunstra, DD and Johnson, L (1996) Number and function of Sertoli cells, number and yield of spermatogonia, and daily sperm production in three breeds of boar. Journal of Reproduction and Fertility **107**:137-149.

- Olar, TT, Amann, RP and Pickett, BW** (1983) Relationships among testicular size, daily production and output of spermatozoa, and extragonadal spermatozoal reserves of the dog. Biology of Reproduction **29**:1114-1120.
- Olson, GE and Hinton, BT** (1985) Regional differences in luminal fluid polypeptides of the rat testis and epididymis revealed by two-dimensional gel electrophoresis. Journal of Andrology **6**:20-34.
- Orgebin-Crist, MC** (1962) Recherches experimentales sur la duree de passage des spermatozoides dans l'epididyme du taureau. Annales de Biologie Animale, Biochimie, Biophysique **2**:51-108.
- Orgebin-Crist, MC** (1965) Passage of spermatozoa labelled with thymidine-³H through the ductus epididymidis in the rabbit. Journal of Reproduction and Fertility **10**:241-251.
- Orgebin-Crist, MC** (1967) Maturation of spermatozoa in the rabbit epididymis. Fertilizing ability and embryonic mortality in does inseminated with epididymal spermatozoa. Annales de Biologie Animale, Biochimie et Biophysique **7**:373-389.
- Orgebin-Crist, MC** (1968) Gonadal and epididymal sperm reserves in the rabbit: estimation of the daily sperm production. Journal of Reproduction and Fertility **15**:15-25.
- Orgebin-Crist, MC** (1969) Studies on the function of the epididymis. Biology of Reproduction, Supplement **1**:155-175.
- Orgebin-Crist, MC and Fournier-Delpech, S** (1982) Evidence for maturational changes during epididymal transit. Journal of Andrology **3**:429-433.
- Orgebin-Crist, MC, Danzo, BJ and Davies, J** (1975) Endocrine control of the development and maintenance of sperm fertilising ability in the epididymis. . In Handbook of Physiology, Vol. V. Endocrinology. Section 7, Male Reproductive System. DW Hamilton and RO Greep Eds. American Physiological Society, Washington, D.C. pp. 319-338.
- Ortavant, R** (1956) Autoradiographie des cellules germinales du testicule de belier. Durée des phenomenes spermatogénétiques. Archives D'Anatomie Microscopique Morphologie Experimentale **45**:1-10.
- Ortavant, R** (1958) Le cycle spermatogénétique chez le belier. D.Sc. Thesis, University of Paris. Paris.
- Ortavant, R** (1959) Spermatogenesis and morphology of the spermatozoon. In Reproduction in Domestic Animals, Vol. 2. HH Cole and PT Cupps Eds. Academic Press, New York. pp. 1-50.
- Orth, JM** (1982) Proliferation of Sertoli cells in fetal and postnatal rats: A quantitative autoradiographic study. The Anatomical Record **203**:485-492.
- Orth, JM** (1984) The role of follicle stimulating hormone in controlling Sertoli cell proliferation in testes of fetal rats. Endocrinology **115**:1248-1255.

- Orth, JM and Christensen, AK** (1977) Localization of ^{125}I -labelled FSH in the testes of hypophysectomised rats by autoradiography at the light and electron microscopic levels. Endocrinology **101**:262-278.
- Orth, JM and Christensen, AK** (1978) Autoradiographic localization of specifically bound ^{125}I -labelled follicle stimulating hormone on spermatogonia of the rat testis. Endocrinology **103**:1944-1951.
- Orth, JM and Weisz, J** (1980) Development of 5- β hydroxysteroid dehydrogenase and glucose-6-phosphate dehydrogenase activity in Leydig cells of the fetal rat testis: A quantitative cytochemical study. Biology of Reproduction **22**:1201-1209.
- Orth, JM, Gunsalus, GL and Lamperti, AA** (1988) Evidence from Sertoli cell-depleted rats indicates that spermatid numbers in adults depends on the number of Sertoli cells produced during perinatal development. Endocrinology **122**:787-794.
- Orth, JM, Higginbotham, CA and Salisbury, RL** (1984) Hemicastration causes and testosterone prevents enhanced uptake of [^3H] thymidine by Sertoli cells in testes of immature rats. Biology of Reproduction **30**:263-270.
- Ortiz, E, Price, D, Williams-Ashman, HG and Banks, J** (1956) The influence of androgen on the male accessory reproductive glands of the guinea pig: studies on growth, histological structure and fructose and citric acid secretion. Endocrinology **59**:479-492.
- Osman, AM and El Azab, EA** (1974) Gonadal and epididymal sperm reserves in the camel, *Camelus dromedarius*. Journal of Reproduction and Fertility **38**:425-430.
- Osman, DI** (1978) On the ultrastructure of modified Sertoli cells in the terminal segment of the seminiferous tubules of the boar. Journal of Anatomy **127**:603-613.
- Osman, DI and Plöen, L** (1978) The mammalian tubuli recti: ultrastructural study. The Anatomical Record **192**:1-18.
- Osman, DI and Plöen, L** (1979) Fine structure of the modified Sertoli cells in the terminal segment of the seminiferous tubules of the bull, ram and goat. Animal Reproduction Science **2**:343-351.
- Oud, JL and de Rooij, DG** (1977) Spermatogenesis in the Chinese hamster The Anatomical Record **187**:113-124.
- Page, DC, Mosher, R, Simpson, EM, Fisher, EMC, Mardon, G, Pollack, J, McGillivry, B, de la Chapelle, A and Brown, LG** (1987) The sex-determining region of the human Y chromosome encodes a finger protein. Cell **51**:1091-1104.
- Palacios, J, Regadera, J, Nistal, M and Panigua, R** (1991) Apical mitochondria-rich cells in the human epididymis: An ultrastructural, enzymohistochemical and immunochemical study. The Anatomical Record **231**:82-88.
- Palmer, MS, Sinclair, AH, Berta, P, Ellis, NA, Goodfellow, PN, Abbas, NE and Fellous, M** (1989) Genetic evidence that ZFY is not the testis-determining factor. Nature **342**:937-939.

- Palombi, F, Farini, D, Salanova, M, De Grossi, S and Stefanini, M** (1992) Development and cytodifferentiation of peritubular myoid cells in the rat testis. The Anatomical Record **233**:32-40.
- Pang, SF, Chow, PH and Wong, TM** (1979) The role of the seminal vesicles, coagulating glands and prostate glands on the fertility and fecundity of mice. Journal of Reproduction and Fertility **56**:129-132.
- Paniagua, R, Codesal, J, Nistal, M, Rodriguez, MC and Santamaria, L** (1987a) Quantification of cell types throughout the cycle of the human seminiferous epithelium and their DNA content. Anatomy and Embryology **176**:225-230.
- Paniagua, R, Ragadera, J, Nistal, M and Abaurrea, MA** (1981) Histological, histochemical and ultrastructural variations along the length of the human vas deferens before and after puberty. Acta Anatomica **111**:190-203.
- Paniagua, R, Rodriguez, MC, Nistal, M, Fraile, B and Amat, P** (1987b) Changes in the lipid inclusion/Sertoli cell cytoplasm area ratio during the cycle of the human seminiferous epithelium. Journal of Reproduction and Fertility **80**:335-341.
- Paranko, J, Kallajoki, M, Pelliniemi, LJ, Lehto, VP and Virtanen, I** (1986) Transient coexpression of cytokeratin and vimentin in differentiating rat Sertoli cells. Developmental Biology **117**:35-44.
- Parvinen, M** (1982) Regulation of the seminiferous epithelium. Endocrine Review **3**:404-417.
- Parvinen, M** (1993) Cyclic function of Sertoli cells. In The Sertoli Cell. LD Russell and MD Griswold Eds. Cache River Press, Clearwater. pp. 331-347.
- Parvinen, M, Vihko, KK and Toppari, J** (1986) Cell interactions during the seminiferous epithelial cycle. International Review of Cytology **104**:105-119.
- Peirce, EJ and Breed, WG** (1987) Cytological organization of the seminiferous epithelium in the Australian rodents *Pseudomys australis* and *Notomys alexis*. Journal of Reproduction and Fertility **80**:91-103.
- Peirce, EJ and Breed, WG** (1989) Light microscopical structure of the excurrent ducts and distribution of spermatozoa in the Australian rodents *Pseudomys australis* and *Notomys alexis*. Journal of Anatomy **162**:195-213.
- Peirce, EJ and Breed, WG** (1990) Organization of testicular interstitial tissue of an Australian rodent, the spinifex hopping mouse, *Notomys alexis*. Cell and Tissue Research **260**:469-477.
- Peirce, EJ and Breed, WG** (1998) A pilot study to determine the validity of the optical disector method for cell quantitation in testes of Australian rodents. Australian Mammal Society 1998 Conference Program and Abstracts. A81. (Abstract)
- Pelletier, R-M and Byers, SW** (1992) The blood-testis barrier and Sertoli cell junctions: Structural considerations. Microscopy Research and Technique **20**:3-33.

- Pelliniemi, LJ and Niemi, M** (1969) Fine structure of the human foetal testis. Zeitschrift für Zellforschung und mikroskopische Anatomie **99**:507-522.
- Perey, B, Clermont, Y and Leblond, CP** (1961) The wave of the seminiferous epithelium in the rat. The American Journal of Anatomy **108**:47-77.
- Pineau, C, Sharpe, RM, Saunders, PTK, Gérard, N and Jégou, B** (1990) Regulation of Sertoli cell inhibin production and of inhibin α -subunit mRNA levels by specific germ cell types. Molecular and Cellular Endocrinology **72**:13-22.
- Pineau, C, Velez de la Calle, JF, Pinon-Lataillade, G and Jégou, B** (1989) Assessment of testicular function after acute and chronic irradiation: Further evidence for an influence of late spermatids on Sertoli cell function in the adult rat. Endocrinology **124**:2720-2728.
- Plöen, L** (1971) A scheme of rabbit spermateliosis based upon electron microscopical observations. Zeitschrift für Zellforschung und mikroskopische Anatomie **115**:553-564.
- Plöen, L, Ekwall, H and Afzelius, BA** (1979) Spermiogenesis and the spermatozoa of the European common shrew (*Sorex araneus* L.). Journal of Ultrastructural Research **68**:149-159.
- Pöllänen, P and Breed, WG** (1991) Transillumination patterns of seminiferous tubules in two species of Australian rodents, *Pseudomys australis* and *Notomys alexis*. Reproduction Fertility and Development **3**:303-312.
- Posalaky, Z, Meyer, R and McGinley, D** (1981) The effects of FSH on Sertoli cell junctions in vitro: A freeze fracture study. Journal of Ultrastructural Research **74**:241-254.
- Price, D, Mann, T and Lutwak-Mann, C** (1955) The stimulating effect of female hormones on the metabolic activity and histological structure of male rat accessory reproductive glands. The Anatomical Record **122**:363-380.
- Price, D and Williams-Ashman, HG** (1961) The accessory reproductive glands of mammals. In Sex and Internal Secretions 3rd Ed. Vol.1. WC Young Ed. Williams and Wilkins, Baltimore. pp. 366-448.
- Queiroz, GF and Nogueira, JC** (1992) Duration of the cycle of the seminiferous epithelium and quantitative histology of the testis of the South American white-belly opossum (*Didelphis albiventris*), Marsupialia. Reproduction Fertility and Development **4**:213-222.
- Raburn, DJ, Reinhart, AJ, Coquelin, A and Hutson, JC** (1993) Regulation of the macrophage population in postnatal rat testis. Journal of Reproductive Immunology **24**:139-151.
- Ramos, AS** (1979) Morphologic variations along the length of the monkey vas deferens. Archives of Andrology **3**:187-196.

- Ramos, AS and Dym, M (1977) Ultrastructure of the ductuli efferentes in monkeys. Biology of Reproduction 17:339-349.
- Rasweiler, IV JJ and Bedford, JM (1982) Biology of the scrotum. III. Effects of abdominal temperature upon the epithelial cells of the rat cauda epididymidis. Biology of Reproduction 26:691-705.
- Redi, CA (1986) Relative positions of the spermatogenic stages in the mouse testis: morphological evidences for their non-randomised adjacencies. Andrologia 18:25-32.
- Regaud, C (1901) Etudes sur la structure des tubes seminiferes et sur la spermatogenese chez les mammiferes. Archives d'Anatomie Microscopique et de Morphologie. 4:101-156, 231-380.
- Reid, BL and Cleland, KW (1957) The structure and function of the epididymis. 1. The histology of the rat epididymis. Australian Journal of Zoology 5:223-246.
- Reynolds, ES (1963) The use of lead citrate at high pH as an electron opaque stain in electron microscopy. Journal of Cell Biology 17:208-212.
- Ribble, DO and Millar, JS (1992) Intraspecific variation in testes size among northern populations of *Peromyscus*. Functional Ecology 6:455-459.
- Rich, KA, Bardin, CW, Gunsalus, GL and Mather, JP (1983) Age-dependent pattern of androgen binding protein secretion from rat Sertoli cells in primary culture. Endocrinology 113:2284-2293.
- Risbridger, GP, Robertson, DM, Drummond, AE, Hedger, MP, Clements, JA, Li, H and de Kretser, DM (1990) Interaction between the seminiferous tubules and Leydig cells of the testis. Reproduction, Fertility and Development 2:219-223.
- Ritzén, EM, Boitani, C, Parvinen, M, French, FS and Feldman, M (1982) Stage dependent secretion of ABP by rat seminiferous tubules. Molecular and Cellular Endocrinology 25:25-34.
- Robaire, B (1979) Effects of unilateral orchidectomy on rat epididymal Δ^4 -5 α -reductase and 3 α -hydroxysteroid dehydrogenase. Canadian Journal of Physiology and Pharmacology 57:998-1003.
- Robaire, B and Hermo, L (1988) Efferent ducts, epididymis and vas deferens: structure, functions, and their regulation. In The Physiology of Reproduction. E Knobil and J Neill Eds. Raven Press, New York. pp. 999-1080.
- Robaire, B and Viger, RS (1995) Regulation of epididymal epithelial cell functions. Biology of Reproduction 52:226-236.
- Robaire, B, Ewing, LL, Zirkin, BR and Irby, DC (1977) Steroid Δ^4 -5 α -reductase and 3 α -hydroxysteroid dehydrogenase in the rat epididymis. Endocrinology 101:1379-1390.

- Robb, GW, Amann, RP and Killian, GJ** (1978) Daily sperm production and epididymal sperm reserves of pubertal and adult rats. Journal of Reproduction and Fertility **54**:103-107.
- Roger, JC and Hughes, RL** (1973) Studies of the accessory glands of male marsupials. Australian Journal of Zoology **21**:302-320.
- Romer, AS and Parsons, TS** (1986) The Vertebrate Body. 6th Ed. Saunders, Fort Worth.
- Roosen-Runge, EC** (1951) Motions of the seminiferous tubules of rat and dog. The Anatomical Record **109**:413. (Abstract)
- Roosen-Runge, EC** (1952) Kinetics of spermatogenesis in mammals. Annals of the New York Academy of Sciences **55**:574-584.
- Roosen-Runge, EC** (1955a) Quantitative studies on spermatogenesis in the albino rat. III. Volume changes in the cells of the seminiferous tubules. The Anatomical Record **123**:385-398.
- Roosen-Runge, EC** (1955b) Untersuchungen über die Degeneration samenbildenden Zellen in der normalen Spermatogenese der Ratte. Zeitschrift für Zellforschung und mikroskopische Anatomie **41**:221-235.
- Roosen-Runge, EC** (1961a) Rudimental 'genital canals' of the gonad in rat embryos. Acta Anatomica **44**:1-11.
- Roosen-Runge, EC** (1961b) The rete testis in the albino rat: its structure, development and morphological significance. Acta Anatomica **45**:1-30.
- Roosen-Runge, EC** (1969) Comparative aspects of spermatogenesis. Biology of Reproduction Supplement **1**:24-39.
- Roosen-Runge, EC** (1973) Germinal cell loss in normal metazoan spermatogenesis. Journal of Reproduction and Fertility **35**:339-348.
- Roosen-Runge, EC** (1977) The Process of Spermatogenesis in Animals. Cambridge University Press, Cambridge.
- Roosen-Runge, EC and Anderson, D** (1959) The development of the interstitial cells in the testis of the albino rat. Acta Anatomica **37**:125-137.
- Roosen-Runge, EC and Giesel, LO** (1950) Quantitative studies on spermatogenesis in the albino rat. The American Journal of Anatomy **87**:1-30.
- Roosen-Runge, EC and Holstein, A-F** (1978) The human rete testis. Cell and Tissue Research **109**:409-433.
- Rosiepen, G, Weinbauer, GF, Schlatt, S, Berhe, HM and Nieschlag, E** (1994) Duration of the cycle of the seminiferous epithelium, estimated by the 5-bromodeoxyuridine technique, in laboratory and feral rats. Journal of Reproduction and Fertility **100**:299-306.
- Rosiepen, G, Chapin, RE and Weinbauer, GF** (1995) The duration of the cycle of the seminiferous epithelium is altered by administration of 2,5-hexanedione in the adult Sprague-Dawley rat. Journal of Andrology **16**:127-135.

- Ross, AD and Entwistle, KW** (1979) The effects of scrotal insulation on spermatozoal morphology and the rates of spermatogenesis and epididymal passage of spermatozoa in the bull. Theriogenology **11**:111-129.
- Ross, MH** (1967) The fine structure and development of the peritubular contractile cell component in the seminiferous tubules of the mouse. The American Journal of Anatomy **121**:523-558.
- Rowley, MJ and Heller, CG** (1971) Quantitation of the cells of the seminiferous epithelium of the human testis employing the Sertoli cell as a constant. Zeitschrift für Zellforschung und mikroskopische Anatomie **115**:461-472.
- Rowley, MJ, Berlin, JD and Heller, CG** (1971) The ultrastructure of four types of human spermatogonia. Zeitschrift für Zellforschung und mikroskopische Anatomie **112**:139-157.
- Rowley, MJ, Teshima, F and Heller, CG** (1970) Duration of transit through the human male ductular system. Fertility and Sterility **21**:390-396.
- Russell, LD** (1977a) Movement of spermatocytes from the basal to the adluminal compartment of the rat testis. The American Journal of Anatomy **148**:313-328.
- Russell, LD** (1977b) Observations on rat Sertoli ectoplasmic ('functional') specializations in their association with germ cells of the rat testis. Tissue and Cell **9**:475-498.
- Russell, LD** (1978) The blood-testis barrier and its formation relative to spermatocyte maturation in the adult rat: A lanthanum tracer study. The Anatomical Record **190**:99-112.
- Russell, LD** (1979a) Spermatid-Sertoli tubulobulbar complexes as devices for the elimination of cytoplasm from the head region of late spermatids of the rat. The Anatomical Record **194**:233-246.
- Russell, LD** (1979b) Further observations on tubulobulbar complexes formed by late spermatids and Sertoli cells in the rat testis. The Anatomical Record **194**:213-232.
- Russell, LD** (1993) Form, dimensions, and cytology of mammalian Sertoli cells. In The Sertoli Cell. LD Russell and MD Griswold Eds. Cache River Press, Clearwater. pp.1-37.
- Russell, LD** (1999) Sertoli cells: Overview. In Encyclopedia of Reproduction, Vol. 4. Academic Press, New York. pp. 381-387.
- Russell, LD and Brinster, RL** (1996) Ultrastructural observations of spermatogenesis following transplantation of rat testis cells onto mouse seminiferous tubules. Journal of Andrology **17**:615-627.
- Russell, LD and Clermont, Y** (1976) Anchoring device between Sertoli cells and late spermatids in rat seminiferous tubules. The Anatomical Record **185**:259-278.
- Russell, LD and Clermont, Y** (1977) Degeneration of germ cells in normal, hypophysectomized and hormone treated hypophysectomized rats. The Anatomical Record **187**:347-366.

- Russell, LD and Frank, B** (1978) Characterization of rat spermatocytes after plastic embedding. Archives of Andrology **1**:5-18.
- Russell, LD and Malone, JP** (1980) A study of Sertoli-spermatid tubulobulbar complexes in selected mammals. Tissue and Cell **12**:263-285.
- Russell, LD and Peterson, RN** (1984) Determination of the elongate spermatid-Sertoli cell ratio in various mammals. Journal of Reproduction and Fertility **70**:635-641.
- Russell, LD, Alger, LE and Nequin, LG** (1987) Hormonal control of pubertal spermatogenesis. Endocrinology **120**:1615-1632.
- Russell, LD, Bartke, A and Goh, JC** (1989a) Postnatal development of the Sertoli cell barrier, tubule lumen, and cytoskeleton of Sertoli and myoid cells in the rat, and their relationship to tubular fluid secretion and flow. The American Journal of Anatomy **184**:179-189.
- Russell, LD, Ettl, RA, Sinha Hikim, AP and Clegg, ED** (1990a) Histological and Histopathological Evaluation of the Testis. Cache River Press, Clearwater.
- Russell, LD, Gardner, RJ and Weber, JE** (1986) Reconstruction of a type-B configuration monkey Sertoli cell: size, shape, and configurational and specialized cell-to-cell relationships. The American Journal of Anatomy **175**:73-90.
- Russell, LD, Ren, HP, Sinha Hikim, I, Schulze, W and Sinha Hikim, AP** (1990b) A comparative study in twelve mammalian species of volume densities, volumes, and numerical densities of selected testis components, emphasizing those related to the Sertoli cell. The American Journal of Anatomy **188**:21-30.
- Russell, LD, Russell, JA, MacGregor, GR and Meistrich, ML** (1991) Linkage of manchette microtubules to the nuclear envelope and observations of the role of the manchette in nuclear shaping during spermiogenesis in rodents. The American Journal of Anatomy **192**:97-120.
- Russell, LD, Saxena, NK and Turner, T** (1989b) Cytoskeletal involvement in spermiation and sperm transport. Tissue and Cell **21**:361-379.
- Sadler, TW** (1985) Langman's Medical Embryology, 5th Ed. Williams and Wilkins, Baltimore.
- Saithoh, K, Terada, T and Hatakeyama, S** (1990) A morphological study of the efferent ducts of the human epididymis. International Journal of Andrology **13**:369-376.
- Sakai, KK, Hymson, DL and Shapiro, R** (1979) The effects of adenosine and adenine nucleotides on the guinea pig vas deferens: Evidence for the existence of purinergic receptors. Life Science **24**:1299-1308.
- Salim, B and Entwistle, KW** (1982) Duration of the seminiferous epithelial cycle in hybrid *Bos indicus* x *Bos taurus* bulls. Journal of Reproduction and Fertility **66**:729-734.

- Sapsford, CS, Rae, CA and Cleland, KW** (1969) The fate of residual bodies and degenerating germ cells and the lipid cycle in Sertoli cells in the bandicoot (*Perameles nasuta*). Australian Journal of Zoology **17**:195-292.
- Sar, M, Lubahn, DB, French, FS and Wilson, EM** (1990) Immunohistochemical localisation of the androgen receptor in rat and human tissues. Endocrinology **127**:3180-3186.
- Sar, M, Hall, SH, Wilson, EM and French, FS** (1993) Androgen regulation of Sertoli cells. In The Sertoli Cell. LD Russell and MD Griswold Eds. Cache River Press, Clearwater. pp. 509-516.
- Sarich, VC** (1985) Rodent macromolecular systematics. In Evolutionary Relationships Among Rodents. A Multidisciplinary Approach. WP Luckett and JL Hartenberger Eds. Plenum Press, New York. pp. 423-452.
- Schlatt, S, de Kretser, DM and Hedger, MP** (1999) Mitosis of resident macrophages in the adult rat testis. Journal of Reproduction and Fertility **116**:223-228.
- Schoysman, R and Bedford, JM** (1986) The role of the human epididymis in sperm maturation and sperm storage as reflected in the consequences of epididymo-vasostomy. Fertility and Sterility **46**:293-299.
- Schuler, HM and Gier, HT** (1976) Duration of the cycle of the seminiferous epithelium in the prairie vole (*Microtus ochrogaster ochrogaster*). Journal of Experimental Zoology **197**:1-12.
- Schultz, AH** (1938) The relative weight of the testes in primates. The Anatomical Record **72**:387-394.
- Schulze, C** (1974) On the morphology of the human Sertoli cell. Cell and Tissue Research **153**:339-355.
- Schulze, W and Rehder, U** (1984) Organization and morphogenesis of the human seminiferous epithelium. Cell and Tissue Research **237**:395-407.
- Schulze, W, Riemer, M, Rehder, U and Hohne, KH** (1986) Computer-aided three-dimensional reconstructions of the arrangement of primary spermatocytes in human seminiferous tubules. Cell and Tissue Research **244**:1-8.
- Serre, V and Robaire, B** (1998) Segment-specific morphological changes in aging brown Norway rat epididymis. Biology of Reproduction **58**:497-513.
- Sertoli, E** (1865) Dell'esistenza di particolari cellule ramificate nei canalicoli seminiferi dell'testicolo umano. Morgagni **7**:31-39.
[English translation: On the existence of special branched cells in the seminiferous tubules of the human testis. In Male Reproduction BP Setchell Ed. Van Nostrand Reinhold, New York. pp. 55-63.]
- Setchell, BP** (1977) Reproduction in male Marsupials. In The Biology of Marsupials. B Stonehouse and D Gilmore Eds. Macmillan, London. pp. 411-457.
- Setchell, BP** (1978) The Mammalian Testis. Paul Elek, London.

- Setchell, BP** (1982) Spermatogenesis and spermatozoa. In Reproduction in Mammals. Vol. 1. Germ Cells and Fertilization. 2nd Ed. CR Austin and RV Short Eds. Cambridge University Press Cambridge. pp. 63-101.
- Setchell, BP** Ed (1984) Male Reproduction. Van Nostrand Reinhold, New York.
- Setchell, BP** (1998) The Parkes lecture. Heat and the testis. Journal of Reproduction and Fertility **114**:179-194.
- Setchell, BP** (1991) Male reproductive organs and semen. In Reproduction in Domestic Animals. 4th Ed. PT Cupps Ed. Academic Press, San Diego. pp. 221-229.
- Setchell, BP and Carrick, FN** (1973) Spermatogenesis in some Australian marsupials. Australian Journal of Zoology **21**:491-499.
- Setchell, BP and Cox, JE** (1982) Secretion of free and conjugated steroids by the horse testis into lymph and venous blood. Journal of Reproduction and Fertility Supplement **32**:123-127.
- Setchell, BP, Laurie, MS, Flint, APF and Heap, RB** (1983) Transport of free and conjugated steroids from the boar testis in lymph, venous blood and rete testis fluid. Journal of Endocrinology **96**:127-136.
- Setchell, BP, Maddocks, S and Brooks, DE** (1994) Anatomy, vasculature, innervation and fluids of the male reproductive tract. In Physiology of Reproduction 2nd Ed. E Knobil and JD Neill Eds. Raven Press, New York. pp. 1063-1176.
- Setchell, BP, Pöllänen, P and Zupp, JL** (1988) Development of the blood-testis barrier and changes in vascular permeability at puberty in rats. International Journal of Andrology **11**:225-233.
- Setchell, BP, Sanchez-Partida, LG and Chairussyuhur, A** (1993) Epididymal constituents and related substances in the storage of spermatozoa: a review. Reproduction Fertility and Development **5**:601-612.
- Setiadi, D, Lin, M and Rodger, JC** (1997) Post-testicular development of spermatozoa of the tammar wallaby (*Macropus eugenii*). Journal of Anatomy **190**:275-288.
- Sharma, AK and Gupta, RC** (1980) Duration of seminiferous epithelial cycle in buffalo bulls (*Bubalus bubalis*). Animal Reproduction Science **3**:217-224.
- Sharpe, RM** (1994) Regulation of Spermatogenesis. In The Physiology of Reproduction. 2nd Ed. E Knobil, JD Neill Eds. Raven Press, New York. pp. 1363-1434.
- Sharpe, RM, Donachie, K and Cooper, I** (1988) Re-evaluation of the intratesticular level of testosterone required for quantitative maintenance of spermatogenesis in the rat. Journal of Endocrinology **117**:19-26.
- Sharpe, RM, Maddocks, S, Millar, M, Saunders, PTK, Kerr, JB and McKinnell, C** (1992) Testosterone and spermatogenesis: Identification of stage-dependent, androgen-regulated proteins secreted by adult rat seminiferous tubules. Journal of Andrology **13**:172-184.

- Shaver, SL** (1953) X-irradiation injury and repair in the germinal epithelium of male rats. I. Injury and repair in adult rats. The American Journal of Anatomy **92**:391-431.
- Shire, JGM and Bartke, A** (1972) Strain differences in testicular weight and spermatogenesis with special reference to C57BL/10J and DBA/2J mice. Journal of Endocrinology **55**:163-171.
- Short, RV** (1977) Sexual selection and the descent of man. In Reproduction and Evolution. JH Calaby and CH Tindale-Biscoe Eds. Australian Academy of Science, Canberra. pp. 3-19.
- Short, RV** (1979) Sexual selection and its component parts, somatic and genital selection, as illustrated by man and the great apes. Advances in the Study of Behaviour **9**:131-158.
- Short, RV** (1984) Testis size, ovulation rate and breast cancer. In One Medicine. OA Ryder and ML Bird Eds. Springer-Verlag, Berlin. pp 32-44.
- Short, RV** (1997) The testis: the witness of the mating system, the site of mutation and the engine of desire. Acta Paediatrica Supplement **422**:3-7.
- Silber, SJ** (1988) Pregnancy caused by sperm from vasa efferentia. Fertility and Sterility **49**:373-375.
- Silber, SJ** (1989) Apparent fertility of human spermatozoa from the caput epididymidis. Journal of Andrology **10**:263-269.
- Silber, SJ, Balmaceda, J, Borrero, C, Ord, T and Asch, R** (1988) Pregnancy with sperm aspiration from the proximal head of the epididymis: a new treatment for congenital absence of the vas deferens. Fertility and Sterility **50**:525-528.
- Simorangkir, DR, de Kretser, DM and Wreford, NG** (1995) Increased numbers of Sertoli and germ cells in adult rat testes induced by synergistic action of transient neonatal hypothyroidism and neonatal hemicastration. Journal of Reproduction and Fertility **104**:207-213.
- Simpson, GG** (1945) The principles of classification and a classification of mammals. Bulletin of the American Museum of Natural History **85**:1-350.
- Simpson, GG** (1961) Historical zoogeography of Australian mammals. Evolution **15**:431-446.
- Sinclair, AH, Berta, P, Palmer, MS, Hawkins, JR, Griffiths, BL, Smith, MJ, Foster, JW, Frischauf, A-M, Lovell-Badge, R and Goodfellow, PN** (1990) A gene from the human sex-determining region encodes a protein with a homology to a conserved DNA-binding motif. Nature **346**:240-244.
- Singh, J and Handelsman, DJ** (1996) Neonatal administration of FSH increases Sertoli cell numbers and spermatogenesis in gonadotropin-deficient (*hpg*) mice. Journal of Endocrinology **151**:37-48.

- Sinha Hikim, AP, and Swerdloff, RS** (1993) Temporal and stage-specific changes in spermatogenesis of rat after gonadotropin deprivation by a potent gonadotropin-releasing hormone antagonist treatment. Endocrinology **133**:2161-2170.
- Sinha Hikim, AP, Amador, A, Klemcke, H, Bartke, A and Russell, LD** (1989) Correlative morphology and endocrinology of Sertoli cells in hamster testes in active and inactive states of spermatogenesis. Endocrinology **125**:1829-1843.
- Sinha Hikim, AP, Maiti, BR and Ghosh, A** (1985) Spermatogenesis in the bandicoot rat. I. Duration of the cycle of the seminiferous epithelium. Archives of Andrology **14**:151-154.
- Sinha Hikim, AP, Rajavashisth, TB, Sinha Hikim, I, Lue, Y, Bonavera, JKJ, Leung, A, Wang, C and Swerdloff, RS** (1997) Significance of apoptosis in the temporal and stage-specific loss of germ cells in the adult rat after gonadotropin deprivation. Biology of Reproduction **57**:1193-1201.
- Sinha Hikim, AP, Wang, C, Leung, A and Swerdloff, RS** (1995) Involvement of apoptosis in the induction of germ cell degeneration in adult rats after gonadotropin-releasing hormone antagonist treatment. Endocrinology **136**:2770-2775.
- Sinowatz, F and Amselgruber, W** (1986) Postnatal development of bovine Sertoli cells. Anatomy and Embryology **174**:413-423.
- Sinowatz, F and Amselgruber, W** (1988) Ultrastructure of sustentacular (Sertoli) cells in the bovine testis. Acta Anatomica **133**:274-281.
- Sirlin, JL and Edwards, RG** (1955) The labelling of mouse sperm by adenine-8-C¹⁴. Experimental Cell Research **9**:596-599.
- Sirlin, JL and Edwards, RG** (1958) The labelling of mammalian spermatozoa with radioactive tracers. The Journal of Experimental Zoology **137**:363-388.
- Skakkebaek, NE and Heller, CG** (1973) Quantification of human seminiferous epithelium. I. Histological studies in twenty-one fertile men with normal chromosome complements. Journal of Reproduction and Fertility **32**:379-389.
- Skakkebaek, NE, Bryant, JI and Philip, J** (1973a) Studies on meiotic chromosomes in infertile men and controls with normal karyotypes. Journal of Reproduction and Fertility **35**:23-34.
- Skakkebaek, NE, Hultén, M, Jacobsen, P and Mikkelsen, M** (1973b) Quantification of human seminiferous epithelium. II. Histological studies in eight 47,XXY men. Journal of Reproduction and Fertility **32**:391-401.
- Skinner, MK and Fritz, IB** (1985) Testicular peritubular cells secrete a protein under androgen control that modulates Sertoli cell functions. Proceedings of the National Academy of Sciences **82**:114-118.
- Skinner, MK, Takacs, K and Coffey, RJ** (1989) Transforming growth factor- a gene expression and action in the seminiferous tubule: peritubular cell-Sertoli cell interactions. Endocrinology **124**:845-854.

- Skinner, MK, Tung, PS and Fritz, IB** (1985) Cooperativity between Sertoli cells and testicular peritubular cells in the production and deposition of extracellular matrix components. Journal of Cell Biology **100**:1941-1947.
- Smith, CA, Hartman, TD and Moore, HDM** (1986) A determinant of M_r 34000 expressed by hamster epididymal epithelium binds specifically to spermatozoa in co-culture. Journal of Reproduction and Fertility **78**:337-348.
- Solari, AJ and Tres, L** (1967) The ultrastructure of the human sex vesicle. Chromosoma **22**:16-31.
- Solari, AJ and Fritz, IB** (1978) The ultrastructure of immature Sertoli cells. Maturation-like changes during culture and the maintenance of mitotic potentiality. Biology of Reproduction **18**:329-345.
- Soranzo, L, Dadoune, J-P and Fain-Maurel, MA** (1982) La segmentation du canal epididymaire chez la souris: etude ultrastructurale. Reproduction, Nutrition, Developpement **22**:999-1012.
- Sprando, RL and Russell, LD** (1987) Comparative study of cytoplasmic elimination in spermatids of selected mammalian species. The American Journal of Anatomy **178**:72-80.
- Stalker, A, Hermo, L and Antakly, T** (1989) Covalent affinity labelling, radioautography, and immunocytochemistry localise the glucocorticoid receptor in rat testicular Leydig cells. The American Journal of Anatomy **186**:369-377.
- Steinberger, A and Steinberger, E** (1971) Replication pattern of Sertoli cells in maturing rat testis *in vivo* and in organ culture. Biology of Reproduction **4**:84-87.
- Steinberger, A and Steinberger, E** (1976) Secretion of a FSH-inhibiting factor by cultured Sertoli cells. Endocrinology **99**:918-921.
- Steinberger, A and Steinberger, E** (1977) The Sertoli cell. In The Testis Vol 4. AD Johnson and WR Gomes Eds. Academic Press, New York. pp. 371-399.
- Steinberger, E and Steinberger, A** (1975) Spermatogenic function of the testis. In Handbook of Physiology, Vol. V. Endocrinology. Section 7, Male Reproductive System. RO Greep and EB Astwood Eds. American Physiological Society, Washington, DC. pp. 1-19.
- Stoffel, MH and Freiss, AE** (1994) Morphological characteristics of boar efferent ductules and epididymal duct. Microscopy Research and Technique **29**:411-431.
- Strahan, R** (1995) The Mammals of Australia. Australian Museum/Reed Books, Chatswood.
- Sun, EL and Flickinger, CJ** (1980) Morphological characteristics of cells with apical nuclei in the initial segment of the adult rat epididymis. The Anatomical Record **196**:285-293.

- Suttle, JM, Moore, HDM, Peirce, EJ and Breed, WG** (1988) Quantitative studies on variation in sperm head morphology of the hopping mouse, *Notomys alexis*. The Journal of Experimental Zoology **247**:166-171.
- Suzuki, F and Racey, PA** (1976) Fine structural changes in the epididymal epithelium of moles (*Talpa europaea*) throughout the year. Journal of Reproduction and Fertility **47**:47-54.
- Suzuki, F and Racey, PA** (1984) Light and electron microscopical observations on the male excurrent duct system of the common shrew (*Sorex araneus*). Journal of Reproduction and Fertility **70**:419-428.
- Swierstra, EE** (1966) Structural composition of Shorthorn bull testes and daily spermatozoa production as determined by quantitative testicular histology. Canadian Journal of Animal Science **46**:107-119.
- Swierstra, EE** (1968a) Cytology and duration of the cycle of the seminiferous epithelium of the boar; duration of spermatozoan transit through the epididymis. The Anatomical Record **161**:171-186.
- Swierstra, EE** (1968b) A comparison of spermatozoa production and spermatozoa output of Yorkshire and Lacombe boars. Journal of Reproduction and Fertility **17**:459-469.
- Swierstra, EE** (1971) Sperm production of boars as measured from epididymal sperm reserves and quantitative testicular histology. Journal of Reproduction and Fertility **27**:91-99.
- Swierstra, EE and Foote, RH** (1963) Cytology and kinetics of spermatogenesis in the rabbit. Journal of Reproduction and Fertility **5**:309-322.
- Swierstra, EE and Foote, RH** (1965) Duration of spermatogenesis and spermatozoan transport in the rabbit based on cytological changes, DNA synthesis and labelling with tritiated thymidine. The American Journal of Anatomy **116**:401-412.
- Swierstra, EE, Gebauer, MR and Pickett, BW** (1974) Reproductive physiology of the stallion. I. Spermatogenesis and testicular composition. Journal of Reproduction and Fertility **40**:113-123.
- Syntin, P, Dacheaux, F, Druart, X, Gatti, J-L, Okamura, N and Dacheaux, J-L** (1996) Characterization and identification of proteins secreted in the various regions of the adult boar epididymis. Biology of Reproduction **55**:956-974.
- Takano, H** (1980) Qualitative and quantitative histology and histogenesis of the mouse epididymis, with special emphasis on the regional difference. Acta Anatomica Nipponica **55**:573-587.
- Tauber, PF, Zaneveld, LJD, Propping, D and Schumacher, GFB** (1975) Components of human split ejaculate. Journal of Reproduction and Fertility **43**:249-267.
- Temple-Smith, PD** (1994) Comparative structure and function of marsupial spermatozoa. Reproduction, Fertility and Development **6**:421-435.

- Temple-Smith, PD, and Bedford, JM** (1976) The features of sperm maturation in the epididymis of a marsupial, the brushtailed possum, *Trichosurus vulpecula*. The American Journal of Anatomy **147**:471-500.
- Temple-Smith, PD, Southwick, GJ, Yates, CA, Trounson, AO and deKretser, DM** (1985) Human pregnancy by *in vitro* fertilisation (IVF) using sperm aspirated from the epididymis. Journal of In Vitro Fertilization and Embryo Transfer **2**:199-222.
- Temple-Smith, PD, Southwick, GJ, Herrera Castaneda, E, Hamer, J and McClatchey, M** (1989) Surgical manipulation of the epididymis: an experimental approach to sperm maturation. In Perspectives in Andrology. Vol. **63**. M Serio Ed. Serono Symposia Publications, Raven Press, New York. pp. 281-290.
- Temple-Smith, PD, Zheng, SS, Kadioglu, T and Southwick, GJ** (1998) Development and use of surgical procedures to bypass selected regions of the mammalian epididymis: effects on sperm maturation. Journal of Reproduction and Fertility Supplement **53**:183-195.
- Tezón, JC, Ramella, E, Cameo, MS, Vazquez, MH, and Blaquier, JA** (1985) Immunochemical localization of secretory antigens in the human epididymis and their association with spermatozoa. Biology of Reproduction **32**:591-597.
- Thaler, CD and Cardullo, RA** (1995) The mammalian sperm surface: molecular and cellular aspects. In Cambridge Reviews in Human Reproduction. Gametes. The Spermatozoon. JG Grudzinskas and JL Yovich Eds. Cambridge University Press, Cambridge. pp. 20-44.
- Thomas, TS, Reynolds, AB and Oliphant, G** (1984) Evaluation of the site of synthesis of rabbit sperm acrosome stabilizing factor using immunocytochemical and metabolic labelling techniques. Biology of Reproduction **30**:693-705.
- Thomas, TS, Wilson, LS, Reynolds, AB and Oliphant, G** (1986) Chemical and physical characteristics of the rabbit sperm acrosome stabilizing factor. Biology of Reproduction **35**:691-703.
- Tindall, DJ, Millar, DA and Means, AR** (1977) Characterisation of androgen receptor in Sertoli cell-enriched testis. Endocrinology **101**:13-23.
- Tindall, DJ, Vitale, R and Means, AR** (1975) Androgen binding protein as a biochemical marker of formation of the blood-testis barrier. Endocrinology **97**:636-648.
- Torres, CN, Godinho, HP and Setchell, BP** (1981) Frequency and duration of the stages of the cycle of the seminiferous epithelium of the nine-banded armadillo (*Dasypus novemcinctus*). Journal of Reproduction and Fertility **61**:335-340.
- Tung, PS and Fritz, IB** (1980) Interactions of Sertoli cells with myoid cells *in vitro*. Biology of Reproduction **23**:207-217.

- Tulsiani, DRP, Skudlarek, MD, Holland, MK and Orgebin-Crist, MC** (1993) Glycosylation of rat sperm plasma membrane during epididymal maturation. Biology of Reproduction **48**:417-428.
- Turner, TT** (1979) On the epididymis and its function. Investigative Urology **16**:311-319.
- Turner, TT** (1991) Spermatozoa are exposed to a complex microenvironment as they traverse the epididymis. Annals of the New York Academy of Science **637**:364-383.
- Turner, TT** (1995) On the epididymis and its role in the development of the fertile ejaculate. Journal of Andrology **16**:292-298.
- Turner, TT and Reich, GW** (1985) Cauda epididymal sperm motility: A comparison among five species. Biology of Reproduction **32**:120-128.
- Turner, TT, Hartmann, PK and Howards, SS** (1977) In vivo sodium, potassium, and sperm concentrations in the rat epididymis. Fertility and Sterility **28**:191-194.
- Turner, TT, Plesums, JL and Cabot, CL** (1979) Luminal fluid proteins of the male rat reproductive tract. Biology of Reproduction **21**:883-890.
- Tutin, CEG** (1980) Reproductive behaviour of wild chimpanzees in the Gombe National Park, Tanzania. Journal of Reproduction and Fertility Supplement **28**:43-57.
- Usselman, MC and Cone, RA** (1993) Rat sperm are mechanically immobilized in the cauda epididymis by 'immobilin' a high molecular weight glycoprotein. Biology of Reproduction **29**:1241-1253.
- Utakoji, T** (1966) Chronology of nucleic acid synthesis in meiosis of the male Chinese hamster. Experimental Cell Research **42**:585-596.
- Van Alphen, MAA, van de Kant, HJG and de Rooij, DG** (1988) Follicle-stimulating hormone stimulates spermatogenesis in the adult monkey. Endocrinology **123**:1449-1455.
- Van der Meer, Y, Huiskamp, R, Davids, JAG, van der Tweel, I and de Rooij, DG** (1992) The sensitivity of quiescent and proliferating spermatogonial stem cells to X irradiation. Radiation Research **130**:289-295.
- Van der Meer, Y, Huiskamp, R, Davids, JAG, van der Tweel, I and de Rooij, DG** (1992) The sensitivity to X rays of mouse spermatogonia that are committed to differentiate and of differentiating spermatogonia. Radiation Research **130**:296-302.
- van Dissel-Emiliani, FM, Grootenhuis, AJ, de Jong, FH and de Rooij, DG** (1989) Inhibin reduces spermatogonial numbers in testes of adult mice and Chinese hamsters. Endocrinology **125**:1898-1903.
- van Haaster, LH and de Rooij, DG** (1993) Spermatogenesis is accelerated in the immature Djungarian and Chinese hamster and rat. Biology of Reproduction **49**:1229-1235.
- van Haaster, LH, de Jong, FH, Docter, R and de Rooij, DG** (1992) The effect of hypothyroidism on Sertoli cell proliferation and differentiation and hormone levels during testicular development in the rat. Endocrinology **131**:1574-1576.

- van Haaster, LH, de Jong, FH, Docter, R and de Rooij, DG** (1993) High neonatal triiodothyronine levels reduce the period of Sertoli cell proliferation and accelerate tubular lumen formation in the rat testis, and increase serum inhibin levels. Endocrinology **133**:755-760.
- van Straaten, HWM and Wensing, CJG** (1977) Histomorphometric aspects of testicular morphogenesis in the pig. Biology of Reproduction **17**:467-472.
- van Vorstenbosch, CJAHV, Spek, E, Colenbrander, B and Wensing, CJG** (1984) Sertoli cell development of pig testis in the fetal and neonatal period. Biology of Reproduction **31**:565-577.
- Vaughan, TA** (1986) Mammalogy 3rd Ed. Saunders, Philadelphia.
- Veeramachaneni, DNR, Amann, RP, Palmer, JS and Hinton, BT** (1990) Proteins in luminal fluid of the ram excurrent ducts: Changes in composition and evidence for differential endocytosis. Journal of Andrology **11**:140-154.
- Vergouwen, RPF, Jacobs, SGPM, Huiskamp, R, Davids, JAG and de Rooij, DG** (1991) Proliferative activity of gonocytes, Sertoli cells and interstitial cells during testicular development in mice. Journal of Reproduction and Fertility **39**:233-243.
- Vilar, O, Perez del Cerro, MI and Mancini, RE** (1962) The Sertoli cell as a 'bridge cell' between the basal membrane and the germinal cells. Experimental Cell Research **27**:158-161.
- Viotto, MJ, Orsi, AM, Mello Dias, S and Newmann, HK** (1991) Structure of the rete testis of the cat (*Felis domestica*, L). Anatomischer Anzeiger **172**:341-349.
- Vitale, R, Fawcett, DW and Dym, M** (1973) The normal development of the blood-testis barrier and the effects of clomiphene and oestrogen treatment. The Anatomical Record **176**:333-344.
- Vogel, DL, Gunsalus, GL, Bercu, BB, Musto, NA and Bardin, CW** (1983) Sertoli cell maturation is impaired by neonatal passive immunisation with antiserum to luteinising hormone-releasing hormone. Endocrinology **112**:1115-1121.
- Vogl, AW, Pfeiffer, DC, Redenbach, DM and Grove, BD** (1993) Sertoli cell cytoskeleton. In The Sertoli Cell. LD Russell and MD Griswold Eds. Cache River Press, Clearwater. pp. 39-86.
- Vogl, AW, Soucy, LJ and Lew, GJ** (1985) Distribution of actin in isolated seminiferous epithelia and denuded tubule walls of the rat. The Anatomical Record **213**:63-71.
- von Ebner, V** (1871) Untersuchungen über den Bau der Samencanälchen und die Entwicklung der Spermatozoiden bei den Säugethieren und beim Menschen. In Untersuchungen aus dem Institute für Physiologie und Histologie Leipzig. pp. 200-236.
- von Ebner, V** (1888) Zur Spermatogenese bei den Säugethieren. Archiv für Mikroskopische Anatomie und Entwicklungsmechanik **31**:236-292.

- Vornberger, W, Prins, G, Musto, NA and Suarez Quian CA (1994) Androgen receptor distribution in rat testis: new implications for androgen regulation of spermatogenesis. Endocrinology **134**:2307-2316.
- Vreeburg, JMT, Holland, MK, Cornwall, GA and Orgebin-Crist, MC (1990) Secretion and transport of mouse epididymal proteins after injection of ³⁵S-methionine. Biology of Reproduction **43**:113-120.
- Vreeburg, JMT, Holland, MK and Orgebin-Crist, MC (1992) Binding of epididymal proteins to rat spermatozoa *in vivo*. Biology of Reproduction **47**:588-597.
- Waites, GMH and Ortavant, R (1968) Effets précoces d'une brève élévation de la température testiculaire sur la spermatogénèse du belier. Annales de Biologie Animale, Biochimie et Biophysique **8**:323-331.
- Wang, J, Wreford, NGM, Lan, HY, Atkins, R and Hedger, MP (1994) Leukocyte populations of the adult rat testis following removal of the Leydig cells by treatment with ethane dimethane sulfonate and subcutaneous testosterone implants. Biology of Reproduction **51**:551-561.
- Wang, YC and Tse, MKW (1981) Fine structural and functional study of the prostatic complex of the guinea pig. Acta anatomica **109**:209-217.
- Wang, YF and Holstein, AF (1983) Intraepithelial lymphocytes and macrophages in the human epididymis. Cell and Tissue Research **233**:517-521.
- Wang, ZX, Wreford, NGM and de Kretser, DM (1989) Determination of Sertoli cell numbers in the developing rat testis by stereological methods. International Journal of Andrology **12**:58-64.
- Warren, D, Huhtaniemi, I, Tapanainen, J, Dufau, M and Catt, K (1984) Ontogeny of gonadotrophin receptors in the fetal and neonatal rat testis. Endocrinology **114**:470-476.
- Wartenberg, H (1989) Differentiation and development of the testis. In The Testis 2nd Ed. HG Burger and DM de Kretser Eds. Raven Press, New York. pp. 67-118.
- Watts, CHS and Aslin, H (1974) Notes on the small mammals of north-eastern South Australia and south-western Queensland. Transactions of the Royal Society of South Australia **98**:61-70.
- Watts, CHS and Aslin, H (1981) The Rodents of Australia. Angus and Robertson, Sydney.
- Watts, CHS and Baverstock, PR (1995) Evolution in the Murinae (Rodentia) assessed by microcomplement fixation of albumin. Australian Journal of Zoology **43**:105-118.
- Watts, CHS, Baverstock, PR, Birrell, J and Krieg, M (1992) Phylogeny of the Australian rodents (Muridae): a molecular approach using microcomplement fixation of albumin. Australian Journal of Zoology **40**:81-90.

- Weber, JE, Russell, LD, Wong, V and Peterson, RN** (1983) Three-dimensional reconstruction of a rat stage V Sertoli cell: II. Morphometry of Sertoli-Sertoli and Sertoli-germ cell relationships. The American Journal of Anatomy **167**:163-179.
- Weinbauer, GR and Nieschlag, E** (1991) Peptide and steroid regulation of spermatogenesis in primates. Annals of the New York Academy of Sciences **637**:107-121.
- Weinbauer, GR and Nieschlag, E** (1993) Hormonal control of spermatogenesis. In Molecular Biology of the Male Reproductive System. D de Kretser Ed. Academic Press, San Diego. pp. 99-142.
- Welsh, TH, Bambino, TH and Hseuh, AJW** (1982) Mechanism of glucocorticoid-induced suppression of testicular androgen biosynthesis *in vitro*. Biology of Reproduction **27**:1138-1146.
- Wilson, JD** (1994) Translating gonadal sex into phenotypic sex. In The Differences Between the Sexes. RV Short and E Balaban Eds. Cambridge University Press, Cambridge pp. 203-212.
- Wing, T-Y and Christensen, AK** (1982) Morphometric studies on rat seminiferous tubules. The American Journal of Anatomy **165**:13-25.
- Winter, JSD and Faiman, C** (1972) Pituitary-gonadal relation in male children and adolescents. Pediatric Research **6**:126-135.
- Witschi, E** (1948) Migration of the germ cells of human embryos from the yolk sac to the primitive gonadal fold. Contributions to Embryology, Carnegie Institute **32**:67-80.
- Wong, PYD** (1990) Electrolyte and fluid transport in the epididymis. In Epithelial Secretion of Water and Electrolytes. JA Young and PDY Wong Eds. Springer Verlag, Berlin. pp. 333-347.
- Wong, PYD and Tsang, AYF** (1982) Studies on the binding of a 32K rat epididymal protein to rat epididymal spermatozoa. Biology of Reproduction **27**:1239-1246.
- Wong, PYD and Yeung, CH** (1977) Hormonal regulation of fluid resorption in isolated rat cauda epididymidis. Endocrinology **101**:1392-1397.
- Wong, PYD, Au, CL and Bedford, JM** (1982) Biology of the scrotum. II. Suppression by abdominal temperature of transepithelial ion and water transport in the cauda epididymidis. Biology of Reproduction **26**:683-689.
- Wong, PYD, Au, CL and Ngai, HK** (1978) Electrolyte and water transport in rat epididymis - its possible role in sperm maturation. International Journal of Andrology **1**:600-628.
- Wong, PYD, Tsang, AYF and Lee, WM** (1981) Origin of the luminal fluid proteins of the rat epididymis. International Journal of Andrology **4**:331-341.
- Wong, V and Russell, LD** (1983) Three-dimensional reconstruction of a rat stage V Sertoli cell. I. Methods, basic configuration and dimensions. The American Journal of Anatomy **167**:143-161.

- Wong, YC, Breed, WG and Chow, PH** (1985) Ultrastructure of the epithelial cells of the ventral prostate from the hopping mouse, *Notomys alexis*. Acta Anatomica **121**:163-169.
- Woolley, P** (1975) The seminiferous tubules in dasyurid marsupials. Journal of Reproduction and Fertility **45**:255-261.
- Wreford, NG** (1995) Theory and practice of stereological techniques applied to the estimation of cell number and nuclear volume in the testis. Microscopy and Research Technique **32**:423-236.
- Wright, WW and Frankel, AI** (1980) An androgen receptor in the nuclei of late spermatids in testes of male rats. Endocrinology **107**:314-318.
- Wright, WW, Parvinen, M, Musto, NA, Gunsalus, GL, Philips, DM, Mather, JP and Bardin, CW** (1983) Identification of stage specific proteins synthesized by rat seminiferous tubules. Biology of Reproduction **29**:257-270.
- Wyker, R and Howards, SS** (1977) Micropuncture studies of the motility of rete testis and epididymal spermatozoa. Fertility and Sterility **28**:108-112.
- Yanagimachi, R, Kamiguchi, Y, Mikamo, K, Suzuki, F and Yanagimachi, H** (1985) Maturation of spermatozoa in the epididymis of the Chinese hamster. The American Journal of Anatomy **172**:317-330.
- Yeung, CH and Cooper, TG** (1994) Basal cells of the human epididymis: Antigenic and ultrastructural similarities to tissue-fixed macrophages. Biology of Reproduction **50**:917-926.
- Zeheb, R and Orr, GA** (1984) Characterization of a maturation-associated glycoprotein on the plasma membrane of rat cauda epididymal sperm. Journal of Biological Chemistry **259**:839-848.
- Zhengwei, Y, McLachlan, RI, Bremner, WJ and Wreford, NG** (1997) Quantitative (stereological) study of normal spermatogenesis in the adult monkey (*Macaca fascicularis*). Journal of Andrology **18**:681-687.
- Zuckerman, Z, Rodriguez-Rigau, LJ, Weiss, DB, Chowdhury, AK, Smith, KD and Steinberger, E** (1978) Quantitative analysis of the seminiferous epithelium in human testicular biopsies, and the relation of spermatogenesis to sperm density. Fertility and Sterility **30**:448-455.
- Zunke, VU and Gossrau, R** (1981) Zur Morphologie und Zonengliederung des Nebenhodenganges der Ratte. 1. Semidunnschnittuntersuchungen. Anatomischer Anzeiger **149**:409-424.

Peirce, E.J. and Breed, W.G. (1987) Cytological organization of the seminiferous epithelium in the Australian rodents *Pseudomys-australis* and *Notomys-alexis*. *Journal of Reproduction and Fertility (England)*, v. 80 (1), pp. 91-103, May 1987

NOTE:

This publication is included in the print copy of the thesis held in the University of Adelaide Library.

It is also available online to authorised users at:

<http://dx.doi.org/10.1530/jrf.0.0800091>

Peirce, E.J. and Breed, W.G. (1989) Light microscopical structure of the excurrent ducts and distribution of spermatozoa in the Australian rodents *Pseudomys-australis* and *Notomys-alexis*.

Journal of Anatomy, v. 162, pp. 195-213, February 1989

NOTE: This publication is included in the print copy of the thesis held in the University of Adelaide Library.

Peirce, E.J. and Breed, W.G. (1990) Organization of testicular interstitial tissue of an Australian rodent, the spinifex hopping mouse, *Notomys alexis*. *Cell and Tissue Research*, v. 260 (3), pp. 469-477, January 1990

NOTE: This publication is included in the print copy of the thesis held in the University of Adelaide Library.

It is also available online to authorised users at:

<http://dx.doi.org/10.1007/BF00297226>