



Pigmentation of the nipple-areolar complex and its reconstitution in breast reconstruction

Thesis for the Degree of Doctor of Philosophy

Nicola Ruth Dean MB ChB FRCS (Eng)

Department of Surgery, Department of Anatomical Sciences and
Co-operative Research Centre for Tissue Growth and Repair,
The University of Adelaide

December 2002

ABSTRACT

Reconstruction of the nipple-areolar complex is the final step in the recovery of women who have undergone mastectomy for breast cancer. Reconstruction of breast shape has been an area of major developments in surgical techniques in recent times. Nipple-areolar reconstruction, however, has not reached the same stage of evolution and is not as widely practiced. Clinicians that do perform nipple-areolar reconstruction as an integral part of a breast reconstruction program, indicate that it is difficult to match the colour of the normal nipple-areola and that the colour of reconstructions fades over time.

The purpose of this research was to assess the quality of current methods of nipple-areolar reconstruction, with special reference to pigmentation and, if they were found lacking, to investigate the feasibility of producing an engineered pigmented skin substitute that could be used in this clinical context. The research falls into three main parts - a clinical study of patients who have undergone breast reconstruction, a histological study of normal areolar skin and a cell culture study.

Patients who had undergone nipple-areolar reconstruction (n=63) were found to be less happy with the colour of their nipple-areolar reconstruction than with the general attributes of the breast reconstruction as a whole. There was found to be a measurable colour mismatch between normal and reconstructed nipple-areolar complexes and a reduction of colour saturation (i.e. fading) of the reconstructed nipple-areolar complex over time.

Pigmentation of the nipple-areolar complex at a histological level has not previously been reported and was a logical area to study if improvements in the colour of nipple-areolar reconstructions are to be achieved. Melanin and melanocyte complements in breast and areolar skin of twenty patients were measured using

conventional histochemical staining, immunohistochemistry and image analysis. The melanin content of areolar skin was about twice that of breast skin. This could mainly be accounted for by the higher number of melanocytes in areolar skin but basement membrane convolution and higher amount of melanin per melanocyte also contributed.

Detection of all normal melanocytes present in sections of skin was not straightforward. Preliminary experiments were carried out with several different primary antibodies for immunohistochemical labelling. The antibody clone TA99 (also known as Mel-5) against Pigment Associated Antigen (PAA) was found to be the most sensitive and was used in the quantitative study of melanocytes in breast and areolar skin.

Production of a tissue-engineered skin construct with the pigmentary characteristics of nipple-areolar skin is theoretically possible and could be used as an adjunct to current methods of nipple-areolar reconstruction. Production of such a construct for clinical use would have to be in an environment free of the toxins and potentially infective serum that are often used for *in vitro* cell culture.

It was possible to grow keratinocytes and melanocytes *in vitro* from adult surgical discard skin from the trunk (breast and abdomen). Initial cultures of melanocytes from this source in a serum-free medium were unsuccessful and culture of keratinocytes in serum-free medium was very slow. A subsequent series of experiments showed that melanocytes and keratinocytes can be grown successfully in the presence of autologous human serum and that the commonly used additives phorbol 12-myristate 13-acetate (PMA) and cholera toxin can be omitted from melanocyte culture medium if autologous human serum is used. Cells cultured in such a medium were used to produce new skin constructs by seeding them onto freeze-thawed human dermis.

STATEMENT OF ORIGINALITY

This work contains no material which has been accepted for the award of any other degree or diploma in any university or other tertiary institution and, to the best of my knowledge and belief, contains no material previously published or written by another person, except where due reference has been made in the text.

I give consent to this copy of my thesis, when deposited in The University of Adelaide Library, being available for photocopying and loan.

Nicola Ruth Dean

ACKNOWLEDGMENTS

I am very grateful for the help and advice of my supervisors - Dr. Julie Haynes, Dr. Chris Goddard and Prof. Rodney Cooter. I am particularly grateful for their support, their approachability and for always making time for me, even when their own schedules were busy. I would also like to thank Dr. James Brennan and Dr. Tim Neild for their advice and teaching on immunohistochemistry and colour analysis respectively.

I would like to thank Carol Brooker, Colleen Daly, Carl Stephan and Brendan Zeeman who gave their time to be the panel of external observers for the clinical study and Gail Hermanis, Nadia Gagliardi, Christopher Leigh, Tarvik Morgernstern and Jo Cool who taught me various techniques used in this work.

I am also grateful to Alan Hoare and Henry Zawada of the Department of Clinical Photography who took the photographs of the patients for the clinical study, and to the theatre nurses and surgeons who enabled me to have skin samples for the histology and cell biology studies. Thanks also to Prof. Grantley Gill for access to his patients for the clinical study. Thanks to Heather McElroy and Prof. Maciej Henneberg for advice on statistical matters.

Dr. Achim Jungbluth kindly donated primary antibodies for my immunohistochemistry work, for which I am grateful. Thanks to Ritu Gupta for giving some good advice on cell culture techniques and to Dr. Tony Simula for his support in the cell culture laboratory.

I received funding for this work from a Womens' and Childrens' Hospital Research Scholarship (1 year), a partial scholarship from the Co-operative Research Centre for Tissue Growth and Repair (5 months) and a Womens' and Childrens' Hospital Medical Postgraduate Research Scholarship (1 year).

I am grateful to all the patients who agreed to participate in the studies described. I thank my mother - Prof. Christine Dean, and my father, Dr. Gerald Dean for being a great source of inspiration and support in all my work. I would lastly and most importantly like to thank my family - John, Eva and Samson for their love and for their faith in me, without which I could never have completed this thesis.

ETHICS APPROVAL

Approval for the participation of patients in this work was granted by the Royal Adelaide Hospital Ethics Committee and the North Western Area Health Authority. Patient information sheets and approval letters are appended. (Appendices I-V)

LIST OF ABBREVIATIONS

AEC	3-amino-9-ethyl carbazole
AHS	Autologous human serum
BPE	Bovine pituitary extract
CEA	Cultured epithelial autograft
CSS	Cultured skin substitute
DAB	Di-aminobenzidine
DMSO	Dimethyl sulfoxide
DOPA	L3,4 Dihydroxyphenylalanine
EDTA	Sodium edetate
EGF	Epidermal growth factor
FBS	Fetal bovine serum
FGF	Fibroblast growth factor
GAG	Glycosaminoglycan
H&E	Haematoxylin and Eosin
HIER	Heat induced epitope retrieval
MEM	Modified Eagle's Medium
MGM	Melanocyte growth medium
PAA	Pigment Associated Antigen
PBS	Phosphate buffered saline
PMA	Phorbol 12-myristate 13-acetate
PSE	Pigmented skin equivalents
PSF	Penicillin, streptomycin and fungizone
PUVA	Psoralen and ultraviolet A
SCF	Stem cell factor
SFM	serum-free medium
TPA	Tetradecanoylphorbol-13-acetate
TRAM	Transverse Rectus Abdominis Myocutaneous
TRP-1	Tyrosine related protein -1
UV	Ultraviolet

TABLE OF CONTENTS

Abstract

Statement of originality

Acknowledgments

Ethics approval

List of abbreviations

Table of contents

List of figures

List of tables

INTRODUCTION *1*

CHAPTER 1 LITERATURE REVIEW

1.1 Nipple-areolar reconstruction *2*

1.1.1 The history of nipple-areolar reconstruction

1.1.2 The issue of colour

1.2 Pigmentation of the normal nipple-areolar complex *15*

1.2.1 The mechanism of skin pigmentation

1.2.1.1 Mechanism of skin pigmentation - cellular level

1.2.1.2 Mechanism of skin pigmentation - sub-cellular level

1.2.1.3 Mechanism of skin pigmentation - molecular level

1.2.2 Early work on the normal pigmentation of human skin

1.2.3 Electron microscopy in the development of understanding of skin pigmentation

1.2.4 Histology of the nipple-areolar complex

1.2.5 Endocrine effects on the pigmentation of the nipple-areolar complex

1.2.6 Further work on the pigmentation of normal skin

	<u>page</u>
1.2.7 Immunohistochemistry and the study of normal melanocytes	
1.3 The evolution of pigmented skin equivalents	35
1.3.1 Production of skin components <i>in vitro</i>	
1.3.2 Bilayered skin equivalents	
1.3.3 Culture of human melanocytes <i>in vitro</i>	
1.3.4 Advances in keratinocyte culture	
1.3.5 Early pigmented skin equivalents and further advances in melanocyte culture	
1.3.6 Clinical experience with cultured keratinocytes and skin substitutes	
1.3.7 Further work on melanocyte culture <i>in vitro</i>	
1.3.8 In search of normal pigmentation for skin substitute	
1.3.9 The issue of safety in cultured skin substitutes	
1.3.10 The influence of the dermis on melanocyte behaviour	
1.3.11 Further clinical cases using transplantation of isolated melanocytes	
1.3.12 Co-cultured melanocyte and keratinocyte sheets as a therapeutic option	
1.3.13 Further developments in pigmented skin substitutes	
1.4 Summary of literature review	62

CHAPTER 2 A STUDY OF NIPPLE-AREOLAR RECONSTRUCTIONS

2.1 Aims and objectives	64
2.2 Materials and methods	65
2.2.1 Patients	

2.2.2	Method of review and questionnaires	
2.2.3	Photography	
2.2.4	Independent panel review	
2.2.5	Computerised colour analysis	
2.2.6	Scoring of questionnaires and statistical analysis	
2.3	Results	76
2.3.1	Demographics	
2.3.2	General information on breast reconstruction	
2.3.3	Patients with nipple-areolar tattoos	
2.3.4	Patients' perceptions of nipple-areolar reconstruction within the context of breast reconstruction	
2.3.5	The influence of time on the colour of nipple-areolar reconstructions	
2.3.6	Patients comments	
2.3.7	External observers' views and partners' views on outcome of nipple-areolar and breast reconstruction.	
2.3.8	Colour analysis	
2.4	Discussion	98
2.4.1	Justification for study methods	
2.4.2	Population and study sample	
2.4.3	The impact of nipple-areolar reconstruction on breast reconstruction as a whole	
2.4.4	The quality of nipple-areolar reconstructions	

CHAPTER 3 PIGMENTATION OF THE NORMAL FEMALE AREOLA

3.1	Aims and objectives	106
3.2	Materials and methods	107
3.2.1	Materials	
3.2.1.1	Instruments and equipment	
3.2.1.2	Disposables and glassware	
3.2.1.3	Chemicals and solutions	
3.2.1.4	Miscellaneous	
3.2.2	Skin samples	
3.2.3	Method for processing skin samples	
3.2.4	Method for staining melanin	
3.2.5	Image analysis for sections stained for melanin	
3.2.6	Comparative immunohistochemistry for the detection of melanocytes	
3.2.6.1	Introduction and basic method	
3.2.6.2	Preliminary experiments	
3.2.6.3	Optimising conditions for Mel-5 staining	
3.2.6.4	Immunostaining of melanocytes for quantitative comparison of different primary antibodies	
3.2.7	Final method of detecting melanocytes for quantitative study of melanocytes in parallel sections of areolar / breast skin	
3.2.8	Image analysis for sections immunostained for melanocytes	
3.2.8.1	Comparison of sensitivities of primary antibodies	
3.2.8.2	Quantity of melanocytes in normal areolar skin	
3.2.9	Method for electron microscopy	

	<i>page</i>
3.3 Results	124
3.3.1 Electron microscopy of areolar skin	
3.3.2 Amount of melanin in breast skin vs areolar skin	
3.3.3 Relationship between amount of melanin in skin and Fitzpatrick sun sensitivity skin type	
3.3.4 Correlation of amount of melanin in skin and measured skin colour	
3.3.5 Comparison of different primary antibodies for the immunohistochemical detection of normal melanocytes.	
3.3.5.1 Results of preliminary experiments	
3.3.5.2 Conditions for Mel-5 labelling	
3.3.5.3 Immunostaining of melanocytes for quantitative comparison of different primary antibodies	
3.3.6 Quantity of melanocytes, melanocyte to keratinocyte ratios and amount of melanin per melanocyte in areolar and breast skin.	
3.4 Discussion	145
3.4.1 Introduction	
3.4.2 Characteristics of areolar skin	
3.4.3 Immunohistochemical labelling of normal melanocytes	
3.4.4 Limitations and usefulness of the current study	

**CHAPTER 4 THE POTENTIAL FOR TISSUE ENGINEERED
NIPPLE-AREOLAR SKIN IN BREAST RECONSTRUCTION**

PATIENTS

4.1.1	Introduction	155
4.1.2	Aims and objectives	155
4.2	Materials and methods	157
4.2.1	Establishing epidermal cell culture	
4.2.1.1	Skin harvest and collection	
4.2.1.2	Preparation of basal epidermal cells for <i>in vitro</i> culture from adult surgical discard skin	
4.2.1.3	Growth of epidermal cells in standard culture media	
4.2.1.4	Separation of melanocytes and keratinocytes in culture	
4.2.1.5	Immunostaining of <i>in vitro</i> cultured melanocytes	
4.2.2	Investigating a culture medium safe for use in the clinical setting	
4.2.2.1	Comparison of cell culture media containing autologous human serum with other media for melanocyte growth	
4.2.2.2	Comparison of media with and without PMA and cholera toxin for melanocyte growth	
4.2.3	Production of skin constructs	
4.2.3.1	Production of a skin construct from cultured cells and preserved dermis	
4.2.3.2	Assessment of skin constructs	

	<i>page</i>
4.3 Results	173
4.3.1 Establishing epidermal cell culture	
4.3.1.1 Deriving basal epidermal cells from adult surgical discard skin	
4.3.1.2 <i>In vitro</i> culture of melanocytes and keratinocytes from adult surgical discard skin in standard culture media	
4.3.1.3 Separation of melanocytes and keratinocytes	
4.3.1.4 Immunostaining of cultured melanocytes	
4.3.2 Investigating a culture medium safe for use in the clinical setting	
4.3.2.1 Comparison of culture media containing autologous human serum with other media for melanocyte growth	
4.3.2.2 Comparison of media free of PMA and cholera toxin with media containing PMA and cholera toxin for melanocyte growth	
4.3.3 Skin constructs	
4.3.3.1 Production of skin constructs	
4.3.3.2 Assessment of skin constructs	
4.4 Discussion	197
4.4.1 Epidermal cell culture from adult surgical discard skin	
4.4.2 Culture media safe for use in a clinical setting	
4.4.3 Skin constructs	
4.4.4 Clinical application of skin constructs for nipple-areolar reconstruction	

	<u>page</u>
APPENDICES	207
I Royal Adelaide Hospital Ethics Committee approval letter.	
II North Western Area Health Authority Ethics Committee approval letter.	
III Clinical Study Patient Information Sheet	
IV Skin donation Patient Information Sheet	
V Modified patient information sheet for patients donating skin	
VI Letter inviting patients to attend clinical study	
VII Consent form for participation in clinical study	
VIII Feedback form	
IX Patients' Aesthetics Questionnaire	
X Demographics Questionnaire	
XI Partners' Aesthetics Questionnaire	
XII Panel Aesthetics Questionnaire	
XIII Fitzpatrick Classification of Sunreactive Skin Types	
XIV Questionnaire for patients donating skin specimens	
XV Patient details for histology specimens	
XVI Consent form for donation of skin	
XVII Protocol for Masson-Fontana staining	
XVIII Protocol for Immunohistochemistry of melanocytes	
PAPERS	231
BIBLIOGRAPHY	233

LIST OF FIGURES

		<i><u>page</u></i>
Fig. 1	Reconstruction of the breast mound with a silicone prosthesis	4
Fig. 2	Reconstruction of the breast mound using a TRAM flap	5
Fig. 3	Patient prepared for a free TRAM flap procedure	6
Fig. 4	Balancing of TRAM breast reconstruction by reduction of the contralateral breast	7
Fig. 5	A Different methods of nipple reconstruction, B Sources of skin graft for reconstruction of the areola	9
Fig. 6	Skate flap reconstruction of the nipple-areolar complex	11
Fig. 7	Breast reconstruction	13
Fig. 8	The epidermal melanin unit	16
Fig. 9	Diagram illustrating melanosomes migrating from a melanocyte to a keratinocyte	18
Fig. 10	The biochemistry of melanin production	20
Fig. 11	The evolution of pigmented skin substitutes	36
Fig. 12	The evolution of pigmented skin substitutes (continued)	37
Fig. 13	Standardised photography of a woman with bilateral breast reconstructions for assessment by independent observers	69
Fig. 14	Typical images of patient A before and B after nipple-areolar reconstruction, for rating of impact of nipple-areolar reconstruction by panel of independent observers	71
Fig. 15	Colour analysis: A image of patient with colour standard within colour analysis computer software programme, B colour wheel showing “degrees” of hue	74
Fig. 16	Occupations of patients enrolled in nipple-areolar reconstruction study	77

	<u>page</u>
Fig. 17 Frequency of patients' ratings of different attributes of breast reconstruction	81
Fig. 18 Patients' ratings for fading vs time since procedure	85
Fig. 19 A Patient 3 months after tattoo procedure - it was her fourth tattoo because previous ones had faded. B Patient 8 months after tattoo - she was disappointed with the degree of fading	87
Fig. 20 Images of breast reconstruction patients wearing colour standards	89
Fig. 21 Ratings of patients, their partners and a panel of independent observers	93
Fig. 22 Saturation of the breast mound vs saturation of the upper abdomen in patients with TRAM flap reconstructions	96
Fig. 23 Colour saturation mismatch over time	97
Fig. 24 Spectrum of objectivity / subjectivity in the methods used in the current study	99
Fig. 25 Schematic representation of protocol for processing skin samples	110
Fig. 26 Masson-Fontana staining of an areolar skin section	112
Fig. 27 Outlining the viable epidermis of a section stained with Masson-Fontana stain	114
Fig. 28 Image analysis of sections for comparison of antibody staining	120
Fig. 29 Use of paired sections for staining for melanin and for melanocytes	122
Fig. 30 Electron microscopy of melanocyte and adjacent keratinocyte	125
Fig. 31 Melanin content of areolar skin and breast skin	127
Fig. 32 Percentage of epidermis occupied by melanin in areolar and breast skin	128
Fig. 33 Amount of melanin per length of skin surface in areolar and breast skin	130

	<u>page</u>
Fig. 34 Amount of melanin per length of basement membrane in areolar and breast skin	130
Fig. 35 Labelling with anti-vimentin antibody	133
Fig. 36 Using the high molecular weight cytokeratin antibody CK34 β E12 to establish the sensitivity of melanocyte antibodies A skin stained with Mel-5, B parallel section stained with CK34 β E12 giving negative image of melanocytes	135
Fig. 37 Effect of staining of parallel sections of skin with Mel-5. A Incubation of the primary antibody overnight at 4°C, B Incubation of the primary antibody for 30mins at room temperature before overnight incubation at 4°C.	136
Fig. 38 Staining of positive controls (nodular melanoma) for different primary antibodies	139
Fig. 39 Staining of skin sections with anti-c-kit antibody stains normal melanocytes but is often poorly localised.	140
Fig. 40 Staining of parallel sections of skin with different antibodies for the identification of melanocytes A Mel-5, B NKI/ beteb, C T311, D A103 (Melan A), E c-kit, F S100 (VIP used as chromogen)	141
Fig. 41 Number of melanocytes per mm of basement membrane	143
Fig. 42 Number of melanocytes per mm of skin surface	143
Fig. 43 Melanocyte to keratinocyte ratio in areolar and breast skin	144
Fig. 44 Amount of melanin per melanocyte in areolar and breast skin	144
Fig. 45 Typical sections of A areolar and B breast skin stained with the Masson-Fontana technique showing the increased ratio of basement membrane (green) to skin surface length in areolar skin	146

	<u>page</u>
Fig. 46 Diagram illustrating how melanocytes, which are spaced evenly along the dermo-epidermal junction, appear crowded on the rete ridges for an observer looking at the epidermal sheet from the surface	148
Fig. 47 A Ratios of melanocytes to keratinocytes in the six wells of the Transwell culture plate B Side view of a Transwell	169
Fig. 48 Imaging of skin constructs	172
Fig. 49 Keratinocytes grown in serum-free medium (phase contrast micrographs)	176
Fig. 50 Images of single neonatal melanocytes growing in a serum-free melanocyte medium	177
Fig. 51 Co-cultures of melanocytes and keratinocytes (phase contrast micrographs)	178
Fig. 52 Phase contrast micrographs of melanocytes after 2 weeks culture in medium containing FBS	179
Fig. 53 Melanocytes A after 16 days of culture in 5% FBS and B after 4 weeks of culture in 5% FBS	180
Fig. 54 Cultured melanocytes stained with Mel-5	182
Fig. 55 A Melanocytes treated with 5% DMSO during immunohistochemical technique B Melanocytes treated with 70% alcohol during immunohistochemical technique	183
Fig. 56 Melanocytes growing in medium with 1% AHS and no cholera toxin or PMA	185
Fig. 57 Co-cultures of melanocytes and keratinocytes growing in AHS with no cholera toxin or PMA	186
Fig. 58 Areas of confluent A melanocytes and B keratinocytes grown in AHS	187

	<i><u>page</u></i>
Fig. 59 Growth of primary cultures of melanocytes in medium containing no serum, fetal bovine serum (FBS) or autologous human serum (AHS)	188
Fig. 60 Mean cell counts for passaged melanocytes in different media	190
Fig. 61 Photographs of skin constructs with colour standards on A day 0 B day 2 C day 4 post-seeding of epidermal cells	192
Fig. 62 Colour saturations of skin constructs (dermis) from experiment 1 vs time since seeding	193
Fig. 63 Hue of skin constructs (dermis) from experiment 1 vs time since seeding	193
Fig. 64 Paraffin sections of skin constructs consisting of freeze thawed abdominal dermis and epidermal cells from breast skin of a different patient	195
Fig. 65 Melanocytes labelled with the antibody Mel-5	196
Fig. 66 Potential donor site for skin for cell culture in a patient about to undergo TRAM flap reconstruction of the breast mound	198
Fig. 67 A Separation of adult human skin by trypsin floatation. B Separation of adult human skin by collagenase.	201

LIST OF TABLES

		<i><u>page</u></i>
Table 1	Grouping of questionnaire ratings	73
Table 2	Chi-squared test comparing number of patients happy with general attributes of breast reconstruction and number of patients happy with nipple-areolar colour	82
Table 3	Chi-squared test comparing number of patients happy with general attributes of breast reconstruction and number of patients happy with nipple-areolar projection	82
Table 4	Patients' scores for colour of the nipple-areolar reconstruction by source of pigmentation of the neo-areola	83
Table 5	Patients' scores for fading of the nipple-areolar reconstruction by source of pigmentation of the neo-areola	83
Table 6	Colour saturation mismatch (saturation of normal minus saturation of reconstructed) nipple-areolar skin by source of areolar pigmentation	95
Table 7	Dilutions and antigen retrieval techniques of the primary antibodies used in the comparative study of immunohistochemical detection of normal melanocytes	117
Table 8	Two way analysis of variance between melanin content of breast and areolar skin and measurements per length of basement membrane and per length of skin surface	131
Table 9	Number of melanocytes per mm of basement membrane for different immunohistochemical methods of identifying melanocytes in whole skin specimen	142
Table 10	Melanocyte counts in medium containing AHS vs FBS	174
Table 11	Mean melanocyte counts in medium containing AHS vs FBS	189

INTRODUCTION

“Regardless of the position, the size or the contour, a breast is not recognized as a breast until it possesses an areola-nipple complex.” (Snyder et al. 1976)

Now that breast mound reconstruction after breast cancer extirpation has reached such high standards, there is increasing interest in matching this with an equally excellent reconstruction of the nipple-areolar complex. It has been shown that nipple-areolar reconstruction confers a significant benefit to breast reconstruction patients in terms of satisfaction with the final result of their reconstructions (Wellisch et al. 1987).

The idea for this project came from a clinical observation that in those patients who had undergone complete breast reconstruction (breast mound and nipple-areolar reconstructions), the nipple-areolar reconstructions faded over time. From this observation there arose three main questions:

- Is the fading of nipple-areolar reconstructions perceived by patients as a real problem or is it simply a phenomenon observed by surgeons?
- What is it that reconstructive surgeons are trying to reproduce? i.e. What are the determinants of normal nipple-areolar pigmentation, in terms of melanocyte and melanin concentrations?
- Is it possible to produce safely an autologous pigmented epithelium *in vitro* that would enable a permanently pigmented nipple-areolar reconstruction?

As the research relating to each of these questions covers three separate disciplines, plastic and reconstructive surgery, histology and cell biology, the body of this thesis is organised into chapters accordingly. The literature review is likewise divided into three main parts.

CHAPTER 1

LITERATURE REVIEW

This literature review encompasses relevant literature until the 30th April 2001. Subsequent clinical and experimental studies were designed on the basis of the literature to this date.

1.1 NIPPLE-AREOLAR RECONSTRUCTION

1.1.1 The history of nipple-areolar reconstruction

Reconstruction of the nipple-areolar complex was first performed in non-oncological cases, such as those with deformity secondary to burns. Adams published a case using vulval skin to reconstruct the nipple-areolar complex (Adams 1949). In 1972 Millard split the contralateral nipple to produce a new nipple (Millard 1972). While this technique gave good results, it was at the expense of making a previously normal nipple abnormal.

With the advent of breast reconstruction for mastectomy defects, initially with silicone implants (Snyderman and Guthrie 1971) (Fig. 1) nipple-areolar reconstruction became an issue. However, early breast reconstruction involved creation of the breast mound only, the goal being to create a “brassiere breast” (Little 1984). The use of autogenous tissue to create a breast mound improved the options available for women undergoing reconstruction, and the Transverse Rectus Abdominis Myocutaneous (TRAM) flap (Hartrampf et al. 1982) is now considered the gold standard for breast mound reconstruction (Fig. 2). This procedure may be performed as a pedicled flap,

where the vessels to the tissue are left connected, or as a free flap, where the deep inferior epigastric vessels are divided and re-anastomosed, either in the axilla or to the internal mammary vessels (Fig. 3). Operations on the contralateral breast, either to reduce or enlarge it, have also improved the final outcome of breast reconstruction (Fig. 4).

J.W. Little III has been an advocate for reconstruction of the nipple-areolar complex, as he believes that a more realistic breast reconstruction helps in the recovery from the psychological trauma of breast cancer and mastectomy (Little 1984). In 1982 Little introduced his 'quadrapod' flap. This involves raising up four small skin flaps from a disc on the breast mound reconstruction and using them to reform the prominence of the nipple. This method leaves a denuded area around the new nipple which then requires a skin graft to provide neo-areolar skin (Little et al. 1983). This skin graft is harvested from the contralateral areolar skin (when a contralateral breast reduction was performed), or from the upper inner thigh (Fig. 5). Broadbent nominated the upper inner thigh as a good donor site for skin graft for the areola after studying the natural distribution of melanin in the skin (Broadbent et al. 1977). This method was advocated for its discreet donor site and greater than average pigmentation and is still popular today.

The nipple produced by the quadrapod flap technique was found to lose projection with time and several other local flap techniques arose in response to this problem. Bosch described a trapdoor shaped cutaneous-fat flap with the neo-areola skin produced by grafting from upper inner thigh skin (Bosch and Ramirez 1984). Hartrampf's dermal-fat flap was very similar, although he preferred grafts taken from the infragluteal fold (Hartrampf and Culbertson 1984).

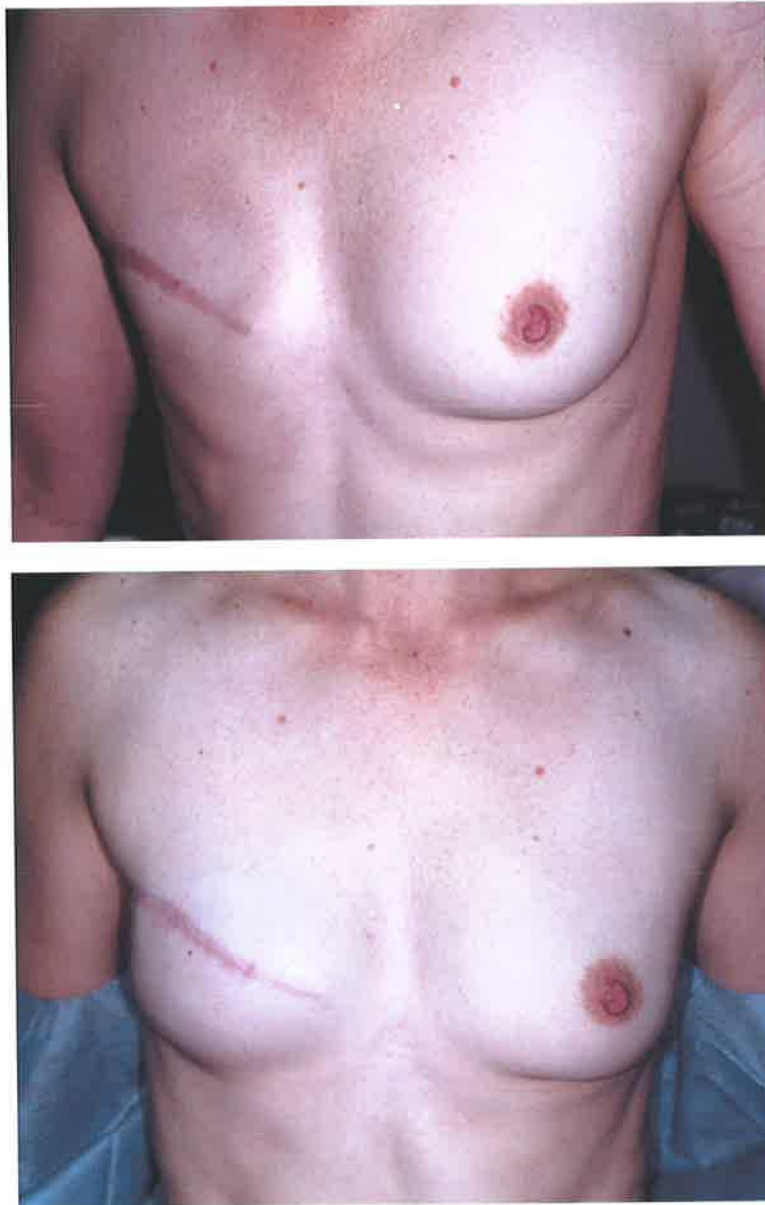

Fig. 1 Reconstruction of the breast mound with a silicone prosthesis

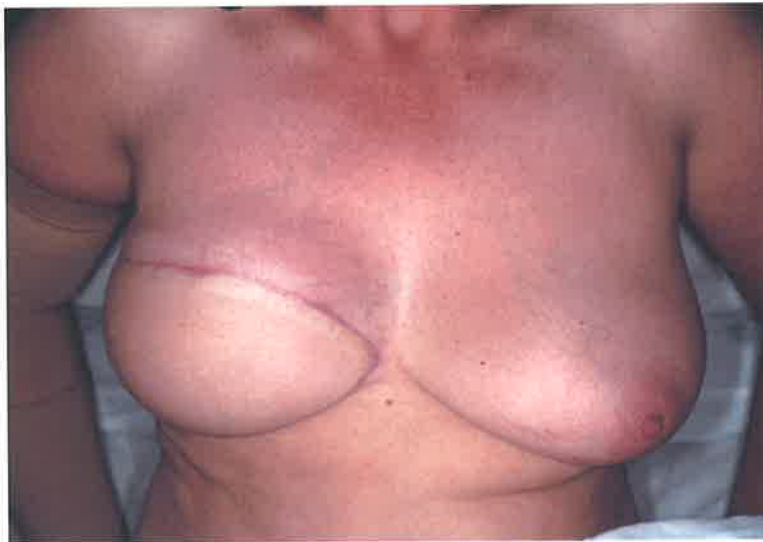
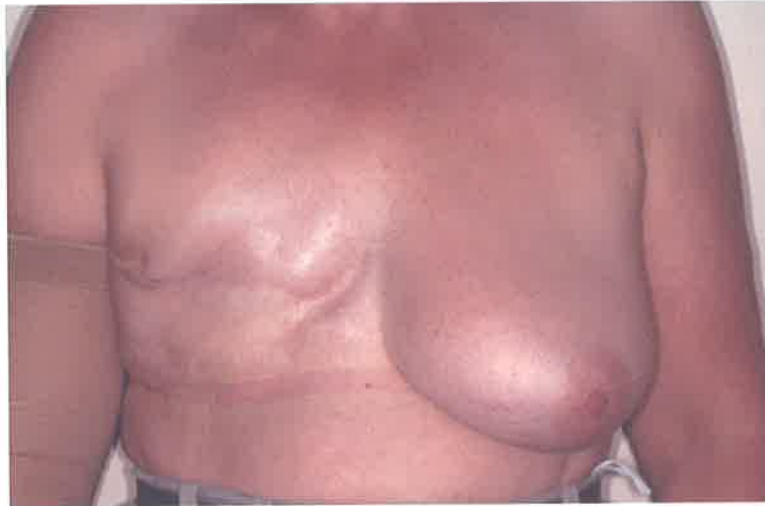
Fig. 2 Reconstruction of the breast mound using a TRAM flap

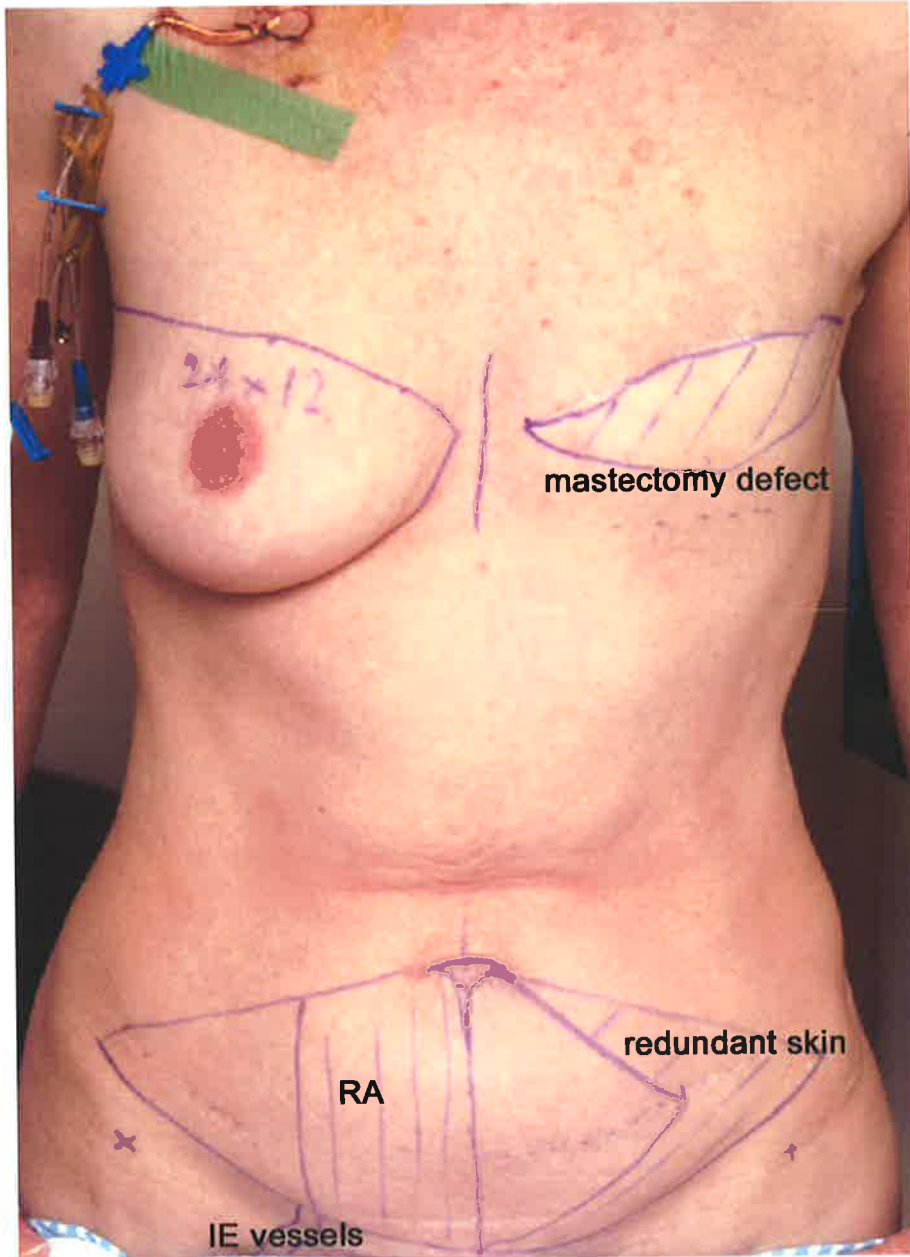


Fig. 3 Patient prepared for a free TRAM flap procedure - the deep inferior epigastric arteries and veins (IE vessels), rectus abdominis muscle (RA), mastectomy defect and flap are marked out.

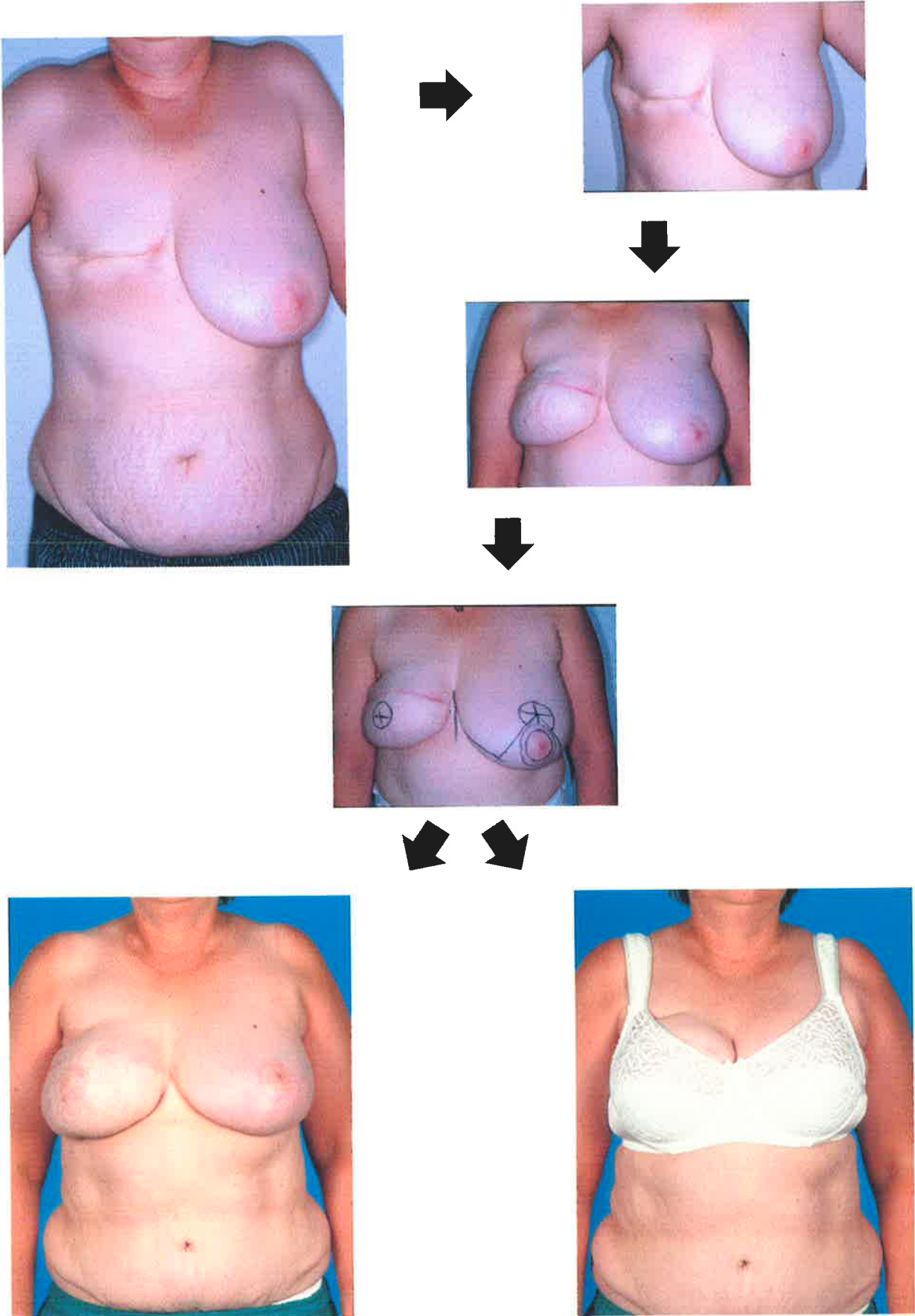


Fig. 4 Balancing of TRAM breast reconstruction by reduction of the contralateral breast

In 1984, Little published a review of reconstructive techniques and presented a new modification of his quadrupod flap (Little 1984). In this review he urged surgeons to strive to achieve nipple-areolar reconstructions as good as the breast reconstructions then available. He expressed the view that nipple sharing as a technique was unacceptable because of the damage to the contralateral nipple. His 'fortified' version of the quadrupod technique was developed to achieve better maintenance of projection of the new nipple.

In the following year, the use of intradermal tattoo was reported for nipple-areolar reconstruction (Becker 1986). Becker suggested that tattoo could be used either on the nipple only, if the neo-areola was sufficiently pigmented, or on the whole of the nipple-areolar complex if the grafted neo-areola did not provide a good colour match. The development of intradermal tattooing introduced the concept of using non-specialised skin (i.e. skin which did not have an intrinsically high melanin content) for grafting the areola, in conjunction with a planned tattooing of the whole nipple-areolar complex at a later date. The technique of tattooing was further developed by Spear and Little (Spear et al. 1989).

Between 1985 and 1987 a further three local flap techniques of nipple reconstruction were published. Cohen and colleagues described the 'pinwheel and barrier' technique (Cohen et al. 1986). Smith and Nelson described the 'mushroom-shaped' reconstruction (Smith and Nelson 1986) and Weiss described an 'S' reconstruction (Weiss et al. 1989). All these techniques attempted to address the problem of loss of projection of the nipple over time and all were local flaps performed in conjunction with areolar grafting with specialised skin (upper inner thigh). Vecchione also described a 'coiled wrap' technique to salvage loss of projection in a previously reconstructed nipple by extracting a core of tissue then wrapping it with a strip of non-specialised skin graft (Vecchione 1986).

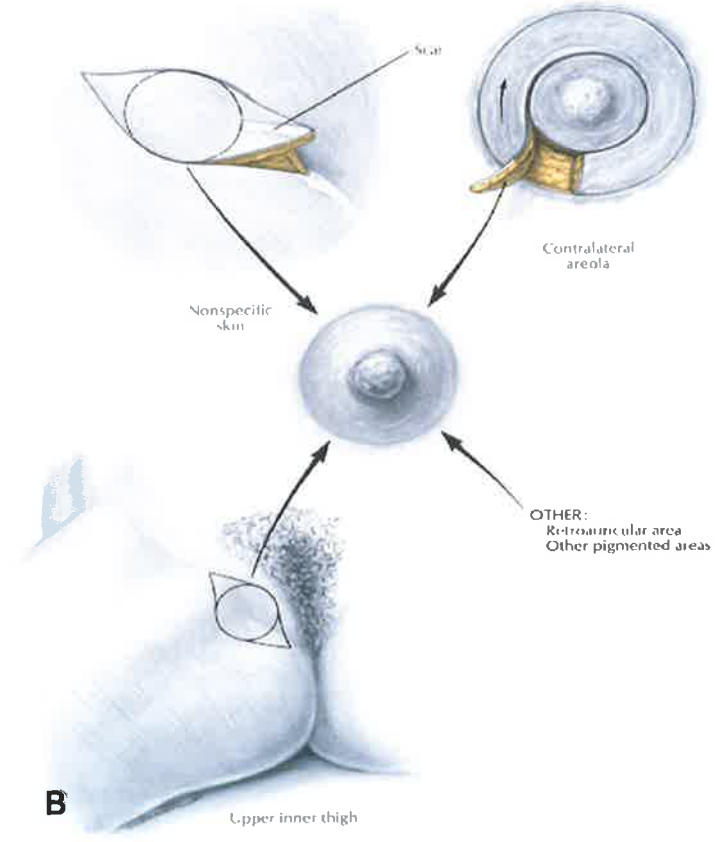
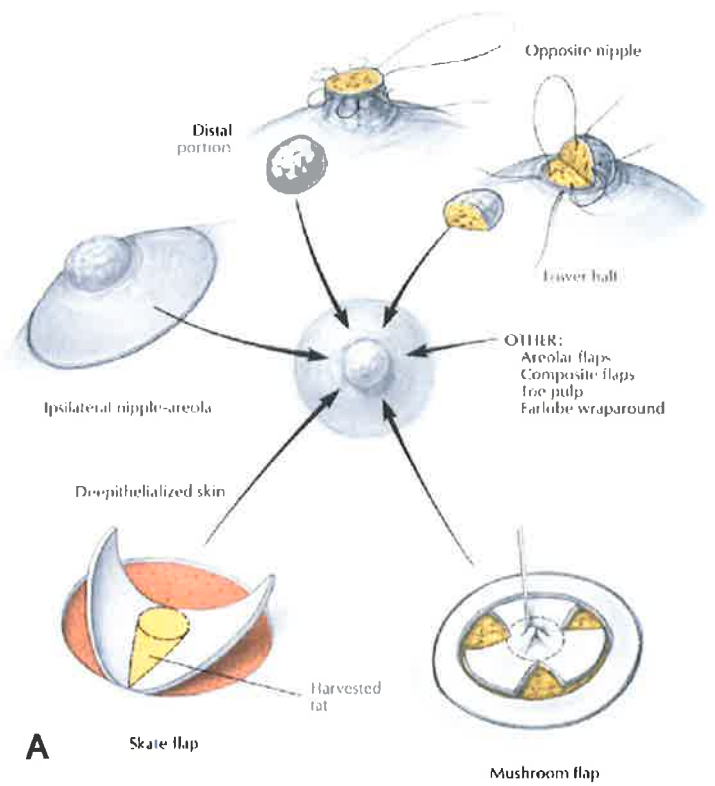


Fig. 5 A Different methods of nipple reconstruction, **B** Sources of skin graft for reconstruction of the areola (from Bostwick 1990)

In 1988 Little published his 'skate' flap technique (Fig. 6) (so named because the flap is supposed to resemble the skate fish in shape). Using this local flap, he demonstrated long-term maintenance of nipple projection. Little advocated the use of non-specialised skin graft in conjunction with planned tattooing to give the best results.

In the quest to produce a good nipple-areolar reconstruction without the need for any skin grafting, two more local flap techniques were developed. The 'modified star' technique (Eskenazi 1993) and the 'double-opposing tab flap' technique (Kroll and Hamilton 1989) used intradermal tattooing as the only adjunct to these local flaps, hence avoiding a donor wound. In 1998 Hugo and colleagues described a double-opposing pennant flap in conjunction with intradermal tattoo (Hugo et al. 1998). Bostwick also used a local flap, the "C-V flap", for reconstruction of the nipple with tattooing alone for reconstruction of the areola (Bostwick 1999). The disadvantages to all these local flaps is loss of long term projection and a tendency for the nipple to become ovoid (Kroll et al. 1997).

As an alternative to local flaps, Tanabe and co-authors used rolled auricular cartilage in a flap to maintain nipple projection (Tanabe et al. 1997). This technique, however, employed two donor sites - one on the pinna and one in the groin. In 1997, Bhatti and Berry advocated the revival of nipple sharing as a technique - this time in conjunction with intradermal tattooing (Bhatti and Berry 1997).

In 1998, Baltaci and Kilic described the use of cultured autologous melanocytes for pigmenting a disc of reconstructed breast skin to mimic the areola (Baltaci and Kilic 1998). They did not report the use of this technique in conjunction with any other reconstruction of the nipple-areolar complex. The melanocytes were cultured from a pigmented naevus. In their paper there was no discussion of the possibility of malignant transformation in these naeval cells.

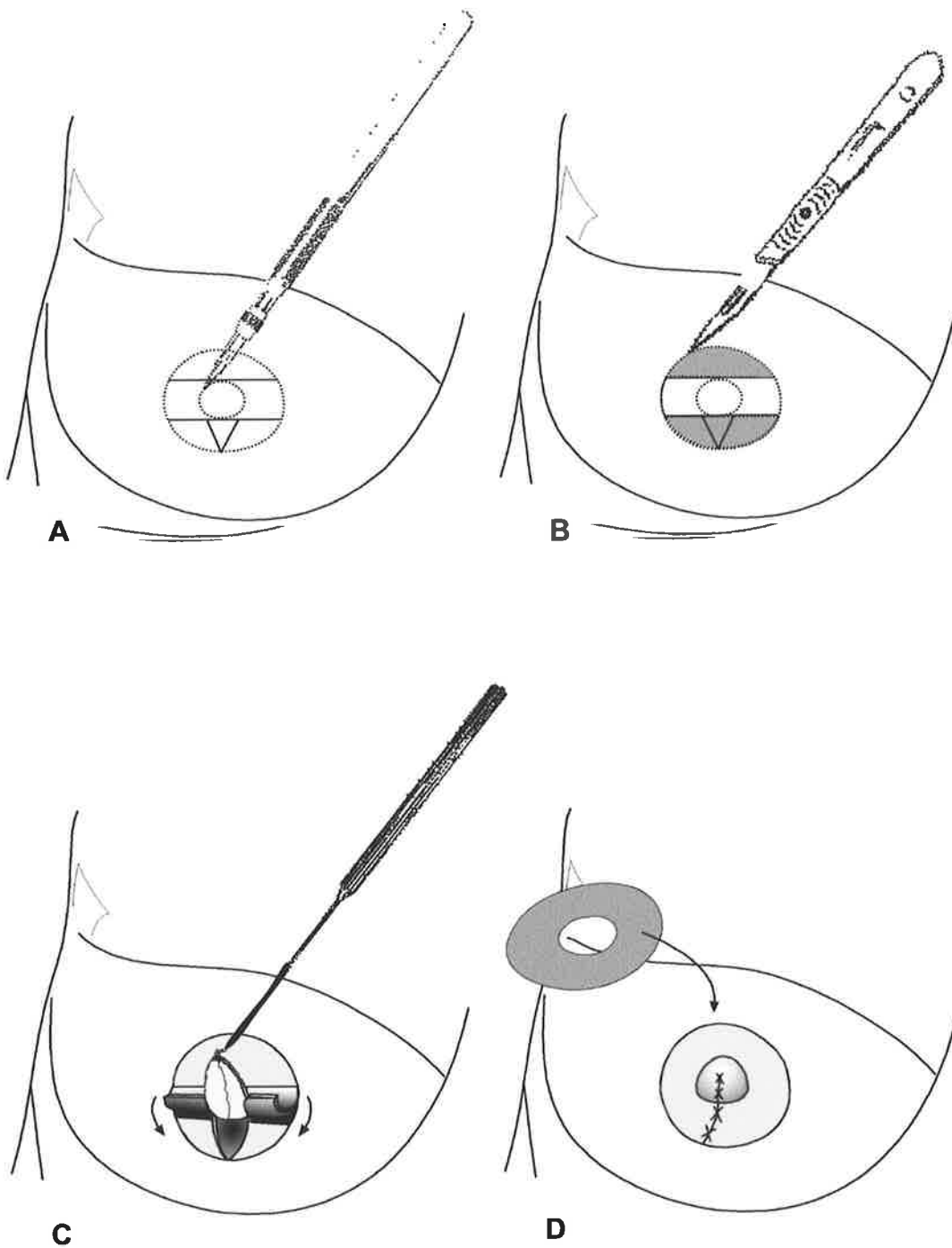


Fig. 6 Skate flap reconstruction (Little and Spear 1988) of the nipple-areolar complex **A** Marking a circle on the breast mound and dividing into three **B** Cutting around the circumference and de-epithelialising the upper and lower thirds **C** Elevating the central core and wrapping side "wings" of skin around to form the new nipple **D** Placing the full thickness skin over the new nipple to form the new areola.

1.1.2 The issue of colour

Poor colour match and fading of nipple-areolar reconstructions is recognised in the literature as a problem (Bostwick 1999; Henseler et al. 2001). An ideal method would produce optimal colouration immediately post-operatively and be retained long term. This seems impossible to achieve with current techniques. “Specialised” areolar skin grafts from pigmented areas such as the upper inner thigh may not give optimal colour match to the other side and are reported to fade with time (Fig 7) (Bostwick 1999). This technique also necessitates a donor wound - usually in the groin, the scar may be painful and complications such as infection are a risk (Cohen et al. 1986).

In those techniques which routinely use tattooing, fading has also been described as a problem. In Becker’s initial paper on intradermal tattooing it was stated that approximately 25% of patients needed to have touch-up tattoos or retattooing in order to improve colour match (Becker 1986). Bhatti and Berry, in their paper on nipple-areolar reconstruction by intradermal tattooing and nipple sharing, strongly advocated the benefits of intradermal tattooing but did not formally evaluate patients’ perceptions of colour match and fading and still reported having to retattoo 10% of patients (Bhatti and Berry 1997). Hugo and colleagues stated that 40% of their patients receiving intradermal tattoo required re-tattooing (Hugo et al. 1993). Henseler and colleagues have highlighted the difficulties of good colour matching when tattooing the nipple-areolar complex and examined what is “normal” nipple-areolar colour in a population of Scottish women. (Henseler et al. 2001). In the only published study that has considered patients’ perceptions of the colour of their nipple-areolar reconstruction, 60% of the patients reported the tattoo as being “too light” although the majority still reported being “satisfied” with their outcome (Spear and Arias 1995).

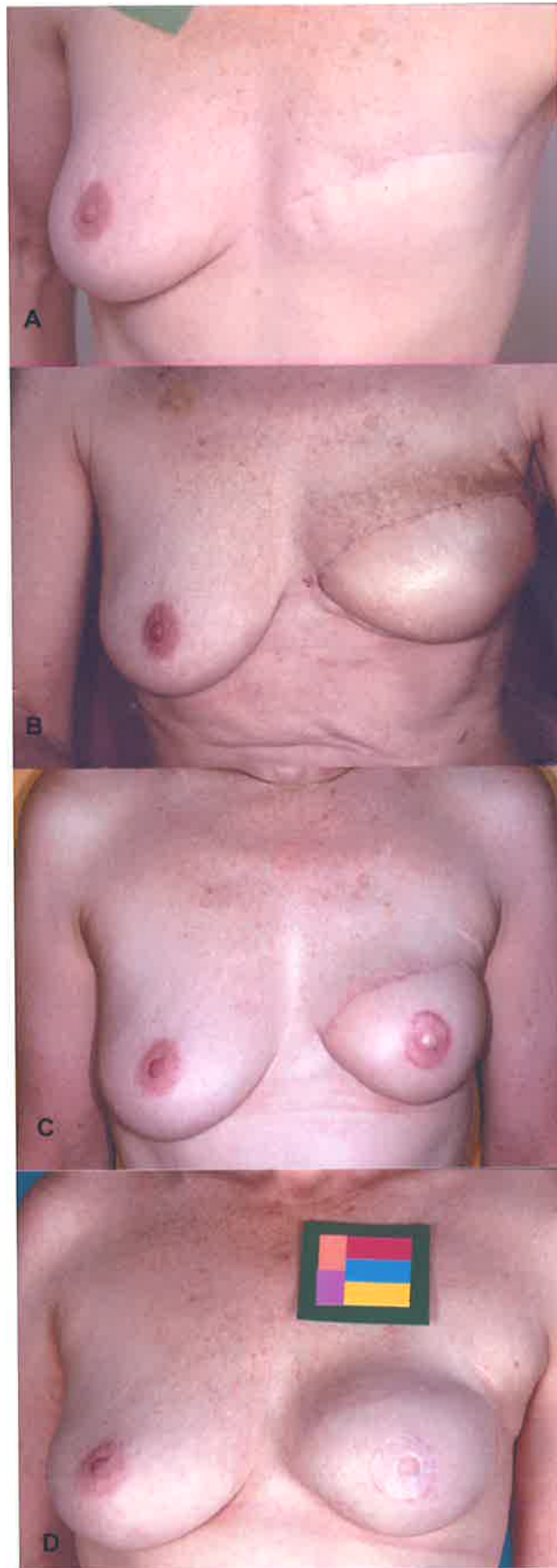

Fig. 7 Breast reconstruction **A** mastectomy defect **B** TRAM flap reconstruction of breast mound **C** Nipple-areolar reconstruction with skin graft from groin **D** Appearance 2 years after nipple-areolar reconstruction

In summary, colour match and maintenance of colour in the reconstructed nipple-areolar complex is difficult to achieve and is expressed as a problem by most authors in the field. Both specialised skin grafts and tattoos appear to be susceptible to fading with time, but because there have been few studies quantifying or formally evaluating this phenomenon, it is difficult to compare different techniques and results.

1.2 PIGMENTATION OF THE NORMAL NIPPLE-AREOLAR COMPLEX

1.2.1 The mechanism of skin pigmentation

The mechanism of pigmentation of skin can be considered at different levels: the cellular level, the sub-cellular level and the molecular level.

1.2.1.1 Mechanism of skin pigmentation - cellular level

Melanocytes are dendritic cells derived from the neural crest and are the source of melanin pigment in human skin. They form a network in the basal layer of the epidermis with each melanocyte being related to a number of neighbouring keratinocytes by its dendrites. Melanocytes produce the pigment melanin in the form of subcellular organelles called melanosomes, which then migrate along the dendrites of the melanocyte into neighbouring keratinocytes. It is the number and distribution of these melanosomes within keratinocytes that determines skin pigmentation (Fitzpatrick et al. 1971).

It is thought that melanocytes have a fixed relationship to a set number of keratinocytes with which they have contact via their dendrites. The melanocyte and its related pool of keratinocytes is termed the epidermal-melanin unit (Fitzpatrick et al. 1967) (Fig. 8). The evidence for this relationship between the cells of the skin came from split skin techniques used in conjunction with incubation of skin with dehydroxyphenylalanine (DOPA) (Fitzpatrick et al. 1967). It was Fitzpatrick's group that established that the melanocyte is the sole site of melanin formation and that melanosomes are the pigment producing structures within melanocytes. Their paper, in

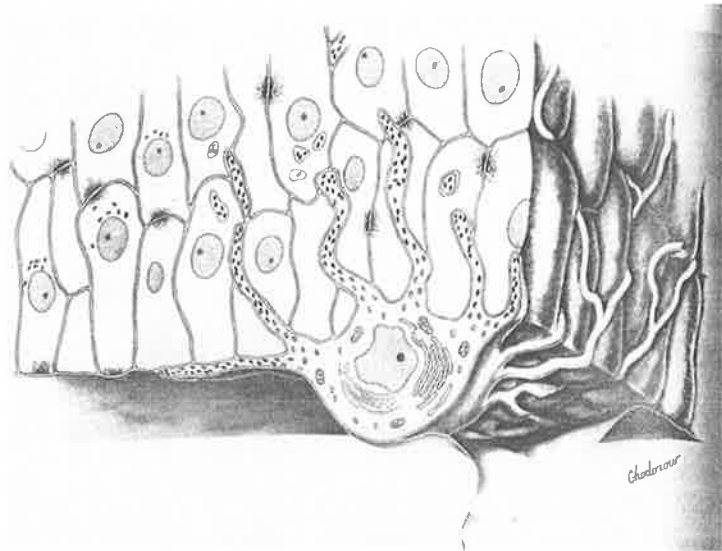


Fig. 8 The epidermal melanin unit (From (Fitzpatrick et al. 1967)) A melanocyte is seen at the level of the basement membrane interdigitating with a number of keratinocytes via its melanosome carrying dendrites.

1967, also introduced the idea that keratinocytes contribute to regulation of the rate of production of melanin by the melanocytes (Fitzpatrick et al. 1967). The ratio of melanocytes to the pool of keratinocytes (in the suprabasal as well as basal layers) in the epidermal melanin unit is approximately 1:36 (Frenk and Schellhorn 1969) but is variable between sites (Fitzpatrick et al. 1967; Montagna and Parakkal 1974).

1.2.1.2 Mechanism of skin pigmentation - sub-cellular level

Within the melanocyte, the spherical body containing the scaffolding onto which the pigment is deposited is known as a pre-melanosome or stage 1 melanosome. As melanin is deposited, the structure is categorised by its stage of maturity, as seen with electron microscopy (Fitzpatrick et al. 1971). Stage 2 melanosomes are ellipsoid in shape and show evenly spaced filaments within them. In stage 3 melanosomes the filaments within the structure are partly obscured by melanin. Stage 4 melanosomes are completely filled with pigment making the underlying filaments invisible.

When the melanosomes reach maturity they migrate from the perikaryon to the dendrites of the melanocyte and then to a related keratinocyte (Fig. 9). It was originally thought that melanocytes actively secreted melanosomes into the keratinocytes – the cytocrine theory (Fitzpatrick and Szabo 1959), but now there is increasing evidence to suggest that the keratinocytes play a more active role (Jimbow et al. 1983; Seiberg et al. 2000). The movement of melanosomes is a process subject to the influence of ultraviolet (UV) irradiation, with higher levels of UV causing increased melanosome migration and greater skin pigmentation (Jimbow et al. 1983).

Once the melanosomes have passed from the melanocyte's dendrite to the keratinocyte they may either remain solitary or be packaged together in secondary

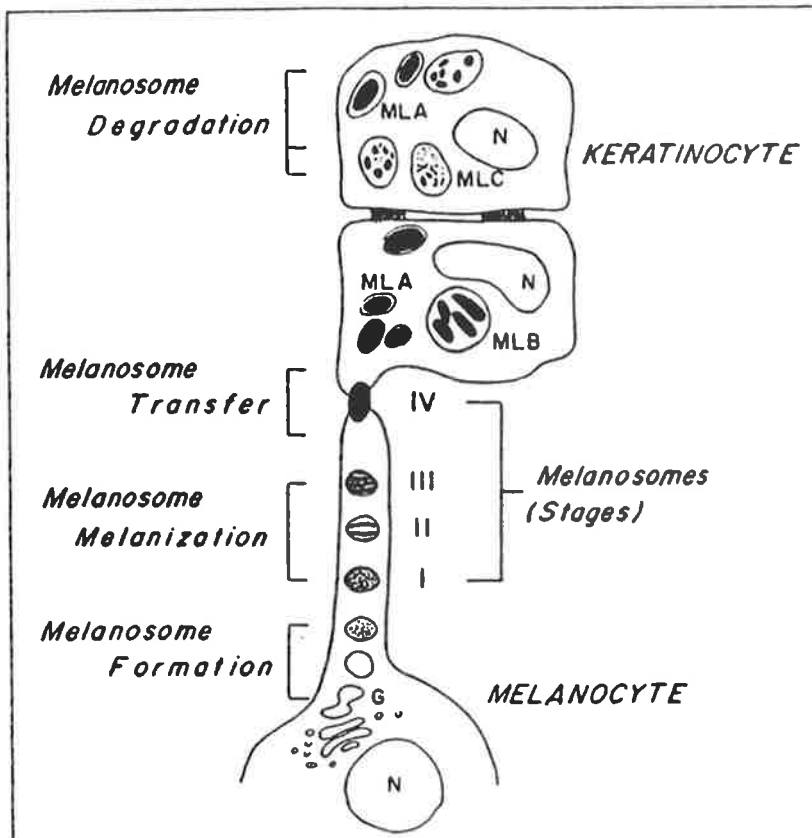


Fig. 9 Diagram illustrating melanosomes migrating from a melanocyte to a keratinocyte. In fair skin the melanosomes become grouped as they enter the keratinocyte cytoplasm (From (Fitzpatrick et al. 1967)).

lysosomes, depending on the type of skin. In intrinsically dark skin, melanosomes exist singly in the keratinocytes and in intrinsically pale skin, melanosomes are packaged in groups (Jimbow et al. 1983).

The amount of pigment in the skin is determined by the rate of breakdown of melanosomes as well as their rate of production. Melanosomes are broken down by enzymatic digestion within lysosomes in the keratinocyte's cytoplasm (Fitzpatrick et al. 1971).

1.2.1.3 Mechanism of skin pigmentation - molecular level

Melanin is the pigment produced in the melanocytes by the action of the enzyme tyrosinase. This single enzyme catalyses the conversion of tyrosine to dihydroxyphenylalanine (DOPA) as well as subsequent steps of the conversion of DOPA to a melanin polymer (Fig. 10) (Fitzpatrick 1950). This polymer then becomes strongly bound to an associated protein on the filament of the melanosome to give the final form of melanin pigment. The dominant monomers in eumelanin are dopaquinone, 5,6-dihydroxyindole-2-carboxylic acid and 5,6 dihydroxyindolequinone, and the three-dimensional arrangement of these monomers allows the resultant molecule to have some interesting properties: - melanin has an ability to undergo reversible oxidation and reduction reactions because of its ability to produce stable free radicals, it can bind copper ions, and bind with a number of organic molecules (Jimbow et al. 1983). Natural melanin's classically exist in two types, eumelanin (dark brown / black) or pheomelanin (yellow / red). Pheomelanin is unusual in its pure form and is only seen in humans in the hair of redheads (Lerner and Case 1959; Jimbow et al. 1983). In fact the reality is much more complex and there is evidence that many mixed types of melanin also exist (Hearing and Jimenez 1989).

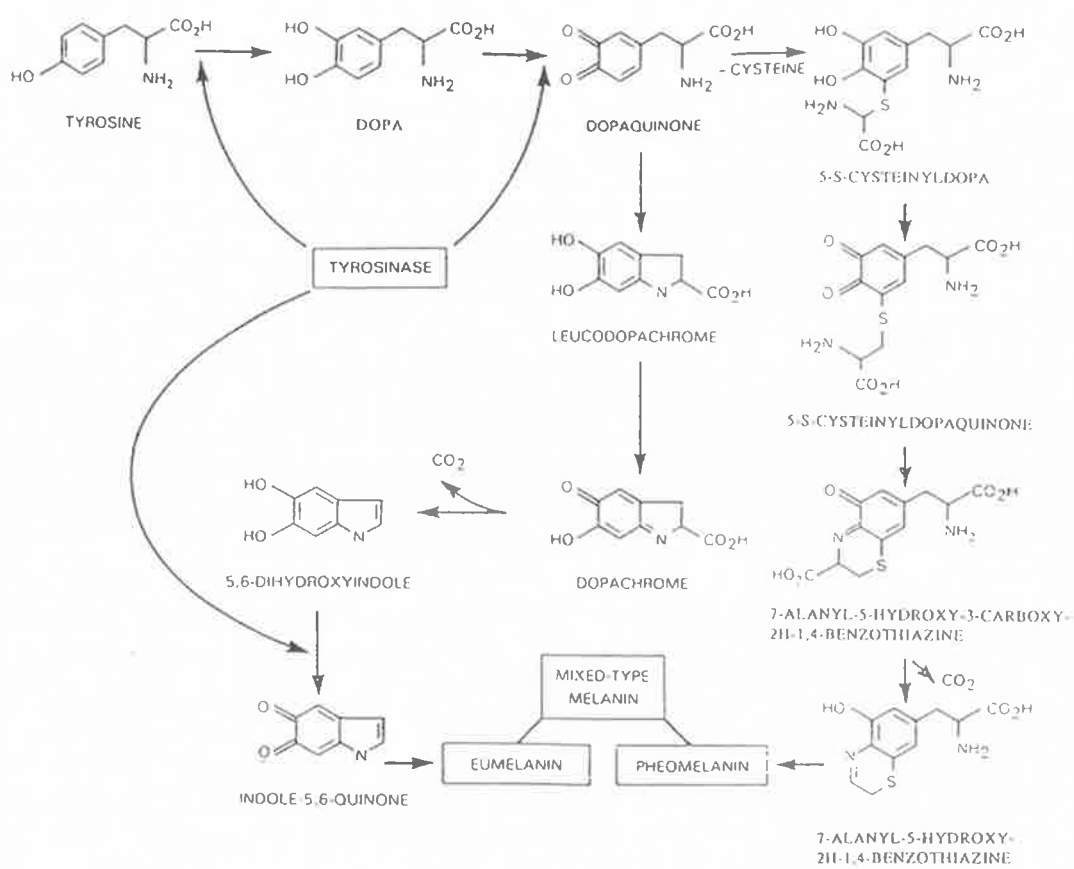


Fig. 10 The biochemistry of melanin production (from McLeod 1994)

The rate of melanin production is determined primarily by the rate of production and breakdown of tyrosinase (Fitzpatrick and Szabo 1959; Lerner and Case 1959), but an increasing number of other factors have now also been implicated in the regulation of melanin production, such as tyrosine inhibitors and activators and post-tyrosinase factors and enzymes (Hearing and Jimenez 1989).

The molecular mechanism for transfer of melanosomes from melanocyte to keratinocyte is still incompletely understood. Yamamoto and Bhawan suggest from ultrastructural studies that several mechanisms may co-exist: firstly, the insertion of a melanocyte's dendrite into the keratinocyte and subsequent digestion of the tip of the dendrite, secondly, a mechanism of membrane fusion allowing passage of melanosomes between cells and thirdly, exocytosis and subsequent endocytosis of individual melanosomes (Yamamoto and Bhawan 1994). There is also evidence that the protease-activated receptor 2 on keratinocytes plays an important role in melanosome transfer; it has been found that inhibitors of this receptor produce reduction in pigmentation and activators of the receptor produce increase in pigmentation in *in vitro* skin equivalents (Seiberg et al. 2000). Shoji and colleagues have found that the protein kinase C- α is an isoform that has differentially high levels in melanocytes compared to keratinocytes and that it may be implicated in melanocyte signalling (Shoji et al. 1998).

1.2.2 Early work on the normal pigmentation of human skin

Simon in 1840 was the first to document that there are pigmented cells in the female areola (Simon 1840; Becker 1958). In Becker's historical review of work on skin pigmentation he recorded that in 1912, Bloch and Ryhiner's development of the DOPA reaction (incubation of skin with a solution of L3,4 dihydroxyphenylalanine) to stain melanocytes was invaluable in the development of skin pigmentation research

(Becker 1958). In the 1930s, 40s and 50s there was an interest in determining how the pigmentation of human skin was derived in an effort to explain differences in skin colour. The appreciation of the melanocyte as the cell of pigment production led investigators to explore whether it was a variation in number of these cells that caused different pigmentation of the skin or whether it was some other factor. Edwards and Duntley published a substantial article on the pigments and colour of living skin. They described pigmentation as being primary (determined by genetic factors) and secondary (determined by exposure to UV) (Edwards and Duntley 1939). These authors used spectrophotometry to examine skin colour and investigated topographical variations in colour (ie variation between different sites in the body). They found that “the topographical distribution of pigments, including melanin, was identical in all the subjects studied” (ie there was no difference in topographical distribution between people of different ethnic origins). They also found that variation in skin colour between people could be accounted for entirely by differences in amount of melanin present. In their article, Edwards and Duntley showed a graph of reflectance vs. wavelength for the female breast and for the nipple and areola in one subject, but did not discuss these particular findings.

Staricco and Pinkus performed the first large quantitative study on the melanocytes in the skin. They used enzymatically split skin and the DOPA reaction to examine skin samples from surgical discard material from many sites in the body. However, they did not look at the nipple-areolar complex. They found that the number of melanocytes varied topographically but was not related to sex, age or ethnic origin. They found that in negroid* skin melanin was present in all layers of the epithelium whereas in fair skinned people melanin was confined to the basal layer (Staricco and Pinkus 1957).

* Terms used by authors of original paper, not this author's usage.

Staricco and Pinkus pointed out that the rete ridges of the dermis can alter the density of melanocytes as perceived from the skin surface. If melanocytes are spaced equidistant along the basement membrane, then from the surface, areas with underlying rete ridges appear more densely populated with melanocytes (Staricco and Pinkus 1957). Fitzpatrick and Szabo also verified that it was not the number of melanocytes that varied between people of different skin colour, but their capacity for melanin production (Fitzpatrick and Szabo 1959). What was not understood at this time was that the amount of melanin present is also related to the rate of degradation of melanin in lysosomes in keratinocytes.

Cochran in 1970 was the first to count melanocytes in vertical sections of normal skin. The purpose of his study was to provide an estimate of normal melanocyte numbers to act as a control for histopathologists examining vertical skin sections of those with pigmentary disorders or melanocyte tumours. Cochran looked at the variability of melanocyte count with age, sex and topography. He examined skin from a large number of sites on the body but did not include the female nipple-areolar complex (Cochran 1970).

In Cochran's quantitative work he used haematoxylin and eosin (H&E) staining only and counted the "clear cells" of the basal layer as melanocytes. Although he did use the DOPA reaction in one single specimen and stated that the DOPA stained cells were the same as the 'clear cells' in an H&E stained section of the same block, it is still debatable whether some of the clear cells may have been keratinocytes. His clear cell counts can therefore not be guaranteed to be true melanocyte counts. Cochran found that, on average, one in ten basal cell in the skin was a 'melanocyte'. He found no difference between the sexes and found that melanocyte count was higher in face, neck and arm skin, compared to the skin of the rest of the body (Cochran 1970).

1.2.3 Electron microscopy in the development of understanding of skin pigmentation

In 1961 Clark proved that the 'clear cells' of the epidermis were not all melanocytes, as previously postulated. He developed a modified DOPA reaction that could be used in conjunction with electron microscopy, allowing examination of the cytoplasm and dendrites of the cells. He found that only some of the 'clear cells' were dendritic and stained with DOPA. He concluded that the remaining cells were apoptotic 'clear keratinocytes' (Clark 1961).

With the development of electron microscopy, dermatologists and pathologists investigated the ultrastructure of cells in different disease states. Mishima found that the melanosomes of different naevi and other pathological entities showed certain typical characteristics and that normal melanocytes and naevus cells are ultrastructurally distinct (Mishima 1965).

Zelickson, in his book on the ultrastructure of normal and abnormal skin (Zelickson 1967), illustrated beautifully the electron microscopical features of the melanocyte:- dendritic processes, no desmosomes and minimal filaments, a round nucleus with a double membrane, a cord like nucleolus, rough endoplasmic reticulum and smooth endoplasmic reticulum, abundant mitochondria and melanin granules. Zelickson also described the use of time-lapse cinematography techniques in understanding melanocyte function. He found that melanin granules "streamed" from the tips of dendrites to epithelial cells. Yamamoto and Bhawan have been able to further elucidate the mechanisms of melanosome transfer (described above in section 1.2.1.3) in their ultrastructural study of Caucasian facial skin (Yamamoto and Bhawan 1994).

Mishima and Widlan proved conclusively that the DOPA reaction used for assessing the population of melanocytes, underestimated the number of melanocytes. They combined DOPA and pre-melanin silver reactions (with ammoniated silver nitrate) in split skin and used both electron microscopy and high power light microscopy to look at the specimens (Mishima and Widlan 1967). They found that there were 17 melanocytes per 100 basal cells in the skin samples (a melanocyte to keratinocyte (m:k) ratio of 1:6) when using the combined DOPA and premelanin technique, whereas 8.5 melanocytes per 100 cells (m:k of 1:12) were recorded with the DOPA reaction alone. The study also established that with ultraviolet irradiation of skin the total number of melanocytes increases, as well as more of the existing melanocytes becoming enzymatically active.

In reference to ultrastructural changes with exposure to ultraviolet radiation Fitzpatrick made the observation that “the most important factor in pigmentation of skin after UV radiation is the degree of melanization of the individual melanosomes rather than the number of organelles produced” (Fitzpatrick et al. 1971).

1.2.4 Histology of the nipple-areolar complex

Montagna performed the most complete study of the histology of the normal nipple and areola in specimens obtained from fresh cadavers (Montagna 1970). He observed that melanocytes were present deep in the lactiferous ducts and sebaceous glands of the nipple-areolar skin of women (not men or children) but the function of these melanocytes was unknown, as it clearly could not be for pigmentation at this depth (Montagna 1970). Montagna hypothesized that the more intense pigmentation of the nipple-areolar skin compared with surrounding skin was a mechanism for visual

sexual cues. He did not include a quantitative study of the melanocytes in the investigation of the nipple and areola (Montagna 1970).

A histological study of the glands of Montgomery in the human female areola found that these 'tubercles' were in fact lactiferous ducts and mammary glandular tissue. Sebaceous glands but no apocrine glands were present and large melanotic melanocytes were within the ducts (Montagna and Yun 1972). More recently, examination of Montgomery's areolar tubercles by conventional light microscopic techniques has confirmed that these tubercles are a culmination of a lactiferous duct and a free (ie not related to a hair follicle) sebaceous gland into a terminal duct (Smith et al. 1982).

1.2.5 Endocrine effects on the pigmentation of the nipple-areolar complex

Pigmentation of the nipple-areolar complex is linked to oestrogens. However, the relationship between oestrogen level and degree of pigmentation is not straightforward. The increased pigmentation of the nipple and areola in pregnancy, has been noted by several authors (Montagna and Parakkal 1974; Jimbow et al. 1983) but there has been little comment on the differential pigmentation of the nipple-areolar complex in the non-pregnant state. Davis and colleagues looked at pigmentary changes in women with ovarian failure who had been given exogenous oestrogens. They found that young women with primary ovarian failure developed pronounced hyperpigmentation with relatively small doses of oestrogens, whereas women with secondary ovarian failure did not develop any hyperpigmentation, meaning that oestrogen levels were not solely responsible for controlling pigmentation (Davis et al. 1945). Davis hypothesised that this difference could be related to differences in pituitary activity. Forty years later, Ranson and co-workers (1988) studied the effects of

oestrogens in cultured melanocytes (Ranson et al. 1988). They found that oestradiol produces an increase in tyrosinase activity in normal melanocytes but that this did not seem to be a classical receptor-mediated response.

Tadokoro and co-workers have shown that androgen receptors are present in genital skin melanocytes. It is not clear whether these melanocytes were neonatal foreskin melanocytes or from another source. This group have shown that cultured genital melanocytes have increased tyrosinase activity after the application of testosterone and suggest that this could also have a role in the darkening of the nipple-areolar skin at puberty (Tadokoro et al. 1997).

1.2.6 Further work on the pigmentation of normal skin

In 1988 Fitzpatrick produced a classification of skin types. The driving force behind this was to determine appropriate PUVA (psoralen and ultraviolet A) doses for treatment of psoriasis. Prior to this time, phenotypic features such as eye and hair colour had been used to determine likely sensitivity of skin to ultraviolet light. However, Fitzpatrick found this method to be unreliable for planning treatment. His classification depended on interviewing the patient about previous responses to sun exposure (Appendix XIII). He described six skin types, the first four being 'white' with different histories of response to sun exposure, the fifth being 'brown' and the sixth being 'black'. Inherently this classification system is very subjective and crude, but has been of use in clinical settings and is yet to be superseded (Fitzpatrick 1988).

Bhawan's group has been one of the few to investigate melanocyte and melanin content of normal human skin in recent times. Their study on the effect of topical tretinoin on sun damaged skin was a double-blind, randomised, controlled multicentre trial in which 533 subjects were enrolled (Bhawan et al. 1991). The area sampled in

this study was the “crow’s feet” periorbital skin. Punch biopsies were taken at the beginning of the study and after 24 weeks of treatment. Masson-Fontana staining of fixed, paraffin-embedded skin was used to assess melanin content of the skin. Although this is an old technique, it is still the best known way of demonstrating melanin in human skin (Bacharach-Buhles et al. 1999; Chiba et al. 2000). Melanocytic and keratinocytic cellular atypia were assessed by light microscopy using plastic 1µm sections stained with Polysciences Multiple Stain (PMS, Polysciences, Inc, Warrington, Pa) to identify the two cell types. The other parameters measured were dermal thickness, epidermal thickness and epidermal morphology. The results of the study were that tretinoin treated skin had increased epidermal thickness, increased granular layer thickness, decreased melanin content and stratum corneum compaction. This study was innovative in the way it combined old histochemical techniques such as the Masson-Fontana stain and new image analysis technology. A four year follow-up study using the same techniques found no untoward effects of tretinoin on keratinocytes or melanocytes (Bhawan et al. 1996).

1.2.7 Immunohistochemistry and the study of normal melanocytes

When the seminal work on normal skin pigmentation was performed, immunohistochemistry was in its infancy and was not available for routinely processed paraffin sections (Taylor 1994). Although it has been proven that the DOPA reaction is not accurate in counting all melanocytes (Mishima and Widlan 1967), there have been no publications repeating the melanocyte population studies of the 1950’s (Staricco and Pinkus 1957; Fitzpatrick and Szabo 1959) using modern immunohistochemical methods. The development of new antibodies for immunohistochemistry is primarily aimed at improving diagnosis of pathological conditions; hence most antibodies to

melanocytes have been tailored for the diagnosis of malignant melanoma in its various forms. The requirement of a good diagnostic antibody is a high specificity (ie it only attaches to melanocytes) and a high sensitivity (it attaches to all the pathological entities it purports to, every time). In terms of sensitivity of antibodies for detection of normal melanocytes, however, there is a high degree of variability which is often not measured. This is because staining of normal tissue is a byproduct of the staining of the pathological entity and not the central concern in most laboratories.

Polyclonal S100 was one of the first antibodies for the detection of melanoma. The S100 protein was originally discovered in brain tissue (Moore 1965) and its presence in melanocytes is a reflection of their neural crest origin. In the skin the S100 antigen is not specific to melanocytes, as it is also present in Langerhans cells, nerve fibres and nerve endings (Bhawan 1997).

S100 is in fact a family of proteins whose distribution in tissues is varied (Schafer and Heizmann 1996). The distribution of various S100 proteins in normal skin and melanocytic lesions was examined by Boni and colleagues. In this study of formalin fixed, paraffin-embedded tissues, the antibody against S100A6 stained keratinocytes, normal melanocytes and sweat glands faintly and was found to stain melanoma intensely. S100B was found in normal melanocytes, Langerhan's cells and primary and metastatic melanoma whereas other S100 proteins were not expressed in normal melanocytes. There was no discussion in this paper about the completeness of normal melanocyte staining, making it difficult to determine whether all melanocytes were stained and whether or not this was assessed (Boni et al. 1997). Bhawan has found that anti-S100 antibody underdetects normal melanocytes and he concluded that although anti-S100 is a useful antibody for staining melanocytic lesions, it is not reliable for the detection of normal melanocytes (Bhawan 1997).

A pre-melanosomal glycoprotein is the common antigen for two other available antibodies HMB-45 and NKI / beteb, which are used in the diagnosis of melanoma. Each antibody reacts with a different epitope of the same antigen (Adema et al. 1993) found mainly on early stage melanosomes and pre-melanosomes. This antigen is found exclusively in melanocytes, making these two antibodies specific to cells of the melanocyte cell line. However, Bhawan has found that HMB-45 does not reliably detect all normal melanocytes (Bhawan 1997). NKI / beteb reacts better in frozen sections than in formalin fixed paraffin embedded sections. Some amelanotic melanoma metastases do not react with NKI / beteb (because of their poor differentiation). In Vennegoor's paper (Vennegoor et al. 1988) there is little discussion of the sensitivity of NKI / beteb in normal melanocytes but a subsequent study by Adema and co-workers found that NKI / beteb did react in normal resting (ie non-dividing) adult melanocytes (Vennegoor et al. 1988; Adema et al. 1993).

Pigmentation-associated antigen (PAA) was originally identified in a patient with melanoma. Its function is unknown, but it is associated with melanization and may be a melanosomal structural protein (Thompson et al. 1985). The mouse monoclonal antibody to this antigen was originally named by its clone - TA99 but is also known as Mel-5. The antigen is also known as Tyrosine-related protein 1 (TRP1) and is identical to the glycoprotein gp75. Bhawan described the use of the antibody Mel-5 in formalin-fixed paraffin-embedded sections for the identification of normal melanocytes and for use in distinguishing melanocytic from non-melanocytic skin lesions. He reiterated the problem of confusing atypical keratinocytes with melanocytes in routine H&E staining (Bhawan 1997). Bhawan also made the point that the DOPA reaction for assessing normal populations of melanocytes is unsuitable because it only labels active melanocytes, whereas Mel-5 labels inactive and active melanocytes (Bhawan et al. 1995). The presence of melanocytes within basal cell carcinoma tumour nests has been

demonstrated using antibody TMH-1 - another tyrosine-related protein antibody but there are no reports of its use in normal skin (Kore-eda et al. 1998).

Jungbluth and colleagues have described a new antibody against tyrosinase called T311, which can be used for the detection of melanocytic lesions in paraffin-embedded tissues. This antibody was found to be specific to melanocytes and sensitive for the detection of melanoma, except for desmoplastic variants. T311 did detect normal melanocytes but the sensitivity for detection of normal melanocytes was not formally measured (Jungbluth et al. 2000). Vimentin is another protein which has been used as a label for melanocytes (Puches et al. 1991). It is a cytoskeletal component of melanocytes that is not present in keratinocytes. However, vimentin is also present in dermal fibroblasts, making differentiation between fibroblasts and melanocytes at the dermo-epidermal junction difficult. Mahrle and co-authors studied anti-vimentin staining in human skin and found that vimentin had a high specificity for melanocytes in the basal layer of the epidermis and did not stain basal keratinocytes but lacked sensitivity (Mahrle et al. 1983).

A serotonin-like substance has also been identified in melanocytes (Johansson et al. 1998). In this study of normal skin and cultured cells a serotonin antibody was used to establish the presence of serotonin in these cells. NKI / beteb was used as the baseline antibody for detecting normal melanocytes in human skin.

Several comparative studies have investigated the differences between the specificity of various antibodies in melanocytic lesions. In a study of the histological differences between pigmented solar keratosis and lentigo maligna, HMB-45, NKIC3, vimentin and S100 antibodies were used to identify melanocytes in formalin fixed paraffin sections of skin but no normal skin was used for comparison (Lane et al. 1993). Di-aminobenzamine (DAB) was used as a chromogen and melanin in the skin was bleached before staining to improve the visualization of immunostained cells. Lentigo

maligna was found to contain significantly more melanocytes than pigmented solar keratosis (Lane et al. 1993). Orosz performed a study comparing different antibodies against melanocytes. He compared the immunostaining of melanocytes with S100, HMB-45 and Melan-A (also known as Mart-1) in a large number of pathological conditions. He found that all three antibodies stained the naevus and melanoma specimens tested with varying intensity and found Melan-A to be the most reliable for not staining other soft tissue tumours. Although both studies (Land et al. 1993; Orosz 1999) provided valuable data on the immunostaining of abnormal melanocytes, neither study included comparisons with normal skin.

Perrin and colleagues (1997) performed a comprehensive study of melanocytes in the normal nail unit. Melanocytes in this area had been undetectable by the DOPA reaction in previous studies (Higashi and Saito, 1969). The antibodies used were S100, TRP-1 (Tyrosine related protein - 1 / Mel-5) and TMH as well as HMB45. Specimens were prepared as frozen sections, formalin fixed paraffin sections and split epidermal preparations. In the paraffin embedded vertical sections there was no staining with HMB 45 or S100. In the frozen sections melanocytes were stained but different antibodies reacted with varying intensities in different areas of the nail matrix. The density of melanocytes detected when monoclonal antibodies HMB45, TMH1 and B8G3 were used was found to be greater in the proximal nail matrix, but when monoclonal antibodies 2B7 and 5C12 were used to detect the melanocytes they were more numerous distally and scarcely present in the proximal nail matrix. This phenomenon is attributed to the fact that the proximal nail unit has melanocytes with pre-melanosome and stage 1 melanosomes (but hardly any stage III or IV melanosomes) and the distal nail unit contains more of the mature (stage III and IV) melanosomes. Split epidermal preparations were stained with the DOPA reaction and with TRP-1. Perrin found that more melanocytes were identified using the antibody to

TRP-1 (Mel-5) than were detected with DOPA (Perrin et al. 1997). The incomplete staining of normal melanocytes by anti-S100 and HMB-45 was also confirmed by Bhawan who found Mel-5 to be more sensitive (Bhawan 1997).

The immunostaining of normal melanocytes was also investigated in a study that focused on the role of stem cell factor (SCF) and its receptor KIT in the homeostasis of normal human melanocytes (Grichnik et al. 1998). This study used human skin transplanted onto immunodeficient mice, injected with either SCF or placebo. Routine H&E staining was used to identify 'clear cells' and these cells were counted as melanocytes. There was no comment on the problem of confusing apoptotic keratinocytes with melanocytes (which would give an overestimation of the number of melanocytes) and in fact this method was found to detect fewer melanocytes than immunohistochemical methods. Antibodies used were TRP-1 (Mel-5), gp100/ pmel-17 (NKI/beteb) and Ki67 - an antigen indicative of active cell proliferation. An important point was made that "melanocytic antigen expression is dynamic, with the amount of particular antigen expressed being dependent on the local conditioning of each cell". This investigation is the first report in the scientific literature that highlights the variability of antigen expression and subsequent immunostaining in normal melanocytes. Although this may seem obvious, this issue and its relation to immunostaining of normal melanocytes does not seem to have been previously been discussed in the literature. In this study, it was found that expression of melanocyte antigens increased with addition of SCF to the cells (Grichnik et al. 1998).

Grichnik et al. counted the number of melanocytes per length of epidermis but did not consider the influence of the degree of convolution of the basement membrane. Also, the results of melanocyte counts were expressed as cells per 0.5mm length of epidermis with the n being four. It is not clear what total length of epidermis was

measured or how the area was chosen for counting (ie was it a randomly chosen area or the most pigmented area?) (Grichnik et al. 1998).

The immunohistochemical staining of epithelial cell cultures and cultured skin substitutes is a field that is developing in parallel with cell culture techniques themselves. The DOPA reaction has been used to evaluate numbers of melanocytes in mixed keratinocyte and melanocyte co-cultures (Franzi et al. 1992). In this study there was no discussion about the issue of underestimating the number of melanocytes by the DOPA reaction. Si and co-authors studied the expression of vimentin in cultured neonatal melanocytes. They found that the cultured melanocytes stained with anti-vimentin antibody (immunofluorescence) and they then verified that it was vimentin and not peripherin that was being stained, by performing immunoblotting techniques (Si et al. 1993). The Mel-5 antibody against TRP-1 has been used successfully to stain melanocytes in frozen sections of cultured pigmented skin equivalents (Nakazawa et al. 1997).

It is apparent from the literature reviewed above that there is a paucity of knowledge of the immunoreactivity of melanocytes in normal skin. However, there will be an increasing need to have well defined norms for the immunohistochemistry of normal skin so that the reconstructed pigmented skin equivalents have standards for comparison. The pigmented skin equivalents themselves also need to be scrutinized closely and it is therefore important to know the likely immunoreactivity of these 'normal' cells.

1.3 THE EVOLUTION OF PIGMENTED SKIN EQUIVALENTS (Figs 11 & 12)

1.3.1 Production of skin components *in vitro*

Initial *in vitro* cultures of human epithelial cells from skin explants in the 1960s had a limited period of growth and viability (Karasek 1966; Briggaman et al. 1967; Andreassi 1992). The successful serial culture of human keratinocytes *in vitro* by Rheinwald and Green in 1975 overcame this problem and the stage was set for the production of clinically useful skin equivalents (Rheinwald and Green 1975; Green et al. 1979).

Once the technique for culturing keratinocytes was established, the next problem in making skin equivalents was the production of a dermal analogue. Bell was the first to produce a dermal construct by using human fibroblasts to stimulate a collagen gel (Bell et al. 1979). He envisaged that his tissue may be useful as an immunologically tolerated tissue for wound healing or as a model for the study of fibroblasts. One of the problems with Bell's model was the large degree of shrinkage of the construct. To reduce this phenomenon Bell used hooks to anchor the construct to its containing dish, but in spite of this, shrinkage was still a problem. The concept of anchoring the collagen gel was later developed by Auger's group in Canada. They used a ring of filter paper at the periphery of the petri dish to stop the collagen contracting inwards (Auger et al. 1998).

Soon after Bell's publication, Yannas and Burke described the principles of designing an artificial skin (Yannas and Burke 1980). A year later, Burke and Yannas published the first report of a dermal substitute that could be used clinically to replace skin in burns patients. Their model provided an artificial dermis plus a temporary silicone 'epidermis'. The dermal substitute was composed of bovine collagen and

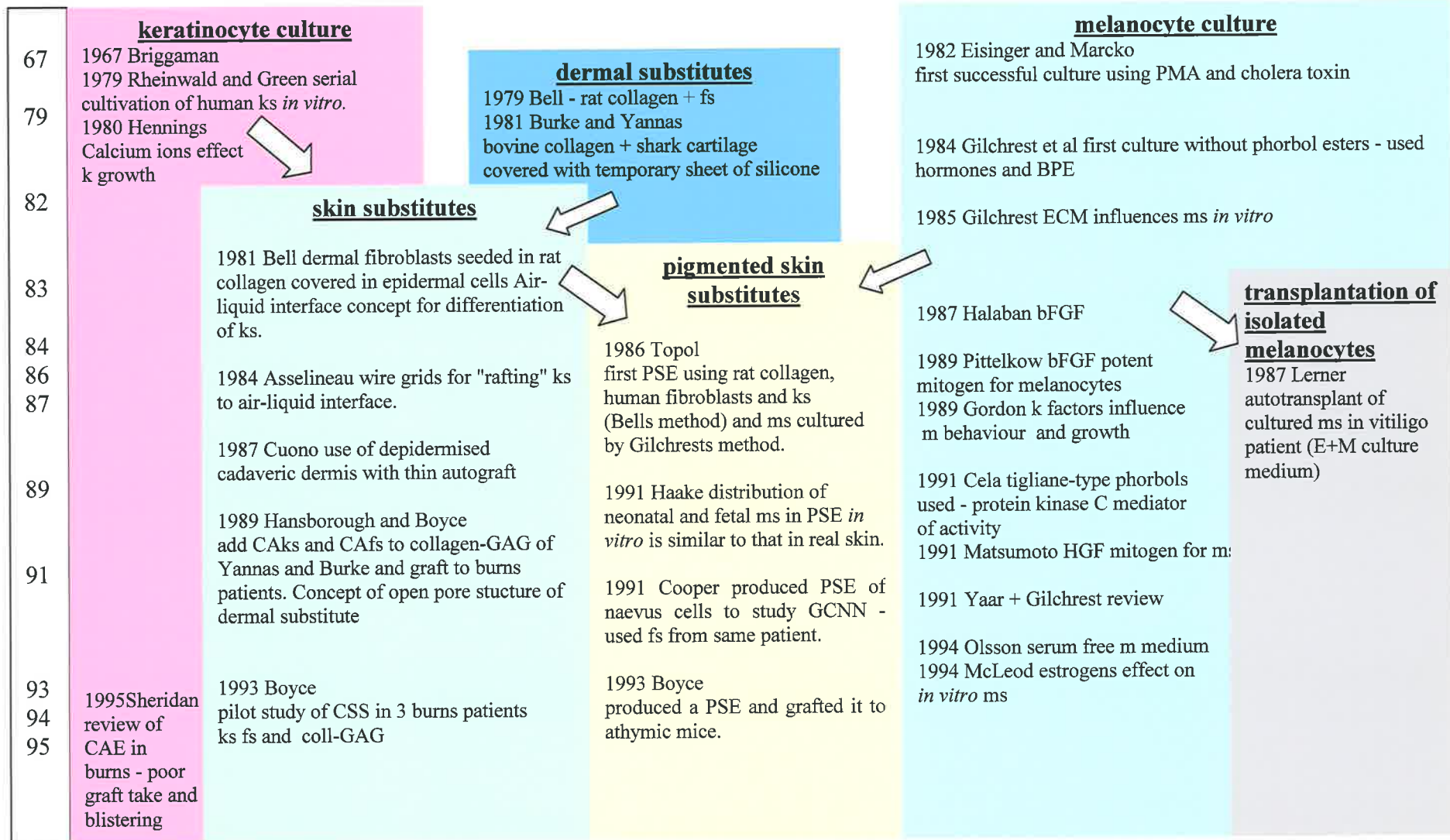


Fig. 11 The evolution of pigmented skin substitutes

	<u>skin substitutes</u>	<u>pigmented skin substitutes</u>	<u>melanocyte culture</u>	<u>transplantation of isolated melanocytes</u>
95	1995 Boyce compared CSS to skin grafting in 17 burns patients		1995 Swope physiologic medium for melanocyte culture	
97		1997 Swope cytometric sorting to regulate melanocyte content. 1997 Medalie Influence of dermal analogues on CSS pigmentation and m no.	1997 Kippenberger ms divide in the culture medium then reattach (timelapse photography)	
98		1998 Regnier Construction of a PSE containing ms, ks and Langerhans cells + acellular dermis 1998 Nakazawa PSEs respond to UVB like normal skin 1998 De Luca ? used PSE on burns patients? (unpublished)		1998 Olsson Treatment of leucoderma with basal cell enriched suspension
99		1999 Pellegrini and De Luca CAE with passenger ms and cadaveric dermis.		1998 Baltaci Used cultured naevi cells to pigment area of TRAM skin as a neo- areola.
00		2000 Stoner + Woods repigmented burn scar with CAE onto dermabraded dermis.		

Fig. 12 The evolution of skin substitutes (continued)

chondroitin 6-sulphate that acted as a scaffold into which fibroblasts and dermal matrix would grow. The silicone sheet could be retained until donor sites had healed sufficiently for reharvesting, at which time it was removed and replaced with very thin autograft. They described this as a “biodegradable template for the synthesis of a permanent neodermal tissue”. They ascribed the increased mechanical strength of their model, compared with collagen gel, to cross-linking of the collagen to the chondroitin 6-sulphate (a glycosaminoglycan (GAG)) and its fixation in glutaraldehyde. They also thought that the cross-linking was responsible for the controlled rate of degradation of the substitute’s collagen, which was so important in its success (Burke and Yannas 1981; Yannas 1984).

The development of this skin substitute allowed large burn wounds to be excised completely in the absence of sufficient donor skin for conventional grafting. The early excision and closure of such wounds is known to bestow a physiological benefit on these very ill patients (Burke and Yannas 1981).

Burke and Yannas tried their skin substitute on 10 patients with burns and reported “good to excellent” long-term clinical, cosmetic and functional results, although they admitted that they were limited by having only 16 months of follow-up. They showed vascular infiltration of the tissue and found that the neo-dermis more closely resembled native dermis than scar. They recorded high rates of “take” of the thin autograft. They also found that the persistent mesh pattern, usually characteristic of healed meshed split skin grafting placed directly onto a wound bed, was absent in the patients who had been treated with the dermal substitute. Their dermal substitute is now commercially manufactured as “Integra®” (Integra Life Sciences Corporation, New Jersey, USA).

1.3.2 Bilayered skin equivalents

The next stage in the process of producing a true skin substitute was to combine a dermal substitute with *in vitro* cultured keratinocytes. Bell again produced pioneering work in this field. He and co-workers were the first to produce a graftable bilayered skin equivalent (Bell 1981; Bell et al. 1981). Their model consisted of rat collagen seeded with dermal fibroblasts which was then allowed to contract before being covered with a human epidermal cell suspension. They successfully grafted these skin equivalents to rats and recorded long-term survival of cells and histological integrity of the construct (Bell et al. 1983).

De-epidermised human skin, porcine skin and human amniotic membrane have also been used successfully as substrates for producing skin equivalents (Regnier et al. 1984). Regnier's group found that keratinocytes harvested from a biopsy and suspended after trypsinization, could be seeded onto these dermal equivalents and produce differentiating keratinocyte cultures (Regnier et al. 1984).

Boyce and Hansborough showed that cultured keratinocytes could form biological attachments to their collagen / chondroitin sulphate dermal analogue, but it was important that the keratinocytes were sub-confluent before seeding. Confluent keratinocytes had a limited viability and did not form the same biological attachments (Boyce and Hansborough 1988).

1.3.3 Culture of human melanocytes *in vitro*

Development of skin equivalents has been paralleled by advances in *in vitro* culture of human melanocytes. Melanocytes have a negligible rate of mitosis *in vivo* and early melanocyte culture was hindered by the rapid overgrowth of cultures by

keratinocytes and contaminating fibroblasts. In 1982 Eisinger and Marko achieved selective melanocyte culture using phorbol esters and cholera toxin (Eisinger and Marko 1982). These additives to the culture medium were toxic to keratinocytes and promoted the growth of melanocytes. The group cultured both adult and neonatal melanocytes and found that neonatal melanocytes divided faster and could be maintained in culture longer than adult melanocytes (Eisinger and Marko 1982).

One of the drawbacks of Eisinger and Marko's method was that phorbol 12-myristate 13-acetate (PMA) is toxic, necessitating careful handling in the laboratory and causing a potential hazard to recipients of the cultured cells in clinical applications. Since then, it has been found that safer tigliane-type phorbol esters (such as 12-deoxyphorbol, 13-phenylacetate) have a similar mitogenic effect to PMA (Cela et al. 1991).

Gilchrest's group supplemented the culture medium with hormones to avoid use of phorbol esters; their medium contained insulin, bovine hypothalamic extract, thyronine, epidermal growth factor, fetal bovine serum, and cholera toxin (Gilchrest et al. 1984). Keratinocytes were eliminated from the culture within two weeks and 10x the initial inoculum of melanocytes were obtained within four weeks. Population doublings obtained for hormone-supplemented medium was up to 8.6 over 10 days for melanocytes from newborn skin and up to 2.4 over 10 days for melanocytes from adult skin. The number of passages achieved for newborn was six and for adult was two to three (Gilchrest et al. 1984). Melanocytes in prolonged culture without keratinocytes, become packed with densely melanized melanosomes, indicating that the melanocytes were still active in producing melanin but were not able to discharge it (Gilchrest et al. 1984).

Neilsen's group in Denmark used a third approach to melanocyte culture. They used the physical differences between keratinocytes and melanocytes to separate the

cells by differential centrifugation. They found that although separation of the two cell types was incomplete, if cultures with predominately melanocytes were cultured in selective medium, contaminating keratinocytes were then lost on passaging and subculturing (Nielsen and Don 1984).

1.3.4 Advances in keratinocyte culture

Further developments were also made in the culture of human keratinocytes *in vitro*. Hennings discovered the importance of calcium ions on the growth of keratinocytes in culture (Hennings et al. 1980). The same group observed that the degree of phenotypic expression or differentiation of cultured cell lines varied depending on a wide range of factors. Holbrook and Hennings reviewed critically the scientific methods of various culture techniques for the manipulation of differentiation of epidermal cell cultures (Holbrook and Hennings 1983). Boyce and Ham furthered this work and found that the calcium level in the medium had a profound effect on the balance between keratinocyte differentiation versus mitosis. They found that the higher the calcium level was in the medium, the greater the amount of stratification and differentiation of cells (Boyce and Ham 1983; Boyce and Ham 1985).

Boyce and Ham went on to describe a keratinocyte medium free of serum, containing only defined factors (MCDB153). Epidermal growth factor, bovine insulin and hydrocortisone were essential elements included (Boyce and Ham 1983; Boyce and Ham 1985). The importance of having a defined medium was that the culture conditions were reliable and reproducible. Serum-free cultures are also preferable from the perspective of transmission of disease. Tenchini et al confirmed that the serum-free method can produce adequate keratinocyte growth and was preferable for studies on the biology of keratinocytes (Tenchini et al. 1992).

The long-term viability of epithelial cell cultures is of great importance for the possibility of generating clinically useful skin substitutes. The population dynamics of cultured keratinocytes were studied by Milstone, who found that the keratinocytes *in vitro* had a dynamic behaviour pattern similar to that *in vivo*, in contrast to cultures of other cell lines (Milstone 1983).

The use of an air-liquid interface has been found to produce differentiation of keratinocytes into the characteristic layers seen *in vivo*. The technique involves culturing the cells submerged in medium at first and then lifting them on grids to the surface of the medium (Bell et al. 1983; Asselineau and Prunieras 1984). Keratinocytes can also be raised to the surface of the medium by placing them on allogenic (pig) dead de-epidermised dermis (Prunieras et al. 1983). The contact the keratinocytes have with the air appears to stimulate their differentiation (Verrando and Ortonne 1984).

1.3.5 Early pigmented skin equivalents and further advances in melanocyte culture

Topol and co-workers were the first to create a pigmented skin equivalent *in vitro*. They used Bell's dermal substitute of human fibroblasts seeded in rat collagen. Melanocytes, cultured by Gilchrest's hormone-supplemented medium method, were placed on the dermal equivalent at the same time as keratinocytes that were derived from human skin explants (Topol et al. 1986).

Topol's group established that melanin can be transferred from melanocytes to keratinocytes *in vitro* and that the proximity of melanocytes to keratinocytes affects pigment transfer. They also found that melanocytes trapped deep in the dermal equivalent became highly pigmented and that UV irradiation caused increased pigment transfer from melanocytes to keratinocytes as well as larger melanosomes in the melanocytes (Topol et al. 1986).

In vitro culture of melanocytes was not only of interest for skin equivalents but also for the purposes of studying melanocyte and melanoma behaviour and for understanding the complex cell - cell interactions in the skin. In the mid-1980s melanocyte-only cultures were used as models for experiments in these fields but these have the intrinsic problem that melanocytes have been artificially stimulated and are existing in an abnormal environment.

Halaban's group looked at the culture characteristics of different types of melanocytes and found that neonatal melanocytes would proliferate for up to 6 months, in contrast to adult melanocytes which could only be sustained for one month. They found that melanocytes from naevi could be cultured for four to six weeks, in contrast to melanocytes from melanoma which were difficult to culture and inhibited by phorbol esters (Halaban et al. 1986). This was a shortcoming in the phorbol ester method, for those wishing to study melanoma cells *in vitro*. Halaban also showed that bFGF a mitogen for melanocytes which comes from co-cultured keratinocytes *in vitro*, is likely to be the natural mitogen for melanocytes *in vivo* (Halaban et al. 1987; Halaban et al. 1988).

Herlyn studied the factors needed to produce melanocyte culture *in vitro*. Neonatal melanocytes were used in these studies and growth was found to be optimal when the phorbol ester PMA, basic fibroblast growth factor, insulin and synthetic alpha melanocyte-stimulating hormone were all included in the medium (Herlyn et al. 1988).

A clinical application for isolated melanocyte culture is the replacement of absent or inactive melanocytes in patients with hypopigmentary disorders of the skin. Lerner and co-workers described the successful auto-transplantation of cultured melanocytes in a patient with vitiligo, using a modification of Eisinger and Marcko's original method for isolated melanocyte culture (Lerner et al. 1987). They did not discuss the implications for the patient of returning to him melanocytes that had been

cultured in a mutagenic environment. Their method involved raising suction blisters on the skin over the hypopigmented areas and injecting cultured melanocytes, which were derived from a normally pigmented patch of skin. Repigmentation was not successful in all the areas treated (Lerner et al. 1987).

Hirobe et al cultured neonatal melanocytes successfully and found that the skin colour of the donor influenced their growth characteristics (Hirobe et al. 1988). Melanocytes from black donors contained mature stage IV melanosomes, whereas melanocytes from white donors contained no mature melanosomes.

Pittelkow and Shipley contributed some important advances in techniques of melanocyte culture. Firstly, they further developed the concept of using physical characteristics to separate keratinocytes and melanocytes that was first used by Neilson and Don (1984, see section 1.3.3). They found that washing a co-culture of keratinocytes and melanocytes with a dilute solution of trypsin and EDTA (ethylenediaminetetra acetic acid) resulted in preferential detachment of the melanocytes from the culture flask. The melanocytes could then be gently tipped out of the flask and a separate culture established (Pittelkow and Shipley 1989). The medium that Pittelkow and Shipley used for their cultures was based on the concept that basic fibroblast growth factor (bFGF) is a powerful mitogen for melanocytes. They simply combined this growth factor with Boyce and Ham's defined keratinocyte medium MCDB153 with minor modifications (Pittelkow and Shipley 1989). A second important finding of this group was that melanocytes that had been in a primary culture with keratinocytes proliferated much better than those which had been cultured separately *ab initio* - suggesting that keratinocytes had a mitogenic effect on the melanocytes (Pittelkow and Shipley 1989).

The interrelations of keratinocytes and melanocytes were also independently being investigated by Gordon and colleagues. They found that bFGF only acted as a

mitogen for melanocytes if those melanocytes had been exposed to keratinocytes. They found that once melanocyte cultures are established by using a melanocyte mitogen-containing medium, melanocyte growth, melanisation and dendricity *in vitro* is influenced strongly by factors from keratinocytes. Only neonatal melanocytes were cultured in the experiments and so it is not known whether similar results would be obtained for adult melanocytes (Gordon et al. 1989).

1.3.6 Clinical experience with cultured keratinocytes and skin substitutes

By the early 1990s sheets of cultured epithelial autografts had been used to cover burn wounds in several centres (O'Connor et al. 1981; Woodley et al. 1988; Munster et al. 1990; De Luca et al. 1992; Donati et al. 1992; Rue et al. 1993). However, these sheets were delicate, difficult to handle and did not always 'take' successfully to the wound bed. Woodley and co-authors noticed a tendency of the cultured epidermal autografts to blister more easily than normal skin, even months after the grafting procedure and attributed this to the failure of the keratinocytes to develop anchoring fibrils (Woodley et al. 1988). In a review of five cases with massive burns, Sheridan and Tompkins found a 51% initial engraftment rate and described a relationship between graft failure and episodes of systemic sepsis. They also found a high incidence of late blistering of the cultured autologous epithelium which often required replacement. They concluded there was a need for a more robust and reliable tissue for this role (Sheridan and Tompkins 1995).

In 1987 Cuono et al. reported the use of cultured autologous keratinocytes in conjunction with de-epidermized cadaveric allograft skin in two burns patients. His rationale was that the elements of skin producing an immune reaction were those cells carrying class II major histocompatibility complexes and these cells are mainly in the

epidermis. The method reported was to debride the burn acutely and cover it with freeze-thawed cadaveric allograft skin. Simultaneously, skin biopsies were taken to culture autologous keratinocytes. Once the allograft had "taken" and the keratinocyte cultures had reached confluence, the allograft epidermis was removed by dermabrasion and replaced with a sheet of cultured keratinocytes. Histologically the keratinocytes developed biological connections with the allogeneic dermis, including anchoring fibrils. Although the allogeneic dermis was reported as being permanent there was also no definitive testing (such as DNA analysis) to confirm that the allogeneic dermis was permanent and not replaced by the host cells (Cuono et al. 1987). This method is reported to have produced a useful skin equivalent but only limited conclusions can be drawn from such a small study (Cuono et al. 1987).

Boyce and Hansborough showed that cultured keratinocytes could form biological attachments not only to dermis but also to a collagen / glycosaminoglycan dermal analogue. They found that it was important that the keratinocytes used were sub-confluent before seeding; keratinocytes cultured to confluence had a limited viability and did not form the same biological attachments (Boyce and Hansborough 1988).

In 1989 Hansborough and Boyce applied this method clinically, closing burn wounds in four patients using cultured autologous keratinocytes attached to a collagen-glycosaminoglycan dermal substitute, with the addition of cultured autologous fibroblasts (Hansborough et al. 1989). They reported reconstitution of the basement membrane and anchoring fibrils within nine days of grafting. Macroscopically they found that four of their 13 composite skin grafts failed and that failure related to wound bed colonisation. Although they reported some ulceration of the composite graft they did not see the massive epidermal sloughing seen with epidermal sheets alone. They

described good clinical results in terms of skin integrity but did not show any long-term results.

Hansborough, Boyce and co-workers attributed the successful fibrovascular ingrowth into the skin substitute to the open pore structure of the collagen / glycosaminoglycan dermal substitute (Hansborough et al. 1989). This group has since published a study of patients comparing cultured skin substitutes (CSS) with conventional autografting in major burns cases (Boyce et al. 1995). They examined outcomes in 17 patients who had both meshed split skin grafting and grafting with cultured skin substitutes (keratinocytes on a fibroblast infiltrated collagen-glycosaminoglycan dermal substitute) on paired sites. The type of graft for each of the sites was randomly chosen. Joints, hands and face were excluded as recipient sites. Assessment of erythema, pigmentation, epidermal blistering, surface texture, skin suppleness and scar height were assessed on an ordinal scale 14 days after grafting. The skin substitute was reported to have a reduced area of initial engraftment with slower vascularisation and greater mechanical fragility compared with autograft. However, there were no reports of late blistering of the "epidermis" in the cultured skin substitute, in contrast to the reports of blistering found when epidermal sheets alone are used (Sheridan and Tompkins 1995). Cultured skin substitutes were reported as becoming hyperpigmented, but whether this was patchy or uniform was not stated. The group found that results with the skin substitute improved over the course of the study and that this could partly be attributed to better control of microbial contamination. Histology of the grafted cultured skin substitute showed a keratinised epithelium of equivalent thickness to split skin graft. Boyce showed that the collagen-glycosaminoglycan component of his skin substitute is degraded and replaced by new collagen which is arranged in a 'basketweave' pattern, similar to native dermis and not in the linear bundle pattern seen in scarring (Boyce et al. 1993). Complete basement membrane was

present within two weeks of grafting with this skin substitute and was mature by 3 months (Boyce et al. 1993; Boyce et al. 1995; Nemecek and Dayan 1999). A criticism of this study is that more than half the enrolled patients did not receive cultured skin substitutes, the reasons given were that the patient either died or the “medical staff elected not to apply CSSs”. The article does not say how many patients were in each category, so it is difficult to know how much patient selection may have influenced the results (Boyce et al. 1995). All assessments were by the investigators rather than by independent observers, which may have influenced the results. Boyce acknowledged this weakness in the study and emphasised the need for further studies with less subjective elements (Boyce et al. 1995).

Harriger and co-authors have also reported using a collagen glycosaminoglycans and cultured keratinocyte skin substitute to replace skin in 5 burns patients. They reported that repigmentation from passenger melanocytes took place within 2 months (Harriger et al. 1995).

1.3.7 Further work on melanocyte culture *in vitro*

Medrano and Nordlund (1990) found that MCDB153 (the keratinocyte medium of Boyce and Ham) could be modified for the co-culture of melanocytes and keratinocytes. The medium contained low concentrations of tetradecanoylphorbol-13-acetate (TPA) and calcium. It contained bFGF, crude bovine pituitary extract, insulin, transferrin, hydrocortisone, 5% FCS and α -tocopherol (Medrano and Nordlund 1990). They addressed the culture of adult, not neonatal or fetal melanocytes, and found that they could achieve four to eight passages and considerable expansion in melanocyte numbers up to 2-7 million cells over a period up to six months. Population doubling of 6.22-8.45 occurred (Medrano and Nordlund 1990). This work established that

melanocyte culture was less demanding in terms of mitogen requirements when keratinocytes were present in the culture.

In a study of suitable media for development of skin substitutes, it was found that composite skin substitutes incubated with the keratinocyte differentiation medium (of Boyce and Ham) plus bFGF and keratinocyte growth medium had partial or no pigmentation whereas skin substitutes cultured in keratinocyte differentiation medium containing EGF with melanocyte growth medium plus phorbol ester and 5% fetal bovine serum, had complete pigmentation (Boyce et al. 1993).

In the early 1990s the effects of naturally occurring substances on melanocyte proliferation was the subject of several investigations. Matsumoto found that rat hepatocyte growth factor (HGF) was a mitogen for human melanocyte growth and that its action was synergistic with bFGF (Matsumoto et al. 1991). Krasgakis and co-workers reported that interferon gamma and interferon alpha inhibited proliferation of melanoma cells *in vitro* but not normal melanocytes *in vitro* (Krasagakis et al. 1991). Interferon beta and gamma also caused normal melanocytes to become more like melanoma cells in their morphology and antigen expression (Krasagakis et al. 1991). TPA was also found to alter the phenotype of *in vitro* cultured melanocytes to that of melanoma cells implying that melanocytes cultured in the presence of TPA can not be considered 'normal' for the purposes of physiological studies (Krasagakis et al. 1993). McLeod et al established that 17 β -oestradiol enhances tyrosinase activity of cultured melanocytes from normal human skin. However, this response of pigment cells is not mediated by the classical receptor, as antibodies to this receptor do not bind to the melanocytes (McLeod et al. 1994). Melanocyte stimulating hormone and adrenocorticotrophic hormone have also been found to be mitogenic and melanogenic for cultured melanocytes (Abdel-Malek et al. 1995; Swope et al. 1995).

Yaar and Gilchrest published a review of human melanocyte culture (Yaar and Gilchrest 1991). They summarised that -

- bFGF stimulates melanocytes in culture but also stimulates melanoma,
- serum increases yields in melanocyte culture,
- keratinocytes produce factors that stimulate dendricity in melanocytes
- surfaces coated with fibronectin of type I / III collagen facilitate melanocyte attachment.
- melanocyte morphology is probably influenced by basement membrane and extracellular matrix.
- melanocytes also synthesize basement membrane components *in vitro* suggesting that they probably contribute to production of the basement membrane.
- less differentiated pre-melanocytes are paler and tend to have fewer dendrites than adult melanocytes.
- protein kinase C is an important mediator in melanocyte stimulation.

Studies of melanocyte cell cultures has improved understanding of which characteristics of melanocyte behaviour are intrinsic (and conserved *in vitro*) and which are determined by extrinsic factors. For example, Haake and Scott (1991) found that the difference in pattern of melanocyte distribution in fetal and neonatal skin is determined by the melanocytes themselves, as cultured neonatal and fetal melanocytes within a skin equivalent model assume the same distribution as *in vivo*. These authors also demonstrated transfer of melanosomes from melanocytes to keratinocytes in the skin equivalents (Haake and Scott 1991). The pigmentary phenotype of melanocytes also seems to be an intrinsic property, as this is conserved throughout their lifespan *in vitro* (Swope et al. 1995). Hence, if a melanocyte is from a dark skinned person, the

melanocyte will continue to be densely pigmented and transfer large amounts of melanin to surrounding keratinocytes *in vitro*.

The response to ultraviolet light is another property retained by melanocytes *in vitro*. This attribute was exploited by Dubertret who used ultra violet light to promote the growth and migration of melanocytes from a foreskin explant over the surface of a dermal equivalent (Dubertret and Coulomb 1994).

As melanocyte mitosis *in vivo* is an infrequent phenomenon, it has not been possible to study the mechanics of melanocyte mitosis prior to cell culture. In an elegant time-lapse photography study, Kippenberger and colleagues showed that melanocytes retract their dendrites when they undergo mitosis *in vitro* and become spherical before detaching from the support medium and dividing. After mitosis they re-attach and form new dendrites. Kippenberger's group concluded that for optimum melanocyte population expansion *in vitro*, these floating mitotic melanocytes should be preserved when exchanging culture medium (Kippenberger et al. 1997).

1.3.8 In search of normal pigmentation for skin substitutes

Although advances in melanocyte culture have been made, normal pigmentation in skin substitutes remains an elusive goal. Boyce's group produced a cultured skin substitute for clinical use in patients with large burns, but found that pigmentation of the cultured skin substitute is unsatisfactory. Cultured autologous epithelium with or without the dermal substitute of collagen-glycosaminoglycan gave hypopigmentation with small areas of hyperpigmentation. This phenomenon was attributed to the survival and subsequent local proliferation of a few passenger melanocytes in the 'selective' keratinocyte medium (Boyce et al. 1991). In contrast, burn wounds treated with epithelium cultured by the method of Rheinwald and Green (1975) have been reported

by one group (De Luca and Cancedda 1992) as resulting in normal pigmentation and distribution of melanocytes. De Luca's group did report that pigmentation after grafting of cultured epithelial autograft was slow (four weeks to six months) and the reason for this is unknown (De Luca and Cancedda 1992; Franzi et al. 1992).

With the aim of producing skin substitutes of normal pigmentation, Boyce's group added melanocytes to their keratinocyte and fibroblast-containing collagen-glycosaminoglycan skin substitute and successfully grafted it to athymic mice. The melanocytes were cultured separately in a medium containing phorbol esters and fetal bovine serum. Keratinocytes and melanocytes were then seeded onto the dermal substitute at a ratio of 30:1. No explanation for the derivation of this ratio was given. The control group of mice received cultured skin substitutes with epithelium cultured in a standard keratinocyte medium from caucasian donors with no added melanocytes. The melanocytes used for selective culture were pooled from multiple donors, some of whom were dark skinned. This made comparisons of the control group with the melanocyte-added group difficult. However, the research did demonstrate that pigmentation was homogeneous, not patchy, when separately cultured melanocytes were included in the skin substitute (Boyce et al. 1993). Boyce found evidence that melanosomes were transferred to keratinocytes in the grafted cultured skin substitutes but that melanosomes within the keratinocytes at the *in vitro* stage were rare. This contrasts to earlier research where melanosome transfer to keratinocytes occurred *in vitro* (Topol et al. 1986; Haake and Scott 1991).

Boyce's research group incidentally found several limitations of the athymic mouse model - firstly that hyperkeratosis of the CSS graft occurred and secondly that the area of pigmentation receded over time. Additionally, the grafting of normal human skin to athymic mice produced hyperpigmentation over time - making it difficult to interpret the results and extrapolate to grafting in humans (Boyce et al. 1993).

Boyce's group raised the issue of the long term risks of using melanocyte mitogens such as phorbol esters in skin cell culture for clinical applications. The next hurdle was to find a melanocyte culture medium which was chemically defined and free of toxic mitogens (Boyce et al. 1993). Swope and co-workers (1995) identified physiological mitogens that could support long-term proliferation of melanocytes. They used α -melanotropin, endothelin-1 and basic fibroblast growth factor in place of phorbol esters and bovine pituitary extract and thus provided safer agents for use with melanocytes destined for transplantation:- "the growth medium hereby described is advantageous in that it lacks nonphysiologic, and potentially hazardous, mitogens such as TPA and cholera toxin, diminishes the dependency on variable, undefined constituents such as bovine pituitary extract (BPE), and allows for rapid and long-term proliferation of melanocytes for extensive experimental or clinical uses."(Swope et al. 1995).

Swope's group derived some of their cultured melanocytes from adult breast skin. These melanocytes were found to proliferate more slowly than those from neonatal foreskins but they did proliferate over a period of 8 days. Proliferation in the TPA-containing medium was not significantly different from that in the more physiological medium. Melanocytes cultured in Swope's physiological melanocyte medium also maintained tyrosinase activity. Swope's group looked exclusively at melanocyte-only cultures, and not co-cultures with keratinocytes or fibroblasts (Swope et al. 1995).

Swope's group also carried out an experiment to look at ways of regulating the number of melanocytes seeded into a cultured skin substitute. An epidermal culture was depleted of melanocytes by cytometric sorting, then melanocytes were reintroduced in a quantitative manner, in an attempt to achieve homogeneous pigmentation. However, the melanocytes reintroduced to the cultures were much darker than those of

the native skin (as was the case in Boyce's previous study (Boyce et al. 1993)), making it impossible to draw any conclusions on the intensity of pigmentation of the comparative groups. The reasons for using keratinocytes plus 4% melanocytes as the control group were not given and it was not made clear how these initial ratios were established (Swope et al. 1997). It appears that flow cytometry can be used to regulate the ratios of cells in a co-culture initially, but it is not clear what the long-term outcome of such a procedure is, in terms of pigmentation. This technique is also unlikely to be practical for producing pigmented skin substitutes for clinical use (Boissy et al. 1989; Swope et al. 1997).

1.3.9 The issue of safety in cultured skin substitutes

There are several safety concerns associated with cultured skin substitutes. There is the risk of pathogen transmission when allogeneic cells are used and the potential risks of genetically modified cells (Boyce et al. 1995, Nemecek and Dayan 1999). Meier's group have demonstrated that the effect of bFGF on normal melanocytes in skin reconstructs is not the same as that on melanoma cells. It has been shown that bFGF is critical for progression of the reconstructed 'melanoma' but has no effect on the distribution of normal melanocytes (Meier et al. 2000). All authors agree that it is important that safety issues are considered when generating skin substitutes for clinical application.

1.3.10 The influence of the dermis on melanocyte behaviour

As well as the influence of culture media and keratinocytes on melanocytes, the influence of the extracellular matrix and various dermal components are increasingly

being recognised. Although the influence of the substrate on melanocyte culture was identified by Gilchrest and co-workers (1985), almost a decade elapsed before publications again appeared in the field of melanocyte culture. "Composite grafts have been used to study melanocyte function *in vitro* and *in vivo* but little attention has been paid to the influence of the dermal substrate used to generate the composites" (Medalie et al. 1997).

Medalie's group produced composite skin substitutes *in vitro* by removing the epidermis from cadaveric skin and rendering it acellular by a series of freeze-thaw cycles. Keratinocytes were then seeded on to the dermis and the composite skin maintained *in vitro* for 1 week before grafting onto nude mice. The graft repigmented completely and histologically, melanocytes were normally distributed along the basement membrane (Medalie et al. 1996).

In a comparative study of different dermal analogues and their influence on the behaviour of the skin substitute as a whole, Medalie and colleagues compared acellular cadaveric dermis (with no added live fibroblasts) with fibroblast-contracted collagen gels. Interestingly collagen / glycosaminoglycan dermal substitutes were not used in the study even though these were being used clinically in the same institution (Medalie et al. 1997). Both dermal analogs in the study were seeded with keratinocytes from "dark skinned" neonatal foreskins. The precise meaning of "dark skinned" was not given. Melanocytes reportedly survived as passenger cells in the keratinocyte culture but methods of identification and quantification were not clear. Once the cultured skin substitutes had been at the air-liquid interface for one week they were transplanted onto full thickness defects on athymic mice (Medalie et al. 1997). Because the donors of the cells were dark skinned, the melanocytes in the final cultured skin substitute could be visualised with light microscopy. Cultured skin substitutes produced using acellular dermis were found to attain rete ridge formation, whereas in the collagen gel model a

flat interface was seen between epithelium and neo-dermis. Microscopically, in the collagen gel construct the melanocytes were found to be few in number and clustered together whereas in the acellular dermis cultured skin substitute, melanocytes were more numerous and evenly spread. Histologically, in the keratinocytes of the cultured skin substitute that contained acellular dermis, at one week melanocytes and pigmented keratinocytes were not evident but melanin was present in keratinocytes at six weeks (Medalie et al. 1997).

Pigmentation of grafts in the acellular dermis model was initially focal and became generalised over time. In the case where acellular dermis was the dermal analogue, 92% of the total area of the total cultured skin substitute had repigmented within six weeks. However, no comments were made on changes in intensity of pigmentation and no comparisons with the pigmentation of the intact donor skin were made. In the collagen gel construct only small foci of pigmentation persisted. Medalie's group suggest that "type IV collagen and laminin significantly increase melanocyte attachment and migration *in vitro*" accounting for the differential pigmentation of the two substitutes.

This important study underlines that the attainment of good pigmentation of cultured skin substitutes may not depend on the ratio of keratinocytes to melanocytes that is present in the transplanted CSS but may depend much more on the dermal analogue being conducive to proliferation and redistribution of the melanocytes.

Regnier and co-workers succeeded in experimentally producing an even more physiologically complete skin substitute by constructing a skin equivalent containing keratinocytes, melanocytes and Langerhan's cells. Olsson's serum-free and phorbol-free culture medium was used for the melanocytes and Rheinwald and Green's method used for keratinocyte culture. The issue of carrier melanocytes in the keratinocyte cultures was not considered. They seeded melanocytes to keratinocytes at a ratio of

1:10 but did not report how they derived this ratio. Acellular human dermis was used as the dermal component of the skin construct (no live fibroblasts were present). It is thought that in acellular dermis it is unnecessary to seed fibroblasts because the fibroblast growth factors are still present from lysed fibroblasts in sufficient amount to stimulate the epidermal cells (Regnier et al. 1998).

1.3.11 Further clinical cases using transplantation of isolated melanocytes

In parallel with the laboratory development of cultured skin substitutes mentioned above, there has been further clinical work performed with isolated melanocytes.

Following Lerner's original work in 1987, several authors have reported the use of cultured melanocytes alone for the treatment of vitiligo, leucoderma and piebaldism (Olsson and Juhlin 1993; Falabella 1997; Jimbow 1998). Olsson and Juhlin reported treatment of 26 patients with hypopigmentary disorders using a method of trypsinising harvested skin from the buttock and producing a basal cell-enriched suspension of cells. The melanocyte medium used was free of serum and phorbols. The recipient site was dermabraded and the cell suspension applied with a collagen sheet. Details of how the various cell types were separated or why a fewer number of basal cells per unit area would result in a normal pigmentation were not included in the paper. Presumably the authors were anticipating passenger melanocytes to proliferate on the dermabraded skin. There were no sites treated with dermabrasion alone to act as a control and no biopsies were taken for histological examination. However, many of the patients treated in this way had improvement of pigmentation in the treated site (Olsson and Juhlin 1998).

Transplantation of isolated melanocytes was also used by Baltaci and Kilic (1998) who cultured nevus cells to pigment an area of skin on a reconstructed breast

mound as a neo-areola. They used a melanocyte culture medium that contained phorbol ester and bovine pituitary extract. They cultured the melanocytes for four weeks, renewing the culture medium every four days, and then applied the cultured cells to the dermabraded recipient site. Post-operatively the patient exposed the area to natural sunlight but the duration of sun exposure treatment is not clear. They reported pigmentation occurring three weeks after the application of cells and no loss of pigmentation at six months. There was no occurrence of malignant melanoma in the six months of follow-up (Baltaci and Kilic 1998).

1.3.12 Co-cultured melanocyte and keratinocyte sheets as a therapeutic option

Stoner and Wood adopted the techniques instituted by those treating vitiligo to treat a small area of hypopigmentation in a burns patient (Stoner and Wood 2000). They relied on the phenomenon that 'passenger melanocytes' survive in conventional keratinocyte-culture medium with a fibroblast feeder layer. Melanocytes were reported to have proliferated to confluence in one week *in vitro*. The cultured epithelial sheet was transferred to the hypopigmented area, which had been dermabraded in preparation for the graft. There were no sites treated with dermabrasion alone as a control. Repigmentation of the site was reported to be complete and homogeneous. This case contrasts to the spotty pigmentation described when cultured epithelial autograft (CEA) is applied to burn wounds, where no dermis is present (Boyce 1991). Stoner and Wood did not discuss this contrast or the possible role of the dermis in their paper.

1.3.13 Further developments in pigmented skin substitutes

Now that skin equivalents have an established clinical role, a need for measures of efficacy and quality has arisen. In addressing this issue, Christolini and co-workers have looked at ways of testing the mechanical properties of skin equivalents so that they can be compared with each other and with normal skin (Christolini et al. 1999). Such tools will become useful, both for both quality control and for comparative studies.

The promise of pigmented skin equivalents as a useful model for investigating cell-cell interaction has also now come to fruition. Seiberg and colleagues (2000) used melanocyte-containing skin equivalents to study the regulators of melanosome transfer between melanocytes and keratinocytes. They showed that known activators of protease-activated receptor 2 (PAR-2) caused increased pigmentation of the skin equivalent and that a known inhibitor of PAR-2 caused hypopigmentation of the skin equivalent, concluding that PAR-2 is at least one of the regulators of melanosome transfer (Seiberg et al. 2000).

Reconstructed skin has also been used to test pigment modifying drugs (Bessou et al. 1997). This group cultured keratinocytes in a serum-free medium and melanocytes in a cholera-toxin and phorbol ester-free medium. They used dead de-epidermised human dermis and seeded the melanocytes and keratinocytes onto it at a ratio of 1:20. Once they had established the skin constructs (after 22 days) they proceeded to apply various drugs and assessed the effects of pigment modification with colourimetry, histological examination using Masson-Fontana staining and the DOPA reaction.

Medalie and colleagues have also used skin equivalents for investigating the control of melanocyte growth and activation. The skin equivalents were composed of acellular dermis seeded with keratinocytes that have been cultured in a medium known

to sustain 'passenger melanocytes'. The rationale behind this method is that a few, widely separated melanocytes are more likely to undergo mitosis and hence the opportunity for observation of melanocyte division and migration behaviour will be greater. The cultured skin substitute produced and grafted onto athymic mice by Medalies group produced after three weeks in culture, clusters of melanocytes present in the skin substitute. After six weeks the melanocytes were evenly distributed along the basement membrane and clinically there was repigmentation of 90-100% of the graft. They found that pigmentation was stable for six months but that histologically, pigmentation started to accumulate within the dermis at 12 weeks. These results add to the idea that pigmentation could be due to the influence of the dermal analogue on the melanocytes. This important concept may be crucial to the successful manufacture of pigmented skin equivalents (Medalie et al. 1998).

In a review on pigmented skin equivalents (PSE), Nakazawa and colleagues (1998) noted that the problem with culturing melanocytes in isolation, in terms of studying melanocyte behaviour, was that under hyperproliferative conditions the specific differentiation functions of melanocytes are often altered or lost, making it hard to draw extrapolations to the *in vivo* situation. They noted that the presence of keratinocytes can act as a substitute for mitogens in stimulating melanocyte proliferation. They indicated that the physiological ratio of melanocytes to keratinocytes is strictly maintained *in vitro*, presumably by cell-cell interactions (De Luca et al. 1989; Nakazawa et al. 1998). Different groups have seeded their PSE with various ratios of melanocytes to keratinocytes from 3:7 to 1:10 to 1:20 (Nakazawa et al. 1998) but the effect of the seeding ratio on the final result is not established and is an area that needs further study.

Pellegrini and colleagues have emphasised the importance of including keratinocyte stem cells in cultured skin equivalents. Stem cells are cells that have a

capacity for self-maintenance with the potential for proliferative self-renewal extending for at least one lifespan of the organism. This is in contrast to the transient amplifying cell population, which arises from stem cells and will eventually generate terminally differentiated cells. This latter population has a high proliferative rate only for a limited period of time. It is therefore important that if keratinocytes are to be used for coverage of large burn wounds they must be produced in a culture environment which allows the maintenance of stem cells (Pellegrini et al. 1998).

De Luca and Pellegrini's method of skin replacement in burns patients utilises Medalie's principles of a physiological dermal analogue as the optimal substrate for cultured cells. Their method is to use cadaveric skin to cover the burn wound acutely and simultaneously to take biopsies for keratinocyte culture, then to remove cadaveric epithelium at 14 days and replace it with cultured keratinocytes (Pellegrini et al. 1998). In this process, although melanocytes are not separately cultured, apparently enough "passenger melanocytes" survive, such that good repigmentation occurs when the cells are applied to the cadaveric dermis (personal communication with author by electronic mail).

Boyce's group have now conducted a clinical trial of cultured skin substitutes versus autograft in a limited number of burns patients (Boyce et al. 1999) and found that the cultured skin substitute (keratinocytes, fibroblasts and Integra®) gave functionally stable and cosmetically acceptable wound closure. However, they acknowledge that further studies need to be performed to evaluate whether this sort of construct is a viable alternative to autograft and have not as yet used a cultured skin substitute containing separately cultured melanocytes for a clinical trial.

1.4 SUMMARY OF LITERATURE REVIEW

The possibility of a pigmented skin equivalent playing a role in the reconstruction of the female nipple-areolar complex is realistic. This literature review demonstrates that there is no single effective method for reconstructing the nipple-areolar complex and that permanent reconstitution of the pigmentation is not generally achieved. Furthermore it highlights that although there is a body of literature on nipple-areolar reconstruction there are few formal studies published examining patient evaluation of nipple-areolar colour after reconstruction.

Review of the histological literature in relation to nipple-areolar pigmentation reveals that although the structure of the nipple-areolar complex has been studied, there have been no studies examining the amount of melanin or numbers of melanocytes in this area of special pigmentation. Skin pigmentation and melanocyte count in other areas of the body have been examined but not with the aid of modern immunohistochemical methods. Although there is a substantial body of work on the immunohistochemistry of melanoma there is little information on which primary antibodies are most sensitive for the purposes of quantifying melanocytes in normal skin. This knowledge is an essential precursor to any modern quantitative study of nipple-areolar or any other type of skin.

This review has shown that pigmented skin equivalents have evolved as a concept and as a reality from a number of different, disparate fields. The quest for a replacement for skin in burns patients has long been established, but useful information has also arisen from scientists generating skin equivalents for pharmaceutical testing and by cell biologists using isolated cell cultures to examine cell-cell interactions, in both normal and malignant cell lines. Specialists in dermatology have also had a particular interest in isolated melanocyte culture as a potential treatment for pigmentary

disorders such as vitiligo. The drawing together of all this experience from these different fields is essential if progress is to be made in the further development of pigmented skin equivalents.

There are several unresolved issues that are currently important in the development of pigmented skin equivalents - the influence on melanocytes of the dermal analogue used in skin substitutes, the influence of the initial ratio of melanocytes to keratinocytes seeded onto pigmented skin substitutes and the safety issues surrounding cultured skin substitutes in general and pigmented skin equivalents in particular. The successful generation of a clinically useable pigmented skin equivalent, that may have an application in nipple-areolar reconstruction will depend on the resolution of these issues.

CHAPTER 2

A STUDY OF NIPPLE-AREOLAR RECONSTRUCTIONS

2.1 AIMS AND OBJECTIVES

Aims:

To assess the quality of currently available types of nipple-areolar reconstructions, with special reference to their colour.

Objectives:

- To evaluate patients' perceptions of nipple-areolar reconstructions and their colour, using the other aspects of breast reconstruction as standards for comparison.
- To evaluate the patients' partners' perceptions and external observers' perceptions of nipple-areolar reconstructions and their colour, using the other aspects of breast reconstruction as standards for comparison.
- To measure objectively the colour of nipple-areolar reconstructions and assess its change over time.
- To evaluate the impact of nipple-areolar reconstruction on breast reconstruction.

2.2 MATERIALS AND METHODS

2.2.1 Patients

The population from which the sample of nipple-areolar reconstruction patients was drawn was a set of patients who had undergone nipple-areolar reconstruction with the surgeon Prof. R.D. Cooter in his private practice or who had undergone the same operation in the Royal Adelaide or Queen Elizabeth Hospitals in Adelaide, Australia. Sixty-nine patients were identified from medical records and operating theatre lists as having had nipple-areolar reconstructions. These patients had been operated on over a period of seven years between 1994 and 2000.

Once a population database had been constructed, the Cancer Registry of South Australia was contacted to find out which of these patients had died, so that deceased patients were removed from the list of possible participants. Three patients had died and the remaining 66 were invited to participate in the study by letter (Appendix VI).

None of the patients in this population had had tattooing of the nipple-areolar skin as part of their reconstruction and it was felt that it was important to include at least some patients who had undergone this procedure. After permission had been granted from the surgeons involved, the medical records and operating lists of the Royal Adelaide Hospital were searched for patients having undergone tattooing of nipple-areolar reconstructions. Ten patients were identified and invited to participate in the study, using the same letter of invitation as the previous set of patients.

2.2.2 Method of review and questionnaires

With the letter of invitation to participate in the study, patients received an information sheet about the study (Appendix III) and a consent form (Appendix VII) with a pre-paid return envelope. Those who returned the consent form were contacted by telephone to arrange an appointment with the author in the Department of Plastic and Reconstructive Surgery at the Royal Adelaide Hospital. In the event that patients had moved house, their general practitioners were contacted for the current address. If no response was received within one month a second letter of invitation was sent to the patient. If patients did not respond to the second letter they were sent a questionnaire by post and a feedback form (Appendix VIII) that asked questions about why they did not want to be reviewed.

A "Patients' Aesthetic Questionnaire" (Appendix IX) was devised using 10 cm visual analogue scales, with opposing responses at either end, to gauge the patients' responses. To obtain internal standards for the assessment of the nipple-areolar reconstructions, four questions were asked regarding the quality of the breast reconstruction as a whole. The attributes measured were: symmetry in a bra, symmetry naked, appearance in a bra and appearance naked. These questions were taken from a previous study of breast reconstructions (Dean et al. 1983). The next questions inquired about patient perception of the colour of the nipple-areolar reconstruction, the degree of fading of the nipple-areolar reconstruction, the projection of the reconstructed nipple and loss of projection of the nipple over time. As nipple reconstructions can either be too large or too small, two visual analogue scales were provided so that the patient could respond on either one or the other, depending on whether the nipple was on the large side or on the small side. The final questions asked patients about their satisfaction with the breast reconstruction before and after nipple-areolar reconstruction.

A “Demographics Questionnaire” was devised to obtain information on occupation, age and marital status. A question on whether or not the patient was sexually active was also included because of the known phenomenon of sexual problems in patients who have undergone mastectomy (Maguire et al. 1978).

Patients who had consented to participate in the study attended the Department of Plastic and Reconstructive Surgery at the Royal Adelaide Hospital. The nature of the study was then re-iterated from the patient information sheet and instructions were given as to how to complete the questionnaires. Verbal instructions were the same as those written at the top of the questionnaires, and were given in an attempt to reduce the risk of invalid responses that may have occurred with written instructions alone. The patient then completed the two questionnaires, the author being out of the room during this period.

After completion of the questionnaires, the author and patient had an informal discussion about the patient’s experience of breast reconstruction. Notes about these discussions were made either at the time or immediately after the patient had left the appointment. The patient was then accompanied by the author to the Department of Clinical Photography, where the study photographs were taken, and brought back to the Department of Plastic and Reconstructive Surgery before departure. Finally, each patient who had a partner, was asked to give “Partner Aesthetics Questionnaires” to her partner for completion and then to return the complete questionnaire in a pre-paid envelope. The “Partner Aesthetics Questionnaire” (Appendix XI) had the same format as that used for the patients, except questions about “satisfaction” and regarding changes of the nipple-areolar complex over time were omitted. The decision not to ask partners about changes over time was because early anecdotal reports from patients suggested that the timepoint at which partners were allowed to see the breast reconstruction was highly variable.

2.2.3 Photography

Each patient had a standard series of photographs (Fig. 13) taken to allow assessment of the nipple-areolar reconstruction and the breast reconstruction as a whole, by a panel of external observers. There were oblique and horizontal shots taken of the normal and reconstructed breasts to enable those viewing the slides to judge symmetry of the breasts and projection of the nipple reconstruction as well as general appearance.

A cardboard colour standard was adhered to the patient's skin, perpendicular to the angle of the camera, and a further photograph taken for the purposes of colour analysis (see below)(Fig. 15). All photography was performed by professional clinical photographers in a studio, using a Nikon (Japan) F5 camera with a 60mm / F2.8 micronikkor lens.

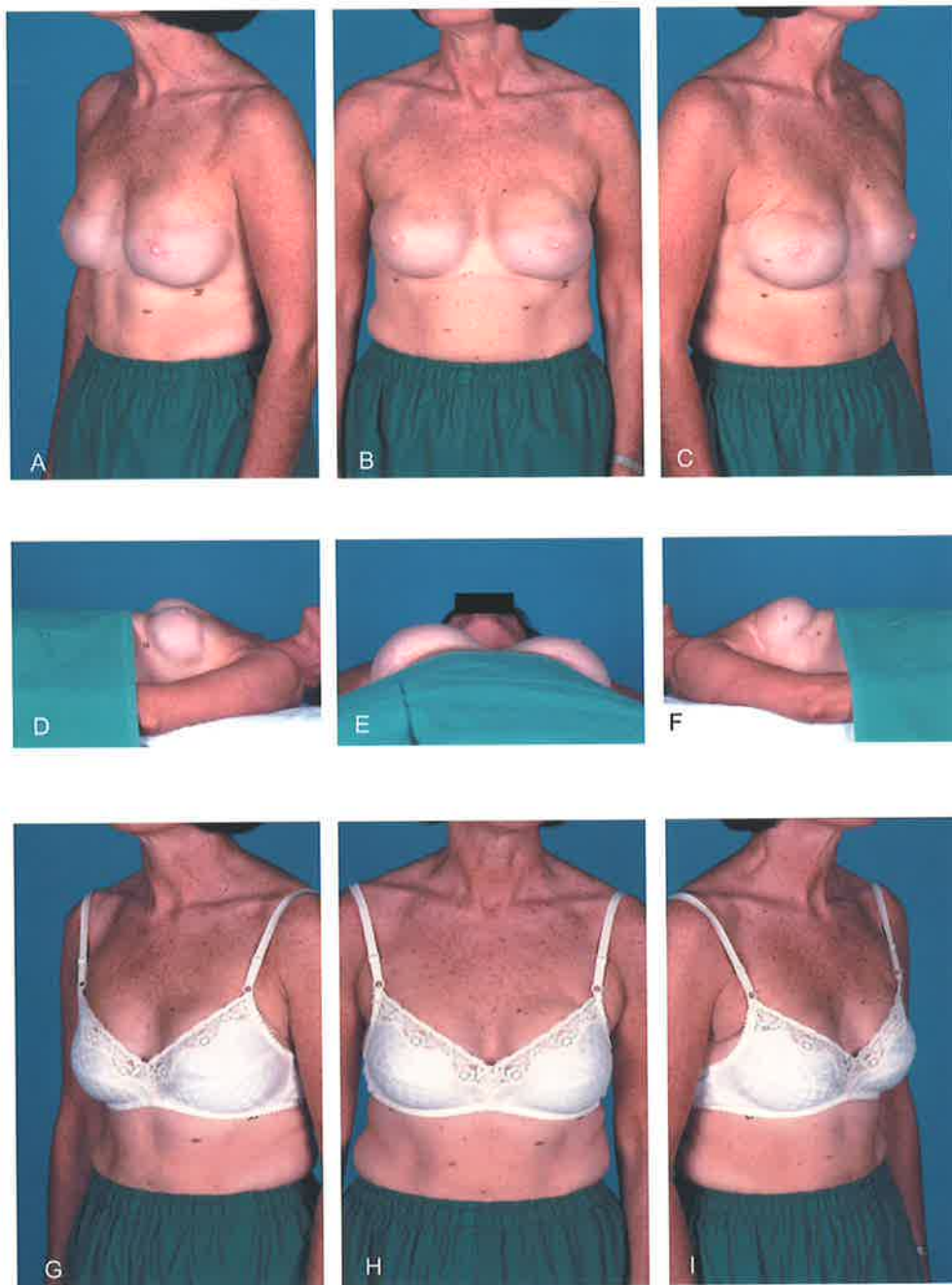


Fig. 13 (A-I) Standardised photography of a woman with bilateral breast reconstructions for assessment by independent observers

2.2.4 Independent panel review

Four people were asked to take part in a review of patients' slides. The panel consisted of a male physiotherapist, a male postgraduate student of anthropology, a female research nurse and a female ward clerk. None had any prior involvement in the study and they were not paid any fee.

Photographs of the study patients before the nipple-areolar reconstructions were found from archives, where possible, so that the impact of the nipple-areolar reconstruction on the breast reconstruction as a whole could be assessed by the panel. Once all relevant photographs had been located, the panel was convened for a structured viewing of the slides. Each panel member had a questionnaire (Appendix XII) for each patient. The questionnaires had the same format as the Patients' Aesthetics Questionnaires but did not ask about satisfaction and included an additional question on the impact of the nipple-areolar reconstruction on the appearance of the breast reconstruction (Fig. 14).

Panel members were coded A, B, C and D and were given instructions on how to fill out the questionnaire. There was no identification on the slides of the patients and patients were ordered randomly. There was a set of seven slides for each patient and one minute was allowed for the viewing of each set. Panel members were not allowed to confer. At the end of the session, questionnaires were returned and data were entered for statistical analysis.

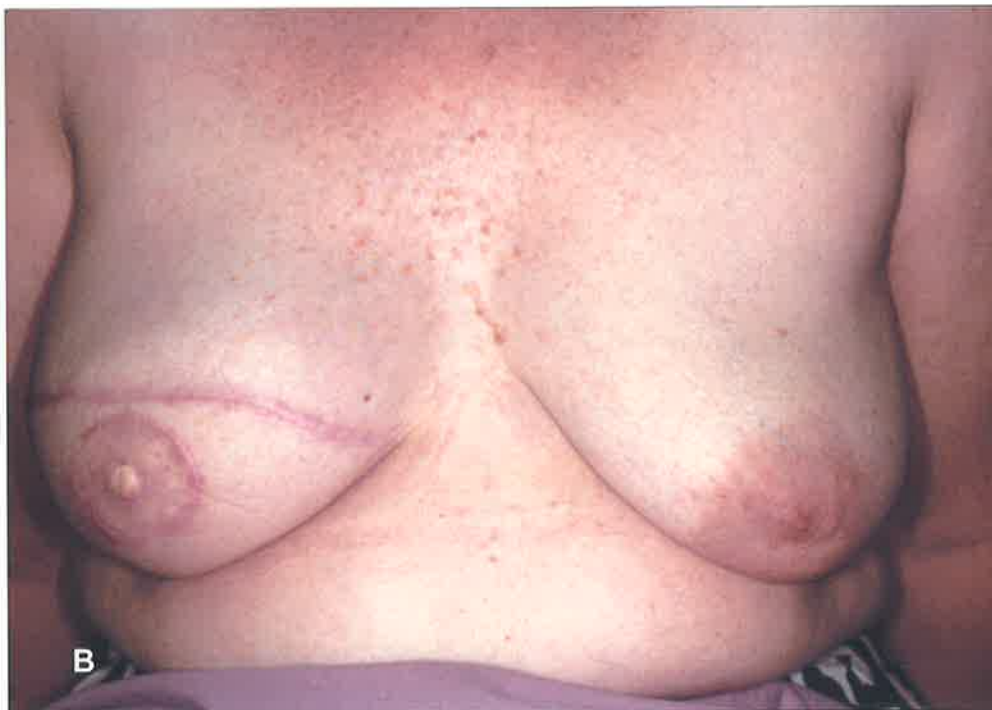
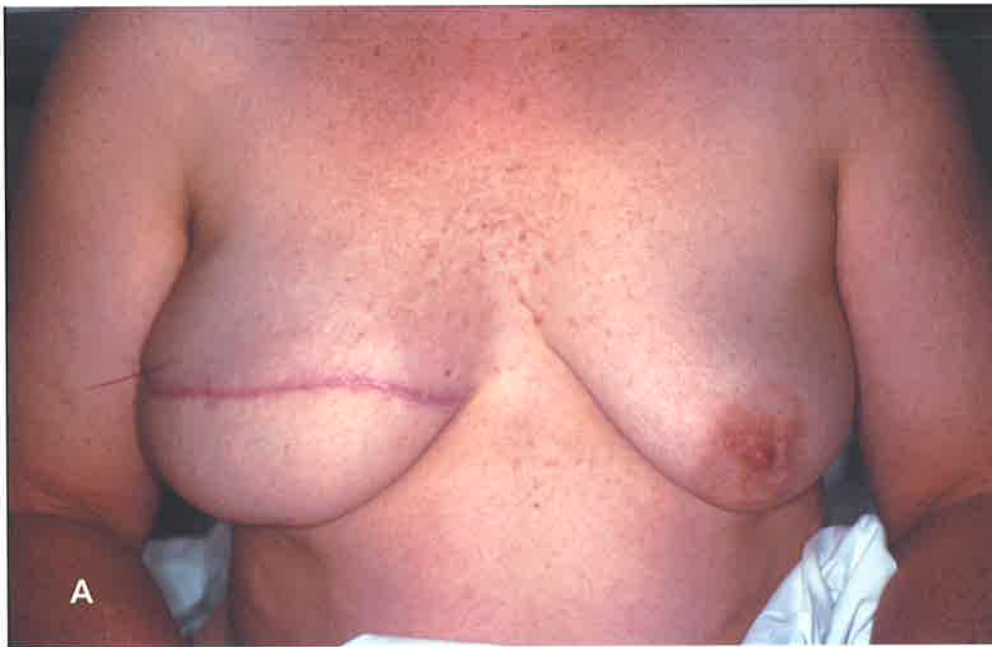
Fig. 14 Typical images of patient **A** before and **B** after nipple-areolar reconstruction, for rating of impact of nipple-areolar reconstruction by panel of independent observers

2.2.5 Computerised colour analysis

The photographs that included the colour standard were developed as 35mm colour slides then scanned using a Nikon LS 2000 slide scanner into a computer to enable standardisation and comparison of colour between images. The Adobe Photoshop (v5.5, Adobe Systems Incorporated, U.S.A.) computer software package was used to save the images, as TIFF files, in the computer's hard drive. There was no modification of the colours, contrast or brightness of the images within Adobe Photoshop. Using a custom-designed computer programme (Davey et al. 1999) the image colours were adjusted to the colours within the colour standards (Fig 15). Colours in selected regions of the image were then measured, and expressed in terms of the Hue, Saturation and Value colour model (HSV).

Hue (H) is a number that distinguishes between colours in terms of their dominant wavelength, e.g. between red (360) and yellow (420). Typical Caucasian skin has a hue of approximately 380 (between red and yellow). The Hue number represents a position in degrees around a colour "wheel", with red at the 0 and 360 point, yellow at 60, green at 120, blue at 240. The 0 / 360 discontinuity at red falls within the range of skin colours, so the scale is modified in this programme by allowing numbers greater than 360, up to 420 ($360 + 60$; yellow).

Saturation (S) shows the difference between colours such as red and pink. Bright red is "highly saturated" with an S value of 1, pink has the same hue but a lower saturation. Fading of a colour is typically seen as a decrease in saturation. Value (V), the 3rd parameter, is about "dullness". Well-lit areas of an image have a Value close to 1, but in the shadows V falls and colours become dull. Although value is needed to completely describe the colour of part of an image, it has more to do with lighting than the properties of the skin.

The areas of the image sampled for measurement of colour were; the normal areola (in the cases that there was a normal side), the reconstructed areola, the normal breast, the reconstructed breast mound and the upper abdomen. Measurements were entered into a database (Microsoft Excel 97, Microsoft Corporation) and analysed as described below.

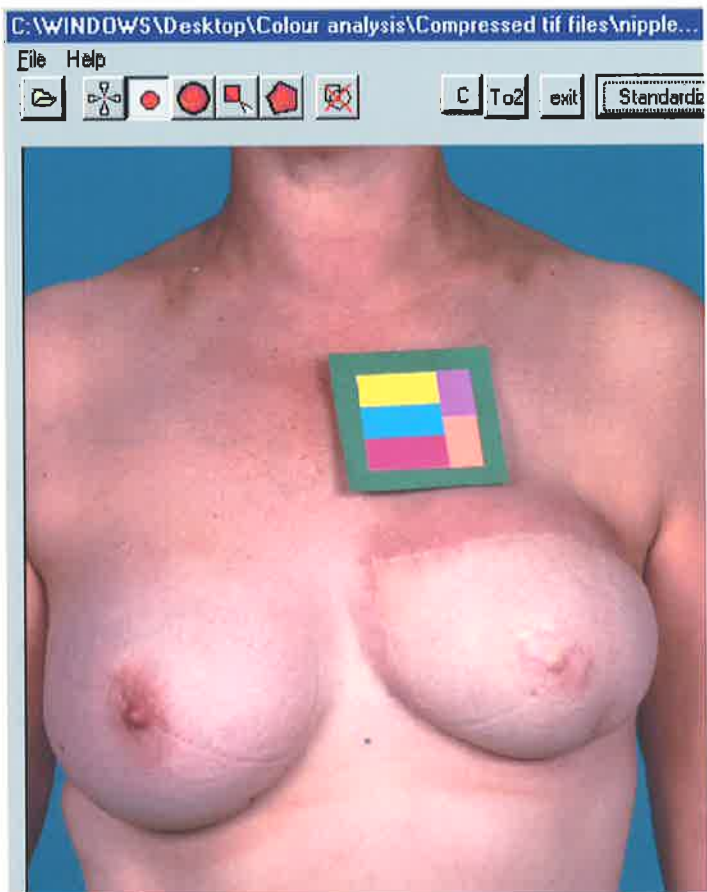
2.2.6 Scoring of questionnaires and statistical analysis

The position of the mark on the analogue scale was measured in millimetres from the end associated with an undesirable outcome. Thus for all measurements, a low rating indicated an unfavourable outcome. For the attribute of fading of the nipple-areolar complex, this meant that a mark towards the “no, not faded at all” end of the scale translated as a high rating and a mark towards the “yes, faded a lot” end of the scale translated as a low rating. Ratings were grouped as shown in Table 1 below.

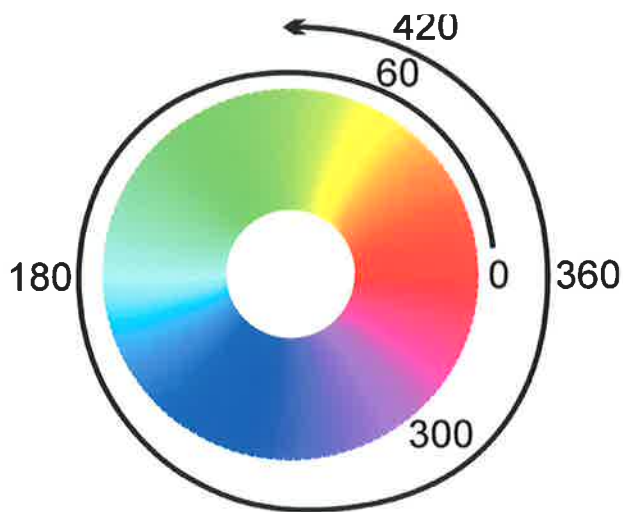
Table 1 Grouping of questionnaire ratings

<i>rating</i>	<i>group</i>
0 – 25	unhappy with results
26 – 50	moderately unhappy with results
51 – 75	moderately happy with results
76 – 100	happy with results

For statistical analysis, the frequency of patients happy with the results was used as being the most relevant to clinical practice because producing results that patients are happy with is the usual clinical goal (rather than producing a high mean score, which is clinically meaningless). Those patients who gave ratings of greater than 75 in at least three out of the four general attributes (symmetry in a bra, appearance in a bra,



A



B

Fig. 15 Colour analysis: **A** image of patient with colour standard within colour analysis computer software programme, **B** colour wheel showing “degrees” of hue

symmetry naked and appearance naked) were regarded as being happy with the general attributes of the breast reconstruction.

A chi squared test was used to compare the number of patients happy with nipple-areolar colour with the number of patients happy with the general attributes of breast reconstruction. For other results, where measurements were paired (e.g. comparing normal to reconstructed breasts), paired student t-tests were used, with the two-tailed p value given. Where data were unpaired, either two-sample t-tests or analysis of variance were used, depending on the number of variables. Regression analysis was used for analysis of results over time.

Colour analysis data were analysed by comparing normal with reconstructed sides, using paired t-tests and using regression analysis for change in hue or saturation over time.

All analyses were performed using a computer software package (Microsoft Excel 97, Microsoft corporation).

2.3 RESULTS

2.3.1 Demographics

Sixty-three women were recruited to the study. Their mean age was 51.5 years (standard deviation (s) 7.54)(range 36-69). Forty-eight of the patients were married, eleven were divorced or separated and four were single. Forty-three reported having a regular sexual partner, sixteen reported having no sexual partner and four did not respond to the question.

Using the A.S.C.O. (Australian Standard Classification of Occupations) occupation classification system, there was a higher percentage of professionals, associate professionals and manager / administrators in the study compared to that which would be expected in the general population of women (Castles 1993) (Fig. 16).

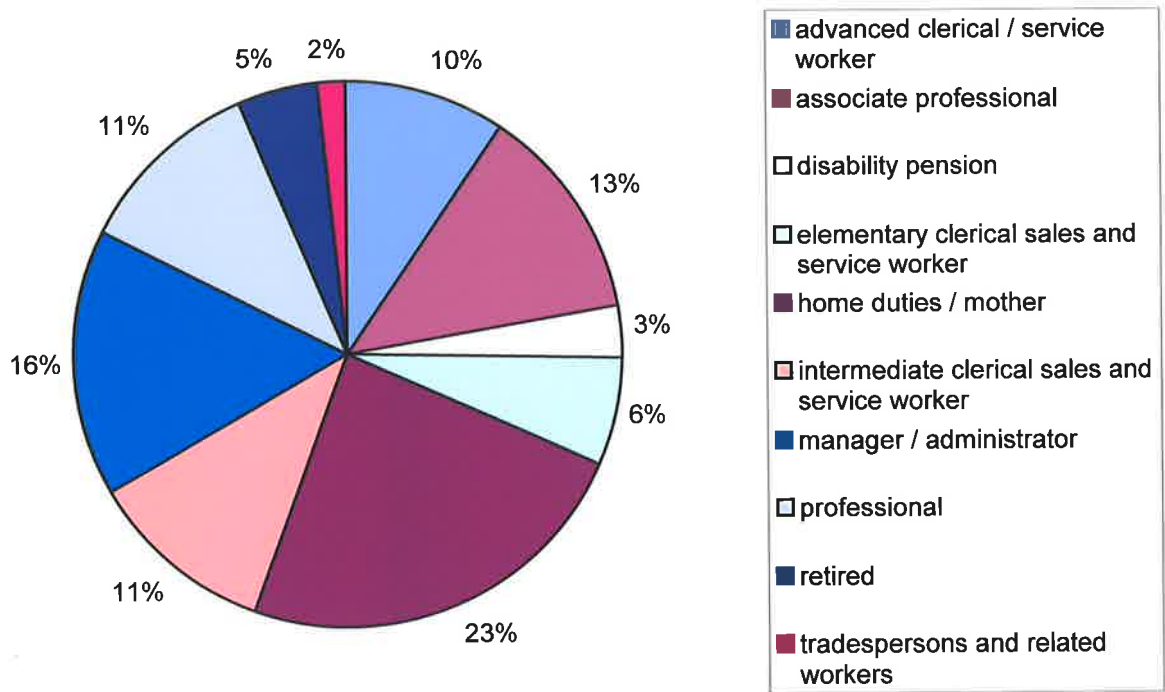


Fig. 16 Occupations of patients enrolled in nipple-areolar reconstruction study

2.3.2 General information on breast reconstruction

At time of enrolment in the study, fifty-five patients had had unilateral breast reconstructions and eight had undergone bilateral breast reconstructions. Forty three had undergone reconstruction of the breast mound using a vascularised composite flap of skin and subcutaneous fat and muscle from the lower abdomen - a TRAM (Transverse Rectus Abdominis Myocutaneous) flap, with 41 of these operations involving disconnection of the vessels and reconnection using microsurgery and two being pedicled flaps (where the vessels are not disconnected). Fifteen patients had undergone reconstruction of the breast mound with silicone implants or tissue expanders; one had had a latissimus dorsi free flap and one had had both a latissimus dorsi free flap and an implant. Two patients, who had required central resections of the breast only, had retained the native breast mound and required nipple-areolar reconstructions only.

In the case of unilateral breast reconstruction, the breast contralateral to the reconstruction was operated on as follows: reduction - 23 cases, no-operation - 21 cases, augmentation - six cases and mastopexy - five cases.

The mean time since nipple-areolar shape reconstruction was 24 months (standard deviation 15.6, range 0.85-63.43) for the whole sample. There was found to be no statistically significant difference between tattoo patients and the rest of the patients in terms of time since pigmentation procedure.

The frequency of methods used to pigment the nipple-areolar reconstruction was as follows: - skin graft from groin - 21 patients; skin graft from opposite areola - 21 patients; tattoo - 6 patients. In 13 patients there was no deliberate effort to recreate areolar pigmentation, with non-specialised redundant skin being used to cover the denuded area of the skate flap.

2.3.3 Patients with nipple-areolar tattoos

Nipple-areolar tattoo is not necessarily performed at the time of the nipple-areolar shape reconstruction. When the issues of colour and fading are being studied, it is therefore necessary to distinguish between “time since reconstruction” and “time since pigmentation procedure”. Where a pigmented skin graft is used to colour the neo-areola, time since reconstruction and time since pigmentation procedure are the same. One patient reported that she had had four tattoo procedures due to fading of the previous tattoos. In this case, the time since the latest tattoo was used for purposes of analysis.

No significant difference was found between tattoo and non-tattoo patients in the time since procedure to pigment the nipple-areolar reconstruction (ANOVA $p=0.1$) i.e. groups were comparable in this regard.

There was no significant difference in the scores given by tattoo patients and non-tattoo patients for colour of the nipple-areolar reconstruction. On two sample t-testing assuming equal variance: mean score by tattoo patients = 62.33 (variance 1281.06), mean score by non-tattoo patients = 55.31 (variance 713.14) $p=0.55$ (2-tailed). There was no significant difference in the scores given by patients for fading of the nipple-areolar reconstruction, although tattoo patients tended to think that fading was worse than non-tattoo patients did. (N.B. low score = severe fading, high score = no fading). On two sample t-testing assuming equal variance: mean score by tattoo patients = 34.66 (variance 1612.26), mean score by non-tattoo patients = 49.00 (variance 1090.25) $p=0.32$ (2-tailed). There was a high degree of variance and a low number of tattoo patients, so a type two error cannot be excluded.

2.3.4 Patients' perceptions of nipple-areolar reconstruction within the context of breast reconstruction

The outcome of the patients' questionnaires is shown in figure 17. Most patients gave a high rating for satisfaction with their breast reconstruction and there was no statistically significant difference between the number satisfied with the breast mound (41 patients gave scores greater than 75) and the number satisfied with the final result of reconstruction (39 patients gave scores over 75).

In the patients' ratings there was a statistically significant difference between the different attributes of breast reconstruction when analysis of variance of the raw data was performed ($p < 0.001$). On examination of the data for the source of variation, the ratings for colour and projection of the nipple-areolar reconstruction were lower than those for the other aspects of breast reconstruction. Further analysis was performed using chi-squared tests to compare number of patients happy with general attributes with number happy with nipple-areolar colour or fading or projection. When the number of patients happy with the general attributes of breast reconstruction was compared to the number of patients happy with nipple-areolar colour there was found to be a statistically significant difference on chi-squared testing ($p < 0.01$; Table 2).

A smaller statistically significant difference was found when number of patients happy with nipple-areolar projection was compared with the number happy with general attributes using a chi-squared test ($p < 0.05$, Table 3).

There was no significant difference in scores for colour or fading between patients grouped by source of pigmentation of the neo-areola (Tables 4 and 5) There was a trend for colour to be rated more highly in tattoo patients but fading was rated as being worse.

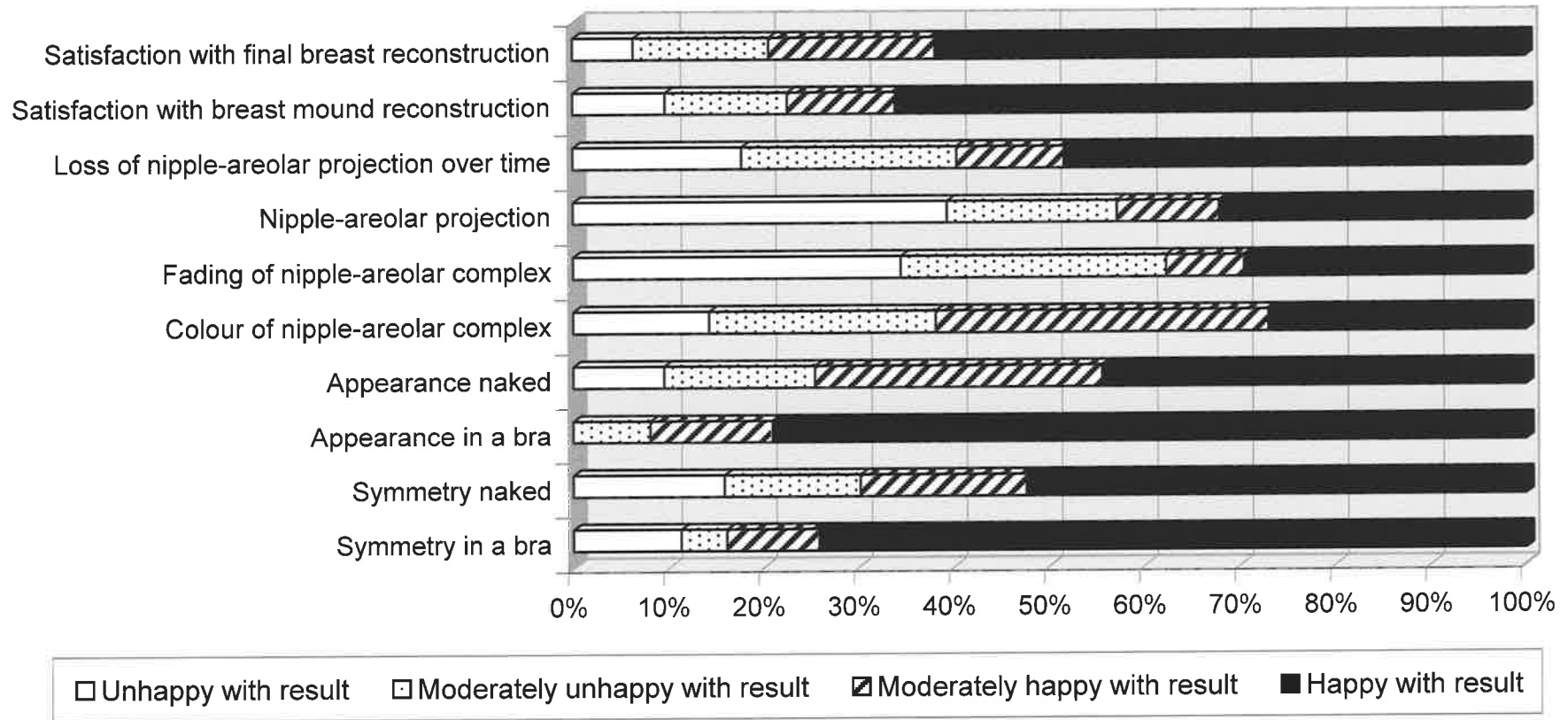


Fig. 17 Frequency of patients' ratings of different attributes of breast reconstruction

Table 2 Chi squared test comparing number of patients happy with general attributes of breast reconstruction and number of patients happy with nipple-areolar colour.

<i>actual</i>	<i>general attributes</i>	<i>nipple-areolar colour</i>	<i>total</i>
no. happy with result	34	17	51
no. not happy with result	29	46	75
total	63	63	126

<i>expected</i>	<i>general attributes</i>	<i>nipple-areolar colour</i>
no. happy with result	25.5	25.5
no. not happy with result	37.5	37.5

Table 3 Chi squared test comparing number of patients happy with general attributes of breast reconstruction and number of patients happy with nipple-areolar projection.

<i>actual</i>	<i>general attributes</i>	<i>nipple-areolar projection</i>	<i>total</i>
no. happy with result	34	18	52
no. not happy with result	29	38	67
total	63	56	119

<i>expected</i>	<i>general attributes</i>	<i>nipple-areolar projection</i>
no. happy with result	27.5	24.5
no. not happy with result	35.5	31.5

Table 4 Patients' scores for colour of the nipple-areolar reconstruction by source of pigmentation of the neo-areola

<i>group</i>	<i>n</i>	<i>mean</i>	<i>variance</i>
tattoo	6	62.33	1281.07
areolar	21	54.95	613.05
groin	21	58.76	873.09
non-specific skin	13	46.85	655.97

<i>source of variation</i>	<i>SS</i>	<i>F</i>	<i>F critical</i>	<i>P-value</i>
between groups	1480.02	0.64	2.77	0.59
within groups	43999.79			

Table 5 Patients' scores for fading of the nipple-areolar reconstruction by source of pigmentation of the neo-areola.

<i>group</i>	<i>n</i>	<i>mean</i>	<i>variance</i>
tattoo	6	34.67	1612.27
areolar	20	52.05	1144.26
groin	19	46.05	1097.61
non-specific skin	13	44.08	961.74

<i>source of variation</i>	<i>SS</i>	<i>F</i>	<i>F critical</i>	<i>P-value</i>
between groups	1536.35	0.45	2.77	0.72
within groups	61100.15			

2.3.5 The influence of time on the colour of nipple-areolar reconstructions

For the whole sample there was no significant correlation between time since procedure and the patient's rating of the nipple-areolar colour or fading. In patients who had a deliberately pigmented nipple-areolar reconstruction (ie excluding those with non-specialised skin grafts) fading was found to be worse with greater time since procedure (slope of regression line differing from zero $p < 0.005$, (Fig. 18). Patients gave ratings at one time point only and no conclusions can be made about what ratings individual patients would give over time.

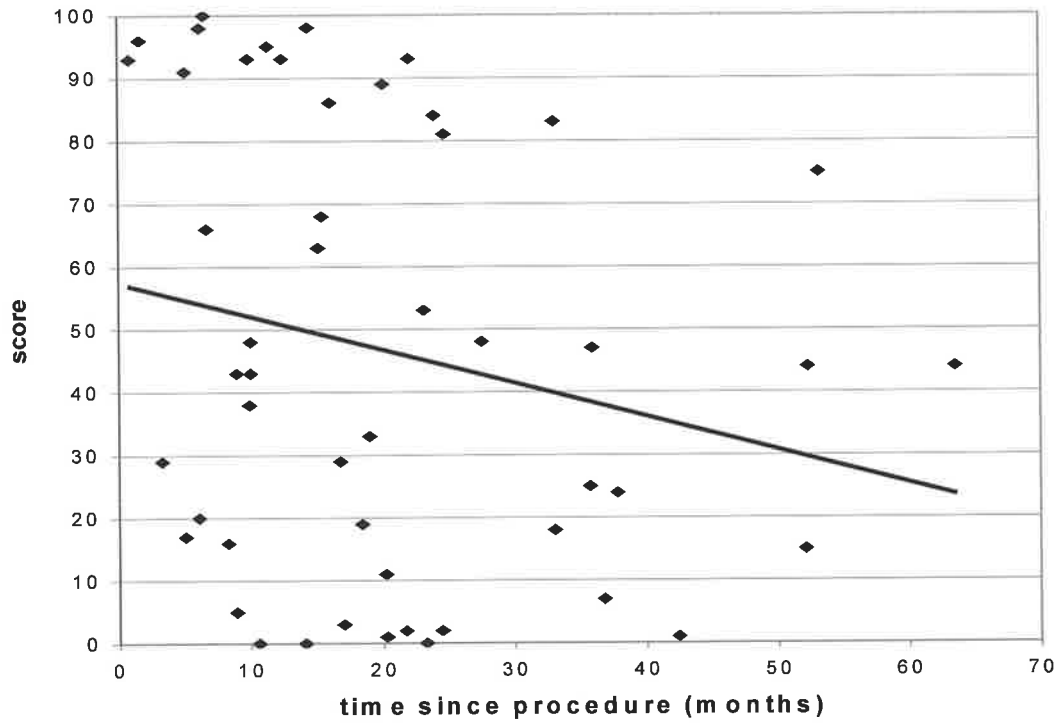


Fig. 18 Patients' ratings for fading vs time since procedure (a high rating indicates little fading)

2.3.6 Patients' comments

All the patients who attended appointments volunteered that they were glad to have had breast reconstructions, although some seemed to have felt the procedure to be longer and more arduous than they had expected. Several patients felt that the breast reconstruction had helped them to “get over the cancer”. Some women said that they found it difficult to express an opinion about the merits of nipple-areolar reconstruction specifically, because for them, it had been performed as part of a breast reconstruction “package” and it did not occur to them that the nipple-reconstruction was not always offered in this way.

Those who did express an opinion were generally positive about the impact of nipple-areolar reconstruction. There was one case where a woman felt that having the nipple-areolar reconstruction had had a very negative impact, because it made the breast into a sexual object for others but because she had no sensibility, it was not a sexual object for her and she found this disparity abhorrent.

Many patients expressed the view that the reconstructed nipple-areolar complex did not match the normal one. Aspects that they found unsatisfactory were colour, projection of the nipple, softness of the nipple and lack of sensibility.

Three out of the five tattoo patients interviewed complained about fading (Fig. 19).

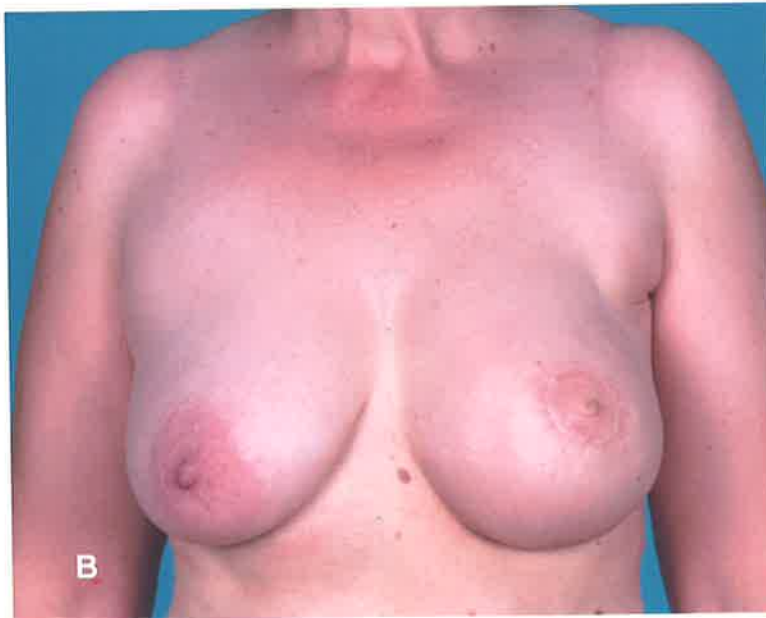
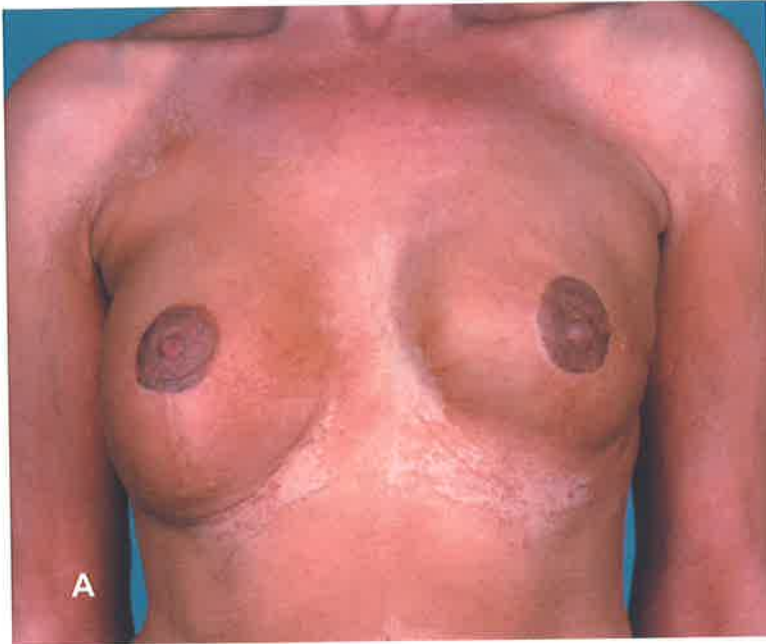
Fig. 19 A Patient 3 months after tattoo procedure - it was her fourth tattoo because previous ones had faded. **B** Patient 8 months after tattoo - she was disappointed with the degree of fading

The following comments were made by patients during the visit for the study appointment. They were noted at the time or on the same day and the author has tried to reproduce them verbatim. Not all comments have been included here but the author has endeavoured to make the selection representative.

"I am very glad I had it done [the breast reconstruction]. I did not leave the house for 12 months between the mastectomy and the reconstruction."

"Reconstruction made me forget about the cancer."

"[Reconstruction] would be good for a younger woman who had been in a relationship for less time. It was OK for me because I had been in a relationship a long time before the cancer. The nipple-areola has never had any colour at all - so I don't know if it has faded or not."

"It was so much easier for me, psychologically, having the immediate reconstruction - it made me focus on the reconstruction instead of the cancer.- but maybe it made me more fussy about the reconstruction. ...The [reconstructed] nipple is too soft - it looks different to the other one in clothes."

"Best decision I ever made [to have breast reconstruction]- life is so much better"

"Don't know whether I'd have a nipple reconstruction again - it is flat in clothes and doesn't do anything. I had problems with the stitches in the groin."

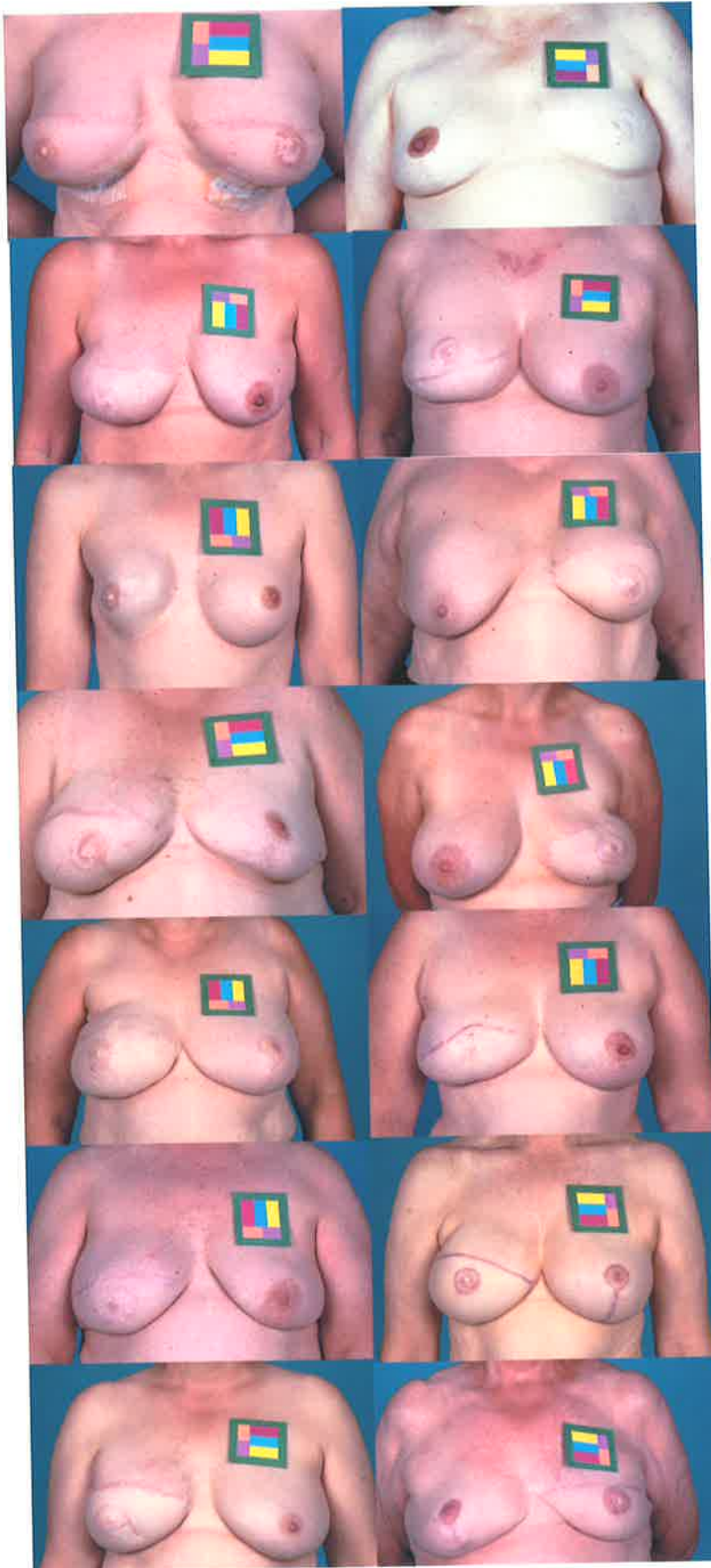


Fig. 20 Images of breast reconstruction patients wearing colour standards

"I would not have a nipple reconstruction if I had it again - I did not like the fact that it made the breast into a sexual object for someone else but that I had no sexual feeling in it. I accepted the initial reconstruction but almost rejected it when I had the nipple reconstruction and told my husband "hands off". It does not look like a nipple or feel like a nipple."

"It was a big operation but it was worth it - I would certainly recommend to any one to have it [breast reconstruction] done. With the external prosthesis I had neck and back pain because it was heavy - now all that has gone."

"Things were a bit difficult with my husband after my [first] operation. At first I wouldn't get undressed in front of him and then he did look and told me that he didn't find me very appealing. That really hurt me... he was very cold towards me. I felt very depressed and low. Since I had the nipple reconstruction we have never looked back. He saw them and said "they're a bute (sic) pair" ...we are much happier now .. we have never looked back. [later] I think it was good to have something there afterwards [after the mastectomy] instead of being completely flat...I had two friends who died of breast cancer and they found the prosthesis very heavy and uncomfortable. Having something there made me feel better about myself."

"I don't think the nipple is long enough"

"It is so wonderful just to feel whole again, as a woman. It is so good not to have to get up in the morning and see that hole in my chest. Dr. Cooter has given me back my confidence."

"It [breast reconstruction] is so marvellous. I am pleased I had it done. The only thing is the colour of the nipple..."

"I feel all woman again now. Before I felt like half man and half woman."

“I wish I had known about it [breast reconstruction] sooner - I had 2 years with a prosthesis. I think the nipple reconstruction is important - it makes it like a real breast.”

“Once I’d been put back together I felt I could carry on as normal”

“The nipple is so flat and the areola is so pale...It is a bit of a joke between us.. we call it the search light. I think it is important to have a nipple though.”

“I am not happy with the nipple [areolar complex].”

“I think the reconstruction is great. It would be good if the nipple was a better colour but I am still pleased. The colour [of the nipple-areolar reconstruction] was great straight after the operation but now it doesn’t look as good.”

2.3.7 External observers' views and partners' views on outcome of nipple-areolar and breast reconstruction

Thirty-two completed questionnaires from partners of patients were received. Three patients did not wish their partners to complete questionnaires and the remainder either had no partner or failed to return the questionnaire. The partners of patients gave similar ratings to the patients themselves, with a similar disparity between ratings for general attributes and colour of the nipple-areolar reconstruction (Fig. 21).

The responses of the panel of independent observers showed a statistically significant difference between the ratings given for different attributes of breast reconstruction on analysis of variance ($p < 0.001$). Generally, the independent observers gave a lower rating for the breast reconstructions than the patients (Fig. 21). Fading was frequently given a low rating, as was the colour of the nipple-areolar complex. The nipple-areolar reconstruction was thought to improve the appearance of the breast reconstruction in 81% of cases, according to external observers, a finding that is unlikely to occur by chance alone ($p < 0.001$ using binomial distribution).

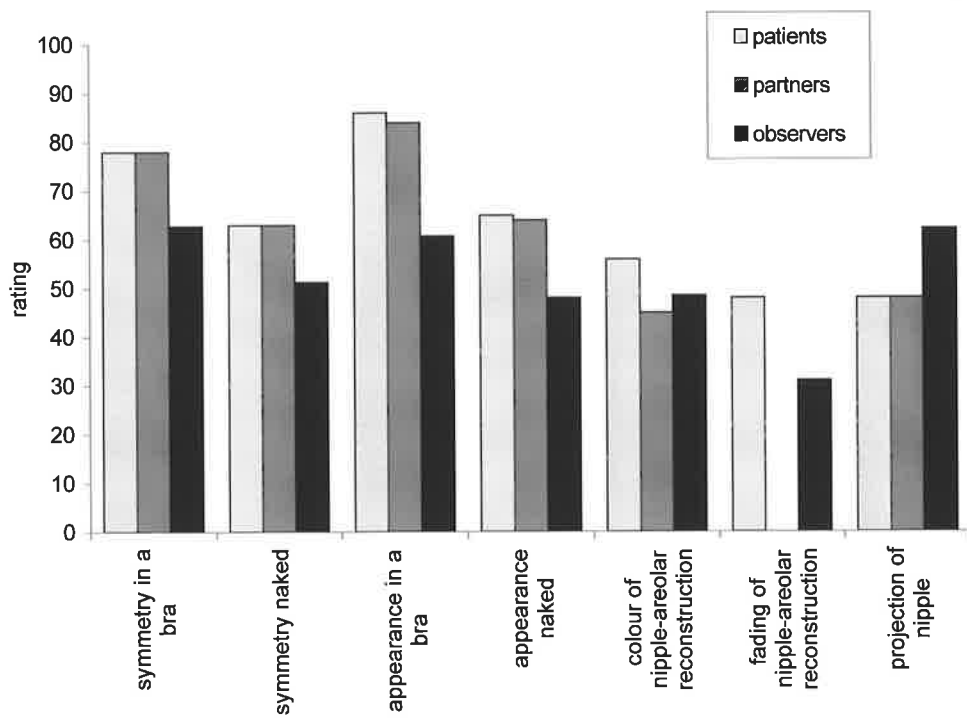


Fig. 21 Ratings of patients, their partners and a panel of independent observers.

2.3.8 Colour analysis

Slides with colour standards were taken for 50 patients. In one, there was a fault in the photographic processing, making the slides unusable and, of the 49 slides scanned, four were found to have too high an error value on the colour analysis program to give accurate results. Colour analysis of scanned images of the patients was completed in 45 cases. Of these, three had had bilateral reconstructions, excluding them from comparison between reconstructed and normal sides. The following data are from the remaining 42 patients.

In the sample there was a statistically significant colour mismatch between the normal and the reconstructed nipple-areolar complex on paired t-tests. The mean hue was 372 on the normal side (variance = 34.7) and 377 on the reconstructed side (variance = 94.7)($p < 0.001$). This means that the reconstructed side was slightly redder than the normal side. The mean saturation was 0.466 on the normal side and 0.371 on the reconstructed side ($p < 0.001$), indicating that the reconstructed side was measurably paler than the normal side.

In comparing colour saturation mismatch by the source of pigmentation of the nipple-areolar reconstruction (areolar skin, groin skin, tattoo or non-specific skin) there was a significant difference between the groups on analysis of variance ($p < 0.05$, Table 6). This can be partly accounted for by the difference between the non-specific skin graft group and the rest of the sample ($p < 0.01$ on two-sample t-test). There was no significant difference in hue mismatch depending on the source of nipple-areolar pigmentation. There was no significant correlation found between the magnitude of colour mismatch and the patients ratings for colour or fading.

Table 6 Colour saturation mismatch (saturation of normal minus saturation of reconstructed) nipple-areolar skin by source of areolar pigmentation

<i>group</i>	<i>n</i>	<i>mean</i>	<i>variance</i>
tattoo	5	0.041	0.0038
areolar	16	0.075	0.0035
groin	12	0.101	0.0042
non-specific skin	10	0.15	0.0038

source of variation	<i>SS</i>	<i>F</i>	<i>F critical</i>	<i>P-value</i>
between groups	0.0547	4.25	2.84	0.01
within groups	0.1674			

Colour saturation of breast mounds created with TRAM flaps closely correlated with that of the upper abdomen on regression analysis ($p < 0.001$, Fig. 22). Reconstructed breast skin was found to be paler than the contralateral normal breast skin (ie less saturated). There was a significant correlation between the difference in saturation between the normal and reconstructed breast skin and the normal and reconstructed nipple-areolar skin on regression analysis ($p < 0.05$).

The pallor of the reconstructed nipple-areolar complex was greater with longer time since procedure, so that the mismatch in colour saturation between the normal and reconstructed sides increased with time. This was measurable and statistically significant on regression analysis ($p < 0.01$, Fig. 23).

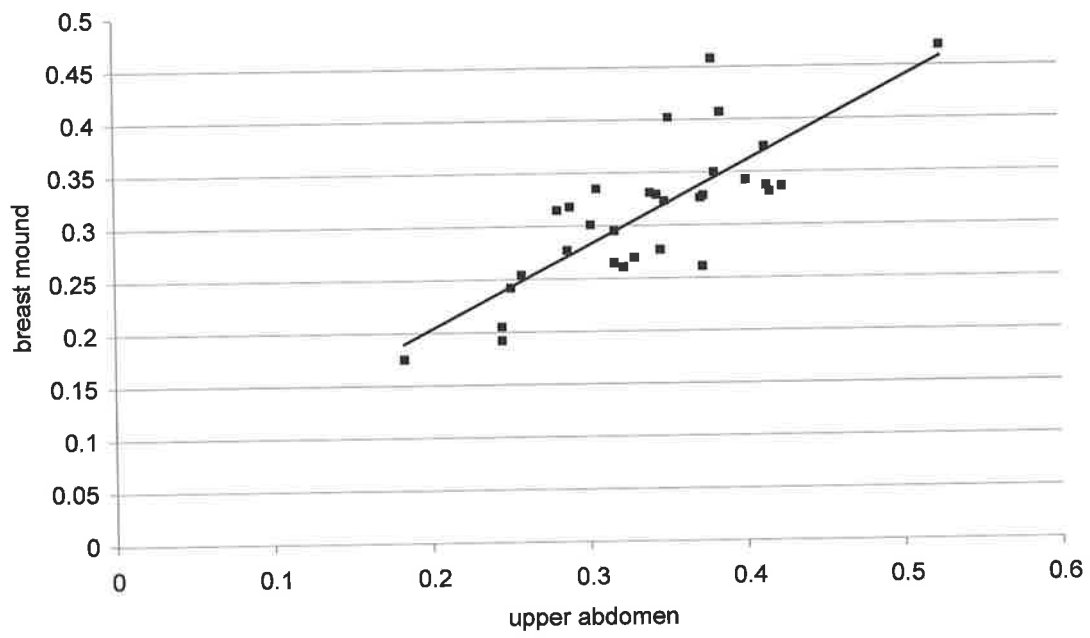


Fig. 22 Saturation of the breast mound vs saturation of the upper abdomen in patients with TRAM flap reconstructions

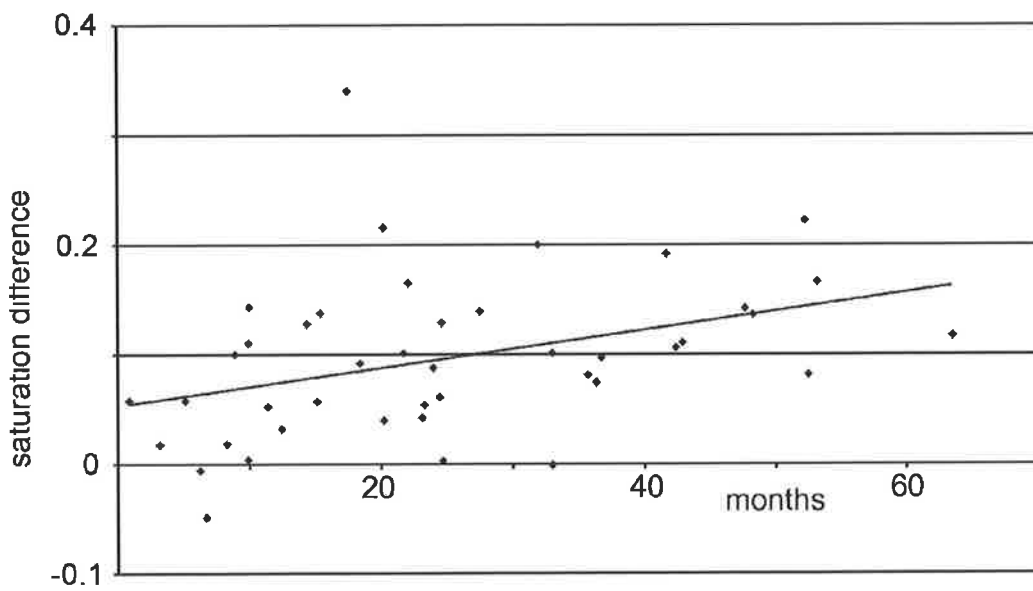


Fig. 23 Colour saturation mismatch over time (n=42)

2.4 DISCUSSION

2.4.1 Justification for study methods

The current study has taken a multi-stranded approach to the assessment of the quality of nipple-areolar reconstructions and their pigmentation (Fig. 24). An objective, quantitative method of research is useful because it should be independent of factors related to the researcher and allows comparison between units and between different timepoints. The set of data generated by such a method is graded so that some measure of severity can be made. The computerised colour analysis used in the current study is an objective quantitative method and is a new tool in the measurement of nipple-areolar colour.

The objective measurement of an observed phenomenon, although accurate and reproducible, may not correlate with the severity of problem perceived by the patient, which is also important. Questionnaires based on visual analogue scales allow the assessment of patient opinions in at least a semi-quantitative way, although whether the data generated by these tools are truly continuous or ordinal is debatable. The use of similar questionnaires for people in different positions of objectivity provides insight into different perspectives of the same issue. In hindsight, it would have been interesting to also ask surgeons to rate the breast and nipple-areolar reconstructions that they had performed.

Highly subjective, non-quantitative informal interviews have also been a part of this study. Although the number of variables influencing this technique means that it is difficult to generalise the results, this method can still give a valid contribution to the assessment of a problem. Meredith (1999) has argued that, in fact, interviews with patients produce much more meaningful results than questionnaires because

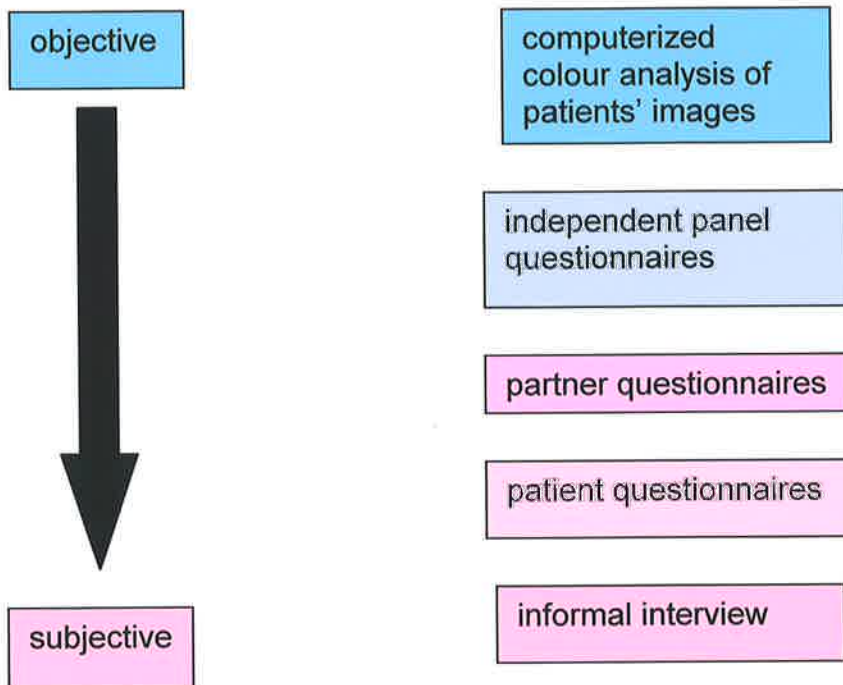


Fig. 24 Spectrum of objectivity / subjectivity in the methods used in the current study

questionnaire responses may not reflect the real views of patients for a variety of reasons (Meredith 1999). The author would argue that to properly assess a clinical problem one should use both objective and subjective measures as a way of ensuring that the results are likely to be both reproducible and relevant.

2.4.2 Population and study sample

The level of recruitment of patients to the study was unusually high. This may reflect a high level of interest in the issue being examined and may also be a reflection of personalities of the patients concerned. Patients and surgeons both reported that referral for consideration of breast reconstruction after mastectomy was still not automatic and that it was those who had the ability and facilities to pro-actively seek out information on breast reconstruction who finally underwent reconstructions. The notion of the women in the sample being more pro-active and / or educated than the general population is also supported by the high proportion of professional / managerial women found to be present. It is therefore likely that the study sample is not representative of the population undergoing mastectomy but may be representative of the population undergoing breast reconstruction. The disparity between these two groups reflects local availability or awareness of breast reconstruction which is an important but separate issue.

The low number of tattoo patients recruited to the study reduced the opportunities for comparing tattooing with other methods of pigmentation of the nipple-areolar reconstruction. However, the fact that so few patients had undergone tattoo procedures by plastic surgeons in the public hospital system is also important. Local surgeons anecdotally reported that on the occasions they had tried tattooing, the procedure had been prolonged and difficult and the results had been sub-optimal. For

these reasons they had not performed many tattoo procedures.

It is acknowledged that the fact that the tattoo patients had undergone reconstruction with different surgeons to the main set of patients is a methodological weakness, but unfortunately was unavoidable.

2.4.3 The impact of nipple-areolar reconstruction on breast reconstruction as a whole

The panel of independent observers in the current study found that the addition of a nipple-areolar complex improved the appearance of breast reconstruction in most cases but not all. It is difficult to separate the issue of whether a nipple-areolar reconstruction is a good thing *per se* from the influence of the quality of that reconstruction. If it is a poor reconstruction, even if the observer feels that the presence of a nipple-areolar complex is important for the appearance of the breast, she / he will not rate it highly.

I found that asking patients about “satisfaction” was not a good discriminator in the evaluation of nipple-areolar reconstructions vs breast reconstruction as a whole and this may have been because I was asking patients to recall their situation before they had the nipple-areolar reconstruction and how satisfied they were at that time. Wellisch and colleagues (1987) have previously found satisfaction with various aspects of breast reconstruction to be significantly higher with the addition of a nipple-areolar complex (Wellisch et al. 1987). In their study, one group had had a nipple added and the other group had a breast mound only. The validity of satisfaction questions in questionnaires is debatable (Meredith 1999) because satisfaction is a very nebulous concept that can depend on many factors and because patients often feel obliged to score these questions highly. Satisfaction of patients is also intrinsically linked to the expectations of the

patients, which is in turn linked to the information given to them. Patients with low expectations will be very satisfied with mediocre results.

Talking to patients was a more fruitful source of information on the impact of nipple-areolar reconstructions on breast reconstruction. It was interesting to find that the views on the nipple-areolar reconstructions varied very widely. To some people, the poor colour of the nipple-areolar complex made the reconstruction “not worth having” and to others it was still important to have this focal point of the breast, even if it did not match the other one.

The finding that nipple-areolar reconstruction has a positive role is supported by Asplund, who found that 79 women in a series of 100 undergoing breast reconstruction chose to have nipple-areolar reconstruction and that most who underwent the procedure felt afterwards that it had been necessary (Asplund 1983).

2.4.4 The quality of nipple-areolar reconstructions

The results from the patient questionnaires in the current study show that the quality of nipple-areolar reconstruction is inferior to the quality of breast reconstruction as a whole. Both the colour of the nipple-areolar reconstruction and the projection of the nipple were rated less highly than the general attributes of breast reconstruction.

The finding that nipple projection is a problem is supported in the literature (Little et al. 1983; Kroll et al. 1997). Banducci and colleagues performed a study of Anton-Hartrampf type nipple reconstructions, measuring the projection of the nipple over a period of time (Banducci et al. 1999). They found that nipple projection reduced significantly over time and that there was a tendency for nipples to flatten more in the cases that a tissue expander or implant had been used for breast mound reconstruction than in an autologous flap. Asplund’s study used a system of grading for nipple projection and evaluation was performed by a surgeon who had not participated in the

surgery (Asplund 1983). Nipple projection was found to be better using a nipple-sharing technique rather than a local flap (mushroomplasty).

In the current study, pigmentation of the reconstructed nipple-areolar complex was found to be sub-optimal by patients and their partners and on objective measurement using colour analysis. The largest recorded study of pigmentation of nipple-areolar reconstructions has been performed by Spear and Arias (1995). Their study only considered patients who had undergone tattoo of the nipple-areola and used patient-based questionnaires to evaluate results. They found that 60% of the tattoos were ultimately too light even though immediately after the procedure the colour was too dark. In spite of this problem of colour match, they again found a high level of satisfaction within the patient group. The conclusions from this study were: firstly, tattoos inevitably fade over time and may need repeated “touch ups” for a good result and secondly, that tattoos are the best option currently available (Spear and Arias 1995). In the current study there were not enough tattoo patients to properly evaluate them as a separate group. However, there was no significant difference in scores for colour between tattoo patients and other patients, or between colour analysis of tattoo and non-tattoo patients, but this may have been because of insufficient patient numbers.

Asplund (1983) also evaluated the colour of nipple areolar reconstructions but, unlike Spear and Arias (1995) who looked at tattooing, she compared pigmentation from upper inner thigh skin grafts and areolar-sharing techniques. Evaluation by an independent surgeon found upper inner thigh skin produced a better coloured neo-areola than if an areola-sharing technique was used (Asplund 1983). Similarly, in the current study, upper inner thigh / groin skin reconstructions tended to be rated higher than those using opposite areolar skin and showed better colour match on colour analysis but the difference did not reach statistical significance. Certainly there was no strong evidence to suggest that opposite areolar skin performed much better than groin skin, which is interesting, because opposite areolar skin had always been assumed to be the gold

standard.

Both the current study and that of Spear and Arias, have found patients to be good evaluators of specific elements of their post-operative outcome. The author would argue that in the assessment of a particular procedure, asking patients to rate specific features of their reconstruction is more informative than asking general satisfaction questions.

Fading of the colour of nipple-areolar reconstructions, as a reduced level of colour saturation, was found to be a real and measurable phenomenon in the current study. Colour analysis was found to be a useful instrument because it allowed quantification of the problem of poor colour match and fading of the reconstructed nipple-areolar skin. The results of colour analysis demonstrated the difference between transferring skin that is vascularised and transferring it as a graft; the colour of the skin transferred from the abdomen was highly conserved, whereas the graft skin used for the neo-areola faded. The cause of fading of pigmentation in tattoo patients is macrophage mediated, but the mechanism for fading of these pigmented grafts has not been studied, to the author's knowledge. It is interesting to note that the magnitude of the difference in saturation between the normal and reconstructed sides is the same for both the breast skin and the nipple-areolar skin, but the significance of this finding is unclear. Hypothetically the colour of the skin could be under the influence of the underlying soft tissue transferred from the abdomen or the colour of the reconstructed nipple areolar complex could be determined by factors from the surrounding "abdominal" dermis.

The method of colour analysis used in the current study could be useful for comparative studies of different methods of tattoo, for longitudinal studies or for the evaluation of new methods of nipple-areolar pigmentation. It has been shown to be useable for most cases and capable of yielding hard data that is objective. Colour analysis could also be used for evaluation of hypopigmentary disorders and their treatment and has been used previously as a method of burns scar assessment (Davey et

al. 1999).

The informal interviews in the current study served to highlight areas that had not been raised in the questionnaires. The softness / firmness of the nipple reconstruction was an issue for some patients, as was the lack of sensibility. These are areas that it may be useful to examine in a more formal way in future studies. Little's concept that the normal appearance of the breast can help the woman recover from the cancer (Little 1984) was also validated by the comments made by the patients. For the author, the informal interviews were also a useful insight into how the breast reconstructions had impacted on people's lives - a difficult matter to gauge by questionnaires or other standard measures. The overall impression was that women were very pleased with the results of their breast reconstructions, even if not every part of it was perfect.

Little has advocated striving for excellence in nipple-areolar reconstructions so that the reconstructed breast looks like a real breast (Little 1984). The current study shows that there is a need to improve nipple-areolar reconstructions so that they will match the high standards set by current breast mound reconstructions.

Addendum to discussion

Since the study described was carried out, another study looking at aspects of breast and nipple-areolar reconstruction has been carried out by Jabor and colleagues. They found that satisfaction with the breast mound reconstruction was greater than that with nipple-areolar reconstruction. Poor colour match and poor nipple projection were issues that affected patients - results similar to this author's study (Jabor et al. 2002).

CHAPTER 3

PIGMENTATION OF THE NORMAL FEMALE AREOLA

3.1 AIMS AND OBJECTIVES

Aim:

To elucidate the histological basis of the special pigmentary characteristics of nipple-areolar skin.

Objectives:

- To evaluate the amount of melanin present in areolar skin compared to non-specialised (breast) skin.
- To evaluate the quantity of melanocytes present in areolar skin compared to non-specialised (breast) skin.
- To evaluate any other characteristics of areolar skin that impart special pigmentation to it.
- To evaluate whether measures of skin colour correlate with histological findings
- To investigate whether melanocytes in nipple-areolar skin have any special ultrastructural characteristics.

3.2 MATERIALS AND METHODS

3.2.1 Materials

3.2.1.1 Instruments and equipment

Microscope, fume hood, processing machine, water bath, vacuum extractor, microtome, humidity chamber, scalpel, forceps, paint brush, oven set at 37 degrees, -80°C freezer, wax embedding bath.

3.2.1.2 Disposables and glassware

Two glass slide racks, 10 glass staining dishes, aluminium foil, albuminised glass microscope slides, glass cover slips, DePex (Gurr. BDH Laboratory Supplies. Poole, England), silver nitrate, glass Coplin jars, light-proof slide box, sterile specimen pots, cassettes, microtome blades, Superfrost plus microscope slides, wash bottles,

3.2.1.3 Chemicals and solutions

Ethanol at various concentrations, potassium iodide, iodine crystals, sodium thiosulphate, detergent, paraffin wax, deionised water, phosphate buffered saline, PAP pen (Zymed Laboratories Inc.), streptavidin-biotin detection kit (Signet Ultra Streptavidin Detection System; Signet Laboratories, Dedham, MA) 3-amino-9-ethyl carbazole (AEC) (Zymed Laboratories, San Francisco, CA) Faramount aqueous mounting medium (DAKO) diaminobenzidine (DAB) (Signet, Dedham, MA), Proteinase K (DAKO, Carpinteria, CA), Mel-5 (clone TA99) (Signet Laboratories,

Dedham, MA), , NKI / beteb (Monosan, Uden, Netherlands) polyclonal S100 (DAKO, Glostrup, Denmark); clone A103 (Melan A) and T311 (kind gifts from Prof Achim Jungbluth New York), c-kit (clone CD117, DAKO); and CK34 β E12 (DAKO, Carpinteria, CA). Vector VIP substrate kit (Vector Laboratories Inc. Burlingame, CA, USA).

Haematoxylin, neutral red, ammonia water, HistoClear and hydrogen peroxide.

3.2.1.4 Miscellaneous

Stockpot (to act as 100°C water bath) and thermometer.

3.2.2 Skin samples

Skin samples were obtained from patients undergoing elective plastic surgical operations - mainly bilateral breast reductions. The Ethics Committees of The Royal Adelaide Hospital and North Western Health Authority had approved this work and patients were given information sheets (Appendix IV) and consented in writing to donate samples.

Variations on the Masson-Fontana method were tried on various skin samples before the definitive protocol was developed.

Skin samples from twenty patients were used for the quantitative study of melanin and melanocytes in breast and areolar skin. When possible, patients were asked by questionnaire (Appendix XIV) about factors that could influence the pigmentation of the breast / areolar skin, namely: Fitzpatrick skin type, pregnancy, oral contraceptive pill, breastfeeding and topless sunbathing. The details of these patients is shown in Appendix XV.

The skin sample for each breast reduction patient included some areolar skin and some breast skin and all skin samples were placed in 10% formalin overnight before processing.

3.2.3 Method for processing skin samples

Skin samples were placed on a wax tile in a fume hood and the junction of areolar and breast skin was noted. In some cases this junction had been marked by the operating surgeon, using a suture. A strip of skin was cut, with one end being areolar skin and the other end being breast skin. The point of the junction of breast and areolar skin in the strip was marked by cutting a V-shaped notch out of the dermis at that point (Fig. 25). Skin strips were then placed in cassettes and processed overnight prior to paraffin embedding. Skin strips were all embedded such that the areolar end of the skin strip was always orientated the same way within the cassette.

Five micrometre sections were cut from blocks using a microtome until a consistent “ribbon” of sections had been obtained. A pair of adjacent sections were floated on to an albumin-coated slide and a positively charged slide respectively. The next four sections were then discarded and then another pair of adjacent sections were used (Fig. 25). This process continued until there were eight pairs of sections on albumin / positively charged slides, each separated by 20-25 μm intervals. An extra two sections for positively charged slides were also cut for each block. All slides were left in a 37°C oven overnight.

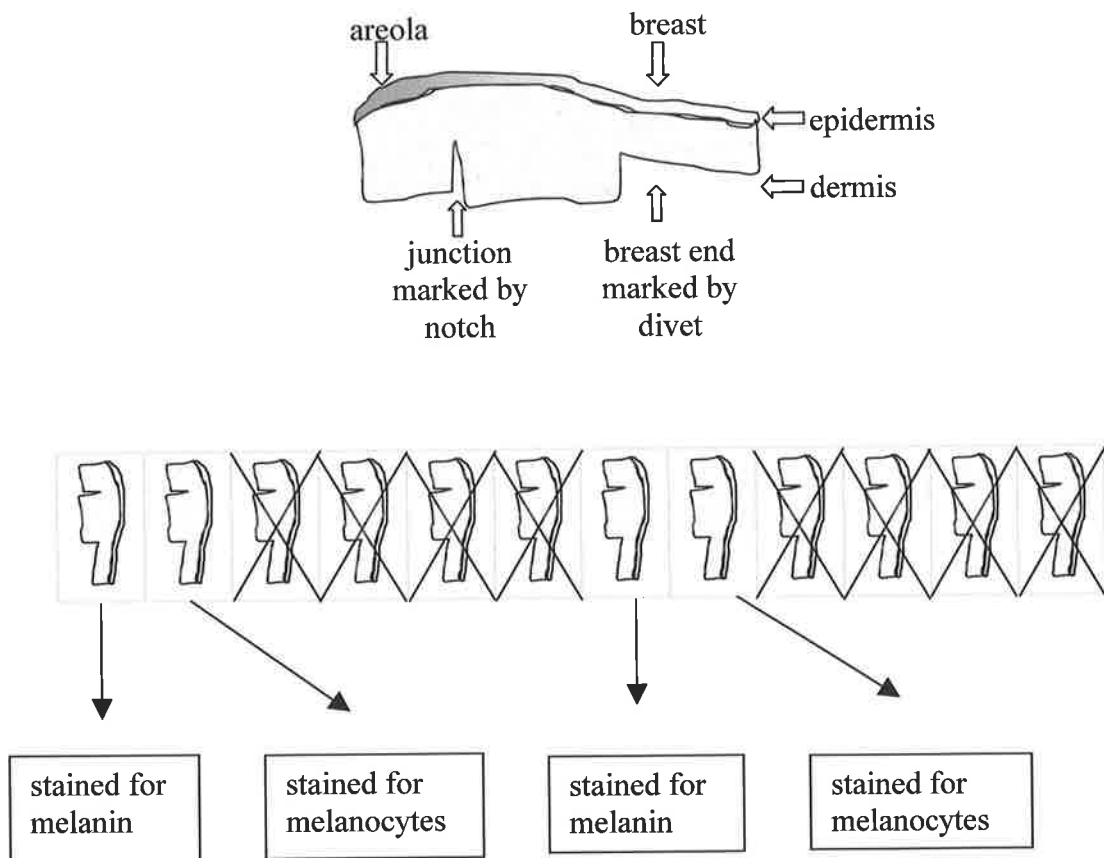


Fig. 25 Schematic representation of protocol for processing skin samples

3.2.4 Method for staining melanin

Masson-Fontana staining of melanin in skin is described using either hexamine silver solution or ammonia / silver solution (Drury and Wallington 1980). With these techniques melanin is seen as a black precipitate (Fig. 26). Early experiments were tried using hexamine silver solution, but this was found to produce inconsistent staining and the definitive set of paired sections were stained with the ammonia / silver solution, as originally described by Masson-Fontana. There did seem to be some batch variation, even with the ammonia / silver solution, so in order to minimise variation in staining, the final sections were stained in only three batches over a time period of two weeks. The final protocol used for staining is appended (Appendix XVII) and an abbreviated version is described:

Ammonia / silver solution was made up fresh. Four grams of silver nitrate were added to 40mls of distilled water and strong ammonia added drop by drop until the brown precipitate that had initially appeared, just disappeared. A further 40 mls of distilled water was added, the solution mixed well and poured into glass Coplin jars.

For each patient's skin sample, the eight breast / areolar sections on albumin coated slides plus a slide with a control section of areolar skin only, were placed in a glass slide rack. The sections were de-waxed with HistoClear, hydrated, treated with Gram's iodine and fixed in sodium thiosulphate before being rinsed in distilled water and left overnight in the ammonia / silver solution. The Coplin jars were covered in aluminium foil and kept in a cupboard to prevent exposure to the light while the slides were in the silver solution. The slides were then rinsed in three changes of distilled water, fixed in sodium thiosulphate and washed in running tap water. They were then counterstained with neutral red and washed again before dehydrating and mounting in

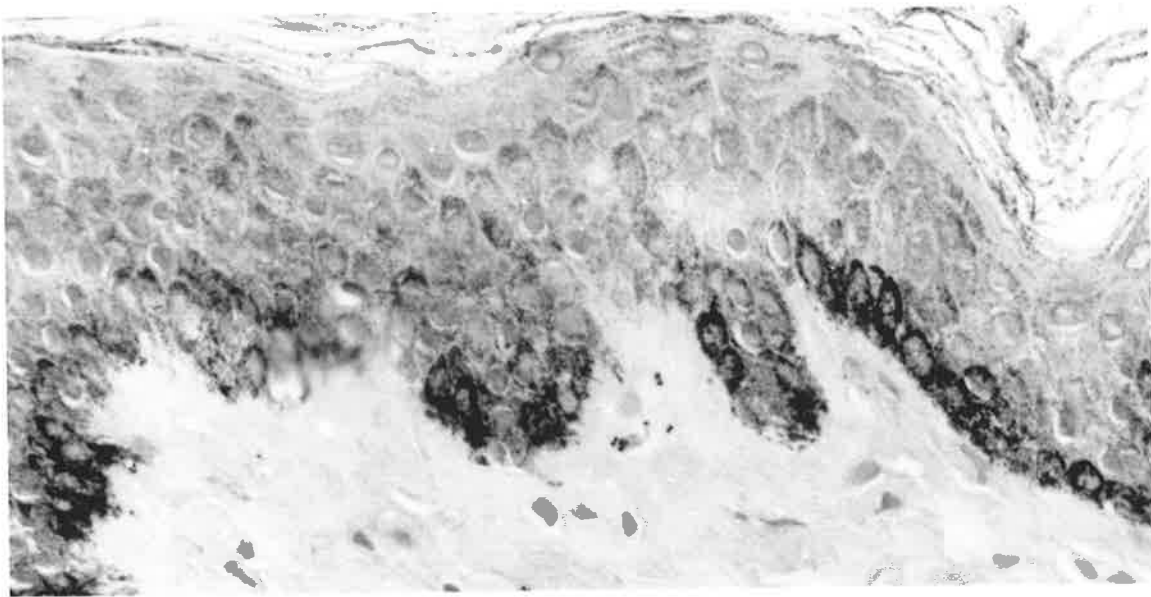


Fig. 26 Masson-Fontana staining of an areolar skin section. Melanin is seen as a black precipitate.

DePex. The slides were then left in the fume hood for two hours and then in the oven at 37°C overnight.

3.2.5 Image analysis of sections stained for melanin

A microscope (Olympus BH2) with a colour digital video camera (Sony HyperHAD) and Image Pro Plus (Version 4, Media cybernetics, Silver Spring, MD) computer software was used for analysis of the stained tissue sections. For all eight of the sections stained with the Masson-Fontana method, three images of x20 fields of areolar skin and three images of x20 fields of breast skin were captured for each of the eight sections for each specimen. Images of two sections were then selected for analysis, based on technical quality of the slide preparation and clarity of staining. The computer software enabled the user to trace and measure an irregular line on an image. The six images of areolar skin and six images of breast skin for each specimen had length of skin surface and length of basement membrane measured in this way.

The cross-sectional area of the epidermis within the x20 image was measured by the author tracing around the limits of the viable epidermis (excluding the stratum corneum) (Fig. 27) and the computer then reporting the area of the outlined part of the image. The computer software could also calculate the area of any distinctive colour - in this case the quantity of black stain (representing melanin). From these basic measurements, percentage of epidermal cross-section occupied by melanin, amount of melanin per length of skin surface and amount of melanin per length of basement membrane were calculated.

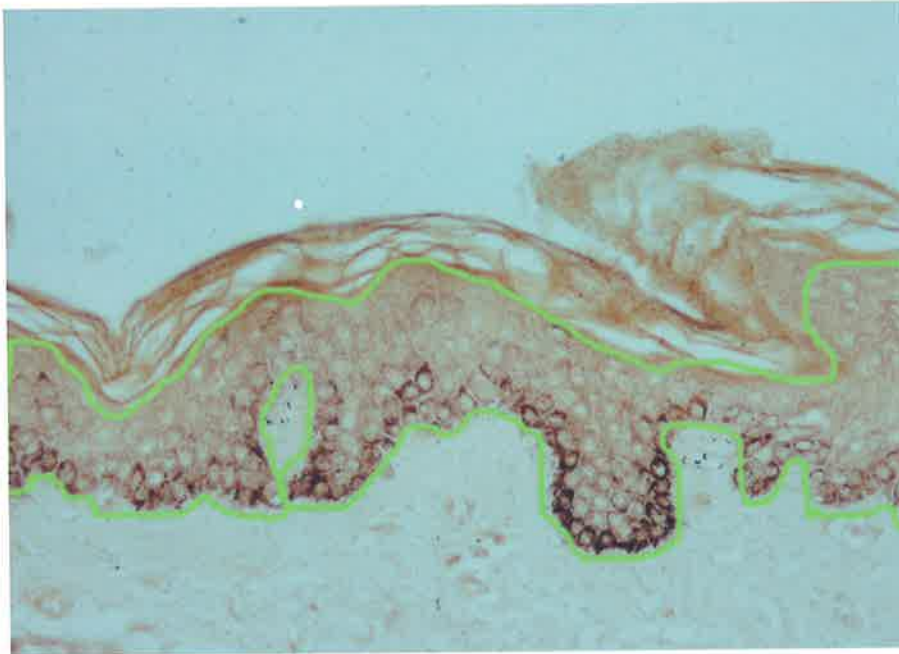


Fig. 27 Outlining the viable epidermis of a section stained with Masson-Fontana stain for melanin.

3.2.6 Comparative immunohistochemistry for the detection of melanocytes

3.2.6.1 Introduction and basic method

Because the aim of this study was to quantify the number of melanocytes in areolar skin, it was important to be sure that all melanocytes were detected. From the literature (Bhawan 1997), the monoclonal antibody TA99 (Mel-5) seemed the most likely to detect all melanocytes. To assess more formally the sensitivity of Mel-5 and other antibodies for detection of normal melanocytes, a range of preliminary experiments were performed on non-numbered sections of breast and areolar skin followed by a comparative study using the paired parallel sections of skin described above.

Immunoperoxidase labelling was carried out using a streptavidin-biotin detection method in a kit form (Signet). Negative controls were performed by substituting mouse supernatant X63 (Kohler and Milstein 1975) for murine primary antibodies, and normal rabbit immunoglobulins for rabbit primary antibodies. Normal areolar skin and malignant melanoma were used as positive controls. Sections labelled with the melanocyte detecting primary antibodies S100 protein, Mel 5, Melan A, NKI/beteb, c-kit and vimentin were visualised with the chromogen AEC and mounted in Faramount aqueous mounting medium, while sections labelled with the keratinocyte-staining antibody CK34 β E12 were visualised with DAB and mounted in DePex.

3.2.6.2 Preliminary experiments

Anti-vimentin and HMB-45 antibodies were tested in preliminary experiments but were not used for the 20 sets of parallel sections. A number of anti-cytokeratin

antibodies were tested for the labelling of basal keratinocytes and hence the creation of a negative image of the melanocytes. The anti-human high molecular weight cytokeratin 34 β E12 was used to identify basal keratinocytes in the final parallel sections. Merkel cells are also left unlabelled by CK34 β E12 (Frisman and Taylor 1994) but are so infrequent in number in the basal layer of the epidermis as to be insignificant in this context (Lacour et al. 1991). To verify this, two sections of skin were stained for synaptophysin and two for neurofilaments.

3.2.6.3 Optimising conditions for Mel-5 staining

Sections of skin were labelled with Mel-5 (clone TA99) using a variety of protocols. Antigen recovery was performed using the following protocols:

- Proteinase K at room temperature for 15 mins;
- heat induced epitope retrieval (HIER) with citrate buffer for 10 mins \pm Proteinase K for 15 seconds, 1 minute or 5 mins;
- HIER with 70% formic acid \pm Proteinase K for 15 seconds, 1 minute or 5 minutes.

Different incubation temperatures for the primary antibody were tested:

- 4°C overnight
- room temperature overnight
- room temperature for 30 mins followed by 4°C overnight

Different dilutions of Mel-5 were also tested; 1:10 and 1:20.

3.2.6.4 Immunostaining of melanocytes for quantitative comparison of different primary antibodies

In the twenty sets of parallel sections the primary antibodies Mel-5 (clone TA99), NKI / beteb, polyclonal S100, Melan-A (clone A103), T311, c-kit (clone CD117) and CK34 β E12 were used.

In the parallel sections, primary antibodies were used with the dilutions and antigen retrievals shown in Table 7. All primary antibodies were incubated overnight at room temperature in a humidified chamber.

Table 7 Dilutions and antigen retrieval techniques of the primary antibodies used in the comparative study of immunohistochemical detection of normal melanocytes

<i>primary antibody</i>	<i>dilution</i>	<i>enzyme treatment</i>	<i>HIER</i>
Mel-5 (clone TA99)	1:20	Proteinase K 15 mins	none
NKI / beteb	1:10	Proteinase K 15 mins	none
S100	1:10 000	none	none
Melan A (clone A103)	1:5000	none	citrate buffer pH6 at 97°C for 30 mins
T311	1:1000		citrate buffer pH6 at 97°C for 30 mins
c-kit	1:100	none	none
CK34 β E12	1:50	Proteinase K 15 mins	none

3.2.7 Final method of detecting melanocytes for quantitative study of melanocytes in parallel sections of areolar / breast skin.

The sections of skin that were the adjacent “pairs” of those stained and analysed for melanin (two for each patient’s specimen), were immunohistochemically labelled with Mel-5 (clone TA99). (Protocol - Appendix XVII).

Aliquots of Mel-5 were stored in a -80°C freezer. Two 10µl aliquots were thawed and diluted to 1:20 with normal serum (kit blocking reagent). Sections were first de-waxed and hydrated. Sections were circled with a PAP pen then immersed in phosphate buffered saline (PBS). In a humidifying chamber the sections were treated with proteinase K solution (1 drop of proteinase K in 2mls of TRIS-HCl buffer pH 7.6) for 15 mins at room temperature. Sections were rinsed three times with PBS then treated with 3% hydrogen peroxide for 5 minutes. After rinsing three times with PBS, 1 to 3 drops of the Mel-5 / TA99 antibody in normal serum were placed on the sections for overnight incubation at room temperature in a humidified chamber. In the negative control section, the X63 was substituted for the Mel-5. After rinsing with PBS, the biotinylated secondary antibody (kit linking reagent) was applied to the sections for 20 minutes. After further rinsing with PBS the Streptavidin (kit labelling reagent) was applied for 20 minutes. While this incubation was taking place the AEC was made up from the AEC kit using distilled water.

After rinsing with PBS one to two drops of AEC were applied to the sections and the reaction observed under the microscope for 3 to 12 minutes. The chromagen was washed off using deionized water. The author tended to err on the side of overdevelopment of the chromagen because underdeveloped sections may have left some melanocytes difficult to visualise and the only side effect of overdevelopment was

background staining of the dermis, which did not affect the quantification of stained basal epidermal cells.

Sections were then counterstained with haematoxylin and mounted in Faramount aqueous mounting medium. Slides were left overnight at room temperature in a fume hood then packed into lightproof boxes and put in the fridge until image analysis was performed.

To ensure that the AEC was not deteriorating over time a single area on a single section of skin was monitored and the number of stained cells counted. Monitoring took place five times over the period between staining and final image analysis.

3.2.8 Image analysis for sections immunostained for melanocytes

Immunoperoxidase labelled sections were protected from light until the study was completed. A microscope (Olympus BH2) with a colour digital video camera (Sony HyperHAD) and Image Pro Plus Version 4, (Media cybernetics, Silver Spring, MD computer software) were used for analysis of the stained tissue sections.

3.2.8.1 Comparison of sensitivities of primary antibodies

For comparison of different antibodies for sensitivity to detect normal melanocytes, two x10 fields were captured for each of the tissue sections; one of breast skin and one of areolar skin. The length of basement membrane that was in the x10 field was measured on the computer screen using computer software that allowed the user to trace and measure an irregular line. Each part of the x10 field was surveyed with x40 magnification and melanocytes were manually counted (Fig. 28).

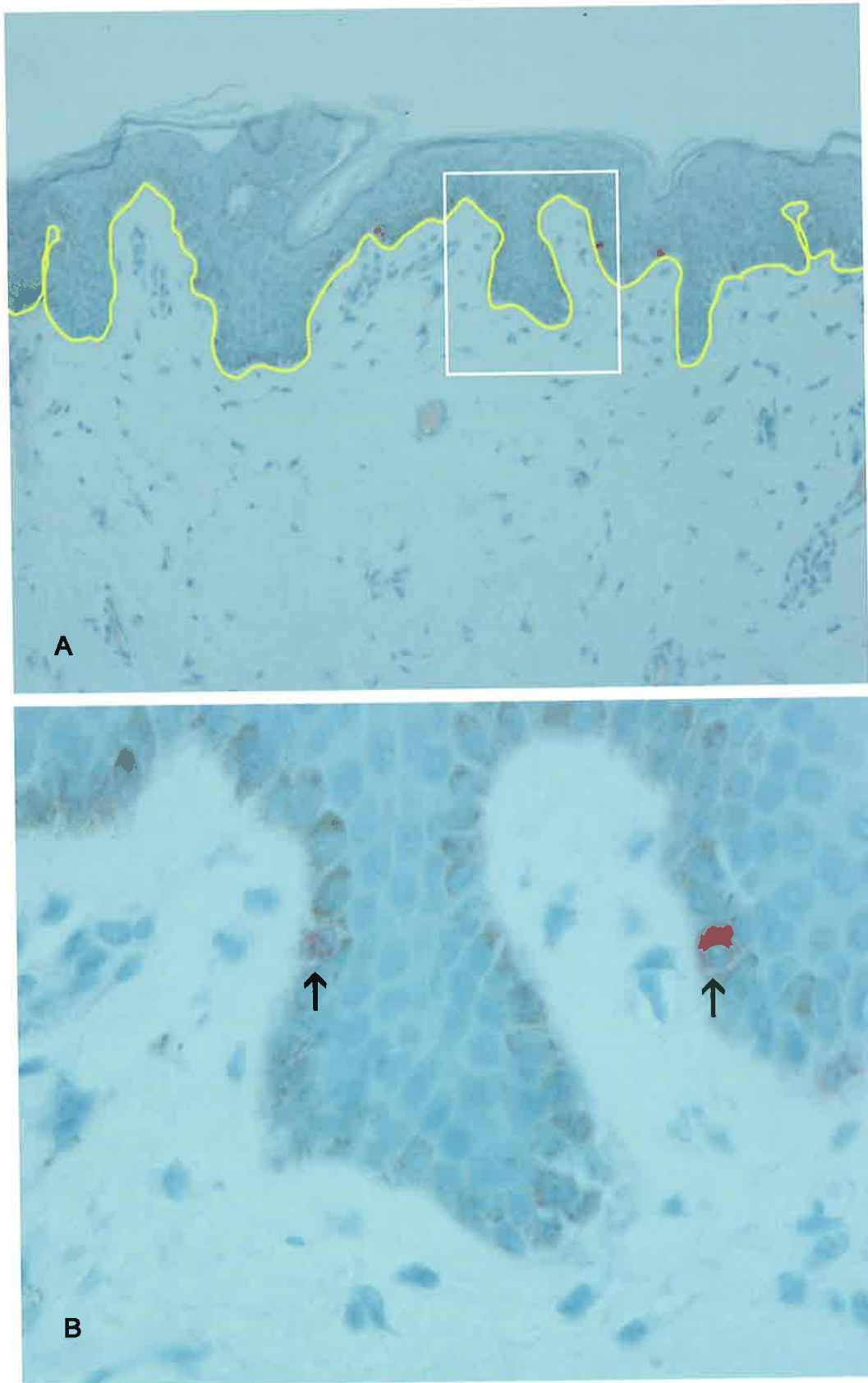


Fig. 28 Image analysis of sections for comparison of antibody staining - **A** x10 field used as total area to be measured and for measurement of basement membrane **B** x40 magnification used to count labelled melanocytes.

The x40 magnification was used because it was too difficult to see the stained cells on a x10 image. The number of stained melanocytes per length of basement membrane was then calculated for each of the primary antibodies used.

3.2.8.2 Quantity of melanocytes in normal areolar skin

The two sections adjacent to those used for image analysis of melanin content were those used for immunohistochemical staining with Mel-5 (Fig. 29). Six “areolar” and six “breast” images were captured, as for the sections stained for melanin. The number of red-stained cells (representing melanocytes) and the number of basal keratinocytes in each image was counted manually and the length of basement membrane and skin surface were measured. Number of melanocytes per length of basement membrane and per length of skin surface were then calculated, as well as amount of melanin per melanocyte and ratio of melanocytes to keratinocytes.

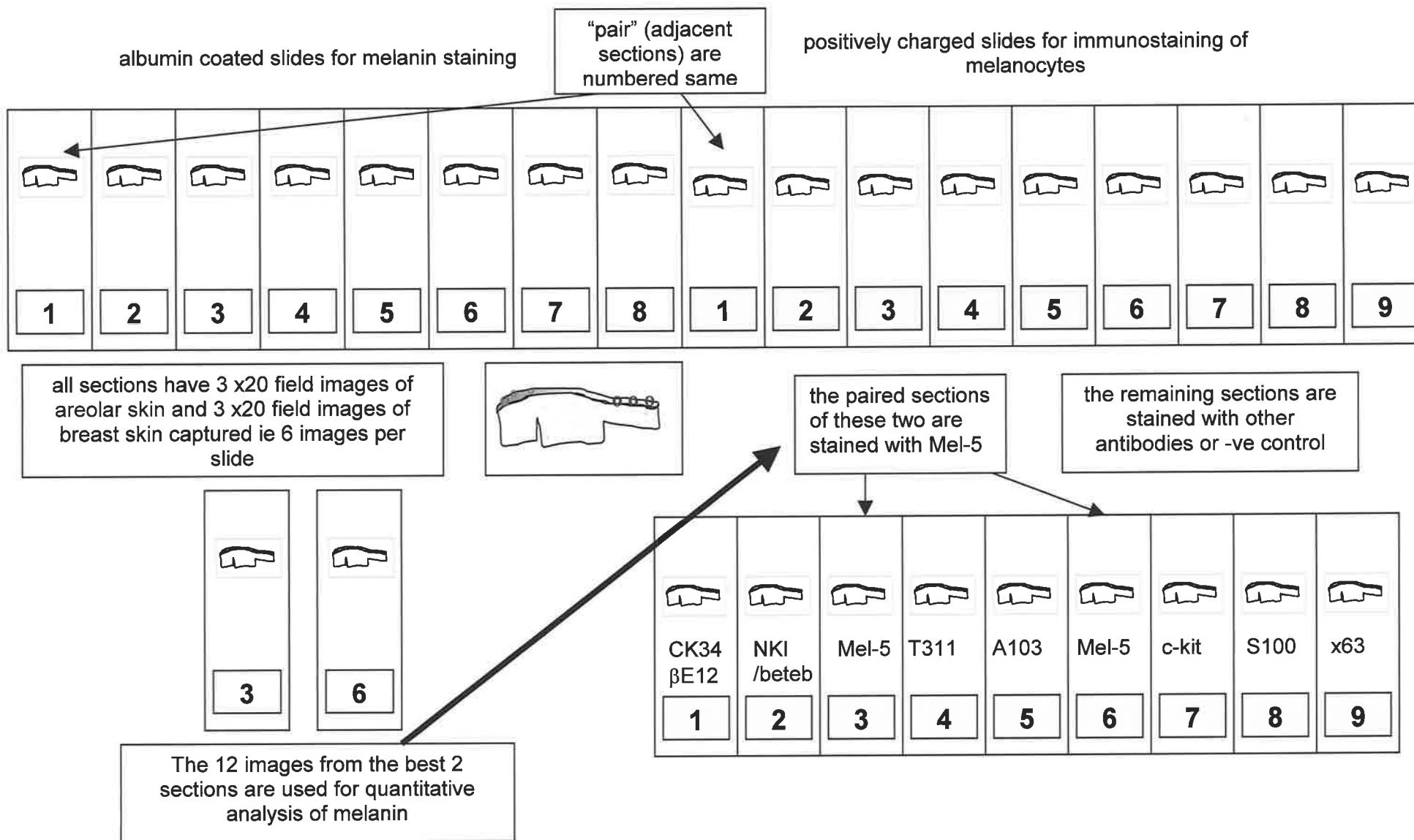


Fig. 29 Use of paired sections for staining for melanin and for melanocytes

3.2.9 Method for electron microscopy

A specimen of areolar skin was collected in 3% glutaraldehyde / 3% formaldehyde made up in 0.2M phosphate buffer pH 7.4, to which had been added 2.5% polyvinyl pyrrolidone and transported to the laboratory where it was cut into 1mm² pieces. These pieces were then post-fixed in 1% osmium tetroxide in buffer and dehydrated in a series of alcohols. The tissues were then embedded in TAAB® embedding resin. One micron survey sections were cut and stained with toluidine blue. Ultrathin sections were then cut and stained with uranyl acetate and lead citrate on rhodium / copper grids. Sections were examined using a Phillips CM 100 transmission electron microscope.

3.3 RESULTS

3.3.1 Electron microscopy of areolar skin

Electron microscopy of the areolar skin of a Caucasian woman revealed melanosomes to be present singly in the dendrites of melanocytes and in groups within the keratinocytes of the melanin-epidermal unit (Fig. 30), which is the usual configuration for Caucasian skin. There were no other distinctive ultrastructural features seen in the specimen examined.

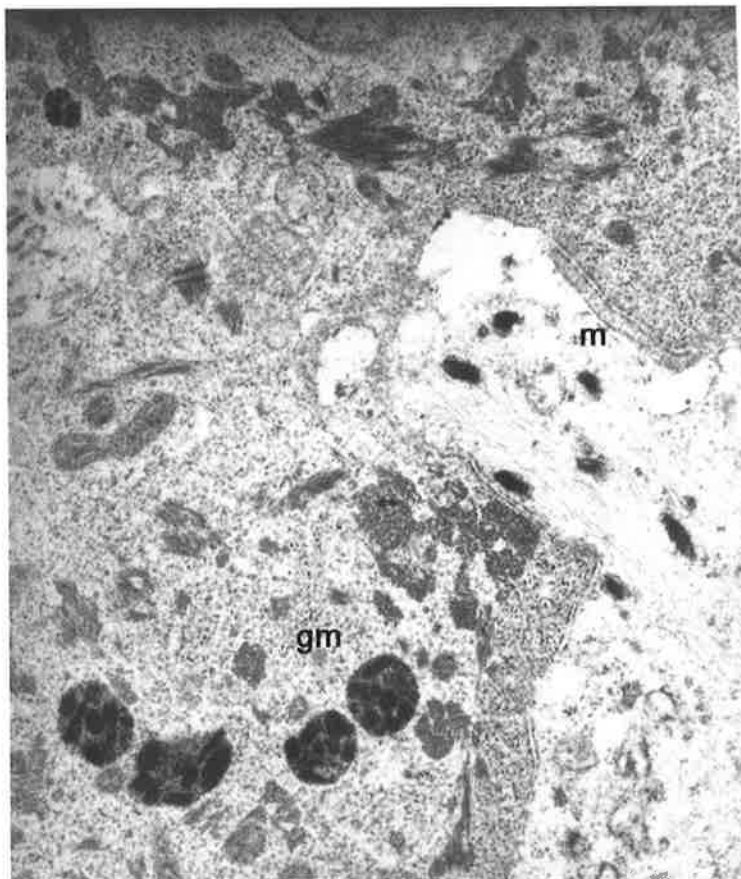
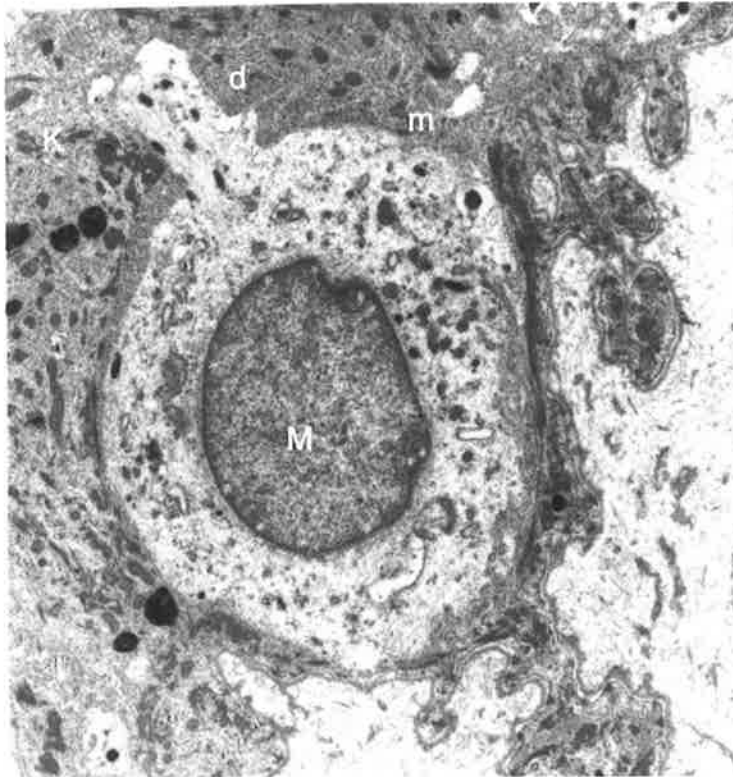


Fig. 30 Electron microscopy of melanocyte (M) and adjacent keratinocyte (K). Single melanosomes (m) are seen within the dendrite (d) of the melanocyte while groups of melanosomes (gm) are seen within the cytoplasm of the keratinocyte.

3.3.2 Amount of melanin in breast skin vs areolar skin

There is a significantly higher percentage of the epidermis occupied by melanin in areolar skin compared to breast skin (Fig. 31 and Fig. 32). Melanin takes up a mean of 8.01% of the epidermal area (excluding the stratum corneum) (variance=29.22) in areolar skin whereas it takes up a mean of 3.48% of the epidermal area (variance=14.51) in breast skin. On paired t-testing the significance of the difference (two tailed) $p < 0.0001$. On average, areolar skin had a 2.5 fold higher melanin content than breast skin (median = 2.48, range 1.20 - 18.18). The median was used in this case, rather than the mean because the data was skewed due to samples with very low content of melanin in the breast skin, yielding high ratios.

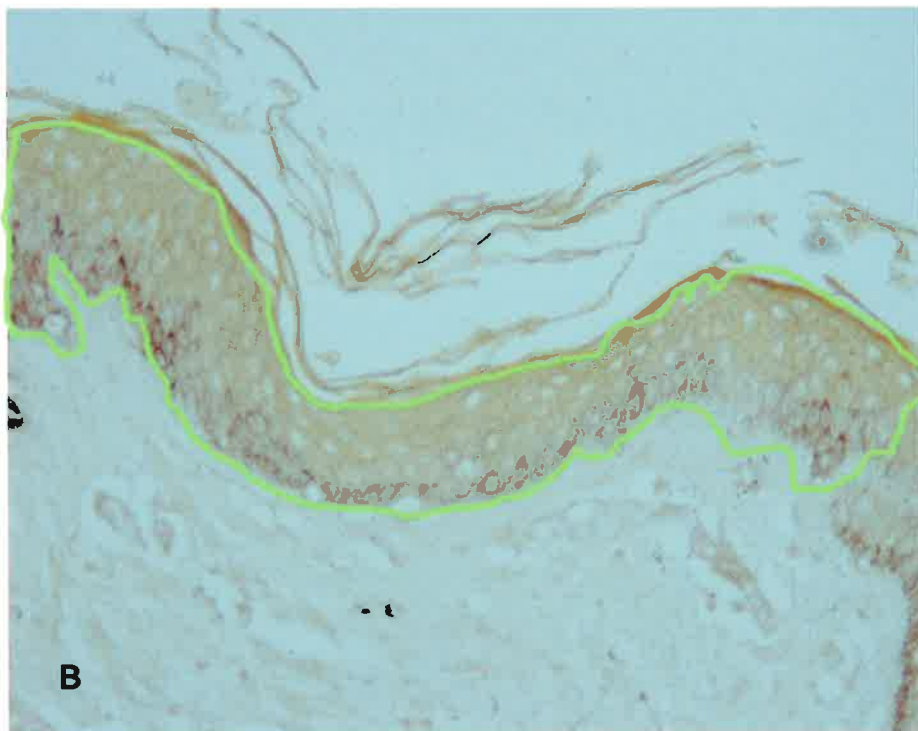
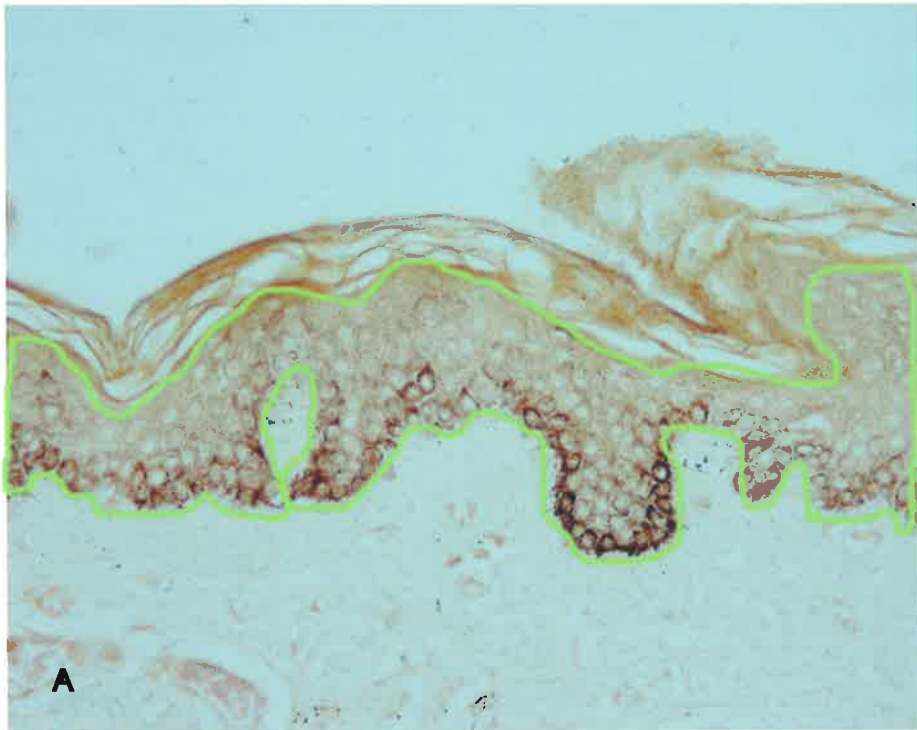


Fig. 31 Melanin content of A areolar skin and B breast skin. The area of the viable epidermis is outlined in green (the stratum corneum is excluded) and the melanin is seen as a black stain in the basal epidermis.

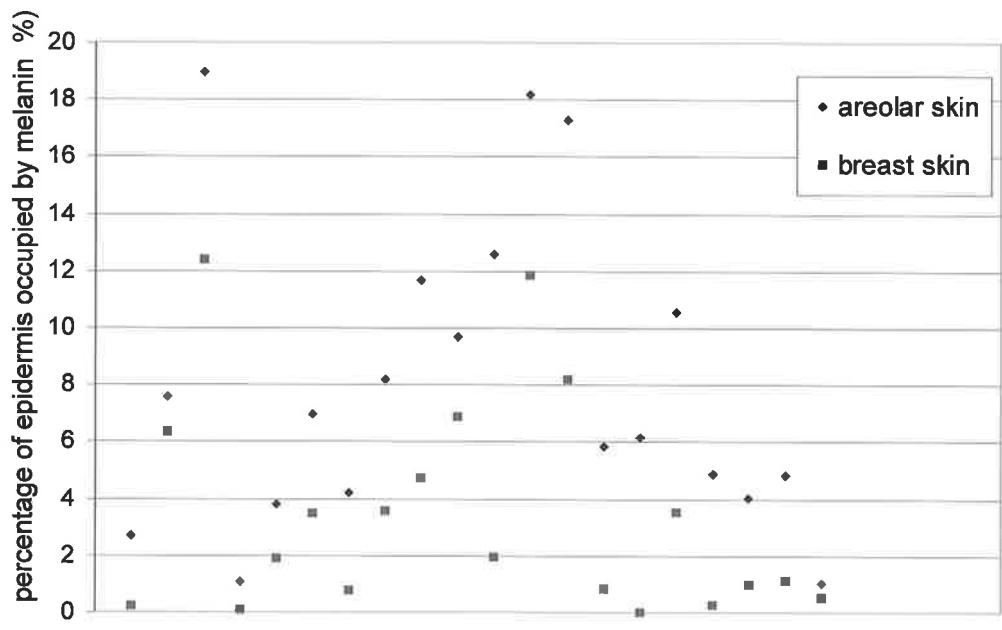


Fig. 32 Percentage of epidermis occupied by melanin in areolar and breast skin

The amount of melanin present per length of skin surface was found to be greater in areolar skin than breast skin (Fig. 33). On paired t-tests: mean (areola) = $5.07 \mu^2/\mu$ (variance=13.69), mean (breast) = $1.82 \mu^2/\mu$ (variance=3.77) $p < 0.0001$.

The amount of melanin present per length of basement membrane was found to be greater in areolar skin than breast skin (Fig. 34). On paired t-tests: mean (areola) = $3.17 \mu^2/\mu$ (variance=3.99), mean (breast) = $1.57 \mu^2/\mu$ (variance=3.33) $p < 0.0001$.

The basement membrane within a x20 field was significantly longer in areolar than breast skin ie the basement membrane was more convoluted in areolar than breast skin. On paired t-tests: mean length of basement membrane in the x20 field was 5676.6μ (variance = 424041.4) for areolar skin and 3561.6μ (variance = 295854.8) for breast skin $p < 0.0001$. Because the basement membrane of areolar skin is convoluted there is more melanin per length of skin surface than per length of basement membrane. Two factor analysis of variance with replication shows that the increased convolution of the areolar basement membrane compared with breast basement membrane is not the sole factor in the higher amount of melanin per length of skin surface present in areolar skin (Table 8).

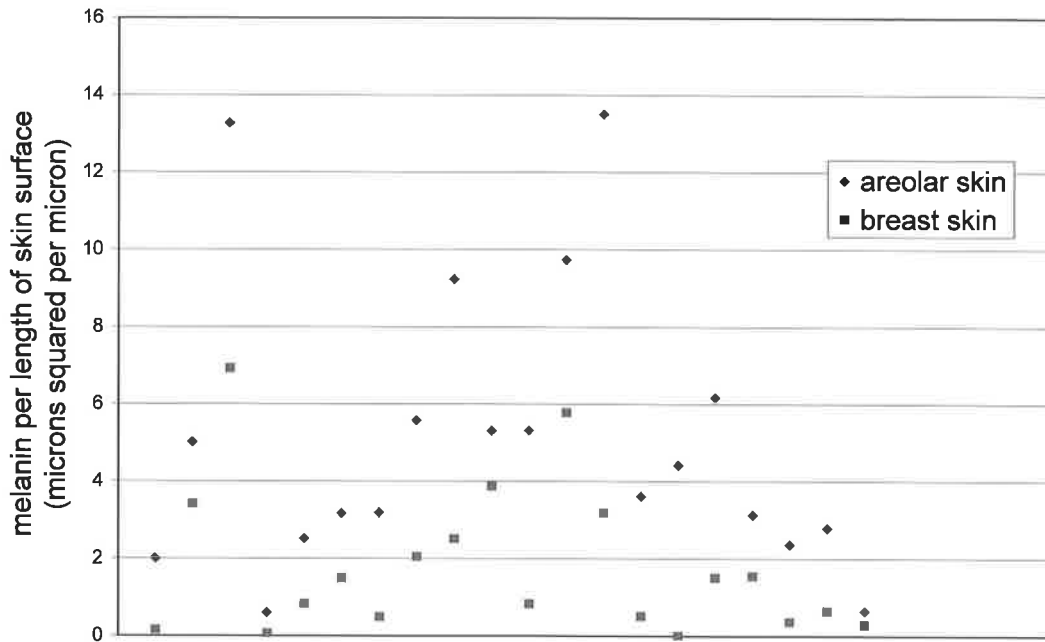


Fig. 33 Amount of melanin per length of skin surface in areolar and breast skin

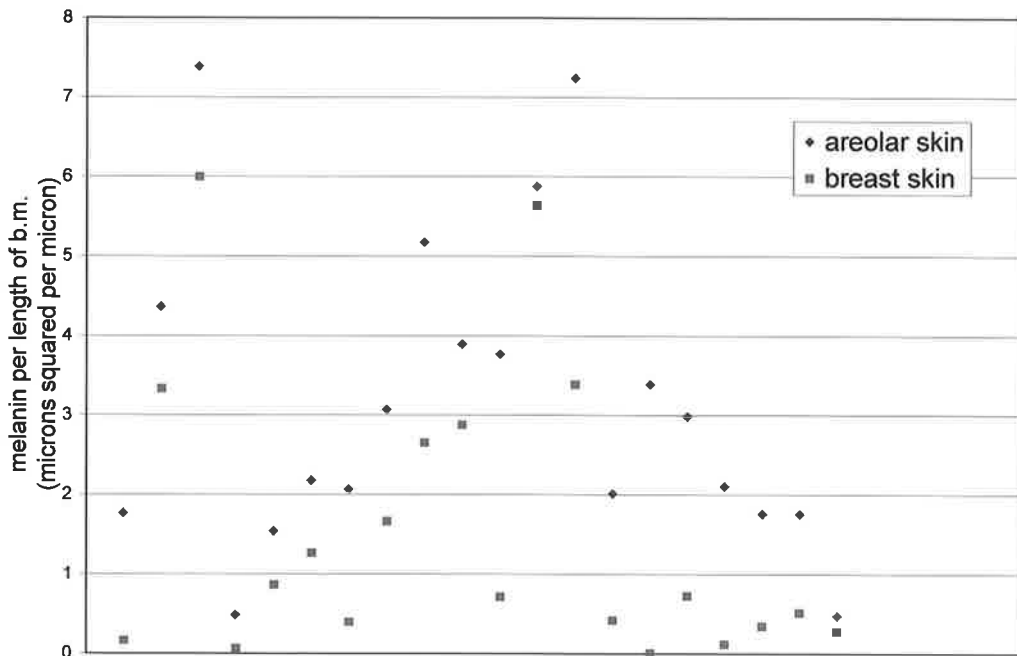


Fig. 34 Amount of melanin per length of basement membrane in areolar and breast skin

Table 8 Two way analysis of variance between melanin content of breast and areolar skin and measurements per length of basement membrane and per length of skin surface

	<i>amount of melanin per length of basement membrane</i>	<i>amount of melanin per length of skin surface</i>	<i>total</i>
<i>areola</i>			
count	20	20	40
sum	63.31	101.44	164.75
average	3.17	5.07	4.12
variance	3.99	13.70	9.55
<i>breast</i>			
count	20	20	40
sum	31.35	36.34	67.69
average	1.57	1.82	1.69
variance	3.33	3.77	3.47
<i>Total</i>			
count	40	40	
sum	94.66	137.78	
average	2.37	3.44	
variance	4.22	11.23	

<i>source of variation</i>	<i>SS</i>	<i>F</i>	<i>F crit</i>	<i>p-value</i>
sample (between breast and areola)	117.76	19.00	3.97	0.00004
columns (between skin surface and basement membrane)	23.25	3.75	3.97	0.06
interaction	13.72	2.21	3.97	0.14
within	470.94			
total	625.68			

3.3.3 Relationship between amount of melanin in skin and Fitzpatrick sun sensitivity skin type

The Fitzpatrick sun sensitivity skin type was assessed in nine patients. The amount of melanin per length of skin surface in breast skin correlates with measured Fitzpatrick types of the patients on regression analysis ($p < 0.05$), although conclusions should be guarded in such a small number of patients. There was no significant correlation between Fitzpatrick sun sensitivity type and areolar skin melanin content.

3.3.4 Correlation of amount of melanin in skin and measured skin colour

There were five photographs of skin donors which had colour standards included and were available for colour analysis. There was no significant correlation found between measured hue or saturation and measured melanin content of the removed skin.

3.3.5 Comparison of different primary antibodies for the immunohistochemical detection of normal melanocytes

3.3.5.1 Results of preliminary experiments

HMB-45 failed to label normal melanocytes. Vimentin was deemed too non-specific, as it also labelled dermal fibroblasts and other mesenchymal elements making the identification of the normal melanocytes extremely difficult (Fig. 35).

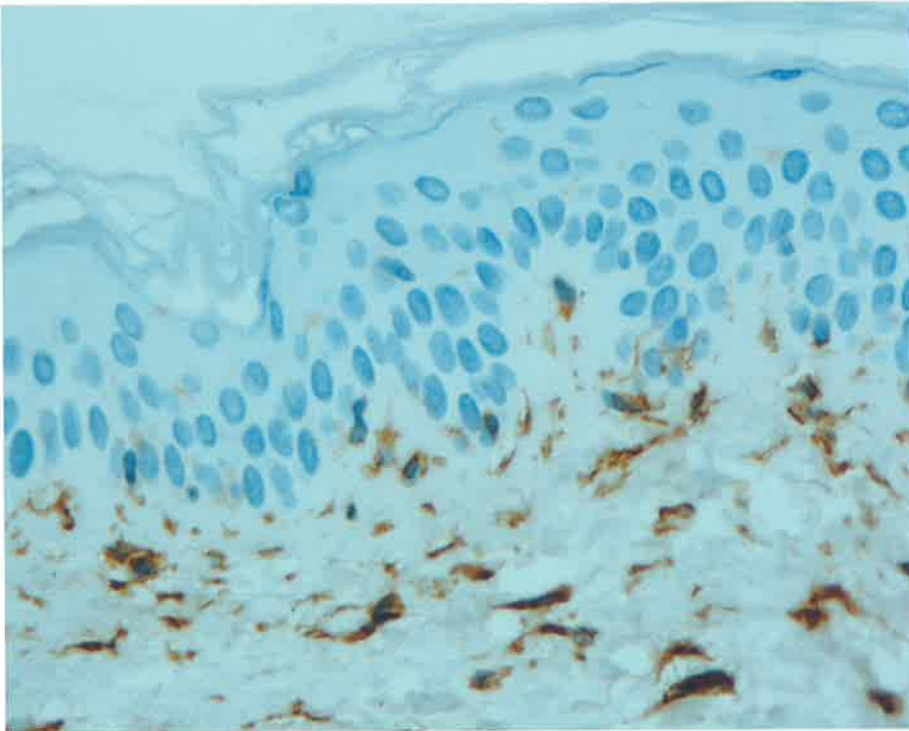


Fig. 35 Labelling with anti-vimentin antibody demonstrates simultaneous labelling of melanocytes and fibroblasts

Although not restricted to the basal layer of keratinocytes, CK34 β E12 gave a clear negative image that enabled counting of unlabelled basal cells (Fig. 36). No Merkel cells were identified in the basal layer of the epidermis of skin sections stained with synaptophysin or neurofilaments. Positive control sections of islets of Langerhans and cerebral cortex respectively were labelled, as were internal positive controls. Basal epidermal cells left unlabeled by CK34 β E12 were therefore taken as being melanocytes in the parallel sections.

3.3.5.2 Conditions for Mel-5 labelling

Optimal labelling for Mel-5 was achieved following digestion with Proteinase K for 15 minutes, at room temperature. Heat induced epitope retrieval (HIER) with citrate buffer plus Proteinase K (for 15 seconds, 1 minute or 5 minutes) resulted in tissue damage and reduced labelling and was not used further.

Sections incubated for 30 minutes at room temperature followed by overnight incubation at 4°C showed more than double the number of melanocytes labelled (176 cells) compared to sections incubated overnight at 4°C alone (84 cells) (Fig. 37). There was no obvious difference between sections incubated at room temperature for 30 mins, before overnight at 4°C; and those that were incubated at room temperature overnight. Increasing the primary concentration of Mel-5 from 1:20 to 1:10 increased background staining but not the number of stained melanocytes.

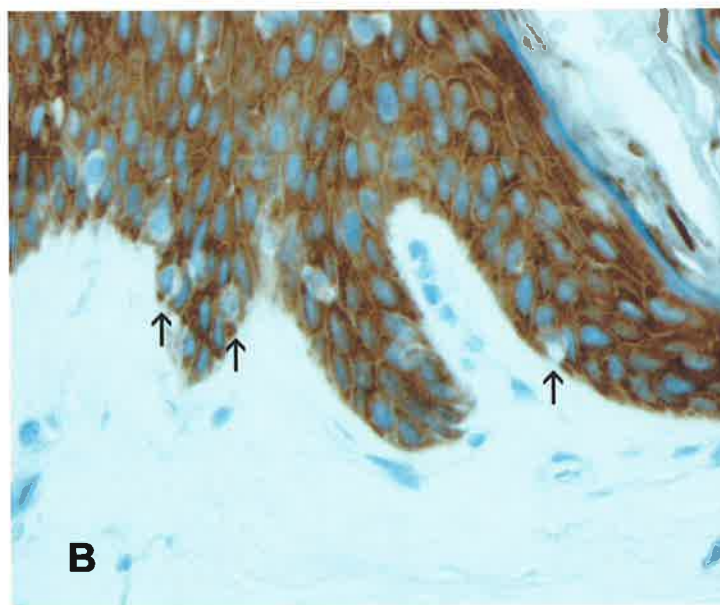
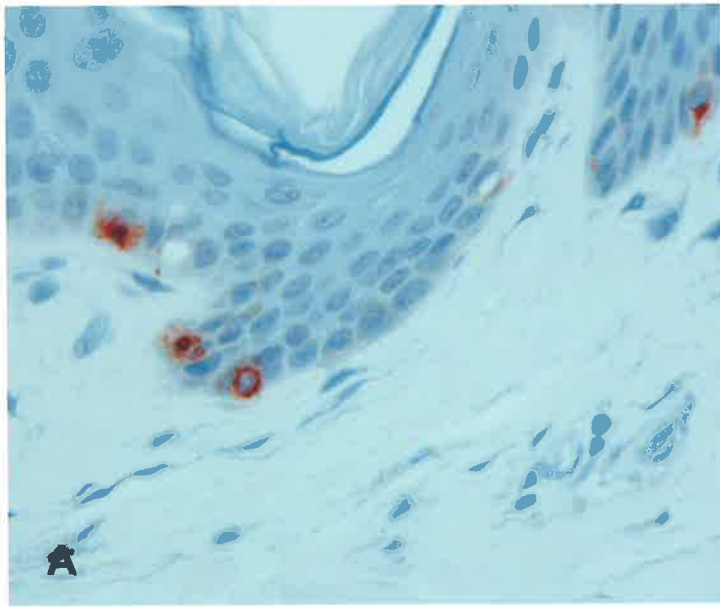


Fig. 36 Using the high molecular weight cytokeratin antibody CK34 β E12 to establish the sensitivity of melanocyte antibodies. **A** skin stained with Mel-5 **B** parallel section stained with CK-34 β E12, giving negative image of melanocytes

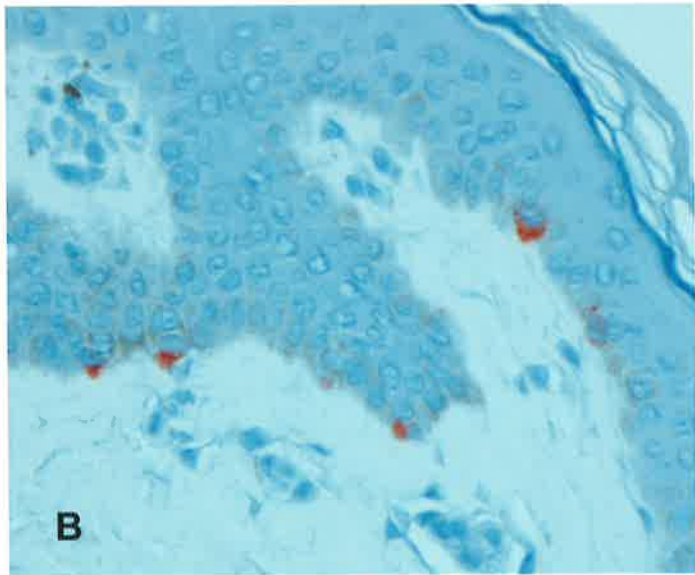
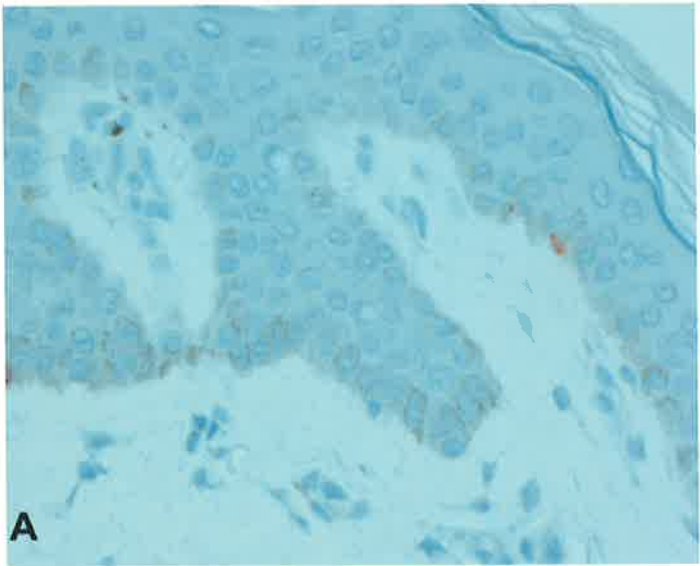


Fig. 37 Effect of temperature on Mel-5 staining in parallel sections of skin. **A** Incubation of the primary antibody overnight at 4°C. **B** Incubation of the primary antibody for 30 mins at room temperature before overnight incubation at 4°C

3.3.5.3 Immunostaining of melanocytes for quantitative comparison of different primary antibodies

In the parallel sections, the positive control sections of malignant melanoma stained positively with A103, S100, NKI / beteb, T311 and c-kit and weakly with Mel-5 (Fig. 38). Negative control slides with X63 and normal rabbit serum showed no staining. Of the 140 stained slides, five had damage to the sections and were not useable for image analysis. Nine of the twenty slides stained with c-kit showed poor localisation of staining (Fig. 39), making it impossible to count stained cells in these sections.

The mean length of basement membrane measured for each section was 3.61mm ($s = 2.10$). Samples of skin stained with each melanocyte antibody are shown in figure 40. On analysis of variance there is a significant difference ($p < 0.001$) between the antibodies in terms of number of melanocytes stained per length of basement membrane. Staining of skin with Mel-5 detected twice the number of melanocytes as the next most sensitive antibody, NKI / beteb (Table 9).

There was no significant difference between the number of melanocytes detected (in a $\times 10$ field) by staining with Mel-5 compared with absence of staining with CK34 β E12 (a keratinocyte antibody). On two-sample t-testing of pooled results (ie areola plus breast), assuming equal variance:-

mean number of melanocytes detected by mel-5 = 30.25 (variance=238.93)

mean number of melanocytes detected by (absence of) CK34 β E12 = 27.80 (variance=82.06)

$p=0.55$. Similar results were found when breast skin and areolar skin were examined separately.

On regression analysis of the means, with three outliers removed, there is a significant linear correlation between Mel-5 and CK34 β E12 ($p < 0.05$). This confirms that Mel-5 stains all the melanocytes present in the skin samples under the conditions used.

Table 9 Number of melanocytes per mm of basement membrane for different immunohistochemical methods of identifying melanocytes in whole skin specimen

	<i>Mel – 5</i>	<i>CK34βE12</i>	<i>NKI / beteb</i>	<i>T311</i>	<i>A103</i>	<i>c-kit</i>	<i>S100</i>
<i>mean</i>	8.80	8.91	4.13	2.05	1.44	2.64	0.43
<i>standard deviation</i>	3.74	2.86	3.13	1.11	2.72	2.27	.051
<i>standard error of mean</i>	0.84	0.66	0.70	0.26	0.64	0.72	0.11




Fig. 38 Staining of positive controls (nodular melanoma) for different primary antibodies. Brown pigmentation from melanin is seen (m) as well as the red immunohistochemical staining (s) with AEC

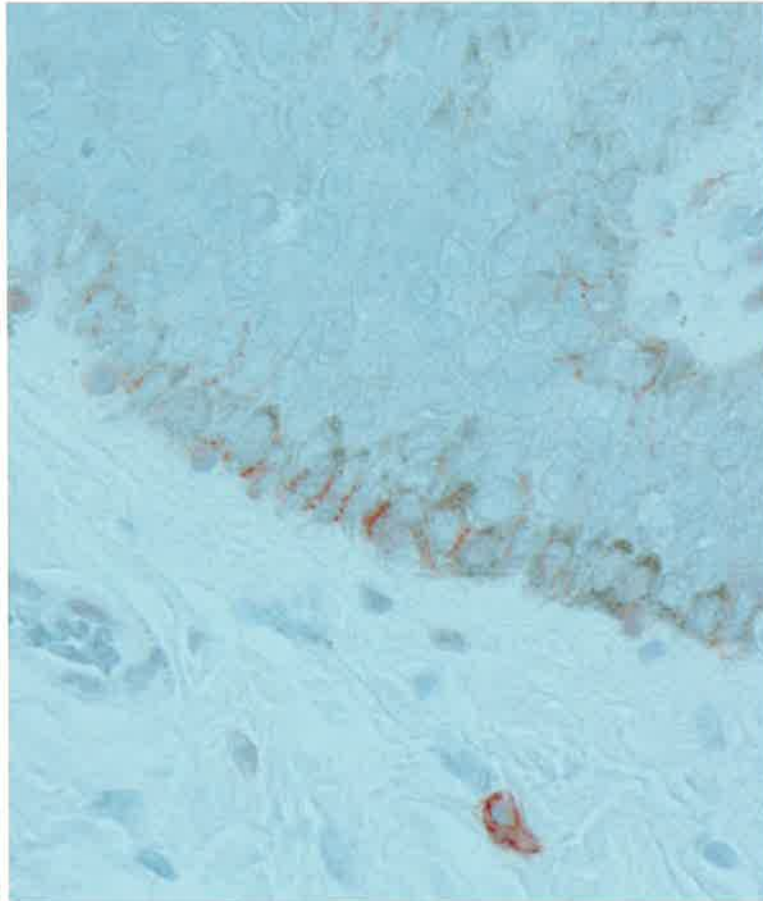


Fig. 39 Staining of skin sections with anti-c-kit antibody stains normal melanocytes but is often poorly localised.

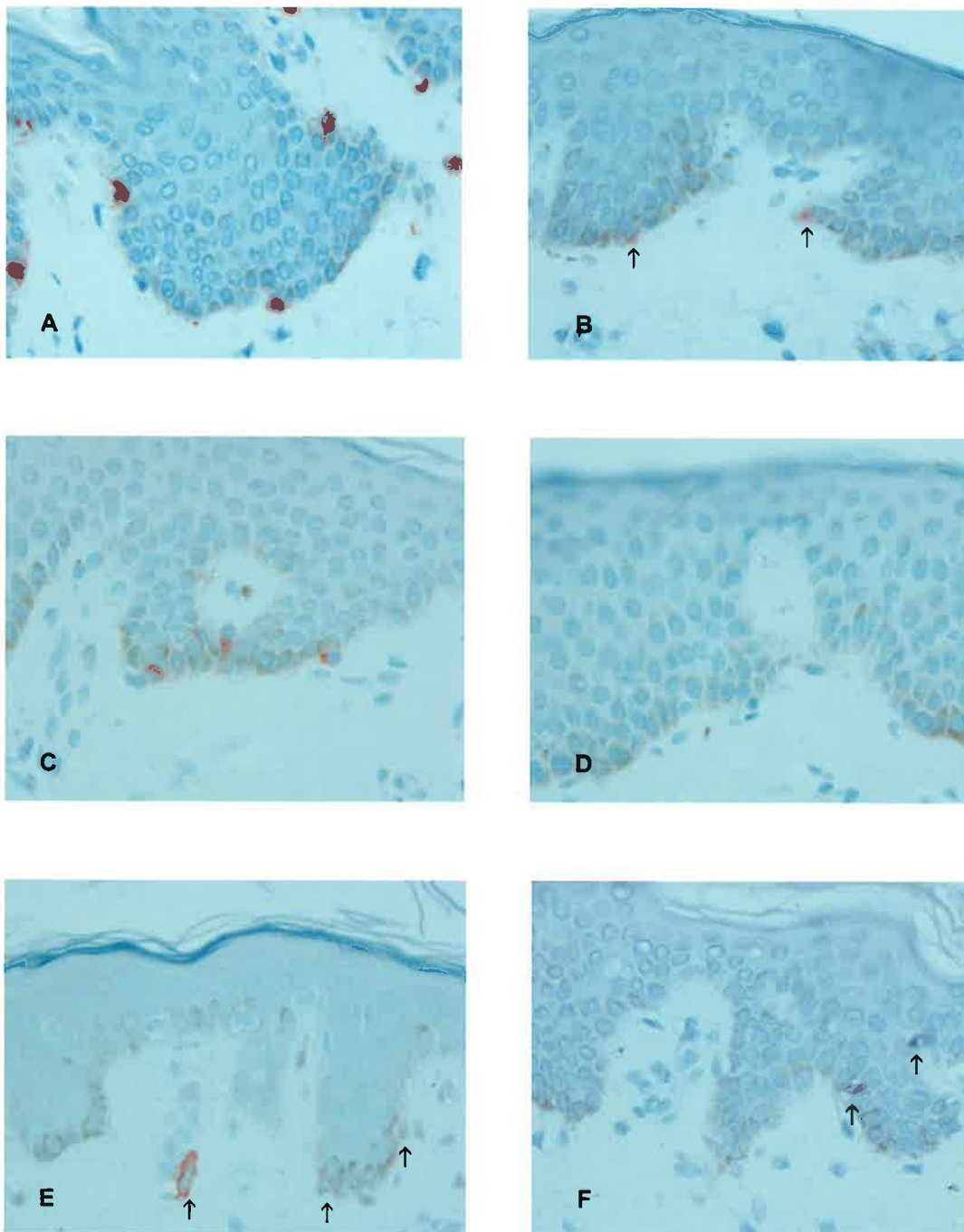


Fig. 40 Staining of parallel sections of skin with different antibodies for the identification of melanocytes **A** Mel-5, **B** NK1 / beteb, **C** T311, **D** A103 (Melan A), **E** c-kit, **F** S100 (VIP used as chromogen)

3.3.6 Quantity of melanocytes, melanocyte to keratinocyte ratios and amount of melanin per melanocyte in areolar and breast skin

There is a significant difference between the number of melanocytes per length of basement membrane in breast and areolar skin. On paired t-testing: mean number of melanocytes per mm areolar skin = 9.67 (variance=8.84), mean number of melanocytes per mm breast skin = 6.80 (variance=9.22) $p < 0.0001$ (two-tailed) (Fig. 41).

There is a higher magnitude of difference between breast and areolar skin if melanocyte quantity is measured by number of melanocytes per length of skin surface. On paired t-testing: mean number of melanocytes per mm of areolar skin surface = 15.08 (variance=25.79), mean number of melanocytes per mm of breast skin surface = 8.51 (variance=18.36) $p < 0.0001$ (two-tailed) (Fig. 42).

The ratio of melanocytes to keratinocytes is significantly greater in areolar skin than in breast skin. On paired t-tests: mean ratio of melanocytes to keratinocytes in areolar skin is 1:9.72 (variance=12.93), mean ratio of melanocytes to keratinocytes in breast skin is 1:14.68 (variance=27.48) $p < 0.0001$ (two-tailed) (Fig. 43).

The amount of melanin per melanocyte is greater in areolar skin than breast skin but the magnitude of the difference is much smaller than other differences between the two types of skin and is less statistically significant. Mean amount of melanin per melanocyte in areolar skin = $400.79 \mu^2$ per melanocyte (variance=174974) mean amount of melanin per melanocyte in breast skin = $312.03 \mu^2$ per melanocytes (variance=217050) $p < 0.05$ (two-tailed) (Fig. 44).

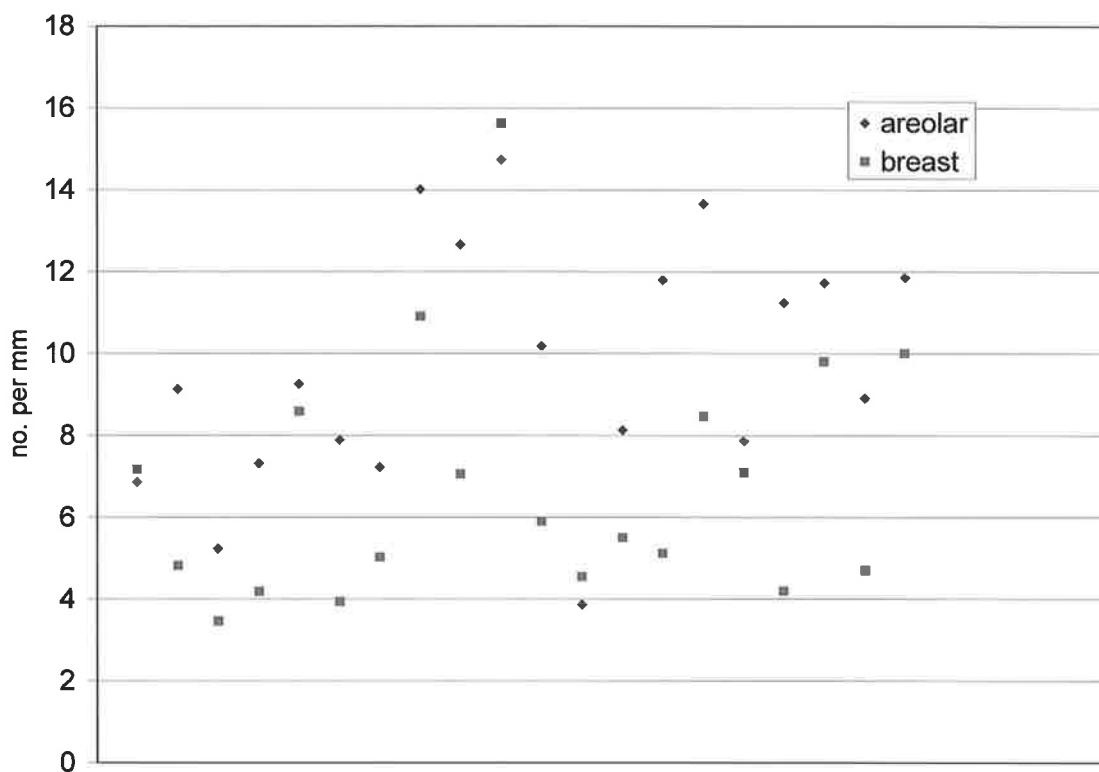


Fig 41 Number of melanocytes per mm of basement membrane

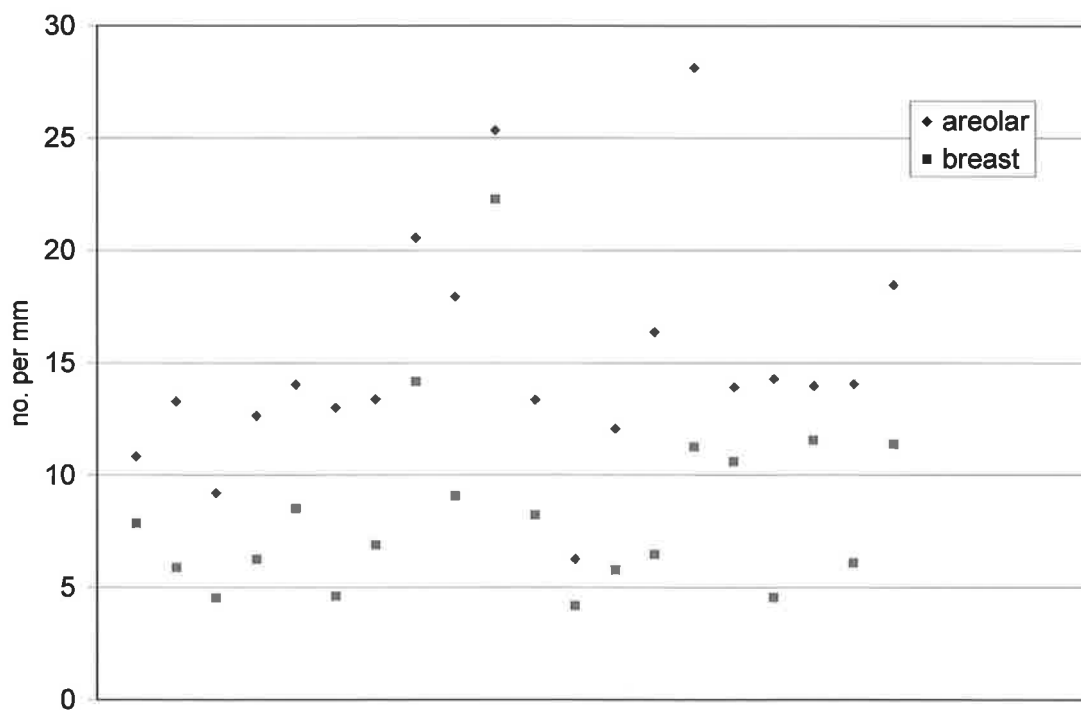


Fig 42 Number of melanocytes per mm of skin surface

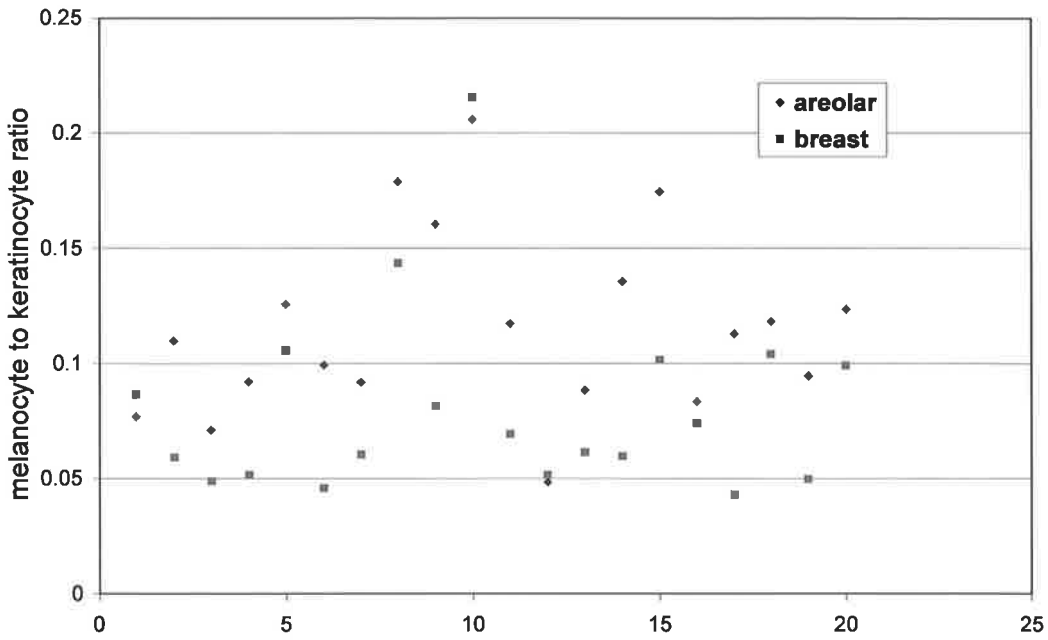


Fig. 43 Melanocyte to keratinocyte ratio in areolar and breast skin

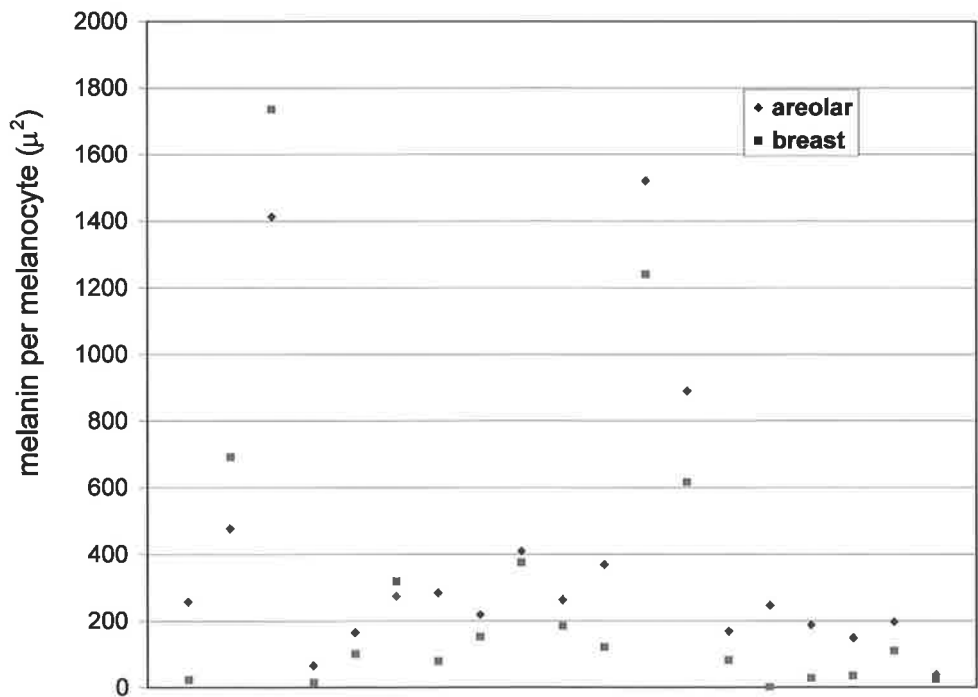


Fig. 44 Amount of melanin per melanocyte in areolar and breast skin

3.4 DISCUSSION

3.4.1 Introduction

Although the influence of oestrogens on the darkening of the nipple-areolar complex has been studied, (Davis et al. 1945; Montagna and Parakkal 1974) the nipple-areolar skin has a baseline pigmentation that is increased compared to the surrounding skin and the origin of this pigmentation has attracted little attention. The need for this information has become apparent only recently in conjunction with breast reconstruction becoming a relatively common sequel to mastectomy. Another reason that this research area may have been previously neglected is the very low rate of melanoma in this specialized skin (Papachristou et al. 1979). However, this perhaps *should* be a reason for studying this skin. Now that reconstruction of the nipple-areolar complex is increasingly commonplace and needs to be improved, it would seem logical to review the histological basis for the pigmentary characteristics of nipple-areolar skin.

3.4.2 Characteristics of areolar skin

In the current study the melanin content of areolar skin was found to be 2.5 times higher than that in breast skin, backing up the visual perception of increased colour. The finding that areolar skin has a basement membrane that is more convoluted than that of breast skin means that a greater amount of melanin is “seen” at the skin surface for a given density of melanin per length of basement membrane (Fig. 45).

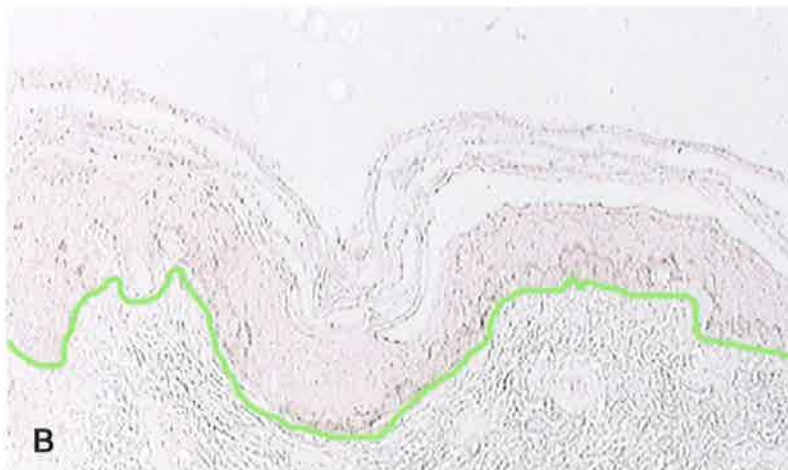
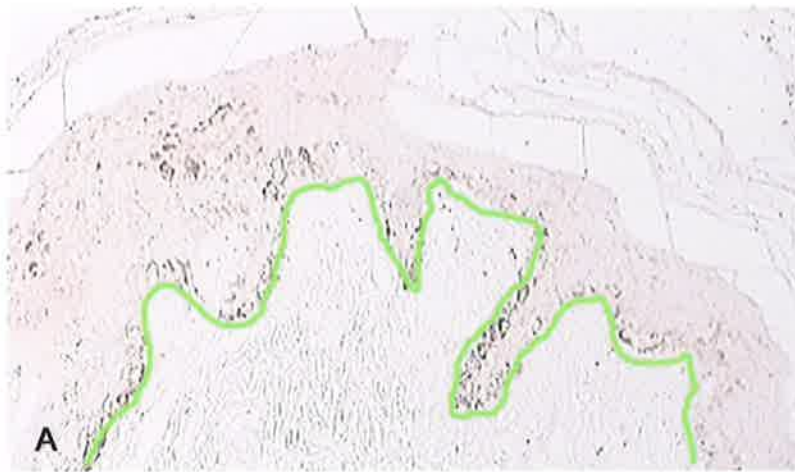

Fig. 45 Typical sections of **A** areolar and **B** breast skin stained with the Masson-Fontana technique showing the increased ratio of basement membrane (green) to skin surface length in areolar skin

The convoluted basement membrane of areolar skin is very similar to the pattern seen in the epidermal hyperplasia of some solar lentigines (Andersen et al. 1997) although Andersen and co-workers did find that epidermal hyperplasia was not a prerequisite for the diagnosis of solar lentigo.

The phenomenon of the rete ridges of the dermis affecting what is seen from the surface was first noted by Staricco and Pinkus with their split skin preparations of DOPA stained melanocytes (Staricco and Pinkus 1957) (Fig. 46). Although this factor plays only a small part in the difference between the amount of melanin presented to the skin surface in breast and areolar skin the finding is relevant in the context of developing *in vitro* skin constructs because the form of manufactured dermal equivalents could be designed to have a greater surface area on the side to which epidermal cells are to be applied.

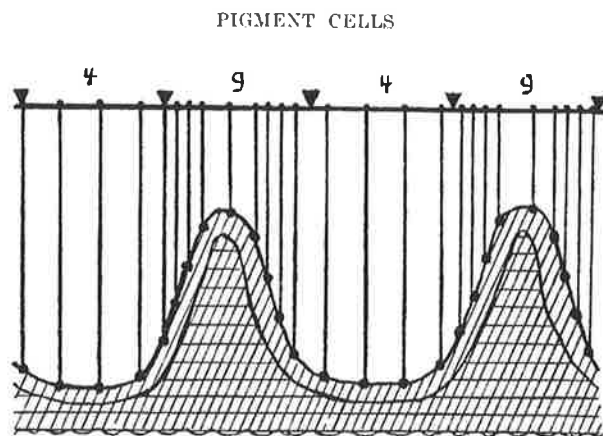


Fig. 46 Diagram illustrating how melanocytes, which are spaced evenly along the dermo-epidermal junction, appear crowded on the rete ridges for an observer looking at the epidermal sheet from the surface (from (Staricco and Pinkus 1957))

The current study found that areolar skin contains a higher number of melanocytes than breast skin and has a higher ratio of melanocytes to basal keratinocytes than breast skin: 1:9.7 in areolar skin compared with 1:14.7 in breast skin. “Normal” numbers of melanocytes or ratios of melanocytes to keratinocytes for different parts of the body have been studied by different authors in different ways. Absolute numbers of melanocytes per mm² of split skin were studied by Starrico and Pinkus who found that male genital skin had approximately twice the number of melanocytes compared to chest skin but did not examine nipple-areolar skin. Cochran found that on average one cell in ten in the basal layer of the epidermis was a melanocyte (Cochran 1970). In vertical sections of oral mucosa there is an average of 4.6 DOPA positive cells per mm of basement membrane (Barrett and Raja 1997). In vertical sections of facial skin and post-auricular skin immunostained with Mel-5 there have been found to be means of 10.86 and 5.51 melanocytes per mm respectively (Bhawan et al. 1995). This compares with 15.08 melanocytes per mm skin surface in areolar skin and 8.51 melanocytes per mm skin surface in breast skin in the current study.

The mechanism for the determination of baseline melanocyte to keratinocyte ratios in different parts of the body is, as yet, unknown and is an interesting issue. Regnier and co-workers have postulated that the architectural form of the dermis, or of the dermal substitute in artificial skin constructs, has a role in the regulation of melanocyte distribution and proliferation (Regnier et al. 1984; Regnier et al. 1998) and that this may be in addition to any cytochemical factors. The finding of different dermal morphology between breast skin and areolar skin supports this concept.

3.4.3 Immunohistochemical labelling of normal melanocytes

The study of immunohistochemical labelling of normal melanocytes was not a primary objective in this research but was important if valid results were to be obtained in the study of areolar skin. The technique of using haematoxylin and eosin (H&E) staining to identify 'clear cells' and counting these cells as melanocytes has been used up until the late 1990s (Grichnik et al. 1998) because of the absence of a more reliable technique for detecting all melanocytes present in any given specimen. However, Clark, in his study of normal skin in the early 1960s found the technique of negative imaging of melanocytes by H&E to be flawed because apoptotic basal keratinocytes were also unstained and easy to confuse with melanocytes (giving an overestimation of the number of melanocytes) (Clark 1961). The DOPA technique for staining melanocytes has likewise been shown to be inaccurate because it does not detect melanocytes which are not actively producing melanin (Mishima and Widlan 1967).

Bhawan and colleagues have shown that the mouse monoclonal antibody Mel-5 (clone TA99) is more sensitive for the detection of normal melanocytes than S100 (Bhawan 1997). Perrin's comprehensive study of melanocytes in the normal nail unit (Perrin et al. 1997) demonstrated no labelling with HMB 45 or S100 in paraffin sections. In frozen sections, melanocytes were labelled but different antibodies reacted with different intensities in different areas of the nail matrix. Perrin attributed this phenomenon to the fact that the proximal nail unit has melanocytes with pre-melanosome and stage 1 melanosomes (but few stage III or IV melanosomes) and the distal nail unit contains more of the mature (stage III and IV) melanosomes. Grichnik and co-authors (1998) reported that expression of antigens in normal human melanocytes is not static but varies depending on the metabolic state of the cell. In their study they observed an increase in expression of "Tyrosine-related protein 1" (PAA), as

detected by Mel-5, and the antigen for NKI / beteb, in the presence of cell factor (SCF) when compared with placebo.

The findings from testing conditions for Mel-5 labelling in the current study suggest that proteinase digestion alone as a pre-treatment gives optimal labelling results. This concurs with the experience of Bhawan and colleagues (Bhawan et al. 1991). In the current study temperature of incubation of the primary antibody altered the number of melanocytes detected twofold but these results must be treated with caution as this experiment was carried out on a small number of sections only. The author did not have access to an automatic immunohistochemical staining machine, as was used by Bhawan's group, and realises that this may cause minor variability in the results, in spite of making every effort to standardise staining protocols.

Sections labelled with NKI / beteb showed the greatest variation of staining between specimens under the same conditions. It may be that the variation of the NKI / beteb antigen in the specimens was related to the *in vivo* metabolic activity of the cells.

The antibody to c-kit was found to be sensitive for detecting normal melanocytes but not specific enough and in many cases stain was poorly localised, making it impossible to count the melanocytes.

Antibody to S100 stained a very small proportion of melanocytes. To ensure that all antibody labelled cells were being visualised by the chromogen system, staining was repeated with the alternative and possibly more sensitive chromogen VIP, but this did not increase the number of melanocytes stained. This validates previous findings that S100 is a poor marker for normal melanocytes (Bhawan 1997) and is similar to Perrin's experience of using S100 for detection of melanocytes in the normal nail matrix (Perrin et al. 1997).

The finding that the number of melanocytes identified by absence of labelling with CK34 β E12 correlated with the number labelled by Mel-5 suggests that Mel-5

stains all the melanocytes present when used in the conditions outlined above in paraffin sections.

The staining of epithelial cell cultures and cultured skin substitutes is a field that is developing in parallel with the development of the cell culture techniques. The DOPA reaction has been used to evaluate numbers of melanocytes in mixed keratinocyte and melanocyte co-cultures and to label melanocytes in grafted cultured epithelium (De Luca et al. 1992; Franzi et al. 1992) and in pigmented skin equivalents (Bessou et al. 1997). However, as previously discussed, the DOPA reaction has been shown to underestimate melanocyte numbers (Mishima and Widlam 1967). The Mel-5 antibody has been used successfully to label melanocytes in frozen sections of cultured pigmented skin equivalents (Nakazawa et al. 1997; Nakazawa et al. 1998).

Although there was little interest in the study of normal skin in the 1980s and 1990s, there is likely to be a revival in this field of study. This is because, for pigmented skin equivalents to develop successfully, it is important to know the cytological make-up of normal skin in a quantitative way, measured by modern immunohistochemical techniques. The pigmented skin equivalents themselves also need to be scrutinized closely and it is therefore important to know the likely immunoreactivity of these 'normal' cells. The current study contributes at least one small piece of this jigsaw by showing that the number of melanocytes identified by absence of staining with CK34 β E12 correlated with the number stained by Mel-5 hence establishing that Mel-5 stains all the melanocytes present when used in the conditions outlined above.

3.4.4 Limitations and usefulness of the current study of areolar skin

One limitation of this study is that the twenty patients from whom specimens were taken, may not be representative of a wide population because most were Caucasians of Fitzpatrick skin types II and III. In addition, although several measures were taken to ensure that staining procedures were specific and sensitive, there is, even with the aid of computer software, some subjective element to the analysis of histological images, which could have produced bias in the results. In retrospect, it would also have been useful to have a sample of sun exposed skin (eg from the arm or face) from each patient, to compare with the breast and areolar skin, although this may have reduced the number of patients willing to participate in the study. It would also have been useful to have a second “blinded” researcher to analyse the images.

This quantitative study of melanin and melanocytes in normal areolar skin may be useful in two ways. Firstly, re-creation of pigmented nipple-areolar skin in breast reconstruction patients could theoretically be achieved using autologous cultured keratinocytes and melanocytes to form a suitable pigmented skin substitute *in vitro* which could then be transferred to the patient. The data presented in this study provide some baseline knowledge on melanocyte numbers and melanocyte to keratinocyte ratios in areolar skin which could be used for the development of such a specialised skin equivalent.

The study of nipple-areolar skin is also of interest because of the fact that it is a specially pigmented area of skin, regardless of its topographical position, and this gives an insight into the factors determining skin pigmentation. The finding that increased skin pigmentation is correlated with an altered dermal morphology may have implications for the design of manufactured dermal substitutes or for the preferences

given to different types of freeze thawed cadaveric or animal dermis in different experimental and clinical settings.

CHAPTER 4

THE POTENTIAL FOR TISSUE ENGINEERED NIPPLE- AREOLAR SKIN IN BREAST RECONSTRUCTION PATIENTS

4.1.1 INTRODUCTION

This is a preliminary study looking at the feasibility of cell culture playing a role in the clinical scenario of nipple-areolar reconstruction and should not be considered a definitive or quantitative cell biology study. The first part of the study was to establish basic methods of yielding epidermal cells and cell culture. The second part of the study focussed on development of a culture medium that would be theoretically safe in a clinical setting. The third part of the study investigated the feasibility of production of skin constructs using cells and dermis from adult surgical discard material and assessment of the colour of these constructs.

4.1.2 AIMS AND OBJECTIVES

Aim:

To investigate the feasibility of producing reconstructed skin *in vitro* with the same pigimentary characteristics as nipple-areolar skin, using non-specific adult surgical discard skin and using a cell culture environment that would be safe in a clinical context.

Objectives:

Establishing epidermal cell culture

- To establish a successful method for harvesting skin from waste tissue in breast reduction and abdominoplasty patients.
- To establish a successful method for yielding basal keratinocytes and melanocytes for *in vitro* culture from adult surgical discard skin.
- To establish that keratinocytes and melanocytes can be cultured from adult surgical discard skin in standard culture media.
- To establish a method for separating mixed cultures of melanocytes and keratinocytes to provide separate cell cultures of each cell type.

Investigating a culture medium safe for use in the clinical setting

- To compare cell culture media containing autologous human serum with other media for melanocyte growth.
- To compare media free of the potentially harmful substances PMA and cholera toxin with media containing PMA and cholera toxin which are frequently used for melanocyte growth.

Production of skin constructs

- To establish a method of production of a skin construct from cultured cells and preserved dermis.
- To establish a method for assessment of skin constructs.

4.2 MATERIALS AND METHODS

4.2.1 Establishing epidermal cell culture

4.2.1.1 Skin harvest and collection

Patients undergoing elective surgery for abdominoplasty or breast reduction were approached about donating skin that is normally discarded, for epidermal cell culture. Potential donors had the research explained to them by the author and were given a written information sheet which outlined the nature of the research (Appendix IV). Patients gave written consent for skin donation on the standard consent form approved by the local Research Ethics Committee (Appendix XVI). Later in the course of the study, patients donating skin were also asked to donate serum for use in cell culture. The Research Ethics Committee approved this change and information sheets and consent forms were changed appropriately (Appendix V). The patient was asked to complete a questionnaire which covered; how sensitive their skin was to sun exposure (Fitzpatrick classification), possible hormonal influences on areolar skin colour (oral contraceptive pill, parity and breast feeding) and direct sun-exposure of the areolae (Appendix XIV). Patients then underwent photography with a colour standard included in the photograph (as described in 2.2.3).

Skin specimens were either full thickness specimens of redundant skin, or were split thickness specimens harvested with a Watson-Braithwaite skin grafting knife (Down's Brand, B.Braun, Australia) or air-driven dermatome (Zimmer, Australia) with disposable blade (Zimmer, Australia). Split skin samples were approximately double the thickness that would be taken for a split skin graft (16/1000 inch). Skin samples

were taken once the discard tissue had been removed from the patient or in some cases when it was still attached to the patient.

After harvesting, skin was placed in a sterile specimen container (70ml, Disposable products, Australia) containing 20mls of Hanks and Hepes Solution (Hanks and Chakrabarti 1975) with gentamicin (Cat. no. G1272, Sigma Chemical Co., St. Louis Missouri, USA). Hank's solution was made by adding 8g of sodium chloride, 0.4g of potassium chloride, 1g of glucose 0.35g of sodium hydrogen carbonate, 60mg of potassium hydrogen phosphate and 47.5mg of sodium hydrogen phosphate to 900mls of milliQ water (MilliQ-Plus/PF Water Purifier) and then making the solution up to one litre, adding 2.383g of Hepes powder (Cat. no. 0511, Amfesco, Ohio, USA) per litre of Hanks solution, adjusting to pH 7.3, and adding 5µg of gentamicin per ml of solution.

Specimen containers were transferred to the laboratory in a polystyrene container containing ice chips and placed in a laboratory refrigerator maintained at 4°C.

4.2.1.2 Preparation of basal epidermal cells for *in vitro* culture from adult surgical discard skin

The methods used for deriving epidermal cells for culture were modifications of those previously described (Eisinger and Marko 1982; Nielsen and Don 1984; McLeod and Mason 1995). Rationale for and evolution of techniques are further elaborated in the Discussion section (4.3.1.1). Within the laboratory, all skin specimens and cell cultures were handled in a Class II biological safety cabinet (BH 2000 series, Clyde-Apac, Environmental Products Div.) with suction facilities. Gown, disposable surgical gloves and eye protection were worn and all surfaces were sprayed with 70% ethanol before and after procedures. Lines were flushed with 1.25% bleach after use and discarded cell cultures were treated with bleach before disposal. Media and solutions

made in the laboratory were filter sterilised using a 0.2µm filter (cat no. 18052, Sartorius, Gottingen, Germany). All instruments were sterilised in an autoclave (5673, R.L. Smith and Co.) prior to use. A water-jacketed, humidified incubator (3250, Forma-Scientific, Ohio, USA) maintained at 37°C under an atmosphere of 5% CO₂ was used for cell culture. A water bath (Gallenkamp, England) maintained at 37°C was used for warming solutions and media and a phase contrast microscope (Olympus, CK2) was used for examining cell cultures.

Method 1 Trypsin overnight / whole epidermis cultured

The initial method of yielding basal cells was to cut the skin into 1cm² pieces in a sterile 100mm diameter petri dish (353003, Falcon, Becton Dickinson Labware, Franklin Lakes, NJ, USA) using number 5 jeweller's forceps and a size 21 scalpel blade (Swann-Morton, U.K.). The skin was then rinsed in 10 ml gentamicin (20µg per ml) solution in sterile phosphate buffered saline (PBS) for 3 minutes followed by rinsing in 10ml of PBS for 3 mins. Pieces of skin were then placed in a 100mm petri dish containing 10ml 0.25% trypsin (CSL Limited, Melbourne, Australia) and the petri dish placed in the refrigerator at 4°C overnight.

Using loupe (x3) magnification (optical telescopes, Design for Vision, USA) and the number 5 jeweller's forceps, the superficial epidermis was separated from the specimen. Two techniques were then used to yield basal cells:

Method 1a:

The superficial epidermal sheets were minced with scissors then further incubated with 0.025% trypsin and 0.5mM EDTA. Incubations with 1.275% trypsin and 5.5mM EDTA and with 2mg/ml of collagenase from *Clostridium histolyticum* (Cat. no. 17449, Serva, Heidelberg, Germany) were also performed to dissociate the cells of

the superficial epidermis. Each of the incubations were for 30 minutes at 37°C with vigorous pipetting of the sample with a glass 5ml graduated pipette (TPP) and pipetboy (ACU, Integra Biosciences) every 10 minutes.

Method 1b:

The basal layer was scraped from the dermis using a size 21 scalpel blade and the cells rinsed from each pass of the blade into 5 mls of keratinocyte medium in a 15ml centrifuge tube (TPP, Europe / Switzerland) .

In both the basal cell suspension and the superficial epidermal samples, soya bean trypsin inhibitor (product no. T6522, Sigma, USA) was filter sterilised (Minisart, 16534, Sartorius, Gottingen, Germany) and added at a final concentration of 10mg/ml and the samples centrifuged at 1000rpm for 5 minutes (Centaur 2 MSE centrifuge, Sanyo, Japan). Supernatant was removed using a 2ml disposable transfer pipette (Cat. no. 20215, Samco, San Fernando, CA, USA) and the cells resuspended in PBS. The cell suspension was then centrifuged again for a further 5 minutes at 1000rpm, the supernatant removed and the cells resuspended in 1ml of serum-free defined keratinocyte medium (Defined Keratinocyte-SFM, Cat. no. 10744, GibcoBRL, Life Technologies, USA). The 1ml of cell suspension was then added to 20mls of either Defined Keratinocyte-SFM or serum-free melanocyte growth medium (MGM-2 BulletKit cc-3143, Clonetics, USA) in vented T75 (Cat. no. 9075, TPP, Europe / Switzerland) or T25 (658170, CellStar, Greiner, Labortechnik, Germany) tissue culture flask (see next section for further details on culture media).

Method 2 Dispass overnight / whole epidermis cultured

The second method used for yielding basal cells was to cut skin into 2mm pieces in a sterile 100mm petri dish using no. 5 jeweller's forceps and a size 21 scalpel blade.

The skin was rinsed in 70% ethanol for 3 minutes followed by rinsing in 10mls of gentamicin (20µg/ml) solution in sterile phosphate buffered saline (PBS) for 3 minutes. The skin was then rinsed for a further 3 minutes in PBS and transferred to a 60mm diameter petri dish containing 5ml of dispase (a metalloproteinase from *Bacillus polymyxa*, Cat. no. 354235, Becton Dickinson Labware, Bedford, MA, USA) (25 units of activity per ml) and were incubated overnight at 4°C. Using loupe (x3) magnification and the number 5 jeweller's forceps, the epidermis was removed from the dermis. The epidermal sheets were then incubated with 2ml of 0.1% trypsin and 1mM EDTA at 37°C in an incubator. The sample was pipetted vigorously with a 2ml disposable pipette after 7, 14, 19 and 24 minutes. The cell suspension plus any remaining macroscopic epidermal sheet fragments were transferred to a 15 ml centrifuge tube with the 2ml transfer pipette. Two mls of soya bean trypsin inhibitor (10mg per ml) were added and the suspension centrifuged at 2000rpm for 10 minutes. The supernatant was removed and the cells resuspended in 1ml of keratinocyte medium. A hemocytometer (Neubauer Improved Bright Line, La Fontaine) count was performed using Trypan blue (T8154, Sigma) to identify non-viable cells and the cell suspension added to 11mls of fresh medium containing PSF and gentamicin (5µg per ml) in a T75 vented tissue culture flask. Cell suspensions derived from this method were seeded into several culture media, as described below, with a volume of 11mls being used for each flask. This method was a modification of the method used at the Mason laboratory at the University of Sydney, New South Wales (McLeod and Mason 1995) and kindly demonstrated to the author by Dr Ritu Gupta.

Method 3 Trypsin overnight / basal epidermal cells only cultured

The third method used for yielding basal cells was to cut the skin into 5mm pieces, rinse it in 70% ethanol for 3 minutes, then in 10 mls of gentamicin (20µg per ml) solution in phosphate buffered saline (PBS) for 3 minutes then in 10mls of PBS for a further 3 minutes. Skin was then incubated overnight with 0.25% trypsin at 4°C followed by removal of the superficial epithelial sheet using loupe (x3) magnification and the number 5 jeweller's forceps and scraping of the basal layer from the dermis using a scalpel blade. With each pass of the blade the cells were rinsed into 5mls of medium in a 15 ml centrifuge tube. Sterile soya bean trypsin inhibitor (10mg/ml) was then added and the cell suspension centrifuged at 2000rpm for 10 minutes. After discarding the supernatant, cells were resuspended in 1ml of medium then seeded into a T75 tissue culture flask. Cell suspensions derived from this method were seeded into several culture media, as described below, with a volume of 11mls being used for each flask.

4.2.1.3 Growth of epidermal cells in standard culture media

Cell culture was in T25 or T75 tissue culture flasks in a water jacketed, humidified incubator maintained at 37°C with an atmosphere of 5% carbon dioxide (CO₂). Medium was kept refrigerated at 4°C and warmed in a water bath to 37°C before use. Medium was exchanged every two to three days, using suction and glass Pasteur pipettes (Cat. no. 54, Chase instruments, NY, USA) to aspirate expired medium and 10ml graduated pipettes (TPP) to introduce new medium.

Culture of adult epithelial cells was initially attempted in serum-free defined keratinocyte medium (Defined Keratinocyte-SFM, Cat. no. 10744, GibcoBRL, Life

Technologies, USA) and serum-free melanocyte medium (MGM-2 BulletKit cc-3143, Clonetics, USA). Defined Keratinocyte-SFM is based on MCDB-153 medium (Boyce and Ham 1983) plus the defined growth promoting agents fibroblast growth factor (FGF), insulin and epidermal growth factor (EGF). It contains no bovine pituitary extract. The MGM-2 BulletKit consists of Melanocyte Basal Medium (Clonetics) plus bovine pituitary extract (BPE), human recombinant FGF, phorbol myristate acetate (PMA), insulin, hydrocortisone, gentamicin and amphotericin-B.

Adult basal epidermal cells were cultured in Defined Keratinocyte-SFM (GibcoBRL/ Life Technologies) to which 5% fetal bovine serum (FBS), (CSL, Melbourne, Australia) had been added and MGM-2 (Clonetics) to which 5% FBS had been added.

Subsequent culture of melanocytes was performed with the melanocyte medium used at the Mason laboratory, University of Sydney (henceforth referred to as US-MGM,). The base for this medium was prepared by taking 900mls of MilliQ (Millipore Corporation, Bedford, MA, USA) water and adding 2g of NaHCO₃, 9.62g of modified Eagle's medium (MEM) with Earles salts (JRH Biosciences, Lenoxa, KS, USA), 0.03g/l penicillin and 0.05g/l streptomycin, adjusting to pH of 7.1 and filter sterilising (0.2µm filter, Sartorius). Each pre-warmed 500ml bottle of basal medium was supplemented with 25mls of FBS (final concentration of 5%), 500µl of 10µM cholera toxin (final concentration of 10nM) and 500µl of PMA (final concentration of 20nM). The author also added 20µg/ml of gentamicin to the medium.

4.2.1.4 Separation of melanocytes and keratinocytes in culture

Melanocytes grown in MGM-2 (Clonetics) plus 5% FBS were harvested once they reached confluence in the T75 flask. Culture flasks were washed with chilled

HEPES saline to remove loosely attached cells. Warm HEPES saline containing 0.05% trypsin with 0.53mM was then added to the flasks and the cells observed for 1-2.5 minutes. This caused rounding of melanocytes. The flask was gently tipped and rotated to collect solution containing melanocytes. This suspension was then transferred into a centrifuge tube and HEPES buffered saline and soybean trypsin inhibitor added. The suspension was then spun at room temperature for 10 minutes at 2000rpm and the cell pellet resuspended in melanocyte medium.

Co-cultures of adult human melanocytes and keratinocytes were differentially harvested, with the melanocytes being harvested as described above, then the keratinocytes being detached by adding a further 10ml 0.05% trypsin with 0.53mM EDTA to the flask and warming to 37°C. Soya bean trypsin inhibitor was added once 90% of the keratinocytes have detached (usually after approx 15 mins). For both cell types cell suspensions were centrifuged for 10 minutes at 2000rpm at room temperature. The methods used for detaching cultured melanocytes and keratinocytes were modifications of those described by Pittelkow and Shipley (1989).

4.2.1.5 Immunostaining of *in vitro* cultured melanocytes

To establish that the dendritic cells grown in culture were melanocytes, melanocyte cultures from one flask underwent immunohistochemical staining with Mel-5 (clone TA99) (Signet Laboratories, Dedham, MA). Cells were fixed in 10% formalin. The T75 culture flask was bisected (Smoller et al. 1991) using a hacksaw and cutting shears. The base of the flask was then cut into small pieces, which were then rinsed in PBS. Pieces of plastic which had cells on and that were approximately 1cm in diameter were chosen for staining. After three washes with PBS (each 3 minutes) the pieces were immersed in Dimethylsulfoxide (DMSO) 5% or 70% alcohol for 5 minutes

followed by another three rinses in PBS. The pieces of flask were then incubated with Mel-5 diluted to 1:20 in normal serum overnight at room temperature. Cells were then blocked for endogenous peroxidases using 3% hydrogen peroxide (3 minutes) and after further rinsing with PBS the biotinylated secondary antibody was applied for 20 minutes (streptavidin-biotin detection kit, Signet Ultra Streptavidin Detection System; Signet Laboratories, Dedham, MA). After further washing with PBS the labelling reagent was added for 20 minutes (streptavidin-biotin detection kit, Signet), followed by further rinsing with PBS and application of the chromagen 3-amino-9-ethyl carbazole (AEC) (Zymed Laboratories, San Francisco, CA). Pieces of flask with cells on were then mounted on glass microscope slides with water soluble mountant (Faramount aqueous mounting medium, DAKO).

4.2.2 Investigating a culture medium safe for use in the clinical setting

4.2.2.1 Comparison of cell culture media containing autologous human serum with other media for melanocyte growth.

Ten to 12mls of blood was taken from patients pre-operatively and the blood sample placed on ice in the same container as the skin sample. In the laboratory, the blood was centrifuged at 2000rpm for 10 minutes. The serum was then transferred into a sterile 15ml centrifuge tube using a sterile 2ml transfer pipette, labelled with the initials of the patient, and refrigerated at 4°C. The following day, after either trypsinization or dispase separation of the skin sample, the autologous human serum was added to warmed medium to give 100mls of medium of the required concentration.

Experiment COM1 - Comparison of human serum-containing medium with other media for epidermal cell culture

In the first experiment comparing human serum-containing medium with other media (experiment COM1), four T75 culture flasks were prepared. These flasks contained: (1) 11mls of US-MGM standard medium containing 5%FBS, (2) 11mls of US-MGM without serum, (3) 11mls of US-MGM with no FBS and containing 5% autologous human serum (AHS) and 11mls of Defined Keratinocyte-SFM (GibcoBRL) with 5% FBS. Skin was harvested while tissue was still attached to the patient and using a Watson-Braithwaite skin grafting knife. Full-thickness skin was also taken from the same patient. Skin cells were prepared from the skin sample using Method 3 described above (section 4.2.1.2.) Media were changed every 2-3 days, at which time, the number of cells in 5 random x10 fields were counted.

Experiment COM2 - Comparison of human serum-containing medium with other media for melanocyte culture

In the second experiment comparing human serum containing medium with other media (experiment COM2) for melanocyte growth, four T75 flasks were prepared containing: (1) 11mls of US-MGM without serum, (2) 11mls of Defined Keratinocyte-SFM (GibcoBRL) containing 0.5% AHS, (3) 11mls of US-MGM with no FBS and (4) 0.5% AHS and 11mls of US-MGM 5% FBS. The author intended that the percentage AHS in the media would be 5%, so as to make it comparable with the medium containing 5% FBS, but produced media containing 0.5% AHS due to an error in calculation which was rectified the following day. 0.5% AHS was used in the first 24 hours; 5% AHS was used from day 2 to day 4. From day 4 post-seeding a concentration

of 1% AHS was used due to limitation of the amount of autologous human serum available. The skin from which these cells were derived was harvested while the tissue was still attached to the patient and using a Watson-Braithwaite skin grafting knife. Skin cells were yielded from the skin sample using Method 3 described above (section 4.2.1.2). Media were exchanged every 2-3 days, at which time the number of cells in 5 random x10 fields were counted.

4.2.2.2 Comparison of media with and without PMA and cholera toxin for melanocyte growth

Experiment COM3 - Comparison of media with and without PMA and cholera toxin for melanocyte growth

In the experiment designed to compare media with and without cholera toxin and PMA, passaged melanocytes were used that had been selectively grown in MGM-2 (Clonetics) plus 5% FBS for a period of 9 days. Three T75 culture flasks were prepared containing: (1) 11mls of US-MGM containing 1% instead of 5% FBS, (2) 11mls of US-MGM containing 1%AHS and no FBS and (3) 11mls of US-MGM without cholera toxin, PMA and FBS and containing 1% AHS. Skin was harvested while tissue was still attached to the patient and using a Watson-Braithwaite skin grafting knife. Skin cells were yielded from the skin sample using Method 3 described above (section 4.2.1.2). A haemocytometer count was performed to ensure that equal numbers of melanocytes were seeded into each of the flasks at the start of the experiment. Media were exchanged every 2-3 days. Number of cells in 5 random x10 fields were counted four times during cell culture and a haemocytometer count was repeated when the cells were harvested.

4.2.3 Production of skin constructs

4.2.3.1 Production of a skin construct from cultured cells and preserved dermis.

Dermis was derived from the same full thickness or split thickness skin specimens as the epidermal cells. Samples were collected from overnight treatment of skin with trypsin or dispase. Dermis from trypsin / dispase treated skin specimens was washed in gentamicin (20 μ /ml) for 3 minutes and in PBS for 3 minutes. It was then placed in empty 100mm diameter petri dishes and frozen at -80°C (Revco, model no. ULT 1786-5-W30, GS Laboratory Equipment, Asheville, NC, USA). When sufficient keratinocytes and melanocytes had been grown in flasks, the dermis was thawed at room temperature and rinsed again in gentamicin and PBS (3 minutes in each solution). Pieces of dermis were then cut to fit into 6 well plates containing membrane inserts (Transwells®, Corning Costar, Cambridge, MA). These were used so that once established, the skin constructs could be maintained at an air-liquid interface (Fig. 47). Basal medium was then added in the Transwell plates and they were then incubated at 37°C to allow the dermis to become permeated with warm medium.

The recommended total seeding density of cells for Transwells was 4x10³ cells per cm² (manufacturer) The area of each membrane was 4.7cm², which meant that the total number of cells for initial seeding per well should be 1.88x10⁴ (rounded up to 2x10⁴). The proportion of melanocytes and keratinocytes making up the total number of cells was planned so that there were different ratios of melanocytes to keratinocytes. The ratios used are shown in figure 47.

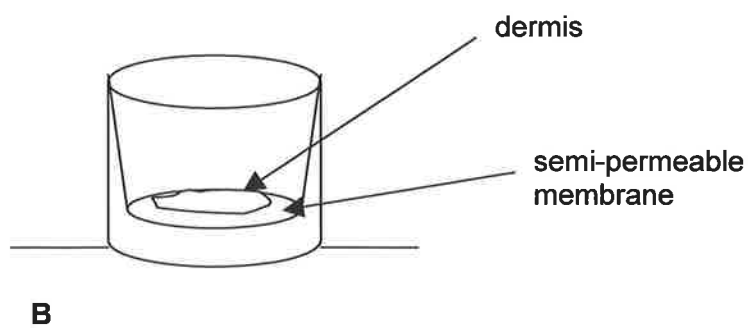
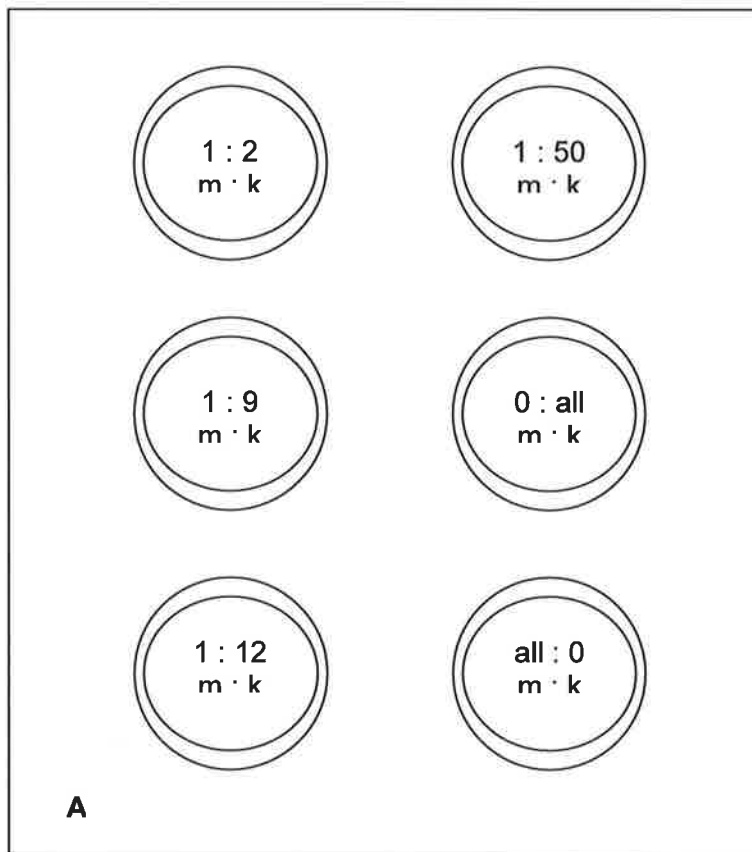


Fig 47 A Ratios of melanocytes (m) to keratinocytes (k) in the six wells of the Transwell culture plate **B** Side view of a Transwell

Experiment SC1 - Production of a skin construct with differing ratios of melanocytes to keratinocytes

Cultures of melanocytes only (grown in 1% AHS in experiment COM3) and keratinocytes only (grown in Defined Keratinocyte SFM (GibcoBRL) plus FBS) were harvested from their respective flasks. Haemocytometer cell counts were performed to establish density of cells in the resultant cell suspensions. From the density of the cells in each of the two suspensions, it was calculated which cell suspension volumes gave the correct ratio of melanocytes to keratinocytes and the correct total cell seeding number. For each Transwell the appropriate volumes of melanocyte suspension and keratinocyte suspension were added onto the dermis and the volume was then topped up to a total of 1.5mls with medium. The medium used for this experiment was US-MGM with 1% AHS and no cholera toxin or PMA. The dermis and cells were maintained submerged in medium for the first three days and from then on were kept at the air-liquid interface.

Experiment 2 and 3 (SC2 and SC3) - Production of skin constructs in an environment free of FBS, cholera toxin and PMA

The cells used for the skin construct experiments 2 and 3 were from co-cultures of keratinocytes and melanocytes established in Defined Keratinocyte SFM with 1% AHS added and had no contact with FBS, cholera toxin or PMA. Ratios of melanocytes to keratinocytes were the same as for skin construct experiment 1 (SC1). In experiment 3 a “home made” device was used instead of a Transwell. This consisted of a six-well culture plate and a sterile plastic perforated sheet to keep the dermis at the air-liquid interface.

4.2.3.2 Assessment of skin constructs

Epidermal cells were inspected every two to three days for morphological characteristics (dendricity of melanocytes, differentiation of keratinocytes, levels of confluence etc.) and for any sign of contamination, using phase contrast microscopy (Olympus CK2).

Images of the skin constructs were recorded using a digital camera (Kodak, DC120, Eastman Kodak Co., CT, USA) and including a colour standard (see Chapter 2) in each image. This allowed for standardization of the colours of the images and comparison of the skin constructs with each other and over a period of time (Fig. 48).

Skin constructs were fixed in 10% formalin overnight, then processed for paraffin-embedding in a histological processing machine (Duplex Processor, Shandon), embedded (Tissue-Tek II, Ames, Australia) 6µm sections were cut with a microtome (Reichert-Jung, Germany) and floated onto positively charged or silane-coated slides. Sections then underwent the immunohistochemical staining protocol for Mel-5 used for the skin sections (See Chapter 4)(Appendix XVII) except that sections were exposed to proteinase K for 5 minutes rather than 15 minutes.

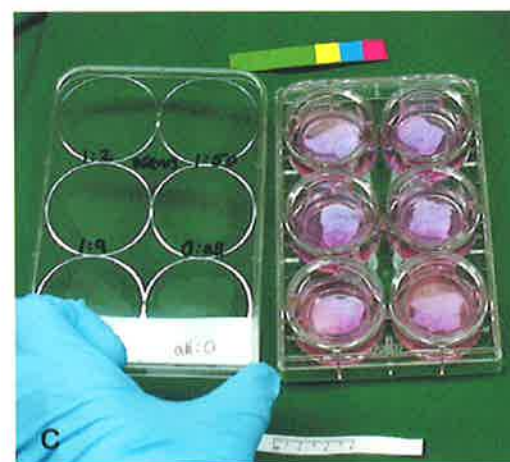
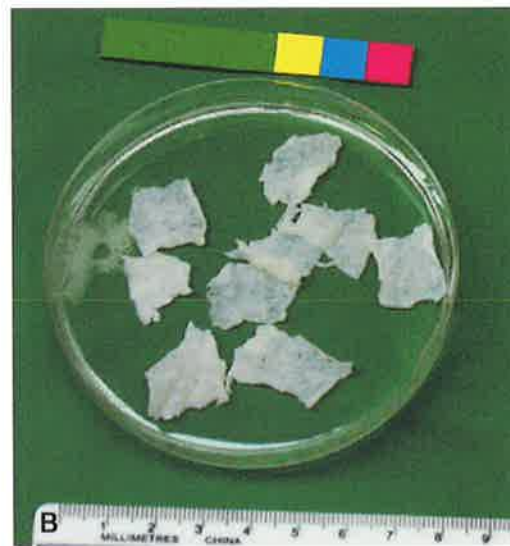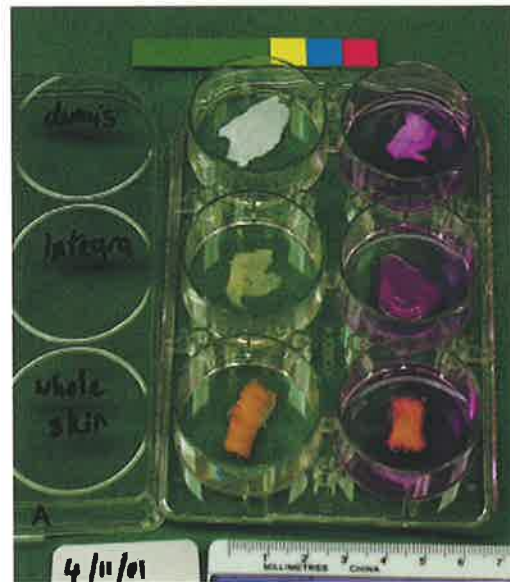


Fig. 48 Imaging of skin constructs **A** photographic standards with whole skin, dermis and integra in, **B** Dermis prior to seeding with cells **C** skin constructs with colour standard

4.3 RESULTS

4.3.1 Establishing epidermal cell culture

4.3.1.1 Deriving basal epidermal cells from adult surgical discard skin

Eleven patients donated skin for cell culture and no patients approached to donate skin refused to do so. There were insufficient patient numbers to correlate Fitzpatrick classification or oral contraceptive pill use and melanocyte density yielded from skin samples. All patients donating skin were Caucasian and none had had recent sun-exposure of the skin that was donated. One neonatal foreskin sample was used for melanocyte culture and underwent Method 2.

Split thickness skin harvested with a Watson-Braithwaite skin grafting knife or with a dermatome was found to separate better than full thickness skin in the cases where 0.25% trypsin was used. However, dispase treatment of the same skin overnight gave total separation of epidermis and dermis. Full thickness samples treated with dispase were therefore useful for yielding specimens of dermis for later use in skin constructs.

Overnight digestion of skin with 0.25% trypsin at 4°C followed by discard of the superficial epidermis and scraping of the basal layer from the dermis (Method 3) gave better cell yields than the dispase separation and dissociation of the epidermis (Method 2) (See Table 10). In the skin samples used in the current study the author found dissociation of epithelial sheets into single cells was difficult to achieve, even with vigorous pipetting, warming with trypsin and use of collagenase. This is in contrast with other authors (Gilchrest et al. 1984; McLeod and Mason 1995). It may be adult epithelial cells dissociate less easily than neonatal cells. Whatever the cause of poor

dissociation, I found a method which did not rely on break up of the epithelial sheets to be better in terms of cell yield.

Table 10 Skin samples used for cell culture and method of yielding epidermal cells

<i>Skin sample</i>	<i>Full thickness (FT) or Split thickness (ST)</i>	<i>Agent used for separation of skin layers</i>	<i>Method used for yielding basal epidermal cells</i>	<i>Yield of basal epidermal cells (Good / Moderate / Poor)</i>
1	ST	trypsin	Method 1a	poor
2	ST	trypsin	Method 1a Method 1b	moderate good
3	FT	trypsin	Method 1	poor
4	FT	trypsin dispase	Method 1 Method 2	poor poor / moderate
5	ST	dispase	Method 2	poor / moderate
6	ST	dispase	Method 2	poor / moderate
7	ST	dispase trypsin	Method 2 Method 3	moderate good
8	ST	dispase trypsin	Method 2 Method 3	moderate good
9	ST	dispase trypsin	Method 2 Method 3	moderate good
10	ST and FT	trypsin	Method 3	good
11	ST	trypsin	Method 3	good

4.3.1.2 *In vitro* culture of melanocytes and keratinocytes from adult surgical discard skin in standard culture media

It was possible to culture keratinocytes in serum-free medium (Fig. 49) but growth of cultures was very slow - it took approximately 6 weeks to achieve 40% confluence and in some cases no keratinocytes grew.

Culture of adult melanocytes in serum-free medium was unsuccessful. Occasional melanocytes were seen in the first few days of culture but they did not multiply and after a few weeks were no longer visible. In the one flask of neonatal epidermal cells seeded, three small colonies of melanocytes became established (Fig. 50) in the first week of culture in serum-free melanocyte medium but did not continue to proliferate.

Growth of keratinocytes in medium containing fetal bovine serum was more rapid (reaching near confluence at two weeks) than in serum-free medium. Keratinocytes could be sustained as a co-culture with melanocytes (Fig. 51) in US-MGM containing FBS, MGM-2 (Clonetics) with added FBS or in Defined Keratinocyte SFM with added FBS.

In vitro culture of adult melanocytes was achieved in medium containing FBS (Fig. 52). In the first experiment where 5% FBS was added to MGM-2 (Clonetics), confluence of a pure culture of melanocytes in a T75 flask was reached after 4 weeks of culture, and after passaging 1:2, melanocytes were again confluent after 7 days (Fig. 53).

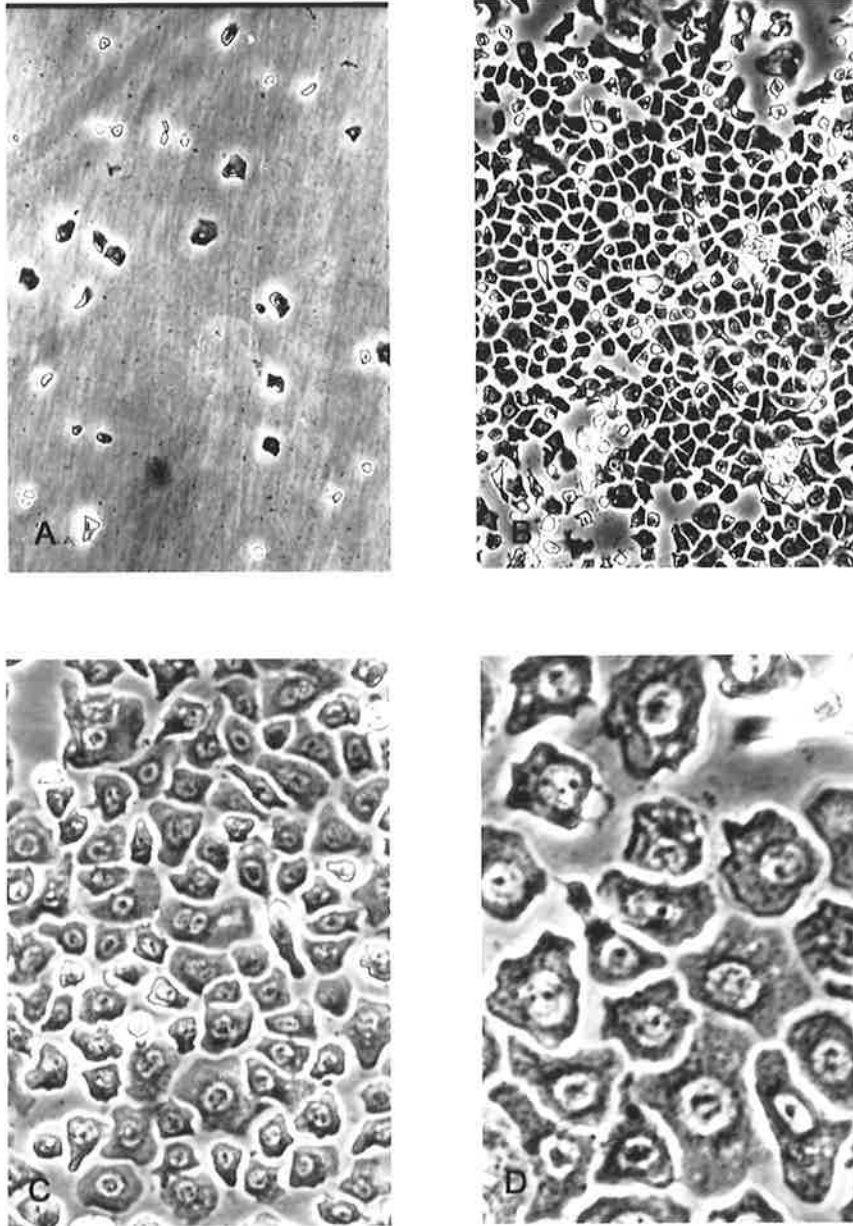


Fig. 49 Keratinocytes grown in serum-free medium **A** sparse growth (x10 magnification) **B** confluent cells (x10) **C** confluent cells (x20) **D** confluent cells (x40)

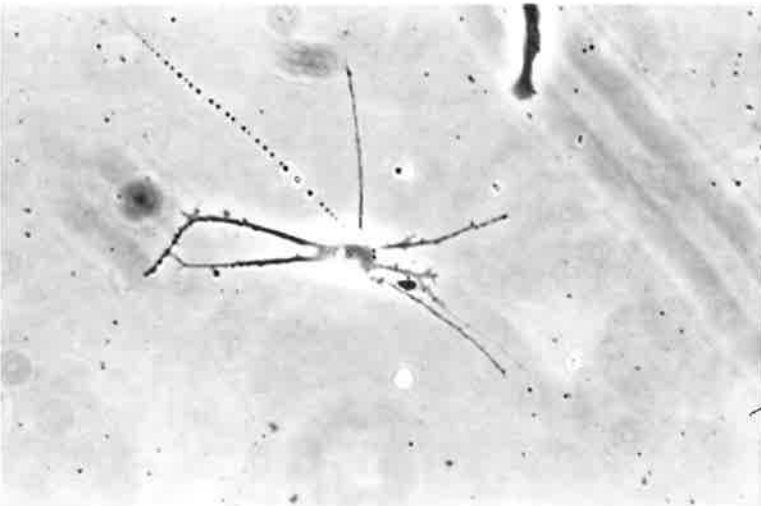
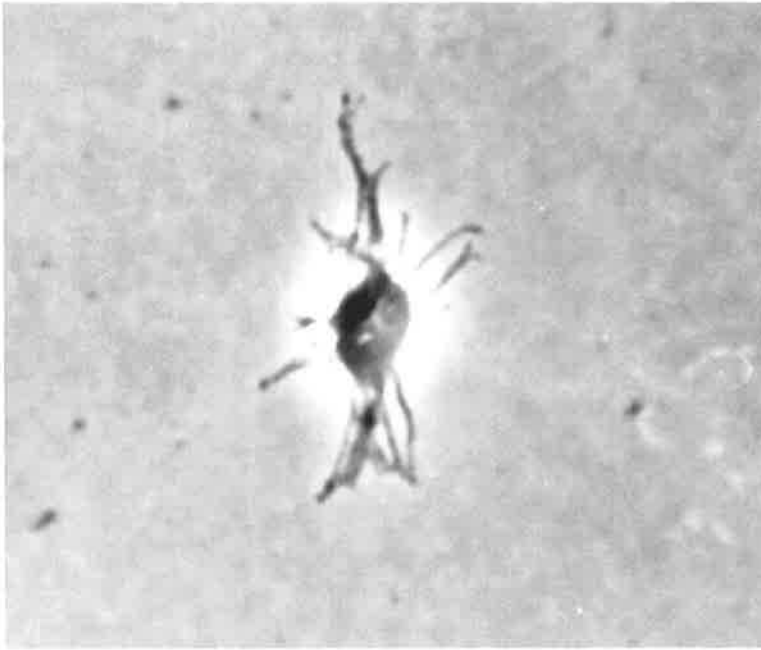


Fig. 50 Images of single neonatal melanocytes growing in a serum-free melanocyte medium

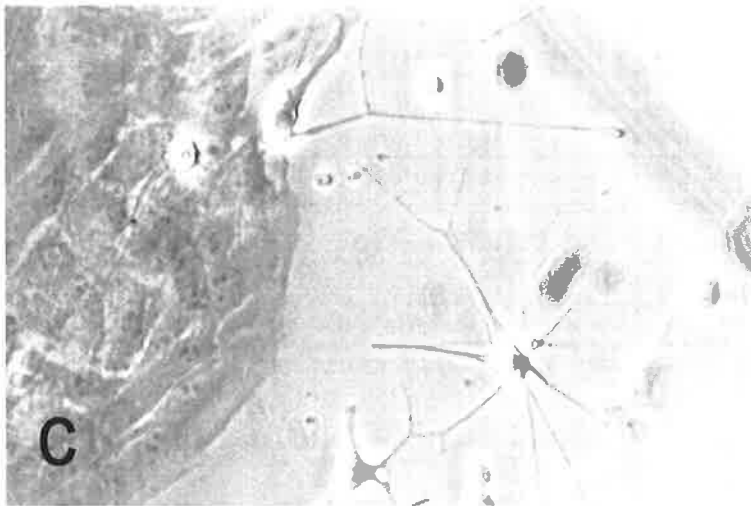
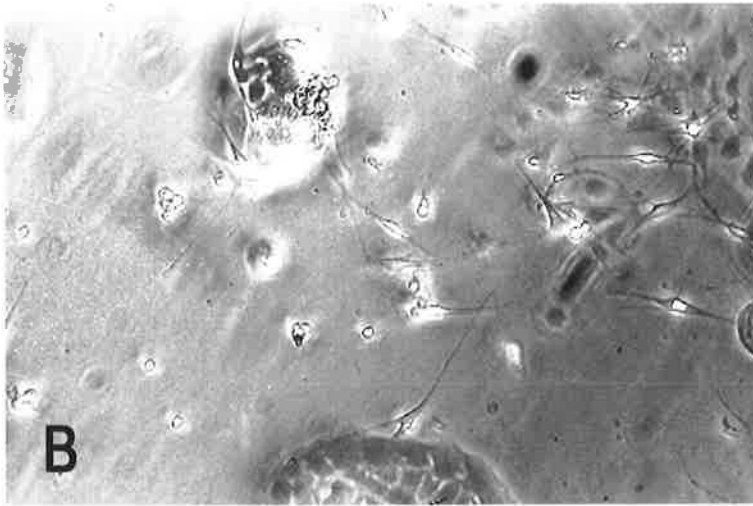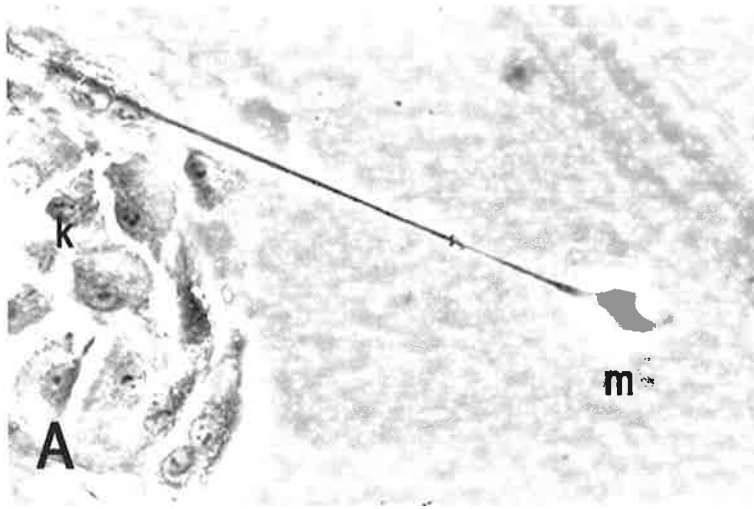
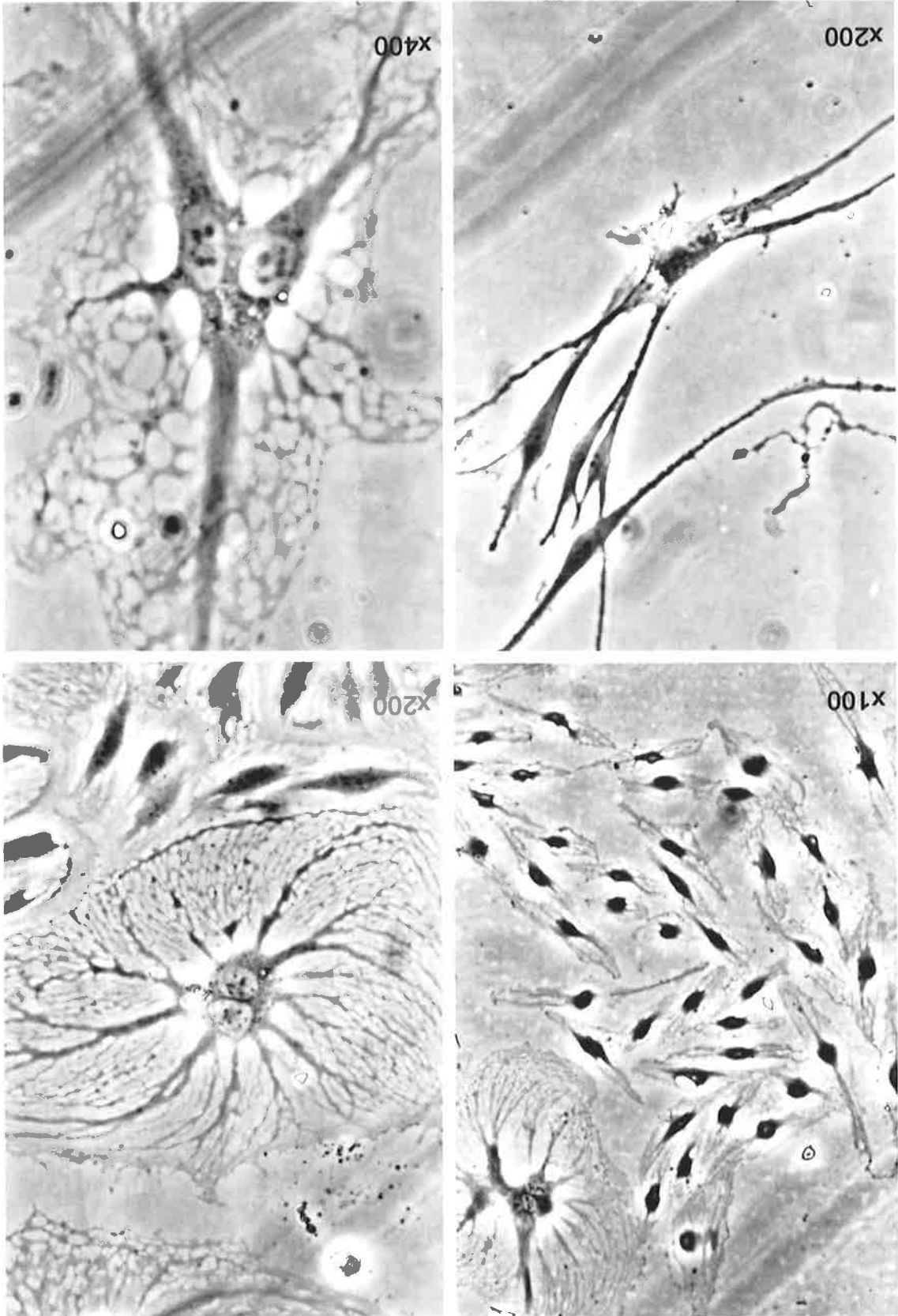


Fig. 51 Co-cultures of melanocytes (m) and keratinocytes (k) **A** and **C** were taken at an original magnification of x200 and **B** was taken at an original magnification of x100

Fig. 52 Phase contrast micrographs of melanocytes after 2 weeks of culture in medium containing FBS.






Fig. 53 Melanocytes **A** after 16 days of culture in 5% FBS and **B** after 4 weeks of culture in 5% FBS

4.3.1.3 Separation of melanocytes and keratinocytes

The use of chilled solutions (HEPES saline with trypsin and EDTA) to differentially separate melanocytes from co-cultures of melanocytes and keratinocytes (Pittelkow and Shipley 1989) was not successful. However, it was possible to separate the two cell types by a modification of this method using 0.05% trypsin and 0.53 mM EDTA (warm) for both cell types as the time difference between the separation of melanocytes (2-5 minutes from start of incubation) and the separation of keratinocytes (20-30 minutes from start of incubation) allowed a large window of opportunity to harvest cells with minimal contamination.

4.3.1.4 Immunostaining of cultured melanocytes

It was important to establish that the cells grown were in fact melanocytes and not some other cell type (e.g. fibroblasts). This is especially relevant because melanocytes become more bipolar and less characteristically dendritic with increasing time in culture. Melanocytes cultured in a T75 flask were successfully stained with the antibody Mel-5 by the method described above. The negative control piece of flask showed no staining at all, while in the other pieces of flask the melanocytes were stained red (Fig. 54). There was some deterioration of the cells during the process of staining and the cells treated with 70% alcohol were more intact at the end of the process than those treated with 5% DMSO (Fig. 55).

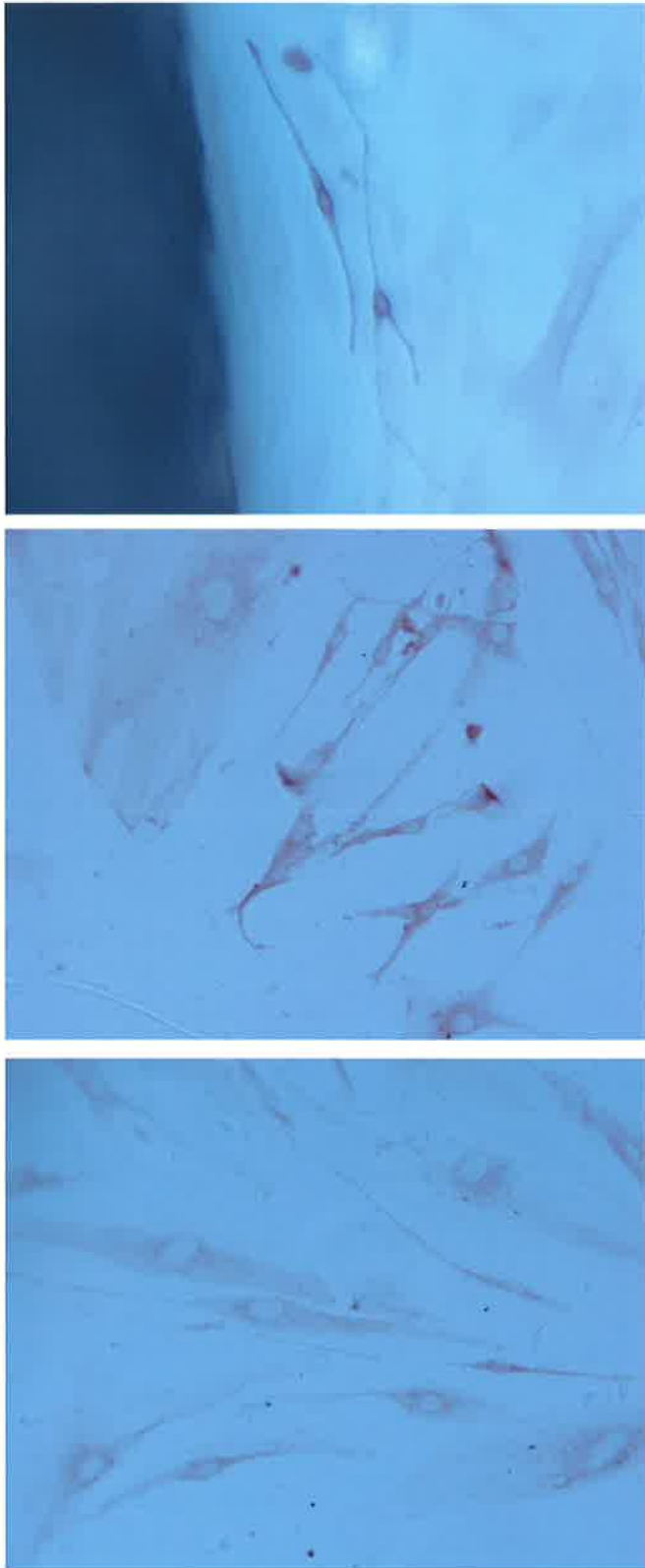


Fig. 54 Cultured melanocytes stained with Mel-5

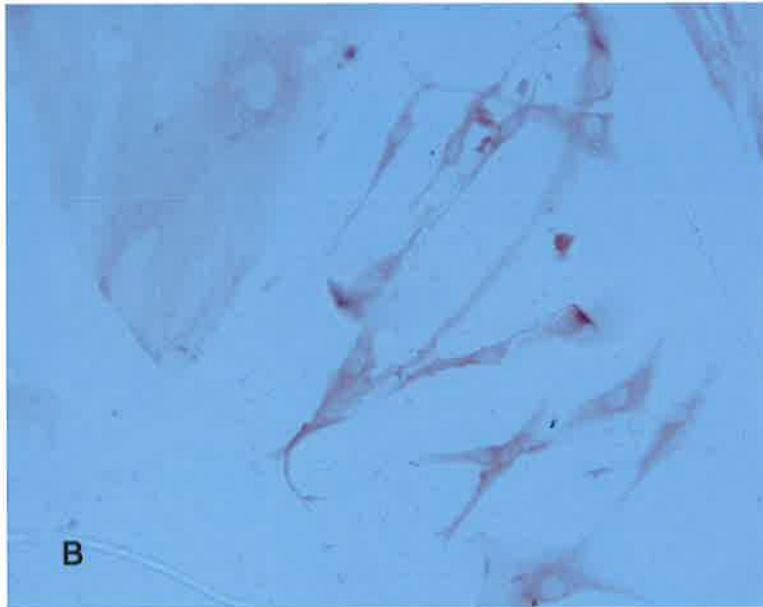
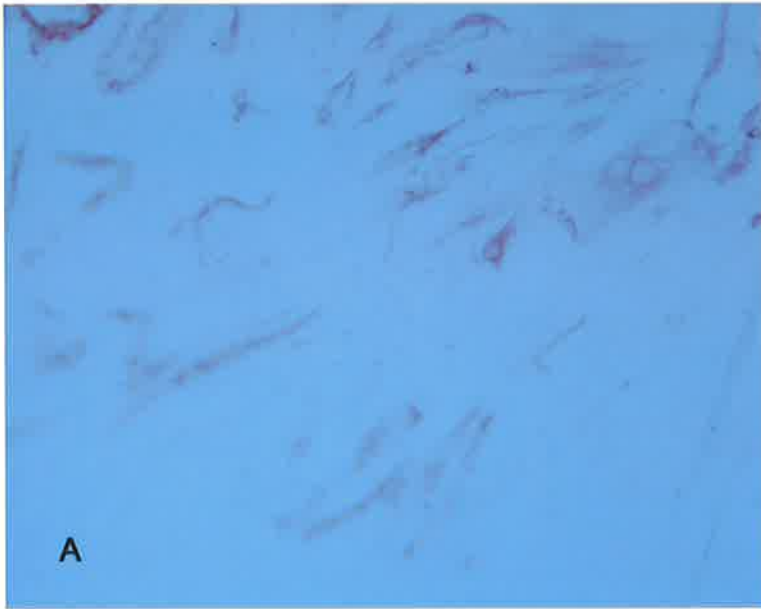

Fig. 55 A Melanocytes treated with 5% DMSO during immunohistochemical technique
B Melanocytes treated with 70% alcohol during immunohistochemical technique

4.3.2 Investigating a culture medium safe for use in the clinical setting

4.3.2.1 Comparison of culture media containing autologous human serum with other media for melanocyte growth

In the first experiment comparing human serum-containing media with other media (experiment COM1) melanocytes were grown successfully in US-MGM supplemented with 5% autologous human serum (Figs 55-57), whereas there was no growth in US-MGM with no serum. The flask containing US-MGM with 5% FBS showed adherence of melanocytes and keratinocytes but became contaminated in the first few days. In the flasks with melanocyte medium and AHS there developed an 80% confluent co-culture of melanocytes and keratinocytes (approx 50:50) in 15 days. Subjectively, the melanocytes grown in medium supplemented with AHS appeared more dendritic than those grown in medium supplemented with FBS. Melanocytes became less dendritic and more bipolar with increasing cell density in both media.

In the second experiment using autologous human serum (COM2) there was a significantly greater growth of melanocytes in media containing AHS compared to media containing FBS (Fig. 58). When cell counts were evaluated by a two sample t-test the significance of the difference between counts for AHS and FBS (two-tailed) was $p < 0.001$ at day 14.

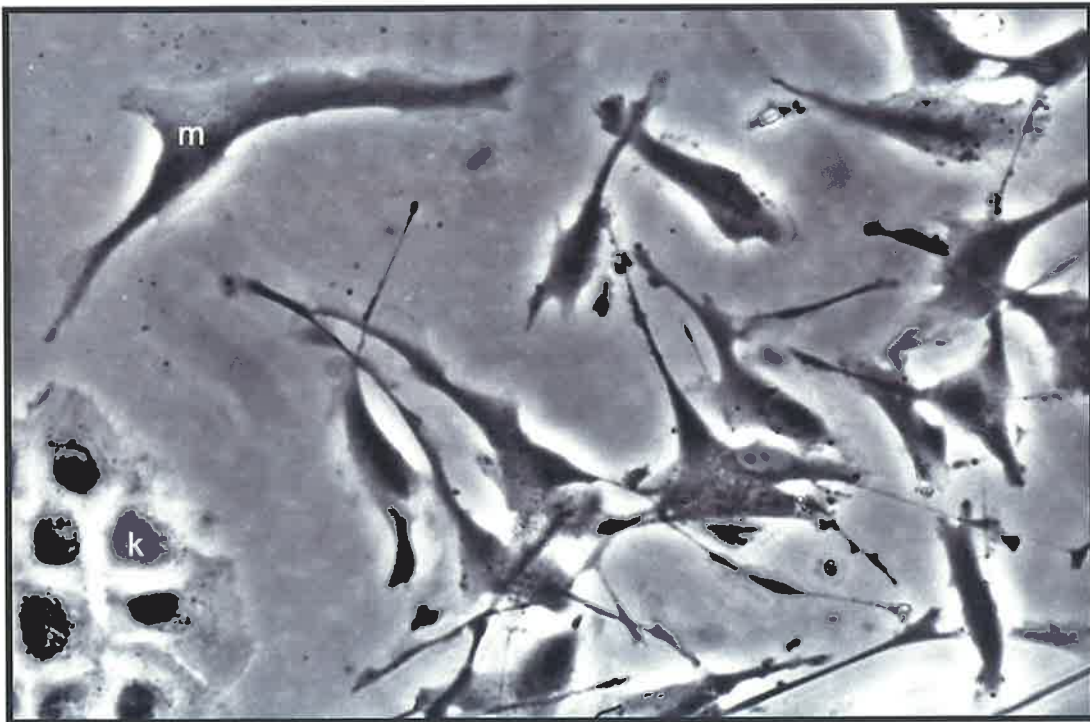
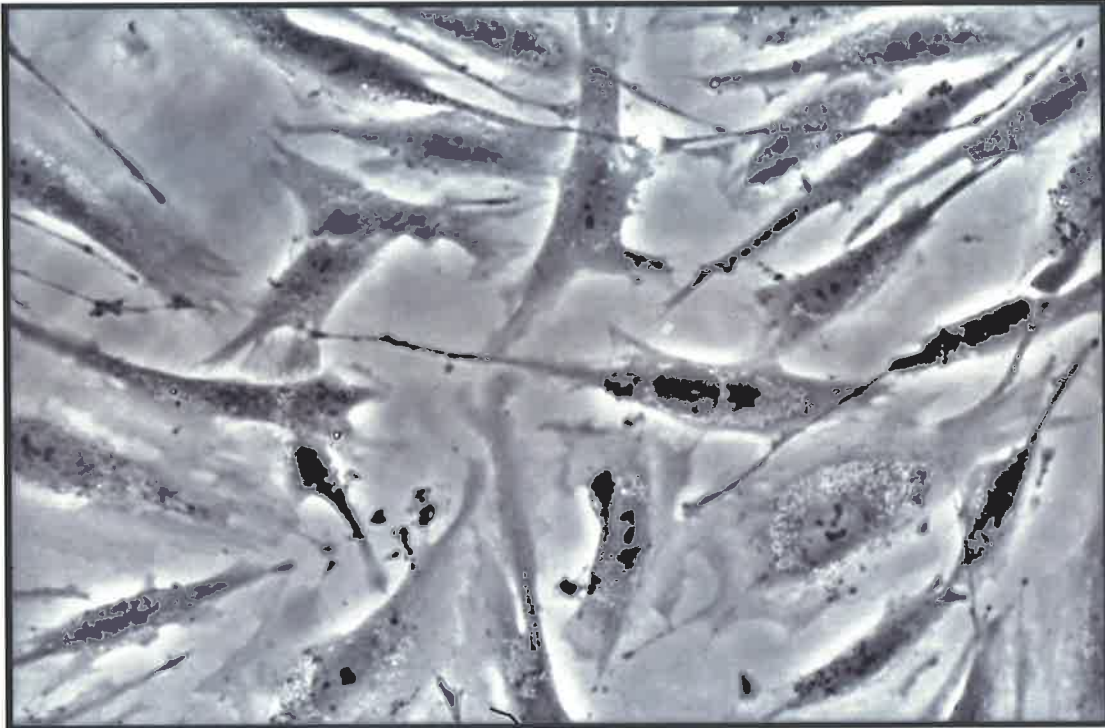


Fig. 56 Melanocytes growing in medium with 1% AHS and no cholera or PMA . Melanocytes (m) showing dendritic processes compared to the more cuboidal keratinocytes (k)

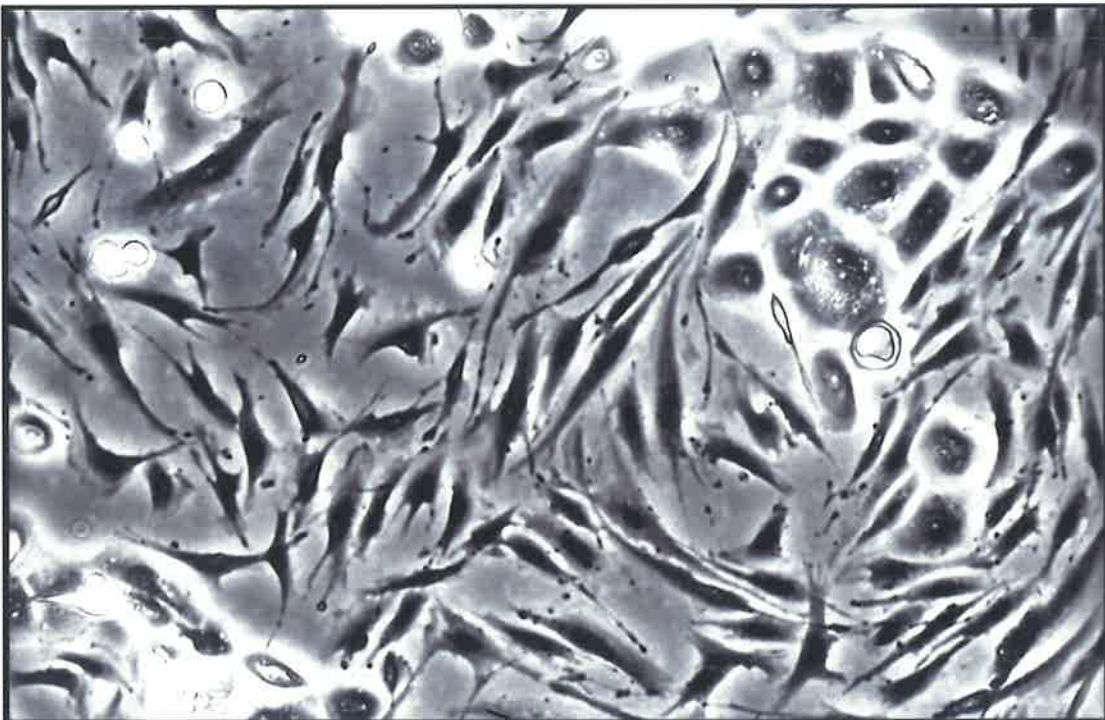
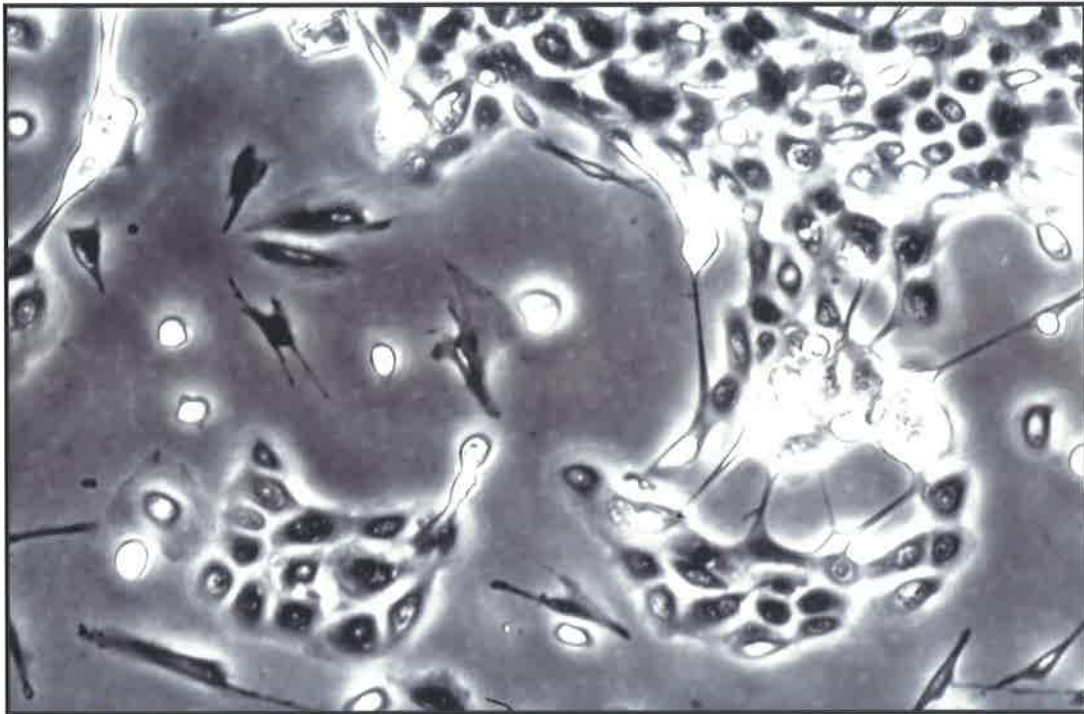


Fig. 57 Co-cultures of melanocytes and keratinocytes growing in AHS with no cholera toxin or PMA showing dendricity of melanocytes and cuboidal shape of keratinocytes

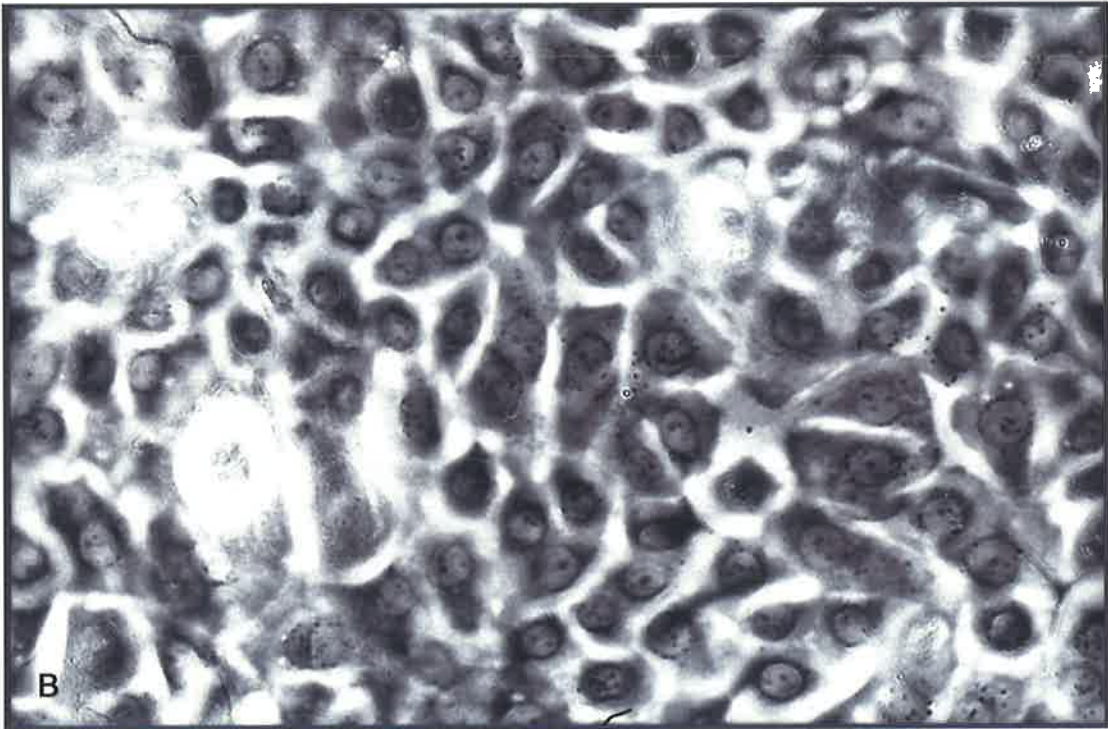
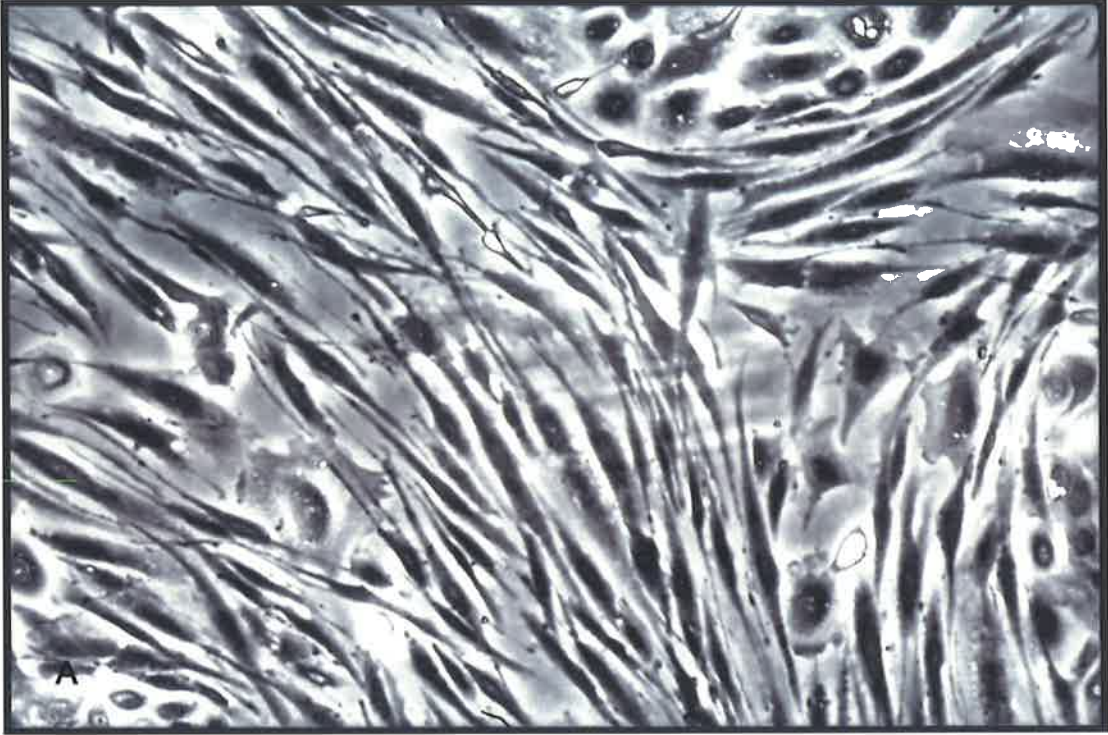


Fig. 58 Areas of confluent A melanocytes and B keratinocytes grown in AHS

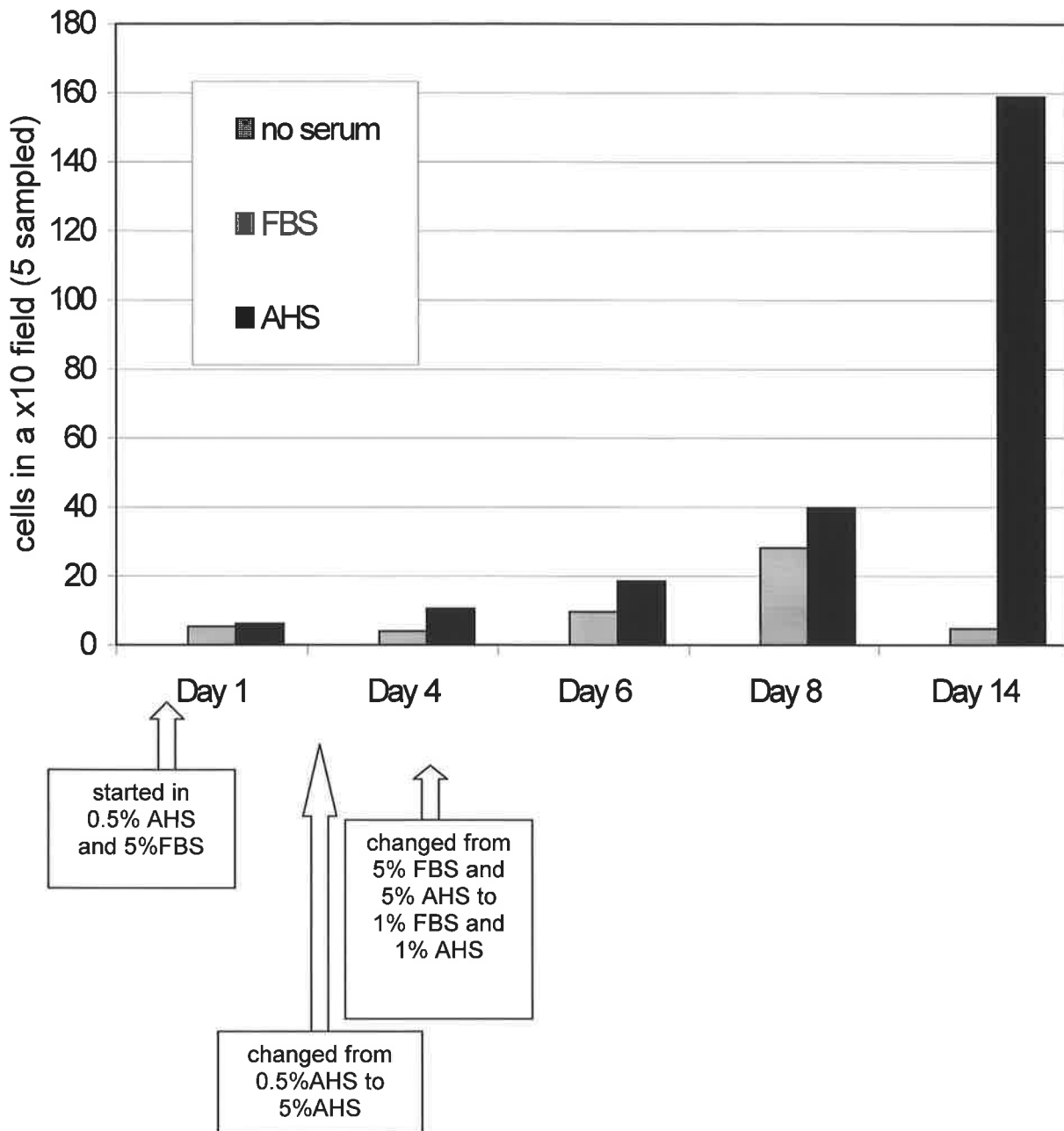


Fig. 59 Growth of primary cultures of melanocytes in medium containing no serum, fetal bovine serum (FBS) or autologous human serum (AHS)(Experiment COM2)

4.3.2.2 Comparison of media free of PMA and cholera toxin with media containing PMA and cholera toxin for melanocyte growth

In this experiment investigating clinically safer culture medium (COM3), the initial numbers of passaged melanocytes seeded (Day 0) were comparable between the groups: 8.4×10^4 cells for the flask containing US-MGM with 1%FBS, 8×10^4 cells for the flask containing US-MGM with 1%AHS with cholera toxin and PMA, and 7.6×10^4 cells for the flask containing US-MGM with 1%AHS with no cholera toxin or PMA (Fig. 60). Overall, there was a significant difference between the media in terms of melanocyte counts on analysis of variance ($p < 0.0001$), this being due to the better growth of melanocytes in medium containing AHS rather than FBS. On two-sample t-testing the difference in melanocyte counts between the medium containing FBS and either of the media containing the AHS was statistically significant on all the days it was measured (Table 11).

Table 11 Mean melanocyte counts in medium containing AHS vs FBS

	<i>Days post-seeding</i>		
	<i>Day 1</i>	<i>Day 4</i>	<i>Day 5</i>
US-MGM+AHS+ cholera+PMA vs US-MGM+FBS <i>(p-value on t-test)</i>	21.4 vs 14.2 <i>(p<0.05)</i>	48.8 vs 19.4 <i>(p<0.001)</i>	86 vs 24.2 <i>(p<0.01)</i>
US-MGM+AHS (no cholera or PMA) vs US-MGM+FBS <i>(p-value on t-test)</i>	39.4 vs 14.2 <i>(p<0.0001)</i>	64.6 vs 19.4 <i>(p<0.0001)</i>	52.2 vs 24.2 <i>(p<0.005)</i>

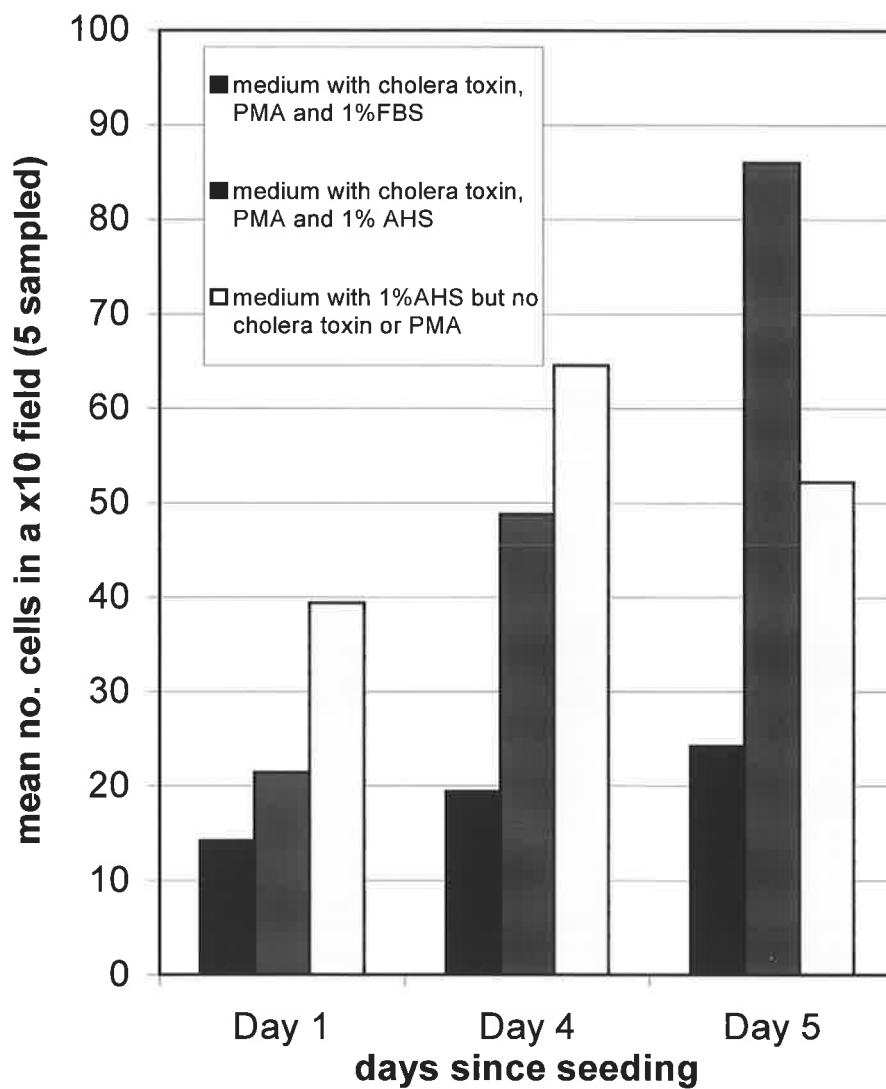


Fig. 60 Mean cell counts for passaged melanocytes in different media

4.3.3 Skin constructs

4.3.3.1 Production of skin constructs

Production of skin constructs was successful using the technique described. On visual inspection by the naked eye and with loupe magnification (x3) an epidermis had developed on the surface of the dermis by day three post-seeding of epidermal cells. The Transwell® culture plates were easy to use for producing and maintaining the constructs and adjusting the medium to the required level in relation to the dermis.

No comparisons were possible between the skin constructs of the different experiments, as a number of constructs were lost due to contamination and some were not optimally processed for histological examination, making immunostaining difficult.

4.3.3.2 Assessment of skin constructs

Photography of the skin constructs with the colour standards gave suboptimal images because the constructs had to be kept in a fume hood, which had poor lighting for the task and many reflections. The intense colour of the cell culture medium also hampered colour analysis (Fig. 61) and latterly the author photographed the constructs in the interval between aspiration of spent medium and instillation of fresh medium.

The skin constructs generated with dermis in experiment SC1 had a number of images suitable for analysis but there was no statistically significant trend found in saturations or hues over time with any of the skin constructs (Figs 62 and 63).

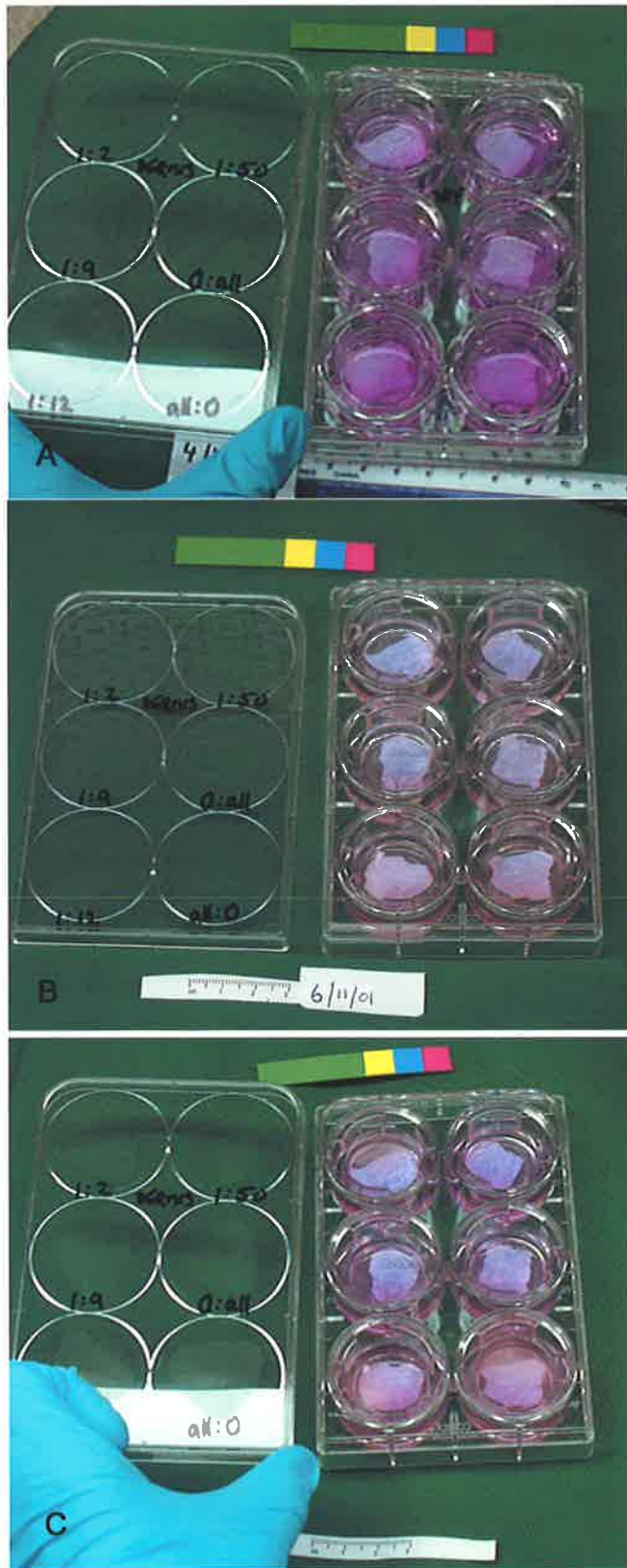


Fig. 61 Photographs of skin constructs with colour standards on **A** day 0 **B** day 2 and **C** day 4 post-seeding of epidermal cells

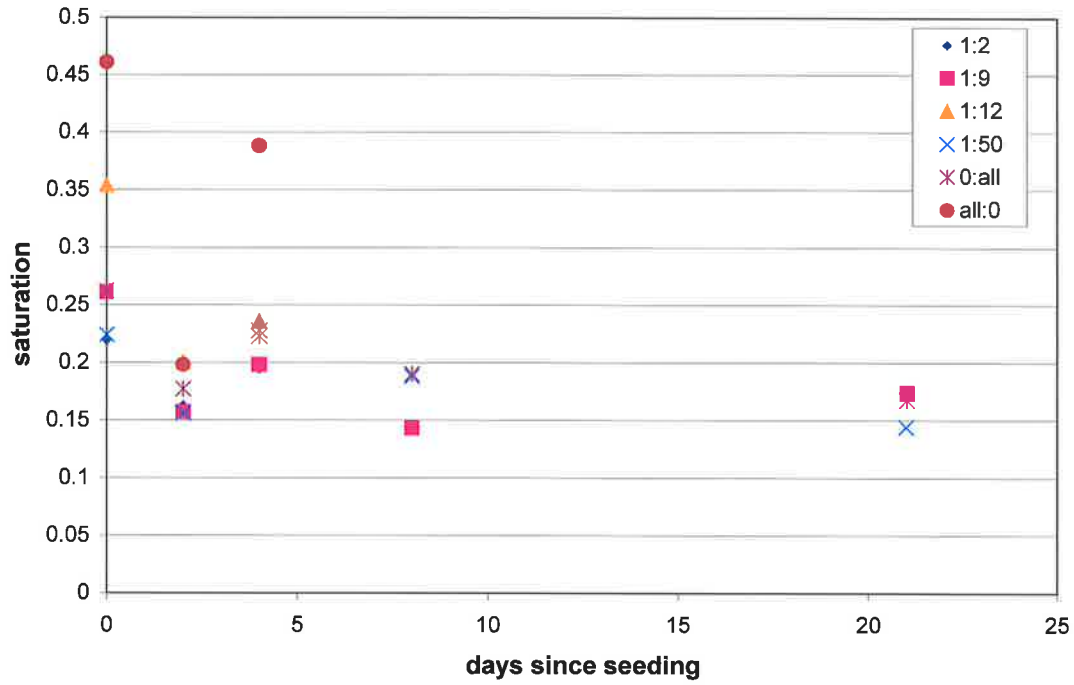


Fig. 62 Colour saturations of skin constructs (dermis) from experiment 1 vs time since seeding

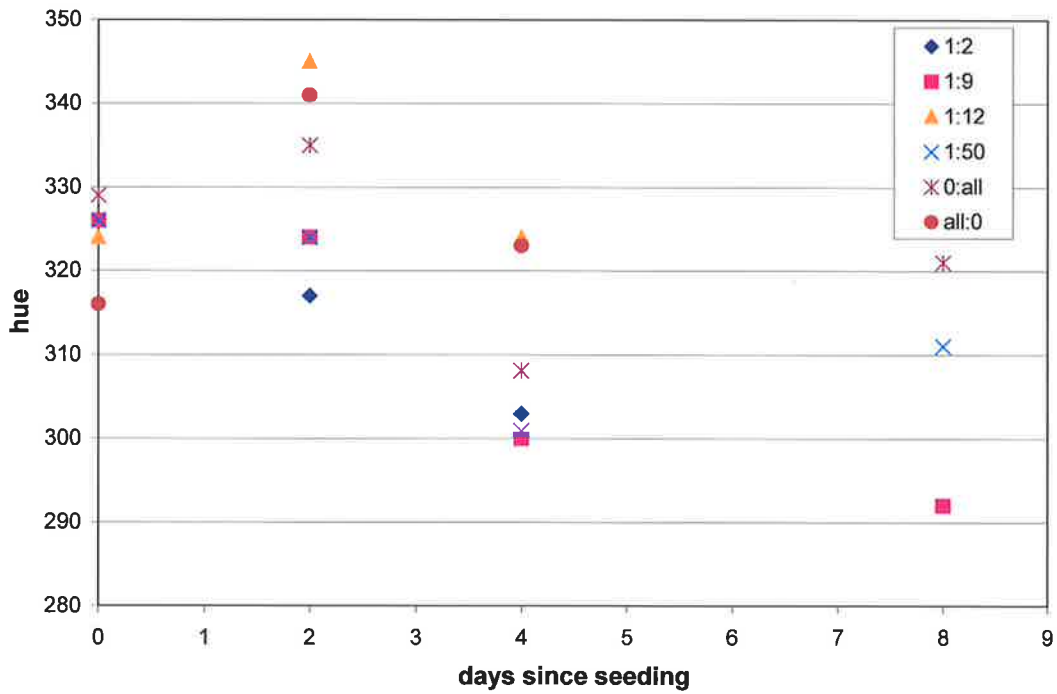


Fig. 63 Hue of skin constructs (dermis) from experiment 1 vs time since seeding

Skin constructs from experiment SC3 developed a stratified layer of keratinocytes above the dermis. The cells were more disordered than in normal skin and cellular morphology was difficult to distinguish. The surface of the construct had an undulating appearance in most instances (Fig. 64).

Mel-5 staining revealed melanocytes within the constructs which were observed as red stained cells at the dermo-epidermal junction (Figs 64 and 65). There were insufficient specimens to perform a formal quantitative assessment of melanocytes in specimens with different seeding ratios of melanocytes to keratinocytes and on simple observation there was no obvious relationship between the number of stained melanocytes and initial seeding ratio.

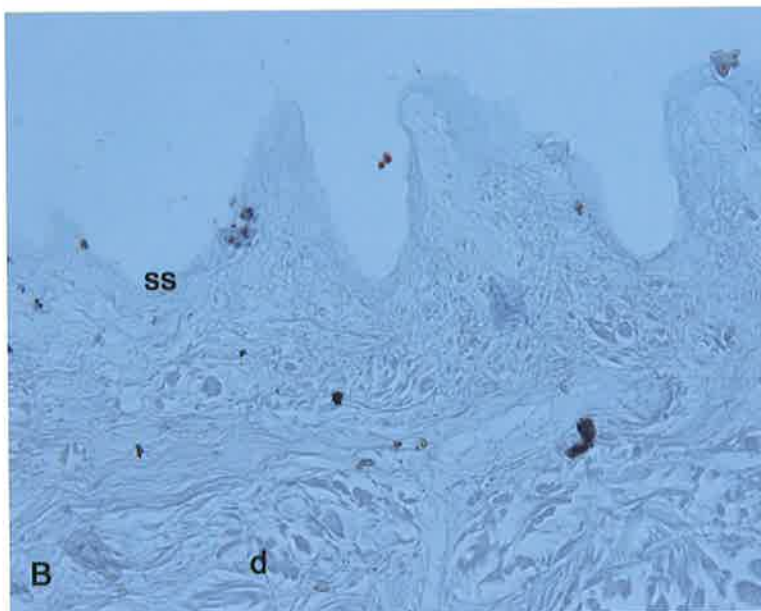
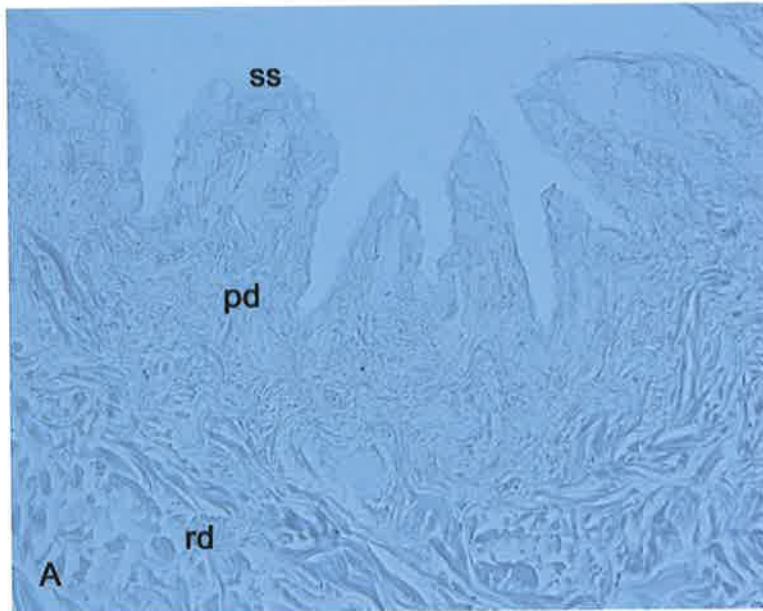


Fig. 64 Paraffin sections of freeze thawed abdominal dermis seeded with epidermal cells from breast skin of a different patient: few epidermal cells seem to have survived. **ss** skin surface **pd** papillary dermis, **rd** reticular dermis **A** negative control **B** stained with Mel-5 - Occasional Mel-5-labelled particles are probably artefact but may be melanocytes.

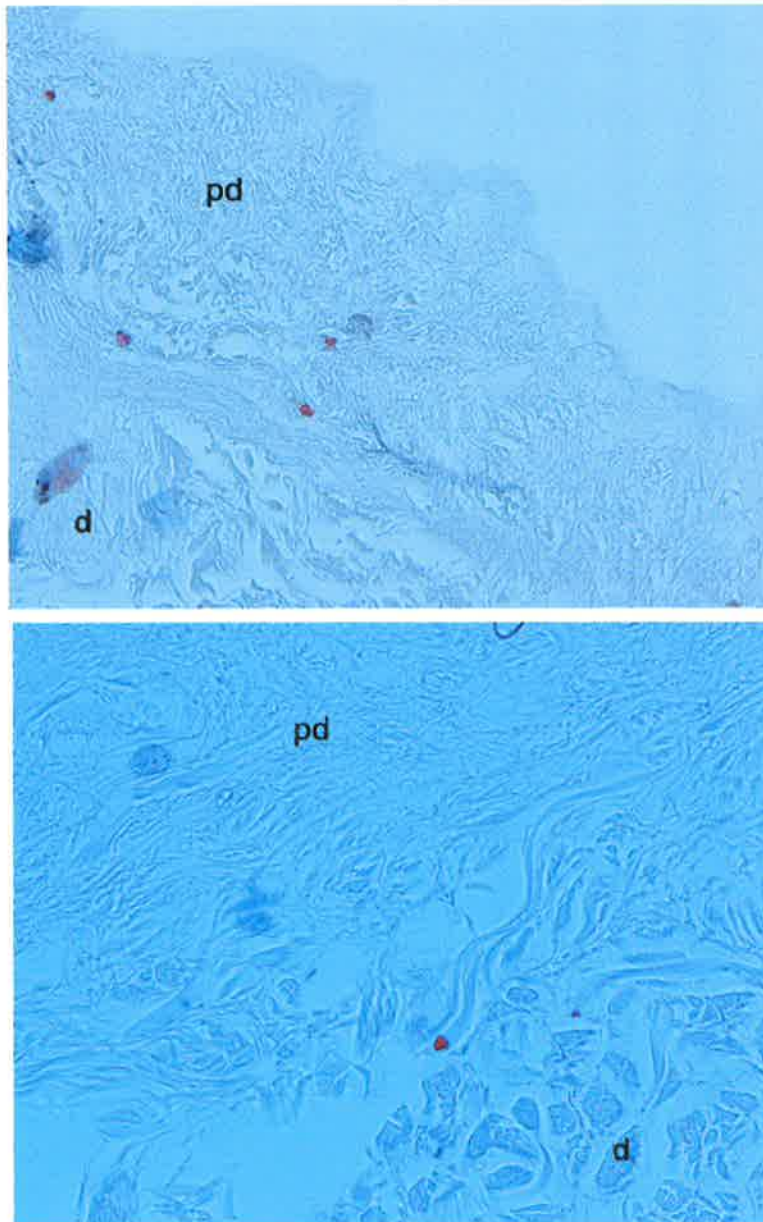


Fig. 65 Particles labelled with Mel-5 (red - chromogen AEC) - may be melanocytes or artefact. **pd** - papillary dermis **d** - reticular dermis

4.4 DISCUSSION

4.4.1 Epidermal cell culture from adult surgical discard skin

In the current study, split thickness skin was found to give the best yield of basal epidermal cells. This is in keeping with the experience of previous investigators (Nielsen and Don 1984; Eisinger 1985) who have used split thickness, rather than full thickness skin for cell culture. If cell culture were to be used in nipple-areolar reconstruction, harvest of skin from patients undergoing TRAM flap reconstruction of the breast mound would be feasible because in the procedure there is usually an area of redundant skin (Fig. 66) suitable for shaving with a skin-grafting knife or dermatome.

Treatment of split skin with 0.25% trypsin overnight, with subsequent removal of the superficial epithelium and scraping of the basal layer, was found to be the most successful method for yielding basal cells. Nielsen and Don elegantly showed the difference between using trypsin and collagenase to digest the skin (Fig. 67) and were the first to describe scraping off the basal layer of the epidermis from the dermis of skin that had been incubated in trypsin, to obtain a cell suspension enriched with melanocytes (Nielsen and Don 1984). Prior to this, Rheinwald and Green (1975) described using 0.25% trypsin to yield their skin cells but their method involved mincing of whole skin and digesting skin with trypsin at 37°C. Eisinger and Marko used overnight incubation of split skin with trypsin overnight at 4°C followed by pipetting of epidermal samples for culture of melanocytes. The difficulty the author had using methods involving dissociating cells from superficial epithelial sheets may have been related to the age of the patients donating skin. McLeod and Mason noticed a difference between the responsiveness of neonatal, fetal and adult skin to treatment aimed at yielding basal cells (McLeod and Mason 1995). As well as trypsin, this group

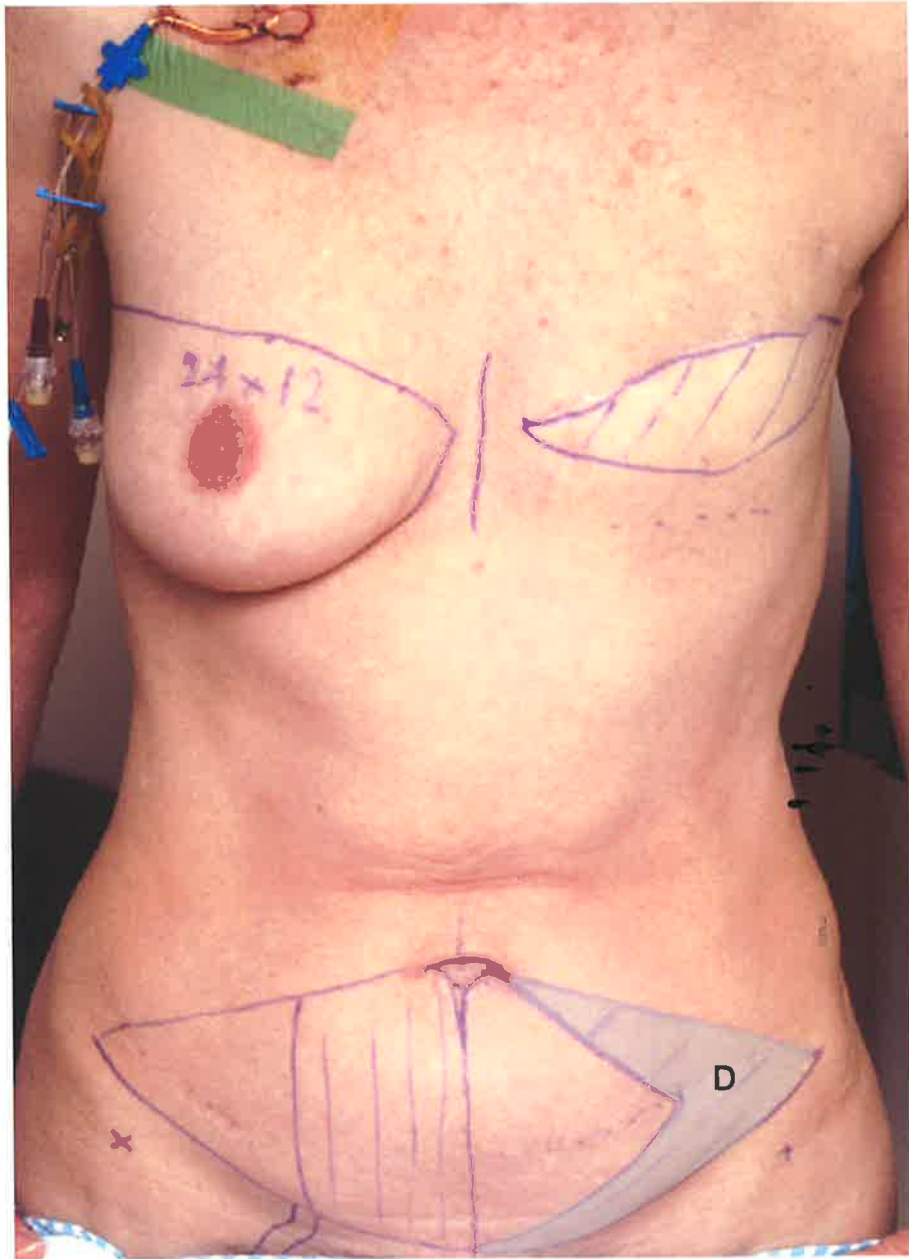


Fig. 66 Potential donor site **D** for skin for cell culture in patient about to undergo TRAM flap reconstruction of the breast mound

also used thermolysin, with which the author has no experience. Although the use of dispase and subsequent dissociation of superficial epithelial sheets was not found to be a reliable method for yielding basal cells in this study, dispase could play a role in treating full thickness skin to yield dermis samples for nipple-areolar reconstructions.

4.4.2 Culture media safe for use in a clinical setting

For *in vitro* cell culture to be used in a clinical setting, the safety of the patient must be considered paramount. *In vitro* culture of melanocytes for research purposes has historically been performed using fetal bovine serum, phorbol esters and cholera toxin (Eisinger and Marko 1982). Fetal bovine serum carries a theoretical risk of transmitting bovine infections and phorbol esters and cholera toxin have a theoretical risk of toxicity to the patient. The current study investigated strategies for eliminating these risks for the clinical scenario of cell culture for nipple-areolar reconstruction that would be acceptable to the regulatory authorities such as the Therapeutic Goods Administration (Australia).

In the current study, growth of melanocytes in a medium containing no serum but supplemented with bFGF (MGM-2, Clonetics) was unsuccessful. Serum-free culture of melanocytes in medium containing bFGF has been reported elsewhere (Gilchrest et al. 1984; Olsson and Juhlin 1993) and poor growth in the current study may have been due to the low initial yield of basal cells when the serum-free medium was being used.

An alternative strategy to using no serum in the culture medium was to use the patient's own serum as a supplement to the medium instead of fetal bovine serum. This strategy means that the benefits of the serum are retained but without the risk of transmission of disease. For culturing cells in this study it was necessary to assess what percentage of autologous human serum was necessary for melanocytes to grow. As this

information is unavailable in the literature, Gilchrest and colleagues' work on concentrations of fetal bovine serum (Gilchrest et al. 1984) was used as a guide. Gilchrest's group found that the best long-term culture of melanocytes was achieved with medium containing 1% FBS and that higher concentrations of FBS led to fibroblast contamination. In the current study, a concentration of 1% AHS produced successful cultures of both melanocytes and keratinocytes. The concentration of serum used is logistically important if this technique is to be applied clinically because patients are easily able to donate enough serum to provide for medium with a concentration of 1% AHS but may not be able or willing to donate enough to maintain the cells in a 5% or 10% AHS medium. The results of the current study cannot be regarded as definitive because of the small numbers used but they did indicate that AHS was at least equivalent in effectiveness to the same concentration of FBS in producing growth of melanocytes *in vitro*.

The need for cholera toxin and PMA in the medium for melanocytes was the next issue to be addressed in the current study. PMA is acknowledged as a tumour-promoting agent and although other phorbol esters have been used successfully for melanocyte culture (Cela et al. 1991), these agents cannot be regarded as safe for patients. In the current study, results indicated that if autologous human serum was used, melanocytes could be grown in the absence of PMA or cholera toxin. Melanocytes tended to grow in a co-culture with keratinocytes in this medium but could easily be separated by the differential trypsinization method described to provide cell lines of either type. It was found that co-cultures could be grown either in the melanocyte medium (US-MGM or MGM-2, Clonetics) or in the serum-free keratinocyte medium (Defined Keratinocyte SFM, Gibco BRL, based on MCDB 153, (Boyce and Ham 1985)). In both cases melanocytes and keratinocytes grew in colonies of their own cell type, rather than the two cell types being evenly interspersed. Melanocytes grown in

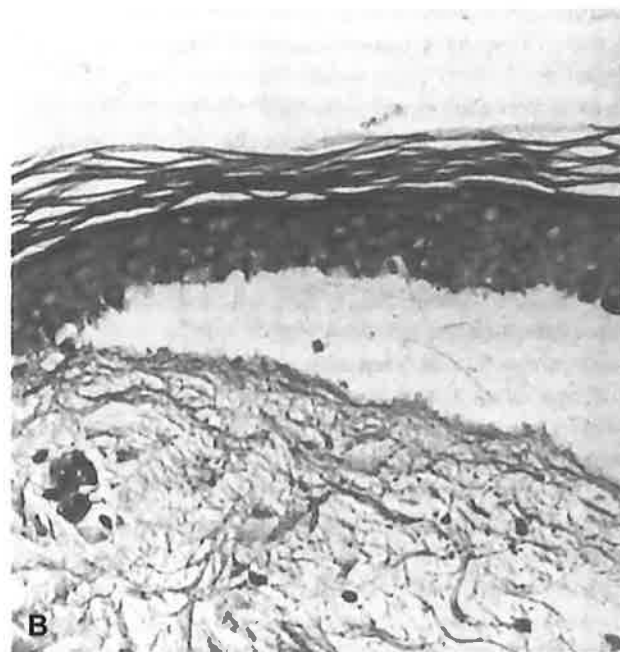
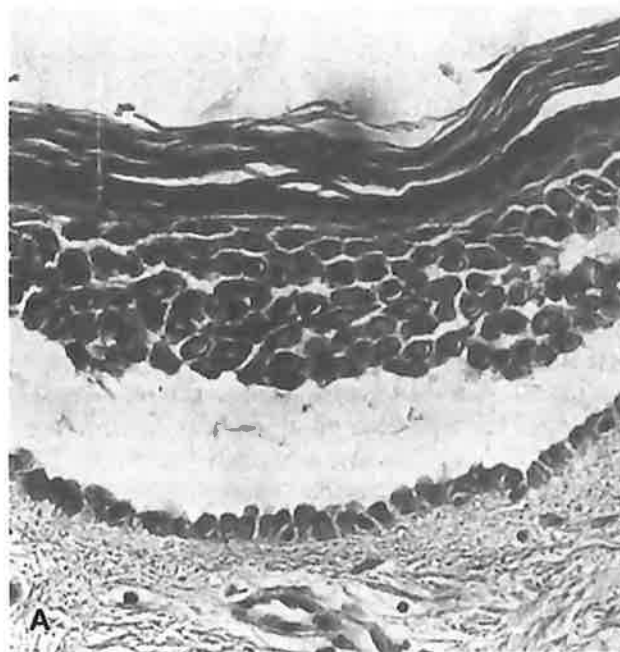


Fig. 67 (From (Nielsen and Don 1984)) **A** Separation of adult human skin by trypsin floatation. Notice the partly dissociated epidermal cells and the layer of basal epidermal cells attached to the intact dermis
B Separation of adult human skin by collagenase. The separation takes place between a relatively intact epidermis and a partly dissociated dermis.

medium free of TPA and cholera toxin looked morphologically similar to those grown in 1% AHS with PMA and cholera toxin. There is an increasing amount of evidence to suggest that growing melanocytes initially in a co-culture with keratinocytes in fact improves their growth potential and provides more physiologically normal cells than endeavoring to culture melanocytes in isolation *ab initio* (Nielsen and Don 1984; Halaban et al. 1988; McLeod and Mason 1995).

The implications for being able to culture keratinocytes and particularly melanocytes in a medium free of FBS, cholera toxin and PMA are wider than the context of nipple-areolar reconstruction. Autologous melanocytes for pigmentary disorders could be grown in a medium containing autologous human serum and may be more reliable than using serum-free medium. Pharmacological studies and research on melanocyte behaviour may also more closely mimic the *in vivo* situation if melanocytes are cultured in a medium containing AHS without PMA and cholera toxin. One limitation of this technique is that human serum is more difficult to obtain outside the clinical context, although expired blood from transfusion services may be available in the research setting.

Naevocytes have been cultured for use in pigmenting an area of a breast reconstruction to mimic an areola (Baltaci and Kilic 1998). The fundamental problem with this method is that naevocytes are not normal melanocytes and have an increased potential to undergo malignant transformation, especially if exposed to mitogens in the culture process (Alanko and Saksela 2000).

4.4.3 Skin constructs

In the current study it was found to be possible to generate skin constructs from adult melanocytes and keratinocytes that had been grown in a medium free of cholera

toxin and PMA and containing autologous human serum. The method used for creation of the skin constructs came from a variety of sources. Preserving dermis by freezing at -80°C is the technique used in the manufacture of Alloderm® (Harper and Livesey 1998). The freezing process kills the cells present but, on thawing, the dermal matrix is intact and may contain growth factors from lysed fibroblasts (Harper and Livesey 1998). This technique was successfully used in the current study. Thicker specimens of dermis, obtained from full thickness skin, are easier to handle and probably more desirable from a reconstructive point of view because they would offer greater structural support to the construct and would be less likely to contract than split thickness specimens.

Differentiation of keratinocytes into stratified layers by placing cultures at an air-liquid interface was discovered by Prunieras et al. (1983). Prior to this study it was known that the calcium content of medium had a significant effect on keratinocyte differentiation (Hennings et al. 1980; Boyce and Ham 1983) and that serum contained a concentration of calcium that could produce keratinocyte differentiation into stratified layers. It was this work which led the author to produce skin constructs in the way described above. The presence of 1% serum in both initial monolayer cultures and subsequent growth of cells in a skin construct was a concentration that achieved a good balance of keratinocyte differentiation - a monolayer in the culture flasks and a stratified epithelium when stimulated with the air-liquid interface. It was shown in this study that the supporting structure for the construct does not have to have a high degree of sophistication and a home-made device produced as good a construct as a specially manufactured one. Bessou and co-workers have successfully produced similar constructs on wire meshes (Bessou et al. 1997).

It was interesting that on histological examination the melanocytes were sited in their correct position along the basement membrane and were single, rather than in

groups. This concurs with the experience of Regnier and co-workers, who advocate the concept that it is something intrinsic to the dermis that determines melanocyte distribution and behaviour (Regnier et al. 1984; Regnier et al. 1998).

The author was unable to prove, either using colour analysis or histologically, that an increased seeding ratio of melanocytes to keratinocytes produced a more pigmented skin construct. Issues that could be addressed in further studies are: the possibility of maintaining the skin constructs in a more natural light environment - in the current study skin constructs were maintained in an incubator with no light, and refinement of the photography of constructs for colour analysis. Bessou and co-workers have produced pigmented skin constructs and performed colourimetric and histological analysis of them in a study examining the effect of pigment modifying drugs. They were able to successfully show a measurable effect of the drugs on this model, both histologically and with colorimetry. This illustrates that producing a perceptibly different pigmentation in pigmented skin constructs is possible.

The development of pigmented skin constructs or pigmented skin equivalents has a range of interesting applications and brings together several fields. Pharmacologists studying the actions of drugs on “skin”, surgeons trying to achieve better results for patients with burns, dermatologists treating hypopigmentary disorders and cell biologists researching the cellular mechanisms for melanocyte and keratinocyte behaviour.

4.4.4 Clinical application of skin constructs for nipple-areolar reconstruction

The objectives of finding a successful method for harvesting and culturing skin cells from adult surgical discard skin have been fulfilled. The objective of finding a relatively safe culture medium for epidermal cells has also been achieved, with the use

of autologous human serum. The current study has also shown that skin constructs can be produced from these cultured cells, and melanocytes in the constructs attain their physiological position, singly along the basement membrane. What has not been established is the effect of varying the seeding ratio of melanocytes to keratinocytes on final colour of the construct. This was not achieved because the number of constructs produced was too low and the method of measurement of colour in the constructs was not suitable.

Creation of neo-areolar skin with pigmented skin constructs differs from the other clinical applications of engineered skin (such as burns surgery), in that donor skin for generation of cell cultures is relatively plentiful - it is the re-engineering of the cell ratios in the skin (and consequent pigmentation) that is required, rather than an expansion of the total amount of skin. This unique set of circumstances, makes this an interesting clinical application for the science of *in vitro* engineered skin.

ADDENDUM TO DISCUSSION

Since the work described above was carried out a co-culture system of melanocytes and keratinocytes on an artificial membrane has become commercially available as Melanoderm™. This system consists of melanocytes and keratinocytes only and has no dermal elements. Its main application is for pharmacological testing of products (Klausner et al. 2001). There have also been developments in trying to use keratinocyte stem cells for skin equivalents but keratinocyte stem cells have not yet been fully genetically characterized (Kuhn et al. 2002).

CHAPTER 5

CONCLUSION

The work described in the previous chapters has led to the following conclusions:

- Current methods of pigmentation nipple-areolar reconstructions are sub-optimal
- The features of the normal areolar skin which pertain to its special pigmentation are:
 - a higher than average density of melanocytes
 - a greater amount of melanin per melanocyte
 - an increased convolution of the basement membrane
- It is possible to culture adult melanocytes *in vitro*
 - in an environment free of cholera toxin or phorbol esters
 - in an environment containing autologous human serum (which does not carry the same infective risk as fetal bovine serum or heterologous human serum)
- It is possible to create reconstituted skin constructs using cells cultured in the above mentioned environment in conjunction with freeze-thawed human dermis

It is not possible, at this stage, to say whether melanocyte to keratinocyte ratios can be maintained at an “engineered” level in skin constructs, whether such constructs will be safe or whether they will meet the clinical need of a more satisfactory source of pigmented skin for nipple-areolar reconstructions.

Appendix I

Appendix II

Appendix III

Patient Information Sheet

New approaches to Nipple-areolar Reconstruction After Breast Cancer

We would like to ask you if you would help us by agreeing to take part in a review of patients who have had nipple-areolar reconstructions. If you agree, you will be asked to fill in a questionnaire and have some photographs taken. The purpose of the study is to find out what people think about the results of their breast and nipple-areolar reconstructions. Another part of the project involves looking at the structure of the areola more carefully to identify how the pigmentation is produced. We are also looking into the possibility of growing pigmented skin cells in a laboratory which may be useful for areola reconstruction in the future.

Your participation in the study is voluntary and you may withdraw at any time and this will not affect your medical treatment in any way.

The investigators in this study are:-

Dr. Nicola Dean
Research Fellow in Plastic Surgery
Tel (08) 8354 2361

Dr. Rod Cooter
Director of Plastic Surgery
Royal Adelaide Hospital
Tel (08) 8222 4500

Dr. Chris Goddard
Director of Cell Biology
CRC for Tissue Growth and Repair
Tel (08) 8303 8887

Dr. Julie Haynes
Lecturer in Anatomical
Sciences
Adelaide University
Tel (08) 8303 5769

Please feel free to contact any of the above if you have any questions about the study.

If you wish to discuss aspects of the study with someone not directly involved you may also contact Mr. Paul Miller, Research Ethics Committee, Queen Elizabeth Hospital 8222 7206.

Appendix IV

Patient Information Sheet

New approaches to Nipple-areolar Reconstruction After Breast Cancer

We would like to ask you if you would help us by donating the skin which would normally be discarded during your operation. In breast reduction and abdominoplasty operations some skin is removed. This skin would normally be disposed of and donating it will not affect your treatment in any way.

If you agree, the skin you donate will be used for research into improving breast reconstruction for women who have had breast cancer. The research involves using the skin to grow cells which may enable us to look into the possibility of better reconstruction of the pigmented part of the breast (nipple and areola) in the longterm. No cells grown from your skin would be transplanted back to any other person.

Your participation is voluntary and you may withdraw at any time and this will not affect your medical treatment in any way.

The investigators in this study are:-

Dr. Nicola Dean
Research Fellow in Plastic Surgery
Tel (08) 8354 2361

Dr. Rod Cooter
Director of Plastic Surgery
Royal Adelaide Hospital
Tel (08) 8222 4500

Dr. Chris Goddard
Director of Cell Biology
CRC for Tissue Growth and Repair
Tel (08) 8303 8887

Dr. Julie Haynes
Lecturer in Anatomical
Sciences
Adelaide University
Tel (08) 8303 5769

Please feel free to contact any of the above if you have any questions about the study.

If you wish to discuss aspects of the study with someone not directly involved you may also contact Research Ethics Committee, Royal Adelaide Hospital 8222 25650.

Appendix V

Patient Information Sheet

New approaches to Nipple-areolar Reconstruction After Breast Cancer

We would like to ask you if you would help us by donating the skin which would normally be discarded during your operation. In breast reduction and abdominoplasty operations some skin is removed. This skin would normally be disposed of and donating it will not affect your treatment in any way.

If you agree, the skin you donate will be used for research into improving breast reconstruction for women who have had breast cancer. The research involves using the skin to grow cells which may enable us to look into the possibility of better reconstruction of the pigmented part of the breast (nipple and areola) in the longterm. No cells grown from your skin would be transplanted back to any other person.

We would also like to ask you if you would donate a sample of blood. The serum (clear fluid) from the blood will be used as nourishment for the cells while they are growing. It would be discarded after use and not used for any other purpose.

Your participation is voluntary and you may withdraw at any time and this will not affect your medical treatment in any way.

The investigators in this study are:-

Dr. Nicola Dean
Research Fellow in Plastic Surgery
Tel (08) 8354 2361

Dr. Rod Cooter
Director of Plastic Surgery
Royal Adelaide Hospital
Tel (08) 8222 4500

Dr. Chris Goddard
Director of Cell Biology
CRC for Tissue Growth and Repair
Tel (08) 8303 8887

Dr. Julie Haynes
Lecturer in Anatomical
Sciences
Adelaide University
Tel (08) 8303 5769

Please feel free to contact any of the above if you have any questions about the study.

If you wish to discuss aspects of the study with someone not directly involved you may also contact Research Ethics Committee, Royal Adelaide Hospital 8222 25650.

Appendix VI

7th February 2000

Dear Mrs,

I am writing to ask for your participation in a study to assess the results of nipple-areolar reconstruction. I am a plastic surgery research doctor, working with Mr. Cooter and together, we are looking at the impact breast and nipple-areolar reconstruction has had for women who have undergone mastectomy. Part of my PhD research also involves examining what role tissue engineering could play in nipple-areolar reconstructions in the future .

Participation would involve coming to see me at the Royal Adelaide Hospital Department of Plastic and Reconstructive Surgery for a brief visit which should take no more than 30 mins. During the visit, I will ask you to fill in two short questionnaires and will accompany you to have some photographs taken by a clinical photographer. It is important for this research to have very high quality photographs and this is why it is necessary to ask patients to come here, rather than to Mr. Cooter's rooms. It is understandable that many people do not enjoy having photographs taken and we do try to be sensitive to this. The photographs will not include your face. We hope this work will help to improve reconstructions for those who develop breast cancer in the future and would be very grateful for your participation. The study **does not** involve any blood tests or any other invasive procedures.

Please read the enclosed patient information sheet and if you are happy to enrol in the study, sign the consent form. The consent form can be returned in the pre-paid envelope provided. You will then be telephoned to arrange an appointment that is convenient to you. **Please feel free to telephone me on (08) 8222 2072 or (08) 8222 4500** with any questions you may have. Thankyou for your help,

Yours sincerely,

Endorsed,

Dr. Nicola Dean

Mr. Rodney Cooter

Appendix VII
STUDY NO.

DATE

Consent Form

I, _____(PRINT NAME) agree to
take part in a study on nipple-areolar reconstructions and agree to clinical
photographs being taken and used as part of this study.

Signed _____

Date _____

Appendix VIII

Feedback Form

It would be very useful to us to know why you did not want to fully take part in the study. Tick a box that you think applies or fill in the "other"

I did not want to have photographs taken

It was not convenient for me to visit the Royal Adelaide Hospital

I was not happy with the result of reconstruction and did not want to discuss it further

I do not like taking part in research studies in general

I forgot about it

Other

Appendix IX

STUDY NO.

DATE

Aesthetics Questionnaire (Patient)

Imagine looking at yourself in the mirror and try to answer these questions as honestly as possible. **MAKE A MARK ON THE LINE TO INDICATE YOUR ANSWER.**

Here is an **EXAMPLE** of how to fill in the questionnaire:

How do you feel today?

wonderful _____ terrible

This would mean that you don't feel wonderful but you feel more wonderful than terrible.

Q1. How would you rate the symmetry of the breasts in a bra?

very symmetrical _____ not at all symmetrical

Q2. How would you rate the symmetry of the breasts naked?

very symmetrical _____ not at all symmetrical

Q3. How would you rate the appearance of the breasts in a bra?

very good _____ very poor

Q4. How would you rate the appearance of the breasts naked?

very good _____ very poor

Appendix IX (cont.)

Q5. How would you rate the colour of the reconstructed nipple and areola?

very good _____ very poor

Q6. Has the colour of the areola faded with time?

yes, faded a lot _____ no, not faded at all

Q7. How would you rate the projection of the nipple (how much the nipple sticks out)?

ANSWER a) or b) NOT BOTH

a) Does it project (stick out):

far too much _____ just right amount

b) Does it project (stick out):

far too little _____ just right amount

Q8. Has the nipple lost projection over time?

extreme loss of projection _____ no loss of projection at all

Q9. How satisfied were you with the result of the reconstruction of the breast shape (breast mound) just before you had the nipple reconstruction?

very satisfied _____ not at all satisfied

Q10. How satisfied are you now with the final result of the breast reconstruction (including the nipple and areola)?

very satisfied _____ not at all satisfied

Appendix XI


STUDY NO.

DATE

Aesthetics Questionnaire (Partner)

Look at the slides and try to answer these questions as honestly as possible. MAKE A MARK ON THE LINE TO INDICATE YOUR ANSWER.

Here is an EXAMPLE of how to fill in the questionnaire:
How do you feel today?

wonderful  terrible

This would mean that you don't feel wonderful but you feel more wonderful than terrible.

Q1. How would you rate the symmetry of the breasts in a bra?

very symmetrical  not at all symmetrical

Q2. How would you rate the symmetry of the breasts naked?

very symmetrical  not at all symmetrical

Q3. How would you rate the appearance of the breasts in a bra?

very good  very poor

Q4. How would you rate the appearance of the breasts naked?

very good  very poor

Appendix XI (cont.)

Q5. How would you rate the colour of the reconstructed nipple and areola?

very good _____ very poor

Q6. How would you rate the projection of the nipple (how much the nipple sticks out)?

ANSWER a) or b) NOT BOTH

a) Does it project (stick out):

far too much _____ just right amount

b) Does it project (stick out):

far too little _____ just right amount

Appendix XII

PANEL MEMBER

STUDY NO.

DATE

Aesthetics Questionnaire (Panel)

Look at the slides and try to answer these questions as honestly as possible. MAKE A MARK ON THE LINE TO INDICATE YOUR ANSWER.

Here is an EXAMPLE of how to fill in the questionnaire:

How do you feel today?

wonderful  terrible

This would mean that you don't feel wonderful but you feel more wonderful than terrible.

Q1. How would you rate the symmetry of the breasts in a bra?

very symmetrical  not at all symmetrical

Q2. How would you rate the appearance of the breasts in a bra?

very good  very poor

Q3. How would you rate the symmetry of the breasts naked?

very symmetrical  not at all symmetrical

Q4. How would you rate the appearance of the breasts naked?

very good  very poor

Appendix XII (cont.)

Q5. How would you rate the colour of the reconstructed nipple and areola?

very good _____ very poor

Q6. How would you rate the projection of the nipple (how much the nipple sticks out)?
ANSWER a) or b) NOT BOTH

a) Does it project (stick out):

far too much _____ just right amount

b) Does it project (stick out):

far too little _____ just right amount

Q7. What impact has the nipple-areolar reconstruction had on the breast reconstruction as a whole? Has it made it look

much worse _____ much better

Q8. Has the colour of the areola faded with time?

yes, faded a lot _____ no, not faded at all

Appendix XIII

Fitzpatrick Classification of Sunreactive Skin Types(Fitzpatrick 1988)

This classification was originally designed to be used in conjunction with a question to the patient : If you are exposed to the (northern hemisphere) sun for 45 mins to 1 hour in the noon sun how painful is the burn at 24 hours? and How much tan will you have after 1 week? The responses led to the summary of skin type classification shown in the table.

<i>Skin colour unexposed skin</i>	<i>Skin type</i>	<i>Sunburn</i>	<i>Tan</i>	<i>Description</i>
White	I	Yes	No	Always burn, never tan
	II	Yes	Minimal	Usually burn, tan less than average
	III	Yes	Yes	Sometimes mild burn, tan about average
	IV	No	Yes	Rarely burn, tan easily
Brown	V	No	Yes	
Black	VI	No	Yes	

Appendix XIV

Breast Reduction Patients Agreeing to Donate Discard Skin for Research

1. Patient label

2. Age

3. Ever Pregnant?

4. No. of children

5. Ever breastfed?

6. Oral contraceptive pill? (circle one option)

currently

has used but not currently taking

never taken

7. Fitzpatrick skin type (circle one option)

I II III IV V VI

8. Sun exposure of areolae? (e.g. on "sunbed")

yes (if so, approximately when?)

no

Signed _____

Date _____

Appendix XV

<i>UR number in LM study data</i>	<i>Photo</i>	<i>Age</i>	<i>Ever pregnant</i>	<i>No. of children</i>	<i>Ever breast fed</i>	<i>OCP</i>	<i>Fitzpatrick skin type</i>	<i>Sun exposure of areolae</i>
152636	N	28						
153434	N	16						
164512	Y	38	Y	2	Y	U	5	N
164859	Y	15	N	0	N	N	3	N
262689	N	22	Y	1	N	U	2	N
286144	N	46						
404946	N	35						
418012	N	28	Y	0	N	U	3	N
470631	N	23						
488518	Y	35	Y	3	N	U	3	Y
499919	N	23						
570563	N							
574894	N	46	Y	2	Y	U	3	N
585749	N	25						
594443	N	29						
688913	Y	55	Y	2	Y	U	2	N
830567	N	44	Y	2	Y	U	3	N
858056	N	17						
870608	N	35	Y	3	Y	U	3	N
abdo	N							
494034	N							
areola	N							
control	N							
burnside 1	N							

Appendix XVI

Appendix XVII

Masson-Fontana staining for staining breast / areola skin for melanin

Prepare ammonia / silver solution

- add 4g silver nitrate to 40mls of distilled water and mix well.
- add strong ammonia drop by drop until the brown precipitate that initially appears just disappears.
- add 40mls of distilled water.

Prepare slides

- 8 test slides plus an areola control slide are put in the slide holder
- the slide holder must be glass

Rehydrate sections

- slides are dewaxed as follows:-
- histoclear 5mins
- histoclear 5mins
- 100% alcohol 3mins
- 100% alcohol 3mins
- 70% alcohol 3mins
- 50% alcohol 3mins
- DH₂O 3mins

1st half of staining

- Gram's iodine 10mins
- 5% sodium thiosulphate 2mins
- DH₂O 3mins
- DH₂O 3mins
- DH₂O 3mins
- Ammonia silver solution overnight in a covered Coplin jar.

2nd half of staining

- DH₂O 3mins
- DH₂O 3mins
- DH₂O 3mins
- 5% sodium thiosulphate 2mins
- running tap water 2mins
- 1% neutral red 30secs
- DH₂O 2mins
- 100% alcohol 3mins
- 100% alcohol 3mins
- 100% alcohol 3mins

Appendix XVII (cont.)

- histoclear 5mins
- histoclear 5mins

Mounting

- mount coverslips with pix
- leave in fume cupboard 2 hours
- leave in oven overnight

Appendix XVIII

Immunohistochemistry protocol for staining breast / areola skin with mel-5 monoclonal antibody

Prepare antibody

- dilute antibody to 1:20. Make up 400µl of 1:20 Primary antibody (mel-5) in Normal Serum (vial 2). (this is 20µl of mel-5 and 380µl of normal serum). The normal serum blocks any non-specific antigen so that the primary antibody only binds to the specific antigen it is against.

Prepare proteinase K

- mix 1 drop (40microlitres) of proteinase K in 2mls of 0.05M TRIS-HCl pH 7.5 -7.7

Prepare slides

- Slides in each batch should be:-
 - A positive control (areola only) slide
 - A negative control slide (the first of the 8 specimen slides - this slide will receive no antibody)
 - 7 test specimen slides
- Place in glass slide holder

Rehydrate sections

- Dewax
 - histoclear 5 mins
 - histoclear 5 mins
 - 100% alcohol 3 mins
 - 100% alcohol 3 mins
 - 95% alcohol 3 mins
 - 95% alcohol 3 mins
 - DH2O 5 mins
 - DH2O 2 mins
 - DH2O 2 mins
- Circle sections with PAP pen
- PBS buffer 5 mins
- 5% sodium thiosulphate 5mins
- gently running tap water 5mins
- PBS buffer 10 mins

Antigen retrieval (in humidifying chamber)

- treat with protease K
 - 15mins at room temp
- rinse 3x3mins with PBS

Appendix XVIII (cont.)

Streptavidin detection method

STEP 1

- wipe slides around tissue sections
- Add 1-3 drops of 3% Hydrogen peroxide (VIAL 1)
- incubate for 5 mins
- rinse 3 x 3 mins with PBS

STEP 2

- tap off excess buffer from slides and wipe slides carefully around tissue sections.
- add 1 to 3 drops of the 1:20 mel-5 in serum.
- use X63 as -ve control - add to slide no. 8
- incubate in humidity chamber overnight.
- rinse 3 x 3 mins with PBS

STEP 3

- tap off excess buffer from slides and wipe slides carefully around tissue sections.
- add 1-3 drops of linking reagent (VIAL 4) to the sections
- incubate in humidity chamber for 20 mins.
- rinse 3 x 3 mins with PBS

STEP 4

- tap and wipe
- add 1-3 drops of the labelling reagent (VIAL 5)
- incubate in humidifying chamber for 20 mins.(mix chromogen kit while waiting).
 - AEC chromogen kit
 - add 1 drop (50microlitres) of reagent A to 1ml of DH2O
 - mix well
 - add 1 drop of reagent B and 1 drop of reagent C
 - mix well
 - use within 30 mins and keep in dark
- rinse 3 x 3 mins with PBS

STEP 5

- tap and wipe.
- add 1-3 drops of substrate / AEC chromogen solution
- incubate for 5-20 mins.
- WATCH TO OBSERVE DEVELOPMENT OF STAINING
- rinse well with distilled H2O
- flood with distilled H2O
- incubate for 1 min.
- counterstain with haematoxylin for 5 secs
- Rinse with tap water 10 secs

Appendix XVII I (cont.)

- Flood with ammonia water and
- incubate to develop counterstain 30 secs
- rinse gently with tap water

Mounting

- keep mounting medium stored upside down
- apply line of medium along on edge of coverslip
- lower long edge of slide to line of mountant
- gently press
- leave to set overnight at room temperature

PAPERS

Publications

Dean, N. Book Review of Bioengineering of Skin Substitutes, Ed. Lynne Savage,

Primary Intention vol 8 no.1, Feb 2000 p26

Dean, N.R., Brennan, J., Haynes, J., Goddard, C. and Cooter, R.D.

Immunohistochemical labeling of normal melanocytes. *Applied Immunohistochemistry and Molecular Morphology* 2002;10(3):199-204

Dean, N.R., Neild, T., Haynes, J., Goddard, C. and Cooter, R.D.

Fading of nipple-areolar reconstructions - the last hurdle in breast reconstruction?

British Journal of Plastic Surgery,(2002) **55**, 574-581.

Paper in preparation

Dean, N.R., Neild, T., Haynes, J., Goddard, C., Brennan, J. and Cooter, R.D.

The histological basis of pigmentation of human female areolar skin to be submitted to

Journal of Investigative Dermatology

Presentations

Royal Australasian College of Surgeons Annual Scientific Congress, May 2000,

Objective assessment of nipple-areolar colour in patients with complete breast reconstructions.

Surgical Research Society of Australasia Annual Scientific Meeting, September 2000

Nipple-areolar colour in women with complete breast reconstructions - an objective assessment of results.

Royal Australasian College of Surgeons Annual Scientific Congress, May 2002,

Engineering pigmented skin equivalents in a safe environment and their possible role in nipple-areolar reconstructions.

BIBLIOGRAPHY

- Abdel- Malek, Z., Swope, V. B., Suzuki, I., Akcali, C., Harriger, M. D., Boyce, S. T., Urabe, K. and Hearing, V. J. (1995). "Mitogenic and melanogenic stimulation of normal human melanocytes by melanotropic peptides." Proceedings of the National Academy of Sciences of the USA **92**(5): 1789-93.
- Adams, W. M. (1949). "Labial transplant for correction of loss of the nipple." Plastic and Reconstructive Surgery **4**: 295.
- Adema, G. J., de Boer, A. J., van 't Hullenaar, R., Denijn, M., Ruiter, D. J., Vogel, A. M. and Figdor, C. G. (1993). "Melanocyte lineage-specific antigens recognized by monoclonal antibodies NKI-beteb, HMB-50 and HMB-45 are encoded by a single c-DNA." American Journal of Pathology. **143**(6): 1579-1585.
- Alanko, T. and Saksela, O. (2000). "Transforming growth factor beta1 induces apoptosis in normal melanocytes but not in nevus cells grown in type I collagen gel." The Journal of Investigative Dermatology **115**(2): 286-91.
- Andersen, W. K., Labadie, R. R. and Bhawan, J. (1997). "Histopathology of solar lentigines of the face: a quantitative study." Journal of the American Academy of Dermatology **36**(3 Pt 1): 444-7.
- Andreassi, L. (1992). "History of keratinocyte cultivation." Burns **18**(Suppl 1): S2-4.
- Asplund, O. (1983). "Nipple and areola reconstruction - a study in 79 mastectomized women." Scandinavian Journal of Plastic and Reconstructive Surgery **17**: 233-240.
- Asselineau, D. and M. Prunieras (1984). "Reconstruction of simplified skin: control of fabrication." British Journal of Dermatology **111**(Suppl 27): 219-222.
- Auger, F. A., Rhoabhia, M., Goulet, F., Berthod, F., Moulin, V. and Germain, L.

- (1998). "Tissue-engineered human skin substitutes developed from collagen-populated hydrated gels: clinical and fundamental applications." Medical and Biological Engineering and Computing **36**: 801-812.
- Bacharach-Buhles, M., Lubowitzki, M. and Altmeyer, P. (1999). "Dose-dependent shift of apoptotic and unaltered melanocytes into the dermis after irradiation with UVA 1." Archives of Dermatology **198**(1): 5-10.
- Baltaci, V. and Kilic, A. (1998). "A new application for reconstruction of areola with transplantation of cultured autologous melanocytes." Plastic and Reconstructive Surgery **101 no. 4**: 1056-1059.
- Banducci, D. R., Thinh, L. E. and Hughes, K. C. (1999). "Long-term follow-up of a modified Anton-Hartrampf Nipple Reconstruction." Annals of Plastic Surgery **43**(5).
- Barrett, A. W. and Raja, A.M. (1997). "The immunohistochemical identification of human oral mucosal melanocytes." Archives of Oral Biology **42**(1): 77-81.
- Becker, H. (1986). "The use of intradermal tattoo to enhance the final result of nipple-areola reconstruction." Plastic and Reconstructive Surgery **77**(4): 673-675.
- Becker, S. W. (1958). "Historical Background of Research on Pigmentary Diseases of the Skin." The Journal of Investigative Dermatology **32**: 185-196.
- Bell, E. (1981). "Development and use of a living skin equivalent." Plastic and Reconstructive Surgery **67**: 386-392.
- Bell, E., Ehrlich, H. P., Buttle, D. J. and Nakatsuji, T. (1981). "Living tissue formed in vitro and accepted as a full thickness skin equivalent." Science **211**: 1052-1054.
- Bell, E., B Ivarsson, B. and Merrill, C. (1979). "Production of a tissue-like structure by contraction of collagen lattices by human fibroblasts of different proliferative potential in vitro." Proceedings of the National Academy of Science of the USA

76(3): 1274-1278.

- Bell, E., Sher, S., Hull, B., Merrill, C., Rosen, S., Chamson, A., Asselineau, D., Dubertret, L., Coulomb, B., Lapiere, C., Nusgens, B. and Neveux, Y. (1983). "The reconstitution of living skin." The Journal of Investigative Dermatology 81(1): 2s-10s.
- Bessou, S., Pain, C. and Taieb, A. (1997). "Use of human reconstructs in the study of pigment modifiers." Archives of Dermatology 133: 331-336.
- Bhatty, M. A. and Berry, R.B. (1997). "Nipple-areola reconstruction by tattooing and nipple sharing." British Journal of Plastic Surgery 50: 331-334.
- Bhawan, J. (1997). "Mel-5: a novel antibody for differential diagnosis of epidermal pigmented lesions of the skin in paraffin-embedded sections." Melanoma Research 7(1): 43-8.
- Bhawan, J., Andersen, W., Lee, J., Labadie, R. and Solares, G. (1995). "Photoaging versus intrinsic aging: a morphologic assessment of facial skin." Journal of Cutaneous Pathology 22(2): 154-9.
- Bhawan, J., Gonzalez-Serva, A., Nehal, K., Labadie, R., Lufrano, L., Thorne, E. G. and Gilchrist, B. A. (1991). "Effects of tretinoin on photodamaged skin. A histologic study [published erratum appears in Arch Dermatol 1991 Sep;127(9):1382]." Archives of Dermatology 127(5): 666-72.
- Bhawan, J., Olsen, E., Lufrano, L., Thorne, E. G., Schwab, B. and Gilchrist, B. A. (1996). "Histologic evaluation of the long term effects of tretinoin on photodamaged skin." Journal of Dermatological Science 11: 177-182.
- Boissy, R. E., Trinkle, L. S. and Nordlund, J. J. (1989). "Separation of pigmented and albino melanocytes and the concomitant evaluation of endogenous peroxide content using flow cytometry." Cytometry 10: 779-787.

- Boni, R., Burg, G., Doguoglu, A., Ilg, E. C., Schafer, B. W., Muller, B. and Heizmann, C.W. (1997). "Immunohistochemical localization of the Ca²⁺ binding S100 proteins in normal human skin and melanocytic lesions." British Journal of Dermatology **137**(1): 39-43.
- Bosch, G. and Ramirez M. (1984). "Reconstruction of the nipple: a new technique." Plastic and Reconstructive Surgery **73**(6): 977-981.
- Bostwick, J. (1990). Plastic and Reconstructive Breast Surgery. St. Louis, Quality Medical Publishing Inc.
- Bostwick, J. (1999). "Discussion of Nipple Reconstruction with the Double-Opposing Tab Flap." Plastic and Reconstructive Surgery **104**(2): 516-517.
- Boyce, S. T., Foreman, T. J., English, K. B., Stayner, N., Cooper, M. L., Sakabu, S. and Hansborough, J. F. (1991). "Skin wound closure in athymic mice with cultured human cells, biopolymers and growth factors." Surgery **110**(5): 866-876.
- Boyce, S. T., Goretsky, M. J., Greenhalgh, D. G., Kagan, R. J., Rieman, M. T. and Warden, G. D. (1995). "Comparative assessment of cultured skin substitutes and native skin autograft for treatment of full-thickness burns." Annals of Surgery **222**(6): 743-52.
- Boyce, S. T., Greenhalgh, D. G., Kagan, R. J., Housinger, T., Sorrell, J. M., Childress, C. P., Rieman, M. and Warden, G. D. (1993). "Skin anatomy and antigen expression after burn wound closure with composite grafts of cultured skin cells and biopolymers." Plastic and Reconstructive Surgery **91**(4): 632-41.
- Boyce, S. T. and Ham, R. G. (1983). "Calcium-regulated differentiation of normal human epidermal keratinocytes in chemically defined clonal culture and serum-free serial culture." The Journal of Investigative Dermatolgy **81**(1): 33s-40s.
- Boyce, S. T. and Ham R. G. (1985). "Cultivation, frozen storage and clonal growth of

normal human epidermal keratinocytes in serum-free media.” Journal of Tissue Culture Methodology **9**: 83-93.

Boyce, S. T. and J. F. Hansborough (1988). “Biologic attachment, growth and differentiation of human epidermal keratinocytes onto a graftable collagen and chondroitin-6-sulphate substrate.” Surgery **103**(4): 421-431.

Boyce, S. T., Kagan, R. J., Meyer, N. A., Yakuboff, K. P. and Warden, G. D. (1999). “The 1999 clinical research award. Cultured skin substitutes combined with Integra Artificial Skin to replace native skin autograft and allograft for the closure of excised full-thickness burns.” Journal of Burn Care and Rehabilitation **20**(6): 453-61.

Boyce, S. T., Medrano, E. E., Abdel-Malek, Z., Supp, A. P., Dodick, J. M., Nordlund, J. J. and Warden, G. D. (1993). “Pigmentation and inhibition of wound contraction by cultured skin substitutes with adult melanocytes after transplantation to athymic mice.” The Journal of Investigative Dermatology **100**(4): 360-365.

Briggaman, R. A., Abele, D. C., Harris, B. A. and Wheeler, C. E. (1967). “Preparation and characterization of a viable suspension of postembryonic human epidermal cells.” The Journal of Investigative Dermatology **48**: 159-168.

Broadbent, T. R., Woolf, R. M. and Metz, P. S. (1977). “Restoring the mammary areola by a skin graft from the upper inner thigh.” British Journal of Plastic Surgery **30**: 220-222.

Burke, J. F. and Yannas, I.V. (1981). “Successful use of a physiologically acceptable artificial skin in the treatment of extensive burn injury.” Annals of Surgery **194**(4): 413-423.

Castles, I. (1993). Women in Australia. Canberra, Australian Bureau of Statistics: 125-126.

- Cela, I. Leong and Krueger, J. (1991). "Tiglyane-type phorbols stimulate human melanocyte proliferation: potentially safer agents for melanocyte culture." The Journal of Investigative Dermatology **96**(6): 987-990.
- Chiba, H., Kazama, T., Takenouchi, T., Nomoto, S., Yamada, S., Tago, O. and Ito, M. (2000). "Two cases of vulval pigmented extramammary Paget's disease: histochemical and immunohistochemical studies." British Journal of Dermatology **142**(6): 1190-4.
- Chistolini, P., De Angelis, G., De Luca, M., Pellegrini, G. and Ruspantini, I. (1999). "Analysis of the mechanical properties of in vitro reconstructed epidermis: preliminary results." Medical and Biological Engineering and Computing **37**(5): 670-2.
- Clark, W. H., Watson, M.C. , Watson, B.E.M. (1961). "Two kinds of "clear" cells in the human epidermis." American Journal of Pathology **39**: 333-344.
- Cochran, A. J. (1970). "The incidence of melanocytes in normal human skin." The Journal of Investigative Dermatology **55**(1): 65-70.
- Cohen, I. K., Ward, J. A. and Chandrasekhar, B. (1986). "The pinwheel flap nipple and barrier areola graft reconstruction." Plastic and Reconstructive Surgery **77**(6): 995-999.
- Cuono, C. B., Langdon, R., Birchall, N., Barttelbort, S. and McGuire, J. (1987). "Composite autologous-allogeneic skin replacement: development and clinical application." Plastic and Reconstructive Surgery **80**(4): 626-635.
- Davey, R. B., Sprod, R. T. and Neild, T. O. (1999). "Computerised colour: a technique for the assessment of burn scar hypertrophy. A preliminary report." Burns **25**: 207-213.
- Davis, M. E., Boynton, M. W., Ferguson, M. C. and Rothman, S. (1945). "Studies on

pigmentation of endocrine origin." Journal of Clinical Endocrinology **5**: 138-146.

De Luca, M., Albanese, E., Bondanza, S., Megna, M., Ugozzoli, L., Molina, F., Cancedda, R., Santi, P. L., Bormioli, M. and Stella, M. (1989). "Multicentre experience in the treatment of burns with autologous and allogenic cultured epithelium, fresh or preserved in a frozen state." Burns **15**(5): 303-9.

De Luca, M., Bondanza, S., Cancedda, R., Tamisani, A. M., Di Noto, C., Muller, L., Dioguardi, D., Brienza, E., Calvario, A. and Zermani, R. (1992). "Permanent coverage of full skin thickness burns with autologous cultured epidermis and reepithelialization of partial skin thickness lesions induced by allogenic cultured epidermis: a multicentre study in the treatment of children [see comments]." Burns **18**(Suppl 1): S16-9.

De Luca, M. and R. Cancedda (1992). "Culture of human epithelium." Burns **18** (suppl 1): S5-S10.

Dean, C., Forrest, A. P. M. and Chetty, U. (1983). "Effects of immediate breast reconstruction on psychosocial morbidity after mastectomy." The Lancet(February): 459-462.

Donati, L., Magliacani, G., Bormioli, M., Signorini, M. and Preis, F. W. (1992). "Clinical experiences with keratinocyte grafts." Burns **18**(Suppl 1): S19-26.

Drury, R. A. B. and Wallington E. A. (1980). Carleton's Histological Technique. Oxford, Oxford University Press.

Dubertret, L. and Coulomb B. (1994). "La reconstruction de la peau humaine en culture." C.R. Societe de Biologie **188**: 235-244.

Edwards, E. W. and Duntley, S.W. (1939). "The pigments and colour of living human skin." American Journal of Anatomy **65**: 1-33.

- Eisinger, M. (1985). Cultivation of Normal Human Epidermal Keratinocytes and Melanocytes. Methods in Skin Research. D. a. S. Skerrow, C.J. Chichester, New York, Brisbane, Toronto, Singapore, John Wiley and Sons Ltd.: 191-212.
- Eisinger, M. and Marko, O. (1982). "Selective proliferation of normal human melanocytes in vitro in the presence of phorbol ester and cholera toxin." Proceedings of the National Academy of Science of the USA **79**: 2018-2022.
- Eskenazi, L. (1993). "A one-stage nipple reconstruction with the "modified star" flap and immediate tattoo." Plastic and Reconstructive Surgery **92**(4): 671-680.
- Falabella, R. (1997). "Surgical therapies for vitiligo." Clinics in Dermatology **15**(6): 927-39.
- Fitzpatrick, T. B. (1950). "Tyrosinase in human skin: Demonstration of its presence and its role in human melanin formation." Science **112**: 223.
- Fitzpatrick, T. B. (1988). "The validity and practicality of sun-reactive skin types I to VI." Archives of Dermatology **124**(6): 869-71.
- Fitzpatrick, T. B., Hori, Y., Toda, K., Kinebuchi, S. and Szabo, G. (1971). The mechanism of normal human melanin pigmentation and of some pigmentary disorders. Biology of Normal and Abnormal Melanocytes. T. Kawamura, T. Fitzpatrick and M. Seiji. Tokyo, University of Tokyo Press: 369-401.
- Fitzpatrick, T. B., Miyamoto, M. and Ishikawa, K. (1967). "The evolution of concepts of melanin biology." Archives of Dermatology **96**: 305-323.
- Fitzpatrick, T. B. and Szabo G. (1959). "The melanocyte: cytology and cytochemistry." The Journal of Investigative Dermatology **32**: 197-209.
- Franzi, A. T., D'Anna, F., Zicca, A. and Trabucchi, E. (1992). "Histological evaluation of human cultured epithelium before and after grafting [comment]." Burns **18**(Suppl 1): S26-31.

- Frenk, E. and Schellhorn, J. P. (1969). "Morphology of the epidermal melanin unit." Dermatologica **139**(4): 271-277.
- Frisman, D. M. and Taylor, C. T. (1994). Immunohistology of the skin: melanoma, intermediate filament. Immunomicroscopy: A diagnostic tool for the surgical pathologist. C. T. Taylor and R. J. Cote. Philadelphia, W. B. Saunders Company. **19**: 318 - 341.
- Gilchrest, B. A., Vrabel, M. A., Flynn, E. and Szabo, G. (1984). "Selective cultivation of human melanocytes from newborn and adult epidermis." The Journal of Investigative Dermatology **83 no. 5**: 370-376.
- Gordon, P. R., Mansur, C. P. and Gilchrest, B. A. (1989). "Regulation of human melanocyte growth, dendricity and melanization by keratinocyte derived factors." The Journal of Investigative Dermatology **92 no. 4**: 565-572.
- Green, H., Keminde, O. and Thomas, J. (1979). "Growth of cultured human epidermal cells into multiple epithelia suitable for grafting." Proceedings of the National Academy of Science of the USA **76**: 5665-5668.
- Grichnik, J. M., Burch, J. A., Burchette, J. and Shea, C. R. (1998). "The SCF/KIT pathway plays a critical role in the control of normal human melanocyte homeostasis [see comments]." The Journal of Investigative Dermatology **111**(2): 233-8.
- Haake, A. R. and Scott, G. (1991). "Physiologic distribution and differentiation of melanocytes in human fetal and neonatal skin equivalents." The Journal of Investigative Dermatology **96**: 71-77.
- Halaban, R., Ghosh, S. and Baird, A. (1987). "bFGF is the putative natural growth factor for human melanocytes." In Vitro Cellular and Developmental Biology **23**: 47-52.

- Halaban, R., Ghosh, S., Duray, P., Kirkwood, J. M. and Lerner, A. B. (1986). "Human melanocytes cultured from nevi and melanomas." The Journal of Investigative Dermatology **87**(1): 95-101.
- Halaban, R., Langdon, R., Birchall, N., Cuono, C., Baird, A., Scott, G., Moellmann, G. and McGuire, J. (1988). "Basic fibroblast growth factor from human keratinocytes is a natural mitogen for melanocytes." Journal of Cellular Biology **107**: 1611-1619.
- Hanks, C. T. and Chakrabarti, S.G. (1975). "Biochemical and morphological studies of rat submandibular gland: I. Centrifugal fractionation of granule-rich fraction." Journal of Dental Research **54**(5): 938-47.
- Hansborough, J. F., Boyce, S. T., Cooper, M. L. and Foreman, T. J. (1989). "Burn wound closure with cultured autologous keratinocytes and fibroblasts attached to a collagen-glycosaminoglycan substrate." Journal of the American Medical Association **262**(15): 2125-2130.
- Harper, J. R. and Livesey, S.A. (1998). Soft tissue regeneration using an acellular dermal matrix as a natural scaffold. Bioengineering of Skin Substitutes. L. M. Savage. Southborough, International Business Communications Inc.
- Harriger, M. D., Warden, G. D., Greenhalgh, D. G., Kagan, R. J. and Boyce, S. T. (1995). "Pigmentation and microanatomy of skin regenerated from composite grafts of cultured cells and biopolymers applied to full-thickness burn wounds." Transplantation **59**(5): 702-7.
- Hartrampf, C. R. jr. and Culbertson, J. H. (1984). "A dermal-fat flap for nipple reconstruction." Plastic and Reconstructive Surgery **73**(6): 982-986.
- Hartrampf, C. R. jr., Schefflan, M. and Black, P. W. (1982). "Breast reconstruction with a transverse abdominal island flap." Plastic and Reconstructive Surgery **69** no. 2:

216-225.

- Hearing, V. J. and Jimenez, M. (1989). "Analysis of mammalian pigmentation at the molecular level." Pigment Cell Research **2**: 75-85.
- Hennings, H., Michael, D., Cheng, C., Steinert, P., Holbrook, K. and Yuspa, S. H. (1980). "Calcium regulation of growth and differentiation of mouse epidermal cells in culture." Cell **19**: 245-254.
- Henseler, H., Cheong, V., Weiler-Mithoff, E. M., MacKay, I. R. and Webster, M. H. C. (2001). "The use of Munsell colour charts in nipple-areola tattooing." British Journal of Plastic Surgery **54**: 338-340.
- Herlyn, M., Mancianti, M. L., Jambrosic, J., Bolen, J. B. and Koprowski, H. (1988). "Regulatory factors that determine growth and phenotype of normal human melanocytes." Experimental Cell Research **179**: 322-331.
- Higashi, N., Saito, T. (1969) "Horizontal distribution of the Dopa-positive melanocytes in the nail matrix." Journal of Investigative Dermatology **53**: 163-165.
- Hirobe, T., Flynn, E., George, S., Vrabel, M. and Garcia, R. I. (1988). "Growth characteristics of human epidermal melanocytes in pure culture with special reference to genetic differences." Journal of Cellular Physiology **135**: 262-268.
- Holbrook, K. A. and Hennings, H. (1983). "Phenotypic expression of epidermal cells in vitro: a review." The Journal of Investigative Dermatology **81**(no. 1 suppl.): 11s-24s.
- Hugo, N. E., Sultan, M. R. and Hardy, S. P. (1993). "Nipple-areola reconstruction with intradermal tattoo and double-opposing pennant flaps." Annals of Plastic Surgery **30**: 510-513.
- Jabor, M. A., Shayani, P., Collins, D. R., Karas, T. and Cohen, B. E. (2002). "Nipple-Areola Reconstruction: Satisfaction and Clinical Determinants." Plastic and

Reconstructive Surgery **110**(2): 457-463.

Jimbow, K. (1998). "Vitiligo. Therapeutic advances." Dermatologic Clinics **16**(2): 399-407.

Jimbow, K., Fitzpatrick, T. B. and Wick, M. M. (1983). Biochemistry and physiology of melanin pigmentation. Biochemistry and Physiology of the Skin. G. L.A. New York, Oxford, Oxford University Press. **2**: 687-712.

Johansson, O., Liu, P. Y., Bondesson, L., Nordlind, K., Olsson, M. J., Lontz, W., Verhofstad, A., Liang, Y. and Gangi, S. (1998). "A serotonin-like immunoreactivity is present in human cutaneous melanocytes." The Journal of Investigative Dermatology **111**(6): 1010-4.

Jungbluth, A. A., Iversen, K., Coplan, K., Kolb, D., Stockert, E., Chen, Y. T., Old, L. J. and Busam, K. (2000). "T311--an anti-tyrosinase monoclonal antibody for the detection of melanocytic lesions in paraffin embedded tissues." Pathology, Research & Practice **196**(4): 235-42.

Karasek, M. (1966). "In vitro culture of human skin epithelial cells." The Journal of Investigative Dermatology **47**: 533-540.

Kippenberger, S., Bernd, A., Bereiter-Hahn, J., Ramirez-Bosca, A. and Kaufmann, R. (1997). "Melanocytes in vitro: How do they undergo mitosis?" Pigment Cell Research **10**: 85-87.

Klausner, M., Neal, P., Breyfogle, B., Kubilus, J. and Ashland, M. (2001). "Improvements to MelanodermTM, an epidermal model containing functional melanocytes for skin lightening studies." The Journal of Investigative Dermatology **117**(2): 513.

Kohler, G. and C. Milstein (1975). "Continuous cultures of fused cells secreting antibody of predefined specificity." Nature **256**(August 7): 495-497.

- Kore-eda, S., Horiguchi, Y., Ueda, M., Toda, K. and Imamura, S. (1998). "Basal cell carcinoma cells resemble follicular matrix cells rather than follicular bulge cells: immunohistochemical and ultrastructural comparative studies." American Journal of Dermatopathology **20**(4): 362-9.
- Krasagakis, K., Garbe, C., Kruger, S. and Orfanos, C. E. (1991). "Effects of interferons on cultured human melanocytes in vitro: interferon-beta but not -alpha or -gamma inhibit proliferation and all interferons significantly modulate the cell phenotype." The Journal of Investigative Dermatology **97**(2): 364-372.
- Krasagakis, K., Garbe, C., Kruger-Krasagakes, S. and Orfanos, C. E. (1993). "12-O-Tetradecanoylphorbol-13-acetate not only modulates proliferation rates but also alters antigen expression and LAK-cell susceptibility of normal human melanocytes in vitro." The Journal of Investigative Dermatology **100**(5): 653-659.
- Kroll, S. S. and Hamilton, S. (1989). "Nipple reconstruction with the double-opposing tab flap." Plastic and Reconstructive Surgery **84**: 520.
- Kroll, S. S., Reece, G., Miller, M. J., Evans, G. R. D., Robb, G. L., Baldwin, B. J. and Wang, B.-g. (1997). "Comparison of nipple projection with the modified double opposing tab and star flaps." Plastic and Reconstructive Surgery **99**: 1602-1605.
- Kuhn, U., Terunuma, A., Pfutzner, W., Foster, R. A. and Vogel, J. C. (2002). "In vivo assessment of gene delivery to keratinocytes by lentiviral vectors." Journal of Virology **76**(3): 1496-504.
- Lacour, J. P., Dubois, D., Pisani, A. and Ortonne, J. P. (1991). "Anatomical mapping of Merkel cells in normal human adult epidermis." British Journal of Dermatology **125**: 535-542.
- Lane, H., O'Loughlin, S., Powell, F., Magee, H. and Dervan, P. A. (1993). "A

- quantitative immunohistochemical evaluation of lentigo maligna and pigmented solar keratosis." American Journal of Clinical Pathology **100**(6): 681-5.
- Lerner, A. B. and J. D. Case J. D. (1959). "Pigment Cell Regulatory Factors." The Journal of Investigative Dermatology **32**: 211-221.
- Lerner, A. B., Halaban, R., Klaus, S. N. and Moellmann, G. E. (1987). "Transplantation of human melanocytes." The Journal of Investigative Dermatology **89**(3): 219-224.
- Little, J. W. I. (1984). "Nipple-areola reconstruction." Clinics in Plastic Surgery **11 no. 2**: 351-364.
- Little, J. W. I., Munasifi, T. and McCulloch, D. T. (1983). "One-stage reconstruction of a projecting nipple: the quadrapod flap." Plastic and Reconstructive Surgery **71**(1): 126-133.
- Little, J. W. I. and Spear, S. L. (1988). "The finishing touches in nipple-areolar reconstruction." Perspectives in Plastic Surgery **2 no. 1**: 1-22.
- Maguire, G. P., Lee, E. G., Bevington, D. J., Kuchemann, C. S., Crabtree, R. J. and Cornell, C. E. (1978). "Psychiatric problems in the first year after mastectomy." British Medical Journal **15th April**: 963- 965.
- Mahrle, G., Bolling, R., Osborn, M. and Weber, K. (1983). "Intermediate filaments of the vimentin and prekeratin type in human epidermis." The Journal of Investigative Dermatology **81**(1): 46-8.
- Matsumoto, K., Tajima, H. and Nakamura, T. (1991). "Hepatocyte growth factor is a potent stimulator of human melanocyte DNA synthesis and growth." Biochemical and Biophysical Research Communications **176**(1): 45-51.
- McLeod, S. (1994). Hormonal Modulation of Human Melanogenesis, PhD thesis Department of Physiology. Sydney, University of Sydney.

- McLeod, S. and Mason, R. (1995). "Isolation of enriched human melanocyte cultures from fetal, newborn and adult skin." Methods in Cell Science **17**: 187 - 193.
- McLeod, S. D., Ranson, M. and Mason, R. S. (1994). "Effects of estrogens on human melanocytes in vitro." Journal of Steroid Biochemistry & Molecular Biology **49**(1): 9-14.
- Medalie, D. A., Eming, S. A., Collins, M. E., Tompkins, R. G., Yarmush, M. L. and Morgan, J. R. (1997). "Differences in dermal analogs influence subsequent pigmentation, epidermal differentiation, basement membrane and rete ridge formation of transplanted composite skin grafts." Transplantation **64**(3): 454-465.
- Medalie, D. A., Tompkins, R. G. and Morgan, J. R. (1996). "Evaluation of acellular human dermis as a dermal analog in a composite skin graft." ASAIO Journal **42**(5): M455-62.
- Medalie, D. A., R. G. Tompkins, et al. (1998). "Characterization of a composite tissue model that supports clonal growth of human melanocytes in vitro and in vivo." The Journal of Investigative Dermatology **111**(5): 810-6.
- Medrano, E. E. and Nordlund, J. J. (1990). "Successful culture of adult human melanocytes obtained from normal and vitiligo donors." The Journal of Investigative Dermatology **95**(4): 441-445.
- Meier, F., Nesbit, M., Hsu, M. Y., Martin, B., Van Belle, P., Elder, D. E., Schaumburg-Lever, G., Garbe, C., Walz, T. M., Donatien, P., Crombleholme, T. M. and Herlyn, M. (2000). "Human melanoma progression in skin reconstructs : biological significance of bFGF." American Journal of Pathology **156**(1): 193-200.

- Meredith, P. (1996). But was the operation worth it? The limitations of quality of life and patient satisfaction research in health-care outcome assessment Journal of Quality of Clinical Practice **16**(2):75-85
- Millard, D. R. J. (1972). "Nipple and areolar reconstruction by split graft from the normal side." Plastic and Reconstructive Surgery **50**(4): 350-353.
- Milstone, L. M. (1983). "Population dynamics in cultures of stratified squamous epithelia." The Journal of Investigative Dermatology. **81**(no. 1 suppl.): 69s-74s.
- Mishima, Y. (1965). "Macromolecular changes in pigmentary disorders." Archives of Dermatology. **91**: 519-557.
- Mishima, Y. and Widlan, S. (1967). "Enzymatically active and inactive melanocyte populations and UV irradiation: combined dopa pre-melanin reactions and electron microscopy." The Journal of Investigative Dermatology **49**: 273-281.
- Montagna, W. (1970). "Histology and cytochemistry of human skin XXXV. The nipple and areola." British Journal of Dermatology **83 jubilee issue 2**: 2-13.
- Montagna, W. and Parakkal, P. F. (1974). The Structure and Function of Skin. New York and London, Academic Press.
- Montagna, W. and Yun, J. S. (1972). "The Glands of Montgomery." British Journal of Dermatology **86**: 126-133.
- Moore, B. W. (1965). "A soluble protein characteristic of the nervous system." Biochemical and Biophysical Research Communications **19**: 739-44.
- Munster, A. M., Weiner, S. H. and Spence, R. J. (1990). "Cultured epidermis for the coverage of massive burn wounds." Annals of Surgery **211**: 676-680.
- Nakazawa, K., Kalassy, M., Sahuc, F., Collombel, C. and Damour, O. (1998). "Pigmented human skin equivalent - as a model of the mechanisms of control of cell - cell and cell- matrix interactions." Medical and Biological Engineering and

Computing **36**: 813-820.

Nakazawa, K., Nakazawa, H., Sahuc, F., Lepavec, A., Collombel, C. and Damour, O.

(1997). "Pigmented human skin equivalent: new method of reconstitution by grafting an epithelial sheet onto a non-contractile dermal equivalent." Pigment Cell Research **10**(6): 382-90.

Nemecek, G. M. and Dayan, A. D. (1999). "Safety evaluation of human living skin

equivalents." Toxicologic Pathology **27**(1): 101-3.

Nielsen, H. I. and Don, P. (1984). "Culture of normal adult human melanocytes."

British Journal of Dermatology **110**: 569-580.

O'Connor, N. E., Mulliken, J. B., Banks-Schlegel, S., Kehinde, O. and Green, H.

(1981). "Grafting of burns with cultured epithelium from autologous epidermal cells." Lancet **1**(8211): 75-81.

Olsson, M. J. and Juhlin, L. (1993). "Repigmentation of vitiligo by transplantation of

cultured autologous melanocytes." Acta Dermatologica Venereologica **73**: 49-51.

Olsson, M. J. and Juhlin, L. (1998). "Leucoderma treated by transplantation of a basal

cell layer enriched suspension." British Journal of Dermatology **138**: 644-648.

Papachristou, D. N., Kinne, D., Ashikari, R. and Fortner, J. G. (1979). "Melanoma of

the nipple and areola." British Journal of Surgery **66**: 287-288.

Pellegrini, G., Bondanza, S., Guerra, L. and De Luca, M. (1998). "Cultivation of human

keratinocyte stem cells: current and future clinical applications." Medical and Biological Engineering and Computing **36**: 778-790.

Perrin, C., Michiels, J. F., Pisani, A. and Ortonne, J. P. (1997). "Anatomic distribution

of melanocytes in normal nail unit: an immunohistochemical investigation."

American Journal of Dermatopathology **19**(5): 462-7.

- Pittelkow, M. R. and G. D. Shipley (1989). "Serum-free culture of normal human melanocytes: growth kinetics and growth factor requirements." Journal of Cellular Physiology **140**: 565-576.
- Prunieras, M., Regnier, M. and Woodley, D. (1983). "Methods for cultivation of keratinocytes at an air-liquid interface." The Journal of Investigative Dermatology **81**(Suppl): 28s-33s.
- Puches, R., Smolle, J., Rieger, E., Soyer, H. P. and Kerl, H. (1991). "Expression of cytoskeletal components in melanocytic skin lesions. An immunohistochemical study." American Journal of Dermatopathology **13**(2): 137-44.
- Ranson, M., Posen, S. and Mason, R. S. (1988). "Human melanocytes as a target tissue for hormones: in vitro studies with 1 alpha-25, dihydroxyvitamin D3, alpha-melanocyte stimulating hormone, and beta-estradiol." The Journal of Investigative Dermatology **91**(6): 593-8.
- Regnier, M., Patwardhan, A., Scheynius, A. and Schmidt, R. (1998). "Reconstructed human epidermis composed of keratinocytes, melanocytes and Langerhans cells." Medical and Biological Engineering and Computing **36**: 821-824.
- Regnier, M., Pautrat, G., Pauly, G. and Prunieras, M. (1984). "Natural substrates for the reconstruction of skin in vitro." British Journal of Dermatology **111**(Suppl 27): 223-4.
- Rheinwald, J. G. and Green, H. (1975). "Serial cultivation of strains of human epidermal keratinocytes: the formation of keratinizing colonies from single cells." Cell **6**: 331-344.
- Rue, L. W., Cioffi, W. G., McManus, W. F. and Pruitt, B. A. (1993). "Wound closure and outcome in extensively burned patients treated with cultured autologous keratinocytes." Journal of Trauma **34**: 662-668.

- Schafer, B. and Heizmann, C. (1996). "The S100 family of EF-hand calcium-binding proteins: functions and pathology." Trends in Biochemical Sciences **21**: 134-40.
- Seiberg, M., Paine, C., Sharlow, E., Andrade-Gordon, P., Costanzo, M., Eisinger, M. and Shapiro, S. S. (2000). "The protease-activated receptor 2 regulates pigmentation via keratinocyte-melanocyte interactions." Experimental Cell Research **254**(1): 25-32.
- Sheridan, R. L. and Tompkins, R. G. (1995). "Cultured autologous epithelium in patients with burns of ninety percent or more of the body surface." Journal of Trauma: Injury, Infection and Critical Care **38 no. 1**: 48-50.
- Shoji, T., Park, H.-Y., Jalbert, N., Bhawan, J. and Byers, H. R. (1998). "In situ and in vitro expression of protein kinase C alpha in human melanocytes." Pigment Cell Research **11**: 18-23.
- Si, S. P., Tsou, H. C., Lee, X. and Peacocke, M. (1993). "Cultured human melanocytes express the intermediate filament vimentin." The Journal of Investigative Dermatology **101**(3): 383-6.
- Simon, G. (1840). "Ueber die Struktur der Warzen und ueber Pimentbildung in der Haut." Archiv fur Anatomie Physiologie und Wissenschaftliche Medicin: 169-184.
- Smith, D. M., Peters, T. G. and Donegan, W. L. (1982). "Montgomery's Areolar Tubercle." Archives of Pathology and Laboratory Medicine **106**: 60-63.
- Smith, J. W. and R. Nelson (1986). "Construction of the nipple with a mushroom-shaped pedicle." Plastic and Reconstructive Surgery **78 no. 5**: 684-687.
- Smoller, B. R., Hsu, A. and Krueger, J. (1991). "HMB-45 monoclonal antibody recognizes an inducible and reversible melanocyte cytoplasmic protein." Journal of Cutaneous Pathology **18**(5): 315-22.
- Snyder, C. C., Browne, E. Z. j. and Pickens, J. E. (1976). Reconstructive problems of

the nipple and areola. Plastic and reconstructive surgery of the breast. R. M. Goldwyn. Boston, Little, Brown and Company: 411-427.

Snyderman, R. and Guthrie, R. (1971). "Reconstruction of the female breast following radical mastectomy." Plastic and Reconstructive Surgery **47**: 565.

Spear, S. L. and Arias, J. (1995). "Long-term experience with nipple-areolar tattooing." Annals of Plastic Surgery **35**: 232-236.

Spear, S. L., Convit, R. and Little, J. W. I. (1989). "Intradermal tattoo as an adjunct to nipple-areola reconstruction." Plastic and Reconstructive Surgery **83**(5): 907-911.

Staricco, R. J. and Pinkus, H. (1957). "Quantitative and qualitative data on the pigment cells of the adult human epidermis." The Journal of Investigative Dermatology **28**: 33-45.

Stoner, M. L. and Wood, F.M. (2000). "The treatment of hypopigmented lesions with cultured epithelial autograft." Journal of Burn Care and Rehabilitation **21**(1): 50-54.

Swope, V. B., Medrano, E. E., Smalara, D. and Abdel-Malek, Z. A. (1995). "Long-term proliferation of human melanocytes is supported by the physiologic mitogens α -melanotropin, endothelin-1 and basic fibroblast growth factor." Experimental Cell Research **217 no. 2**: 453-459.

Swope, V. B., Supp, A. P., Cornelius, J. R., Babcock, G. F. and Boyce, S. T. (1997). "Regulation of pigmentation in cultured skin substitutes by cytometric sorting of melanocytes and keratinocytes." The Journal of Investigative Dermatology **109 no. 3**: 289-295.

Tadokoro, T., Itami, S., Hosokawa, K., Terashi, H. and Takayasu, S. (1997). "Human genital melanocytes as androgen target cells." The Journal of Investigative

Dermatology **109**(4): 513-7.

- Tanabe, H. Y., Tai, Y., Kiyokawa, K. and Yamauchi, T. (1997). "Nipple-areola reconstruction with a dermal-fat flap and rolled auricular cartilage." Plastic and Reconstructive Surgery **100**(2): 431-438.
- Taylor, C. T. (1994). Principles of Immunomicroscopy. Immunomicroscopy : a diagnostic tool for the surgical pathologist. C. T. Taylor. Philadelphia, W.B. Saunders Company. **19**.
- Tenchini, M. L., Ranzati, C. and Malcovati, M (1992). "Culture techniques for human keratinocytes [see comments]." Burns **18**(Suppl 1): S11-6.
- Thompson, T., Mattes, M., Roux, L., Old, L. and Lloyd, K. O. (1985). "Pigmentation-associated glycoprotein of human melanomas and melanocytes: Definition with a Mouse monoclonal antibody." The Journal of Investigative Dermatology **85**: 169-174.
- Topol, B. M., Haimes, H. B., Dubertret, L. and Bell, E. (1986). "Transfer of melanosomes in a skin equivalent model in vitro." The Journal of Investigative Dermatology **87**: 642-647.
- Vecchione, T. R. (1986). "Reconstruction and / or salvage of nipple projection." Plastic and Reconstructive Surgery **78**(5): 679-683.
- Vennegoor, C., Hageman, P., Van Nouhuijs, H., Ruiter, D. J., Calafat, J., Ringens, P. J. and Rumke, P. (1988). "A monoclonal antibody specific for cells of the melanocytes lineage." American Journal of Pathology **130**(1): 179-192.
- Verrando, P. and Ortonne, J. P. (1984). "Insulin receptors in cultured human keratinocytes." British Journal of Dermatology **111**(Suppl 27): 232-4.
- Weiss, J., Herman, O., Rosenberg, L. and Shafir, R. (1989). "The S nipple-areola reconstruction." Plastic and Reconstructive Surgery **83**(5): 904-906.

- Wellisch, D. K., Schain, W. S., Noone, R. B. and Little, J. W. I. (1987). "The psychological contribution of nipple addition in breast reconstruction." Plastic and Reconstructive Surgery **80**(5): 699-704.
- Woodley, D. T., Peterson, H. D., Herzog, S. R., Stricklin, G. P., Burgeson, R. E., Briggaman, R. A., Cronce, D. C. and O'Keefe, E. J. (1988). "Burn wounds resurfaced by cultured epidermal autografts show abnormal reconstitution of anchoring fibrils." Journal of the American Medical Association **259**(17): 2566-2571.
- Yaar, M. and Gilchrest, B. A. (1991). "Human melanocytes growth and differentiation: a decade of new data." The Journal of Investigative Dermatology **97**: 611-617.
- Yamamoto, O. and Bhawan, J. (1994). "Three modes of melanosome transfers in caucasian facial skin: hypothesis based on an ultrastructural study." Pigment Cell Research **7**(158-169): 158-169.
- Yannas, I. V. (1984). "What criteria should be used for designing artificial skin replacements and how well do the current grafting materials meet these criteria?" Journal of Trauma-Injury Infection and Critical Care **24**(9 Suppl): S29-39.
- Yannas, I. V. and Burke, J. F. (1980). "Design of an artificial skin . I. Basic design principles." Journal of Biomedical Material Research **14**: 65-81.
- Zelickson, A. S. (1967). Melanocyte, melanin granule and Langerhan's cell. Ultrastructure of Normal and Abnormal Skin. A. S. Zelickson. Philadelphia, Lea and Febiger.

Dean, N.R., Brennan, J., Haynes, J., Goddard, C. & Cooter, R.D. (2002) Immunohistochemical labeling of normal melanocytes.
Applied Immunohistochemistry and Molecular Morphology, v. 10(3), pp. 199-204

NOTE:

This publication is included on pages 255-257 in the print copy of the thesis held in the University of Adelaide Library.

Dean, N.R., Neild, T., Haynes, J., Goddard, C. & Cooter, R.D. (2002) Fading of nipple-reconstructions: the last hurdle in breast reconstruction?
British Journal of Plastic Surgery, v. 55(7), pp. 574-581

NOTE:

This publication is included on pages 258-265 in the print copy of the thesis held in the University of Adelaide Library.

It is also available online to authorised users at:

<http://doi.org/10.1054/bjps.2002.3920>