

## **Chapter 5 - RESEARCH UNDERTAKEN - ARTHROSCOPY**

### **5.1 Introduction**

This section provides a review of the research undertaken on the arthroscopy of the wrist. It includes six papers published on the following topics: Kienböck's disease, distal radius fractures, STT joint arthritis, contracture of the wrist, intra-osseous ganglion of the lunate, and ulnocarpal stylo-carpal impaction.

### **5.2 Arthroscopic assessment and classification of Kienböck's disease**

#### 5.2.1 Research aims

The aim was to safely and effectively advance the diagnostic techniques of wrist arthroscopy in the management of Kienböck's disease.

#### 5.2.2 Research objectives

1. To document the arthroscopic changes in Kienböck's disease.
2. To develop an arthroscopic classification system based on the spectrum of arthroscopic observations in patients with Kienböck's disease.
3. To make recommendations for subsequent treatment based on arthroscopic findings (i.e. secondary procedure).
4. To determine the correlation between the radiological findings and arthroscopic findings in patients with Kienböck's disease.
5. To determine if the procedure is safe, based on review of complications.

#### 5.2.3 Principles of study methodology

Patients were provided with non-operative treatment including wrist splints, non-steroidal inflammatory medications and advised regarding modification of activities.

A prospective assessment of arthroscopic findings of the wrist was established prior to performing any arthroscopy (Appendix 4.2). A prospective database of operative procedures was reviewed to identify those patients who had undergone wrist arthroscopy with a diagnosis of Kienböck's disease.

The medical records of the 18 patients identified were reviewed. The findings in the various anatomical zones were assessed. These findings were reviewed to determine;

Arthroscopic changes in Kienböck's disease.

If an arthroscopic classification system based on the spectrum of arthroscopic observations could be formulated.

Determine recommendations for subsequent treatment based on arthroscopic findings.

The correlation between the radiological findings and arthroscopic findings in patients with Kienböck's disease.

Assessment of complications.

#### 5.2.4 Main findings of the published research

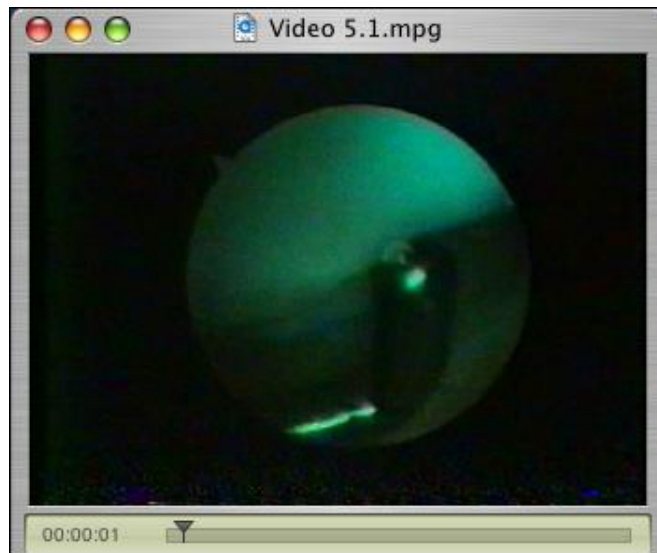
##### Arthroscopic observations

A spectrum of pathology was identified ranging from synovitis only to degenerative changes throughout the entire wrist. The articular changes did vary but tended to have any one of a number of characteristic patterns. The changes were placed into a sequential order based on severity. Following this a classification of the articular changes could be identified.

It was noted that the lunate responded to the avascular necrosis in one of two ways. It either:

- a) Collapsed with subchondral sclerosis and fragmentation, which was usually localised to the proximal pole. The secondary degenerative changes that occur are to the distal articular surface of the radius or
- b) fractured in a coronal plane that extended from the proximal to the distal articular surface.

It is unusual to have involvement of the distal articular surface of the lunate, except if a coronal fracture extends through to the surface, or in late cases (Video 5.1).



**Video 5.1** - Kienböck disease: Wrist arthroscopy view of the left wrist with a soft floating proximal pole of the lunate with adjacent synovitis. Full thickness cartilage defect of the lunate facet.

No complications occurred in this group of patients.

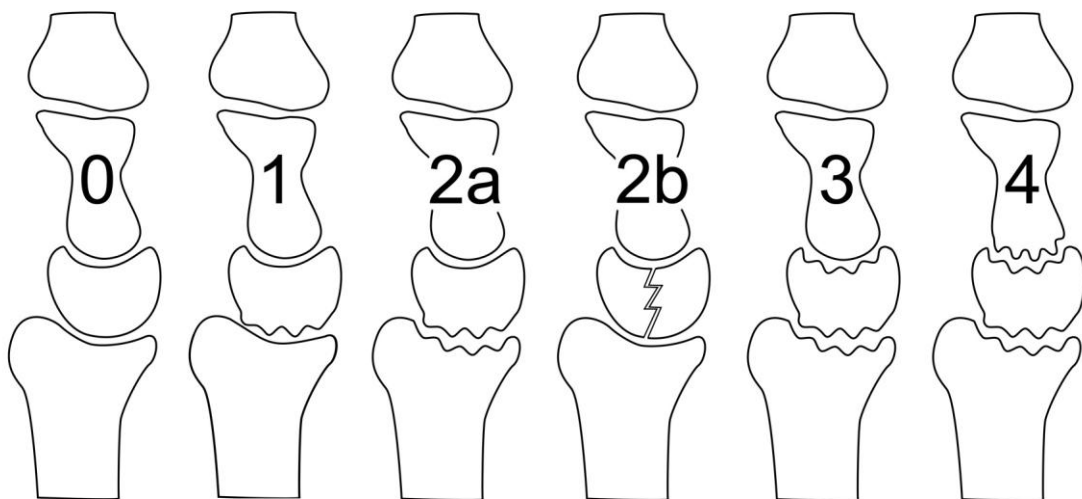
#### Arthroscopic classification

With regard to the definitions of what constituted a functional articular surface, the author defined a normal articular surface as having a normal glistening appearance or minor fibrillation and normal hard subchondral bone on palpation. A non-functional articular surface was defined as having any one of the following: extensive fibrillation, fissuring, localised or extensive articular loss, a floating articular surface, or fracture. Although this was an arbitrary decision, it was based on what could be expected to provide a functional articulation. The amount or type of the synovitis was not used to specifically grade the type of wrist, but it is usually an indication of the severity of the chondral changes.

The grade allocated for each wrist is dependent upon the number of articular surfaces that are defined as non functional.

## Kienböck's disease recommendations

The classification developed (Figure 5.1) takes into account the arthroscopic observations and relates them to the subsequent reconstructive surgical options. A patient with a Grade 0 disorder could be managed with an extra-articular procedure such as joint levelling or a revascularization of the lunate. Grade 1 or 2a can be managed with a radio-scapho-lunate fusion. Grade 1 or 2b can be managed with a proximal row carpectomy. Grade 3 and Grade 4 require salvage procedures such as wrist arthrodesis or arthroplasty. Theoretically a grade 3 patient could be managed with a proximal hemiarthroplasty - when they become available!



**Figure 5.1** –Arthroscopic classification of articular changes of Kienböck's disease.

Grade 0 All articular surfaces functional but may have synovitis.

Grade 1 Non-functional articular surface in the proximal lunate.

Grade 2 A non-functional articular surface of the proximal lunate and lunate facet.

Grade 2b Non-functional proximal and distal lunate.

Grade 3 Non-functional proximal and distal articular surfaces of the lunate and lunate facets of the radius.

Grade 4. All four surfaces are non-functional.

From - Bain and Begg, 2006.

Other non-arthroscopic factors need to be considered. These include the presence of a negative ulnar variance that would direct surgery more to a joint levelling procedure.

Also, the shape of the capitulum is important in some patients. Those with a proximal pointed articular surface are unlikely to obtain a good result with just a proximal row carpectomy. Therefore these factors also need to be taken into account when determining the best surgical reconstructive option.

#### Arthroscopy v radiographs

An important observation was that it was not uncommon for plain radiographs to underscore the severity of the articular involvement identified at arthroscopy. I hoped to provide a correlation of the radiological versus arthroscopic findings, but many of the radiographs had unfortunately been destroyed, which meant that meaningful statistical correlations could not be performed due to insufficient numbers.

The disparity between x-ray assessment and arthroscopic assessment has since been presented by Ribak, who reported that plain radiographs were poorly correlated with arthroscopic findings (Ribak, 2007). This was our experience, but due to insufficient numbers it could not be proved in a scientific model.

#### Complications

No specific complications related to the arthroscopic assessment were observed.

### **5.3 Anatomical reduction of intra-articular fractures of the distal radius**

#### 5.3.1 Research aims

The aim was to develop a safe and efficient therapeutic technique of wrist arthroscopy for the management of distal radius fractures. To aim at an anatomical reduction of the articular surface using minimally invasive techniques.

#### 5.3.2 Research objectives

1. To develop therapeutics of wrist arthroscopy technique for the management of distal radius fractures.
2. To document the arthroscopic findings at the time of surgery.
3. To document patient outcomes using subjective, objective and radiological measures.
4. To document intra-operative and post-operative complications.
5. To determine the efficiency of the arthroscopic procedure based on documented arthroscopic findings and patient-related outcome measures.
6. To determine the safety of the procedure, based on review of complications.
7. To make recommendations for subsequent treatment based on the determined safety and efficiency of the operative procedure.

#### 5.3.3 Principles of study methodology

##### Population

A consecutive series of 31 patients with intra-articular distal radial fractures, managed with arthroscopically assisted reduction performed by the author between 1994 and 1996, was reviewed.

##### Operative technique

Wrist arthroscopy was performed under general anaesthesia with a 2.7mm 30° angle arthroscope using a standard technique via the 3-4, 6R, ulnar and radial mid-carpal portals.

The haematoma was evacuated from the joint using lavage and a motorised resector. Arthroscopy was used to assess the fracture and soft tissue injuries.

Following distraction and closed reduction, fluoroscopy invariably demonstrated an intra-articular step. Despite this, the degree of joint incongruity demonstrated at arthroscopy was surprising. It was not uncommon to find that the fragments were tilted in the sagittal plane, but this was not appreciated on the lateral fluoroscopy because of the overlap of the ulnar, scaphoid and lunate fossae.

#### Reduction of the fracture

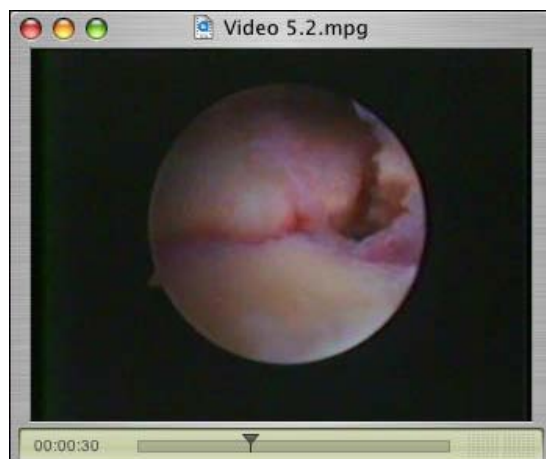The fracture was reduced using a five-level algorithm:

-1st order technique: Traction and closed manipulation. Arthroscopy demonstrated that articular reduction was not achieved by these techniques alone.

-2nd order technique: Percutaneous K-wire (Kirschner) manipulation. The Kapandji (intra-focal) technique with K-wires placed into the fracture, under fluoroscopy. These K-wires elevate, reduce and buttress the distal fragment (Kapandji, 1995). K-wires driven into larger fragment's such as the radial styloid act as joysticks. In both of these techniques the K-wires are positioned under fluoroscopy, and then manipulated as the distal radius articular surface is arthroscopically assessed (Figure 5.2, Video 5.2). The wires are advanced once anatomical reduction is obtained.

NOTE: This figure is included on page 101 of the print copy of the thesis held in the University of Adelaide Library.

**Figure 5.2** –The intra-articular fragments can be manipulated by 1) the arthroscopic probe, 2) K-wires introduced into the fragment and 3) intra-focal wires used to buttress the fragment. From – Mehta et al., 2000.



**Video 5.2** – Wrist arthroscopy demonstrating a distal radius fracture. The radiocarpal joint is lavaged and a motorised resector is used to debride the clot and synovitis from the joint. The articular fragments are manipulated with the arthroscopic probe. In the background, the radial styloid can be seen to be manipulated with a pre-placed K-wire. Once an anatomic articular reduction is obtained, the 1.6mm K-wire is advanced into the cortex on the ulnar aspect of the metaphyseal radius. Further K-wires are used to stabilise the distal radius.



The “London technique” was used in comminuted intra-articular fractures (Bain et al., 1997) (Figure 5.3). K-wires are advanced through the distal ulna into the subchondral distal radius and withdrawn from the radial aspect so that they do not encroach on the distal radio-ulnar joint. For the impacted fracture, placement of two K-wires (with fluoroscopic guidance) beneath the fragment to manipulate it free is usually successful.

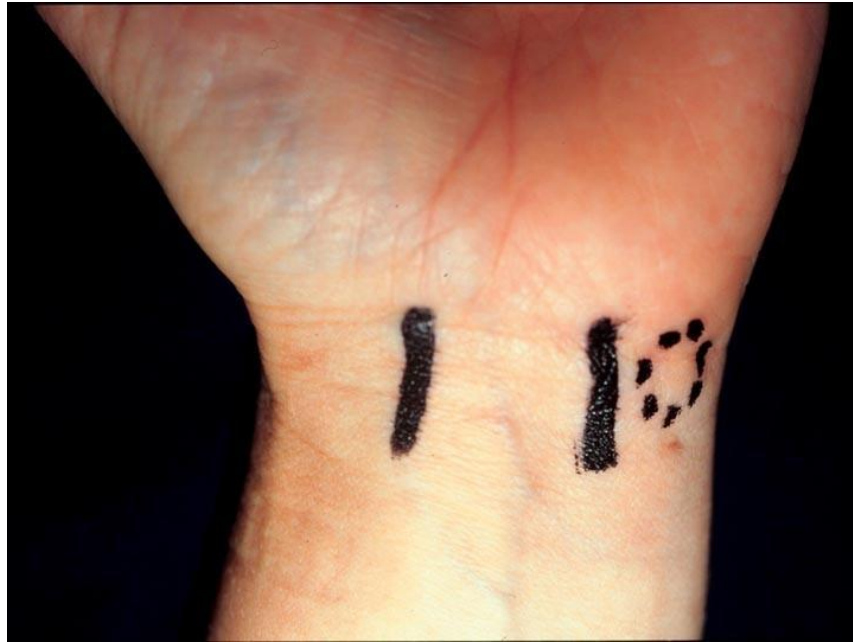NOTE: This figure is included on page 102 of the print copy of the thesis held in the University of Adelaide Library.

**Figure 5.3** – London Technique. The articular surface is reduced, under arthroscopic vision, with “joysticks” and the arthroscopic probe. K-wires are advanced through the distal ulnar and into the subchondral level of the distal radius. The wires are removed from the radial side of the radius. From – Mehta et al., 2000.

-3rd order technique: Arthroscopic manipulation. An arthroscopic probe can be used to manipulate bony fragments. The lunate facet was difficult to stabilise. The author developed a technique of advancing a K-wire into the joint and through the articular surface of the sigmoid notch (following debridement of the torn TFC) and withdrawn from the radial side of the wrist until it is not visible from the joint. The advantage of this technique was that the wire could be directly placed into the fragment under arthroscopic vision. The wire could be manipulated and then advanced to stabilise the fragment.

-4th order technique: Limited open techniques. These techniques are required if the percutaneous techniques are not successful or are potentially unsafe. For patients with volar displaced fractures, percutaneous reduction and fixation techniques were often not adequate. Therefore the author developed the technique of mini-open volar approaches (Figure 5.4). This was through the floor of the flexor carpi radialis sheath and the between the long finger flexor tendons and the flexor carpi ulnaris tendon. They represented mini versions of the open Henry's approach and volar ulnar approach respectively (Henry, 1957; Pourgiezis et al., 1999).

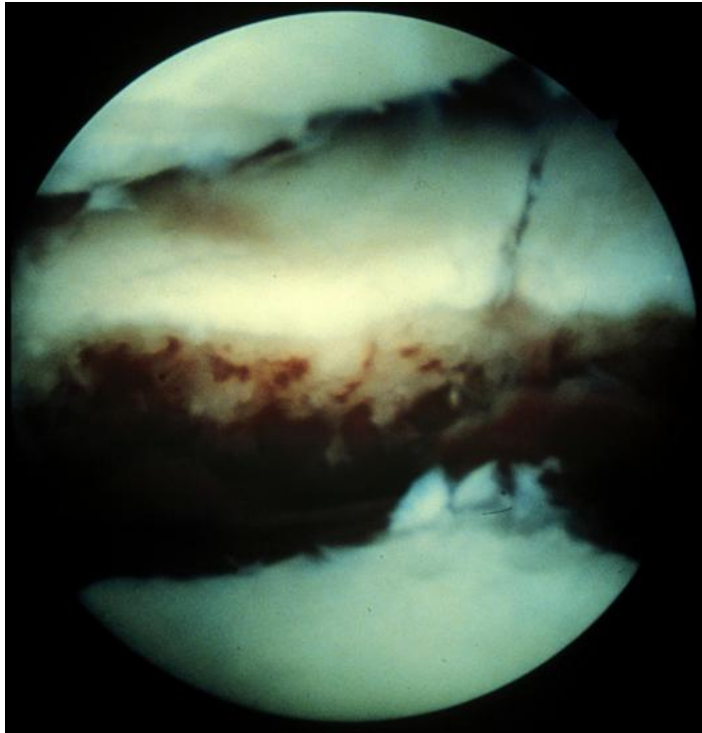
-5th order technique: Open techniques. If all of the above techniques prove futile then an open reduction is performed.



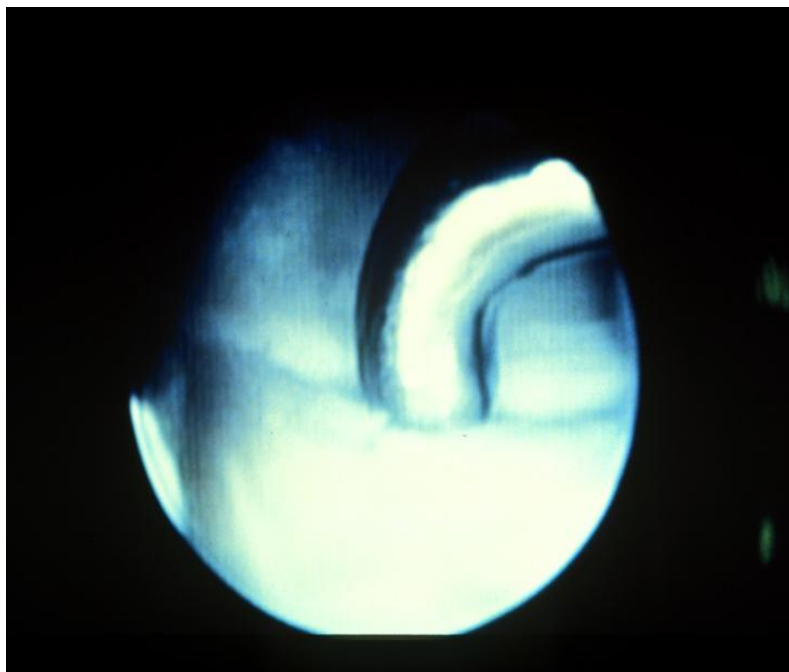
**Figure 5.4** – Mini-open volar approaches. Incision on the radial side of the wrist through the floor of the FCR tendon sheath. Incision on the ulnar side of the wrist was between the long flexor tendons and the ulnar neurovascular bundle. Retraction of the longitudinal structures allows the volar aspect of the distal radius to be identified, so that K-wires can be advanced across the distal radius to provide stability.

### **Fluoroscopy**

Fluoroscopy was valuable in ensuring satisfactory insertion and positioning of the K-wires. Fluoroscopy is used to perform the metaphyseal reduction in the early cases demonstrated that arthroscopy demonstrated failure of reduction. Arthroscopic assessment of the articular surface demonstrated that fluoroscopy assisted reduction of articular surface was often poorer than expected. Assessment of the stability of the fixation was performed dynamically by gentle manipulation of the fracture under fluoroscopic control in two planes. Extra fixation, either percutaneous or external, was utilised if required (Figure 5.5, 5.6).



**Figure 5.5** – Arthroscopic view of distal radius fracture with intra-articular step. From – Bain et al., 1997.

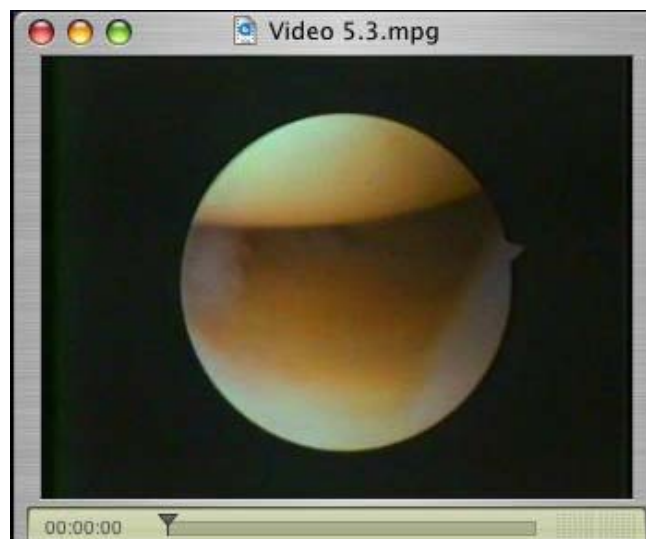

**Figure 5.6** – Arthroscopic view of distal radius fracture following reduction of the articular step. From – Bain et al., 1997.

At arthroscopy the associated soft tissue injuries can also be managed. This includes debridement of the torn triangular fibrocartilage (Video 5.2). The instability of the interosseous ligaments (e.g. scapho-lunate ligament) is assessed using the arthroscopic probe introduced into the mid-carpal joint (Geissler et al., 1996) (Figure 5.7). The scapho-lunate interval can be reduced and stabilised with percutaneous K-wire (Video 5.3).

NOTE: This figure is included on page 106 of the print copy of the thesis held in the University of Adelaide Library.

**Figure 5.7** – Arthroscopic view of the mid-carpal joint with probe in scapho-lunate interval to assess instability as reported by Geissler. From – Bain et al., 1997.



**Video 5.3** – Scapho-lunate stabilisation. Arthroscopic view of the mid-carpal joint with scapho-lunate interval being reduced and stabilised with percutaneous K-wires.

## Management of soft tissue injuries

Via mid-carpal arthroscopy, scapho-lunate instability and lunotriquetral instability were graded using the Leibovic and Geissler arthroscopic classification (Leibovic and Geissler, 1994). Patients with instability were treated by arthroscopically assisted reduction and percutaneous pinning of these joints using two 1.6mm K-wires (Figure 5.7).

Osteochondral lesions were arthroscopically identified and debrided. There was no suggestion of any of these injuries on pre-operative plain radiographs.

## Documentation of patient outcome measures.

Arthroscopic findings were documented at the time of surgery on a standardised proforma sheet (Appendix 4.2) and added to a prospective database of operative procedures. A standardised clinical independent subjective and objective assessment was undertaken and documented by a research nurse at least one year following the operative procedure (Appendix 4.3). A standardised radiological assessment was performed (Appendix 4.4). Pre-operative and follow-up radiographs were independently examined for radial height, radial angle and articular incongruity compared to the contralateral wrist ( Mah, 1992; Palmer, 1989). The fractures were classified using the Frykman and the AO classifications (Geissler, 1995; Melone, 1986). Follow-up radiographs were assessed for articular incongruity and arthritis as described by Knirk and Jupiter (Gartland and Werley, 1951; Knirk and Jupiter, 1986).

The results were graded using the New York Orthopaedic Hospital (NYOH) score and the Gartland and Werley system (G&W) (Fernandez and Geissler, 1991; Levy and Glickel, 1993).

Medical records were reviewed to identify documented intra-operative and post-operative complications.

Correlation between the categorical outcomes (the scoring systems) and the categorical predictors (intra-carpal injuries) was performed using the Fishers Exact Test. The Kruskal-Wallis Test was used to correlate the categorical outcomes with non-normally distributed numeric predictors (e.g. radiological assessment) and non-normally distributed numeric

outcomes (grip, range of motion and pain). Spearman correlations were used for non-normally distributed numeric outcomes and non-normally distributed numeric predictors.

#### 5.3.4 Main findings of the published research

##### Arthroscopic observations

Arthroscopy usually revealed the four-part fracture as described by Melone. It was not uncommon to find at arthroscopy that the fracture was displaced much more than would have been predicted based on assessment with fluoroscopy.

##### Subjective observation

Twenty-three of twenty-five (92%) patients were satisfied with their results. The average residual pain score was 1.3 on a visual analogue scale of 0-10. Most patients had no pain and some had pain that was intermittent.

##### Objective observations

The average active range of motion in the affected wrists was flexion 57° (74% of opposite), extension 56° (78%). The average grip strength was 36kg (90%). Using the NYOH score, excellent to good results were obtained in 88% of the cases; in Frykman VII fractures the score was 100% and in Frykman VIII fractures the score was 77%.

Using the Gartland & Wertley scores, excellent to good results were obtained in 70% of the cases. In Frykman VII fractures the score was 85% and in Frykman VIII the score was fractures 54%.

##### Radiological observations

In 17 wrists (65%) there was no intra-articular radiocarpal step. In eight wrists (31%) there was a step  $\leq 1$ mm and in one patient a step between 1mm and 2mm. This patient had a poor result on both grading systems and was the only patient with severe pain. There was a significant difference in incidence of pain (VAS  $\geq 2$ ) for the patients with no step (18%),  $\leq 1$ mm step (38%) and  $>1$ mm step (100%) ( $p < 0.05$ ).

In the 19 patients with scapho-lunate instability managed with scapho-lunate K-wire fixation, nine had a residual diastasis of  $\geq 3$ mm. There was a significant difference in the incidence of

persistent diastasis with the Geissler classification, (Geissler et al.) (Table 2.4) Grade I (0%), II (0%), III (42%) and IV (100%) ( $p < 0.01$ ).

### Complications

Prior to the development of the author's volar mini-open reduction method and pinning technique, there was one patient with loss of reduction due to comminution of the volar cortex. This was managed with an open reduction and application of volar buttress plate. One patient developed acute post operative median nerve compression, which was managed by prompt decompression. Forearm compartment syndrome did not develop in any patient.

Seven patients with external fixateur had infection of the proximal pin sites. The authors believe this high incidence of infection is related to movement of the soft tissues over the pins as part of the aggressive rehabilitation protocol. We no longer use this protocol and have noticed a decreased incidence of these infections.

A radio-ulnar synostosis developed in one patient who had a comminuted distal radius fracture (AO C3.3) and comminuted fracture of the distal ulna which extended to the diaphysis (Fernandez Type 3). Porter and Tillman reported two similar cases in their series (Fernandez et al., 1996).



## **5.4 Results of arthroscopic debridement for isolated scaphotrapeziotrapezoid arthritis**

### 5.4.1 Research aims

The aim was to develop and report a safe and effective therapeutic method of arthroscopic management of STT joint arthritis

### 5.4.2 Research objectives

1. To develop a therapeutic wrist arthroscopy technique for the management of STT joint arthritis.
2. To perform a cadaveric study to ensure safe portals for the STT joint arthroscopy are developed.
3. To assess patient outcomes based on subjective and objective modalities.
4. To assess the safety of the technique by documentation of complications.
5. To document the arthroscopic findings and compare them to cadaveric reports.

### 5.4.3 Principles of study methodology

A cadaveric study was performed to assess the safety of the portal placement. This included dissection of the subcutaneous tissues and neurovascular structures and their relationship to the joint and possible portals.

#### Documentation of patient outcome measures

1. Arthroscopic findings were documented at the time of surgery on a standardised proforma sheet (Appendix 4.2).
2. A prospective database of operative procedures was reviewed to identify those patients who had undergone the procedure.
3. A standardised, clinical, independent subjective and objective assessment was undertaken and documented by a research nurse at least one year following the operative procedure (Appendix 4.3).
4. A standardised radiological assessment was performed (Appendix 4.4).

Medical records were reviewed to identify documented intra-operative and post-operative complications.

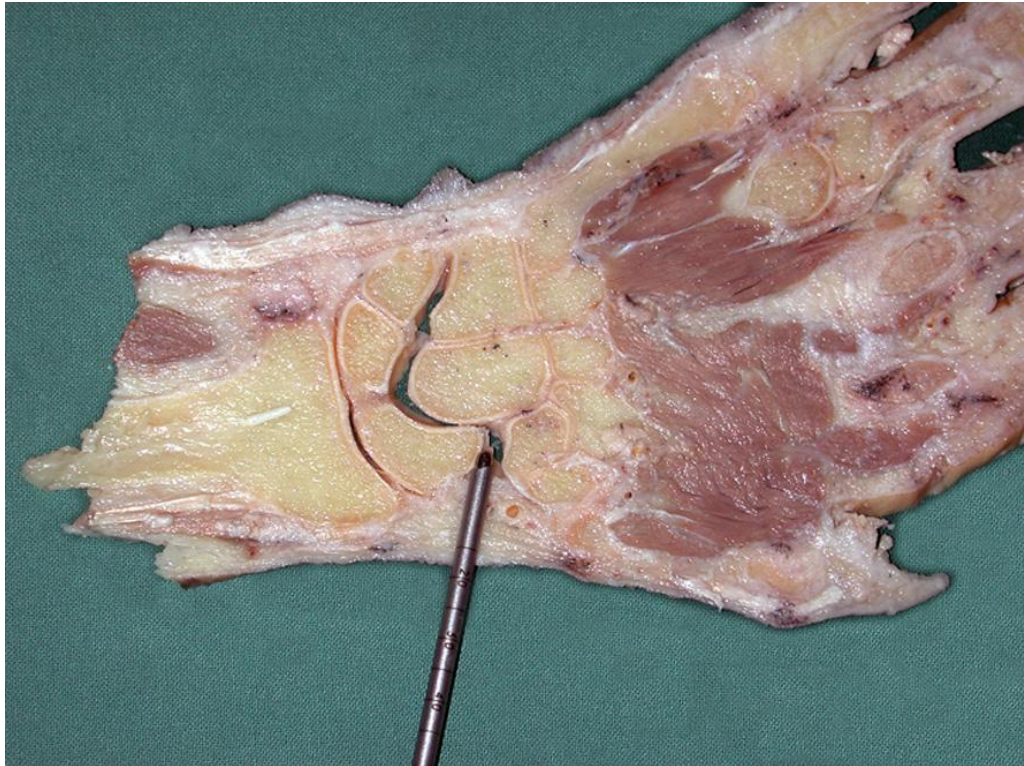
## Indications

Localised persistent wrist pain that limited the patient's ability to perform activities.

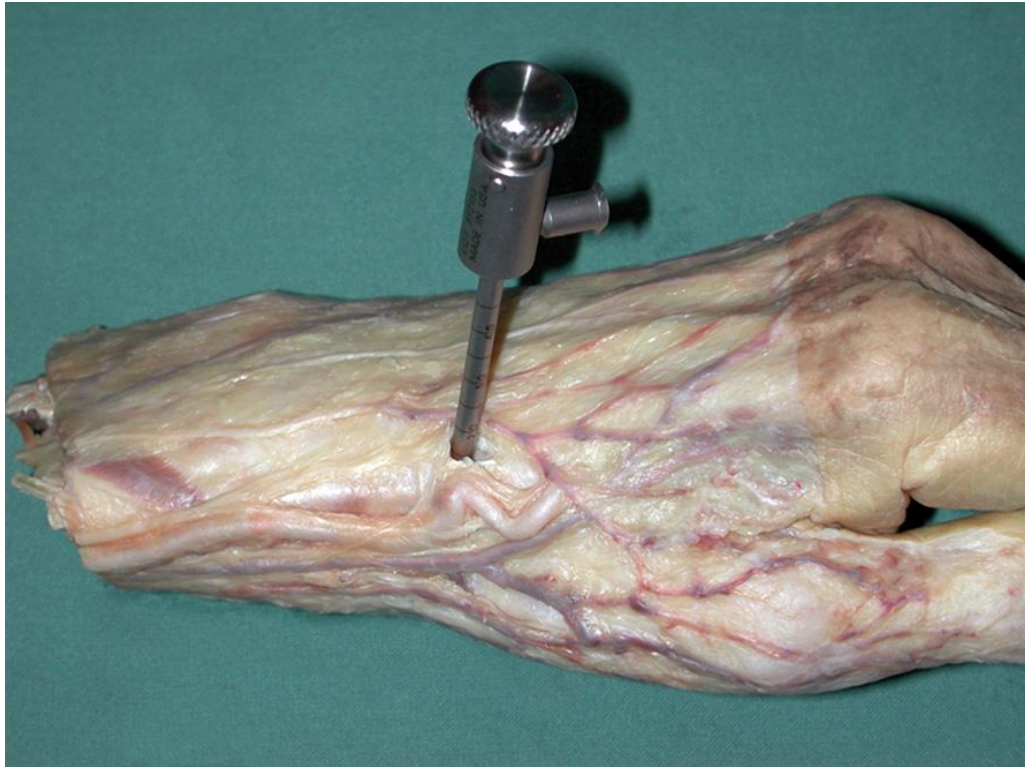All patients received a period of conservative treatment, including splinting and analgesics.

### 5.4.4 Main findings of the published research

The cadaveric study demonstrated that the positioning of the STT joint portal was critical. Placement to the ulnar side of the extensor pollicis longus tendon is safer for the radial artery but the superficial branch of the radial nerve and the extensor carpi radialis longus tendon still are at risk (Figure 5.8, 5.9). If the surgeon goes to the radial side of the extensor pollicis longus tendon, the radial artery and superficial branch of the radial nerve are both at risk. The radial artery is often tortuous within the anatomic "snuff box." The authors recommended a 1.5cm incision in the skin to enable safe blunt dissection. This mini-open approach allows the surgeon to visualise the neurovascular structures to minimise the risk of injury. The portal to the radial side of the extensor pollicis longus tendon provides a wider arc from the radial mid-carpal portal facilitating triangulation.



**Figure 5.8** – Cadaveric coronal section of a left wrist with the arthroscopic portal in the STT joint. Note the close proximity of the radial artery.



**Figure 5.9** – Cadaveric specimen demonstrating the dorsal STT portal ulnar to the EPL tendon. Note the radial nerve and radial artery and the superficial branch of the radial nerve to the radial side of EPL tendon.

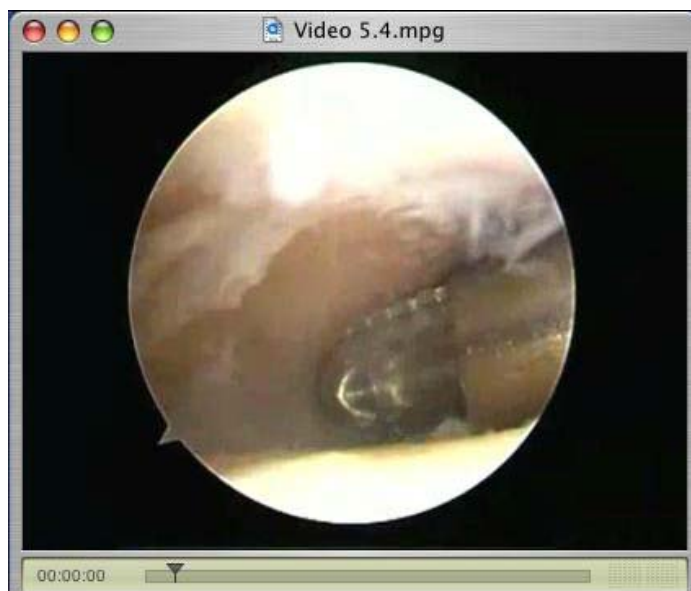The arthroscopic observations demonstrated the presence of eburnated bone on the distal scaphoid, and proximal trapezium and trapezoid were always extensive (Figure 5.10). These were more advanced than expected from review of the paper from Moritomo et al (Moritomo et al., 2000). The joint was debrided with motorised resectors and cautery (Figure 5.11, Video 5.4).

NOTE: This figure is included on page 113 of the print copy of the thesis held in the University of Adelaide Library.

**Figure 5.10** – Arthroscopic view of the articular surface of the trapezium and trapezoid, with the cartilage seen between these 2 bones. From – Ashwood et al., in press.

NOTE: This figure is included on page 114 of the print copy of the thesis held in the University of Adelaide Library.

**Figure 5.11** – Arthroscopic debridement of the STT joint with a motorised resector. From – Ashwood et al., in press.



**Video 5.4** – STT arthritis. Arthroscopic view of the STT joint with eburnated bone on the distal aspect of the scaphoid and on the proximal aspect of the trapezium and trapezoid. A synovectomy of this joint can be performed with the aid of a motorised resector.

Pain and function were improved in all cases. There was improvement in the average wrist score after surgery, from 63 to 91. Mean grip strength improved from 23 to 42kg. There was modest improvement in the measured range of motion following surgery.

It is interesting to compare the results with those of other authors. STT arthrodesis has a high reported complication rate, including non-union, radioscapoid impingement and secondary arthritis of radioscapoid or trapeziometacarpal joints (Garcia-Elias et al., 1999; Ishida and Tsai, 1993; Srinivasan and Matthews, 1996). Garcia- Elias et al reported that almost 40% of patients experienced mild pain after STT excision arthroplasty (Garcia-Elias et al., 1999). It is the author's experience that excision of the distal scaphoid increases dorsal instability and can lead to an aggravation of the pain.

## **5.5 Arthroscopically assisted treatment of intra-osseous ganglion of the lunate**

### 5.5.1 Research aims

The aim was to develop a safe and effective therapeutic wrist arthroscopy technique for the management of intra-osseous ganglion of the lunate.

### 5.5.2 Research objectives

1. To develop a therapeutic wrist arthroscopy technique for the management of intra-osseous ganglion of the lunate.
2. To assess the patient outcomes based on subjective and objective modalities.
3. To assess the safety of the technique by documentation of complications.

### 5.5.3 Principles of study methodology

#### Indications for surgical intervention

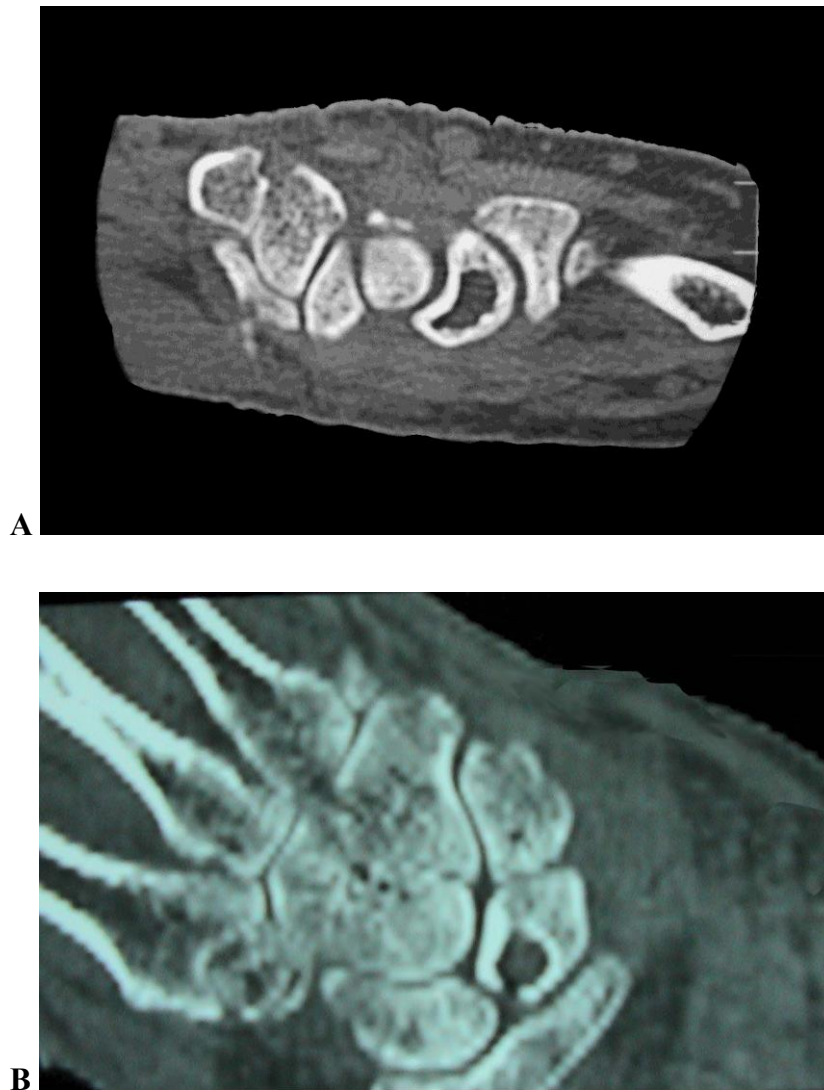
The indication for surgical intervention is persistent wrist pain localised to the site of the lunate that limited the patient's ability to perform normal activities. Symptoms had to be present for a minimum of six months before surgery. All patients received a period of conservative treatment, including splinting and analgesics. Surgery was not considered unless the patient had results from a radiograph and a bone scan that were consistent with a working diagnosis of an intra-osseous ganglion of the lunate.

A standardized assessment was independently completed by a research nurse prior to surgery (Appendix 4.4)

All patients had a pre-operative technetium 99 radionuclide bone scan showing isolated focal increased uptake within the lunate. This investigation helped to confirm that the patient's symptoms were related to the intra-osseous ganglion and not due to other causes. Patients who had a negative bone scan were not offered surgical treatment.

## Pre-operative planning

CT scans were used to define the location and the extent of the lesion more clearly, aiding surgical planning. This is particularly important with this technique because the cyst may be volar or dorsal. The exact site of planned arthroscopic drilling must be determined pre-operatively to ensure that it was performed in a safe and effective manner. CT images were assessed in the coronal and sagittal planes (Figure 5.12).



**Figure 5.12a, b** – Intra-osseous ganglion. Lateral view of left wrist (A) and AP view of left wrist (B). CT scan of the lunate demonstrating the exact position of the ganglion and a small cortical breach from which the ganglion arises. From – Ashwood et al., 2003.

The proximity of the scapho-lunate ligament is also important as an arthroscopic landmark and should be interpreted in the pre-operative assessment.

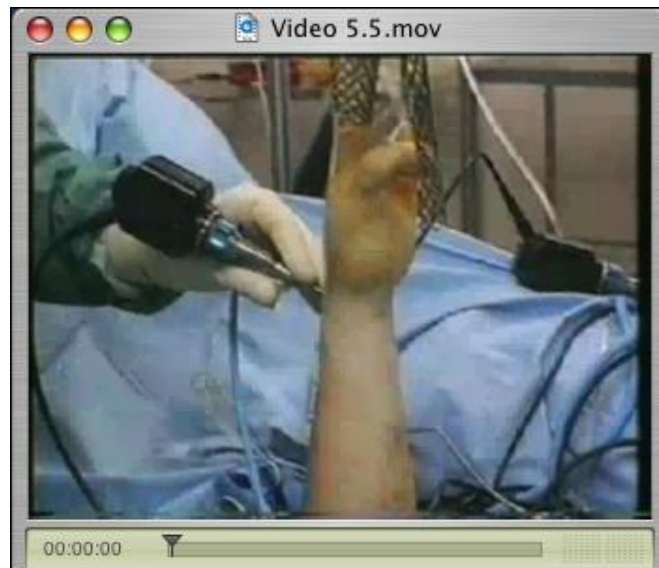

## Surgical Technique

A standard wrist arthroscopy was performed. If the intra-osseous ganglion was mainly volar then a volar portal was required. The author preferred to use the inside-out technique utilising a Wissenger rod as it simple and can be performed safely (Bergman and Bain, In Press). The Wissenger rod is advanced with an inside-out technique through the interligamentous sulcus between the RSC and LRL ligaments (Figure 5.13). As long as the Wissenger rod is brought radial to the flexor carpi radialis tendon the superficial branch of the radial nerve will be safe (Video 5.5).

NOTE: This figure is included on page 118 of the print copy of the thesis held in the University of Adelaide Library.

**Figure 5.13** – Interligamentous sulcus. Wrist arthroscopic view showing long radiolunate ligament (LRL) on the left and radioscaphocapitate (RSC) ligament on the right. From – Bain et al., 1997.



**Video 5.5** – Inside-out volar radial portal technique: Wissinger rod is introduced through interligamentous sides to the radial side of FCR tendon.

A 3.5mm drill was advanced within a trocar via the 3/4 portal under direct vision and strategically positioned on the lunate at the site of the lesion as determined by the pre-operative imaging. The scapho-lunate ligament could often be used as an approximate guide to the position of the ganglion arthroscopically. Satisfactory positioning of the drill tip was then confirmed in the anteroposterior and lateral planes by fluoroscopy (Figure 5.13). The drill was then advanced into the body of the lunate corresponding to the site of the intra-osseous ganglion as previously identified on the CT scan. If the lesion was on the volar aspect of the lunate on CT then a volar portal was used (Video 5.5).

Once an appropriate cortical hole had been made, a biopsy specimen was taken of the lesion by using a curette and arthroscopic biopsy forceps. The cavity was found to be filled with a viscous gelatinous material. Histology confirmed a fibrous capsule of compressed collagen fibre, fibroblasts and mesenchymal cells around a viscous clear mucinoid center. This confirmed the provisional diagnosis of an intra-osseous ganglion.

A standard 3mm arthroscopic motorised resector was introduced into the drill hole to enable debridement of the remaining soft tissue. Fluoroscopy was used intermittently to confirm position of the instruments during the procedure (Figure 5.14). To confirm the adequacy of the debridement, the arthroscope was used to inspect the drill hole. This confirmed that all the

soft tissue was removed. An incision was then made over the dorsal aspect of the wrist proximal to Lister's tubercle. A small cortical window was developed and cancellous bone was harvested.

NOTE: This figure is included on page 120 of the print copy of the thesis held in the University of Adelaide Library.

**Figure 5.14** – Fluoroscopic confirmation of drill placement into the lunate (small arrow, drill in cannula; large arrow, arthroscope). From – Ashwood et al., 2003.

A 3mm trocar was then advanced through the 3-4 portal and into the hole in the lunate. Fluoroscopy was used to confirm that the trocar was well seated within the debrided lunate. The harvested bone graft was advanced through the trocar and impacted into the lunate by pushing the graft through the trocar by using a small rod. This reduced the risk of any graft falling into the wrist joint. The lesion was grafted up to the margin of the cortical bone rather than to the articular cartilage. The lunate was finally assessed arthroscopically and fluoroscopically to ensure that the graft was suitably positioned. The joint was thoroughly irrigated before the wounds were sutured.

## Patient follow-up

A prospective documentation of arthroscopic findings of the wrist was performed (Appendix 4.2). A prospective database of operative procedures was reviewed to identify those patients who had undergone wrist arthroscopy with a diagnosis of intra-osseous ganglion of the lunate.

The medical records of the eight patients were reviewed.

Patients were identified prospectively when they had their surgery. A same standardised assessment was independently completed by a research nurse (Appendix 4.4) at least one year from the time of surgery. This included measurement of range of motion and grip strength by using a goniometer and dynamometer respectively before surgery and at follow-up assessments. Visual analog scales were used to record pain (0-100) and satisfaction levels (0-100). The contralateral normal side was also assessed for comparison. A record of limitation of activities of daily living was noted.

Post-operatively radiographs were also evaluated.

Statistical analysis was performed on the primary results using a paired student's t-test. A p value of .05 was considered significant.

### 5.5.4 Main findings of the published research

Subjective data included visual analog pain scores (0-100), which improved from 68 to 11. The flexion-extension arcs increased from 98° to 114°. Grip strength improved from 11.9kg to 18.9kg. Wrist scores improved 34 points, from 51 to 85 points. Before surgery, two patients could be categorised as having fair and six as poor. At the final follow-up evaluation there were six good or excellent results and two fair results. There were no complications or repeat surgeries in this patient population. Trabecular bone was noted within the grafted lunate.

## **5.6 Arthroscopic capsular release for contracture of the wrist**

### 5.6.1 Research aims

The aim was to develop a safe and efficient therapeutic technique of wrist arthroscopy for the management of wrist contracture. To determine the proximity of the major neurovascular structures on the volar aspect of the wrist.

### 5.6.2 Research objectives

1. To develop a therapeutic wrist arthroscopy technique for the management of wrist contracture which is based on principles in the literature.
2. To assess the safety of performing the technique by reviewing a cadaveric and radiological model
3. To document the arthroscopic findings at the time of surgery.
4. To document patient outcomes using subjective, objective and radiological measures.
5. To document intra-operative and post-operative complications.
6. To determine the efficiency of the arthroscopic procedure based on documented arthroscopic findings and patient-related outcome measures.
7. To determine the safety of the procedure based on review of complications
8. To make recommendations for subsequent treatment based on the determined safety and efficiency of the operative procedure.

### 5.6.3 Principles of study methodology

#### Development of technique

A number of unique factors were identified that need to be addressed for arthroscopic release of the wrist contracture. Of concern were the potential complications including injury to extra-articular structures such as the major nerves, vessel and tendons. The risk of producing instability when releasing the wrist was also considered.

The arthroscopic wrist release technique was developed based on the principles of the open surgical procedure that were utilised in an arthroscopic environment. Previously published effective open surgical release techniques for the treatment of a wrist joint contracture were reviewed (Watson, 1988).

The indications for the technique were based on those developed in other joints for open and arthroscopic releases. That is, a painless stiff joint with minimal changes on plain radiographs (Jones and Savoie, 1993; Kleinman and Graham, 1996; Morrey, 1992; Richmond and al Assal, 1991; Warner et al., 1996; Warner et al., 1997; Watson, 1988; Zanotti and Kuhn, 1997).

The arthroscopic wrist release technique was developed based on the principles developed for arthroscopic release in other joints (Jones and Savoie, 1993; Kleinman and Graham, 1996; Morrey, 1992; Richmond and al Assal, 1991; Warner et al., 1996; Warner et al., 1997; Watson, 1988; Zanotti and Kuhn, 1997).

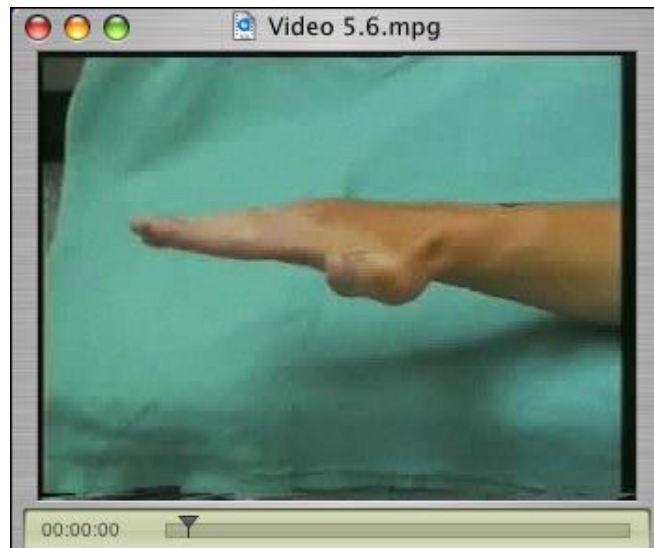
A literature review demonstrated the importance of preventing ulnar translocation of the carpus by restricting the volar capsular release, based on the principles reported by Viegas (Viegas et al., 1995).

A cadaveric and MRI study was performed to assess the proximity of major neurovascular structures to the volar capsule. This was completed prior to performing the operative procedure.

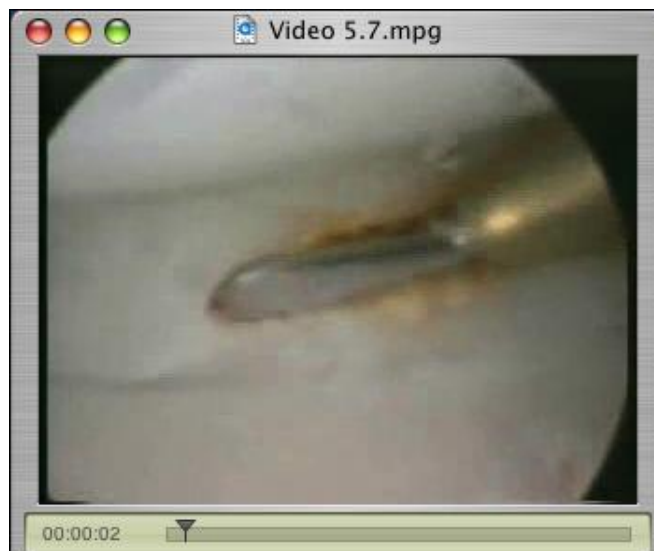The cadaveric study demonstrates that the median nerve is protected by the peri-articular fat and the long flexor tendons. The radial artery is the closest neurovascular structure to the volar capsule. This information is important when considering performing an arthroscopic capsular release of the wrist. From an arthroscopic perspective the surgical release of the

volar capsule can be performed until its peri-articular fat is exposed. It is important that the surgeon does not extend the release through the peri-articular fat as this may compromise the neurovascular structures or the long flexor tendon.

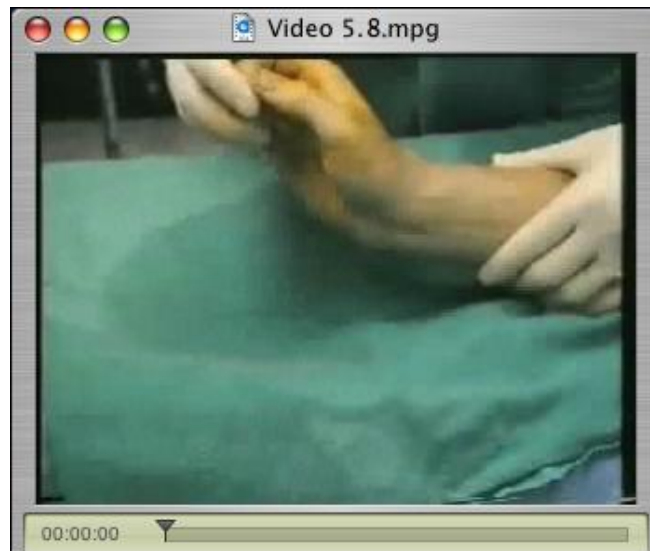The technique of arthroscopic capsular release is demonstrated in Videos 5.6, 5.7, 5.8.



**Video 5.6** – Volar capsular release. Pre-operative range of motion of wrist contracture.



**Video 5.7** - Volar capsular release video. Arthroscopic view showing volar synovitis is debrided to expose the volar capsule, which is released with cautery. The radial side of the RSC ligament is preserved to prevent ulnar-translocation.



**Video 5.8** – Volar capsular release. Post-release manipulation.

#### Documentation of patient outcome measures

- i) Arthroscopic findings were documented at the time of surgery on a standardised proforma sheet (Appendix 4.2).
- ii) A prospective database of operative procedures was reviewed to identify those patients who had undergone the procedure.
- iii) A standardised, clinical, independent subjective and objective assessment was undertaken and documented by a research nurse at least one year following the operative procedure (Appendix 4.3).
- iv) A standardised radiological assessment was performed (Appendix 4.4).

Medical records were reviewed to identify documented intra-operative and post-operative complications.



#### 5.6.4 Main findings of the research:

##### Arthroscopic observations

There was often synovitis on the volar capsule.

##### Subjective observation

There was improvement in pain (VAS 0-10) from 1.5 to 1.0.

##### Objective observations

There was improvement in flexion from 17° to 47° and extension from 10° to 50°. Grip strength improved from 13 to 31kgs.

##### Radiological observations

No ulnar translocation was observed.

##### Complications

No neurovascular or other complications occurred.

## **5.7 Arthroscopic excision of ulnar styloid in stylo-carpal impaction**

### 5.7.1 Research aims

The aim was to develop a safe and therapeutic technique of arthroscopic management of ulnar stylo-carpal impaction

### 5.7.2 Research objectives

1. Assess the pre-operative diagnostic value of fluoroscopic examination of the wrist in the provocation position to determine if there is ulnar styloid impingement.
2. Assess the pre-operative diagnostic value of 3D CT examination of the wrist in the provocation position to determine if there is ulnar stylo-carpal impingement.
3. To assess if the arthroscopic position of the ulnar styloid can be confirmed intra-operatively with fluoroscopy.
4. To assess if the arthroscopic excision of the ulnar styloid can be performed and confirmed with fluoroscopy.
5. To perform a clinical review of those patients who have undergone the arthroscopic excision of the ulnar styloid.

### 5.7.3 Principles of study methodology

Clinical cases of suspected ulnar stylo-carpal impaction were identified. This included factors identified in the literature such as a presentation of ulnar-sided wrist pain, pain with the provocation of ulnar deviation, and a relatively long ulnar styloid identified on plain radiographs.

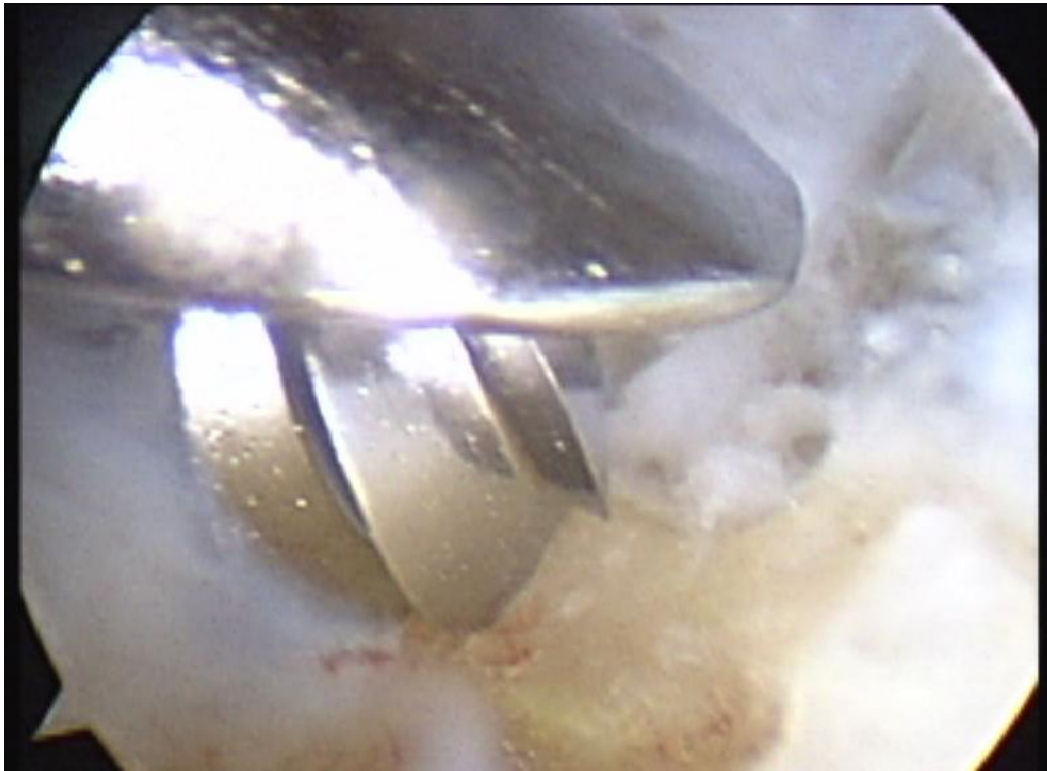
The author performed a dynamic fluoroscopic assessment of the wrist to ensure that the ulnar styloid was impinging on the carpus and that it coincided with the patients symptoms.

A 3D CT scan in the provocation position was also performed to confirm the impingement. There were some patients in which a provisional diagnosis of impingement was made on plain radiographs but were not confirmed using these other 2 modalities.

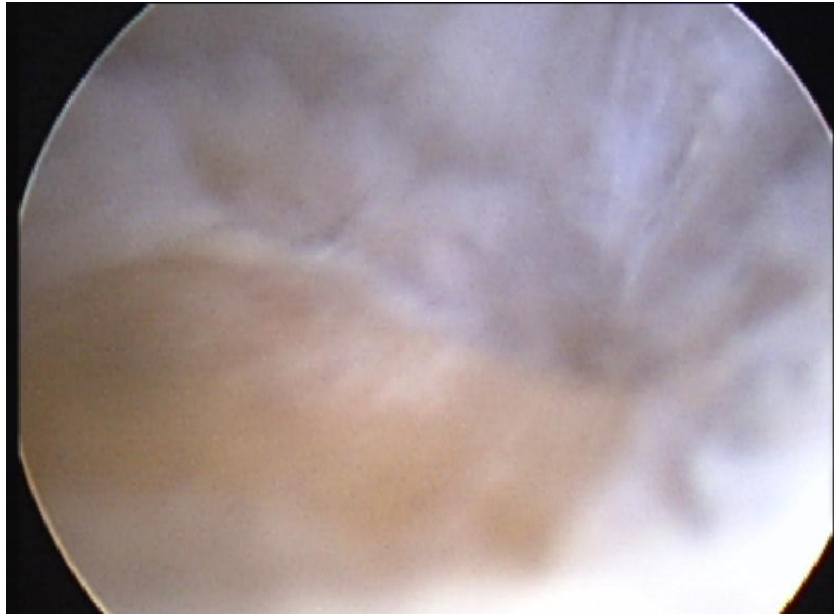
Pre-operative independent standardised clinical assessment was performed (Appendix 4.3).

At time of surgery the position of suspected ulnar styloid was identified arthroscopically and confirmed with fluoroscopy.

The resection of the ulnar styloid was performed with the arthroscopic burr (Figure 5.15, 5.16).



**Figure 5.15** – Arthroscopic view of a burr in position to perform an arthroscopic debridement of the prominent ulnar styloid.



**Figure 5.16** – Arthroscopic view (6R portal) of the prominent ulnar styloid. Note that it is flat and eburnated. In the background can be seen the ulnar carpal ligaments.

Adequate resection was confirmed on fluoroscopy.

A one year post-operative independent standardised clinical assessment was performed (Appendix 4.3).

#### 5.7.4 Main findings of the research

Pre-operative fluoroscopy can be utilised to confirm that the ulnar styloid is impinging on the carpus. This is important there were cases with a provisional diagnosis of stylo-carpal impaction which were proven on provocation testing to not be the case.

A pre-operative 3D CT scan can be utilised to confirm that the ulnar styloid is impinging on the carpus.

Excision of the ulnar styloid can be performed arthroscopically without the need to perform an open procedure.

Fluoroscopy can be utilised to confirm correct position of the arthroscopic burr.

Post-operatively the patients did not demonstrate instability of the distal radio-ulnar joint.

The rehabilitation of the patients was rapid without the need for immobilisation.

Follow-up clinical scores were considerably better than pre-operative scores. The results were reviewed for publication. However the journal preferred to accept the paper as a techniques paper only because there were only 4 cases.

No complications occurred.

## **5.8 Linkages between the various papers**

The work quoted from Quentin Fogg was performed in his thesis (Fogg, 2004). The author supervised his thesis and helped with the development of concepts that he subsequently published in his thesis. The different scaphoid anatomical findings were interesting but left the question, What is the relationship between the scaphoid motion and the type of lunate (Viegas, 1990). The scaphoid kinematic study presented in this thesis is to address this question (Galley et al., 2007).

Having developed a better understanding of the radial mid carpal joint, the natural extension was to the ulnar aspect of the mid carpal joint. However, the literature on the anatomy of the ulnar side of the mid carpal joint has been confusing and its association with the lunate type is unknown. The study on the triquetro-hamate joint was aimed to assess the ulnar side of the mid carpal joint and to identify what its relationship is to the lunate type (McLean et al., 2006) (Viegas, 1990). Therefore the research projects have covered the morphology and kinematics of the radial and ulnar sides of the mid carpal joint. Further research is planned to compare the ligament attachments of the type 1 lunate and type 2 lunate wrists. From this information a better understanding of the ligamentous morphological factors of the carpus and their association with the osseous morphological factors described by Viegas and Fogg can be determined (Viegas, 1990; Viegas et al., 1993) (Fogg, 2004).

The anatomical cadaveric papers increase the understanding of the normal wrist. Imaging of the wrist is required in clinical practice to have an understanding of the morphological abnormalities in the patient's wrist. Previously plain radiographs were the mainstay of assessment of scaphoid fractures. Unfortunately assessment of scaphoid fractures and deformity is difficult with plain radiographs. The papers on the imaging of the scaphoid provide a clinical, relevant radiological assessment of the anatomy of the scaphoid. The longitudinal CT scan technique provides a new technique for imaging the scaphoid. That method of imaging became the standard method (Appendix 4.1) for all future CT scan papers. The "target sign" was used as a criterion for determining the correct alignment in the humpback deformity paper. The humpback deformity paper provides a comparison of a previously published technique to newly developed techniques (Amadio et al., 1989). The clinical utilisation paper is an extension of this work to provide an overview of the clinical uses of CT scanning the scaphoid (Bain, 1999). It includes pre-operative templating and the concept of partial volume averaging.

The next extension is to compare the radiological assessment to histology and post-operative outcome. This unpublished work is to assess the pre-operative CT scan findings including fracture location, deformity and radio-density (Smith et al., 2007). It includes assessing the scaphoid deformity using the standardised longitudinal CT scan method with the “target sign” to ensure correct alignment of the scan. The pre-operative CT scan will be assessed for deformity using the height-to-length ratio and the dorsal cortical angle which are previously developed methods.

A new method to assess the position of the dorsal cortical breach has been developed and will be correlated to avascular necrosis (AVN). This is the dorsal-cortical percentile. A tube saw technique of bone grafting was performed to correct the deformity (Sandow et al., 1992). This involves harvesting a small specimen of the proximal pole of the scaphoid into which is inserted a bone graft. The tube saw specimen was sent for histological assessment of avascular necrosis.

This study will assess the 1) pre-operative radiological findings, 2) the independent histology assessment of avascular necrosis and 3) post-operative fracture union assessed on longitudinal CT scan. From this study the effect of the radio-density of the proximal pole, scaphoid deformity and the location of the dorsal cortical breach will be compared to the histology of the proximal pole of the scaphoid. All the pre-operative radiological and histological factors will then be correlated with fracture union. The dorsal cortical percentile and radio-density of the proximal pole were strongly correlated with AVN and persistent non-union. Some bridging across the fracture fragments was protective against AVN. Therefore the results of this work will correlate the pre-operative radiology, scaphoid pathology and surgical outcome.

The imaging section addresses the radiological assessment of the abnormal wrist. The arthroscopy section advances the surgical treatment of the abnormal wrist. The individual publications address different diagnoses.

The literature reviews had covered diagnostic and a number of therapeutic options of arthroscopy of the wrist. This thesis builds on this platform and covers a number of therapeutic modalities. The paper in the thesis on Kienböck’s disease was an extension of diagnostic arthroscopy (Bain and Begg, 2006). This paper aimed to advance the diagnostic volume of arthroscopy in Kienböck’s disease arthroscopic findings were recorded and

collated into a classification and provides a series of treatment recommendations based on the findings and the treatment options previously published in the literature. The treatment options relate to other unpublished work prepared by the author (Bain and Sood, 2007).

A number of “ectomy” procedures have been published in the literature (Roth and Poehling, 1990). A natural extension of the "ectomy" procedure is to extend it into other anatomical zones of the wrist using the concepts and instrumentation already available. The procedures for debridement of the STT joint and ulnar styloid respectively are line-extensions from the previously reported literature.

The next extension is to arthroscopic assisted reduction of distal radius fractures. This is technically more demanding. A number of authors had already published their findings and results in patients with arthroscopic assisted management of distal radius fractures. The extension from the previously published literature was to have an algorithm-based approach to the management of these injuries. The author reported the operative and clinical results, compared to the subjective findings to the post-operative radiological findings and identified a statistical correlation between the size of the deformity and the severity of pain. The arthroscopic assisted reduction of distal radius fractures includes a 5 level algorithm for management of the fractures and the associated soft tissue injuries. It includes debridement of TFC and inter-ligamentous lesions and percutaneous fixation methods of the distal radius fracture and inter-osseous intervals. The severity of pain was correlated to the size of the articular step.

After reviewing clinical cases of wrist injuries, it was evident that some patients had a disabling wrist contracture. This was witnessed following injury and open surgical procedures.

The natural extension was to consider if an arthroscopic capsular release of the wrist could be performed. The capsular release technique is a new wrist arthroscopic technique that had not been reported in the literature. However, the literature did highlight the potential complication of ulnar translocation of the carpus. Because of the potential complexity of the technique, cadaveric and radiological studies were performed first. The technique was then performed in a clinical setting and reported in the literature (Verhellen and Bain, 2000). The next extension of this work is to perform a dorsal capsular release for patients who have a joint contracture from a tight dorsal capsule (Bergman and Bain, In Press).



The author identified that the role of fluoroscopy in assessment of wrist disorders had not been defined. The paper on the use of fluoroscopy in hand and upper limb surgery reported on the clinical use of fluoroscopy in the operative field (Bain et al., 1997). The author found linking fluoroscopy and arthroscopy to be extremely valuable when performing arthroscopic assisted reduction of distal radius fractures. Arthroscopy provides the best assessment of reduction of the articular surface. However, fluoroscopy provides the best assessment of the reduction of the metaphyseal base and position of the internal fixation.

This device was utilised to assess the kinematics of the scaphoid motion in the normal wrist (Galley et al., 2007). It has been used in arthroscopic procedures such as for the management of distal radius fractures and fixation of the scapho-lunate interval. The extension of the use of this device was critical to enable the development of new arthroscopic techniques such as the arthroscopic ulnar styloid excision and intra-osseous ganglion debridement. Without developing the understanding of the clinical role of fluoroscopy, these techniques could not safely have been performed. The extension of fluoroscopic imaging into the surgical arthroscopy arena has allowed the author to make further advances in these areas.

Anatomy is an important component of the imaging and arthroscopy sections. An understanding of the anatomical alignment of the scaphoid was key to the development of the longitudinal CT scan technique and development of the new methods of assessing scaphoid deformity (Bain et al., 1998; Bain et al., 1995). The appreciation that the natural alignment of the scaphoid is oblique to the conventional anatomical planes is key. Anatomy is inter-related in the safety of the arthroscopic techniques, which included a cadaveric and MRI study of the proximity of the volar capsule to the major neurovascular structures which are relevant to capsular release surgery. A cadaveric study of the STT joint and the adjacent soft tissues was performed to ensure safe portal placement. Once the clinical problem is identified the author has questioned if arthroscopic options can be developed. This requires re-assessment of the normal anatomy and re-interpretation of the imaging. Further anatomic studies are being considered to assess the feasibility of performing an arthroscopic scapho-lunate ligament reconstruction.

## Chapter 6 – CONCLUSION

### 6.1 Introduction

The conclusion provides an overriding discussion of the work presented in the thesis. It includes comments on the significance of the work, problems encountered and future research. It is not aimed to be a detailed reworking of the discussion of each paper published.

### 6.2 Anatomy

The work described in the thesis has made advances in a number of areas. There has been a development in the understanding of the morphology of the normal wrist joint and how the morphology interacts with wrist kinematics.

#### 6.2.1 Scaphoid kinematics

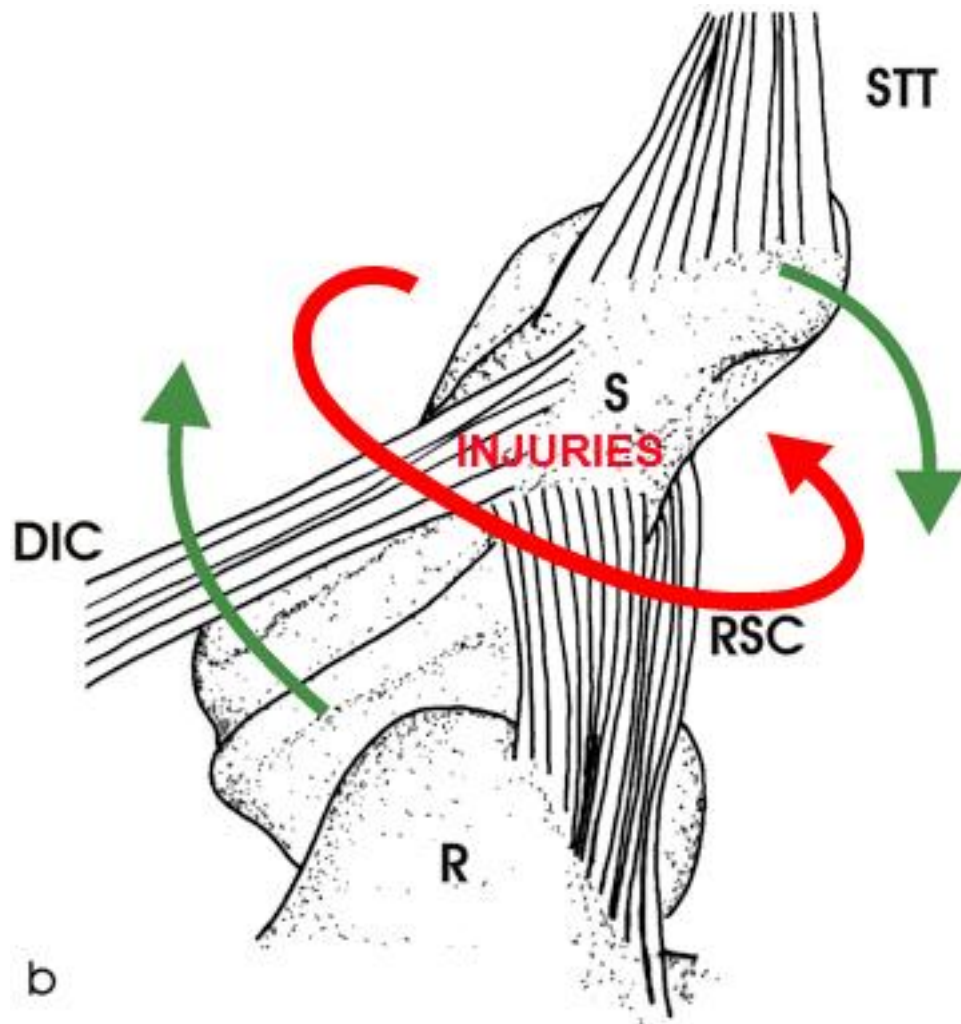
The study on the scaphoid kinematics has demonstrated that the osseous morphology of the lunate has a significant association with the kinematics of the scaphoid. The type 1 lunate wrist has a greater degree of scaphoid translation, whereas the type 2 lunate wrist has a greater degree of scaphoid flexion. Using the older terminology, the scaphoid in the type 1 lunate wrist behaves in the row configuration and the scaphoid from a type 2 lunate wrist behaves in a column configuration. The importance of this is that lunate type can be used as a pre-operative radiological marker to determine the type of scaphoid motion. This may be important in determining which surgical procedure should be performed. For example, Stanley reported that a STT joint arthrodesis is likely to have a better outcome in a row wrist and than a column wrist.

Fogg demonstrated that there are two types of scaphoid, i.e. rotating and flexing scaphoid (Fogg, 2004). He documented differences in the ligamentous attachments of the two types of scaphoid and that there were different ligament attachments acting as rotation or flexion restraints to the scaphoid (Figure 2.8, 2.9, 2.10).

Scapholunate instability is characterised by abnormal scaphoid flexion and rotation.

This suggests that the patient with a gross scapholunate instability has reached the final common position, i.e. the scaphoid is in abnormal rotation and flexion. The flexing scaphoid has a rotational injury to the rotatory restraints, which causes the scaphoid to be unstable (Figure 6.1). The author postulates that the best surgical procedure will be to perform a repair

or reconstruct specifically directed at the rotatory restraints. If the flexion restraints are also repaired then the patient will have abnormal stiffness of the joint. In the late presentation where repair is not feasible then a reconstruction of the rotatory restraints should be considered.



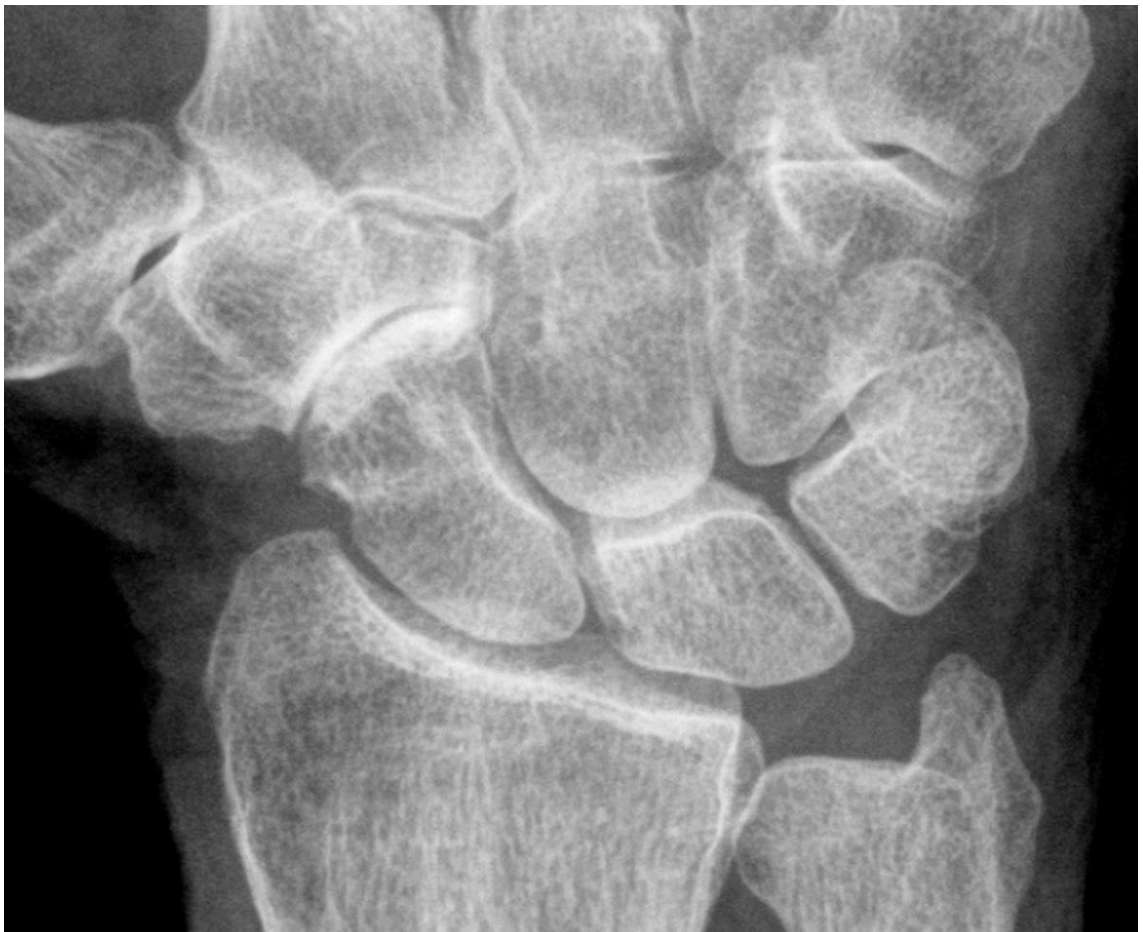**Figure 6.1** – Mechanism of injury. A flexing scaphoid with its rotational restraints. The mechanism of injury is a rotational injury to tear the rotational restraints.

For the rotating scaphoid the opposite is postulated, i.e. for flexion injury of the rotation restraints surgery is directed of the rotational restraints. A reasonable proposal is that one reason the surgical procedures for scapho-lunate instability have only fair results is that the ligament reconstruction should be tailored to the individual's skeletal and ligamentous morphology (Blatt, 1987; Brunelli and Brunelli, 1995; Slater and Szabo, 1999).

A cadaveric morphological study is currently being performed with the aim of assessing whether different ligament repairs or reconstructions are required to stabilise the type 1 and 2 lunate wrists. Plain radiographs are being used to determine the lunate type. CT and MRI scans of the wrists are being performed. The ligament attachments of the wrists will be determined with MRI and confirmed with loupe magnification. This will provide information on the accuracy of MRI in determining the attachment of ligaments. The CT images will be used to determine the scaphoid type (Fogg, 2004) and for 3D kinematic studies for later comparison with the determined ligament attachments.

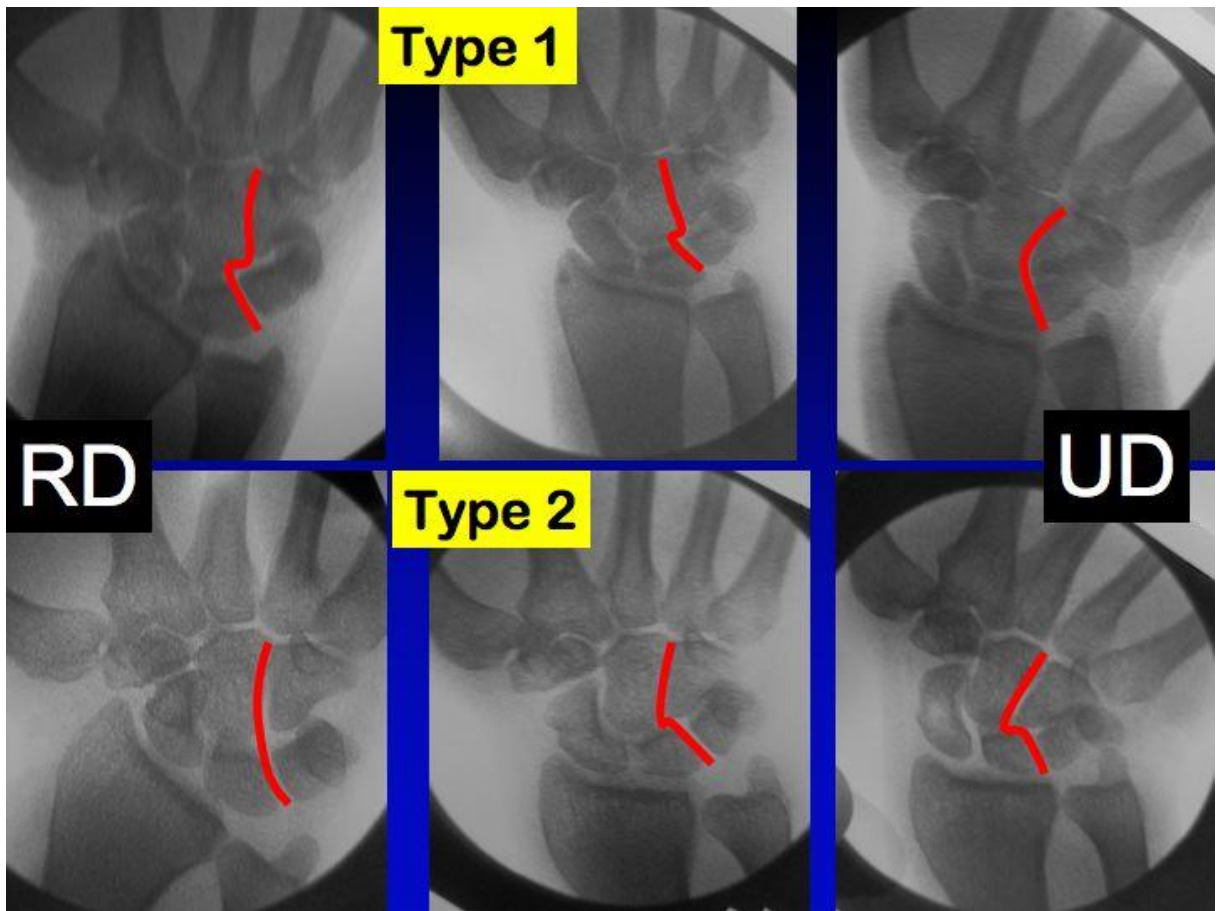
The restraints of the scaphoid will be divided to create a scapho-lunate instability. A surgical reconstruction of the rotation or flexion restraints will be performed. The results in the cadaveric repairs will be compared to determine the stability.

Other current work includes identifying the association between the lunate type and the incidence of STT joint osteoarthritis. Interestingly, the type 2 lunate wrist has a considerably higher incidence of degenerative arthritis at the STT joint than the type 1 lunate wrist (Figure 6.2). It is postulated that this is related to the increased scaphoid flexion at the STT joint with a type 2 lunate wrist, as demonstrated in this thesis. Unfortunately for the type 2 lunate population, they are more prone to arthritis at the STT and luno-hamate joints and have an increased incidence of humpback deformity (Haase et al., 2007) with scaphoid fractures.



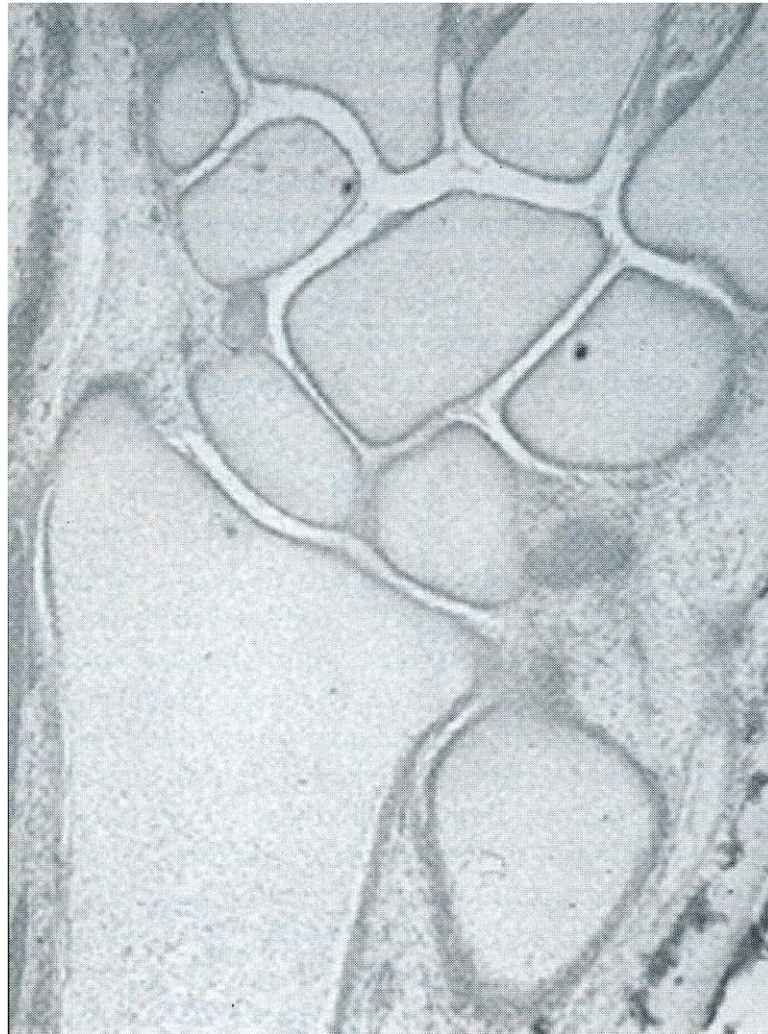
**Figure 6.2** - Plain radiograph of type 2 lunate wrist with STT joint degenerative arthritis.

An interesting observation was the fact that the capito-hamate articulation is co-linear with the luno-triquetral articulation in ulnar deviation in the type 1 lunate wrist. In contrast, the capito-hamate articulation is co-linear with the luno-triquetrial articulation in ulnar deviation in the type 2 lunate wrists (Figure 6.3).



**Figure 6.3** - Fluoroscopic images of wrist. Type 1 lunate wrist on the top and type 2 on the bottom. The left images are in radial deviation, middle in neutral and right in ulnar deviation. The capito-hamate articulation is co-linear with the luno-triquetral articulation in ulnar deviation in the type 1 lunate wrist. In contrast, the capito-hamate articulation is co-linear with the luno-triquetrial articulation in ulnar deviation in the type 2 lunate wrist.

The authors postulated that the morphological difference was genetically determined and resulted from different embryological development of the carpus (Figure 6.4). It is known that a cartilaginous analogue forms and that apoptosis of mesenchymal causes separation of the carpal unit (Berger, 1998). These smaller cartilaginous components later ossify to become the carpal bones. Further investigation is required to determine whether this is the case or whether the different morphologies result from factors such as in-utero positioning or development of separate primary ossification centres.



**Figure 6.4** – Fetal wrist. A 45mm crown-rump fetal wrist with what appears to be a type 2 lunate, which articulates with the capitate and hamate. From Berger, 1998.

### 6.2.2 Triquetro-hamate joint

The triquetro-hamate joint paper has identified two characteristic and distinct morphological patterns of articulation at the triquetro-hamate joint. The more common TqH joint was formed by a type A triquetrum and a type I hamate (TqH-1). It has a helicoidal configuration which is double-faceted, similar to the subtalar joint. The hamate and the triquetrum articular surfaces have complementary concave and convex surfaces. It was postulated that this configuration enforces an obligatory joint rotation in wrist ulnar deviation (i.e. it produces pronation of the distal carpal row in full ulnar deviation). This is a screw-home mechanism that locks the joint in ulnar deviation and it was proposed that this is important in power grip.

The TqH-2 joint is formed by a type 2 hamate and a type B triquetrum, which is less undulating and does not have a hamate groove. The slight concavity of the triquetrum fits neatly against the convexity of the hamate. In maximal ulnar deviation the flat distal part of the triquetrum fits with the slight volar “dish-like” concavity of the hamate. It was postulated that this will allow rotation, but it is not an obligatory rotatory torque on the mid-carpal joint.

The research on the TqH joint was performed on cadaveric material, which provides the best representation of the joint morphology as there is minimal change in the cadaveric model. A formal kinematic study has not been undertaken, although will be required. A statistically significant correlation was not demonstrated between the lunate type and type of triquetrum, hamate or triquetro-hamate joint. Further research is required to determine the association between the morphology of the triquetro-hamate joint and the remainder of the carpus.

The overall significance of the triquetro-hamate paper is that it more accurately defines the hamate, triquetrum and triquetro-hamate joint and identifies that there are two main types of joint, which are part of an overall spectrum of the normality of this joint. Taken together, these two papers demonstrate that the normal wrist has a spectrum of morphological and kinematic patterns and characteristics. This spectrum confirms similar findings by other authors on the variability of the normal wrist (Craigien and Stanley, 1995; Fogg, 2004; Nuttall et al., 1998; Viegas, 1990). Further work is required to better understand the spectrum of differences and what the kinematic and clinical significances of these differences are. Furthermore, we need to better appreciate how we should treat each different wrist type.



## 6.3 Imaging

### 6.3.1 Longitudinal CT scan of the scaphoid

At the commencement of this work it was common for the clinician to only use plain radiographs for the clinical and pre-operative assessment of scaphoid fractures. Assessment of the scaphoid deformity could be performed with the intra-scaphoid angle using trispiral tomography (Amadio et al., 1989).

There is now a standardised way of performing a longitudinal CT scan of the scaphoid, which is comfortable and does not require the use of an immobilisation device. The “target sign” provides objective evidence that the scanning plane is along the line of the longitudinal axis of the scaphoid. Scanning in radial deviation is more comfortable, rotates the scanning plane away from the radius and accentuates the humpback deformity.

In the paper on the humpback deformity, two new methods of assessment of the humpback deformity were developed. Both the height-to-length ratio and the dorsal cortical angle were shown to provide superior reliability compared to the intra-scaphoid angle (Amadio et al., 1989). The baseline values for normal scaphoid height-to-length ratio and the dorsal cortical angle have also been documented.

For the surgeon, it is critical to understand the scaphoid deformity when planning treatment. The development of pain, stiffness and degenerative arthritis are known to be related to scaphoid deformity (Amadio et al., 1989). Having reliably identified the scaphoid humpback deformity, the surgeon then needs to consider correction of the deformity. Fernandez developed the templating technique for planning correction of scaphoid deformity utilising plain radiographs and tracing paper (Fernandez, 1984). The templating method using longitudinal CT scanning prepares the surgeon pre-operatively for correction of the deformity.

In the post-operative period, CT scan assessment to confirm fracture union has been recommended by the author. There are some cases with a non-union in which interpretation of fracture union can be difficult. The description of the partial volume averaging method explains some of those cases in which there was a difference of opinion regarding fracture union.

The significance of the CT scan papers is that there are now standardised methods of performing CT scans, and reliable methods of assessment of the humpback deformity as well as a method for planning correction of the deformity.

Since publication of the three papers on CT scans of the scaphoid, there have been considerable technical advances in imaging that have provided improvements in the clinical assessment of the abnormal wrist. To a large extent, these advances are related to improved data processing and improved computer technology. The advances have also included the development of helical CT scanning, which is faster, provides better resolution and can be easily reformatted. Three-dimensional CT scanning has developed into an imaging modality that can be useful. MRI scanning has also had considerable technical advances, in addition to the use of specialised wrist coils and intra-articular contrast (Mack, 2003, Rubin, 2005). As a consequence, the resolution of lesions of articular cartilage and intra-articular ligaments has improved significantly

There are a number of anatomical factors that affect the deformity of the scaphoid. Fracture location is important and has an effect on the incidence of the humpback deformity (Moritomo et al., 2000). Fractures proximal to the dorsal cortical ridge are stabilised by dorsal ligaments and prevent flexion of the distal scaphoid (Haase et al., 2007).

Pathological factors including avascular necrosis (AVN) are likely to also have an effect on fracture union and possibly deformity. A review is underway of a series of patients who have had tube saw biopsies (Sandow et al., 1992) performed of the proximal pole of the scaphoid at the time of surgical bone grafting (Smith, 2007). The pre-operative longitudinal CT scan is being correlated with the independently assessed histological findings (Ficat, 1985). Post-operative CT scans have been utilised to assess fracture union. The dorsal cortical percentile is a new method of assessment of scaphoid fracture location (Figure 6.5) and has been demonstrated to be associated with the incidence of avascular necrosis (Figure 6.6, 6.7). Intra-observer and inter-observer variability stabilisation studies have been demonstrating good reliability of this new radiological parameter. The correlations to fracture site, radio-density of the proximal pole, comminution and other radiological criteria have been assessed.

NOTE: This figure is included on page 144 of the print copy of the thesis held in the University of Adelaide Library.

**Figure 6.5** - The dorsal cortical percentile. A baseline is drawn along the volar aspect of the scaphoid. Perpendicular lines are drawn at the proximal and distal limits of the scaphoid. A dorsal line completes the box. A line is drawn through the fracture. Where the fracture line intersects, the dorsal line is identified. The distance from the proximal line to the fracture line (P) is measured. The distance from the fracture line to the distal line is measured (D). The dorsal cortical percentile is calculated and recorded as a percentage.  $(P/P+D)$ . Image from Michael Smith.

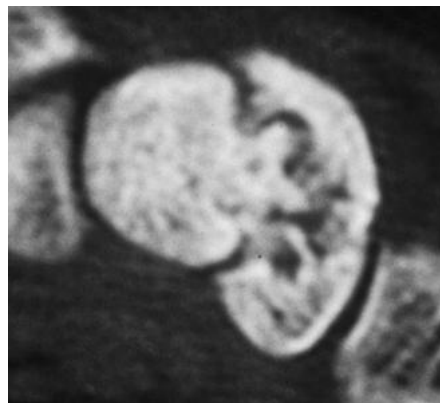
NOTE: This figure is included on page 145 of the print copy of the thesis held in the University of Adelaide Library.

**Figure 6.6** – Normal scaphoid bone. Histology of osteocytes can be visualized within the lacunae. The fatty marrow between the trabeculae is structurally intact and viable. Image from Chris Carter.

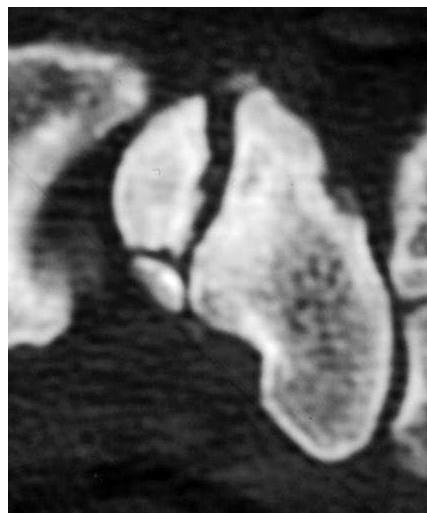
NOTE: This figure is included on page 145 of the print copy of the thesis held in the University of Adelaide Library.

**Figure 6.7** - AVN scaphoid. Histology of necrotic scaphoid bone as indicated by empty lacunae, appositional new bone growth and granulation tissue replacing the marrow. Image from Chris Carter.

The presence of some bridging trabeculi across the fracture was found to be protective for AVN (Figure 6.8). In contrast, some scaphoids appeared to be a pseudo-arthritis with clearly separate fragments (Figure 6.9). This is of considerable interest owing to its association with the published concept of partial volume averaging (Figure 4.6) (Bain, 1999). This concept was initially used to explain how different observers would interpret an incomplete union of a scaphoid fracture. It is important to note that the scaphoid fracture with minimal bridging trabeculi may be an artefact of the way the CT scan processes the information to produce an image and may represent a non-union.



**Figure 6.8** – Bridging trabeculi. CT scan with some bridging trabeculae between the proximal and distal fracture fragments.



**Figure 6.9** – Pseudo-arthritis of the scaphoid. Clearly separate fragments with no bridging trabeculi. Note increased radio-density of proximal pole.

The author now believes that the patient with the minimal bridging callus has a fibrous union, consistent with a report by Slade et al and not a pseudo-arthrosis (Slade et al., 2003). This is an important distinction. It is a fibrous union but not an osseous union. It is an important subgroup of non-union. Slade et al reported the use of arthroscopy in the assessment and management of scaphoid fibrous non-union. CT scanning demonstrated a well-aligned fracture with minimal sclerosis (<1mm) and no cyst formation. Arthroscopy was used to confirm reduction and the presence of an intact cartilaginous envelope. The fracture was seen as a dark line on the articular cartilage and probing revealed a firm fibrous union. These authors recommended percutaneous compression screw fixation without bone grafting and had 100% union at 14 weeks. This shows the importance of identifying this subgroup as they have a protected vascularity and fibrous stability. The fracture should not be taken down, bone graft is not required and the prognosis with surgery is excellent. However, the natural history of this group remains unknown.

This is an interesting example of the extension of the work in the thesis, the advances over this time and how they relate to the literature. The current AVN study has encouraged the author to re-think a point of view held for 10 years. New original work considered in the light of the recent literature has led to a new interpretation of an old concept.

Concepts used in this case include advanced imaging to understand the scaphoid morphology, the use of diagnostic arthroscopy to visualise and palpate the scaphoid, and the use of fluoroscopy to insert the screw into the scaphoid using a percutaneous technique. These concepts highlight many of the principles developed in the thesis.

### 6.3.2 Fluoroscopy

The advances in fluoroscopy have been interesting. Although there have been technical advances, it is the clinical utilisation of fluoroscopy that has been important. Fluoroscopy has become a dynamic modality to assess the kinematics of the wrist.

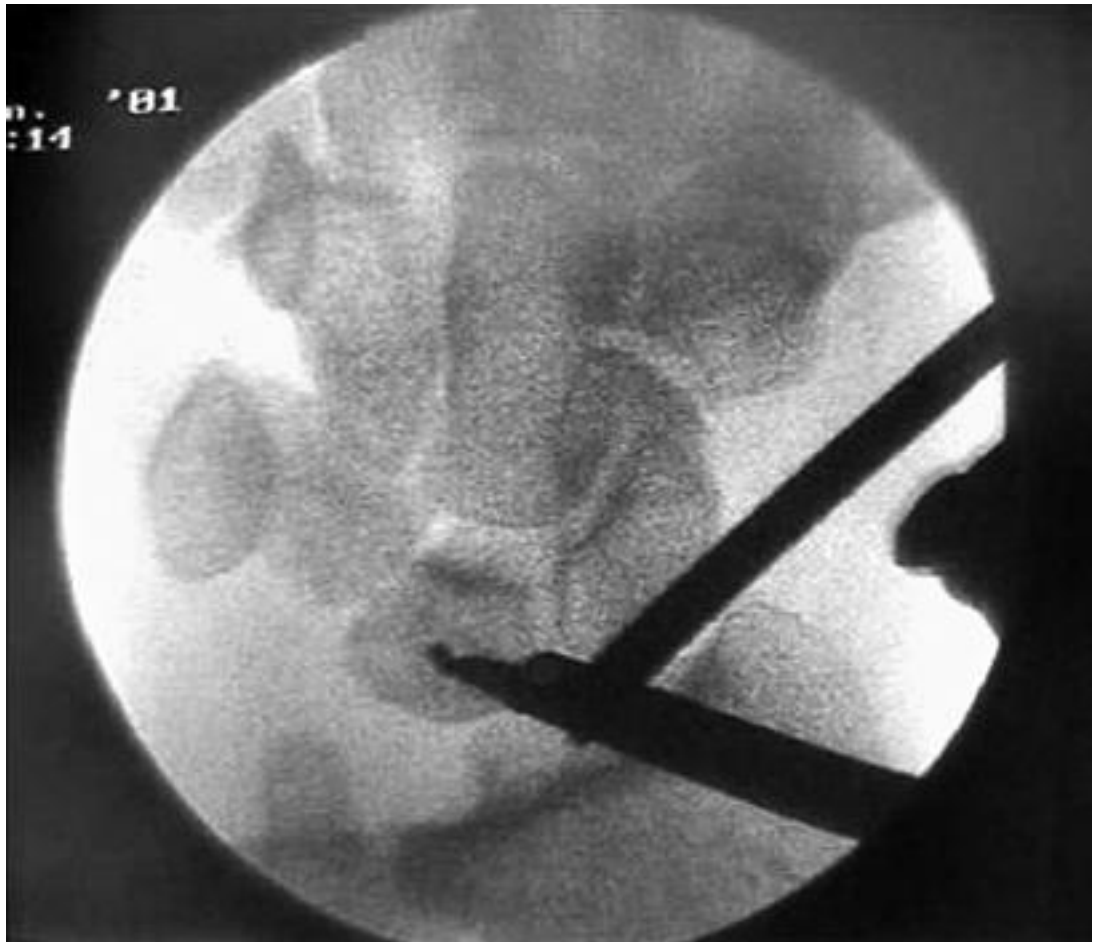
The single fluoroscopic image provides the assessment of the morphology of the skeletal anatomy. Having two views performed, with one being a stress view, gives an understanding of single plane instability. Dynamic fluoroscopy performed by the surgeon provides a dynamic understanding of the kinematic anatomy.

Fluoroscopy has been important in the development of wrist surgery in the kinematic assessment of joint and skeletal stability. It was used initially for confirmation of carpal instability (Braunstein et al., 1985; Protas and Jackson, 1980; White et al., 1984). However, this was usually performed by a radiologist in the radiology department. The author has used it for assessment of mid-carpal instability. However, there have been cases of ulnar translocation of the radiocarpal joint, scapho-lunate and distal radio-ulnar joint instability, for which it was used to confirm the diagnosis. The treating surgeon assesses the instability. The understanding is in the detail of the assessment. Assessment includes the direction of instability, whether the joint can be dislocated, subluxated and reduced. Other factors include the force required to produce and reduce the instability and whether the reduction is congruent and remains stable.

Fluoroscopy was valuable in the assessment of fracture stability following insertion of internal fixation. If the fracture configuration was found to be mobile following fixation then a further level of stability was required (e.g. more K-wires or an external fixateur). The use of the intra-operative fluoroscopic assessment of stability in subsequent cases avoided this complication, by identifying these cases and then utilising additional operative fixation.

Dynamic fluoroscopy was used for the management of stylo-carpal impaction. By performing a provocation test under fluoroscopic guidance, it becomes an important diagnostic imaging modality. A positive test is if the patient has reproduction of the pain when the ulnar styloid impacts in the carpus. As a pre-operative assessment the diagnosis of this uncommon condition could be confirmed or refuted. Dynamic fluoroscopy is now an important diagnostic tool that directs surgical selection and practice. Therefore the role of fluoroscopy has been extended since the publication of the relevant paper in this thesis.

Fluoroscopy is the dynamic component of imaging that can assess the kinematic component of the normal and abnormal anatomy. Therefore another part of the puzzle is better understood, as the surgeon can assess skeletal morphology with computed tomography and kinematic anatomy with fluoroscopy. The combination of fluoroscopy and arthroscopy has been a major factor in extended the practice of arthroscopy (Figure 6.10). The limitation of resolution of the fluoroscopic image remains a problem and for this reason arthroscopy remains a superior modality to confirm anatomical reduction of the articular surface.

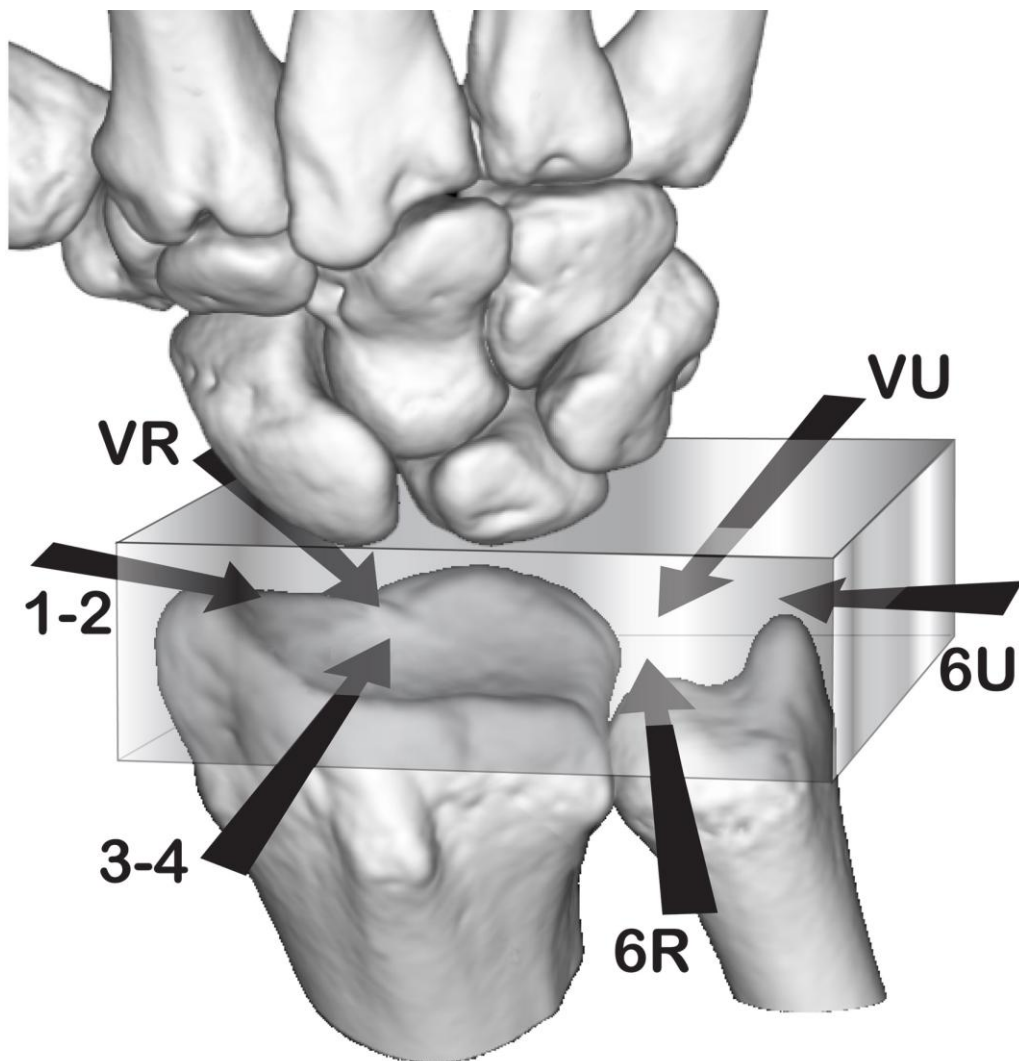


**Figure 6.10** - Fluoroscopic image confirms position of the drill bit, which has been placed into the lunate under arthroscopic vision.



## 6.4 Arthroscopy

The thesis describes considerable advances in the practice of arthroscopy. The description of new portals has extended the indications for arthroscopic surgery of the wrist. This is in part due to the way the portals are used and interchanged. The author refers to this as the “box concept”. The Box concept is that the joint is like a 3D box, with the scope and instruments that can enter the box from multiple different directions (Figure 6.11). The position of the scope and instruments can be changed to allow the scope and instrument to be optimally positioned. Therefore the surgeon can extend the surgical therapeutic possibilities as almost all parts of the joint can be visualised and instrumented.



**Figure 6.11** – “Box concept”. The arthroscopic 3D box with the multiple arthroscopic portals for viewing and instrumentation. This allows therapeutic surgery in any part of the joint. Image from private file.

#### 6.4.1 Kienböck's disease

For diagnostic arthroscopy, the main area of advancement has been with the assessment of Kienböck's disease. The arthroscopic changes have been documented. It was the author's experience that plain radiographs underscored the severity of the articular involvement identified at arthroscopy. An arthroscopic classification was developed based on the spectrum of arthroscopic observations. From this classification, the recommendations for subsequent treatment were outlined. A problem encountered by the author was the inability to fulfil an initial aim of relating the arthroscopic findings to the radiological findings. This is because many of the radiographs were disposed of by the institutions in which the patients were managed. Therefore future work will require the correlation of arthroscopic and radiological findings in patients with Kienböck's disease. Future work is also required to determine the natural history of the articular findings in Kienböck's disease.

#### 6.4.2 Distal radius fractures

Arthroscopy provides a superior assessment of the articular surfaces of the wrist. The paper on arthroscopic management of distal radius fractures confirmed fracture displacement despite an apparent fracture reduction using fluoroscopy. There was a high incidence of osteochondral and ligament injuries of the carpus which were not evident on pre-operative plain radiographs. Other authors have also reported the superior assessment of articular reduction with arthroscopy (Ruch et al., 2004).

A principle aim of the study was to obtain an anatomical reduction of the articular surface with the assistance of the arthroscopic vision. Knirk and Jupiter and later Melone have directed the clinician to accept a step in the articular surface up to 2mm (Bain et al., 1996; Knirk and Jupiter, 1986). The author has demonstrated that the incidence of pain is significantly related to the size of the step. The author recommended that a principal aim of managing intra-articular fractures should be to restore the normal anatomy, aim at articular congruity (i.e. 0mm step) and accept only a step of <1mm. This finding is important as it demonstrates that the step in the articular surface not only affects the radiological outcome (Knirk and Jupiter 1986), but also the subjective outcome.

The secondary aim of treatment was to perform the procedure using minimally invasive techniques. A five-level algorithm was developed with this aim in mind. It uses K-wires were possible to stabilise the fracture. The use of these methods minimises the need to open the

fracture. With arthroscopic management of distal radius fractures there were cases with a volar fracture for which satisfactory stability could not be obtained using the methods initially planned for the study. Limited open volar techniques were developed during the course of the study to overcome the volar instability that can occur. The importance of the fluoroscopy in the assessment of fracture stability as part of this technique has already been stated. Although minimally invasive procedures have low morbidity, it must not be at the expense of joint stability.

Other papers have also identified a high incidence of associated soft tissue injuries with distal radius fractures (Freeland and Geissler, 2000; Geissler et al., 1996; Lindau et al., 2003; Richards et al., 1997; Ruch et al., 2004). In this series, patients with a grade 3 or 4 scapho-lunate injury had a high incidence of persistent diastasis despite percutaneous K-wire fixation (persistent diastasis: 0% grade I & II, 42% grade III, 100% grade IV). Other unpublished work by the author on acute scapho-lunate ligament injuries also demonstrated persistent diastasis of the scapho-lunate interval despite K-wire fixation (Bain and Duncan, 2003). For these reasons, the author no longer performs percutaneous fixation of scapho-lunate ligament injuries, preferring an open repair or reconstruction depending upon the severity of the injury.

Table 6.1 provides a summary of results of various authors at the time of publication. The high incidence of scapho-lunate instability in the author's series is due to the assessment method chosen. The author performed fixation based on instability (Geissler classification) (Table 2.4) and not the presence of a ligament tear. Grades I and II are probably within the limits of normal and ultimately obtained a normal scapho-lunate interval. Grades III and IV are significant instabilities, but are not stabilised with percutaneous fixation techniques.

**Table 6.1 - Arthroscopically Assisted Reduction of Distal Radius Fractures. Adapted from Mehta et al., 2000.**

Author	Total Cases	TFC tears (%)	SL tears (%)	LT tears (%)	Osteo-chondral lesion (%)	Results (G & W)
Hanker GJ 1996	77	65	14	6	18	No results
Roth JH et al 1995	118	39	18	12	-	No results
Geissler WB et al 1996	60	43	32	15	-	No results
Culp RW & Osterman AL 1995	27	54	55	23	42	10E,12G,5F
Wolfe SW et al 1995	7	-	-	-	-	7E
Mehta and Bain 2000	26	58	85	61	19	11E,7G,6F,2P

G&W-Gartland and Werley criteria

E-excellent, G-good, F-fair, P- poor

Minimally invasive techniques are likely to continue to evolve to reduce surgical morbidity. The overall significance of the paper is that it increases the surgical options of treatment, with the development of new techniques, to manage distal radius fractures. The outcomes for scapho-lunate ligament injuries are an important subgroup of the study. The recommendations with regard to the size of the residual articular step are a new guide to management of distal radius fractures, whether they be managed by closed, arthroscopic assisted or open means.

Since completing the arthroscopic study on distal radius fractures, there has been the introduction of volar locking plates (Orbay, 2000; Orbay and Fernandez, 2002; Orbay and Fernandez, 2004). These have been popular as they stabilise the majority of complex fractures. The author now uses the volar locking plates for the majority of fractures that require surgery.

It is the author's opinion that there is still a place for wrist arthroscopy in the management of complex fractures. These include, firstly, those cases where there is some doubt (following fluoroscopic assessment) as to whether the screws could be intra-articular. The arthroscope can be introduced via a volar portal using the existing open volar surgical approach. Assessment of the articular reduction and associated soft tissue ligamentous injuries can also be performed (Levy and Glickel, 1993). Secondly, wrist arthroscopy is useful for complex fractures in the higher demand patients, in which there is greater concern regarding the fracture reduction and scapho-lunate ligament instability. Thirdly, the arthroscopic technique remains the preferred technique in those cases with an isolated radial styloid fracture, as it allows percutaneous fracture fixation and assessment of the scapho-lunate interval.

The author believes that future work is required to determine the role of wrist arthroscopy in conjunction with fixed angle volar plate fixation. After all, imaging of the articular surface is difficult with fluoroscopy and an articular step of >1mm can be associated with an increased incidence of pain and arthritis (Knirk and Jupiter, 1986; Mehta et al., 2000)(2122, 8513). It may be that a greater percentage of cases should have arthroscopy included to assist with optimisation of fracture reduction.

Wrist arthroscopy is now a valuable adjunct in the management of intra-articular distal radius fractures, both in the assessment of associated intercarpal ligament injury and improving the quality of joint surface reduction (Freeland and Geissler, 2000; Geissler et al., 1996; Lindau et al., 2003; Richards et al., 1997; Ruch et al., 2004). The role of arthroscopy has subsequently

been confirmed to be superior to intra-operative fluoroscopy and plain x-ray in assessing joint surface reduction (Edwards et al., 2001). Patients with arthroscopically assisted reduction of intra-articular distal radial fractures have been shown to have superior clinical outcomes, better range of motion and improved radiological variables (displacement and angulation) compared to a fluoroscopic assisted reduction (Ruch et al., 2004).

#### 6.4.3 STT Arthritis

The aim of the STT joint paper was to develop and report a safe and effective therapeutic method of arthroscopic management of STT joint arthritis. This paper was the first peer reviewed paper in the literature to investigate the outcome in this group of patients (Ashwood et al., 2003). The paper included a cadaveric study on the proximity of the neurovascular structures to the STT joint. By following the guidelines provided, the technique can be safely performed. The arthroscopic observations demonstrated the presence of eburnated bone on the distal scaphoid and proximal trapezium and trapezoid that were always extensive. These were more advanced than those expected from the cadaveric study reported by Moritomo et al. (Moritomo et al., 2000). It is likely that the clinically symptomatic cases that required surgery are more advanced than the cadaveric cases selected at random, which often reflect articular signs of aging.

A satisfactory outcome has been demonstrated based on an independent assessment of subjective and objective outcome measures. There was an improvement in pain, functional wrist score and grip strength. There were no complications or re-operations in the clinical series of 10 patients. The complication and re-operation rate of the arthroscopic procedure is better than that of the published results for STT arthrodesis and excision arthroplasty (Eiken, 1979; Garcia-Elias et al., 1999; Ishida and Tsai, 1993; Kaji et al., 1993; McAuliffe et al., 1993; Srinivasan and Matthews, 1996). High rates of STT fusion non union, radiocarpal degenerative arthritis and neuroma formation have been reported. Pain, stiffness and re-operation were reasonably common. Excision arthroplasty of the STT joint has been reported to be associated with carpal malalignment, DISI deformity and pain.

In the author's view, the arthroscopic debridement of the STT joint should be the first-line surgical option for patients with STT joint arthritis. This is based on the fact that the arthroscopic procedure has a satisfactory clinical outcome and has a lower complication and re-operation rate than other reported open techniques.

The STT joint arthroscopic procedure does not further compromise the skeletal morphology. However, it provides symptomatic improvement for the majority of patients. In contrast, the STT fusion and excision arthroplasty are salvage operations of the STT joint, which by their nature do not return the normal joint morphology. Therefore the procedure brings with it the complications and morbidity of the open surgery and modifies the joint kinematics in a non physiological way (Garcia-Elias et al., 1989; Gellman et al., 1988; Short et al., 1992).

Arthroscopic debridement in the knee has been proven to be effective in some patients (Bert and Maschka, 1989; Dandy, 1991). The results in the STT joint have been better than those reported in the knee. In the knee the loads are considerable. Pain and a fixed flexion deformity will have a profound effect on gait and function. In the wrist the loads are much less (Viegas and Patterson, 1997) and restricted motion can be better tolerated (Palmer et al., 1985). The patient also has the potential to favour or bypass the use of the wrist and therefore can better tolerate a disability (Bialocerkowski et al., 2003). Longer-term clinical results are required to determine its overall efficiency.

The overall significance of this paper is that an arthroscopic debridement is a safe and efficient therapeutic technique for STT joint arthritis, with results superior to the historical controls of STT joint fusion and excision arthroplasty based on complication and re-operation rates. Arthroscopic treatment for STT joint has been successful in this small patient population. However, a longer period of follow-ups in a larger series is required to establish its position as a preferred treatment modality.

#### 6.4.4 Intra-osseous ganglion of the lunate

The study on the intra-osseous ganglion of the lunate was the first report on the role of arthroscopy in this condition. The subjective and objective assessments of the results have demonstrated satisfactory outcomes. The technique has been documented to be safe, based on the assessment of complications. The overall significance of the paper is that it reports a minimally invasive method of treating patients with intra-osseous ganglion of the lunate, thereby avoiding the morbidity and complications of the open surgical technique (Schajowicz et al., 1979; Tham and Ireland, 1992; Waizenegger, 1993).

As it is an uncommon condition there is only a small series of cases that have had the surgery. Assessment of a larger group of patients is required before the true position of this paper can be determined. However, the results of the open curette and bone graft have been complicated

by stiffness, as the procedure often requires an open capsulotomy and release to provide adequate exposure (Schajowicz et al., 1979; Tham and Ireland, 1992; Waizenegger, 1993). In fact, it was this complication that led to the impetus to develop the arthroscopic technique.

#### 6.4.5 Capsular release of the wrist

The capsular release procedures in the elbow and shoulder (Jones and Savoie, 1993; Richmond and al Assal, 1991; Warner et al., 1996; Warner et al., 1997) ( Warner et al., 1996; Warner et al., 1997) are now well accepted techniques. The paper on the arthroscopic management of contracture of the wrist is the first report on the role of arthroscopy for release at the wrist. Since publishing the paper on wrist contractures, the author believes that the classification of etiology of contractures should change to separate intra-articular and capsular causes as they have different etiology, treatment and prognosis. The author recommends the classification of contracture should be divided into three categories: intra-articular, capsular and extra-articular. This is a significant separation as patients with intra-articular causes (e.g. fractures, ligament injuries and degenerative arthritis) require intra-articular treatment and have a poorer prognosis. The capsular causes (e.g. capsular injury, immobilisation) can be managed with capsular release. The extra-articular causes (e.g. heterotopic ossification and musculotendonous contracture) require an open surgical approach.

Prior to commencing the procedure, a cadaveric and MRI study was performed to demonstrate the proximity of the major neurovascular structures to the volar capsule. No complications occurred in this small clinical series. However, the surgeon needs to be vigilant in view of the severity of complications that could occur. For this reason, cadaveric training is recommended before the surgeon undertakes this procedure. The author was concerned about the possibility of ulnar translocation of the carpus and followed the recommendations of the cadaveric study by Viegas (Viegas et al., 1995). The author has not witnessed this complication but it remains a potential concern. To minimise the chance of this disabling complication, the author now recommends that the radial half of the RSC ligament be left intact.

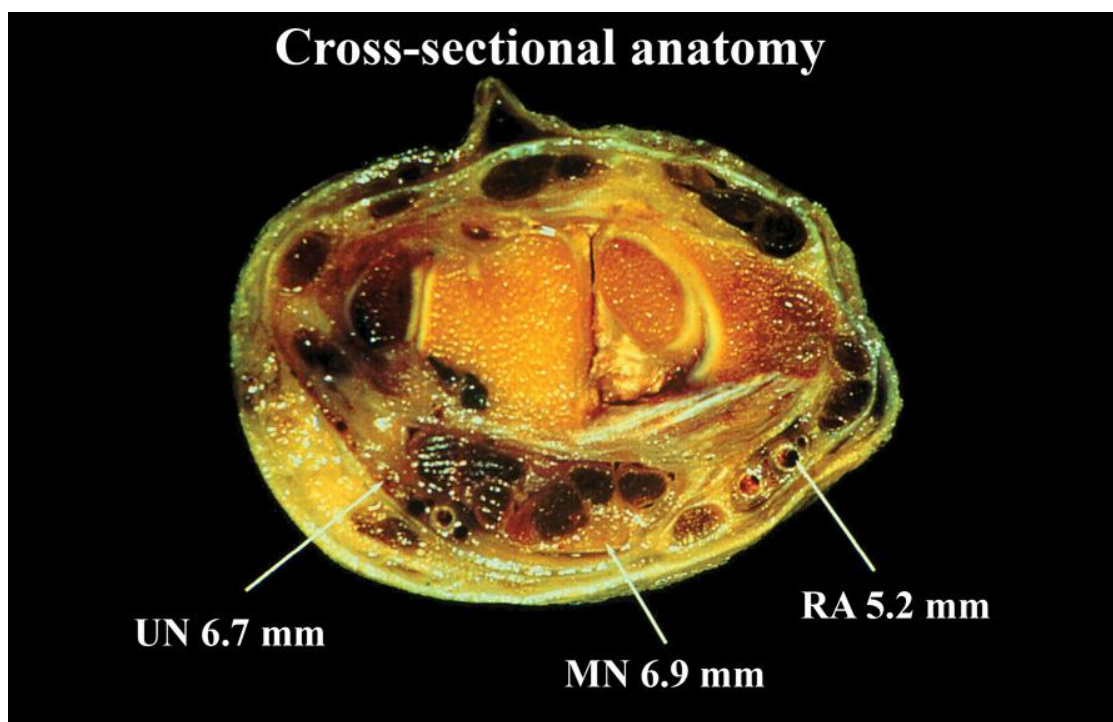
Contractures of the wrist are common, however most patients function well with a moderate contracture (Palmer et al., 1985)(5549). Therefore the majority of patients with contractures are treated with non-operative modalities. As a consequence, this technique has not been tested in a larger series. At present the author has made very tight recommendations of who



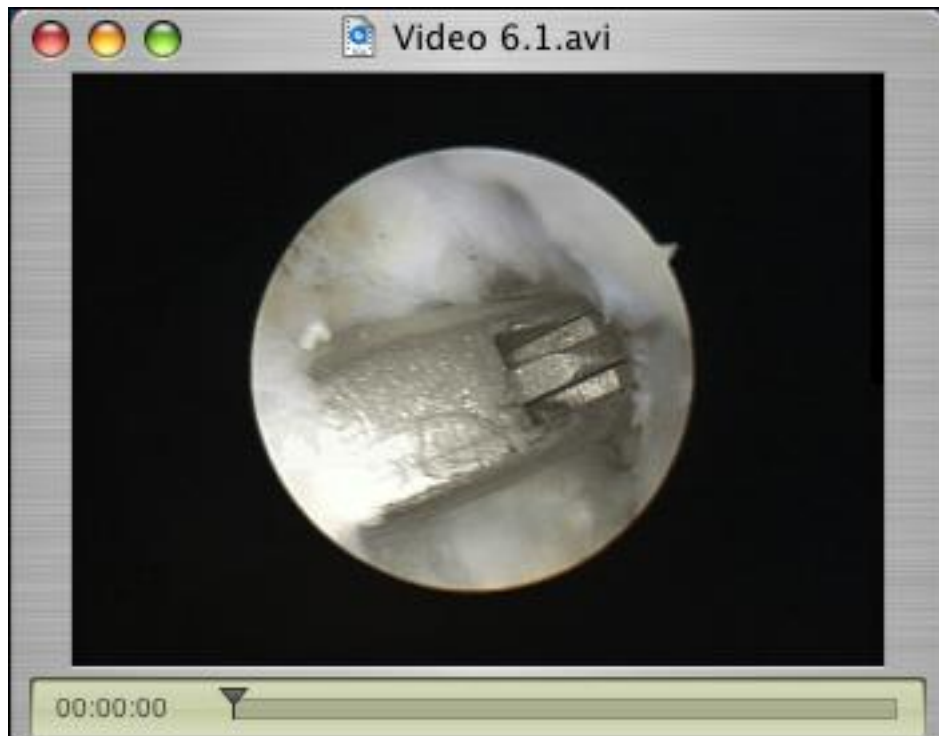should perform the procedure and in which patient population. However, as surgeons become more comfortable with advanced arthroscopic techniques and patient demands for improved function increases, the technique may become more commonly performed. The patients in this small series did improve their flexion from 17° to 47° and extension from 10° to 50° which has been maintained at longer follow-up. The grip strength also improved from 13 to 31kgs, which was thought to be due to the increased wrist extension.

The overall significance of the paper is the addition to the literature of a minimally invasive method of treatment for patients with wrist joint contracture that avoids the open surgical procedure and its morbidity and complications. The cadaveric study details the proximity of the major neurovascular structures to the volar capsule. A technique has been developed that is safe based on a cadaveric study and a small case series. Further studies are required to ensure the safety of this technique in the wider community.

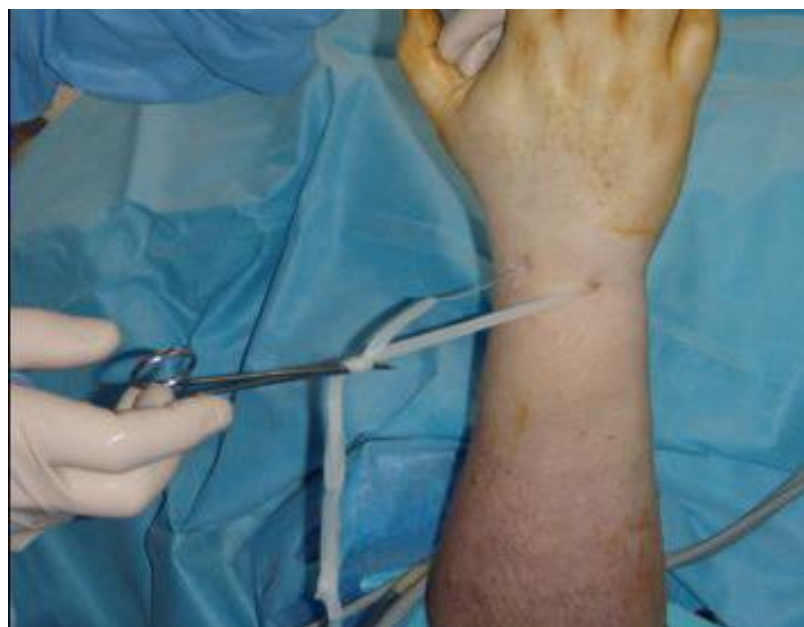The author has also performed an arthroscopic dorsal capsular release. The technique has been reported in a book chapter but requires publication with a series in peer review literature (Bergman and Bain, In Press). The dorsal capsule is in close proximity to the extensor tendons and is probably at greater risk of injury than the structures on the flexor side of the wrist (Figure 6.12). By using a nylon tape, which is railroaded between the extensor tendons and the dorsal capsule, the extensor tendons can be retracted to minimise the risk to the extensor tendons during the capsular release or excision (Video 6.1). The nylon tape is placed into the 3-4 portal on a curved artery clip and advanced to the capsule level so that it is deep to the extensor tendons. It is then “rail-roaded” to the 6R portal and retrieved (Figure 6.13). Traction on the tape will retract the extensor tendons. The best view of the dorsal capsule is via the volar portal, which looks directly at the dorsal capsule. (Video 5.5) Once a clear view is obtained the dorsal capsule is excised leaving the nylon tape and extensor tendons behind (Video 6.1).



**Figure 6.12** - Cross-sectional anatomy of the wrist at the level of radial tuberosity with relationship of major nerves, UN, ulnar nerve; MN, median nerve (just distal to pronator quadratus). From – Verhellen et al., 2000.



**Video 6.1** - Dorsal capsulectomy. Dorsal capsule being excised with the aid of basket forceps. In the background can be seen the white nylon tape retracting the extensor tendons.



**Figure 6.13** - Nylon tape used to retract the extensor tendon off the dorsal capsule. Image from private file.

#### 6.4.6 Stylo-carpal impaction

The paper on ulnar stylo-carpal impaction was the first report on the role of arthroscopy in this condition. It is a rare condition, so the author recommended extra steps be taken to ensure the correct diagnosis before proceeding with surgery. Performing the provocation manoeuvre under fluoroscopic control and a 3D CT scan in the provocation position was recommended.

The ulnar styloid is identified at arthroscopy with the assistance of fluoroscopy. The overall significance of the paper is the addition to the literature of a minimally invasive technique for management of ulnar stylo-carpal impaction that avoids the need to perform an open excision with its associated morbidity. As this condition is rare, and the diagnosis requires specific identification, only 4 cases have been performed.

#### 6.4.7 Complications

The technical difficulties of performing advanced arthroscopic techniques always remain a concern. An understanding of morphological and kinematic principles of anatomy is the key to development to safe and efficient surgical procedures. The use of pre-operative cadaveric studies (e.g. proximity of neurovascular structures), review of the literature to be able to specifically predict potential complications (e.g. ulnar translocation) and performing surgery in a cadaveric model, are all important in the development of new techniques.

Despite the relatively advanced surgical cases performed in a wide variety of pathologies, the incidence of complications was low and similar to that reported in the literature (Culp, 1999; Warhold and Ruth, 1995). There was a case of acute carpal tunnel syndrome following an arthroscopic assisted distal radius fracture. This was managed with an urgent open carpal tunnel release. Clearly this complication is a concern; however, it did not affect the long-term outcome of the patient.

Patients with arthroscopic management of distal radius fractures had the highest incidence of complications. This is in part due to the complexity of the injury and extravasation of fluid. The surgeon needs to be extra vigilant in management of these cases.

Joint stability is a key issue for open and arthroscopic joint surgery. At arthroscopy it remains a significant issue and one that must continue to be considered. The case of the distal radius fracture with persistent instability due to inadequate skeletal stabilisation is a good example.

Stability was considered a critical factor in the development of the arthroscopic capsular release procedure. It was also an important consideration when assessing which procedure to perform in a patient with STT joint arthritis. Arthroscopic excision arthroplasty of the distal scaphoid would be technically possible; however, this would produce a greater degree of carpal instability, as was witnessed with the open procedure (Garcia-Elias et al., 1999).

The author did perform arthroscopic radiofrequency capsular shrinkage for mid-carpal instability (Pathak and Bain, 2003). This technique was later abandoned by the author because of recurrence of the instability.

There were no cases of reflex sympathetic dystrophy (RSD) or septic arthritis in any series in this thesis. The author can not recall any case of RSD or septic arthritis in the 550 cases in the total data-base of arthroscopy.

#### 6.4.8 New published techniques

Many new techniques have been reported in the literature in the last 13 years, some by the author and many by other authors (Adolfsson, 2000; Adolfsson, 2005; Adolfsson and Frisen, 1997; Badia and Jimenez, 2006; Badia and Khanchandani, 2007; Carro et al., 2003; Chen et al., 2005; Culp et al., 1997; Darlis et al., 2006; Gobel et al., 2004; Hagen and Aaser, 1998; Harley et al., 2004; Hirsh et al., 2005; Ho et al., 2003; Luchetti and Andrea, 2003; Menth-Chiari and Poeling, 2000; Nagle, 1999; Nagle and Geissler, 2001; Osterman, 2001; Ruch et al., 1998; Sagerman and Short, 1996; Shih et al., 2005; Slutsky, 2002; Slutsky, 2005; Sweet and Weiss, 2001; Thurston and Stanley, 2000; Weil et al., 2006; Weiss et al., 1997; Wiesler et al., 2006). The indications for arthroscopy can be considered as diagnostic and therapeutic. Table 2.1 provides a list of indications for wrist arthroscopy written by the author in 1994, at the commencement of the thesis, and subsequently published in 1997 (Bain et al., 1997).

Table 6.2 provides a current list of indications for wrist arthroscopy. It includes the newer techniques of wrist arthroscopy and separates them into sections for the soft tissue and bone. It also separates them into technique related groups to highlight the complexity of the surgery performed.

**Table 6.2 - Current Indications for Wrist Arthroscopy 2007**

	Soft Tissue	Bone
Diagnostic	Wrist pain of unknown origin Synovial biopsy	Assessment of instability Staging of Kienböck's disease* Staging prior to limited wrist fusion
"Ectomy" Procedures	Bacterial sampling, drainage and joint lavage Dorsal and volar ganglions Intra-osseous ligaments Synovectomy Triangular fibrocartilage complex (TFCC) tears Articular cartilage lesions	Distal ulnar (wafer procedure) Ulnar styloid* Lunate Os central carpi Pisiform Proximal pole of scaphoid Distal pole of scaphoid Proximal row carpectomy STT Joint debridement* Hamate
Tissue Shrinkage	Capsular shrinkage Ligament shrinkage	
Surgical release	Volar capsular release* Dorsal capsular release*	
Drilling		Drilling of intra-osseous ganglion of the lunate*
Repair procedures including osseous percutaneous fixation	TFCC suture Dorsal radiocarpal ligament	Distal radius fractures # Peri-lunate dislocation Scaphoid fractures Scapholunate pinning Lunotriquetral pinning
Reconstructive procedures	SL ligament reconstruction^ DRUJ stabilisation^	Bone graft to scaphoid non-union Limited wrist fusion Full wrist fusion^

\*Described by the author. # Contribution provided by the author. ^ Future work planned

It is most interesting to compare these two tables and note the significant advances that have occurred in this 13-year period. The areas in which the author has described the technique, made a contribution to the literature or has future work planned are marked.

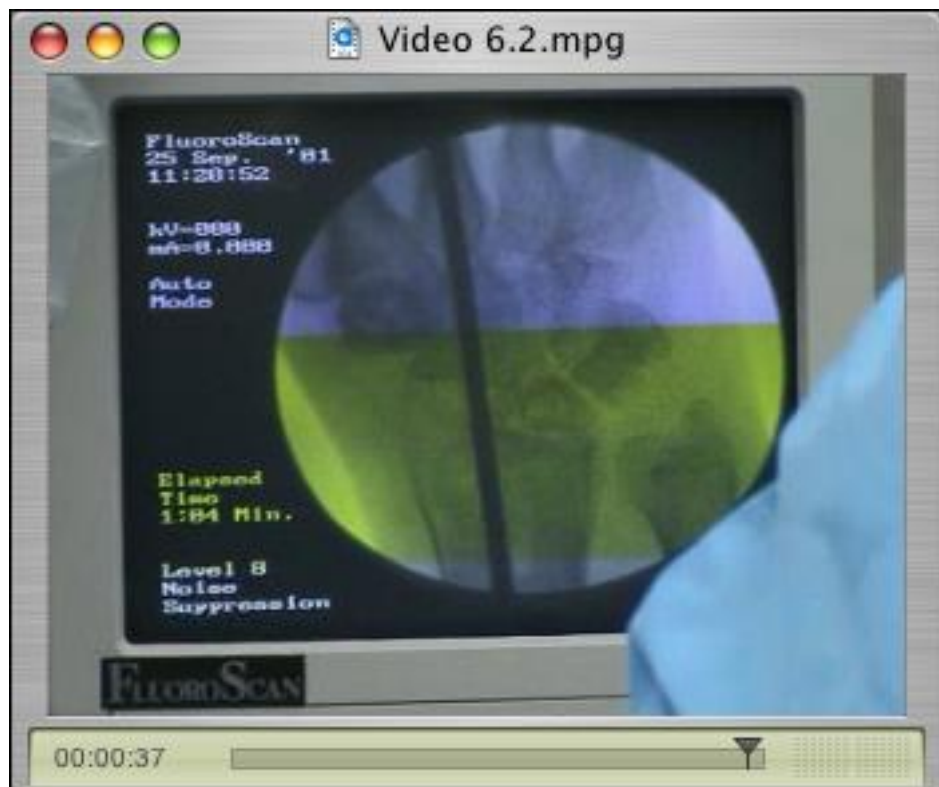The arthroscopic papers have demonstrated the importance of diagnostic arthroscopy to identify the detail of the articular surface as documented in the reduction of distal radius fractures and assessment of the articular changes in Kienböck's disease. The importance of arthroscopy as a diagnostic modality is supported by other papers in the literature (Cooney et al., 1990; Freeland and Geissler, 2000; Geissler and Freeland, 1996; Geissler et al., 1996; Lindau et al., 2003; Richards et al., 1997; Roth and Haddad, 1986; Ruch et al., 2004).

The importance of using a minimally invasive technique is highlighted in the paper on management of STT joint arthritis, where the reduced complications and re-operation rates are better than historical controls. Its use is likely also to be important in the surgical management of intra-osseous ganglion of the lunate, wrist joint contracture and ulnar stylo-carpal impingement.

#### 6.4.9 New arthroscopy techniques

The author has performed a full wrist fusion in a rheumatoid patient (Video 6.2). This involves arthroscopic synovectomy and debridement of the radiocarpal and mid carpal joints. A Steinman pin is advanced through the shaft of the 3<sup>rd</sup> metacarpal and into shaft of the radius. Bone graft is harvested from the iliac crest and added to the joints via the arthroscopy portals. Arthroscopy assisted scapholunate ligament reconstructions have also been reported by (Ho et al., 2007). The author has performed arthroscopy assisted ligament reconstruction of the scapholunate instability in a cadaveric model. The author has explored the options of an open sigmoid notch osteoplasty with an arthroscopic assisted DRUJ stabilisation procedure (Wallwork and Bain, 2001). The ligament reconstruction was modelled on the Adams DRUJ reconstruction (Adams and Berger, 2002).





**Video 6.2** - Radiocarpal fusion. Bone graft harvested from distal radius and placed into debrided radiocarpal and mid-carpal joints. Steinman pin advanced from 3<sup>rd</sup> metacarpal into radius.

#### 6.4.10 Outcome measures

Further work is required in this area on outcome measures. Patient-rated outcome measures should be the foundation of assessment; after all it is the patient's wrist. The Adelaide questionnaire is an outcome tool that utilises patients' opinions in the assessment of the wrist. It was developed by Andrea Bialocerkowski in her PhD thesis (Bialocerkowski, 2002; Bialocerkowski et al., 2000; Bialocerkowski et al., 2003; Bialocerkowski et al., 2003). The author of this thesis was the supervisor of her thesis and co-author of the published material. The author has started to utilise this assessment tool to provide patient derived data when assessing disorders of the wrist (Bialocerkowski and Bain, 2007).

When performing surgery it is important that we have assessment tools that are related to the surgical outcomes and clinically based patient derived outcomes. Having observed the results obtained from surgery, the onus is then on the surgeon to assess the clinical outcome based on these modalities. When the surgeon assesses the outcome of these patients it is important to go back to the primary anatomy to identify whether the reconstructive procedures have in fact improved the symptomatic and functional outcome required for the patient.

## 6.5 Summary

The work described in this thesis has addressed the perceived deficiencies in the knowledge of wrist anatomy, imaging and arthroscopy that limited the surgical treatment of wrist disorders. The thesis encompasses studies of normal anatomy, imaging of the abnormal wrist, and the development of wrist arthroscopy.

The problem areas identified which were addressed included (i) the morphology and kinematics of the normal wrist, (ii) imaging of scaphoid deformity and the clinical application of fluoroscopy in the management of the wrist disorders and, (iii) surgery of the wrist, which was usually performed as an open procedure, and the clinical application of wrist arthroscopy, which was in its first decade of development.

To address these deficiencies, a radiological study was undertaken to determine how the morphology of the lunate affected the kinematics of the scaphoid. Lunate morphology was demonstrated to be associated with scaphoid kinematics. The result of this finding is that it is now possible to predict scaphoid kinematics because lunate type can be determined from plain radiographs. An anatomical study of the triquetro-hamate joint was undertaken to determine the morphology of this joint and whether it is related to the lunate morphology. Two types of triquetro-hamate joint were identified but these were not associated with the morphology of the lunate. One type had a helicoidal configuration and the other was relatively flat. Further research is required to determine the effect of these morphological differences on wrist kinematics.

To image deformity of the scaphoid, a standardised method of longitudinal computed tomography was developed. An inter-observer reliability study was undertaken to compare the previously reported intra-scaphoid angle to newly developed methods of assessing the humpback deformity. The height-to-length ratio and dorsal cortical angle were found to be more reliable than the intra-scaphoid angle. The concepts of partial volume averaging for the assessment of scaphoid fracture union and pre-operative templating of correction of scaphoid deformity were described. Further research has commenced to assess the association of pre-operative radiological factors to avascular necrosis and clinical outcome measured by fracture union.

The role of arthroscopy was investigated in a number of clinical conditions. Patients with Kienböck's disease were assessed to determine whether characteristic patterns of articular

changes could be identified at arthroscopy. Based on the findings, a classification of these arthroscopic findings was developed and used to direct future treatment. A study of arthroscopically assisted reduction of distal radius fractures was undertaken, which included development of new arthroscopically assisted and mini-open reduction and fixation techniques. Post-operative articular deformity was found to be associated with an increased incidence of pain. Arthroscopic debridement for STT joint arthritis was demonstrated to be a safe and effective treatment with a lower complication and re-operation rate than previously reported open procedures. New arthroscopic methods of capsular release of the wrist, arthroscopically assisted drilling of intra-osseous ganglion of the lunate and arthroscopic debridement of the ulnar styloid were developed. The use of fluoroscopy has developed as a diagnostic tool and is a valuable adjunct to arthroscopy.

The work described in this thesis increases the knowledge of the normal wrist morphology and imaging. It further advances the role of arthroscopy in the treatment of wrist conditions.

## **LIST OF TABLES**

This section provides a list of all of the tables within the thesis.

Table 2.1 - Indications for Wrist Arthroscopy 1996

Table 2.2 - Arthroscopic Wrist Portals

Table 2.3 - TFCC Injuries – Palmer’s Classification

Table 2.4 - Geissler Arthroscopic Classification of Carpal Instability

Table 6.1 - Arthroscopically Assisted Reduction of Distal Radius Fractures

Table 6.2 - Current Indications for Wrist Arthroscopy 2007

## LIST OF FIGURES

This section provides a list of all of the figures within the thesis. The first number is the chapter in which the figure is referenced.

**Figure 1.1** - Drawing from a medieval text shows omission of the carpus.

**Figure 1.2** - First radiological image created by Roentgen in 1895. It shows the osteology of the hand but omits to include the wrist. Image from National Library of Medicine, Public domain.

**Figure 1.3** - An open volar approach to a large intra-osseous ganglion of the lunate. With this exposure through the floor of the carpal tunnel the patient developed a contracture of the wrist. This complication raises the question, how to treat this complication and how to prevent it. Image from private file.

**Figure 2.1** – Type 1 lunate. Wrist radiograph of a type 1 lunate, note the single distal articular facet of the lunate.

**Figure 2.2** – Type 2 lunate. Wrist radiograph of a type 2 lunate, note the double distal articular facet of the lunate.

**Figure 2.3** – Cadaveric right wrist. Mid-carpal joint with type 2 lunate. Note the large radial sided facet of the lunate (L) and small ulnar sided facet of the lunate (arrow). The hamate (H) articulates with the ulnar facet of the lunate and the triquetrum (T). The capitate (C) articulates with the scaphoid and the radial facet of the lunate. From – Viegas et al., 1990.

**Figure 2.4** - Wrist radiograph with a type 1 lunate. Note the large radius of curvature of the capitate which articulates with the scaphoid and single facet of the lunate and triquetrum. From – Nakamura et al., 2000.

**Figure 2.5** - Wrist radiograph with a type 2 lunate. Note the small radius of curvature of the capitate. Which articulates with the scaphoid and the radial facet of the lunate but not the ulnar aspect of the lunate or triquetrum. From – Nakamura et al., 2000.

**Figure 2.6** - Histological view of the carpus including the scapho-lunate ligament. From – Fogg, 2004.

**Figure 2.7a,b** – Dorsal view of a right scaphoid. With the rotating scaphoid there is a single dorsal ridge for insertion of the radioscaphoid (RS) ligament. In the flexing scaphoid there are 3 ridges for insertion of the radioscaphocapitate (RSC) and dorsal intercarpal ligament (DIC). The middle ridge is for attachment of the radioscaphoid (RS) ligament. Adapted from – Fogg, 2004.

**Figure 2.8** – Lateral 3-D view of right scaphoid. In the rotating scaphoid (left) the radioscaphoid (RS) ligament attaches to the dorsal ridge of the scaphoid. The radiocapitate (RC) and dorsal intercarpal ligament (DIC) bypass and encircle the scaphoid. These act like a pulley and help control the position of the scaphoid but allow rotation. In contrast, in the flexing scaphoid (right), the radioscaphocapitate (RSC) ligament attaches to the scaphoid as does the dorsal intercarpal ligament (DIC) and act as rotatory restraints but allow flexion. From – Fogg, 2004.

**Figure 2.9** – Diagrams of a left scaphoid looking from the radial aspect. Stylised diagram of the rotating and flexing scaphoid. Note in the rotating scaphoid that the dorsal intercarpal ligament (DIC) and radioscaphocapitate (RSC) do not attach to the scaphoid but act as a pulley. The volar scapho-trapezo-trapezoidal (STT) ligament has a narrow base on the scaphoid which helps to act as a point of rotation around which the scaphoid rotates. In contrast with the flexing scaphoid, the STT ligament has a wide base on the scaphoid. The radioscaphocapitate ligament (RSC) has an attachment to the scaphoid waist, over which it flexes.

**Figure 2.10** – Dorsal anatomical cadaveric dissection of a left scaphoid comparing the two types. In the rotating scaphoid the dorsal intercarpal ligament (DIC) has a loose membranous (M) attachment to the scaphoid before passing onto the trapezium (Tm). In contrast in the flexing scaphoid the DIC has a strong attachment to the scaphoid and does not extend to the trapezium. From – Fogg, 2004.

**Figure 2.11** – Cadaveric coronal section of a right wrist. Type 1 lunate which articulates with a unicondylar mid-carpal joint. This is similar to a hip joint. From – Fogg, 2004.

**Figure 2.12** – Cadaveric coronal section of a right wrist. Type 2 lunate with a radial facet which articulates with the capitate and the ulnar facet which articulates with the hamate. This creates a bicondylar mid-carpal joint which is similar to a knee joint. From – Fogg, 2004.

**Figure 2.13** - Correlation of scaphoid inclination index to scaphoid flexion index. From - Garcia-Elias et al., 1995.

**Figure 2.14** - Radiographic measurements obtained in order to calculate the scaphoid indices. From – Garcia-Elias et al., 1995.

**Figure 2.15** – Radiographical views of the right scaphoid. Percutaneous electrical stimulation was used to achieve union in this angulated scaphoid fracture. Seven years later, significant degenerative change associated with pain and limited extension caused the patient to return for re-evaluation. **A**, Anteroposterior view, note retained stimulation wire; **B**, lateral view; **C**, lateral tomogram, note improved detail of scaphoid anatomy; **D**, one year after cheilectomy, patient had improved motion and less pain. From - Amadio et al., 1989.

**Figure 2.16** - Intrascaphoid angle. Lateral diagram of left wrist. A perpendicular line is drawn to the proximal and distal articular surfaces and the resulting angle is measured. From - Amadio et al., 1989.

**Figure 2.17** - Photograph of operating room set-up for performing wrist arthroscopy. Image from private file.

**Figure 2.18** - Dorsal wrist arthroscopy portals. The convention is to describe portals according to their anatomic location. The radiocarpal portals are numbered according to their relation to the extensor compartments, e.g. the 3 4 portal is situated between the third and fourth extensor compartments; the 6R compartment is on the radial side (R) of the Extensor Carpi Ulnaris tendon (sixth compartment). A=artery; DRUJ = distal radioulnar joint; MCR = mid-carpal radial; MCU = mid-carpal ulnar. From - Bain et al., 1997.

**Figure 3.1** - Demonstrates the results obtained from the author's patient population. It is interesting to compare the author's results with those published by Garcia Elias (Figure 2.13) SII (scaphoid inclination index), SFI (scaphoid flexion index) The results for each individual are marked with a number to represent the lunate type, i.e. 1, 2 or 3 (intermediate). Red line is the correlation of the total group. The thin red line is for the correlation of the type 1 lunate wrists and thin black line is for the correlation of the type 2 lunate wrists.



**Figure 3.2** - Hamate, dorsal view (A) a right type I hamate and (B) a type 2 hamate. The type 1 hamate with a deep hamate groove and a distinct distal ridge. The type 2 hamate has a shallow hamate groove and no distal ridge.

**Figure 3.3** - Triquetrum, mid-carpal view (A) right type A triquetrum and (B) a type B triquetrum. The type A triquetrum has a helicoidal shape. The type B triquetrum has a flat dish shape.

**Figure 3.4** - Triquetro-hamate joint, volar view (A) Type TqH-1 joint. Note the biconcave articulation between a type A triquetrum and type I hamate. (B) Type TqH-2 joint. Note the dish shaped articulation between a type B triquetrum and type II hamate.

**Figure 4.1** - Longitudinal CT scan of the scaphoid with the wrist held in radial deviation. From - (Bain et al., 1995).

**Figure 4.2** – The target sign. Longitudinal CT scan of the left wrist. The head of the capitate is between the proximal and distal poles of the scaphoid. It is objective evidence that the scan is along the longitudinal axis of the scaphoid. From - Bain et al., 1995.

**Figure 4.3** - Humpback deformity. Longitudinal CT scan of the right wrist. The proximal pole of the scaphoid is extended and the distal pole flexed. It produces carpal shortening. From - Bain, 1999.

**Figure 4.4** - Height-to-length ratio. A baseline is drawn along the volar aspect of the scaphoid. The length of the scaphoid along the baseline is measured, as is the height of the scaphoid perpendicular to the baseline. The height-to-length ratio is recorded as a percentage. From - Bain et al., 1998.

**Figure 4.5** - Dorsal cortical angle. A line is drawn along the dorsal cortex of the proximal and distal halves of the scaphoid and the angle between these lines is measured. From - Bain et al., 1998.

**Figure 4.6** - Partial volume averaging. A three-dimension "slice" of tissue is computed to produce a two-dimensional image. A non union which passes obliquely through a "slice" may appear united as there is some bone within the slice which will appear on the two-dimensional image as an incomplete union. From - Bain, 1999.

**Figure 4.7** – Diagram demonstrating a longitudinal CT scan representation of right wrist. Pre-operative CT scan "template". The trapezoidal bone graft and screw in situ is useful to determine the need for a structural bone graft, the preferred fixation screw, and to assess whether it should be inserted via a volar or dorsal approach. From - Bain, 1999.

**Figure 5.1** - Arthroscopic classification of articular changes of Kienböck's disease. Grade 0: All articular surfaces functional but may have synovitis. Grade 1: Non-functional articular surface in the proximal lunate. Grade 2: A non-functional articular surface of the proximal lunate and lunate facet. Grade 2b: Non-functional proximal and distal lunate. Grade 3: Non-functional proximal and distal articular surfaces of the lunate and lunate facets of the radius. Grade 4: All four surfaces are non-functional. From - Bain et al., 2006.

**Figure 5.2** –The intra-articular fragments can be manipulated by 1) the arthroscopic probe, 2) K-wires introduced into the fragment and 3) intra-focal wires used to buttress the fragment. From – Mehta et al., 2000.

**Figure 5.3** - London Technique. The articular surface is reduced, under arthroscopic vision, with "joysticks" and the arthroscopic probe. K-wires are advanced through the distal ulnar and into the subchondral level of the distal radius. The wires are removed from the radial side of the radius. From – Mehta et al., 2000.

**Figure 5.4** - Mini-open volar approaches. Incision on the radial side of the wrist through the floor of the FCR tendon sheath. Incision on the ulnar side of the wrist was between the long flexor tendons and the ulnar neurovascular bundle. Retraction of the longitudinal structures allows the volar aspect of the distal radius to be identified so that K-wires can be advanced across the distal radius to provide stability.

**Figure 5.5** – Arthroscopic view of distal radius fracture with intra-articular step. From – Bain et al., 1997.

**Figure 5.6** – Arthroscopic view of distal radius fracture following reduction of the articular step. From – Bain et al., 1997.

**Figure 5.7** – Arthroscopic view of the mid-carpal joint with probe in scapho-lunate interval to assess instability as reported by Geissler. From – Bain et al., 1997.

**Figure 5.8** – Cadaveric coronal section of a left wrist with the arthroscopic portal in the STT joint. Note the close proximity of the radial artery.

**Figure 5.9** - Cadaveric specimen demonstrating the dorsal STT portal ulnar to the EPL tendon. Note the radial nerve and radial artery to the radial side of EPL tendon.

**Figure 5.10** - Arthroscopic view of the articular surface of the trapezium and trapezoid, with the cartilage seen between these 2 bones. From – Ashwood et al., in press.

**Figure 5.11** - Arthroscopic debridement of the STT joint with a motorised resector. From – Ashwood et al., in press.

**Figure 5.12a, b** – Intra-osseous ganglion. Lateral view of left wrist (A) and AP view of left wrist (B). CT scan of the lunate demonstrating the exact position of the ganglion and a small cortical breach from which the ganglion arises. From – Ashwood et al., 2003.

**Figure 5.13** – Interligamentous sulcus. Wrist arthroscopic view showing long radiolunate ligament (LRL) on the left and radioscapohcapitate (RSC) ligament on the right. From – Bain et al., 1997.

**Figure 5.14** - Fluoroscopic confirmation of drill placement into the lunate (small arrow, drill in cannula; large arrow, arthroscope). From – Ashwood et al., 2003.

**Figure 5.15** - Arthroscopic view of a burr in position to perform an arthroscopic debridement of the prominent ulnar styloid.

**Figure 6.1** – Mechanism of injury. A flexing scaphoid with its rotational restraints. The mechanism of injury is a rotational injury to tear the rotational restraints.

**Figure 6.2** - Plain radiograph of type 2 lunate wrist with STT joint degenerative arthritis.

**Figure 6.3** - Fluoroscopic images of wrist. Type 1 lunate wrist on the top and type 2 on the bottom. The left images are in radial deviation, middle in neutral and right in ulnar deviation. The capito-hamate articulation is co-linear with the luno-triquetral articulation in ulnar deviation in the type 1 lunate wrist. In contrast, the capito-hamate articulation is co-linear with the luno-triquetral articulation in ulnar deviation in the type 2 lunate wrist.

**Figure 6.4** – Fetal wrist. A 45mm crown-rump fetal wrist with what appears to be a type 2 lunate, which articulates with the capitate and hamate. From Berger, 1998.

**Figure 6.5** - The dorsal cortical percentile. A baseline is drawn along the volar aspect of the scaphoid. Perpendicular lines are drawn at the proximal and distal limits of the scaphoid. A dorsal line completes the box. A line is drawn through the fracture. Where the fracture line intersects, the dorsal line is identified. The distance from the proximal line to the fracture line (P) is measured. The distance from the fracture line to the distal line is measured (D). The dorsal cortical percentile is calculated and recorded as a percentage. (P/P+D). Image from Michael Smith.

**Figure 6.6** – Normal scaphoid bone. Histology of osteocytes can be visualized within the lacunae. The fatty marrow between the trabeculae is structurally intact and viable. Image from Chris Carter.

**Figure 6.7** - AVN scaphoid. Histology of necrotic scaphoid bone as indicated by empty lacunae, appositional new bone growth and granulation tissue replacing the marrow. Image from Chris Carter.

**Figure 6.8** – Bridging trabeculi. CT scan with some bridging trabeculae between the proximal and distal fracture fragments.

**Figure 6.9** – Pseudo-arthritis of the scaphoid. Clearly separate fragments with no bridging trabeculi. Note increased radio-density of proximal pole.

**Figure 6.10** - Fluoroscopic image confirms position of the drill bit, which has been placed into the lunate under arthroscopic vision.

**Figure 6.11** – “Box concept”. The arthroscopic 3D box with the multiple arthroscopic portals for viewing and instrumentation. This allows therapeutic surgery in any part of the joint. Image from private file.

**Figure 6.12** - Cross-sectional anatomy of the wrist at the level of radial tuberosity with relationship of major nerves, UN, ulnar nerve; MN, median nerve (just distal to pronator quadratus). From – Verhellen et al., 2000.

**Figure 6.13** - Nylon tape used to retract the extensor tendon off the dorsal capsule. Image from private file.

## LIST OF VIDEOS

This section provides a list of all of the videos within the thesis. The first number is the chapter in which the video is referenced. The videos are contained in the CD in the back-cover of the thesis.

**Video 2.1** - Arthroscopy of a patient with a partial deep tear of the TFCC. Note the superficial surface of the TFC, which provides a suspicion of the diagnosis. This was managed an arthroscopic debridement of the deep surface of the TFC within the DRUJ.

**Video 2.2** - Infiltration of the mid-carpal joint with saline. Leakage of the saline from the 6R portal is due to leakage of the intracarpal ligaments (scapho-lunate or lunotriquetral ligaments).

**Video 5.1** - Kienböck disease: Wrist arthroscopy view of the left wrist with a soft floating proximal pole of the lunate with adjacent synovitis. Full thickness cartilage defect of the lunate facet.

**Video 5.2** – Wrist arthroscopy demonstrating a distal radius fracture. The radiocarpal joint is lavaged and a motorised resector is used to debride the clot and synovitis from the joint. The articular fragments are manipulated with the arthroscopic probe. In the background, the radial styloid can be seen to be manipulated with a pre-placed K-wire. Once an anatomic articular reduction is obtained, the 1.6mm K-wire is advanced into the cortex on the ulnar aspect of the metaphyseal radius. Further K-wires are used to stabilise the distal radius.

**Video 5.3** – Scapho-lunate stabilisation. Arthroscopic view of the mid-carpal joint with scapho-lunate interval being reduced and stabilised with percutaneous K-wires.

**Video 5.4** - STT arthritis. Arthroscopic view of the STT joint with eburnated bone on the distal aspect of the scaphoid and on the proximal aspect of the trapezium and trapezoid. A synovectomy of this joint can be performed with the aid of a motorised resector.

**Video 5.5** – Inside-out volar radial portal technique: Wissenger rod is introduced through interligamentous sides to the radial side of FCR tendon.

**Video 5.6** - Volar capsular release. Pre-operative range of motion of wrist contracture.

**Video 5.7** - Volar capsular release video. Arthroscopic view showing volar synovitis is debrided to expose the volar capsule, which is released with cautery. The radial side of the RSC ligament is preserved to prevent ulnar-translocation.

**Video 5.8** - Volar capsular release. Post-release manipulation.

**Video 6.1** - Dorsal capsulectomy. Dorsal capsule being excised with the aid of basket forceps. In the background can be seen the white nylon tape retracting the extensor tendons.

**Video 6.2** - Radiocarpal fusion. Bone graft harvested from distal radius and placed into debrided radiocarpal and mid-carpal joints. Steinman pin advanced from 3<sup>rd</sup> metacarpal into radius.

## **APPENDICES**

This section provides a list of all of the appendices within the thesis. The first number is the chapter in which the appendix is first referenced.

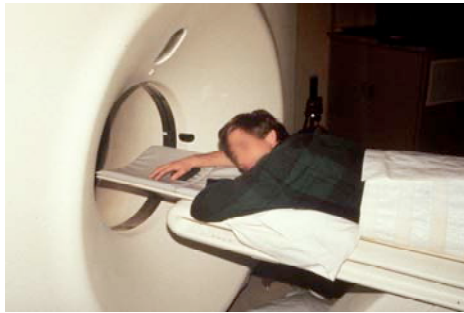
- 4.1 Protocol for longitudinal computed tomography scan of the scaphoid
- 4.2 Wrist arthroscopy proforma sheet
- 4.3 Wrist examination proforma sheet
- 4.4 Protocol for plain radiographs of the wrist

## CT Scaphoid Protocol


Computerised tomography provides superior resolution for the assessment of pathology of the scaphoid. Imaging in the longitudinal plain provides a greater appreciation of the “hump back” deformity (flexion deformity which occurs in the scaphoid following fractures)

### TECHNIQUE

**Patient Positioning:** The patient is placed PRONE on the table with the arm above the head. The wrist is positioned in **RADIAL DEVIATION** and neutral flexion (not flexed or extended). No immobilisation devices are required.



**Scanning plane:** The **FIRST METACARPAL** is aligned along the scanning plane and a scout scan taken. This position approximates the final position. The hand is then **REPOSITIONED** as required so that the scanning plane runs along the **LONGITUDINAL AXIS** of the scaphoid.



**Imaging:** 1mm cuts are performed. The image printed is magnified so that the scaphoid takes up the majority of the frame.

The scaphoid can be scanned if a plaster has been applied or if there is metal in-situ. Should there be any problems please don't hesitate to call me.

Greg Bain



**WRIST ARTHROSCOPY****FINDINGS IN RADIOCARPAL JOINT**

Patient Id ..... Name .....

Operation Date ..... Hospital ..... Wrist  Right  Left

Diagnosis .....

Treatment .....

- TFCC**
- No Tear
  - Radial Volar Tear
  - Radial Dorsal Tear
  - Ulnar
  - Carpal
  - Central

- Pathology**
- Acute Tear
  - Chronic Tear

- Treatment**
- Debridement
  - Suture PDS
  - Resection of distal ulnar

**Distal Radius**

- Lunate Facet**
- Normal
  - Fracture
  - Scuffing

- Scaphoid Facet**
- Normal
  - Fracture
  - Scuffing

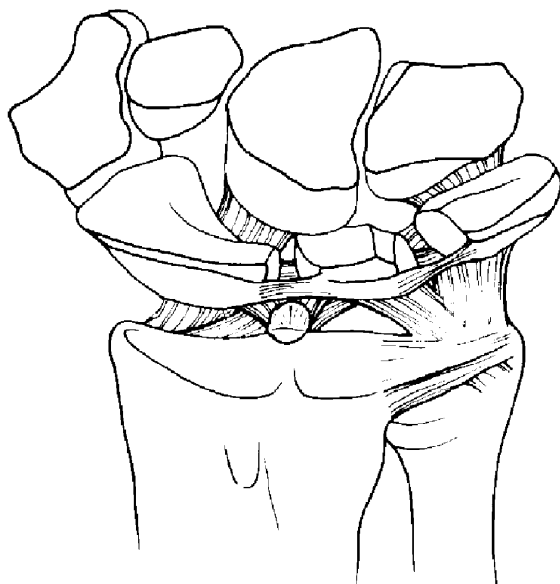
- S-L**
- No Tear
  - Attenuated
  - Tear from Lunate
  - Tear from Scaphoid
  - Mid Substance Tear

- Dorsal
- Membranous
- Volar

- L-T**
- No Tear
  - Attenuated
  - Tear from Lunate
  - Tear from Triquetrum
  - Mid Substance Tear

- Dorsal
- Membranous
- Volar

- Synovitis**
- Nil
  - Generalised
  - Radial Styloid
  - S-L
  - L-T
  - TFCC
  - Ulnar recess
  - Midcarpal S-L
  - Midcarpal L-T
  - STT Joint
  - Other



- STT Joint**
- Normal
  - Haemorrhage
  - Ligament Tear
  - Joint Articular Injury

- Sagittal Ridge**
- 0.0 - 0.5mm
  - 0.5 - 1.0mm
  - 1.0 - 1.5mm
  - > 1.5mm

- Shape**
- Flat
  - Inverted V
  - Inverted U
  - Pedunculated

**FINDINGS IN MIDCARPAL JOINT**

# WRIST ARTHROSCOPY



- S-L findings**  Grade  
 Step with 10lb traction
- Does not admit probe
  - Just admits probe
  - Easily admits probe
  - Can rotate probe
  - Admits scope

- Treatment**
- Nil
  - Debridement
  - Fixation - polished K wires
  - Fixation - Threaded pins
  - Radial styloidectomy

- L-T findings**  Grade  
 Step with 10lb traction
- Does not admit probe
  - Just admits probe
  - Easily admits probe
  - Can rotate probe
  - Admits scope

- Treatment**
- Nil
  - Debridement
  - Fixation - polished K wires
  - Fixation - Threaded pins

- OA Radiocarpal**
- Normal
  - Scaphoid
  - Lunate
  - Triquetrum
  - Scaphoid facet
  - Lunate facet

- OA Midcarpal**
- Normal
  - Scaphoid
  - Lunate
  - Triquetrum
  - Capitate
  - Hamate

- Lunate**
- Type 1
  - Type 2

- Scaphoid**
- Normal
  - Fracture
- Displacement  
 Direction

- Treatment**
- Nil
  - Kwires
  - AO cannulated screw
  - Herbert Whipple screw
  - Threaded pin

- Articular Injury**
- Nil
  - Contusion **Site**
  - Cleft **Site**

**Size**

**Size**

- Cartilage Removed**  Yes  No

- Video**  Yes  No

**Comments**

**Outbridge**

- 1 Intact Surface - soft or blistered
- 2 Fissuring
- 3 Deep fissures/fragmentation
- 4 Bone/Bone

- Grade 1 - Attenuation or haemorrhage in RC Joint  
No Step in MC joint
- Grade 2 - Step in MC joint  
Will not admit a probe
- Grade 3 - Step seen in both RC and MC Joints  
Admits a probe
- Grade 4 - Admits a 2-7mm scope

Leubovic OCNA Vol 255, (4), 1994, p685-707

**Creation date**

Wrist Questionnaire

Name	Age	Hand Dominance	<input type="radio"/> Right	<input type="radio"/> Left	<input type="radio"/> Ambi
Occupation			Employer		
Wrist	<input type="radio"/> Right	<input type="radio"/> Left	<input type="radio"/> Both	Date	Sex <input type="radio"/> <File Missing>

Flag

History

I understand that the information obtained may be used for clinical decision making, disability assessment and for research.

Signed.....Date.....

Do you experience  Pain  Numbness  Clicking  Catching  Weakness

Pain Level  None  Slight  Occasional  Severe

Astra Pain Level ..... 1-100

target  Yes  No

Please Mark on the diagram the site of pain. Also mark your worst pain with an (X)

Please place an (O) where you feel a click or clunk in your wrist



**Contralateral**

<b>Deformity</b>	Prominent Ulna styloid		
	Radial Deviation		
	Dinner-fork		
<b>Active ROM: (degrees)</b>	Supination		
	Pronation		
	Flexion		
	Extension		
	Radial Deviation		
	Ulnar Deviation		
	Grip (distance - pulp to palm)	Grip (distance - pulp to palm)	
Grip strength (kg)			
Tip Pinch			
Key Pinch			
Chuck Pinch			
<b>Complications</b>	None or minimal	- 0	
	Slight crepitation	1-2	
	Severe crepitation	3-4	
	Median Nerve compression	1-3	
	Pulp-palm distance 1cm	- 3	
	Pulp-palm distance 2cm	- 5	
	Pain in distal radioulnar joint	1 - 3	
	Maximum	- 15	
<b>Instability test</b>	Watson		
	Luno triquetral Ballotment		
	Shuck test		
	TFC Provocation Test		
	Mid Carpal		
	Piano Key test		
	CMC grind		
	Finkelstein test		

Incongruity	Grade	Step Of	Contralateral	
	0	0-1 mm	<input type="checkbox"/>	<input type="checkbox"/>
	1	1-2 mm	<input type="checkbox"/>	<input type="checkbox"/>
	2	2-3 mm	<input type="checkbox"/>	<input type="checkbox"/>
	3	>3 mm	<input type="checkbox"/>	<input type="checkbox"/>
<b>Arthritis Grade</b>				
	0	Slight joint-space narrowing	<input type="checkbox"/>	<input type="checkbox"/>
	1	Marked joint-space narrowing osteophyte formation	<input type="checkbox"/>	<input type="checkbox"/>
	3	Bone-on-bone, osteophyte formation Cysts formation	<input type="checkbox"/>	<input type="checkbox"/>
<b>Joint Space</b>				
		Normal	<input type="checkbox"/>	<input type="checkbox"/>
		Decreased	<input type="checkbox"/>	<input type="checkbox"/>
		Not apparent	<input type="checkbox"/>	<input type="checkbox"/>
<b>Lateral Alignment</b>				
		<20° dorsal tilt	<input type="checkbox"/>	<input type="checkbox"/>
		> 20° dorsal tilt	<input type="checkbox"/>	<input type="checkbox"/>
<b>Neurological Signs</b>				
		Roos	<input type="checkbox"/>	<input type="checkbox"/>
		Radial tunnel - Tinels	<input type="checkbox"/>	<input type="checkbox"/>
		Cubital tunnel -Tinels	<input type="checkbox"/>	<input type="checkbox"/>
		Cubital tunnel Flexion pressure test	<input type="checkbox"/>	<input type="checkbox"/>
		Carpal tunnel -Tinels	<input type="checkbox"/>	<input type="checkbox"/>
		Carpal tunnel - Flexion pressure test	<input type="checkbox"/>	<input type="checkbox"/>
		Carpal tunnel - Phalens	<input type="checkbox"/>	<input type="checkbox"/>
		Carpal tunnel - reverse Phalens	<input type="checkbox"/>	<input type="checkbox"/>
		Guyon's canal - Tinels	<input type="checkbox"/>	<input type="checkbox"/>
		Strength of thumb abduction	<input type="checkbox"/>	<input type="checkbox"/>
		Strength of finger abduction	<input type="checkbox"/>	<input type="checkbox"/>

Diagnosis

---

Treatment

---

Functional Scoring System modified from Gartland & Werley. JBJS. 33A 895-907, 1951  
 Solgaard Aetor. Orthop Scand 59(1) 39-43 1988  
 Knirk & Jupiter. JBJS 68A 647-659

Flag

## Protocol for Plain Radiography of the Wrist

Disorders of the wrist can be difficult to diagnose with routine plain radiography. This series of radiographs is aimed to improve the chance of diagnosis of scaphoid fractures and scapholunate instability and also allow a standardised reproducible assessment of ulna variance. These patients can be billed for radiographs of the wrist and scaphoid.

### TECHNIQUE

Patients should be seated adjacent to the x-ray table, with the shoulder abducted to 90°. The wrist is placed in a neutral position with regard to supination, pronation, flexion, extension, radial deviation and ulna deviation. The following images are obtained, with the beam centred on the wrist.

1. **PA wrist:** with the wrist in neutral pronation/supination the ulnar and radial styloids are maximally separated.
2. **PA /CF:** clenched fist separates the scapholunate interval. Keep patient in contact with the film – keep wrist straight i.e. 3<sup>rd</sup> metacarpal inline with the radius.
3. **PA UD:** PA with ulnar deviation of wrist. This opens the scapholunate interval projection.
4. **PA 30°:** PA with the tube tilted 30° towards the elbow. This projection will elongate the scaphoid which helps to demonstrate fractures of the scaphoid.
5. **S-L view:** PA radiograph with a 10° block under the ulna side of the wrist to profile the scapholunate joint. If a 10° sponge is not available then the tube can be tilted 10° so that the beam passes from ulna to radius.
6. **PA OBL with UD 45°** semi-pronated PA with ulnar deviation.
7. **True lateral of the wrist.** The x-ray tube is adjusted to a cross table position. The wrist stays in the same position except a sponge is placed under the wrist. It is important that the wrist be in a neutral position and not flexed or extended. Aim to get the carpal bones lateral. Metacarpals should be inline with the radius.

If the patient is unable to abduct the shoulder 90° the arm should be placed at the patients side with the elbow at 90° and the wrist in the neutral position. The radiographs are then performed using a cross table technique for all PA views.

Please call me if there are any problems 8361 8399

Greg Bain

## REFERENCES

- Abe Y, Doi K, Hattori Y, Ikeda K, Dhawan V (2003). A benefit of the volar approach for wrist arthroscopy. *Arthroscopy*, 19(4): 440-445.
- Abrams RA, Petersen M, Botte MJ (1994). Arthroscopic portals of the wrist: An anatomic study. *Journal of Hand Surgery (American Volume)*, 19(6): 940-944.
- Adams BD (1993). Partial excision of the triangular fibrocartilage complex articular disk: A biomechanical study. *Hand Surg*, 18: 334-340.
- Adams BD, Berger RA (2002). An anatomic reconstruction of the distal radioulnar ligaments for posttraumatic distal radioulnar joint instability. *Journal of Hand Surgery (American Edition)*, 27(2): 243-251.
- Adolfsson L (2000). Arthroscopic removal of os centrale carpi causing wrist pain. *Arthroscopy*, 16(5): 537-539.
- Adolfsson L (2005). Arthroscopic synovectomy in wrist arthritis. *Hand Clinics*, 21(4): 527-530.
- Adolfsson L, Frisen M (1997). Arthroscopic synovectomy of the rheumatoid wrist. A 3.8 year follow-up. *Journal of Hand Surgery (British Edition)*, 22(6): 711-713.
- Adolfsson L, Nylander G (1993). Arthroscopic synovectomy of the rheumatoid wrist. *Journal of Hand Surgery British Volume*, 18(1): 92-96.
- Alexander AH, Turner MA, Alexander CE, Lichtman DW (1990). Lunate silicone replacement arthroplasty in kienböck's disease: A long-term follow-up. *Journal of Hand Surgery (American Volume)*, 15: 401-407.
- Allieu Y, Chammas M, Lussiez B, et.al (1991). Place de l'arthrodèse scapho-trapézöidienne dans le traitement de la maladie de kienböck: A propos de onze observations. *Annales de Chirurgie de la Main*, 10: 22-29.
- Almquist EE (1987). Kienböck's disease. *Hand Clinics*, 3: 141-148.



- Almquist EE, Burns JF, Jr. (1982). Radial shortening for the treatment of kienböck's disease - a 5 to 10 year follow-up. *Journal of Hand Surgery (American Edition)*, 7(4): 348-352.
- Amadio PC, Berquist TH, Smith DK, Ilstrup DM, Cooney WP, III., Linscheid RL (1989). Scaphoid malunion. *Journal of Hand Surgery (American Edition)*, 14A: 679-687.
- Amadio PC, Wolfe SW. Fractures of the carpal bones. In: Green DP, Hotchkiss RN, Pederson WC Wolfe SW, (Ed). *Green's operative hand surgery*. ed. Philadelphia. Elsevier, Churchill Livingstone. 2005: 711-768.
- Amrami KK (2005). Radiology corner: Diagnosing radiographically occult scaphoid fractures-whats the best test? *Journal of the American Society for Surgery of the Hand*, 5: 134-138.
- Annamalai G, Raby N (2003). Scaphoid and pronator fat stripes are unreliable soft tissue signs in the detection of radiographically occult fractures. *Clinical Radiology*, 58(10): 798-800.
- Armstrong AL, Hunter JB, Davis TR (1994). The prevalence of degenerative arthritis of the base of the thumb in post-menopausal women. *Journal of Hand Surgery (British Edition)*, 19(3): 340-341.
- Arnoczky SP, Warren RF (1982). Vascularity of the menisci of the knee - landmark paper explaining when to repair and when to resect torn menisci. *American Journal of Sports Medicine*, 10: 90.
- Ashwood N, Bain GI, Fogg Q (2003). Results of arthroscopic debridement for isolated scaphotrapezotrapezoid arthritis. *Journal of Hand Surgery (American Volume)*, 28(5): 729-732.
- Assad C, Ross DC, Richards RS, Roth JH. Outcome of arthroscopic reduction and percutaneous pinning of scapholunate instability. in ASSH 52nd Annual Meeting. 1997. Denver.
- Avrahami E (1990). Panic attacks during mr imaging: Treatment with i.V. Diazepam. *AJNR American Journal of Neuroradiology*, 11(4): 833-835.

- Axelrod TS, Paley D, Green J, McMurtry RY (1988). Limited open reduction of the lunate facet in comminuted intra-articular fractures of the distal radius. *Journal of Hand Surgery (American Volume)*, 13A: 372-377.
- Badia A, Jimenez A (2006). Arthroscopic repair of peripheral triangular fibrocartilage complex tears with suture welding: A technical report. *Journal of Hand Surgery (American Edition)*, 31(8): 1303-1307.
- Badia A, Khanchandani P (2007). Suture welding for arthroscopic repair of peripheral triangular fibrocartilage complex tears. *Techniques in Hand and Upper Extremity Surgery*, 11(1): 45-50.
- Bain GI (1999). Clinical utilisation of computed tomography of the scaphoid. *Hand Surgery*, 4(1): 3-9.
- Bain GI, Begg M (2006). Arthroscopic assessment and classification of kienbock's disease. *Techniques in Hand and Upper Extremity Surgery*, 10(1): 8-13.
- Bain GI, Bennett JD, MacDermid JC, Slethaug GP, Richards RS, Roth JH (1998). Measurement of the scaphoid humpback deformity using longitudinal computed tomography: Intra- and interobserver variability using various measurement techniques. *Journal of Hand Surgery (American Edition)*, 23A(1): 76-81.
- Bain GI, Bennett JD, Richards RS, Slethaug GP, Roth JH (1995). Longitudinal computed tomography of the scaphoid: A new technique. *Skeletal Radiology*, 24: 271-273.
- Bain GI, Duncan AWW (2003). Arthroscopy-assisted reduction and percutaneous fixation of acute scapholunate injuries. *Knee Surg Sports Traumatol*, 11: 56-60.
- Bain GI, Hunt J, Mehta JA (1997). Operative fluoroscopy in hand and upper limb surgery. One hundred cases. *Journal of Hand Surgery (American Edition)*, 22B(5): 656-658.
- Bain GI, Richards R, Roth J (1996). Arthroscopy of the wrist: Introduction and indications. In: McGinty JB, Caspari RB, Jackson RW, Poehling GG, (Ed). *Operative arthroscopy*. 2 ed. Philadelphia. Lippincott - Raven. 897-904.

- Bain GI, Richards R, Roth J (1996). Wrist arthroscopy: Indications and technique. In: Peimer CA, (Ed). Surgery of the hand and the upper extremity. ed. New York. McGraw-Hill. 867-882.
- Bain GI, Richards RS, Roth JH (1997). Wrist arthroscopy. In: Lichtman DM, Alexander AH, (Ed). The wrist and its disorders. Second ed. Philadelphia. W.B. Saunders. 151-168.
- Bain GI, Sood A (2007). Effect of distal scaphoid and triquetrum excision on radioscapholunate, in IFSSH & IFSHT. Sydney, Australia.
- Bassett RL (1987). Displaced intraarticular fractures of the distal radius. Clin Orthop Relat Res, (214): 148-152.
- Bayer LR, Widding A, Diemer H (2000). Fifteen minutes bone scintigraphy in patients with clinically suspected scaphoid fracture and normal x-rays. Injury, 31(4): 243-248.
- Bednar JM, Osterman AL (1993). Carpal instability: Evaluation and treatment. J Am Acad Orthop Surg, 1(1): 10-17.
- Bednar MS, Arnoczky SP, Weiland AJ (1991). The microvasculature of the triangular fibrocartilage complex: Its clinical significance. Journal of Hand Surgery (American Volume), 16(6): 1101-1105.
- Begley BW, Engber WD (1994). Proximal row carpectomy in advanced kienböck's disease. Journal of Hand Surgery (American Edition), 196: 1016-1018.
- Belsole RJ, Eikman EA, Muroff LR (1981). Bone scintigraphy in trauma of the hand and wrist. Journal of Trauma, 21(2): 163-166.
- Berger RA (1982). The three-dimensional rotational behaviours of the carpal bones. Clin Orthop Relat Res, 167: 303-310.
- Berger RA (1998). General anatomy. In: Cooney WP, Linscheid RLDobyns JH, (Ed). The wrist diagnosis and operative treatment. ed. St Louis. Mosby. 32-60.
- Bergman J, Bain G. Arthroscopic release of wrist contracture. In: Slutsky DJ, Osterman AL, (Ed). Distal radius fractures and carpal injury: The cutting edge. ed. Philadelphia. Elsevier. In Press.

- Berna JD, Abaledejo F, Sanchez-Canizares MA, Chavarria G, Pardo A, Pellicer A (1998). Scaphoid fractures and nonunions: A comparison between panoramic radiography and plain x-rays. *Journal of Hand Surgery (British Edition)*, 23(3): 328-331.
- Berna JD, Chavarria G, Albadalejo F, Sanchez-Canizares MA, Martinez J (1993). Orthopantography of the wrist and the knee. *European Journal of Radiology*, 16(3): 250-253.
- Bert JM, Maschka K (1989). The arthroscopic treatment of unicompartmental gonarthrosis: A five year follow-up study of abrasion arthroplasty plus arthroscopic debridement and arthroscopic debridement alone. *Arthroscopy*, 5: 25-32.
- Bialocerkowski A (2002). An instrument that assesses ADL following a wrist disorder: Development and preliminary testing, in Division of Health Science, University of South Australia: Adelaide. p. 440.
- Bialocerkowski AE, Bain GI (2007). Functional ability of individuals following limited wrist fusion, in IFSSH & IFSHT. Sydney, Australia.
- Bialocerkowski AE, Grimmer KA, Bain GI (2000). A systematic review of the content and quality of wrist outcome instruments. *International Journal for Quality in Health Care*, 12(2): 149-157.
- Bialocerkowski AE, Grimmer KA, Bain GI (2003). Development of a patient-focused wrist outcome instrument. *Hand Clinics*, 19(3): 437-448, ix.
- Bialocerkowski AE, Grimmer KA, Bain GI (2003). Validity of the patient-focused wrist outcome instrument: Do impairments represent functional ability? *Hand Clinics*, 19(3): 449-455, ix.
- Biondetti PR, Vannier MW, Gilula LA, Knapp R (1987). Wrist: Coronal and transaxial ct scanning. *Radiology*, 163(1): 149-151.
- Birchard D, Pichora D (1990). Experimental corrective scaphoid osteotomy for scaphoid malunion with abnormal wrist mechanics. *Journal of Hand Surgery (American Edition)*, 15(6): 863-868.

- Biyani A, Mehara A, Bhan S (1990). Morphological variations of the ulnar styloid process. *Journal of Hand Surgery (British Edition)*, 15(3): 352-354.
- Blatt GU (1987). Capsulodesis in reconstructive hand surgery. *Hand Clinics of North America*, 3: 81-102.
- Bogumill GP (1977). Clinico-pathological correlation in a case of congenital arterio-venous fistula. *Hand*, 9(1): 60-64.
- Botte MJ, Pacelli LL, Gelberman RH (2004). Vascularity and osteonecrosis of the wrist. *Orthopedic Clinics of North America*, 35(3): 405-421, xi.
- Bowers WH (1985). Distal radioulnar joint arthroplasty: The hemiresection-interposition technique. *Journal of Hand Surgery (American Edition)*, 10A: 169-178.
- Bradway JK, Amadio PC, Cooney WP, III. (1989). Open reduction and internal fixation of displaced comminuted intra-articular fractures of the distal end of the radius. *Journal of Bone and Joint Surgery*, 71-A: 839-847.
- Braunstein EM, Louis DS, Greene TL, Hankin FM (1985). Fluoroscopic and arthrographic evaluation of carpal instability. *American Journal of Roentgenology*, 144: 1259-1262.
- Breitenseher MJ, Metz VM, Gilula LA, Gaebler C, Kukla C, Fleischmann D, Imhof H, Trattig S (1997). Radiographically occult scaphoid fractures: Value of mr imaging in detection. *Radiology*, 203(1): 245-250.
- Brooks S, Cicuttini FM, Lim S, Taylor D, Stuckey SL, Wluka AE (2005). Cost effectiveness of adding magnetic resonance imaging to the usual management of suspected scaphoid fractures. *British Journal of Sports Medicine*, 39(2): 75-79.
- Brown JA, Janzen DL, Adler BD, Strothers K, Favero KJ, Gopper PT, Connell DG (1994). Arthrography of the contralateral asymptomatic wrist in patients with unilateral wrist pain. *Canadian Association of Radiology Journal*, 45: 292-296.
- Brunelli GA, Brunelli GR (1995). A new technique to correct carpal instability with scaphoid rotary subluxation: A preliminary report. *Journal of Hand Surgery (American Edition)*, 20 582-585.

- Brydie A, Raby N (2003). Early mri in the management of clinical scaphoid fracture. *British Journal of Radiology*, 76(905): 296-300.
- Burgess RC (1987). The effect of a simulated scaphoid malunion on wrist motion. *Journal of Hand Surgery (American Edition)*, 12A: 774-776.
- Burgess RC (1990). Anatomic variations of the midcarpal joint. *Journal of Hand Surgery American Volume*, 15(1): 129-131.
- Carro LP, Golano P, Farinas O, Cerezal L, Hidalgo C (2003). The radial portal for scaphotrapeziotrapezoid arthroscopy. *Arthroscopy*, 19(5): 547-553.
- Carroll RE (1983). Discussion of carpal collapse deformity after lunate resection for kienböck's disease (abstract). *Journal of Hand Surgery (American Volume)*, 8: 612.
- Cerofolini E, Luchetti R, Pederzini L, Soragni O, Colombini R, D'Alimonte P, Romagnoli R (1990). Mr evaluation of triangular fibrocartilage complex tears in the wrist: Comparison with arthrography and arthroscopy. *Journal of Computer Assisted Tomography*, 14(6): 963-967.
- Chamay A, Piaget-Morerod F (1994). Arthrodesis of the trapeziometacarpal joint. *Journal of Hand Surgery British Volume*, 19(4): 489-497.
- Chen AC, Hsu KY, Chang CH, Chan YS (2005). Arthroscopic suture repair of peripheral tears of triangular fibrocartilage complex using a volar portal. *Arthroscopy*, 21(11): 1406.
- Chen YC (1979). Arthroscopy of the wrist and finger joints. *Orthopaedic Clinics of North America*, 10(3): 723-733.
- Chuinard RG, Zeman SC (1980). Kienböck's disease: An analysis and rationale for treatment by capitate-hamate fusion. *Orthopaedic Transactions*, 4: 18.
- Chung KC, Zimmerman NB, Travis MT (1996). Wrist arthrography versus arthroscopy: A comparative study of 150 cases. *Journal of Hand Surgery (American Volume)*, 21(4): 591-594.

- Colles A (1814). On the fracture of the carpal extremity of the radius. In: The edinburgh medical and surgical journal exhibiting a concise view of the latest and most important discoveries in medicine surgery and pharmacy. ed. Edinburgh. George Ramsay and Company. 182-185.
- Cooney WP, III (1993). Contractures of the elbow. In: Morrey BF, (Ed). The elbow and its disorders. 2 ed. Philadelphia. WB Saunders. 464-475.
- Cooney WP, Berger RA (1993). Treatment of complex fractures of the distal radius. Combined use of internal and external fixation and arthroscopic reduction. *Hand Clinics*, 9(4): 603-612.
- Cooney WP, III., Dobyns JH, Linscheid RL (1980). Complications of colles' fractures. *Journal of Bone and Joint Surgery*, 62A(4): 613-619.
- Cooney WP, Dobyns JH, Linscheid RL (1990). Arthroscopy of the wrist: Anatomy and classification of carpal instability. *Arthroscopy*, 6(2): 133-140.
- Cooney WP, Sagerman SD, Short WH (1994). Arthroscopic repair of the radial sided tfcc tears: A followup study. Presented at the 49th Annual Meeting of the American Society for Surgery of the Hand, Cincinnati, OH: 41-44.
- Craig MA, Stanley JK (1995). Wrist kinematics. Row, column or both? *Journal of Hand Surgery British Volume*, 20(2): 165-170.
- Culp RW (1999). Complications of wrist arthroscopy. *Hand Clinics of North America*, 15(3): 529-535.
- Culp RW (2005). Wrist arthroscopy: Operative procedures. In: Osterman AL Kaufmann RA, (Ed). *Greens' operative hand surgery*. 5 ed. Churchill Livingstone. Elsevier.
- Culp RW, McGuigan FX, Turner MA, Lichtman DM, Osterman AL, McCarroll HR (1993). Proximal row carpectomy: A multicenter study. *Journal of Hand Surgery (American Edition)*, 18A: 19-25.
- Culp RW, Osterman AL (1995). Arthroscopic reduction and internal fixation of distal radius fractures. *Orthopaedic Clinics of North America*, 26(4): 739-748.

- Culp RW, Talsania JS, Osterman AL (1997). Arthroscopic proximal row carpectomy. *Techniques in hand and Upper Extremity Surgery*, 1(2): 116-119.
- Dandy DJ (1991). Arthroscopic debridement of the knee for osteoarthritis (editorial). *Journal of Bone and Joint Surgery British Volume*, 73B: 877-878.
- Darlis NA, Kaufmann RA, Giannoulis F, Sotereanos DG (2006). Arthroscopic debridement and closed pinning for chronic dynamic scapholunate instability. *Journal of Hand Surgery (American Edition)*, 31(3): 418-424.
- Darrach W (1912). Anterior dislocation of the head of the ulna. *Annals of Surgery*, 56: 802-803.
- Darrow JC, Jr., Linscheid RL, Dobyns JH, Mann JM, 3rd, Wood MB, Beckenbaugh RD (1985). Distal ulnar recession for disorders of the distal radioulnar joint. *Journal of Hand Surgery (American Volume)*, 10(4): 482-491.
- De Smet L (2002). Pitfalls in wrist arthroscopy. *Acta Orthop Belg*, 68(4): 325-329.
- del Pinal F, Herrero F, Cruz-Camara A, San Jose J (1999). Complete avulsion of the distal posterior interosseous nerve during wrist arthroscopy: A possible cause of persistent pain after arthroscopy. *Journal of Hand Surgery (American Volume)*, 24(2): 240-242.
- Dennison D, Weiss AP (1999). Diagnostic imaging and arthroscopy for wrist pain. *Hand Clin*, 15(3): 415-421, vii.
- Dias JJ, Thompson J, Barton NJ, Gregg PJ (1990). Suspected scaphoid fractures: The value of radiographs. *Journal of Bone and Joint Surgery British Volume*, 72B: 98-101.
- Dingman PVC (1952). Resection of the distal end of the ulna (darrach operation) an end-result study of twenty-four cases. *Journal of Bone and Joint Surgery*, 34: 893-900.
- Dorsay TA, Major NM, Helms CA (2001). Cost-effectiveness of immediate mr imaging versus traditional follow-up for revealing radiographically occult scaphoid fractures. *AJR American Journal of Roentgenology*, 177(6): 1257-1263.
- Duncan DS, Thurston AJ (1985). Clinical fracture of the carpal scaphoid-an illusionary diagnosis. *Journal of Hand Surgery (British Edition)*, 10(3): 375-376.



- Edwards CC, 2nd, Haraszti CJ, McGillivary GR, Gutow AP (2001). Intra-articular distal radius fractures: Arthroscopic assessment of radiographically assisted reduction. *Journal of Hand Surgery (American Edition)*, 26(6): 1036-1041.
- Eiken O (1979). Implant arthroplasty of the scapho-trapezial joint. *Scandinavian Journal of Plastic and Reconstructive Surgery*, 13(3): 461-468.
- Engdahl DE, Schacherer TG (1989). A new method of evaluating angulation of scaphoid nonunions. *Journal of Hand Surgery (American Edition)*, 14A: 1033-1034.
- Feipel V, Rooze M (1999). Three-dimensional motion patterns of the carpal bones: An in vivo study using three-dimensional computed tomography and clinical applications. *Surgical and Radiologic Anatomy*, 21(2): 125-131.
- Feldon P, Terrono AL, Belsky MR (1992). Wafer distal ulna resection for triangular fibrocartilage tears and/or impaction syndrome. *Journal of Hand Surgery (American Edition)*, 17A: 731-737.
- Ferlic DC, Clayton ML, Mills MF (1991). Proximal row carpectomy: Review of rheumatoid and non-rheumatoid wrists. *Journal of Hand Surgery (American Edition)*, 16: 420-424.
- Fernandez DL (1984). A technique for anterior wedge-shaped grafts for scaphoid nonunions with carpal instability. *Journal of Hand Surgery (American Edition)*, 9(5): 733-737.
- Fernandez DL, Geissler WB (1991). Treatment of displaced articular fractures of the radius. *Journal of Hand Surgery (American Volume)*, 16: 375-384.
- Fernandez DL, Geissler WB, Larney DM (1996). Wrist instability with or following fractures of the distal radius. In: Buchler U, (Ed). *Wrist instability*. ed. London. Martin Dunitz. 181-192.
- Ficat GR (1985). Idiopathic bone necrosis of the femoral head. Early diagnosis and treatment. *Journal of Bone and Joint Surgery (British Edition)*, 67: 3-9.
- Field J, Herbert TJ, Prosser R (1996). Total wrist fusion. A functional assessment. *Journal Of Hand Surgery (British & European Edition)*, 21B(4): 429-433.

- Fogg QA (2004), Scaphoid variation and an anatomical basis for variable carpal mechanics, in Department of Anatomical Sciences, The University of Adelaide: Adelaide. p. 275.
- Fowler C, Sullivan B, Williams LA, McCarthy G, Savage R, Palmer A (1998). A comparison of bone scintigraphy and mri in the early diagnosis of the occult scaphoid waist fracture. *Skeletal Radiology*, 27(12): 683-687.
- Freeland AE, Geissler WB (2000). The arthroscopic management of intra-articular distal radius fractures. *Hand Surgery*, 5(2): 93-102.
- Friedman L, Johnston GH, Yong-Hing K (1990). Computed tomography of wrist trauma. *Journal of the Canadian Association of Radiologists*, 41: 141-145.
- Frykman EB, af Ekenstam FW, Wadin K (1988). Triscaphoid arthrodesis and its complications. *Journal of Hand Surgery (American Edition)*, 13A: 844-849.
- Fusetti C, Poletti PA, Pradel PH, Garavaglia G, Platon A, Della Santa DR, Bianchi S (2005). Diagnosis of occult scaphoid fracture with high-spatial-resolution sonography: A prospective blind study. *Journal of Trauma*, 59(3): 677-681.
- Gaebler C, Kukla C, Breitenseher M, Trattinig S, Mittlboeck M, Vecsei V (1996). Magnetic resonance imaging of occult scaphoid fractures. *Journal of Trauma*, 41(1): 73-76.
- Gaebler C, Kukla C, Breitenseher MJ, Mrkonjic L, Kainberger F, Vecsei V (1998). Limited diagnostic value of macroradiography in suspected scaphoid fractures. *Acta Orthopaedica Scandinavica*, 69(4): 401-403.
- Galley I, Bain GI, McLean JM (2007). Influence of lunate type on scaphoid kinematics. *Journal of Hand Surgery (American Edition)*, 32(6): 842-847.
- Gan BS, Richards RS, Roth JH (1995). Arthroscopic treatment of triangular fibrocartilage tears. *Orthop Clin North Am*, 26(4): 721-729.
- Garcia-Elias M, Cooney WP, III., An K, Linscheid RL, Chao WYS (1989). Wrist kinematics after limited intercarpal arthrodesis. *Journal of Hand Surgery (American Edition)*, 14A: 791-799.

- Garcia-Elias M, Cooney WP, An KN, Linscheid RL, Chao EY (1989). Wrist kinematics after limited intercarpal arthrodesis. *Journal of Hand Surgery (American Edition)*, 14(5): 791-799.
- Garcia-Elias M, Lluch AL, Farreres A, Castillo F, Saffar P (1999). Resection of the distal scaphoid for scaphotrapeziotrapezoid osteoarthritis. *Journal of Hand Surgery British Volume*, 24(4): 448-452.
- Garcia-Elias M, Lluch AL, Farreres A, Castillo F, Saffar P (1999). Resection of the distal scaphoid for scaphotrapezoid osteoarthritis. *Journal Of Hand Surgery (British & European Volume)*, 24B(4): 448-452.
- Garcia-Elias M, Ribe M, Rodriguez J, Cots M, Casas J (1995). Influence of joint laxity on scaphoid kinematics. *Journal of Hand Surgery British Volume*, 20(3): 379-382.
- Gartland JJ, Werley CW (1951). Evaluation of healed colles' fractures. *Journal of Bone and Joint Surgery*, 33A: 895-907.
- Gehrke J, Mellenberg D, Donnelly R (1993). The fluoroscan imaging system in foot and ankle surgery. *Foot and Ankle International*, 14: 545-549.
- Geissler WB (1995). Arthroscopically assisted reduction of intra-articular fractures of the distal radius. *Hand Clinics of North America*, 11: 19-29.
- Geissler WB (1997). Arthroscopic treatment of intra-articular distal radius fractures. *Atlas of the Hand Clinics*, 2(1): 97-124.
- Geissler WB, Fernandez DL, Lamey DM (1996). Distal radioulnar joint injuries associated with fractures of the distal radius. *Clin Orthop Relat Res*, (327): 135-146.
- Geissler WB, Freeland AE (1996). Arthroscopically assisted reduction of intraarticular distal radial fractures. *Clin Orthop Relat Res*, (327): 125-134.
- Geissler WB, Freeland AE, Savoie FH, III., McIntyre LW, Whipple TL (1996). Intracarpal soft-tissue lesions associated with an intra-articular fracture of the distal end of the radius. *Journal of Bone and Joint Surgery*, 78A: 357-365.

- Geissler WB, Hammit MD (2001). Arthroscopic aided fixation of scaphoid fractures. *Hand Clin*, 17(4): 575-588, viii.
- Gelberman RH, Panagis JS, Taleisnik J, Baumgaertner M (1983). The arterial anatomy of the human carpus part 1: The extraosseous vascularity. *Journal of Hand Surgery (American Edition)*, 8: 367-375.
- Gelberman RH, Salamon PB, PB, Jurist JM, Posch JL (1975). Ulnar variance in kienböck's disease. *Journal of Bone and Joint Surgery*, 57A: 674-676.
- Gellman H, Kauffman D, Lenihan JM, Botte MJ, Sarmiento A (1988). An in vitro analysis of wrist motion: The effect of limited intercarpal arthrodesis and the contributions of the radiocarpal and midcarpal joints. *Journal of Hand Surgery (American Edition)*, 13A: 378-383.
- Gobel F, Vardakas DG, Riano F, Vogt MT, Sarris I, Sotereanos DG (2004). Arthroscopically assisted intra-articular corrective osteotomy of a malunion of the distal radius. *American Journal of Orthopedics*, 33(6): 275-277.
- Goldfarb CA, Hsu J, Gelberman RH, Boyer MI (2003). The lichtman classification for kienböck's disease: An assessment of reliability. *Journal of Hand Surgery American Volume*, 28(1): 74-80.
- Gooding A, Coates M, Rothwell A (2004). Cost analysis of traditional follow-up protocol versus mri for radiographically occult scaphoid fractures: A pilot study for the accident compensation corporation. *New Zealand Medical Journal*, 117(1201): U1049.
- Green DP (1993). *Operative hand surgery*. 3rd ed. Green DP. Philadelphia: Churchill Livingstone, 800.
- Green DP, Hotchkiss RN, Pederson WC, Wolfe SW (2005), eds. *Green's operative hand surgery*. 5th ed. Elsevier, Churchill Livingstone: Philadelphia. 2313.
- Green DP, O'Brien ET (1978). Open reduction of carpal dislocations: Indications and operative techniques. *Journal of Hand Surgery (American Volume)*, 3: 250-265.
- Grieco A, Molteni G, De Vito G, Sias N (1998). Epidemiology of musculoskeletal disorders due to biomechanical overload. *Ergonomics*, 41(9): 1253-1260.

- Groves AM, Cheow HK, Balan KK, Bearcroft PW, Dixon AK (2005). 16 detector multislice ct versus skeletal scintigraphy in the diagnosis of wrist fractures: Value of quantification of  $^{99\text{Tc}}\text{m}$ -mdp uptake. *British Journal of Radiology*, 78(933): 791-795.
- Gundry CR, Kursunoglu-Brahme S, Schwaighofer B, Kang HS, Sartoris DJ, Resnick D (1990). Is mri better than arthrography for evaluating the ligaments of the wrist? In vitro study. *AJR American Journal of Roentgenology*, 154(2): 337-341.
- Haase SC, Berger RA, Shin AY (2007). Association between lunate morphology and carpal collapse patterns in scaphoid nonunions. *Journal of Hand Surgery (American Edition)*, 32(7): 1009-1012.
- Hagen O, Aaser P (1998). Arthroscopical wrist arthrodesis for rheumatoid arthritis. *Acta Orthopaedica Scandinavica*, 69.
- Hambidge JE, Desai VV, Schranz PJ, Compson JP, Davis TRC, Barton NJ (1999). Acute fractures of the scaphoid. Treatment by cast immobilisation with the wrist in flexion or extension? *Journal of Bone and Joint Surgery (British Edition)*, 81(1): 91-92.
- Hanker GJ (1996). Intraarticular fractures of the distal radius. 2 edn. *Operative arthroscopy*, ed. McGinty JB. New York: Lippincott-Raven Publishers. 987-997.
- Hardy DC, Totty WG, Reinus WR, Gilula LA (1987). Posteroanterior wrist radiography: Importance of arm positioning. *Journal of Hand Surgery (American Edition)*, 12(4): 504-508.
- Harley BJ, Werner FW, Boles SD, Palmer AK (2004). Arthroscopic resection of arthrosis of the proximal hamate: A clinical and biomechanical study. *Journal of Hand Surgery (American Edition)*, 29(4): 661-667.
- Hastings H, II., Thornberry RL, Kleinman WB, et al (1983). Carpal collapse deformity after lunate resection for Kienboeck's disease. *Journal of Hand Surgery (American Volume)*, 8: 612.
- Hefzy MS, Grood E, S, (1988). Review of knee model. Four bar linkage of the knee - landmark paper describing the knee movements of rollback and gliding relative to the acl and pcl attachments. *Appl Mech Rev*, 41: 1-13.

- Henry AK (1957). Extensile exposure: The front of the forearm. In: Extensile exposure. Second ed. Edinburgh. E & S Livingstone Ltd. 94-115.
- Herbert TJ, Faithfull RG, McCann DJ, Ireland J (1990). Bilateral arthrography of the wrist. *Journal of Hand Surgery (British Edition)*, 15(2): 233-235.
- Hermansdorfer JD, Kleinman WB (1991). Management of chronic peripheral tears of the triangular fibrocartilage complex. *J Hand Surg (Am)*, 16: 340-346.
- Hirsh L, Sodha S, Bozentka D, Monaghan B, Steinberg D, Beredjiklian PK (2005). Arthroscopic electrothermal collagen shrinkage for symptomatic laxity of the scapholunate interosseous ligament. *Journal of Hand Surgery (British Edition)*, 30(6): 643-647.
- Hjorth Jensen C, Thomsen K, Holst-Nielsen F, Choueka J, Koval KJ, Kummer FJ, Zuckerman JD (1996). Radiographic staging of kienböck's disease: Poor reproducibility of stahl's and lichtman's staging systems. *Acta Orthopaedica Scandinavica*, 67: 274-276.
- Ho CA, Herring JA, Ezaki M (2007). Long-term follow-up of progressive macrodystrophia lipomatosa. A report of two cases. *Journal of Bone and Joint Surgery*, 89(5): 1097-1102.
- Ho PC (2007). New techniques in wrist arthroscopy, in International Advanced Wrist Symposium, Australian Hand Surgery Society: Cairns, Queensland, Australia.
- Ho PC, Lo WN, Hung LK (2003). Arthroscopic resection of volar ganglion of the wrist: A new technique. *Arthroscopy*, 19(2): 218-221.
- Hodgkinson DW, Nicholson DA, Stewart G, Sheridan M, Hughes P (1993). Scaphoid fracture: A new method of assessment. *Clinical Radiology*, 48(6): 398-401.
- Hori Y, Tamai S, Okuda H, Sakamoto H, Takita T, Masuhara K (1979). Blood vessel transplantation to bone. *Journal of Hand Surgery (American Edition)*, 4(1): 23-33.
- Hunter JC, Escobedo EM, Wilson AJ, Hanel DP, Zink-Brody GC, Mann FA (1997). Mri imaging of clinically suspected scaphoid fractures. *AJR American Journal of Roentgenology*, 168(5): 1287-1293.

- Inoue G, Shionoya K (1997). Herbert screw fixation by limited access for acute fractures of the scaphoid. *Journal of Bone and Joint Surgery British Volume*, 79B: 418-421.
- Ishida O, Tsai TM (1993). Complications and results of scapho-trapezio-trapezoid arthrodesis. *Clin Orthop Relat Res*, (287): 125-130.
- Ishiguro T (1984). Experimental and clinical studies of kienböck's disease: Excision of the lunate followed by packing of the free tendon. *J Jpn Orthop Assoc*, (58): 509-522.
- Jafarnia K, Collins ED, Kohl HW, 3rd, Bennett JB, Ilahi OA (2000). Reliability of the lichtman classification of kienböck's disease. *Journal of Hand Surgery (American Volume)*, 25(3): 529-534.
- Jantea CL, Fu FH, McCarthy DM, Herndon JH, Horikoshi M (1994). Palmer approaches/portals for arthroscopy of the wrist. *Arthroscopie*, 7: 225-231.
- Johnson LL (1986). Arthroscopic abrasion arthroplasty historical and pathologic perspective: Present status. *Arthroscopy*, 2: 54-69.
- Johnston HM (1907). Varying positions of the carpal bones in the different movements at the wrist: Part i. *J Anat Physiol*, 41(Pt 2): 109-122.
- Jones GS, Savoie FH, 3rd (1993). Arthroscopic capsular release of flexion contractures (arthrofibrosis) of the elbow. *Arthroscopy*, 9(3): 277-283.
- Jonsson K, Jonsson A, Sloth M, Kopylov P, Wingstrand H (1992). CT of the wrist in suspected scaphoid fracture. *Acta Radiologica*, 33: 500-501.
- Kaempffe FA, Lerner R (1996). Ultrasound diagnosis of triceps tendon rupture: A report of two cases. *Am Academy of Ortho Surg*, 63: 408.
- Kaji H, Honma H, Usui M, Yasuno Y, Saito K (1993). Hypothenar hammer syndrome in workers occupationally exposed to vibrating tools. *Journal Of Hand Surgery (British & European Volume)*, 18B: 761-766.
- Kambolis C, Bullough PG, Jaffe HI (1973). Ganglionic cystic defects of bone. *Journal of Bone and Joint Surgery*, 55(3): 496-505.

- Kang HS, Kindynis P, Bahme SK, Resnick D, Hagighi P, Haller J, Sartoris DJ (1991). Triangular fibrocartilage and intercarpal ligaments of the wrist: MRI imaging. *Radiology*, 181: 401-404.
- Kapandji A (1982). *The physiology of joints: Annotated diagrams of the mechanics of the human joints*. Vol. 1. Edinburgh: Churchill Livingstone.
- Kapandji A (1995). Treatment of articular distal radial fractures by intra-focal pinning with arum pins. In: Saffar P Cooney WP, III., (Ed). *Fractures of the distal radius*. ed. London. Martin Dunitz. 160-166.
- Kato H, Nakamura R, Shionoya K, Makino N, Imaeda T (2000). Does high-resolution mr imaging have better accuracy than standard mr imaging for evaluation of the triangular fibrocartilage complex? *Journal of Hand Surgery (British Edition)*, 25(5): 487-491.
- Kauer JM (1986). The mechanism of the carpal joint. *Clin Orthop Relat Res*, (202): 16-26.
- Kawai H, Yamamoto K, Yamamoto T, Tada K, Kaga K (1988). Excision of the lunate in kienböck's disease. *Journal of Bone and Joint Surgery (British Edition)*, 70B: 287-292.
- Kelsey JL, Praemer A, Nelson LM, Felberg A, Rice DP (1997). *Upper extremity disorders, frequency, impact and cost*. New York: Churchill Livingstone.
- Kilborn LC, Labbe EE (1990). Magnetic resonance imaging scanning procedures: Development of phobic response during scan and at one-month follow-up. *Journal of Behavioral Medicine*, 13(4): 391-401.
- Kleinman WB, Graham TJ (1996). Distal ulnar injury and dysfunction. In: CA P, (Ed). *Surgery of the hand and upper extremity*. ed. New York. McGraw Hill. 667-710.
- Knirk JL, Jupiter JB (1986). Intraarticular fractures of the distal end of the radius in young adults. *Journal of Bone and Joint Surgery*, 68A: 647-659.
- Kukla C, Gaebler C, Breitenseher MJ, Trattng S, Vecsei V (1997). Occult fractures of the scaphoid. The diagnostic usefulness and indirect economic repercussions of radiography versus magnetic resonance scanning. *Journal of Hand Surgery (American Edition)*, 22B: 810-813.



- Landis JR, Koch GG (1977). The measurement of observer agreement for categorical data. *Biometrics*, 33(1): 159-174.
- Landsmeer JM (1961). Studies in the anatomy of articulation. I. The equilibrium of the "Intercalated" Bone. *Acta Morphologica Neerlando-Scandinavica*, 3: 287-303.
- Larsen CF, Lauritsen J (1993). Epidemiology of acute wrist trauma. *International Journal of Epidemiology*, 22(5): 911-916.
- Leblebicioglu G, Doral MN, Atay AA, Tetik O, Whipple TL (2003). Open treatment of stage III kienböck's disease with lunate revascularization compared with arthroscopic treatment without revascularization. *Arthroscopy*, 19(2): 117-130.
- Leibovic SJ, Geissler WB (1994). Treatment of complex intra-articular distal radius fractures. *Orthopaedic Clinics of North America*, 25(4): 685-706.
- Levinsohn EM, Palmer AK, Coren AB, Zinberg E (1987). Wrist arthrography: The value of the three compartment injection technique. *Skeletal Radiology*, 16(7): 539-544.
- Levy HJ, Glickel SZ (1993). Arthroscopic assisted internal fixation of volar intraarticular wrist fractures. *Arthroscopy*, 9(1): 122-124.
- Lichtman DM, Mack G, R., MacDonald RI, Gunther SF, Wilson JN (1977). Kienböck's disease: The role of silicone replacement arthroplasty. *Journal of Bone and Joint Surgery*, 59-A(7): 899-908.
- Lichtman DM, Schneider JR, Swafford AR, Mack GR (1981). Ulnar midcarpal instability-clinical and laboratory analysis. *Journal of Hand Surgery American Volume*, 6(5): 515-523.
- Lindau T, Adlercreutz C, Aspenberg P (2003). Cartilage injuries in distal radial fractures. *Acta Orthopaedica Scandinavica*, 74(3): 327-331.
- Linscheid RL, Dobyns JH, Beabout JW, Bryan RSM (1972). Traumatic instability of the wrist. *Journal of Bone and Joint Surgery*, 54A: 1612-1632.
- Low G, Raby N (2005). Can follow-up radiography for acute scaphoid fracture still be considered a valid investigation? *Clinical Radiology*, 60(10): 1106-1110.

- Luchetti R, Andrea A (2003). Arthroscopic wrist arthrolysis. *Journal of Hand Surgery (American Edition)*, 28 Suppl 1: 4.
- MacConaill MA (1941). The mechanical anatomy of the carpus and its bearings on some surgical problems. *Journal of Anatomy*, 75: 166-175.
- Mack GR, Bosse MJ, Gelberman RH, Yu E (1984). The natural history of scaphoid non-union. *Journal of Bone and Joint Surgery*, 66A: 504-509.
- Mack MG, Keim S, Balzer JO, Schwarz W, Hochmuth K, Windolf J, Vogl TJ (2003). Clinical impact of mri in acute wrist fractures. *European Radiology*, 13(3): 612-617.
- Mah ETA (1992). Percutaneous kirschner wire stabilisation following closed reduction of colles' fractures. *Journal of Hand Surgery (American Volume)*, 17: 55-62.
- Mayfield JK, Honnson RP, Kilcoyne RF (1980). Carpal dislocations: Pathomechanics and progressive perilunar instability. *Journal of Hand Surgery (American Edition)*, 5: 226-241.
- McAuliffe JA, Dell PC, Jaffe R (1993). Complications of intercarpal arthrodesis. *Journal of Hand Surgery (American Edition)*, 18 1121-1128.
- McIntyre LF, Caspari RB (1993). The rationale and technique for arthroscopic reconstruction of anterior shoulder instability using multiple sutures. *Orthopaedic Clinics of North America*, 24: 55-58.
- McLean J, Bain G, Eames M, Fogg Q, Pourgiezis N (2006). An anatomic study of the triquetrum-hamate joint. *Journal of Hand Surgery (American Edition)*, 31(4): 601-607.
- Mehta JA, Bain GI, Heptinstall RJ (2000). Anatomical reduction of intra-articular fractures of the distal radius. An arthroscopically-assisted approach. *Journal of Bone and Joint Surgery (British Edition)*, 82(1): 79-86.
- Melone CP, Jr. (1986). Open treatment for displaced articular fractures of the distal radius. *Clin Orthop Relat Res*, (202): 103-111.
- Melone CP, Jr. (1993). Distal radius fractures: Patterns of articular fragmentation. *Orthopaedic Clinics of North America*, 24(2): 239-253.

- Menth-Chiari WA, GG P, Wiesler ER, Ruch DS (1999). Arthroscopic debridement for the treatment of kienböck's disease. *Arthroscopy*, 15(1): 12-19.
- Menth-Chiari WA, Poehling GG (2000). Preiser's disease: Arthroscopic treatment of avascular necrosis of the scaphoid. *Arthroscopy*, 16(2): 208-213.
- Mikic ZD (1978). Age changes in the triangular fibrocartilage of the wrist joint. *J Anat*, 126 (Pt 2): 367-384.
- Mikkelsen SS, Gelineck J (1987). Poor function after nonoperative treatment of kienböck's disease. *Acta Orthopaedica Scandinavica*, 58: 241-243.
- Minami A, Kimura T, Suzuki K (1994). Long-term results of kienböck's disease treated by triscaphe arthrodesis and excisional arthroplasty with a coiled palmaris longus tendon. *Journal of Hand Surgery (American Edition)*, 19: 219-228.
- Missakian ML, Cooney WP, Amadio PC, Glidewell HL (1992). Open reduction and internal fixation for distal radius fractures. *Journal of Hand Surgery (American Edition)*, 17(4): 745-755.
- Mogan JV, Newberg AH, Davis PH (1981). Intraosseous ganglion of the lunate. *Journal of Hand Surgery (American Edition)*, 6(1): 61-63.
- Moojen TM, Snel JG, Ritt MJ, Venema HW, Kauer JM, Bos KE (2002). Scaphoid kinematics in vivo. *Journal of Hand Surgery (American Edition)*, 27(6): 1003-1010.
- Moojen TM, Snel JG, Ritt MJ, Venema HW, Kauer JM, Bos KE (2003). In vivo analysis of carpal kinematics and comparative review of the literature. *Journal of Hand Surgery (American Edition)*, 28(1): 81-87.
- Morgan RL, Linder MM (1997). Common wrist injuries. *American Family Physician*, 55(3): 857-868.
- Moritomo H, Goto A, Sato Y, Sugamoto K, Murase T, Yoshikawa H (2003). The triquetrum-hamate joint: An anatomic and in vivo three-dimensional kinematic study. *Journal of Hand Surgery (American Edition)*, 28(5): 797-805.

- Moritomo H, Murase T, Goto A, Oka K, Sugamoto K, Yoshikawa H (2006). In vivo three-dimensional kinematics of the midcarpal joint of the wrist. *Journal of Bone and Joint Surgery*, 88(3): 611-621.
- Moritomo H, Viegas SF, Elder K, Nakamura K, Dasilva MF, Patterson RM (2000). The scaphotrapezio-trapezoidal joint. Part 2: A kinematic study. *Journal of Hand Surgery (American Edition)*, 25(5): 911-920.
- Moritomo H, Viegas SF, Elder KW, Nakamura K, Dasilva MF, Boyd NL, Patterson RM (2000). Scaphoid nonunions: A 3-dimensional analysis of patterns of deformity. *Journal of Hand Surgery (American Edition)*, 25(3): 520-528.
- Moritomo H, Viegas SF, Nakamura K, Dasilva MF, Patterson RM (2000). The scaphotrapezio-trapezoidal joint. Part 1: An anatomic and radiographic study. *Journal of Hand Surgery (American Edition)*, 25(5): 899-910.
- Morley J, Bidwell J, Bransby-Zachary M (2001). A comparison of the findings of wrist arthroscopy and magnetic resonance imaging in the investigation of wrist pain. *Journal of Hand Surgery (British Edition)*, 26(6): 544-546.
- Morrey BF (1992). Posttraumatic stiffness: Distraction arthroplasty. *Orthopedics*, 15(7): 863-869.
- Morrey BF, An K-N (1985). Functional anatomy of the elbow ligaments. *Clin Orthop Relat Res*, 201: 84.
- Muller W (1983). *The knee: Form, function, and ligamentous reconstruction*. New York: Springer-Verlag.
- Nagle DJ (1994). Arthroscopic treatment of degenerative tears of the triangular fibrocartilage. *Hand Clinics*, 10(4): 615-624.
- Nagle DJ (1999). Laser-assisted wrist arthroscopy. *Hand Clinics*, 15(3): 495-499, ix.
- Nagle DJ, Geissler WB (2001). Laser assisted wrist arthroscopy. *Atlas of the Hand Clinics of North America*, 6: 189-201.

- Nakamura K, Beppu M, Matsushita K, Arai T, Ide T (1997). Biomechanical analysis of the stress force on midcarpal joint in kienböck's disease. *Hand Surgery*, 2(2): 101-115.
- Nakamura K, Beppu M, Patterson RM, hanson CA, Hume PJ, Viegas SF (2000). Motion analysis in two dimensions of radial-ulnar deviation of type i versus type ii lunates. *Journal of Hand Surgery (American Edition)*, 25A(5): 877-888.
- Nakamura R, Imaeda T, Miura T (1991). Scaphoid malunion. *Journal of Bone and Joint Surgery (British Volume)*, 73B: 134-137.
- Nakamura R, Watanabe K, Tsunoda K, Miura T (1993). Radial osteotomy for kienböck's disease evaluated by magnetic resonance imaging: 24 cases followed for 1-3 years. *Acta Orthopaedica Scandinavica*, 64: 207-211.
- Navarro A (1921). Luxaciones del carpo *Anales de la Facultad de Medicina*, 6: 113-141.
- Nillium A, Rosser B (1983). Akut compartment syndrom vid knaartroskopi. *Lakartidningen*: 80-90.
- Nordstrom DL, DeStefano F, Vierkant RA, Layde PM (1998). Incidence of diagnosed carpal tunnel syndrome in a general population. *Epidemiology*, 9(3): 342-345.
- Norkin CC, Levangie PK (1984). *Joint structure and function: A comprehensive analysis*. Philadelphia: FA Davis company.
- Nuttall D, Trail IA, Stanley JK (1998). Movement of the scaphoid in the normal wrist. *Journal of Hand Surgery (British Edition)*, 23(6): 762-764.
- Oka K, Murase T, Moritomo H, Goto A, Sugamoto K, Yoshikawa H (2005). Patterns of bone defect in scaphoid nonunion: A 3-dimensional and quantitative analysis. *Journal of Hand Surgery (American Edition)*, 30(2): 359-365.
- Oni OOA (1997). Irreducible buttonhole dislocation of the proximal interphalangeal joint of the finger:A case report. *Journal of Hand Surgery (American Edition)*: 100.
- Orbay JL (2000). The treatment of unstable distal radius fractures with volar fixation. *Hand Surg*, 5(2): 103-112.

- Orbay JL, Fernandez DL (2002). Volar fixation for dorsally displaced fractures of the distal radius: A preliminary report. *Journal of Hand Surgery (American Volume)*, 27(2): 205-215.
- Orbay JL, Fernandez DL (2004). Volar fixed-angle plate fixation for unstable distal radius fractures in the elderly patient. *Journal of Hand Surgery American Volume*, 29(1): 96-102.
- Osterman AL (1990). Arthroscopic debridement of triangular fibrocartilage complex tears. *Arthroscopy*, 6(2): 120-124.
- Osterman AL (2001). Arthroscopic pisoforectomy. in *International Wrist Investigators Workshop*.
- Osterman AL, Raphael J (1995). Arthroscopic resection of dorsal ganglion of the wrist. *Hand Clinics*, 11(1): 7-12.
- Palmer AK (1989). Triangular fibrocartilage complex lesions: A classification. *Journal of Hand Surgery (American Volume)*, 14A: 594-606.
- Palmer AK (1990). Triangular fibrocartilage disorders: Injury patterns and treatment. *Arthroscopy*, 6(2): 125-132.
- Palmer AK, Glisson RR, Werner FW (1984). Relationship between ulnar variance and triangular fibrocartilage complex thickness. *Journal of Hand Surgery (American Volume)*, 9(5): 681-682.
- Palmer AK, Werner FW, Murphy D, Glisson R (1985). Functional wrist motion: A biomechanical study. *Journal of Hand Surgery (American Edition)*, 10A(1): 39-46.
- Papaioannou T, Dickson RA (1982). Arthrodesis of the wrist in rheumatoid disease. *Hand*, 14(1): 12-16.
- Pathak G, Bain G (2003). Arthroscopic capsular shrinkage for midcarpal instability of the wrist. *J Bone Joint Surg (Br)*, 85B: 177.

- Pederzini L, Luchetti R, Soragni O, Alfarano M, Montagna G, Cerofolini E, Colombini R, Roth J (1992). Evaluation of the triangular fibrocartilage complex tears by arthroscopy, arthrography, and magnetic resonance imaging. *Arthroscopy*, 8(2): 191-197.
- Pederzini LA, Tosi M, Prandini M, Botticella C, Milandri L (2006). All-class suture technique for palmer class 1b triangular fibrocartilage repair. *Riv Chir Mano*, 43(2): 1-3.
- Peek RD, Haynes DW (1984). Compartment syndrome as a complication of arthroscopy a case report and a study of interstitial pressures. *The American Journal of Sports Medicine*, 12: 464.
- Pianka G (1992). Wrist arthroscopy. *Hand Clinics*, 8(4): 621-630.
- Plancher KD (2001). Methods of imaging the scaphoid. *Hand Clinics*, 17(4): 703-721.
- Poehling GG, Roth JH (1991). Articular cartilage lesions of the wrist. In: Mc Ginty JB, (Ed). *Operative arthroscopy*. ed. New York. Raven Press. 635-639.
- Poehling GP, Chabon SJ, Siegel DB (1994). Diagnostic and operative arthroscopy. In: Gelberman RH, (Ed). *The wrist: Master techniques in orthopedic surgery*. ed. New York. Raven Press.
- Pogue DJ, Viegas SF, Patterson RM, Peterson P, Jenkins DK, Sweo TD, Hokanson JA (1990). Effects of distal radius fracture malunion on wrist joint mechanics. *Journal of Hand Surgery (American Volume)*, 15: 721-727.
- Potter HG, Asnis-Ernberg L, Weiland AJ, Hotchkiss RN, Peterson MG, McCormack RR, Jr. (1997). The utility of high-resolution magnetic resonance imaging in the evaluation of the triangular fibrocartilage complex of the wrist. *Journal of Bone and Joint Surgery*, 79(11): 1675-1684.
- Pourgiezis N, Bain GI, Roth JH (1999). Volar ulnar approach to the distal radius and carpus. *Can J Plast Surg*, 7(6): 273-278.
- Prince RL, Knuiman MW, Gulland L (1993). Fracture prevalence in an Australian population. *Australian Journal of Public Health*, 17(2): 124-128.

- Protas JM, Jackson WT (1980). Evaluating carpal instabilities with fluoroscopy. *American Journal of Roentgenology*, 135: 137-140.
- Proubasta I, Lluch A, Celaya F, Doncel A, Mata JM, Donoso L (1989). Angled radiographic view of the wrist for diagnosis of fractures of the carpal scaphoid. *AJR American Journal of Roentgenology*, 153(1): 196.
- Quinn SF, Murray W, Watkins T, Kloss J (1987). Ct for determining the results of treatment of fractures of the wrist. *American Journal of Roentgenology*, 149: 109-111.
- Rangger C, Kathrein A, Freund MC, Klestil T, Kreczy A (1998). Bone bruise of the knee: Histology and cryosections in 5 cases. *Acta Orthopaedica Scandinavica*, 69(3): 291-294.
- Reagan DW, Linscheid RL, Dobyns JH (1984). Lunotriquetral sprains. *Journal of Hand Surgery (American Edition)*, 9 502-514.
- Resnick D, Georgen TG (2003). Physical injury: Concepts and terminology. In: Resnick D, (Ed). *Diagnosis of bone and joint disorders*. 4th ed. Philadelphia. WB Saunders. 2627-2782.
- Ribak S (2007). The importance of wrist arthroscopy for staging and treatment of kienböck's disease., in Pesentation FP484, IFSSH. Sydney.
- Richards RS, Bennett JD, Roth JH, Milne K, Jr. (1997). Arthroscopic diagnosis of intra-articular soft tissue injuries associated with distal radial fractures. *Journal of Hand Surgery (American Volume)*, 22(5): 772-776.
- Richards RS, Roth JH (1991). Wrist arthroscopy:Advances in diagnosis and treatment. *ADVANCES IN OPERATIVE ORTHOPAEDICS*, 1: 203-225.
- Richmond JC, al Assal M (1991). Arthroscopic management of arthrofibrosis of the knee, including infrapatellar contraction syndrome. *Arthroscopy*, 7(2): 144-147.
- Rogers WD, Watson HK (1990). Degenerative arthritis at the triscaphe joint. *Journal of Hand Surgery (American Edition)*, 15(2): 232-235.



- Rolfe EB, Garvie NW, Khan MA, Ackery DM (1981). Isotope bone imaging in suspected scaphoid trauma. *British Journal of Radiology*, 54(645): 762-767.
- Roth JH (1988). Radiocarpal arthroscopy: Techniques and selected cases. In: Lichtman DM, (Ed). *The wrist and its disorders*. ed. Philadelphia. WB Saunders. 108-117.
- Roth JH, Haddad RG (1986). Radiocarpal arthroscopy and arthrography in the diagnosis of ulnar wrist pain. *Arthroscopy*, 2(4): 234-243.
- Roth JH, Poehling GG (1990). Arthroscopic "-ectomy" Surgery of the wrist. *Arthroscopy*, 6: 141-147.
- Roth JH, Poehling GG, Whipple TL (1988). Arthroscopic surgery of the wrist. *Instructional Course Lectures*, 37: 183-194.
- Roth JH, Poehling GG, Whipple TL (1988). Hand instrumentation for small joint arthroscopy. *Arthroscopy*, 4: 126-128.
- Roth JH, Richards RS, Bennett JD, Milne K, Jr. (1995). Soft tissue injuries in distal radial fractures. *Current Trends in Hand Surgery*: 151-156.
- Rubin DA (2005) Expert panel on musculoskeletal imaging. Acute hand and wrist trauma. 8
- Ruby LK, Cooney WP, 3rd, An KN, Linscheid RL, Chao EY (1988). Relative motion of selected carpal bones: A kinematic analysis of the normal wrist. *Journal of Hand Surgery American Volume*, 13(1): 1-10.
- Ruby LK, Stinson J, Belsky MR (1985). The natural history of scaphoid non-union: A review of 55 cases. *Journal of Bone and Joint Surgery*, 67-A: 428-432.
- Ruch DS, Bowling J (1998). Arthroscopic assessment of carpal instability. *Arthroscopy*, 14(7): 675-681.
- Ruch DS, Chang DS, Poehling GG (1998). The arthroscopic treatment of avascular necrosis of the proximal pole following scaphoid nonunion. *Arthroscopy*, 14(7): 747-752.

- Ruch DS, Poehling GG (2005). Wrist arthroscopy: Anatomy and diagnosis. In: Green DP, Hotchkiss RN, Pederson WC, Wolfe SW, (Ed). Green's operative hand surgery. ed. Philadelphia. Elsevier, Churchill Livingstone. 769-780.
- Ruch DS, Vallee J, Poehling GG, Smith BP, Kuzma GR (2004). Arthroscopic reduction versus fluoroscopic reduction in the management of intra-articular distal radius fractures. *Arthroscopy*, 20(3): 225-230.
- Sagerman SD, Hauck RM, Palmer AK (1995). Lunate morphology: Can it be predicted with routine x-ray films? *Journal of Hand Surgery (American Edition)*, 201: 38-41.
- Sagerman SD, Short W (1996). Arthroscopic repair of radial-sided triangular fibrocartilage complex tears. *Arthroscopy*, 12: 339-342.
- Sanders WE (1988). Evaluation of the humpback scaphoid by computed tomography in the longitudinal axial plane of the scaphoid. *Journal of Hand Surgery (American Edition)*, 13A: 182-187.
- Sandow MJ, Wai YL, Hayes MG (1992). Intercarpal arthrodesis by dowel bone grafting. *Journal of hand Surgery [Br]*, 14(4): 463-466.
- Schajowicz F, Clavel Sainz M, Slullitel JA (1979). Juxta-articular bone cysts (intra-osseous ganglia): A clinicopathological study of eighty-eight cases. *Journal of Bone and Joint Surgery British Volume*, 61(1): 107-116.
- Shih JT, Lee HM, Hou YT, Tan CM (2005). Results of arthroscopic reduction and percutaneous fixation for acute displaced scaphoid fractures. *Arthroscopy*, 21(5): 620-626.
- Short WH, Werner FW, Fortino MD, Palmer AK (1992). Distribution of pressures and forces on the wrist after simulated intercarpal fusion and kienböck's disease. *Journal of Hand Surgery (American Edition)*, 17A: 443-449.
- Shrout, Fleiss JL (1979). Intraclass correlations: Uses in assessing rater reliability. *Psychological Bulletin*, 86: 420-428.

- Slade JF, 3rd, Geissler WB, Gutow AP, Merrell GA (2003). Percutaneous internal fixation of selected scaphoid nonunions with an arthroscopically assisted dorsal approach. *J Bone Joint Surg Am*, 85-A Suppl 4: 20-32.
- Slater RR, Szabo RM (1999). Scapholunate dissociation: Treatment with the dorsal intercarpal ligament capsulodesis. *Techniques in hand and Upper Extremity Surgery*, 3(4): 222-228.
- Slutsky DJ (2002). Arthroscopic repair of dorsal radiocarpal ligament tears. *Arthroscopy*, 18(9): E49.
- Slutsky DJ (2002). Wrist arthroscopy through a volar radial portal. *Arthroscopy*, 18(6): 624-630.
- Slutsky DJ (2005). Arthroscopic dorsal radiocarpal ligament repair. *Arthroscopy*, 21(12): 1486.
- Smiley P, Wasilewski SA (1990). Arthroscopic synovectomy. *Arthroscopy*, 6: 18-23.
- Smith DK, An KN, Cooney WP, 3rd, Linscheid RL, Chao EY (1989). Effects of a scaphoid waist osteotomy on carpal kinematics. *Journal of Orthopaedic Research*, 7(4): 590-598.
- Smith DK, Linscheid RL, Amadio PC, Berquist TH, Cooney WP (1989). Scaphoid anatomy: Evaluation with complex motion tomography. *Radiology*, 173(1): 177-180.
- Smith M, Bain GI, Chabrel N (2007). Anatomy, diagnostic techniques - CT scan assessment of AVN of the scaphoid, in 23rd International Wrist Investigators Workshop. Seattle, USA.
- Smith PA (2007). An alternative method for "All-inside" Anterior cruciate ligament reconstruction. *Arthroscopy*, 23(4): 451.
- Srinivasan VB, Matthews JP (1996). Results of scaphotrapezotrapezoid fusion for isolated idiopathic arthritis. *Journal of Hand Surgery (British & European Edition)*, 21B(3): 378-380.

- Stahl S, Reis ND (1986). Traumatic ulnar variance in kienböck's disease. *Journal of Hand Surgery (American Edition)*, 11(1): 95-97.
- Stanley JK, Gupta SR, Hullin MG (1986). Modified instruments for wrist fusion. *Journal of Hand Surgery (British Edition)*, 11(2): 245-249.
- Stordahl A, Schjoth A, Woxholt G, Fjermeros H (1984). Bone scanning of fractures of the scaphoid. *Journal of Hand Surgery (British Edition)*, 9(2): 189-190.
- Sullivan PP, Berquist TH (1991). Magnetic resonance imaging of the hand, wrist, and forearm: Utility in patients with pain and dysfunction as a result of trauma. *Mayo Clinic Proceedings*, 66(12): 1217-1221.
- Sweet S, Weiss L, E. (2001). Applications of electrothermal shrinkage in wrist arthroscopy. *Atlas of the Hand Clinics*, 6(2): 203-210.
- Taleisnik J (1976). The ligaments of the wrist. *Journal of Hand Surgery (American Volume)*, 1: 110-118.
- Taylor AR (1979). Synovectomy of the knee in rheumatoid arthritis patients. *Journal of Bone and Joint Surgery*, 61(B): 121.
- Terry DW, Jr., Ramin JE (1975). The navicular fat stripe: A useful roentgen feature for evaluating wrist trauma. *American Journal of Roentgenology, Radium Therapy and Nuclear Medicine*, 124(1): 25-28.
- Tham S, Coleman S, Gilpin D (1999). An anterior portal for wrist arthroscopy. *Journal Of Hand Surgery (British & European Volume)*, 24B(4): 445-447.
- Tham S, Ireland DC (1992). Intraosseous ganglion cyst of the lunate: Diagnosis and management. *Journal of Hand Surgery (British Edition)*, 17(4): 429-432.
- Theumann N, Favarger N, Schnyder P, Meuli R (2001). Wrist ligament injuries: Value of post-arthrography computed tomography. *Skeletal Radiol*, 30(2): 88-93.
- Thurston AJ, Stanley JK (1999). Dowel fusion of the scapho-trapezio-trapezoid joint: A description of a new technique. *Hand Surg*, 4(2): 125-129.

- Thurston AJ, Stanley JK (2000). Hamato-lunate impingement: An uncommon cause of ulnar-sided wrist pain. *Arthroscopy*, 16(5): 540-544.
- Tiel-van Buul M, et.al (1997). The diagnostic management of suspected scaphoid fracture. *Injury*, 28: 1-8.
- Tiel-van Buul MM, van Beek EJ, Borm JJ, Gubler FM, Broekhuizen AH, van Royen EA (1993). The value of radiographs and bone scintigraphy in suspected scaphoid fracture. A statistical analysis. *Journal of Hand Surgery (British Edition)*, 18(3): 403-406.
- Tiel-van Buul MMC, van Beek EJR, Broekhuizen AH, Nooitgedacht EA, Davids PHP, Bakker AJ (1992). Diagnosing scaphoid fractures: Radiographs cannot be used as a gold standard. *British Journal of Accident Surgery*, 23(2): 77-79.
- Tiel-van Buul MMC, Van beek EJR, et.al (1992). The reliability of the 3-phase bone scan in suspected scaphoid fracture: An inter- and intra-observer variability analysis. *Euro J Nuclear Medicine*, 19: 848-852.
- Tiel-van Buul MMC, van-Beek EJ, Broekhuizen AH, Bakker AJ, Bos KE (1993). Radiography and scintigraphy of suspected scaphoid fracture a long-term study in 160 patients. *Journal of Bone and Joint Surgery British Volume*, 75: 61-65.
- Tomaino MM, Gainer M, Towers JD (2001). Carpal impaction with the ulnar styloid process: Treatment with partial styloid resection. *Journal of Hand Surgery (British Edition)*, 26(3): 252-255.
- Topper SM, Wood MB, Ruby LK (1997). Ulnar styloid impaction syndrome. *Journal of Hand Surgery (American Edition)*, 22(4): 699-704.
- Trumble TE, Gilbert M, Vedder N (1996). Arthroscopic repair of the triangular fibrocartilage complex. *Arthroscopy*, (12): 588-597.
- Vender MI, Watson HK, Wiener BD, Black DM (1987). Degenerative change in symptomatic scaphoid non-union. *Journal of Hand Surgery (American Edition)*, 12A: 514-519.
- Verhellen R, Bain GI (2000). Arthroscopic capsular release for contracture of the wrist: A new technique. *Arthroscopy*, 16(1): 106-110.

- Verheyden J, Short WH (2001). Arthroscopic wafer procedure. *Atlas of the Hand Clinics*, 6(2): 241-252.
- Viegas SF (1986). Intraarticular ganglion of the dorsal interosseous scapholunate ligament: A case for arthroscopy. *Arthroscopy*, 2(2): 93-95.
- Viegas SF (1990). The lunatohamate articulation of the midcarpal joint. *Arthroscopy*, 6(1): 5-10.
- Viegas SF, Ballantyne G (1987). Attritional lesions of the wrist joint. *Journal of Hand Surgery (American Volume)*, 12(6): 1025-1029.
- Viegas SF, Hillman GR, Elder K, Stoner D, Patterson RM (1993). Measurement of carpal bone geometry by computer analysis of three-dimensional ct images`. *Journal of Hand Surgery (American Volume)*, 18A: 341-349.
- Viegas SF, Patterson RM (1997). Load mechanics of the wrist. *Hand Clinics of North America*, 13(1): 109-128.
- Viegas SF, Patterson RM, Hobanson JA, Davis J (1993). Wrist anatomy: Incidence distribution and correlation of anatomic variations tears and arthrosis. *Journal of Hand Surgery (American Volume)*, 18A: 463-475.
- Viegas SF, Patterson RM, Ward K (1995). Extrinsic wrist ligaments in the pathomechanics of ulnar translation instability. *Journal of Hand Surgery (American Edition)*, 20A: 312-318.
- Viegas SF, Wagner K, Paterson R, Peterson P (1990). Medial (hamate) facet of the lunate. *Journal of Hand Surgery (American Volume)*, 15A: 564-571.
- von Bonin G (1929). A note on the kinematics of the wrist joint. *Journal of Anatomy*, 63(Pt 2): 259-262..
- Vrettos BC, Adams BK, et.al (1996). Is there a place for radionuclide bone scintigraphy in the management of radiograph-negative scaphoid trauma? *South African Medical Journal*, 86: 540-542.

- Waizenegger M (1993). Intraosseous ganglia of carpal bones. *Journal of Hand Surgery British*, 18(3): 350-355.
- Wallwork NA, Bain GI (2001). Sigmoid notch osteoplasty for chronic volar instability of the distal radioulnar joint: A case report. *Journal of Hand Surgery (American Edition)*, 26(3): 454-459.
- Warhold LG, Ruth RM (1995). Complications of wrist arthroscopy and how to prevent them. *Hand Clinics of North America*, 11(1): 81-89.
- Warner JJ, Allen A, Marks PH, Wong P (1996). Arthroscopic release for chronic, refractory adhesive capsulitis of the shoulder. *Journal of Bone and Joint Surgery*, 78(12): 1808-1816.
- Warner JJP, Allen AA, Marks PH, Wong P (1997). Arthroscopic release of postoperative capsular contracture of the shoulder. *Journal of Bone and Joint Surgery*, 79A(8): 1151-1158.
- Warren LF, Marshall JL (1979). The supporting structures and layers on the medial side of the knee: An anatomical analysis. *Journal of Bone and Joint Surgery*, 61(1): 56-62.
- Watson FM, Eaton RG (1987). Post-traumatic radio-ulnar synostosis. *J Trauma*, 18: 467-468.
- Watson HK (1980). Limited wrist arthrodesis. *Clin Orthop Relat Res*, 149: 126-136.
- Watson HK (1988). Stiff joints. In: Green DP, (Ed). *Operative hand surgery*. ed. New York. Churchill Livingstone. 537-552.
- Watson HK, Ashmead Dt, Makhlof MV (1988). Examination of the scaphoid. *Journal of Hand Surgery (American Volume)*, 13(5): 657-660.
- Watson HK, Monacelli DM, Milford RS, Ashmead D, IV. (1996). Treatment of kienböck's disease with scaphotrapezio-trapezoid arthrodesis. *Journal of Hand Surgery (American Volume)*, 21(a): 9-15.
- Watson HK, Rogers WD, Ashmead Dt (1989). Reevaluation of the cause of the wrist ganglion. *Journal of Hand Surgery (American Volume)*, 14(5): 812-817.

- Watson HK, Ryu J, Burgess RC (1986). Matched distal ulnar resection. *Journal of Hand Surgery (American Edition)*, 11A: 812-817.
- Weber ER (1980). Biomechanical implications of scaphoid waist fractures. *Clin Orthop Relat Res*, 149: 83-89.
- Weber ER (1984). Concepts governing the rotational shift of the intercalated segment of the carpus. *Orthopaedic Clinics of North America*, 15: 193-207.
- Weber ER (1997). Physiological bases for wrist function. In: Lichtman DM, Alexander AH, (Ed). *The wrist and its disorders*. 2nd ed. Philadelphia. WB Saunders. 48-54.
- Weil WM, Slade JF, 3rd, Trumble TE (2006). Open and arthroscopic treatment of perilunate injuries. *Clin Orthop Relat Res*, 445: 120-132.
- Weiss AP, Sachar K, Glowacki KA (1997). Arthroscopic debridement alone for intercarpal ligament tears. *Journal of Hand Surgery (American Edition)*, 22(2): 344-349.
- Whipple T (1992). *Arthroscopic surgery of the wrist*. Philadelphia: JB Lippincott.
- Whipple TL (1982). Clinical applications of wrist arthroscopy. In: Lichtman DM, (Ed). *The wrist and its disorders*. ed. Philadelphia. WB Saunders. 118-128.
- Whipple TL (1988). Powered instruments for wrist arthroscopy. *Arthroscopy*, 4: 290-294.
- Whipple TL (1982). Articular surface defects and loose bodies. In: *Arthroscopic surgery of the wrist*. ed. Philadelphia. JB Lippincott. 93-102.
- Whipple TL (1995). The role of arthroscopy in the treatment of intra-articular wrist fractures. *Hand Clinics of North America*, 11(1): 13-18.
- Whipple TL (1995). The role of arthroscopy in the treatment of scapholunate instability. *Hand Clinics of North America*, 11: 37-40.
- Whipple TL (1995). Stabilization of the fractured scaphoid under arthroscopic control. *Orthopaedic Clinics of North America*, 26(4): 749-754.
- Whipple TL, Geissler WB (1993). Arthroscopic management of wrist triangular fibrocartilage complex injuries in the athlete. *Orthopedics*, 16(9): 1061-1067.



- White SJ, Louis DS, Braunstein EM, Hankin FM, Green TL (1984). Capitate-lunate instability: Recognition by manipulation under fluoroscopy. *American Journal of Roentgenology*, 143: 361-364.
- Wiesler ER, Chloros GD, Lucas RM, Kuzma GR (2006). Arthroscopic management of volar lunate facet fractures of the distal radius. *Techniques in hand and Upper Extremity Surgery*, 10(3): 139-144.
- Wilson AJ, Mann FA, Gilula LA (1990). Imaging the hand and wrist. *Journal of Hand Surgery (British Edition)*, 15(2): 153-167.
- Wnorowski DC, Palmer AK, Werner FW (1992). Anatomic and biomechanical analysis of the arthroscopic wafer procedure. *Arthroscopy*, 8: 204-212.
- Wolfe SW, Easterling KJ, Yoo HH (1995). Arthroscopic-assisted reduction of distal radius fractures. *Arthroscopy*, 11(6): 706-714.
- Wolfe SW, Neu C, Crisco JJ (2000). In vivo scaphoid, lunate, and capitate kinematics in flexion and in extension. *Journal of Hand Surgery American Volume*, 25(5): 860-869.
- Wozasek GE, Moser KD (1991). Percutaneous screw fixation for fractures of the scaphoid. *Journal of Bone and Joint Surgery British Volume*, 73B: 138-142.
- Wright TW, Cooney WP, III., Ilstrup DM (1994). Anterior wrist ganglion. *Journal of Hand Surgery (American Edition)*, 196: 954-958.
- Young L, Bartell T, Logan SE (1988). Ganglions of the hand and wrist. *Southern Medical Journal*, 81(6): 751-760.
- Zanotti RM, Kuhn JE (1997). Arthroscopic capsular release for the stiff shoulder. Description of technique and anatomic considerations. *American Journal of Sports Medicine*, 25(3): 294-298.

## **ATTACHMENTS - PUBLICATIONS**

### **Introduction**

The following two pages list all of the peer review publications presented in the thesis. The number provided before the title corresponds to the research undertaken section. The full peer-reviewed publication is then provided.

### **Anatomy**

3.2 Influence of lunate type on scaphoid kinematics.

Galley I, Bain GI, McLean JM (2007). *Journal of Hand Surgery (American Volume)*, 32(6): 842-847. (see page 217)

3.3 An anatomic study of the triquetrum-hamate joint.

McLean J, Bain G, Eames M, Fogg Q, Pourgiezis N (2006). *Journal of Hand Surgery (American Volume)*, 31(4): 601-607. (see page 223)

### **Imaging**

4.2 Longitudinal computed tomography of the scaphoid.

Bain GI, Bennett JD, Richards RS, Slethaug GP, Roth JH (1995). *Skeletal Radiology*, 24: 271-273. (see page 230)

4.3 Measurement of the scaphoid humpback deformity using longitudinal computed tomography: Intra- and inter-observer variability using various measurement techniques.

Bain GI, Bennett JD, MacDermid JC, Slethaug GP, Richards RS, Roth JH (1998). *Journal of Hand Surgery (American Volume)*, 23A(1): 76-81. (see page 233)

4.4 Clinical utilisation of computed tomography of the scaphoid.

Bain GI (1999). *Hand Surg*, 4(1): 3-9. (see page 239)

4.5 Operative fluoroscopy in hand and upper limb surgery. One hundred cases.

Bain GI, Hunt J, Mehta JA (1997). *Journal of Hand Surgery (American Volume)*, 22B(5): 656-658. (see page 246)

## **Arthroscopy**

### 5.2 Arthroscopic assessment and classification of Kienböck's disease.

Bain GI, Begg M (2006). *Tech Hand Up Extrem Surg*, 10(1): 8-13. (see page 249)

### 5.3 Anatomical reduction of intra-articular fractures of the distal radius. An arthroscopically-assisted approach.

Mehta JA, Bain GI, Heptinstall RJ (2000). *Journal of Bone and Joint Surgery (British Volume)*, 82(1): 79-86. (see page 255)

### 5.4 Results of arthroscopic debridement for isolated scaphotrapeziotrapezoid arthritis.

Ashwood N, Bain GI, Fogg Q (2003). *Journal of Hand Surgery (American Volume)*, 28(5): 729-732. (see page 263)

### 5.5 Arthroscopically assisted treatment of intra-osseous ganglions of the lunate: A new technique.

Ashwood N, Bain GI (2003). *Journal of Hand Surgery (American Volume)*, 28(1): 62-68. (see page 267)

### 5.6 Arthroscopic capsular release for contracture of the wrist: A new technique.

Verhellen R, Bain GI (2000). *Arthroscopy*, 16(1): 106-110. (see page 273)

### 5.7 Arthroscopic excision of ulnar styloid in stylo-carpal impaction.

Bain GI, Bidwell TA (2006). *Arthroscopy*, 22(6): 677.e1-3. (see page 278)

Galley, I., Bain, G.I. & McLean, J.M. (2007). Influence of lunate type on scaphoid kinematics.  
*Journal of Hand Surgery (American Volume)*, vol 32(6), pp. 842-847.

NOTE: This publication is included on pages 217-222 in the print copy of the thesis held in the University of Adelaide Library.

McLean, J., Bain, G., Eames, M., Fogg, Q. & Pourgiezis, N. (2006). An anatomic study of the triquetrum-hamate joint.  
*Journal of Hand Surgery (American Volume)*, vol 31(4), pp. 601-607.

NOTE: This publication is included on pages 223-229 in the print copy of the thesis held in the University of Adelaide Library.

Bain, G.I., Bennett, J.D., Richards, R.S., Slethaug, G.P. & Roth, J.H. (1995). Longitudinal computed tomography of the scaphoid: a new technique  
Skeletal Radiology, vol 24 (4), pp. 271-273.

NOTE: This publication is included on pages 230-233 in the print copy of the thesis held in the University of Adelaide Library.

Bain, G.I., Bennett, J.D., MacDermid, J.C., Slethaug, G.P., Richards, R.S. & Roth, J.H. (1998). Measurement of the scaphoid humpback deformity using longitudinal computed tomography: Intra- and inter-observer variability using various measurement techniques. *Journal of Hand Surgery (American Volume)*, vol 23A(1), pp. 76-81.

NOTE: This publication is included on pages 233-238 in the print copy of the thesis held in the University of Adelaide Library.

Bain, G.I. (1999). Clinical utilisation of computed tomography of the scaphoid.  
*Hand Surgery, vol 4(1), pp. 3-9.*

NOTE: This publication is included on pages 239-245 in the print  
copy of the thesis held in the University of Adelaide Library.



Bain, G.I., Hunt, J. & Mehta, J.A. (1997). Operative fluoroscopy in hand and upper limb surgery. One hundred cases.  
*Journal of Hand Surgery (British and European Volume)*, vol 22B(5), pp. 656-658

NOTE: This publication is included on pages 246-248 in the print copy of the thesis held in the University of Adelaide Library.

It is also available online to authorised users at:

[http://dx.doi.org/10.1016/S0266-7681\(97\)80368-3](http://dx.doi.org/10.1016/S0266-7681(97)80368-3)

Bain, G.I. & Begg, M. (2006). Arthroscopic assessment and classification of Kienböck's disease.  
*Techniques in Hand and Upper Extremity Surgery, vol 10(1), pp. 8-13.*

NOTE: This publication is included on pages 249-254 in the print copy of the thesis held in the University of Adelaide Library.

Mehta, J.A., Bain, G.I. & Heptinstall, R.J. (2000). Anatomical reduction of intra-articular fractures of the distal radius. An arthroscopically-assisted approach. *Journal of Bone and Joint Surgery (British Volume)*, vol 82(1), pp. 79-86.

NOTE: This publication is included on pages 255-262 in the print copy of the thesis held in the University of Adelaide Library.

Ashwood, N., Bain, G.I. & Fogg, Q. (2003). Results of arthroscopic debridement for isolated scaphotrapeziotrapezoid arthritis.  
*Journal of Hand Surgery (American Volume)*, vol. 28(5), pp. 729-732

NOTE: This publication is included on pages 263-266 in the print copy of the thesis held in the University of Adelaide Library.

Ashwood, N. & Bain, G.I. (2003). Arthroscopically assisted treatment of intra-osseous ganglions of the lunate: A new technique.  
*Journal of Hand Surgery (American Volume)*, vol 28(1), pp. 62-68

NOTE: This publication is included on pages 267-272 in the print copy of the thesis held in the University of Adelaide Library.

Verhellen, R. & Bain, G.I. (2000). Arthroscopic capsular release for contracture of the wrist:  
A new technique.  
*Arthroscopy, vol 16(1), pp. 106-110*

NOTE: This publication is included on pages 273-277 in the print  
copy of the thesis held in the University of Adelaide Library.

Bain, G.I. & Bidwell, T.A. (2006). Arthroscopic excision of ulnar styloid in stylo-carpal impaction.  
*Arthroscopy*, vol 22(6), pp. 677.e1-677.e3

NOTE: This publication is included on pages 278-280 in the print copy of the thesis held in the University of Adelaide Library.

**A Video CD is included with the print copy  
held in the University of Adelaide Library.**