

# **Chemotherapy-induced mucositis: the role of matrix metalloproteinases and the extracellular matrix**

Noor Al-Dasooqi

BSc (Hons)

Thesis submitted for the degree of

**Doctor of Philosophy**

Discipline of Medicine

Faculty of Health Sciences

University of Adelaide

October 2011

This work contains no material which has been accepted for the award of any other degree or diploma in any university or other tertiary institution and, to the best of my knowledge and belief, contains no material previously published or written by another person, except where due reference has been made in the text.

I give consent to this copy of my thesis, when deposited in the University Library, being available for loan and photocopying, subject to the provisions of the Copyright Act 1968.

The author acknowledges that copyright of published works contained within this thesis (as listed below) resides with the copyright holder(s) of those works.

I also give permission for the digital version of my thesis to be made available on the web, via the University's digital research repository, the library catalogue and also through web search engines, unless permission has been granted by the University to restrict access for a period of time.

Noor Al-Dasooqi

October 2011

---

<i>Declaration</i>	ii
<i>Index</i>	iii
<i>Abstract</i>	x
<i>Acknowledgments</i>	xii
<i>Publications arising from thesis</i>	xiv
<i>Contributions made by co-authors</i>	xv
<i>Additional studies and publications</i>	xvii
<i>Thesis explanation</i>	xviii
<i>Ethics</i>	xix
<b>1.0 Literature Review</b>	<b>1</b>
1.1 Introduction	1
1.2 The healthy alimentary tract	2
<i>1.2.1 Alimentary tract histology</i>	2
<i>1.2.2 Cell renewal</i>	3
1.3 The gastrointestinal lamina propria	5
<i>1.3.1 Role, structure and constituents</i>	5
<i>1.3.2 Cellular components</i>	5
<i>1.3.3 Extracellular matrix</i>	6
<i>1.3.4 Role of the basement membrane in epithelial integrity</i>	6
1.4 Chemotherapy and the alimentary tract	9
<i>1.4.1 Irinotecan</i>	9
1.5 Signalling systems in mucositis	10
<i>1.5.1 The 5-phase model for the development of mucositis</i>	10
<i>1.5.2 Mucositis signalling pathways</i>	11

---

1.6	Matrix metalloproteinases (MMPs)	12
	<i>1.6.1 Function</i>	12
	<i>1.6.2 Regulation of MMPs</i>	12
1.7	MMPs in Cancer	13
1.8	The healthy alimentary tract, MMPs and the extracellular matrix	14
1.9	MMPs, tissue remodelling and disease	18
	<i>1.9.1 MMPs in gut diseases</i>	18
	<i>1.9.2 MMP expression following chemotherapy</i>	18
	<i>1.9.3 Tissue injury and MMP synthesis</i>	20
	<i>1.9.4 MMPs and inflammation</i>	21
1.10	Evidence for role of MMPs in mucositis	23
	<i>1.10.1 Message generation and amplification phases</i>	23
	<i>1.10.2 Ulcerative phase</i>	24
	<i>1.10.3 Healing phase</i>	26
1.11	Serum MMPs as biomarkers of mucositis	26
1.12	Theoretical opportunities for intervention	28
1.13	Conclusions	29
1.14	Aims of study	29
<b>2.0</b>	<b>Selection of housekeeping genes for gene expression studies in a rat model of irinotecan-induced mucositis</b>	<b>30</b>
2.1	Introduction	30
2.2	Materials and methods	33
	<i>2.2.1 Animals</i>	33
	<i>2.2.2 Irinotecan-induced mucositis model</i>	33

---

2.2.3	<i>Histological Assessment</i>	34
2.2.4	<i>Immunohistochemistry</i>	34
2.2.5	<i>Reference gene selection and primers</i>	35
2.2.6	<i>RNA isolation and reverse transcription</i>	39
2.2.7	<i>Real-time PCR</i>	39
2.2.8	<i>Determination of reference gene expression stability</i>	40
2.2.9	<i>Calculation of relative expression of MMP2</i>	40
2.2.10	<i>Statistical analysis</i>	41
2.3	Results	42
2.3.1	<i>Response to treatment</i>	42
2.3.2	<i>Histological analysis</i>	42
2.3.3	<i>RNA quality</i>	42
2.3.4	<i>RT-PCR efficiency</i>	43
2.3.5	<i>Expression of housekeeping genes following irinotecan treatment</i>	43
2.3.6	<i>Stability of housekeeping genes within sample groups</i>	47
2.3.7	<i>Stability of housekeeping genes compared to normal tissue</i>	47
2.3.8	<i>MMP2 expression in the jejunum following irinotecan treatment</i>	49
2.3.9	<i>Validation of selected candidate housekeeping gene using MMP2 in the jejunum</i>	51
2.4	Discussion	53
2.5	Conclusions	56
2.6	Acknowledgments	57

---

<b>3.0</b>	<b>Matrix metalloproteinases are possible mediators for the development of alimentary tract mucositis in the DA rat</b>	<b>58</b>
3.1	Introduction	58
3.2	Materials and methods	61
	3.2.1 <i>Animals</i>	61
	3.2.2 <i>Experimental plan</i>	61
	3.2.3 <i>Histological assessment</i>	62
	3.2.4 <i>RNA isolation and reverse transcription</i>	62
	3.2.5 <i>Real-time PCR</i>	63
	3.2.6 <i>Immunohistochemistry</i>	66
	3.2.7 <i>Statistics</i>	67
3.3	Results	68
	3.3.1 <i>Response to treatment and histological analysis</i>	68
	3.3.2 <i>MMP and TIMP gene expression following irinotecan treatment</i>	70
	3.3.3 <i>Tissue levels of MMPs following irinotecan</i>	72
	3.3.4 <i>Tissue levels of TIMPs following irinotecan</i>	79
	3.3.5 <i>Plasminogens gene expression following irinotecan</i>	79
3.4	Discussion	81
3.5	Conclusions	85
3.6	Acknowledgments	86
<b>4.0</b>	<b>Irinotecan-induced alterations in intestinal cell kinetics and extracellular matrix component expression</b>	<b>87</b>
4.1	Introduction	87
4.2	Materials and methods	91

---

4.2.1	<i>Animal study</i>	91
4.2.2	<i>Histological assessment</i>	92
4.2.3	<i>TUNEL for apoptotic cells</i>	92
4.2.4	<i>Picro-sirius red staining for collagen</i>	93
4.2.5	<i>Masson's trichrome staining</i>	93
4.2.6	<i>Immunohistochemistry</i>	94
4.2.7	<i>Statistics</i>	95
4.3	Results	96
4.3.1	<i>Response to treatment and histological analysis</i>	96
4.3.2	<i>Proliferation and apoptosis following irinotecan</i>	96
4.3.3	<i>Collagen fibres and basement membrane collagen following irinotecan</i>	101
4.3.4	<i>The expression of extracellular matrix proteins following irinotecan</i>	105
4.4	Discussion	109
4.5	Conclusions	113
4.6	Acknowledgments	114
<b>5.0</b>	<b>Serum MMPs as biomarkers of mucositis in cancer patients receiving cytotoxic chemotherapy</b>	<b>115</b>
5.1	Introduction	115
5.2	Methods	117
5.2.1	<i>Patient cohort</i>	117
5.2.2	<i>Analysis of medical records</i>	117
5.2.3	<i>Sample preparation for enzyme-linked immunosorbent assay (ELISA) detection of fecal calprotectin</i>	118

---

5.2.4	<i>Sample preparation for enzyme-linked immunosorbent assay (ELISA) detection or serum MMP-2, -3 and -9</i>	118
5.2.5	<i>Statistics</i>	119
5.3	Results	120
5.3.1	<i>Patient characteristics</i>	120
5.3.2	<i>Toxicities induced following cytotoxic chemotherapy</i>	121
5.3.3	<i>Fecal levels of calprotectin</i>	121
5.3.4	<i>Serum levels of MMP-2, -3 and -9</i>	121
5.3.5	<i>Association between serum MMPs and GI toxicity</i>	127
5.4	Discussion	128
5.5	Conclusions	131
5.6	Acknowledgments	132
<b>6.0</b>	<b>General discussion</b>	<b>133</b>
6.1	Introduction	133
6.2	Chemotherapy-induced mucositis	133
6.3	Housekeeping genes in mucositis	136
6.4	Gastrointestinal matrix metalloproteinase expression following chemotherapy	137
6.5	The upstream regulators of MMP expression	140
6.6	What could be the downstream targets of MMPs in mucositis?	142
6.7	Structure of the extracellular matrix following chemotherapy	143
6.7.1	<i>Collagen</i>	144
6.7.2	<i>Fibronectin</i>	147
6.8	Serum matrix metalloproteinases as biomarkers of mucositis	148
6.9	Conclusions	149



<b>7.0</b>	<b>References</b>	<b>151</b>
------------	-------------------	------------

**Publications arising from this thesis**

Chemotherapeutic agents, including irinotecan hydrochloride, are highly effective in the treatment of a range of cancers; however, they cause a variety of unwanted toxicities. Mucositis is the term used to describe the damage caused by cytotoxic agents to mucous membranes of the alimentary tract (AT). This condition affects 40-100% of patients depending on dose regimen. There is currently no effective treatment and the underlying molecular mechanisms are not fully understood. Previous research has shown that mucositis encompasses changes in stress response gene expression and subsequently activation of tissue injury and inflammation mediators.

Matrix metalloproteinases (MMPs) are a group of zinc-dependent endopeptidases; which have been shown to play a role in tissue injury and inflammation in many gastrointestinal disorders. Furthermore, MMPs mediate these phenomena through the regulation of the extracellular matrix (ECM). This work aims to elucidate whether MMPs contribute to the pathogenesis of mucositis and whether these can be used as biomarkers for mucositis development or be targeted for future treatment strategies. To investigate these aims, studies were performed in an animal model of irinotecan-induced mucositis. A pilot clinical study was also conducted.

To investigate the role of MMPs in mucositis pathogenesis, a time-course model of irinotecan-induced mucositis was utilised. Rats were administered with 200mg/kg irinotecan intraperitoneally at 0h and killed 30, 60, 90 min, 2, 6, 12, 24, 48, 72, 144h post-treatment. Sections were embedded in paraffin or frozen for further analysis. To ensure the accuracy of the molecular investigations in this thesis, the appropriateness of a range of housekeeping genes for normalisation of RT-PCR methods was investigated for the first time in this model. Findings indicated that the most suitable combination of genes

to use is Ywhaz/UBC in the jejunum and UBC/ $\beta$ -actin in the colon *or* UBC if restricted to a single housekeeping gene. Subsequent molecular and histological assessments demonstrated a significant alteration in gene expression and tissue levels of MMPs and their inhibitors (TIMPs) following irinotecan ( $p < 0.05$ ). The increase in MMP-2, -3, -9 and -12 levels was associated with inflammatory infiltrate and maximum tissue damage. In contrast, MMP-1 expression correlated with tissue restitution. Furthermore, histological techniques illustrated a substantial increase in total collagen deposits around crypts from 24h in the jejunum and colon. Fibronectin expression decreased significantly in both regions from 6-24h following treatment. Irinotecan induced a significant alteration in epithelial cell kinetics in both the jejunum and colon ( $p < 0.05$ ) and this correlated with changes in ECM components.

To determine if systemic MMP levels are useful markers of impending toxicity, a pilot clinical study was carried out. Eight patients receiving a variety of chemotherapy regimens were recruited. The most reported toxicity following treatment was diarrhoea. Analysis of patient serum samples revealed a 5.74-fold increase in systemic MMP-3 and a 2-fold increase in systemic MMP-12 levels following the administration of chemotherapy. Analysis of MMP-3 levels with patient symptoms revealed a correlation.

Findings from this thesis provide clear evidence demonstrating a role for MMPs and ECM components in the pathogenesis of irinotecan-induced mucositis. Alterations in total collagen deposits and fibronectin levels in the AT following treatment may underlie the dysregulated cell kinetics following treatment hence leading to toxicity. Furthermore, preliminary findings from the pilot clinical study suggest that circulating MMPs are potential biomarkers of gastrointestinal toxicity induced by specific chemotherapy agents.

All thanks to God for providing me with this opportunity and helping me achieve my PhD for without His assistance and guidance none of this would have been possible.

I extend my true and sincere gratitude to my three supervisors, Dr Rachel Gibson, Dr Joanne Bowen and Professor Dorothy Keefe for their invaluable guidance and continued support throughout my PhD. I very much value having you as my mentors. Your knowledge, enthusiasm and dedication towards medical research has stimulated my interest and allowed me to pursue this project.

Many thanks to all members of the Mucositis Research Laboratory - Andrea, Richard, Emma, Bronwen, Erin, Anthony and Roger. It has been very wonderful to undertake my PhD with such an enthusiastic and supportive research team.

To Mr. Thomas Sullivan at the Discipline of Public Health, University of Adelaide, thanks for providing the statistics for all studies in this thesis.

To my wonderful parents Mayada and Mohammed, without your love, support and continuous prayers I would not have gotten this far. You have been great life coaches, teaching me to always have faith in my abilities and pursue my dreams. Thank you.

To my siblings Nada and Abdul, thank you for always being there to cheer me up and giving me the support I needed. Nada, our frequent coffee outings and retail therapy went a long way. And thank you for always being there to help take care of baby. Abdul, thank you for always being there to accompany me to work when I needed to go in on weekends.

To my wonderful husband Essa, thank you for supporting all my endeavours and providing me with continuous encouragement. You always manage to put a smile on my face with your love, kindness and care. For baby Omar, thank you for keeping me up at night but more importantly for providing your dad and I with countless moments of laughter and happiness. You both (and all our children to come) mean the world to me.

**Al-Dasooqi N**, Bowen JM, Gibson RJ, Logan RM, Stringer A & Keefe DM (2011). Irinotecan-induced alterations in intestinal cell kinetics and extracellular matrix component expression. *International Journal of Experimental Pathology* 92(5): 357-365

**Al-Dasooqi N**, Bowen JM, Gibson RJ, Logan RM, Stringer A & Keefe DM (2011). Selection of housekeeping genes for gene expression studies in a rat model of irinotecan-induced mucositis. *Chemotherapy* 57(1): 43-53

**Al-Dasooqi N**, Gibson RJ, Bowen JM, Logan RM, Stringer A & Keefe DM (2010). Matrix metalloproteinases are possible mediators for the development of alimentary tract mucositis in the DA rat. *Experimental Biology and Medicine* 235(10): 1244-1256

**Al-Dasooqi N**, Gibson RJ, Bowen JM, & Keefe D (2009). Matrix metalloproteinases: key regulators in the pathogenesis of chemotherapy-induced mucositis?. *Cancer Chemotherapy and Pharmacology*, 64(1): 1-9

**Dr Rachel Gibson**

Dr Rachel Gibson was my principal supervisor and therefore listed as a co-author on all publications arising from this thesis. She assisted in the development of my original research proposal and provided funding for the work that was completed during my candidature. In addition she read through many drafts of the individual papers as well as this thesis.

**Professor Dorothy Keefe**

Professor Dorothy Keefe was my co-supervisor and therefore listed as a co-author on all publications arising from this thesis. She assisted in the development of my original research proposal and provided funding for the work that was completed during my candidature. In addition she read through many drafts of the individual papers as well as this thesis.

**Dr Joanne Bowen**

Dr Joanne Bowen was my co-supervisor and therefore listed as a co-author on all publications arising from this thesis. She assisted in the development of my original research proposal and provided funding for the work that was completed during my candidature. In addition she read through many drafts of the individual papers as well as this thesis.

**Associate Professor Richard Logan**

Associate Professor Richard Logan is a member of the Mucositis Research Group. He assisted with all of the animal experiments undertaken in this study. He also read numerous drafts of the individual papers making up this thesis.

**Dr Andrea Stringer**

Dr Andrea Stringer is a member of the Mucositis Research Group. She assisted with all of the animal experiments undertaken in this study. She also read numerous drafts of the individual papers making up this thesis.



During my candidature, I was involved in several other studies, not presented in this thesis. These have resulted in primary authorship or co-authorship on several manuscripts. I am first author on an invited review. I have also contributed an invited book chapter on a newly emerging field in mucositis research.

**Al-Dasooqi N**, Gibson RJ, Bowen JM & Keefe D (2011). HER2 targeted therapy-induced gastrointestinal toxicity: from the clinical experience to possible molecular mechanisms. In: Whitehouse, D and Rapley, R *Molecular and Cellular Therapeutics* (xx). UK: John Wiley & Son (invited book chapter)

**Al-Dasooqi N**, Gibson RJ, Bowen JM & Keefe D (2009). HER2 targeted therapies for Cancer and the Gastrointestinal Tract. *Current Drug Targets*, 10(6): 537-542 IF 4.19 (invited review)

**Al-Dasooqi N**, Bowen JM, Gibson RJ, Sullivan T, Lee J & Keefe D (2009). Trastuzumab induces gastrointestinal side effects in HER2-overexpressing breast cancer patients. *Investigational New Drugs*, 27(2): 173-178 IF 3.4

Stringer A, Gibson R, Bowen J, Logan R, Ashton K, Yeoh A, **Al-Dasooqi N**, Keefe D (2008). Irinotecan-induced mucositis manifesting as diarrhoea corresponds with an amended intestinal flora and mucin profile. *International Journal of Experimental Pathology*, 90(5): 489-99 IF 1.89

This thesis is composed of 6 chapters: literature review, four distinct research chapters, followed by a general discussion. During the course of my candidature, four chapters were published, with a further one under review. Accordingly, each research chapter is written as a publication complete with introduction, materials and methods, results and discussions. Some minor editing of the chapters has been made to ensure a consistent format of the chapters, to avoid significant repetition and to include relevant data omitted from publications. Unavoidable repetition has occurred only as necessary due to the format of the paper.

The animal studies conducted were approved by the Animal Ethics Committee of The Institute of Medical and Veterinary Sciences and of The University of Adelaide. They complied with the National Health and Medical Research Council (Australia) Code of Practice for Animal Care in Research and Training (2004). Due to the potentially severe nature of the diarrhoea caused by irinotecan, animals were monitored four times daily and if any animals showed certain criteria (as defined by the Animal Ethics Committee) they were euthanased. These criteria included a dull ruffled coat with accompanying dull and sunken eyes, coolness to touch with no spontaneous movement, and a hunched appearance.

The clinical study was approved by the Ethics of Human Research Committee of the Royal Adelaide Hospital and was carried out in accordance with the Declaration of Helsinki. Informed consent was obtained from each patient prior to enrolment in the study. All patients were de-identified.

## **1.0 Literature Review**

### **1.1 Introduction**

Mucositis is a major oncological problem associated with the damage caused by anti-cancer therapy to mucous membranes of the alimentary tract (AT) (Gibson et al., 2005; Yeoh et al., 2005; Sonis, 2007). AT mucositis has been reported to occur in 40% of patients receiving standard dose chemotherapy and 100% of patients receiving high dose chemotherapy (Keefe, 2004; Sonis, 2004; Yeoh et al., 2005; Keefe et al., 2007). This condition is manifest by a range of symptoms depending on the area of the AT that is most affected. Clinical symptoms include, but are not limited to, ulceration, nausea and vomiting, diarrhoea and rectal bleeding (Keefe et al., 2007; Capp et al., 2009). Moreover, the effects of mucositis are not confined to AT symptoms but can also result in local and systemic infections as well as fatigue as a consequence of bacterial colonisation and malnutrition, respectively (Keefe et al., 2007; Murphy, 2007; Aprile et al., 2008).

The burden of mucositis is overwhelming to patients. Moreover, mucositis significantly affects clinical outcomes as a result of reductions in anti-cancer therapy doses and treatment breaks (Keefe et al., 2007; Murphy, 2007). A range of products are currently in development for mucositis and fall into four main categories; cell resistance modifiers, mechanism specific inhibitors, damage control agents and healing accelerators (Sonis, 2004). However to date, most have proven to be ineffective for the treatment of mucositis. Better understanding of the pathobiology of mucositis is required in order for an effective therapy to be developed.

Over the last decade, significant progress has been made in understanding the underlying pathobiology for mucositis development (Sonis et al., 2004). The mechanisms of mucositis are complex and include up-regulation of a range of stress response genes and subsequent activation of mitogen activated protein kinase (MAPK) signalling, nuclear factor  $\kappa$ B (NF $\kappa$ B) signalling, Fos/Jun signalling and Wnt signalling (Sonis et al., 2002; Bowen et al., 2007). Furthermore, the downstream mediators of damage include cytokines, ceramide and cyclooxygenase-2 (Yeoh et al., 2005; Logan et al., 2008). Other possible mediators of mucositis which have not been well researched are the matrix metalloproteinases (MMPs). Through regulation of extracellular matrix (ECM) components in the alimentary mucosa, MMPs affect numerous biological phenomena including cell growth, apoptosis, cell motility, immune responses and cytokine and chemokine bioactivity (Clark et al., 2008; Manicone et al., 2008; Wolf et al., 2008). Although direct links between MMPs and mucositis development have yet to be established, MMPs have been shown to contribute to tissue injury and inflammation in many other gastrointestinal diseases (Louis et al., 2000; Meijer et al., 2007; Solberg et al., 2008). This critical review will examine the mechanisms of mucositis and the role of MMPs in normal tissue, as well as in tissue injury and inflammation.

## **1.2 The healthy alimentary tract**

### ***1.2.1 Alimentary tract histology***

The alimentary tract (AT) is a hollow tube that extends from the mouth to anus. This tube has similar structural organisation throughout its length where the wall is formed by four distinctive layers (Michael et al., 2003). From the lumen outwards, these include: the mucosa, the submucosa, the muscularis externa and the serosa. Along the length of the

alimentary tract (AT), the mucosa serves as an interface between the external and internal environments. Moreover, the AT performs numerous functions in this role including; secretion of digestive enzymes, hydrochloric acid, mucins and antibodies, absorption of metabolic substrates, serving as a barrier from pathogens and forming an immunologic barrier (Orga et al., 1994). The mucosa in the AT is composed of 3 layers; the epithelium, the lamina propria and the muscularis mucosa. Beneath the mucosa is the submucosa. This layer is composed of dense irregular as well as loose connective tissue. The primary role of the dense irregular tissue is to serve as a supporting structure to the mucosa. In contrast, the loose connective tissue is made up of stromal cells and extracellular matrix and serves a variety of functional roles (Clark et al., 2008; Manicone et al., 2008). These are discussed in more detail below in 1.3.

### ***1.2.2 Cell renewal***

A hallmark of AT mucosal layer maintenance is a high cell turnover rate which allows for continuous renewal of the epithelial layer. Rapidly dividing epithelial progenitor cells, originating in the proliferative zones of crypts in the small intestine and colon, undergo continuous, regulated apoptosis, proliferation and differentiation to a range of cell types with specialised functions as they migrate towards the lumen (except for paneth cells which migrate towards the crypts in the small intestine) (Potten et al., 1997). This process is tightly regulated by mucosal as well as submucosal signalling in order to maintain homeostasis and to compensate for disturbances which may occur in the AT (Booth et al., 2001). Furthermore, the epithelium lies over the lamina propria; which provides support and regulation of epithelial cell kinetics (Potten et al., 1997; Michael et al., 2003) (Figure 1).

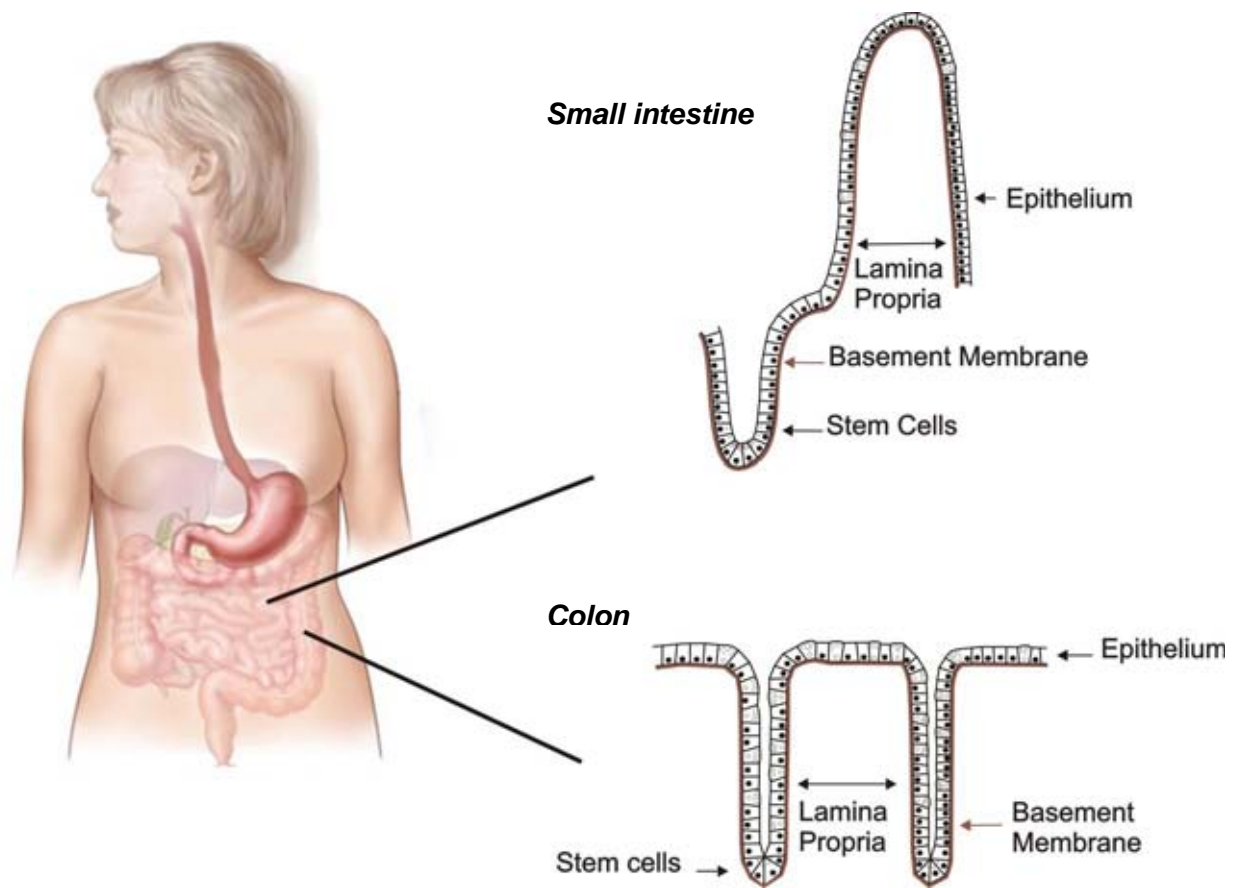


Figure 1: structure of the mucosa in small intestine and colon showing crypts and villi.

### **1.3 The gastrointestinal lamina propria**

#### ***1.3.1 Role, structure and constituents***

The delicate epithelial layer of the mucosa is supported by the lamina propria; a loose connective tissue containing stromal cells and extracellular matrix (ECM) components (Hahn et al., 1990; Pender et al., 2004). The lamina propria plays a vital role in providing an immunological barrier along the length of the AT. In addition, a gel-like ground substance is also abundant throughout the lamina propria and aids in the diffusion of oxygen and nutrients from the blood stream and removal of carbon monoxide and metabolic wastes from the mucosa (Wheatley, 2003).

#### ***1.3.2 Cellular components***

The lamina propria contains many different types of cells, serving a variety of functions. In general, the lamina propria is heavily populated with cells of the immune system (Orga et al., 1994). Moreover, approximately one quarter of the small intestinal and colonic mucosae consist of a loosely organised layer of lymphatic nodules, lymphocytes, macrophages, plasma cells and eosinophils (Orga et al., 1994). Fibroblasts are also present in the lamina propria and produce the extracellular fibres which serve a structural role in the tissue. They are also responsible for maintaining the ground substance of the lamina propria (Michael et al., 2003). In addition, the lamina propria contains smooth muscle fibres, reticular fibres and endothelial cells.

The cellular components of the lamina propria have been shown to vary slightly throughout the AT. For example, whereas the lamina propria in the small intestine has a high proportion of lymphocytes, the lamina propria in the oral cavity is less infiltrated as it



is covered by a thick, protective stratified squamous epithelium (Cutler, 1990; Sengupta et al., 2007). In contrast, the cellular components of the stomach are relatively scant and restricted by the limited space surrounding the gastric pits and glands (Sengupta et al., 2007).

### ***1.3.3 Extracellular matrix***

The ECM is a complex structural network that contains fibrous proteins, proteoglycans and glycoproteins (Michael et al., 2003). The cellular components of the lamina propria produce and secrete the various ECM components. Moreover, the ECM includes the interstitial matrix and basement membranes (Figure 1).

### ***1.3.4 Role of basement membrane in epithelial integrity***

For many years, the primary role of the ECM was believed to provide structural organisation to the tissue through supporting the overlying epithelium and segregating tissue (Yurchenco et al., 1990; Beaulieu, 1997). However, research in matrix biology revealed a vital role for the ECM, in particular the basement membrane, in regulating epithelial cell kinetics (Yurchenco et al., 1990; Beaulieu, 1997). In the early 1990s, cell culture studies demonstrated that detachment from the ECM molecule-containing basement membrane causes apoptosis in a variety of cell lines by induction of apoptosis-specific genes (Meredith et al., 1993; Frisch et al., 1994). Furthermore, *in vitro* studies have shown that the presence of ECM components promotes the expression of differentiation markers, such as sucrase, alkaline phosphatase and cellular apolipoprotein B, and imposes ultrastructural changes in immature intestinal IEC-6 cells (Carroll et al., 1988; Hahn et al., 1990). Subsequent studies identified the importance of direct epithelial

cell-basement membrane interaction on gene regulation, cytoskeletal structure, differentiation and cell growth control (Blau et al., 1991; Adams et al., 1993)

Research by Potten and colleagues (1997) and Beaulieu (1997) has highlighted an important role for the basement membrane ECM in small intestinal and colonic crypt cell activity. Both groups demonstrated that ECM molecules are spatially expressed along the crypt-villus axis. These include: E-cadherin, tenascin, laminin, fibronectin, collagen IV and perlecan (Figure 2). Moreover, the ability of stem cells to remain anchored at the base of the crypts or for daughter cells to move away from this position, results from increased or decreased affinity to those ECM components (Potten et al., 1997). Alteration of the affinity of ECM molecules to the cell occurs through changes in expression of ECM molecules or their cellular receptors (integrins). A review by Beaulieu (1997) suggests that the spatial organisation of ECM molecules is the primary mechanism by which anchorage and migration of cells take place. For example, the adhesive ECM molecule fibronectin is abundant in the crypts, whereas the less adhesive ECM molecule tenascin is more abundant in the villi (Figure 2).

The dynamic spatial organisation of ECM molecules and regulation of their composition along the crypt-villus axis by ECM degrading matrix metalloproteinases (MMPs) allows for tight regulation of crypt cell proliferation, apoptosis and differentiation (Potten et al., 1990; MacDonald et al., 1998). Moreover, previous studies have demonstrated that uncontrolled and excessive ECM degradation severely impairs AT histology and function by causing ulceration, diarrhoea and malabsorption (MacDonald et al., 1998).

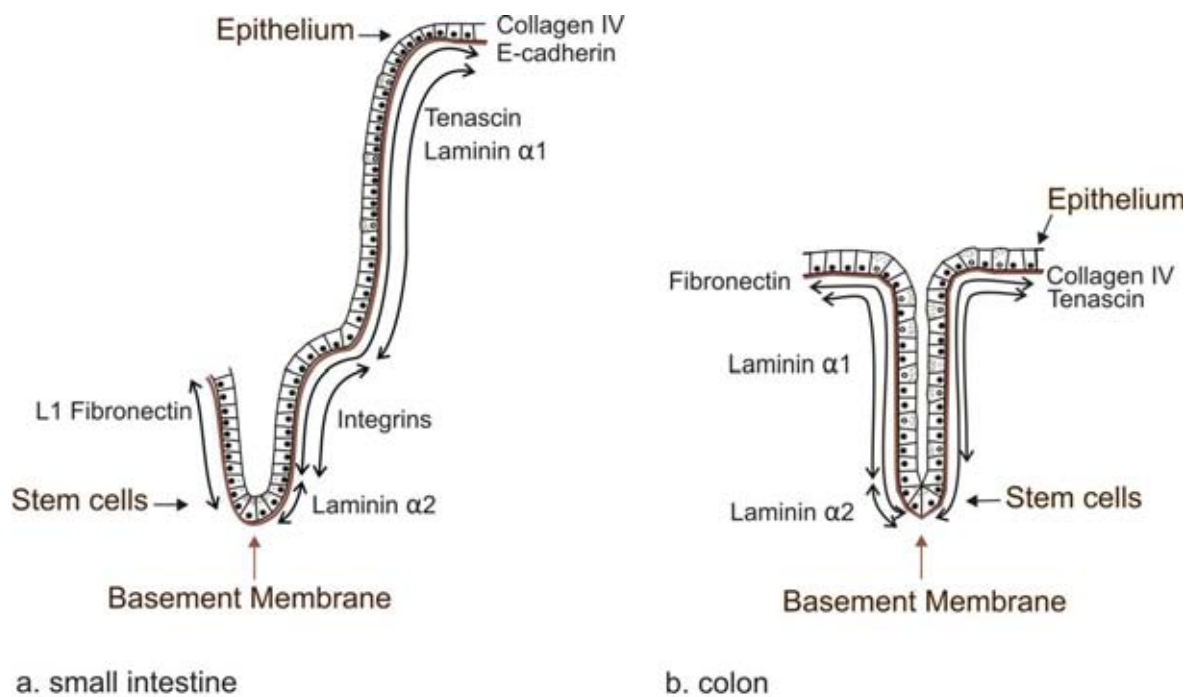


Figure 2: Composition and spatial arrangement of the sheet-like basement membrane ECM components underlying the a. small intestinal and b. colonic epithelia. Submucosal interstitial matrix not shown.

#### **1.4 Chemotherapy and the alimentary tract**

A number of studies have been carried out to investigate the effect of chemotherapy on the histopathological features of the AT (Carneiro-Filho et al., 2004; Gibson et al., 2007; Logan et al., 2008). In the small intestine and colon, chemotherapy has been shown to cause crypt hypoplasia, followed by rebound crypt hyperplasia and finally restoration of normal tissue (Keefe, 2000; Carneiro-Filho et al., 2004; Gibson et al., 2005; Gibson et al., 2007). The historical paradigm for the development of mucositis proposed that chemotherapy has the ability to cause clonogenic cell death in normal cells of the AT thus leading to the observed epithelial atrophy, barrier degradation and ulceration (Keefe, 2004; Sonis, 2004), resulting in AT symptoms. However, a study by Paris and colleagues (2001) found evidence of early damage to submucosal structures, including fibroblasts and endothelial cells, preceding epithelial tissue damage and manifestation of clinical signs (Paris et al., 2001). This study prompted the revision of this 'historic paradigm' and the consideration of a range of signalling systems and events as underlying causes for the development of mucositis. The 5-phase model for mucositis development was formulated to reflect the disarray in molecular signalling.

##### ***1.4.1 Irinotecan***

Irinotecan hydrochloride (CPT-11) is a chemotherapeutic drug used for the treatment of a variety of solid tumours. The mechanism of action of irinotecan is inhibition of DNA topoisomerase I; a key nuclear enzyme responsible for relaxing DNA during DNA replication (Ma et al., 2003). Irinotecan is converted to SN-38 by the enzyme carboxylesterase and this compound is responsible for irreversible DNA damage (Ma et al., 2003; Gibson et al., 2007). Although effective in treating cancer, irinotecan induces severe

and frequent AT toxicity, most notably, diarrhoea. Irinotecan has been shown to cause extensive pathologic alteration in the jejunum and colon as a result of increased apoptosis of crypt cells causing severe and extensive crypt degeneration (Gibson et al., 2007).

### **1.5 Signalling systems in mucositis**

One of the hallmark papers in mucositis signalling was published by Sonis in 2002. They conducted studies to investigate the gene expression differences associated with the development of mucositis in an animal model by using microarray profiling (Sonis et al., 2002). The findings of these studies demonstrated acute and delayed alteration to multiple gene expression profiles following anti-cancer treatment (Sonis, 2002; Sonis et al., 2002). They were able to conclude that the biological events underlying mucositis occur in an interdependent sequence and that the tissue and cellular sources of the up-regulated genes are associated with the endothelium, muscle, inflammatory infiltrate and epithelial cells (Sonis, 2002; Sonis et al., 2002). Since then, a plethora of studies has been published to investigate the roles of specific signalling pathways in mucositis development following a range of cytotoxic drugs (Bowen et al., 2005; Bowen et al., 2007; Bowen et al., 2007; Logan et al., 2007; Logan et al., 2008; Bowen et al., 2010).

#### ***1.5.1 The 5-phase model for the development of mucositis***

The current hypothesis for the development of mucositis was first introduced in 2004 (Sonis, 2004; Sonis, 2004; Sonis, 2007). Briefly, this hypothesis proposes that there are five biological phases of mucositis, namely: *initiation*, occurring following administration of cytotoxic chemotherapy, it encompasses the primary damage response and is a result of DNA and non-DNA damage and the generation of reactive oxygen species (ROS);

*message generation*, involving the up-regulation of transcription factors including nuclear factor  $\kappa$ B (NF $\kappa$ B) and subsequent activation of cytokine and stress response genes; *signalling and amplification*, producing proteins, such as tumour necrosis factor (TNF), interleukin-1 $\beta$  (IL-1 $\beta$ ) and interleukin-6 (IL-6), which cause direct tissue damage and provide positive feedback to amplify the process; *ulceration*, resulting in painful ulcers, bacterial infiltration and an influx of macrophages and other inflammatory cells and finally *healing*, which spontaneously occurs upon cessation of chemotherapy (Sonis, 2004).

### ***1.5.2 Mucositis signalling pathways***

The injury caused by cytotoxic chemotherapy in mucositis is mediated by a range of pathways including MAPK, NF $\kappa$ B & cyclooxygenase-2 (COX-2), Wnt, SAPK/JNK and ceramide signalling (Bowen et al., 2007; Sonis, 2007). Activation of these injurious signalling pathways leads to an excessive influx of immune cells, including macrophages and neutrophils, into the mucosa thus initiating an inflammatory response (Sonis, 2007). Downstream up-regulation of pro-inflammatory cytokines, including TNF, IL-1 $\beta$  and IL-6, has also been reported throughout the entire AT mucosa following chemotherapy (Logan et al., 2007; Logan et al., 2008). Furthermore, their expression correlates with early damage to connective tissue and endothelium (Logan et al., 2007). In addition, pro-inflammatory cytokines have the capacity to initiate epithelial signalling thus causing further tissue damage (Sonis, 2004). It has also been suggested that pro-inflammatory cytokines provide a positive-feedback loop by up-regulating genes associated with tissue injury, including NF $\kappa$ B and mediators of damage, including MMPs.

## **1.6 Matrix metalloproteinases (MMPs)**

### ***1.6.1 Function***

MMPs are a group of zinc-dependent endopeptidases. They were originally described as cleaving ECM components with a predominant role in ECM homeostasis (Reynolds, 1996; Malemud, 2006; Sengupta et al., 2007). However, recent research has identified a wide range of functions including: regulation of cell growth, triggering the release of growth factors, regulating apoptosis, altering cell motility, affecting immune responses and modulating the bioactivity of cytokines and chemokines (Meredith et al., 1993; Clark et al., 2007; Wolf et al., 2007; Manicone et al., 2008). MMPs were originally divided according to their ECM substrate specificity into five classes; which are the collagenases, gelatinases, stromelysins, elastases and membrane type MMPs (Malemud, 2006). However, with the discovery of additional functions of MMPs, the more commonly used nomenclature is MMP-1 to MMP-24.

### ***1.6.2 Regulation of MMPs***

The levels of MMPs are tightly regulated at many stages including transcription, activation from precursor zymogens (post-translational) as well as by tissue inhibitors of metalloproteinase (TIMPs) (Malemud, 2006; Clark et al., 2007; Sengupta et al., 2007). Expression of most MMPs is normally low in tissues, however, they are induced when ECM remodelling is required or following injury (Chakraborti et al., 2003). This process is regulated at the transcriptional as well as post-translational levels (Chakraborti et al., 2003). MMPs are synthesised by a range of cell types including macrophages, neutrophils, fibroblasts and epithelial cells (Pender et al., 2004; Clark et al., 2007). They are secreted as latent, inactive zymogens and are converted to their active form in the extracellular space

(Pender et al., 2004; Fu et al., 2008). A latent MMP can gain catalytic activity through the disruption of the thiol-Zn<sup>2+</sup> interaction (Fu et al., 2008). Van Wart and Birkerdal-Hansen (1990) referred to this mechanism as the 'cysteine-switch' and proposed that the thiol-Zn<sup>2+</sup> interaction can be broken by three mechanisms: (1) modification of the free thiol by physiological (oxidants, electrophiles) or non-physiological (heavy metal ions, alkylating agents) compounds; (2) cleavage of the pro-domain by pro-protein convertases such as furin; and (3) inter- or intra-molecular autolytic cleavage of the pro-domain by chemical or allosteric perturbation of the zymogen (Van Wart et al., 1990). Moreover, MMPs work coordinately to create a cascade of activation where by an activated MMP has the capacity to catalyse the activation of other MMP zymogens (Clark et al., 2007; Fu et al., 2008).

MMP activity is also regulated by TIMPs. These are the endogenous inhibitors of MMPs. To date four family members have been identified, namely: TIMP-1, -2, -3 and -4 (Denhardt et al., 1993; Chakraborti et al., 2003; Clark et al., 2007; Gill et al., 2007). Whilst all members are capable of inhibiting MMPs, TIMP-1 and -2 appear to be the most active (Pender et al., 2004). TIMPs are produced by the same cell types which secrete MMPs; including macrophages, neutrophils, fibroblasts and epithelial cells (Pender et al., 2004; Gill et al., 2007). TIMPs inhibit MMP activity by forming a 1:1 complex with the catalytic site of MMPs and chelating the active-site zinc (Visse et al., 2003).

### **1.7 MMPs in Cancer**

The role of matrix metalloproteinases in tumor growth and metastasis has been widely studied (Bourboulia et al., 2010; Stankovic et al., 2010), however, for the purpose of this review this will be discussed only briefly. MMPs have been shown to contribute to two



facets of tumor behaviour including cancer dissemination and tumor angiogenesis. Moreover, increased expression of MMPs has been shown in a range of cancer types including lung, pancreatic, gastric, ovarian and breast cancers (Bourboulia et al., 2010; Kessenbrock et al., 2010). MMP expression has also been associated with an increase in the probability of metastasis for those cancers (Zucker et al., 2000; Bourboulia et al., 2010). It has been established that tumor cells do not produce MMPs but rather the surrounding stromal cells express MMP-1, -2, -3, -11 and -13 while inflammatory cells produce MMP-9 (Zucker et al., 2000).

### **1.8 The healthy alimentary tract, MMPs and the extracellular matrix**

As previously stated, epithelial cells of the AT undergo continuous renewal. The process of cell turnover is tightly regulated by mucosal as well as submucosal signalling in order to maintain homeostasis and to compensate for disturbances which may occur in the AT (Booth et al., 2001). The ECM is a complex structural network containing fibrous proteins, proteoglycans and glycoproteins. It plays a vital role in providing support and regulation for the overlying epithelium (Michael et al., 2003). Moreover, the ECM includes the interstitial matrix and basement membranes.

For many years, the primary role of the ECM was believed to provide structural organisation to the tissue through supporting the overlying epithelium and segregating tissue (Yurchenco et al., 1990; Beaulieu, 1997). However, research into matrix biology revealed a vital role for the ECM, in particular the basement membrane, in regulating epithelial cell kinetics (Yurchenco et al., 1990; Beaulieu, 1997) (Table 1). In the early 1990s, cell culture studies demonstrated that detachment from the ECM molecule-

containing basement membrane causes apoptosis in a variety of cell lines by induction of apoptosis-specific genes (Meredith et al., 1993; Frisch et al., 1994). Furthermore, *in vitro* studies have shown that the presence of ECM components promotes the expression of differentiation markers, such as sucrose and alkaline phosphatase, and imposes ultrastructural changes in immature intestinal IEC-6 cells (Carroll et al., 1988; Hahn et al., 1990). Subsequent studies identified the importance of direct epithelial cell-basement membrane interaction on gene regulation, cytoskeletal structure, differentiation and cell growth control (Blau et al., 1991; Adams et al., 1993).

ECM components have been shown to be spatially expressed along the small intestinal and colonic crypt-villus axis and include: E-cadherin, tenascin, laminin, fibronectin, collagen IV and perlecan (Beaulieu, 1997; Potten et al., 1997) (Table 1). Beaulieu (1997) suggested that the spatial organisation of ECM molecules is the primary mechanism by which anchorage and migration of cells take place (Beaulieu, 1997). Furthermore, it has been suggested that an increase or decrease in the affinity of stem cells to those ECM components also accounts for the regulation of cell kinetics (Potten et al., 1997). ECM-degrading MMPs have been implicated in providing regulation for ECM composition along the crypt-villus axis in a substrate-specific manner (Table 2) thus allowing for tight regulation of crypt cell proliferation, apoptosis and differentiation (Pender et al., 2004; Sengupta et al., 2007).

Table 1: basement membrane components and their roles in regulating epithelial cell kinetics

<b>ECM component</b>	<b>Spatial expression</b>	<b>Effect on cell kinetics</b>
Collagen IV	Villus	Promote migration
Fibronectin	Highest in crypts & decreasing towards tip of villus	Promote proliferation Inhibit differentiation
Laminin-1 ( $\alpha1\beta1\gamma1$ )	Crypt-villus junction to villus tip	Promote differentiation
Laminin-2 ( $\alpha2\beta1\gamma1$ )	Crypt	Unknown
Tenascin	Highest in villus and decreasing towards crypt	Prevent migration

Table 2: MMPs involved in immune response and respective targets of activity.

<b>MMP</b>	<b>Common name</b>	<b>Substrate</b>
MMP1	Collagenase 1	Aggrecan, Collagen I, II, III, VII, X, XI, Fibronectin, Laminin, tenascin, CXCL12, IL-1 $\beta$ , pro-TNF, pro-MMP1, Pro-MMP2
MMP2	Gelatinase A	Aggrecan, collagen I, III, IV, V, VII, X, XI, decorin, elastin, fibronectin, gelatin, laminin, tenascin, CCL7, IL-1 $\beta$ , pro-TNF, pro-TGF $\beta$ , pro-MMP1, Pro-MMP2
MMP3	Stromelysin 1	Aggrecan, collagen III, IV, V, VII, IX, X, XI, decorin, elastin, fibronectin, gelatin, laminin, tenascin, E-cadherin, CXCL12, IL-1 $\beta$ , pro-TNF, pro-MMP1, pro-MMP3, pro-MMP7, pro-MMP9
MMP7	Matrilysin	Aggrecan, collagen I, IV, decorin, elastin, fibronectin, laminin, tenascin, E-cadherin, $\beta_4$ -integrin, syndecan-1, pro-TNF
MMP9	Gelatinase B	Aggrecan, collagen IV, V, XI, XIV, decorin, elastin, fibronectin, ICAM-1, CXCL1, CXCL7, CXCL8, CXCL12, IL-1 $\beta$ , pro-TNF, pro-TGF $\beta$ , plasminogen
MMP12	Macrophage metalloelastase	Aggrecan, collagen I, IV, elastin, fibronectin, gelatine, laminin, pro-TNF, plasminogen
MMP14	MT-1 MMP	Aggrecan, collagen I, II, III, fibronectin, gelatine, laminin, CD44, CXCL12, pro-TNF, pro-MMP2

## **1.9 MMPs, tissue remodelling and disease**

### ***1.9.1 MMPs in gut diseases***

The distribution and expression of ECM components in the basement membrane plays a predominant role in regulating epithelial cell kinetics (Potten et al., 1990; Potten et al., 1997). Therefore, it is important that MMP and TIMP levels are continuously regulated to achieve a balance in tissue degradation and fibrogenesis. Furthermore, a skewed level of tissue MMPs and TIMPs has been implicated in the development of acute and chronic diseases of the gut (Malemud, 2006; Sengupta et al., 2007). Previous research on inflammatory bowel disease (IBD) and Celiac disease (CD) has indicated a substantial increase in MMP-1, -2, -3 and -9 and a decrease in TIMP-1 and -2 expression in the small intestine and colon (Reynolds, 1996; Louis et al., 2000; Meijer et al., 2007; Solberg et al., 2008). Moreover, this alteration in expression is associated with extensive tissue remodelling in those regions and correlates with histopathological damage and the severity of the condition in patients (Meijer et al., 2007). Previous studies have also demonstrated that uncontrolled and excessive ECM degradation, which occurs as a consequence of elevated tissue MMPs and a skewed MMP:TIMP ratio, severely impairs AT histology and function by causing ulceration, malabsorption and diarrhoea (MacDonald et al., 1998); which are features of mucositis also.

### ***1.9.2 MMP expression following chemotherapy***

The expression of MMPs following chemotherapy has not received a great deal of attention and the only attempts to clarify a role for MMPs in mucositis have been in patients receiving radiation therapy for head and neck tumors or allogeneic stem cell transplants (Vuotila et al., 2002; Shoval et al., 2005) where MMPs have not been shown to

be altered in patients' saliva. Although there is a general lack of evidence for a role of MMPs in human and animal models of chemotherapy-induced injury, a role for MMPs has been described in cancer as well as inflammatory and degenerative processes, including rheumatoid arthritis (Dhaouadi et al., 2007; Murphy et al., 2008; Takaishi et al., 2008), periodontitis (Sorsa et al., 2006) and asthma (Vandenbroucke et al., 2011). Therefore, it is highly plausible to suggest that MMPs may contribute to tissue injury and remodelling following cytotoxic chemotherapy.

A study published by Morvan and colleagues (2004) described the effects of an engineered biopolymer in preventing 5-fluorouracil-induced oral mucositis. Histopathological examination of tissue from animals administered with 5-fluorouracil (5-FU) demonstrated severe damage to the epithelium, connective tissue, muscle as well as the destruction of basement membranes (Morvan et al., 2004). Furthermore, an increase in the levels of MMP-activating plasmins, MMP-2 and MMP-9 and an accompanying decrease in TIMP-1 and TIMP-2 was observed (Morvan et al., 2004). Baseline levels of MMPs and TIMPs were maintained in animals that were given the biopolymer and this correlated with a significant reduction in severity of oral mucositis in the animals, thus providing further support for a role of MMPs in mucositis. Although this study investigated MMP and TIMP expression in oral mucositis, it is reasonable to suggest that similar expression patterns for those peptidases will be observed in the small intestine and colon following chemotherapy as the entire alimentary tract (from mouth to anus) has the same embryological route of development thus sharing many commonalities (Keefe, 2004)

### ***1.9.3 Tissue injury and MMP synthesis***

Although there is not sufficient data in the literature to explain all facets of MMPs function and contribution to the development and amplification of chemotherapy-induced tissue injury, there is growing evidence for an important role of MMPs in a variety of tissue injury models. In general, tissue injury, such as that caused by cytotoxic chemotherapy, triggers a range of signalling pathways which ultimately lead to the up-regulation of MMP expression (Manicone et al., 2008). Moreover, the signalling pathways that modulate MMP expression have been extensively researched (Borden et al., 1997; Westermarck et al., 1997; Clark et al., 2007). It has been demonstrated that both MMPs and TIMPs respond to stimuli at the transcriptional level over a timeframe of several hours (Clark et al., 2008). This is suggestive of MMPs being components of genetic programs such as the wound repair response where they are downstream targets of immediate-early response genes that are induced within minutes of cell stimulation (Figure 3) (Clark et al., 2007). MMP promoter analysis studies have described the existence of a variety of functional elements on MMP promoters including binding sites for activator protein-1 (AP-1), Tcf/Lef-1 (site controlling Wnt signalling) and NFκB (Borden et al., 1997; Westermarck et al., 1997; Clark et al., 2007; Saalbach et al., 2008). MMP gene transcription studies have implicated MAPK signalling, NFκB signalling, Fos/Jun signalling and Wnt signalling in modulating MMP levels following injury (Borden et al., 1997; Lin et al., 2008) and these have all shown strong association with mucositis development in animal models (Bowen et al., 2007) as well as human studies (Yeoh et al., 2005).

Changes at the MMP gene transcription level is not the only mechanism by which MMP levels are increased following tissue injury. It has also been shown that an increased

conversion of pro-MMP to MMP occurs in the ECM during tissue injury (Manicone et al., 2008). It is well established that leukocytes; which are recruited in response to unfavourable tissue stimulation, secrete oxidants (Ra et al., 2007). According to the cysteine-switch mechanism proposed by Van Wart and Birkerdal-Hansen (1990), these oxidants have the ability to stimulate the modification of the free thiol on MMPs thus disrupting the thiol-Zn<sup>2+</sup> interaction and resulting in a biologically active form of MMPs (Van Wart et al., 1990). This type of MMP activation could therefore theoretically occur very early on following cytotoxic drug administration as ROS are produced following direct damage of chemotherapy to cells of the AT.

#### ***1.9.4 MMPs and inflammation***

MMPs have been shown to contribute to the recruitment of inflammatory cells following primary tissue injury (Lint et al., 2007; Sengupta et al., 2007). Upon initiation of tissue injury, leukocytes are required to migrate across the endothelial cell barrier separating blood from tissue. This process involves complex morphological changes in leukocytes and the endothelial cell barrier as well as the formation of cell-cell and cell-matrix interactions (Sengupta et al., 2007; Wu et al., 2007). The process is mediated by high affinity binding of leukocytes to integrins and the induction of MMP-expressing injury response genes (Sengupta et al., 2007; Wu et al., 2007). Furthermore, MMP -2 and -9 have been shown to be up-regulated in effector leukocytes therefore facilitating their migration into the mucosa (Wu et al., 2007). MMP-9 has also been implicated in neutrophil migration across blood vessel basement membranes (Delclaux et al., 1996).



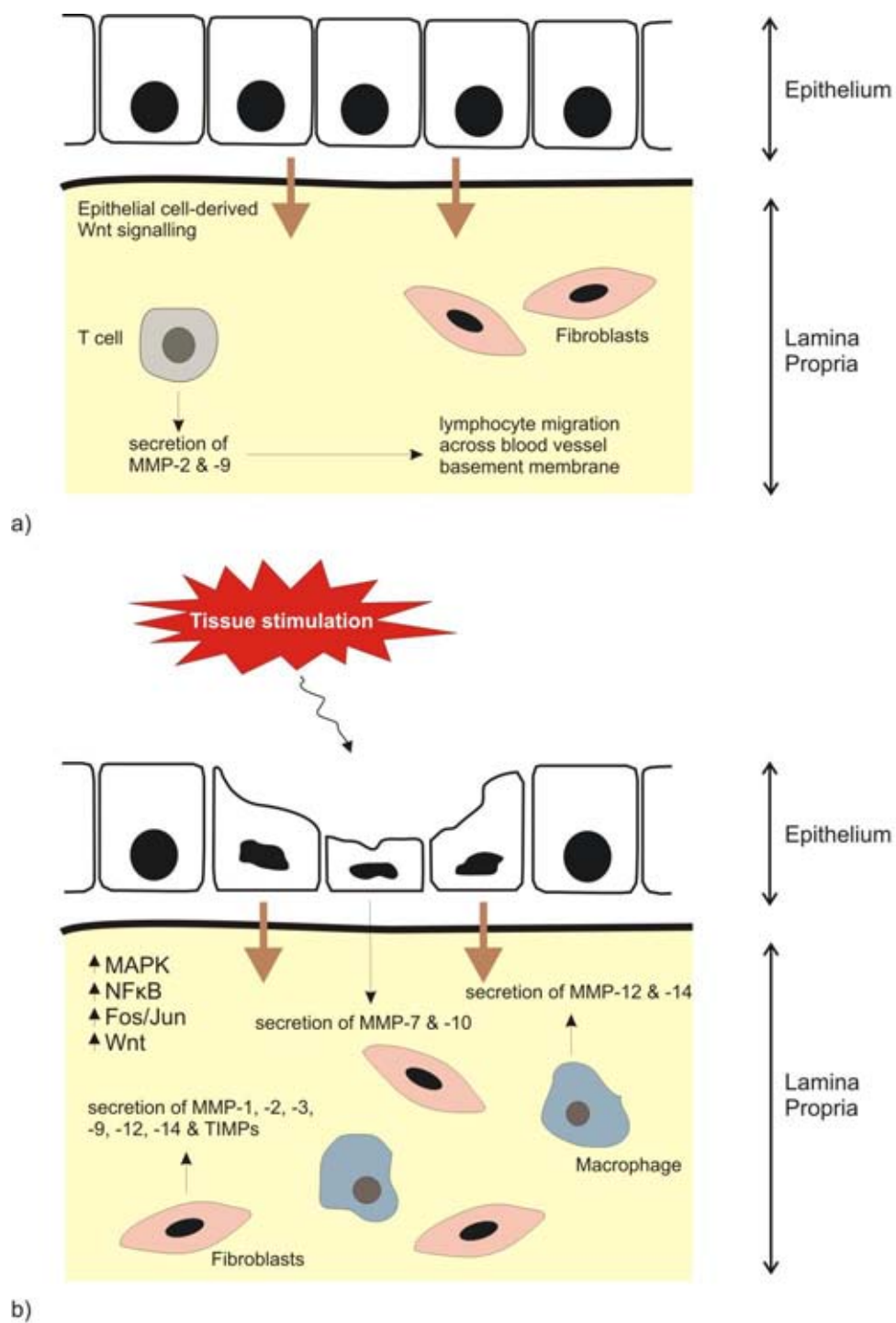


Figure 3: Expression of MMPs in the a. normal and b. injured gut. MMPs and TIMPs are components of genetic programs which are activated upon cell stimulation. They are downstream targets of immediate-early response genes including NFκB and Wnt and are secreted by epithelial as well as immune cells.

A number of studies have documented the relationship between pro-inflammatory cytokines and MMP secretion (Bamba et al., 2003; Lin et al., 2008; Manicone et al., 2008). A study conducted by Bamba and colleagues (2003) investigated the role of TNF, IL-1 $\beta$  and IL-17 on MMP3 secretion in colonic subepithelial myofibroblasts. Findings from this study suggested a causal relationship between an increase in pro-inflammatory cytokines and MMP secretion (Bamba et al., 2003). Furthermore, MMPs have also been shown to mediate activation of pro-inflammatory cytokines in a positive-feedback manner (Manicone et al., 2008). TNF and IL-1 $\beta$  are expressed by T-cells and macrophages as pro-TNF and pro-IL-1 $\beta$ , respectively and require proteolytic processing to gain activity (Manicone et al., 2008). Moreover, several MMPs, including MMP-1, -2, -3, -9, -12, -14 and -17, have been shown to have TNF and IL-1 $\beta$  converting activity (Manicone et al., 2008). The ability of MMPs to activate cytokines may therefore have implications in normal as well as pathological conditions, including those that occur in chemotherapy-induced mucositis.

### **1.10 Evidence for role of MMPs in mucositis**

There is limited evidence in the literature for the modification of ECM components and the involvement of MMPs in the pathogenesis of mucositis. However, due to the already established role of MMPs in numerous tissue injury models, it is hypothesised that MMPs play a role in multiple phases of mucositis development.

#### ***1.10.1 Message generation and amplification phases***

According to previous research, there seems to be some overlap of pathways that govern mucosal injury in the gut and MMP synthesis, in particular MAPK signalling, NF $\kappa$ B

signalling, Fos/Jun signalling and Wnt signalling (Figure 4). Moreover, independent studies have been undertaken to investigate the interplay between signalling systems and mediators of mucositis (Sonis et al., 2002; Bowen et al., 2007; Logan et al., 2008) and those that are required for the up-regulation of MMP expression (Borden et al., 1997; Westermarck et al., 1997; Clark et al., 2007; Manicone et al., 2008). Previous studies have shown a role for ROS and the pro-inflammatory cytokines TNF and IL-1 $\beta$  in the message generation phase of mucositis (Logan et al., 2008) and the induction of MMP synthesis (Bamba et al., 2003), separately, with no studies documenting a direct relationship between MMP synthesis and the development of AT mucositis. Furthermore, past studies have illustrated that MMPs proteolytically activate pro-inflammatory cytokines therefore providing positive feedback and amplifying the message generation phase (Manicone et al., 2008).

### ***1.10.2 Ulcerative phase***

Sonis (2004) proposed that up-regulation of MMPs induced by injury response genes during the up-regulation and amplification phases of mucositis is responsible for some of the damage observed in mucosal and submucosal targets. The ulcerative phase of mucositis is characterised by breakage of the epithelial layer, influx of macrophages into the base of the lesion and possible bacterial colonisation (Sonis, 2004). It is not clear what extent MMPs contribute to these events, however, an increase in MMPs could ultimately disrupt cell-ECM interactions thus leading to deregulation of cell proliferation, apoptosis and differentiation. Furthermore, an increase in MMPs, such as MMP-2, -9 and -12, could also lead to breaking of endothelial lining in mucosal and submucosal layers of the gut therefore mediating immune cell chemotaxis and local tissue inflammation.

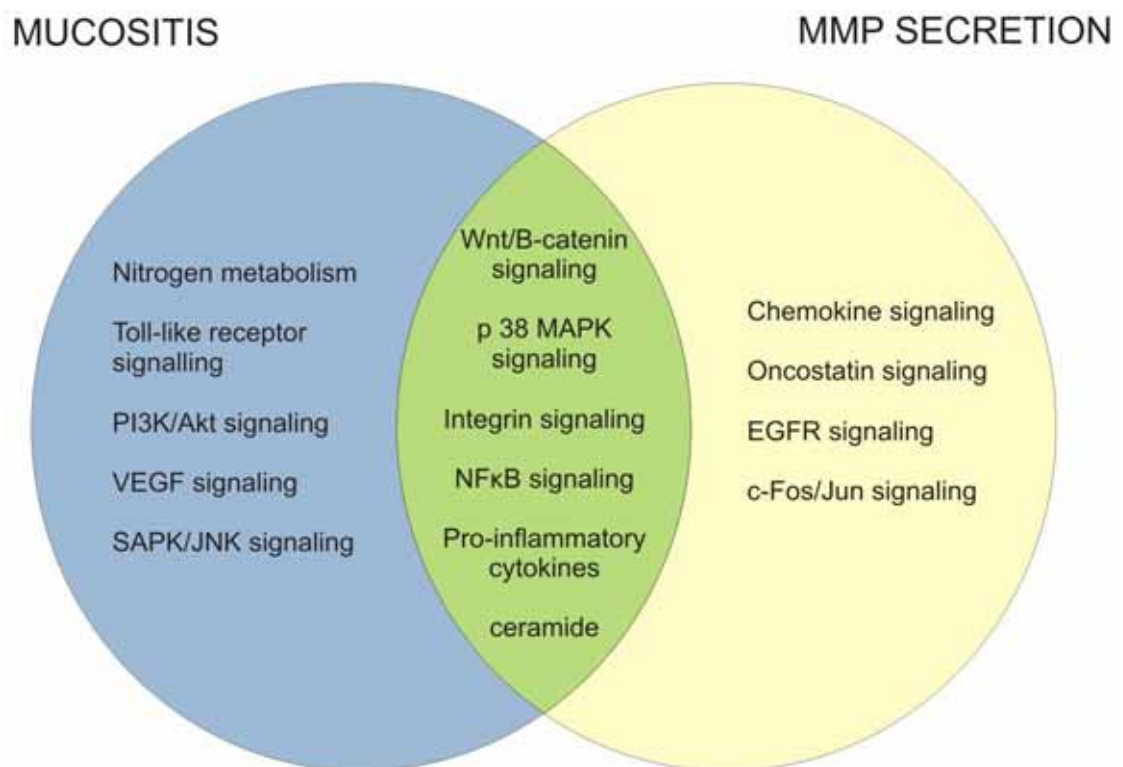


Figure 4: Signaling pathways common to the development of mucositis and the secretion of MMPs.

### ***1.10.3 Healing phase***

Several MMPs have been shown to contribute to tissue restitution following injury (Salmela et al., 2004). A study by Salmela and colleagues (2004) has shown that MMP-1, -7 and -10 are expressed by migrating enterocytes in an intestinal re-epithelialisation model (Salmela et al., 2004). MMP-3 has also been shown to contribute to wound healing as MMP-3 deficient mice fail to re-establish tissue integrity (Bullard et al., 1999). In wound healing models, MMPs have been suggested to control degradation of ECM components in order to allow cell migration and differentiation (Gill et al., 2007). Similarly, MMPs could contribute to tissue healing following chemotherapy-induced tissue damage.

### **1.11 Serum MMPs as biomarkers of mucositis**

AT mucositis is one of the most debilitating aspects of cancer treatment regimens and affects a large proportion of patients. However, to date, there is no effective prophylactic intervention available. Furthermore, there is no established scale that is universally accepted, or meets all the criteria a clinical gastrointestinal mucositis scoring system should achieve (Sonis et al., 2004). Accurate evaluation of mucositis development in the clinic is also made impossible due to the difficulty of obtaining sequential biopsies before, during and after treatment and the inaccessibility of important segments of the GI tract (Sonis et al., 2004). Hence, there is an urgent need for the identification of a biomarker for this condition. A biomarker of GI mucositis will be utilised 1) as a research tool – to enable researchers to elucidate the degree of tissue injury following treatment as symptoms are an unreliable marker of toxicity. This will aid in assessing effectiveness of interventions and 2) to determine the patients most at risk of severe injury before the start of treatment or following sequential cycles of chemotherapy.

The National Cancer Institute defines a biomarker as “*A biological molecule found in the blood, other body fluids, or tissues that is a sign of a normal or abnormal process, or of a condition or disease. A biomarker may be used to see how well the body responds to a treatment for a disease or condition*”. Biomarkers of mucositis could assay aspects related to gut injury including inflammation, apoptosis, fibrosis and changes in gut flora. Recently, there have been advances in identifying markers for GI mucositis. Some of the most used biomarkers in GI mucositis research include citrulline (Lutgens et al., 2005), calprotectin (Stringer et al., 2008), sucrose breath test (Tooley et al., 2009) and cytokines (Logan et al., 2008). However, there are huge discrepancies in our knowledge regarding the feasibility of each of these biomarkers across all patient cohorts, treatment regimens and cancer types. For example, plasma citrulline levels have been shown to effectively correlate with gradings of clinical toxicity in patients undergoing fractionated radiotherapy to the small bowel (Lutgens et al., 2004). In contrast, Wedlake and colleagues (2008) found that although there was a decrease in citrulline levels following pelvic irradiation, this did not correlate with patient symptom scores (Wedlake et al., 2008). Due to the complexity of pathologies underlying the clinical manifestation of mucositis, a combination of biomarkers may be necessary to reflect toxicity.

Recent research efforts have focused on identifying alternative biomarkers for mucositis development. Current research has identified matrix metalloproteinases as major mediators of chemotherapy-induced gut damage in rats (Al-Dasooqi et al., 2010). Hence, MMPs can be used as tissue-specific markers of gut injury following chemotherapy. However, it is not known whether these changes in MMPs are translated systemically, whether the source of systemic MMPs is epithelial- or immune cell-derived and hence whether or not they could

be useful in identifying impending toxicity. Future studies are required to investigate the potential of MMPs as systemic biomarkers.

### **1.12 Theoretical opportunities for intervention**

Cell-cell and cell-matrix interactions are vital biological processes; which have been shown to be compromised in many pathological conditions. MMPs are key enzymes in ECM degradation and therefore aberrant expression of these proteases leads to unfavourable biological events such as gut and respiratory inflammation, osteoarthritis, cancer metastasis and atherosclerotic plaque rupture (Sorsa et al., 2006; Dhaouadi et al., 2007; Murphy et al., 2008; Takaiishi et al., 2008). As a result, pharmaceutical companies have shown interest in the development of MMP inhibitors. There are two main classes of MMP inhibitors; namely broad spectrum MMP inhibitors and specific MMP inhibitors (Nutti et al., 2007). Specific MMPs could potentially have a differential role in each stage of mucositis development, for example, MMP-2 and -9 are involved in damage onset while MMP-7 and -10 contribute to tissue repair following injury. Therefore, specific, rather than broad, spectrum MMP inhibitors should be investigated as possible therapeutic intervention. Currently, anti-mucotoxic drugs fall into 4 main categories; cell resistance modifiers, mechanism specific inhibitors, damage control agents and healing accelerators (Sonis, 2004). Specific MMP inhibitors could potentially fall under ‘mechanism specific inhibitors’ where MMPs involved in tissue injury could be inhibited including MMP-2 and -9. However, this requires better characterisation of the specific MMPs involved in each phase of mucositis pathogenesis.

### **1.13 Conclusions**

MMP expression and activation increases following tissue injury as a result of stress response gene up-regulation. Furthermore, an increase in tissue MMPs stimulates immune cell infiltrate and enhances cytokine activation. MMPs also degrade ECM components of the basement membrane and have the ability to impact cell proliferation, apoptosis and differentiation. Mucositis is characterised by inflammation as well as changes in cell kinetics, however, it is not known if these are associated with altered MMP expression. More definitive studies are required to elucidate the role of MMPs and ECM components in the histopathological and physiological alterations observed in alimentary mucositis.

### **1.14 Aims of thesis**

Whilst extensive literature exists on mucositis and possible preventative/treatment strategies for the condition, there is a big gap in our understanding of the molecular mechanisms behind the damage caused by cancer chemotherapy. Additionally, the mediators of damage caused by chemotherapy in the alimentary tract have not been well identified. Therefore the specific aims of this PhD were:

1. To assess the importance of endogenous controls (housekeeping genes) during RT-PCR and validate their use when investigating the molecular events associated with mucositis.
2. To explore the potential role of matrix metalloproteinases as mediators of AT tissue injury during irinotecan-induced mucositis.
3. To determine the distribution patterns of extracellular matrix proteins in the gastrointestinal tract after the administration of Irinotecan.
4. To demonstrate whether MMPs can be used as biomarkers for mucositis development



## **2.0 Selection of housekeeping genes for gene expression studies in a rat model of irinotecan-induced mucositis**

[Al-Dasooqi et al. (2011) *Chemotherapy* **57**(1): 43-53]

### **2.1 Introduction**

Traditional anti-cancer agents are still the most commonly used treatment option for cancer even though its administration is associated with toxicity (Sonis et al, 2004; Kim et al, 2009; Kolli et al, 2009; Saleh et al, 2009). Alimentary tract (AT) mucositis is a serious and debilitating side effect of cancer chemotherapy and radiotherapy which manifests clinically as ulceration, vomiting, bloating and diarrhoea in patients (Sonis 2004). It is well established that this condition occurs as a result of damage to mucous membranes throughout the AT (Keefe 2004; Sonis 2004). Furthermore, significant progress has been made in recent years in terms of our understanding of the morphological (Gibson et al, 2005; Logan et al, 2008) as well as the signalling alterations (Sonis et al, 2002; Bowen et al, 2007; Bowen et al, 2007) involved in the development of this condition.

The events that occur in the AT following anti-cancer therapy, eventually culminating as mucositis, have recently been divided into five distinct biological phases (Sonis 2004; Sonis 2004). The five proposed phases include: initiation, message generation, signalling and amplification, ulceration and healing (Sonis 2004). It has been previously reported that chemotherapy-induced mucositis encompasses a number of alterations in gastrointestinal morphology (Gibson et al, 2003; Logan et al, 2008). In the small intestine and colon, chemotherapy has been shown to cause crypt hypoplasia, followed by rebound crypt

hyperplasia and finally restoration of normal tissue (Gibson et al, 2003; Logan et al, 2008). In the past, these alterations were proposed to be a result of clonogenic cell death of rapidly dividing cells of the AT thus leading to the observed epithelial atrophy, barrier degradation and ulceration (Keefe 2004). However, more recent studies have shown evidence of more complex pathophysiological alterations following chemotherapy administration. These include the induction of inflammatory responses (Yeoh et al, 2005; Logan et al, 2007; Manzano et al, 2007; Logan et al, 2008), changes in the gut microbiome (Stringer et al, 2007; Stringer et al, 2009; Stringer et al, 2009), activation of submucosal signalling and damage of submucosal structures in addition to clonogenic cell death induction (Paris et al, 2001).

In a hallmark paper by Paris and colleagues (2001) investigating the mechanism of radiation-induced mucosal damage, evidence of early damage to submucosal structures, including fibroblasts and endothelial cells, was found to precede epithelial tissue damage and manifestation of clinical signs. This study suggested that primary tissue damage in one region of the AT may cause alteration in cell signalling systems with the potential of dissemination in multiple tissue regions, and development of mucositis. Sonis and colleagues (2002) conducted studies to investigate the gene expression differences associated with the development of mucositis in an animal model of radiation-induced mucositis by using microarray profiling. The findings of these studies demonstrated acute and delayed alteration to multiple gene expression profiles following anti-cancer treatment (Sonis 2002; Sonis et al, 2002). Similarly, Bowen and colleagues (2007) have shown that there are profound gene expression differences associated with chemotherapy-induced mucositis (Bowen et al, 2007). These studies were able to conclude that the biological

events underlying mucositis occur in an interdependent sequence and that the tissue and cellular sources of up-regulated genes include the endothelium, muscle, inflammatory infiltrate and epithelial cells (Sonis 2002; Sonis et al, 2002; Bowen et al, 2007).

When attempting to analyse the molecular basis of mucositis development, real time PCR (RT-PCR) is the method of choice for monitoring gene expression changes at multiple time-points following treatment. However, selection of a suitable normalisation mechanism is crucial to ensure the accuracy of the data and allow for control of any experimental error which may have been produced during the processes of RNA extraction and cDNA synthesis (Bustin 2002; Andersen et al, 2004; Huggett et al, 2005). Housekeeping genes are the most commonly used strategy for normalisation. Previous studies have highlighted the importance of accurate validation of housekeeping genes to ensure stable expression that is not regulated by the experimental conditions or treatments (van Wijngaarden et al, 2007; Langnaese et al, 2008). In gastrointestinal tissue obtained from animals treated with chemotherapy, it is vital that a valid housekeeping gene which is not affected by the signalling disarray that occurs in mucositis is used. This will ensure that real changes in gene expression are not obscured while artificial changes in gene expression are not produced. Therefore, the aim of this study is to identify the most stable housekeeping gene in multiple regions of the AT, namely the jejunum and colon, during a time-course model of irinotecan-induced mucositis. Eleven commonly used housekeeping genes were evaluated at control, 6, 24, 72 and 144 hours following irinotecan administration in Dark Agouti rats. The matrix metalloproteinase MMP-2 was used as a target gene to validate the appropriateness of the top ranking housekeeping genes in the current experimental model.

## **2.2 Materials and Methods**

### ***2.2.1 Animals***

Thirty female dark agouti rats were used in this study and weighed between 150-170g. All experimental procedures were approved by the Animal Ethics Committees of the Institute of Medical and Veterinary Sciences and the University of Adelaide and complied with the National Health and Medical Research Council (Australia) Code of Practice for Animal Care in Research and Training (2004). Due to the nature of the diarrhoea that can be induced by irinotecan, animals were monitored four times daily and if any animal showed certain criteria (as defined by the Animal Ethics Committee) they were killed. These criteria included a dull ruffled coat with accompanying dull and sunken eyes, coolness to touch with no spontaneous movement, and a hunched appearance.

### ***2.2.2 Irinotecan-induced mucositis model***

Rats were randomly allocated into control (n=6) or experimental groups (n=24). Experimental group rats received 0.01mg/kg subcutaneous atropine in order to reduce cholinergic reaction to irinotecan immediately prior to the administration of a single intraperitoneal dose of 200 mg/kg irinotecan (previously shown to cause gastrointestinal mucositis). Irinotecan (kindly supplied by Pfizer, Kalamazoo, USA) was administered in a sorbitol/ lactic acid buffer (45 mg/ml sorbitol /0.9 mg/ml lactic acid, pH 3.4), required for activation of the drug. Rats in the control group did not receive any treatment. Rats were assessed four times daily for mortality, body weights and diarrhoea. Diarrhoea was graded as: mild diarrhoea (staining of anus); moderate diarrhoea (staining top of legs and lower abdomen); severe diarrhoea (staining over legs and higher abdomen as well as continual anal leakage).

Rats were killed at various time-points following irinotecan administration; 60 min, 6, 24, 72, 144 h, by cardiac puncture and cervical dislocation under 3% halothane in 100% O<sub>2</sub> anaesthesia. The gastrointestinal tract was dissected out from the pyloric sphincter to the rectum and flushed with chilled isotonic saline (0.9 w/v) to remove contents. A 1 cm sample of the small intestine and the colon were taken at approximately 25% and 50% of the lengths, respectively. For histological analysis, samples were fixed in 10% neutral buffered formalin, processed and embedded in paraffin. Jejunal and colonic tissue was also frozen at -80 °C until RNA extraction.

### ***2.2.3 Histological Assessment***

Samples of jejunum and colon were collected and fixed in 10% neutral buffered formalin for routine histological examination. Fixed samples were processed and embedded in paraffin. Sections were cut at 4µm thickness and mounted onto silane coated slides. Haematoxylin and eosin (H&E) staining was carried out. Briefly, sections were dewaxed, rehydrated and stained with Lillie-Mayer's haematoxylin for 10 minutes. Sections were differentiated in 1% acid alcohol before bluing in Scott's tap water and counterstaining with eosin. Finally, sections were dehydrated, cleared and mounted. Sections were examined by light microscopy and analysed by a professional veterinary pathologist.

### ***2.2.4 Immunohistochemistry***

Control and experimental jejunum sections were cut from paraffin blocks at 4 µm thickness and mounted onto silane-coated slides. Sections were dewaxed in xylene and rehydrated through a graded series of alcohols. Sections were immersed in 10 mM citrate buffer (pH 6.0) and antigen retrieval performed by heating sections in microwave on

“high” until boiling and on “low” for 10 minutes. Sections were allowed to cool and endogenous peroxidase activity subsequently blocked with 3% H<sub>2</sub>O<sub>2</sub> in methanol. Non-specific antibody binding was blocked with 20% normal goat serum (NGS) (Sigma, St Louis, MO, USA) in PBS for 30 min at room temperature (RT). Avidin-Biotin Blocking Kit (Vector Laboratories, Burlingame, CA, USA) was used to block endogenous avidin-biotin activity. Sections were incubated overnight with rabbit anti-MMP2 (Abcam, Cambridge, UK) diluted in 5% NGS at 4 °C. Tissue sections were incubated with the appropriate secondary antibody (20 min at RT), ABC labelling reagent (30 min at RT) and developed with DAB. Sections were counterstained with Lillie-Mayer’s haematoxylin, dehydrated and cleared in xylene before being mounted. Qualitative immunohistochemistry was performed. Staining intensity was graded as follows: 0 no staining, 1 weak staining, 2 moderate staining, 3 strong staining and 4 intense staining. This qualitative staining assessment has been previously validated by published grading systems (Bowen et al, 2005; Yeoh et al, 2005; Logan et al, 2008) and is routinely used within our laboratory. All assessments were done in a blinded fashion by one investigator (NA).

### ***2.2.5 Reference gene selection and primers***

A selection of 11 housekeeping genes (GAPDH, Ywhaz, B2M, Ppia,  $\beta$ -actin, Tbp, UBC, Hprt, RNAP2, SDHA, ARBP) belonging to different functional classes were selected in order to reduce the chance that these genes are co-regulated (Table 1). Primers for GAPDH, Ywhaz, B2M, Ppia, Tbp, UBC, Hprt, RNAP2, SDHA and ARBP were as previously published (Table 2) (Chen et al, 2006; van Wijngaarden et al, 2007; Langnaese et al, 2008). The  $\beta$ -actin primer was designed by the primer 3 software (Whitehead

Institute for Biomedical Research, Cambridge, MA) (Rozen et al, 2000) based on the *rattus norvegicus* sequence for  $\beta$ -actin in the GenBank database (NCBI, Bethesda, MD). Netprimer (Premier Biosoft, CA, USA) was also used to check for the absence of potential hairpins, dimers, palindromes and secondary structures. Forward and reverse primers were synthesised by Geneworks Ltd (Thebarton, South Australia, Australia).

Table 1 - Panel of 11 candidate housekeeping genes selected

Gene symbol	Gene name	mRNA accession no.	Function
Ywhaz	Tyrosine 3-monooxygenase/tryptophan 5-monooxygenase activation protein, zeta polypeptide	NM_013011.3	Signal transduction
GAPDH	Glyceraldehyde-3-phosphate dehydrogenase	NM_017008.3	Glycolytic enzyme
Ppia (Ppia)	Cyclophilin A (peptidyl prolyl isomerase A)	NM_017101.1	Catalysis of cis-trans isomerisation proline amidic peptide bonds/ protein folding
Tbp	TATA box binding protein	NM_001004198.1	RNA polymerase II transcription factor
B-ACTIN	B-actin	NM_031144.2	Cytoskeleton structural protein
B2M	Beta-2 microglobulin	NM_012512.1	Beta-chain of major histocompatibility complex class I molecules
SDHA	Succinate dehydrogenase complex	NM_130428.1	Succinate oxidation in the mitochondrial respiratory chain
UBC	Ubiquitin C	NM_017314.1	Possible role in protein catabolism
HPRT	Hypoxanthine guanine phosphoribosyl transferase	NM_012583.2	Metabolic salvage of purines
RNAP2	RNA polymerase II	XM_343922.3	Initiation of eukaryotic protein coding
ARBP	Acidic ribosomal phosphorylation P0	NM_022402.1	Ribosomal structural protein/ nucleic acid binding



Table 2 - Primer sequences and characteristics

Gene	Primer sequence (5'-3')	Nucleotide Position	Amplicon length (bp)	Tm (°C)	PCR efficiency (%)	Ref
Ywhaz	F: GATGAAGCCATTGCTGAACTTG R: GTCTCCTTGGGTATCCGATGTC	650-766	117	53 57	95	<sup>1</sup>
GAPDH	F: CAACTCCCTCAAGATTGTCAGCAA R: GGCATGGACTGTGGTCATGA	493-610	118	55 54	105	<sup>1</sup>
Ppia (Ppia)	F: TATCTGCACTGCCAAGACTGAGTG R: CTTCTTGCTGGTCTTGCCATTCC	381-507	127	57 57	98	<sup>1</sup>
Tbp	F: TGGGATTGTACCACAGCTCCA R: CTCATGATGACTGCAGCAAACC	679-811	132	54 55	100	<sup>1</sup>
B- ACTIN	F: AGGCCAACCGTGAAAAGATG R: ACCAGAGGCATACAGGGACAA	419-519	101	52 54	100	*
B2M	F: CGAGACCGATGTATATGCTTGC R: GTCCAGATGATTGAGAGCTCCA	286-399	114	55 55	92	<sup>1</sup>
SDHA	F: TCCTTCCCACTGTGCATTACAA R: CGTACAGACCAGGCACAATCTG	1222-1326	105	53 57	98	<sup>1</sup>
UBC	F: TCGTACCTTTCTCACCACAGTATCTAG R: GAAAATAAGACACCTCCCATCA	2406-2487	82	58 56	99	<sup>2</sup>
HPRT	F: CTCATGGACTGATTATGGACAGGAC R: GCAGGTCAGCAAAGAATTATAGCC	179-301	123	58 58	97	<sup>1</sup>
RNAP2	F: GTCCAATGACATCGTGGAGA R: CCATCAAAGGAGATGACATGG	4011-4106	96	52 52	99	<sup>3</sup>
ARBP	F: AAAGGGTCTGGCTTTGTCT R: GCAAATGCAGATGGATCG	766-856	91	52 48	95	<sup>3</sup>

\* designed by primer3 and synthesised by GeneWorks Ltd.

<sup>1</sup> Langnaese et al, 2008

<sup>2</sup> Chen et al, 2006

<sup>3</sup> van Wijngaarden et al, 2007

### ***2.2.6 RNA isolation and reverse transcription***

30 mg of jejunal and colonic tissue was homogenised in TRIzol® Reagent (Invitrogen Life Technologies, Mulgrave, Australia). RNA was isolated using Nucleospin® RNA II kit (Macherey-Nagel, Duren, Germany). Total RNA was prepared according to the manufacturers instructions. Briefly, cell lysis buffer was added to the ground tissue and filtered through silica membrane filter columns. Following a sequence of filtration steps, RNA binding conditions were adjusted and DNA digestion performed. A series of washing steps were carried out before highly pure RNA was eluted in RNase-free water. To determine RNA purity and concentration, each tissue sample was specked using the Nanodrop program (NanoDrop Technologies, Wilmington, DE, USA). RNA integrity was assessed by electrophoresis on 1.2% (w/v) agarose gels. RNA was converted to cDNA using the iScript cDNA Synthesis Kit (Bio-Rad, Hercules, CA, USA). For each reaction, 1 µg of RNA was combined with iScript reaction mix, iScript reverse transcriptase and reaction volume made up to 20 µl using nuclease-free water. Samples were incubated for 5 minutes at 25 °C, 30 minutes at 42 °C and 5 minutes at 85 °C. Total cDNA concentration was measured using the Nanodrop program and samples diluted to 100ng/µl with nuclease-free water (Promega, Madison, WI, USA).

### ***2.2.7 Real-time PCR***

Real-time PCR was performed using the Rotor Gene 3000 (Corbett Research, Sydney, Australia). Amplification mixes contained 1 µl of cDNA sample, 5 µl of fluorescent dye SYBR green (Applied Biosystems, Foster City, CA), 3 µl of nuclease-free water (Promega, Madison, WI, USA) and 0.5µl of each forward and reverse primers (all primers were pre-diluted to 50 pmol/µl) to makeup a final volume of 10 µl. Thermal cycling conditions

included denaturation step at 95 °C for 10 min, and then 45 cycles of denaturation at 95 °C for 10 s, annealing at 60 °C for 15 s and extension at 72 °C for 20 s. Amplification was followed by melt curve analysis to confirm product specificity.

All samples were run in triplicates. The experimental threshold (Ct) values were calculated by the RotorGene 6 program. Ct values were converted into relative quantities relative to untreated control calibrator and the  $2^{-\Delta Ct}$  method used to acquire the fold change in gene expression over the time course from time 0.

### ***2.2.8 Determination of reference gene expression stability***

NormFinder (Andersen et al, 2004) was used to analyse reference gene stability in the time-course model of chemotherapy-induced mucositis. Triplicate mean Ct values were converted to linear scale expression quantities via the delta Ct method and entered into the NormFinder program. Group identifiers were also included to allow for identification of the best combination of two genes. Normfinder uses a model-based approach to estimate expression variation for candidate housekeeping genes and also the variation between sample subgroups (Andersen et al, 2004).

### ***2.2.9 Calculation of relative expression of MMP2***

All samples were run in triplicate. Ct values were calculated by the RotorGene 6 program. The delta-delta Ct method was used to calculate relative quantities relative to untreated control calibrator over the time course and data was normalised to the most stable gene UBC and compared to the genes that showed most unstable expression; namely SDHA in the jejunum and GAPDH in the colon.

### *2.2.10 Statistical Analysis*

Changes in gene expression were statistically analysed using the Kruskal-Wallis test. A post hoc Bonferroni adjustment was carried out. Results were declared statistically significant at  $p < 0.05$ .

## **2.3 Results**

### ***2.3.1 Response to treatment***

As previously reported (Gibson et al, 2007; Stringer et al, 2007; Logan et al, 2008), rats treated with cytotoxic chemotherapy began demonstrating clinical signs of mucositis from 2 hours following irinotecan administration where diarrhoea was observed in 23% of rats. The prevalence of diarrhoea peaked at 24 hours where 39% of rats had mild diarrhoea and 5% had moderate diarrhoea. At 72 h, 33% of treated rats had mild diarrhoea. All diarrhoea was resolved at 144h after irinotecan administration. None of the rats in the control groups developed diarrhoea. Chemotherapy-induced death did not occur in this study (Stringer et al, 2007; Logan et al, 2008).

### ***2.3.2. Histological Analysis***

As previously reported (Logan et al, 2008), marked histological evidence of mucositis was observed in the jejunum and colon following irinotecan treatment. These changes were evident as early as 6h following treatment and included the presence of degenerative enterocytes within the crypts. This was followed by more gross architectural disturbances at later time-points. In the jejunum, these changes included villus blunting, epithelial atrophy and increased intensity of inflammatory cell infiltrate through mucosal tissue. Similar damage was seen in the colon at later timepoints with the complete crypt ablation observed at 72h after treatment (Stringer et al, 2007; Logan et al, 2008).

### ***2.3.3 RNA Quality***

RNA purity was measured using the NanoDrop<sup>®</sup> Spectrometer (NanoDrop Technologies, Wilmington, DE, USA). The mean  $A_{260/280}$  ratio for the RNA samples was  $2.09 \pm 0.01$

and reflected pure, protein-free RNA samples. The mean  $A_{260/230}$  ratio was  $1.88 \pm 0.05$  and indicated that the RNA was phenol and ethanol free. RNA integrity was characterised by denaturing gel electrophoresis. The 28S:18S rRNA ratios were approximately 2:1 for all samples indicating intact RNA.

### ***2.3.4 RT-PCR efficiency***

Semi-quantitative RT-PCR was used to measure the relative mRNA levels of a number of candidate housekeeping genes. In order to ensure total compatibility of PCR assays, the efficiency of each assay was measured using serial dilutions of cDNA from an untreated jejunum and colon in triplicates. The RotorGene 6 program was used to generate a standard curve and PCR efficiency was calculated according to the following formula:  $\text{PCR efficiency} = [10^{(-1/M)} - 1] \times 100$ . All PCR assays displayed efficiencies between 92 and 105% (Table 2).

### ***2.3.5 Expression of housekeeping genes following irinotecan treatment***

The fold change in gene expression was calculated for each of the 11 housekeeping genes using the  $2^{-\Delta Ct}$  where untreated controls were used as a baseline for gene expression. Two genes showed differential expression patterns in the jejunum and colon early on following chemotherapy administration. These were Ppia and RNAP2 (Figure 1 & 2). In the jejunum, RNAP2 expression increased at 6h following treatment while this change was not evident in the colon. In contrast, Ppia expression levels increased at 6h following treatment in the colon but not the jejunum. The remaining genes including GAPDH, Ywhaz,  $\beta$ -actin, UBC, B2M, Tbp, Hprt and ARBP showed no change in expression early on following chemotherapy treatment. However, an increase in their expression was observed at 72

and 144h following chemotherapy administration in both the jejunum and colon (Figure 1 & 2). Changes in gene expression noted were not statistically significant following Bonferroni adjustment.

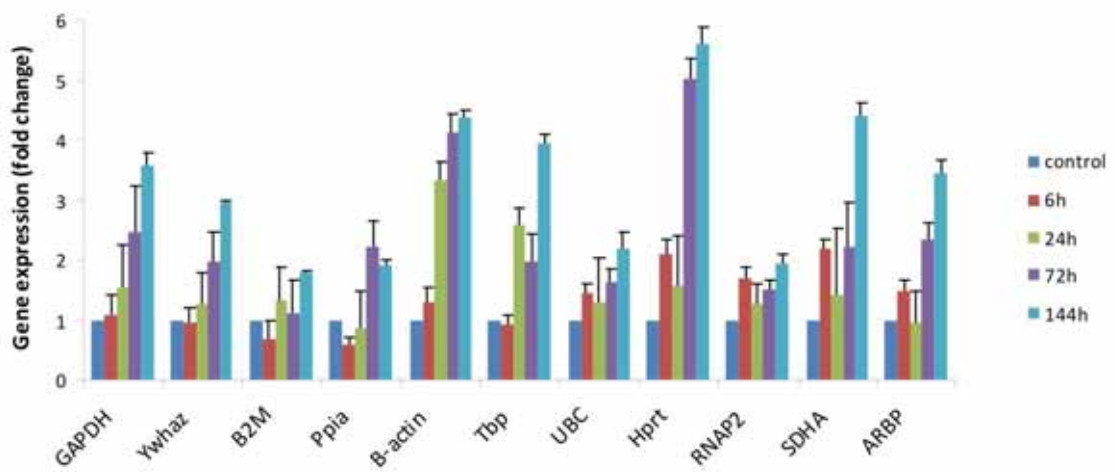


Figure 1 - Jejunal housekeeping gene expression in irinotecan-treated DA rats. Expression ratios were calculated using the RotorGene 6 program. The mean fold change in gene expression values along with the corresponding standard error were used to create the graph. The control group, i.e. untreated, was assigned a value of 1.



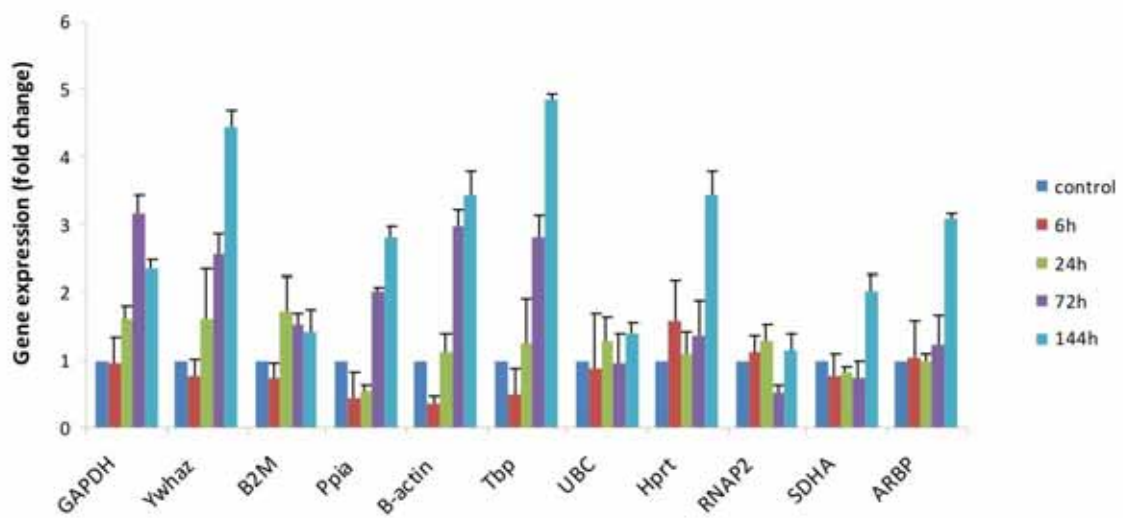


Figure 2 - Colonic housekeeping gene expression in irinotecan-treated DA rats. Expression ratios were calculated using the RotorGene 6 program. The mean fold change in gene expression values along with the corresponding standard error were used to create the graph. The control group, i.e. untreated, was assigned a value of 1.

### ***2.3.6 Stability of housekeeping genes within sample groups***

Stability of the 11 housekeeping genes was evaluated for each sample group. Gene expression levels were measured by RT-PCR and expression stabilities compared using NormFinder. Normfinder identified a single gene for normalisation for each of the time points as follows. The most stable gene in each region was Tbp in the jejunum and UBC in the colon for the control group; Tbp in the jejunum and GAPDH in the colon at 6h following treatment; UBC in the jejunum and  $\beta$ -actin in the colon at 24h following treatment; Ywhaz in the jejunum and B2M in the colon at 72h following treatment;  $\beta$ -actin in the jejunum and Ppia in the colon at 144h following treatment (data not shown).

### ***2.3.7 Stability of housekeeping genes compared to normal tissue***

NormFinder was used to identify the most stable housekeeping genes for the irinotecan-induced mucositis rat model (Table 3). Lower stability values indicated more stable gene expression. The most stably expressed genes in the jejunum across the five time points following irinotecan treatment were found to be Ywhaz and UBC. In the colon, UBC and  $\beta$ -actin showed the most stable expression following chemotherapy (Table 3). The candidate housekeeping genes that performed the worst in the jejunum and colon were SDHA and GAPDH, respectively.

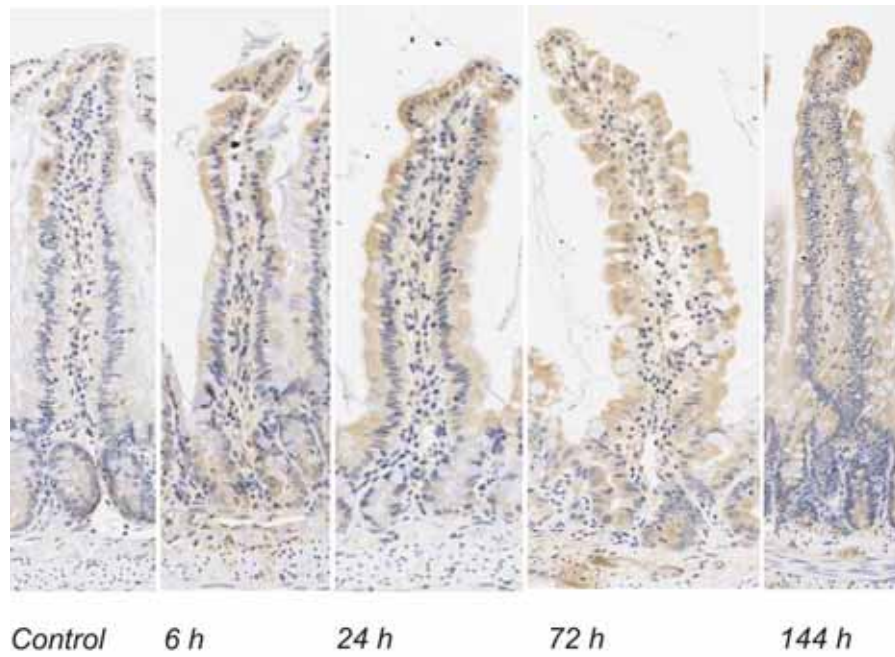
For normalisation to multiple housekeeping genes, the most stable combination was identified as Ywhaz/UBC (stability value 0.151) in the jejunum and  $\beta$ -actin/UBC (stability value 0.273) in the colon.

Table 3 - Housekeeping gene ranking following chemotherapy administration in the jejunum and colon

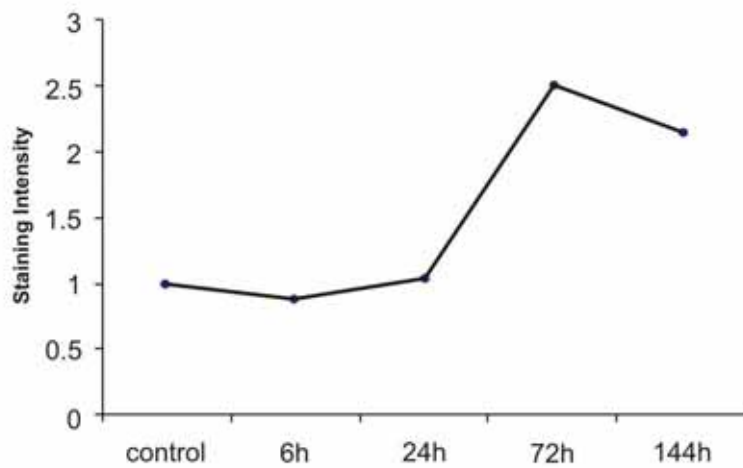
	<i>Jejunum</i>	<i>Colon</i>
GAPDH	0.292	0.710
Ywhaz	0.194	0.624
B2M	0.324	0.575
Ppia	0.334	0.508
B-ACTIN	0.302	0.501
Tbp	0.311	0.558
UBC	0.212	0.432
Hprt	0.401	0.544
RNAP2	0.348	0.633
SDHA	0.462	0.513
ARBP	0.393	0.506

### ***2.3.8 MMP2 expression in the jejunum following irinotecan treatment***

In the jejunum, MMP2 staining was unchanged at 6 h following irinotecan. At 24 h there was a slight increase in villus staining accompanied by a decrease in crypt staining for MMP2. There was a slow increase in MMP2 over the five time points from weak to moderate staining (Figure 3a). MMP2 staining reached its maximum at 72 h following treatment ( $p < 0.05$ ). The mean staining intensities for MMP2 across the time-course are shown in figure 3b.



**a**



**b**

Figure 3 - Immunostaining of MMP2 in the jejunum following irinotecan administration. a) Photomicrographs taken at 20x objective b) the mean staining intensity for MMP2 across the time-course.

***2.3.9 Validation of selected candidate housekeeping gene using MMP2 in the jejunum***

The top ranking housekeeping gene in the jejunum (Ywhaz) showed an approximate 3-fold change in gene expression at 72 h and 144 h following chemotherapy administration. This is slightly higher than the second best housekeeping gene (UBC) which showed a 2-fold change in expression over the time-course. Therefore, UBC was selected as the most preferred gene in the jejunum and colon.

MMP2 expression was evaluated by RT-PCR relative to UBC as well as to the worst housekeeping genes (SDHA in the jejunum and GAPDH in the colon). In the jejunum, the use of the unstable housekeeping gene SDHA resulted in an overestimation of MMP2 expression particularly at 72h following irinotecan with almost a 4-fold difference (Figure 4a). There was also an underestimation in MMP2 expression at 144h (Figure 4a). In contrast, the best and the worst housekeeping genes reflected a similar pattern of MMP2 expression along the time-course in the colon (Figure 4b).

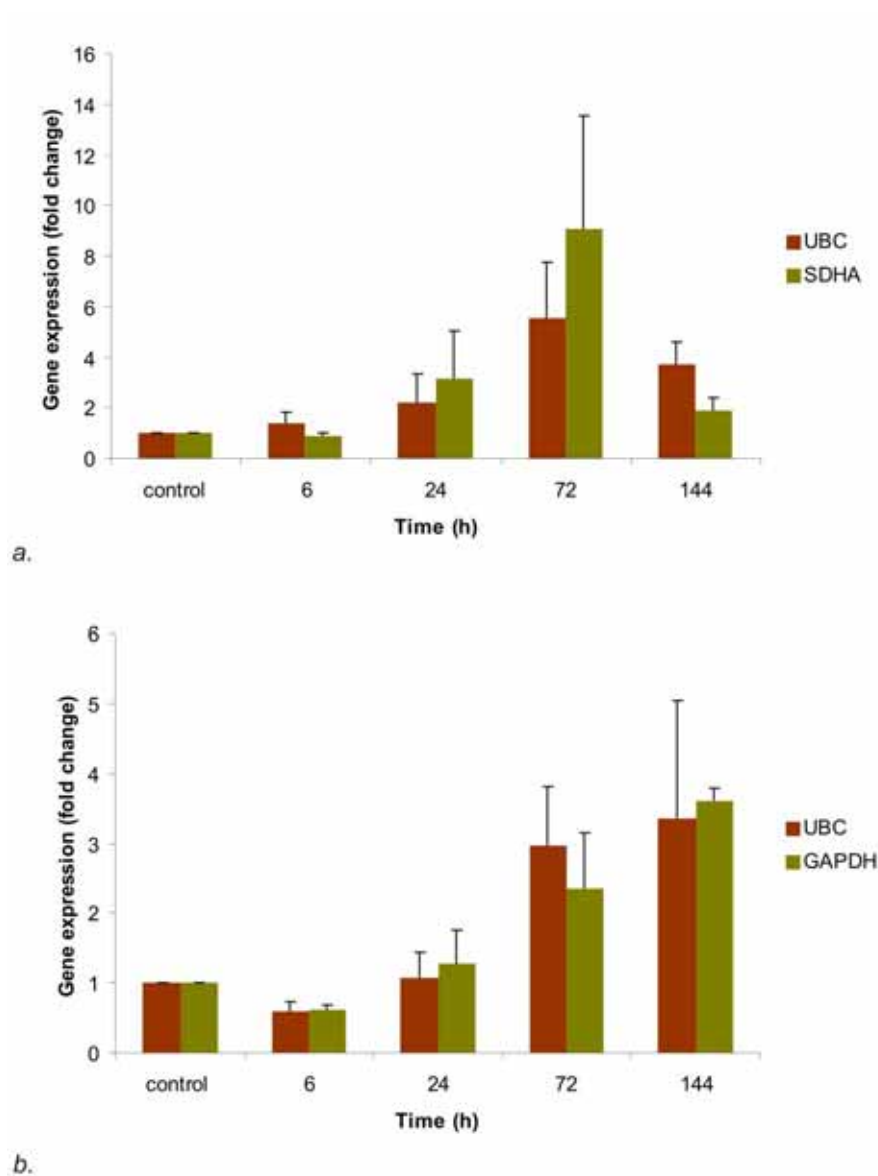


Figure 4 - MMP2 mRNA expression levels in the *a.* jejunum and *b.* colon following irinotecan administration as identified by the top and least ranking housekeeping genes. In all UBC-, SDHA- and GAPDH-normalised data, there is an increase in MMP2 expression peaking at 72 and 144 h following treatment. There is approximately a 4-fold difference in the estimation of MMP2 expression levels at the later time-points in the jejunum. No major difference was noted in the colon. Calculations were performed using the RotorGene6 program.

## 2.4 Discussion

RT-PCR is an important methodology utilised for gene expression studies in rodent models of human disease. Recent studies have investigated a range of housekeeping genes in a panel of rat tissues using low density arrays (Cai et al, 2007) as well as in specific rat models (Al-Bader et al, 2005; Tanic et al, 2007; van Wijngaarden et al, 2007). However to date, there has yet to be a detailed evaluation of housekeeping genes for models of chemotherapy-induced intestinal damage. Despite this, multiple studies have used housekeeping genes to control for gene expression in chemotherapy and radiation-induced mucositis development in rats (Bowen et al, 2007; Feng et al, 2008; Sukhotnik et al, 2008). Previously used housekeeping genes include 18S (Bowen et al, 2007; Sukhotnik et al, 2008) and  $\beta$ -actin (Feng et al, 2008) for normalisation. However, it is not clear on what basis these reference genes were selected. The current study investigated the gene expression stability of 11 housekeeping genes in the jejunum and colon during a timecourse model of irinotecan-induced mucositis. Key findings from this study indicated differential gene expression patterns for the eleven housekeeping genes following chemotherapy treatment, highlighting the importance of pre-study validation. Furthermore, the two most stably expressed genes were Ywhaz and UBC for the jejunum and  $\beta$ -actin and UBC for the colon.

The gastrointestinal symptoms that occur following mucositis development can be attributed to the loss of normal tissue architecture and hence function in multiple regions of the AT (Sonis 2004). The histological modifications associated with mucositis and have been observed in this study included crypt ablation, villus atrophy and increased lamina propria inflammatory infiltrate (Stringer et al, 2007; Logan et al, 2008). One key



pathophysiological feature of mucositis is alteration of mucosal and submucosal signalling (Paris et al, 2001; Gibson et al, 2003; Bowen et al, 2007; Stringer et al, 2007; Stringer et al, 2009). Signalling pathway alterations driving tissue damage occur either early on or in a delayed fashion following chemotherapy administration (Sonis 2004). These pathways include NF $\kappa$ B, ceramide, MAPK, PI3K/ Akt, Wnt/B-catenin and toll-like receptor signalling (Sonis 2004). The housekeeping genes under observation in this study belong to different functional classes and are therefore regulated by different pathways. In this study, it was shown that most of the housekeeping genes were up-regulated in the jejunum and to a lesser extent in the colon at 72 h and/or 144 h following chemotherapy treatment. This is consistent with already established literature which suggests complete dissemination of destructive signalling and maximum damage in tissue at 72h and proliferative regeneration at 144h (Sonis 2004).

Several parameters need to be controlled to obtain reliable quantitation results. These parameters include variation in initial sample amount, RNA recovery, RNA integrity, efficiency of cDNA synthesis and differences in overall transcriptional activity of the tissue analysed. Housekeeping genes are commonly used for normalisation of the aforementioned parameters. Currently, there is no universally valid internal control gene (Schmittgen et al, 2000; Bustin 2002; Bustin 2002) therefore it is important to identify the suitable normalisation gene in specific animal models under investigation. In this study, the NormFinder program was used to rank the 11 candidate housekeeping genes according to their expression stability in an animal model of chemotherapy-induced mucositis. This program uses a model-based approach to estimate the intra- and inter-group expression variation and calculates a stability value for each gene accordingly. In the jejunum, the

top ranking gene identified by NormFinder for normalisation was *Ywhaz*. It showed minimal intra-group variability and induction across the first four time-points, but displayed an augmented expression profile at the later time-point of 144h where there was a 3-fold increase in its expression. Although *UBC* was ranked second by the NormFinder program, it displays a more stable inter-group expression profile over the entire time course in the jejunum and could therefore be used as a normaliser.

*MMP-2* was used as a target gene to validate the use of *UBC* as the optimal housekeeping gene in the current experimental model. *MMP-2* is a zinc-dependent endopeptidase which is tightly regulated at many stages including transcription, activation from precursor zymogens (post-translational) as well as by tissue inhibitors of metalloproteinase (TIMPs) (Malemud 2006; Clark et al, 2007; Sengupta et al, 2007). Expression of most MMPs, including *MMP-2*, is normally low in tissues, however, they are induced when ECM remodelling is required or following injury such as that caused by cytotoxic chemotherapy (Chakraborti et al, 2003). It has been shown that *MMP-2* increases in the jejunum and colon following chemotherapy administration in rats. In this study, *MMP-2* expression was investigated by RT-PCR in order to provide further evidence for the appropriateness of using *UBC* to normalise gene expression. *MMP2* was found to be up-regulated approximately 6-fold in the jejunum and 3.5-folds in the colon compared to the control untreated tissue, demonstrating the utility of *UBC* to detect expression changes in this model.

## 2.5 Conclusions

The development of rat models of chemotherapy-induced mucositis has made it possible to investigate the biological basis underpinning this condition. To date, it is known that mucositis development is a multi-factorial process where there is a vast disarray of many signalling pathways. In order to investigate gene expression differences following mucositis development by RT-PCR, an accurate normalisation gene should be utilised. As indicated by NormFinder, the most suitable combination of housekeeping genes to use are *Ywhaz/UBC* in the jejunum and *UBC/ $\beta$ -actin* in the colon. If restricted to a single housekeeping gene, *UBC* should be used for normalisation of gene expression data in jejunum and colon within and across multiple time-points following administration of the chemotherapeutic agent irinotecan.

## **2.6 Acknowledgements**

Noor Al-Dasooqi was supported by an Australian Postgraduate Award and a GlaxoSmithKline Postgraduate Support Grant; Dr. Joanne M Bowen was supported by a Research Fellowship from the Royal Adelaide Hospital; Dr. Rachel J Gibson was supported by a Cancer Council South Australia Post-Doctoral Fellowship; Andrea Stringer was supported by NHMRC Postgraduate Training Scholarship; Professor Dorothy Keefe is the Cancer Council SA Chair of Cancer Medicine.

### **3.0 Matrix metalloproteinases are possible mediators for the development of alimentary tract mucositis in the DA rat.**

[Al-Dasooqi et al. (2010) *Experimental Biology and Medicine* **235** (10): 1244-1256]

#### **3.1 Introduction**

Irinotecan hydrochloride is a chemotherapeutic drug used for the treatment of a variety of solid tumours (Ma et al, 2003). The mechanism of action of irinotecan is inhibition of DNA topoisomerase I; a key nuclear enzyme responsible for relaxing DNA during DNA replication (Ma et al, 2003). Irinotecan acts on malignant as well as normal cells in the body and has been shown to cause severe alimentary tract (AT) mucositis in the clinic (Sharma et al, 2005; Gibson et al, 2007). AT mucositis is characterised by clinical symptoms including ulceration, nausea and vomiting, abdominal pain and bloating and diarrhoea (Sonis 2004; Murphy 2007). This condition not only decreases patient quality of life but also threatens the effectiveness of anti-cancer treatment as it is a dose limiting toxicity.

Mucositis development is a multifactorial process and involves a cascade of events in multiple tissue regions (Sonis 2004). It has been previously shown that irinotecan causes gross architectural disturbances in AT tissue; most notably the jejunum and colon, as a result of crypt cell damage, oxidative stress, inflammation and changes in gut flora to name a few (Gibson et al, 2003; Gibson et al, 2007; Logan et al, 2008; Stringer et al, 2009). Substantial research efforts have attempted to elucidate the signalling cascades responsible for this damage. Recent studies by Bowen and colleagues (2007) illustrated that

chemotherapy-induced mucositis is associated with the up-regulation of a range of stress response genes and activation of mitogen activated protein kinase (MAPK) signalling, nuclear factor  $\kappa$ B (NF $\kappa$ B) signalling, Fos/Jun signalling and Wnt signalling (Bowen et al, 2007; Bowen et al, 2007). Furthermore, the downstream mediators of this damage include cytokines, ceramide and cyclooxygenase-2 (Yeoh et al, 2005; Logan et al, 2008). Matrix metalloproteinases have also been suggested to play a role in damage onset seen in the AT following chemotherapy administration (Sonis 2004; Al-Dasooqi et al, 2009).

Matrix metalloproteinases (MMPs) are zinc-dependent endopeptidases with a predominant role in extracellular matrix (ECM) homeostasis. Through regulation of ECM components, MMPs effect numerous biological phenomena including cell growth, apoptosis, cell motility, immune responses and cytokine and chemokine bioactivity (Sonis 2002; Clark et al, 2008; Logan et al, 2008; Manicone et al, 2008). MMPs have been proposed to act as mediators of damage in mucositis development (Sonis 2004). Although there is currently no sufficient data in the literature to explain all facets of MMPs function and contribution to the development and amplification of chemotherapy-induced tissue injury, there is growing evidence for an important role of MMPs in a variety of tissue injury models. Furthermore, it has been suggested that MMPs are components of genetic programs such as the wound repair response where they are downstream targets of immediate-early response genes that are induced within minutes of cell stimulation (Clark et al, 2008). Although MMPs have been shown to contribute to tissue injury and inflammation in many gastrointestinal diseases, no direct links have been established between MMPs and mucositis development (Louis et al, 2000; Manicone et al, 2008; Wolf et al, 2008). Therefore, the current study aimed to characterise the expression of multiple MMPs

which have been shown to contribute to injury and inflammation including MMP-1, -2, -3, -9 and -12 as well as their inhibitors TIMP-1 and -2 in a rat model of irinotecan-induced mucositis. This study also investigated the expression of the serine proteases uPA and tPA as well as plasminogen inhibitor PAI-1 as they have been known to play a role in MMP activation.

## **3.2 Materials and Methods**

### ***3.2.1 Animals***

Forty-eight female dark agouti rats weighing 150-170g were used in this study. All experimental procedures were approved by the Animal Ethics Committees of the Institute of Medical and Veterinary Sciences and the University of Adelaide and complied with the National Health and Medical Research Council (Australia) Code of Practice for Animal Care in Research and Training (2004). Due to the severe nature of irinotecan-induced diarrhoea, animals were monitored four times daily. If animals showed any of the criteria specified by the Animal Ethics Committee, they were euthanized. These criteria included a dull ruffled coat with accompanying dull and sunken eyes, coolness to touch with no spontaneous movement, and a hunched appearance. Criteria for animal monitoring and care are as described in previous studies.

### ***3.2.2 Experimental plan***

Rats were randomly allocated into control (n=6) or experimental groups (n=42). Experimental group rats received 0.01mg/kg subcutaneous atropine in order to reduce cholinergic reaction to irinotecan immediately prior to the administration of a single intraperitoneal dose of 200 mg/kg irinotecan (previously shown to cause gastrointestinal mucositis). Irinotecan (kindly supplied by Pfizer, Kalamazoo, USA) was administered in a sorbitol/ lactic acid buffer (45 mg/ml sorbitol /0.9 mg/ml lactic acid, pH 3.4), required for activation of the drug. Rats in the control group did not receive any treatment. Rats were assessed four times daily for mortality, body weights and diarrhoea. Diarrhoea was graded as: none; mild diarrhoea (staining of anus); moderate diarrhoea (staining top of legs and



lower abdomen); severe diarrhoea (staining over legs and higher abdomen as well as continual anal leakage).

Rats were killed at various time-points following irinotecan administration; 1, 6, 24, 48, 72, 96, 144 h, by cardiac puncture and cervical dislocation under 3% halothane in 100% O<sub>2</sub> anaesthesia. The gastrointestinal tract was dissected out from the pyloric sphincter to the rectum and flushed with chilled isotonic saline (0.9 w/v) to remove contents. A 1 cm sample of the small intestine and the colon were taken at approximately 25% and 50% of the lengths, respectively. For histological analysis, samples were fixed in 10% neutral buffered formalin, processed and embedded in paraffin. Jejunal and colonic tissue was also frozen at -80 °C until RNA extraction.

### ***3.2.3 Histological assessment***

Samples of jejunum and colon were collected, processed and stained as described in previous studies (Logan et al, 2008; Stringer et al, 2008; Stringer et al, 2009). Sections were examined by light microscopy and analysed by a professional veterinary pathologist.

### ***3.2.4 RNA isolation and reverse transcription***

30mg of jejunal and colonic tissue was homogenised in TRIzol® Reagent (Invitrogen Life Technologies, Mulgrave, Australia). RNA was isolated using Nucleospin® RNA II kit (Macherey-Nagel, Duren, Germany). Total RNA was prepared according to the manufacturers instructions. Briefly, cell lysis buffer was added to the ground tissue and filtered through silica membrane filter columns. Following a sequence of filtration steps, RNA binding conditions were adjusted and DNA digestion performed. A series of

washing steps were carried out before highly pure RNA was eluted in RNase-free water. To determine RNA purity and concentration, each sample was analysed using the Nanodrop spectrophotometer (NanoDrop Technologies, Wilmington, DE, USA). RNA integrity was assessed by electrophoresis on 1.2% (w/v) agarose gels. RNA was converted to cDNA using the iScript cDNA Synthesis Kit (Bio-Rad, Hercules, CA, USA). For each reaction, 1µg of RNA was combined with iScript reaction mix, iScript reverse transcriptase and reaction volume made up to 20µl using nuclease-free water. Samples were incubated for 5 minutes at 25°C, 30 minutes at 42°C and 5 minutes at 85°C. Total cDNA concentration was measured using the Nanodrop program and samples diluted to 100ng/µl with nuclease-free water (Promega, Madison, WI, USA).

### ***3.2.5 Real-time PCR***

Real-time PCR was performed using the Rotor Gene 3000 (Corbett Research, Sydney, Australia). The expression of each candidate reference gene in each of the forty-two experimental samples was determined relative to the mean expression of the same gene in tissue obtained from untreated animals pooled cDNA. Amplification mixes contained 1µl of cDNA sample, 5µl of fluorescent dye SYBR green (Applied Biosystems, Foster City, CA), 3µl of nuclease-free water (Promega, Madison, WI, USA) and 0.5µl of each forward and reverse primers (all primers were pre-diluted to 50 pmol/µl) to make up a final volume of 10µl. Thermal cycling conditions included denaturation step at 95°C for 10 min, and then 45 cycles of denaturation at 95°C for 10 s, annealing at 60°C (MMP-2 & MMP-9), 55°C (MMP-12, uPA, tPA, PAI-1), 56°C (TIMP-1 & TIMP-2) for 15 s and extension at 72°C for 20 s. Amplification was followed by melt curve analysis to confirm product specificity. Primer pair sequences have been previously described in the literature (Chen

et al, 2006; Fujisaki et al, 2006; Vikman et al, 2007; Wasserman et al, 2007; Almarza et al, 2008; Castro et al, 2008; Durigan et al, 2008) and are summarised in Table 1. UBC was used as a housekeeping gene as it has shown stable expression throughout the time-course of this irinotecan-induced model (Al-Dasooqi et al., 2011). For each set of primers, PCR cycling conditions were optimised to achieve similar amplification efficiency to the housekeeping gene UBC. Each sample was normalised by its UBC content by the RotorGene 6 program. Along with normalising the expression of the gene of interest to the housekeeping genes, it performs the  $2^{-\Delta Ct}$  method to acquire the fold change in gene expression over the time course relative to untreated control calibrator (with adjustment to amplification efficiency) according to the following formula:

$$Ratio = \frac{\text{Efficiency (target gene)}^{\Delta CT \text{ target (calibrator-test)}}}{\text{Efficiency (reference gene)}^{\Delta CT \text{ reference (calibrator-test)}}$$

Table 1 - Primer pair sequences and characteristics

Gene	Primer sequence (5'-3')	Nucleotide Position	Amplicon length (bp)	Tm (°C)	Ref
MMP2	F: CTGATAACCTGGATGCAGTCGT R: CCAGCCAGTCCGATTTGA	2138-2272	135	55 50	<sup>1</sup>
MMP9	F: AAGCCTTGGTGTGGCACGAC R: TGGAAATACGCAGGGTTTGC	760-876	117	56 52	<sup>2</sup>
MMP12	F: CTGGGCAACTGGACACCT R: CTACATCCGCACGCTTCA	259-423	165	52 50	<sup>3</sup>
TIMP1	F: TCCTGGTTCCCTGGCATAAT R: GGCAAAGTGATCGCTCTGGT	406-599	194	52 54	<sup>4</sup>
TIMP2	F: CTACATCTCCTCCCCGGATGA R: GGTGCCCATGATGCTCTTC	617-684	68	56 54	<sup>5</sup>
tPA	F: GTCAGATTCCAGTCAGTGTG R: GTTGCTCGTGATGGTTTTG	1340-1577	238	52 49	<sup>6</sup>
uPA	F: TCGGACAAGAGAGTGCCA R: TCACAATCCCGCTCAGAG	1018-1249	231	50 50	<sup>6</sup>
PAI-1	F: GACAATGGAAGAGCAACATG R: ACCTCGATCTTGACCTTTTG	966-1170	205	50 50	<sup>6</sup>
UBC	F: TCGTACCTTCTCACCACAGTATCTAG R: GAAAATAAGACACCTCCCATCA	2406-2487	82	58 56	<sup>7</sup>

<sup>1</sup> Durigan et al, 2008<sup>2</sup> Vikman et al, 2007<sup>3</sup> Wasserman et al, 2007<sup>4</sup> Almarza et al, 2008<sup>5</sup> Castro et al, 2008<sup>6</sup> Fujisaki et al, 2006<sup>7</sup> Chen et al, 2006

### ***3.2.6 Immunohistochemistry***

Control (n=6) and experimental (n=42) jejunum and colon sections were cut from paraffin blocks at 4µm thickness and mounted onto silane-coated slides. Sections were dewaxed in xylene and rehydrated through a graded series of alcohols. Sections were immersed in 10 mM citrate buffer (pH 6.0) and antigen retrieval performed by heating sections in microwave on “high” until boiling and on “low” for 10 minutes. Sections were allowed to cool and endogenous peroxidase activity subsequently blocked with 3% H<sub>2</sub>O<sub>2</sub> in methanol. Non-specific antibody binding was blocked with 20% normal goat or horse serum (NHS or NGS) (Sigma, St Louis, MO, USA) in PBS for 30 min at room temperature (RT). Avidin-Biotin Blocking Kit (Vector Laboratories, Burlingame, CA, USA) was used to block endogenous avidin-biotin activity. Sections were incubated overnight with antibodies (diluted in 5% NGS or NHS) directed at MMP-1 at 1:800 (LifeSpan Biosciences, Seattle, WA, USA), MMP-2 at 1:10000 (Abcam, Cambridge, UK), MMP-3 at 1:1000 (Epitomics, Burlingame, CA, USA), MMP-9 at 1:500 (Abcam, Cambridge, UK), MMP-12 at 1:500 (Epitomics, Burlingame, CA, USA), TIMP-1 at 1:750 (Acris Antibodies, Herford, Germany) and TIMP-2 at 1:100 (Abcam, Cambridge, UK) diluted in 5% NHS or NGS at 4 °C. Tissue sections were incubated with the appropriate secondary antibody (20 min at RT), ABC labelling reagent (30 min at RT) and developed with DAB. Sections were counterstained with Lillie-Mayer’s haematoxylin, dehydrated and cleared in xylene before being mounted. Qualitative immunohistochemistry was performed. Staining intensity was graded as follows: 0 no staining, 1 weak staining, 2 moderate staining, 3 strong staining and 4 intense staining. This qualitative staining assessment has been previously validated by published grading systems (Bowen et al, 2005; Yeoh et al, 2005; Logan et al, 2008) and

is routinely used within our laboratory. All assessments were done in a blinded fashion by one investigator (NA).

### ***3.2.7 Statistics***

Results were statistically analysed using a Kruskal-Wallis test. P-value cut offs for significance were adjusted to allow for multiple comparison according to the Bonferroni correction. Results were declared statistically significant at  $p < 0.05/\text{group number}$ .

### **3.3 Results**

#### ***3.3.1 Response to treatment and histological analysis***

As previously reported (Stringer et al, 2007; Logan et al, 2008), rats treated with irinotecan began demonstrating clinical signs of mucositis from 2 hours following irinotecan administration where diarrhoea was observed in 23% of rats. The prevalence of diarrhoea peaked at 24 hours where 39% of rats had mild diarrhoea and 5% had moderate diarrhoea. At 72 h, 33% of treated rats had mild diarrhoea. All diarrhoea was resolved at 144h after irinotecan administration. None of the rats in the control groups developed diarrhoea. Irinotecan-induced death did not occur in this study.

Marked histological evidence of mucositis was observed in the jejunum and colon following irinotecan treatment (Figure 1). These changes were evident as early as 6h following treatment and included the presence of degenerative enterocytes within the crypts. This was followed by more gross architectural disturbances at later time points. In the jejunum, these changes included villus blunting, epithelial atrophy and increased intensity of inflammatory cell infiltrate through mucosal tissue. Similar damage was seen in the colon at later time points with focal complete crypt ablation observed at 72h after treatment (Figure 1). Tissue restitution is initiated at 144 h.

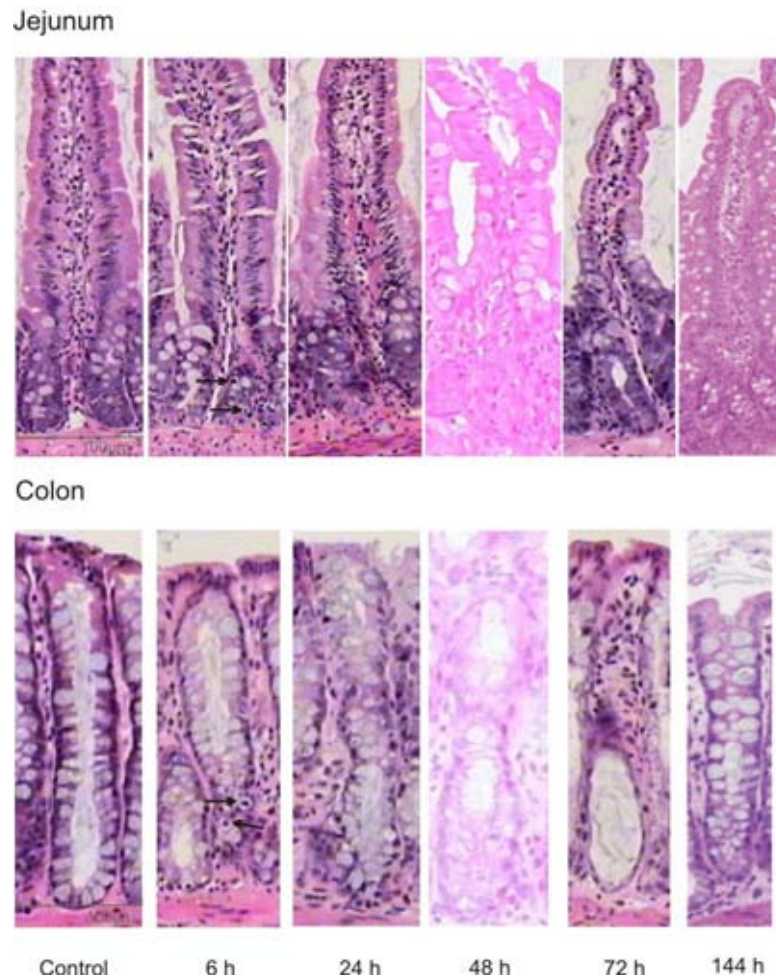


Figure 1: H&E stains illustrating histopathological damage at various time-points following administration of a single 200 mg/kg intraperitoneal dose of irinotecan in the jejunum and colon. Early signs of damage are evident in the jejunum and colon at 6 h (arrows). Villus blunting is noted in the jejunum at 48 h and complete crypt ablation occurs in the colon at 72 h. Tissue restitution is initiated at 144 h in both regions.



### ***3.3.2 MMP and TIMP gene expression following irinotecan treatment***

*Jejunum.* A significant alteration in MMP-2, -9 and -12 gene expression was noted following irinotecan. MMP-2 levels were unchanged at the early time points but increased at 48h after treatment and peaked at an 8.8-fold change in gene expression at 72h after treatment ( $p<0.05$ ) (Figure 2a). In comparison, MMP-9 expression was up-regulated 1.8-fold from baseline at 6h which was sustained until 96h, after which a decrease in expression was noted (Figure 2a). The expression profile of MMP-12 was inconsistent with either MMP-2 or -9 as an initial decrease in expression was observed at 6h following treatment. A significant increase in MMP-12 was noted at 144h ( $p<0.05$ ) where gene expression was 4.4-fold higher than controls (Figure 2a). TIMP-1 expression significantly decreased at 1h following treatment ( $p<0.05$ ) and this was followed by a peak 10.5-fold increase in gene expression at 24h. TIMP-2 expression also increased to 3.4-fold at 96 h following treatment ( $p<0.05$ ) (Figure 2a).

*Colon.* The gene expression of MMP-2, -9 and -12 were altered in the colon following irinotecan. MMP-2 expression decreased at 1h following irinotecan before gradually increasing at 72h ( $p<0.05$ ). MMP-2 expression peaked at 2.6-fold change in gene expression at 144h following treatment ( $p<0.05$ ) (Figure 2b). MMP-9 levels also increased following irinotecan treatment and peaked at 96h with a 3.5-fold change in gene expression in comparison to controls (Figure 2b). There was a significant decrease in MMP-12 expression at 1h following irinotecan ( $p<0.05$ ). This was followed by an increase in MMP-12 at 72h which peaked at 5.4-fold that of controls at 144h (Figure 2b). TIMP-1 and -2 expression following irinotecan was consistent with that seen in the jejunum but to a lesser extent (Figure 2 a & b).

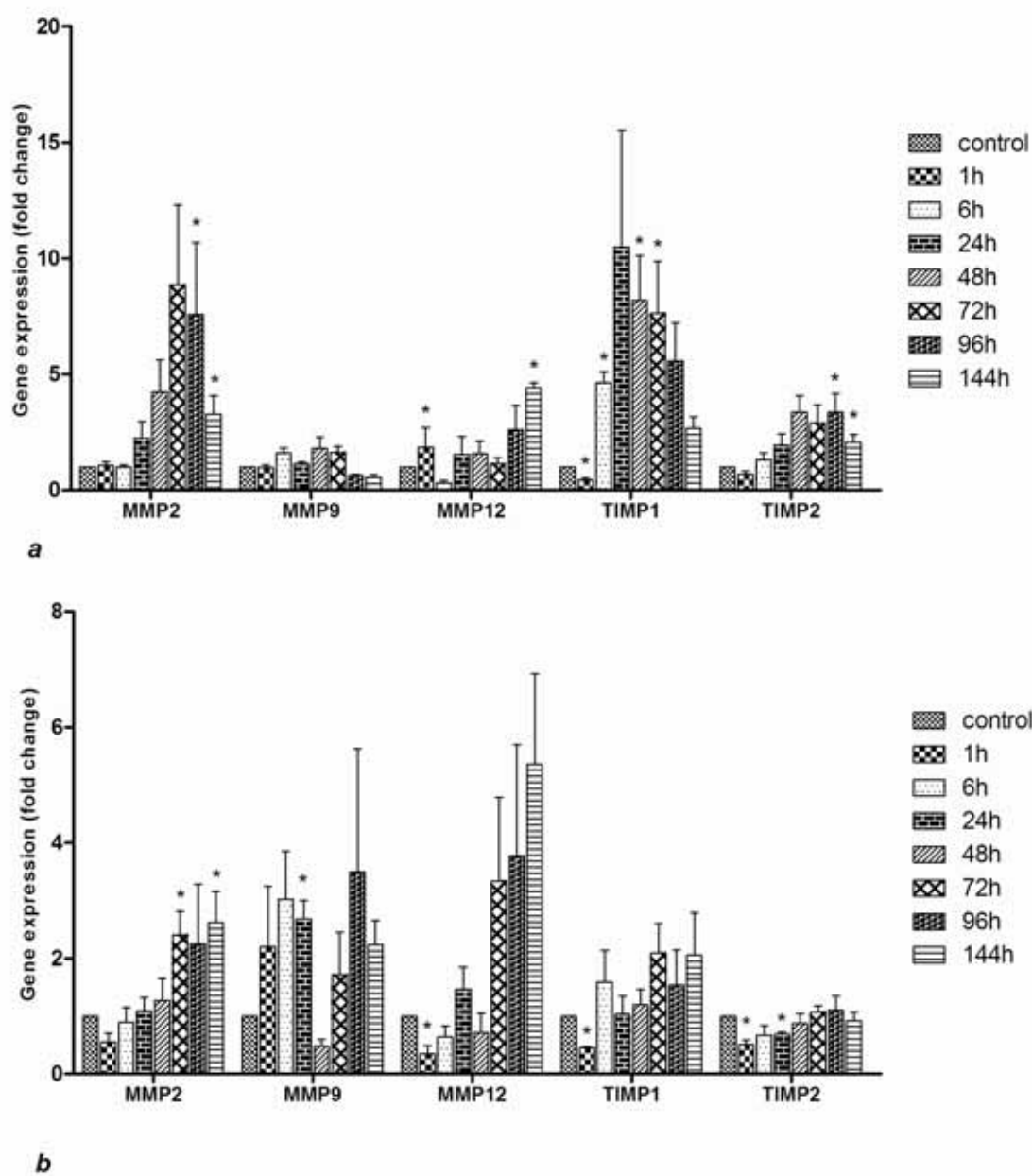


Figure 2: Effect of a single 200 mg/kg intraperitoneal dose of irinotecan on MMP and TIMP gene expression in the a) jejunum and b) colon at 1, 6, 24, 48, 72, 96 and 144h after administration; the data are means + standard error; \* $p < 0.05$ : compared to pooled untreated controls.

### ***3.3.3 Tissue levels of MMPs following irinotecan***

*Jejunum.* Tissue protease levels in this region were altered throughout the time-course under investigation (Figure 3). In particular, MMP-1 levels decreased below that observed for untreated, control tissue at 1h - 24h after irinotecan in both jejunal villi and crypts ( $p < 0.05$ ) (Figure 4 a & b). The decrease was followed by a statistically significant increase in staining levels for MMP-1 at 96h following treatment in both regions ( $p < 0.05$ ). MMP-2 levels were unchanged in the villi and decreased within the crypts early following irinotecan ( $p < 0.05$ ). However, there was an increase in MMP-2 48h after treatment in both regions ( $p < 0.05$ ) (Figure 4 a & b). MMP-3 was primarily expressed in the villus epithelial cells and absent in jejunal crypts in untreated control tissue (Figure 3). In both the crypts and villi there was an increase in MMP-3 expression at 1h and 48h, respectively ( $p < 0.05$ ) (Figure 4 a & b). This increase was sustained throughout the remainder of the time-course (Figure 4 a & b). MMP-9 levels also increased from moderate to intense staining in epithelial cells, basement membrane and underlying lamina propria at 6h onwards and in jejunal crypts at 24h onwards after treatment ( $p < 0.05$ ). There was a statistically significant increase in MMP-12 expression in the villi at 24, 96 and 144h following treatment ( $p < 0.05$ ). However, the most substantial increase in MMP-12 expression occurred in the crypts where intense staining was noted at 96 and 144h following treatment ( $p < 0.05$ ).

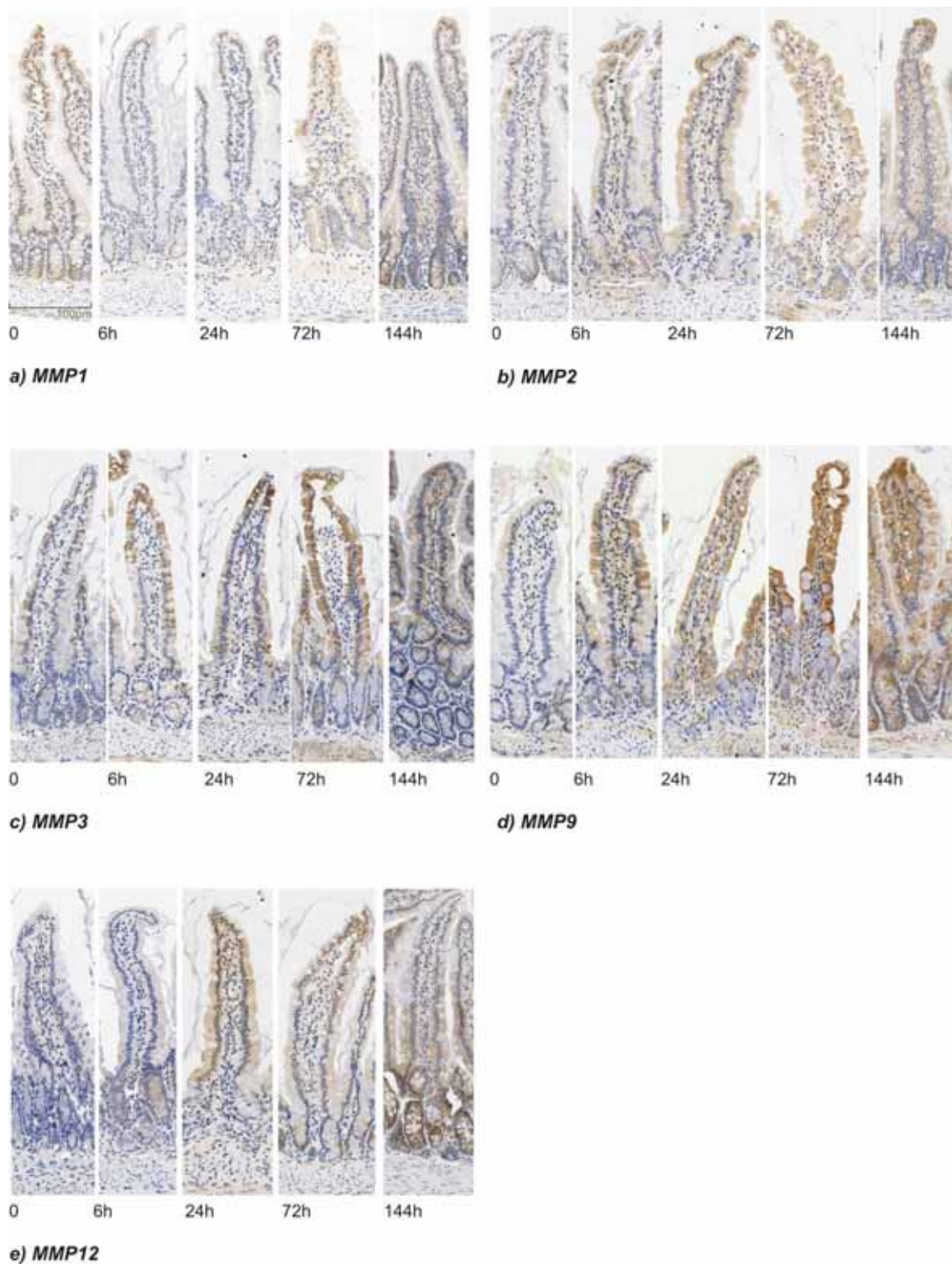


Figure 3: MMP immunostaining in the jejunum in control tissue and at selected time points following the administration of 200 mg/kg irinotecan. All photomicrographs taken at 20x objective.

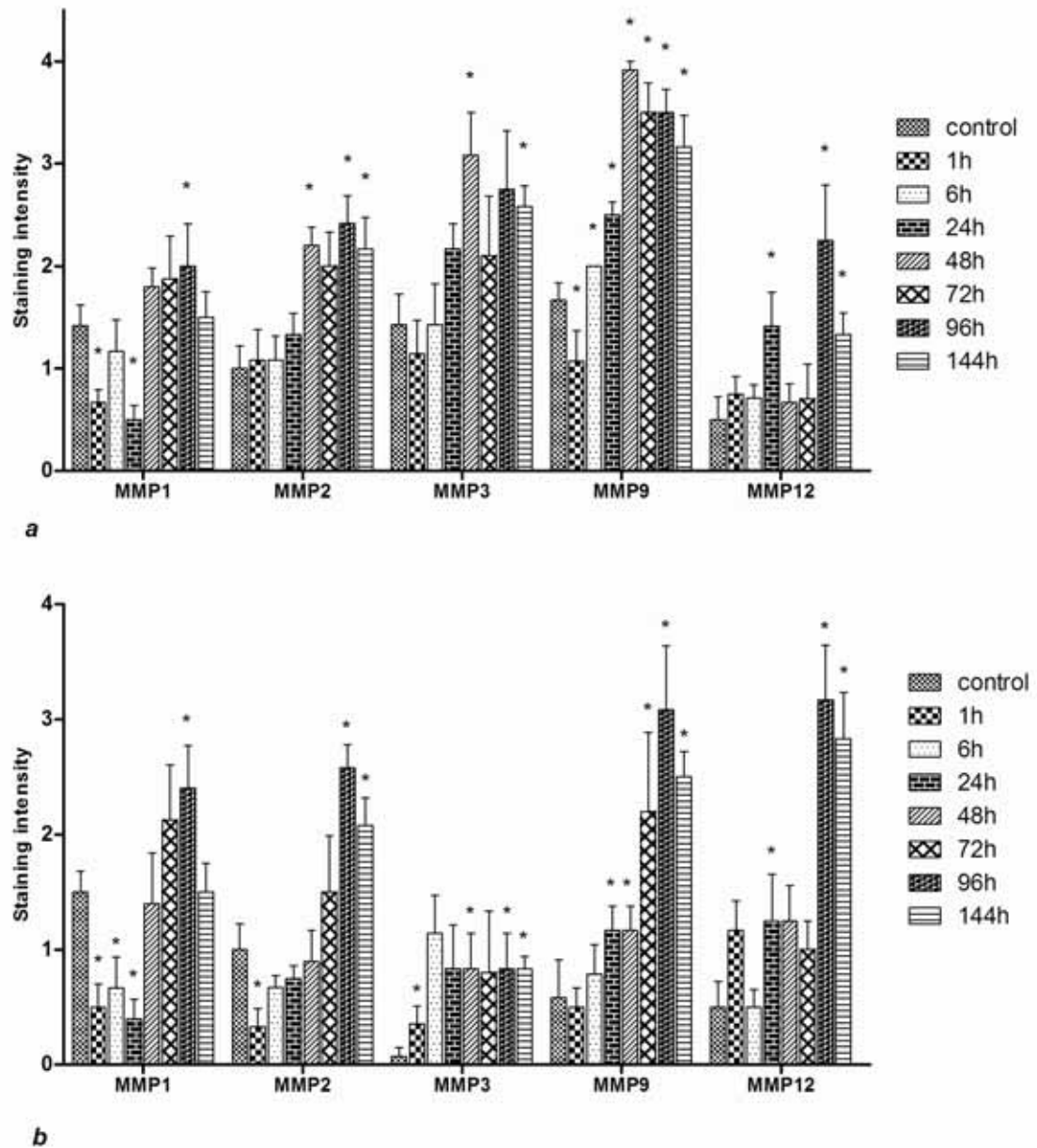


Figure 4: MMP staining in jejunal a) villi and b) crypts at 1, 6, 24, 48, 72, 96 and 144h following the administration of 200mg/kg irinotecan intraperitoneally. All control and experimental tissue were graded by a qualitative scale. The data are means + standard error; \* $p < 0.05$ : compared to untreated controls.

*Colon.* Similar changes in MMP expression were observed in the colon following irinotecan (Figure 5). In particular, an increase in MMP-1 levels was demonstrated at the basal level of the crypts 24h after treatment ( $p<0.05$ ) and a corresponding subsequent increase in apical colon staining was noted at 72h ( $p<0.05$ ) (Figure 6 a & b). MMP-2 staining was weak in control tissue and increased significantly in the apical and basal colon at 96h following treatment ( $p<0.05$ ) (Figure 6 a & b). The expression of MMP-3 was minimal in the basal colon at all time-points. In contrast, MMP-3 expression increased significantly in cells of the apical colon 24h following irinotecan ( $p<0.05$ ) before subsequently significantly decreasing to levels below that seen in control tissue by 144h ( $p<0.05$ ) (Figure 6 a & b). MMP-9 levels were initially very low in untreated, control tissue. However, following irinotecan there was an increase in MMP-9 expression which was intense at the late time points of 96h and 144h ( $p<0.05$ ) (Figure 6 a & b). An increase in MMP-12 from weak to moderate was noted in the apical and basal colon from 24h following treatment ( $p<0.05$ ) (Figure 6 a & b).

MMP expression changes throughout the time course following irinotecan administration are summarised in Table 2.




Figure 5: MMP immunostaining in the colon in control tissue and at selected time points following the administration of 200 mg/kg irinotecan. All photomicrographs taken at 20x objective.

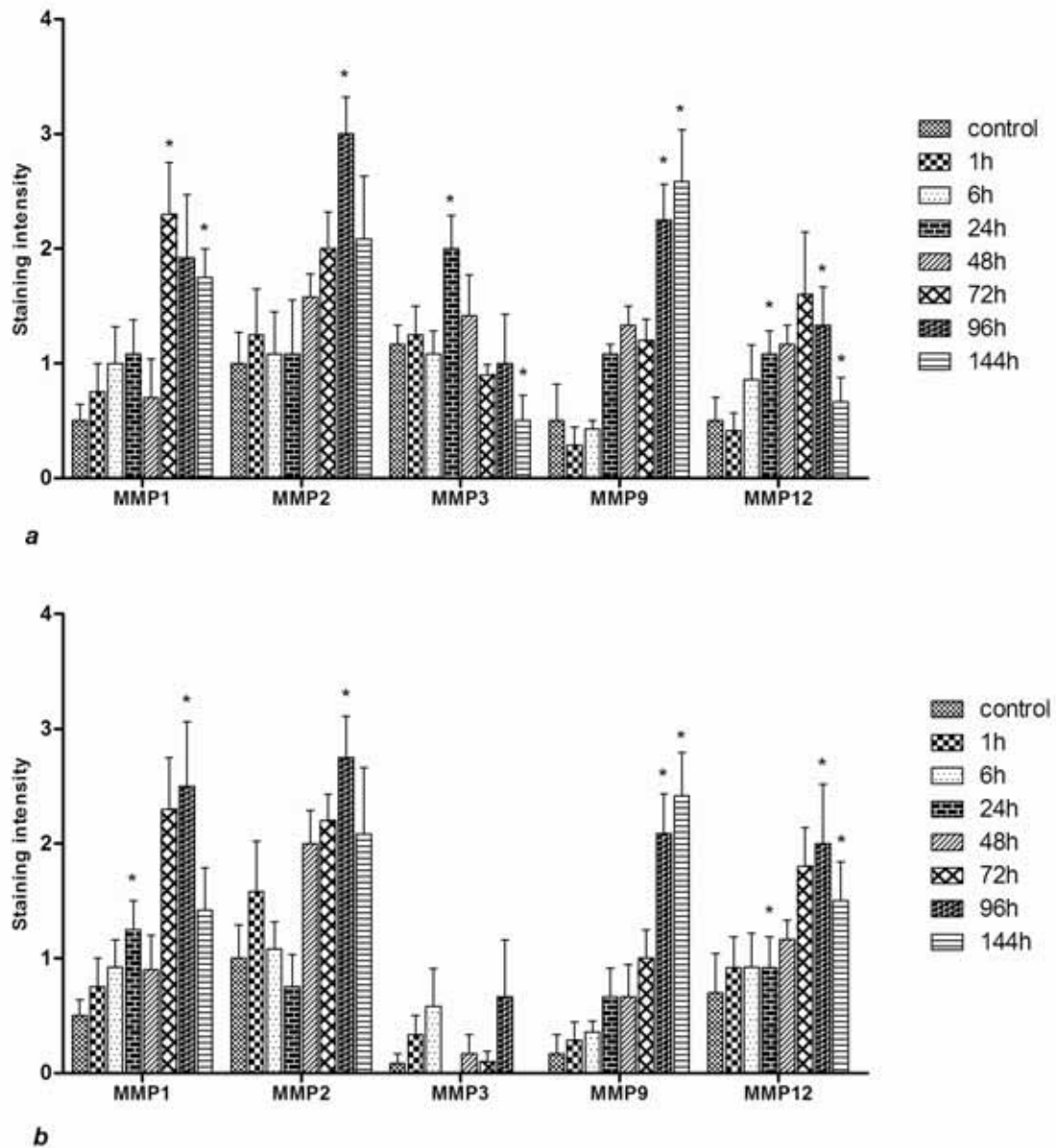


Figure 6: MMP staining in the a) apical and b) basal colon 1, 6, 24, 48, 72, 96 and 144h following the administration of irinotecan 200 mg/kg irinotecan intraperitoneally. All control and experimental tissue were graded by a qualitative scale. The data are means + standard error; \* $p < 0.05$ : compared to untreated controls.



Table 2: Summary of MMP tissue levels early (1-6h) and late (24-144h) following irinotecan administration

	<i>Early</i>	<i>Late</i>
<i>Jejunum</i>		
MMP-1	↓	↑
MMP-2	↓	↑
MMP-3	↑	↑
MMP-9	↓	↑
MMP-12	↔	↑
<i>Colon</i>		
MMP-1	↔	↑
MMP-2	↔	↑
MMP-3	↔	↓
MMP-9	↔	↑
MMP-12	↔	↑

#### ***3.3.4 Tissue levels of TIMPs following irinotecan***

TIMP-1 and -2 were expressed at low levels in the jejunum and colon of untreated, control animals (data not shown). TIMP-1 and -2 levels decreased significantly in the jejunal crypts and villi early on following irinotecan administration (1-6h). There was a subsequent increase in TIMP-1 & -2 levels to moderate staining from 24h onwards following irinotecan (data not shown). In contrast, no change in TIMP-1 and -2 were noted in the colon following irinotecan.

#### ***3.3.5 Plasminogens gene expression following irinotecan***

tPA gene expression increased significantly in the jejunum from 6 h following irinotecan onwards. tPA expression peaked in the jejunum at a 8.5-fold change 48 h following irinotecan ( $p < 0.05$ ) (Figure 7a). uPA gene expression increased 2.6-folds at 1h in the jejunum but a significant increase was only observed at 144 h following irinotecan ( $p < 0.05$ ) (Figure 7a). PAI-1 increased significantly at 6 h following treatment onwards ( $p < 0.05$ ) (Figure 7a). There was no significant change in tPA and uPA in the colon (Figure 7b). A decrease in PAI-1 was noted at 48 h following irinotecan where gene expression was 0.39 (2.56-fold decrease) in comparison to control tissue ( $p < 0.05$ ) (Figure 7b).

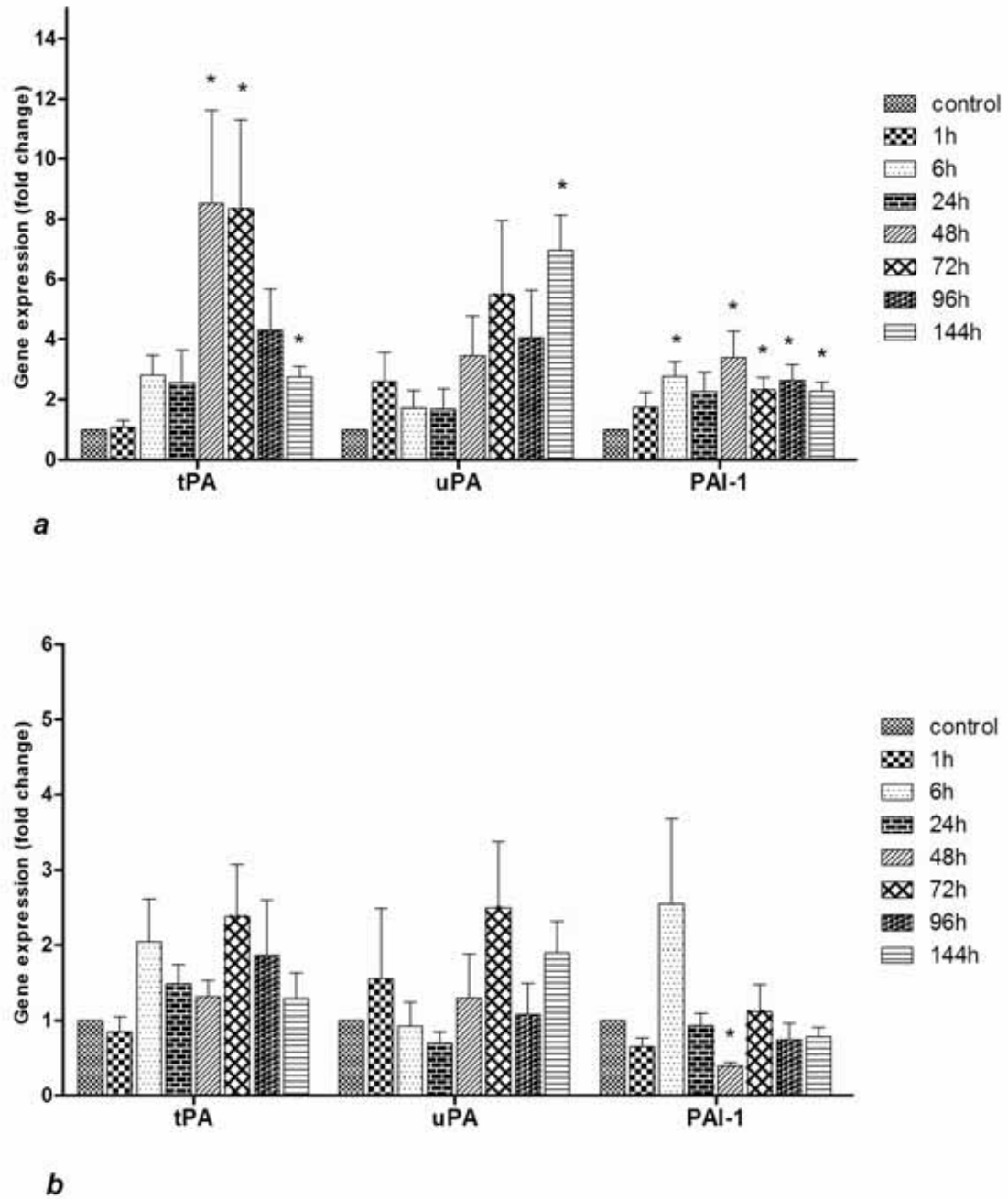


Figure 7: mRNA expression of MMP activators tPA and uPA and inhibitor PAI-1 in the a) jejunum and b) colon at 1, 6, 24, 48, 72, 96 and 144h after administration; the data are means + standard error; \* $p < 0.05$ : compared to pooled untreated controls.

### 3.4 Discussion

The current study investigated the expression profiles of a range of MMPs, previously shown to act as mediators of tissue injury and inflammation (Louis et al, 2000; Meijer et al, 2007; Solberg et al, 2008), in a time course model of irinotecan-induced mucositis. Key findings from this study indicate a substantial augmentation in MMP-1, -2, -3, -9 and -12 as well as TIMP-1 and -2 expression following irinotecan. Furthermore, the expression profiles of these MMPs in correlation with the histopathological damage seen in the tissue suggest varying roles for the MMPs in the different stages of mucositis development within the alimentary tract. This study has also shown that MMP-activators, tPA and uPA, are up-regulated in both the jejunum and colon. The expression of inhibitory PAI-1 increases slightly in the jejunum while it decreases in the colon following the administration of irinotecan.

From this study, it is now possible to elucidate the role that MMPs play in mucositis development by correlating their expression profiles with the underlying histopathology. The current study along with many past studies, have described in detail the pathological alteration that occurs in the AT following irinotecan (Gibson et al, 2003; Gibson et al, 2007; Logan et al, 2008; Stringer et al, 2008; Stringer et al, 2009). These have indicated the presence of degenerative enterocytes within jejunal and colonic crypts as early as 6h following irinotecan administration. Furthermore, intestinal morphometry studies have shown that irinotecan causes maximal villus and crypt damage at 48-72h following its administration thus resulting in epithelial atrophy (Gibson et al, 2003). An increase in inflammatory infiltrate is also noted at those time-points. In the colon, decreases in goblet cell numbers and mucus hypersecretion is also observed (Gibson et al, 2003). It has also

been noted that in areas of crypt loss, collapse and condensation of the propria stroma occurs (Gibson et al, 2007). In the jejunum and colon, tissue restitution is initiated generally by three days post treatment, and as such hyperplasia was observed after 72 h and excess mitotic figures were present even at the later time-points of 96-144h following irinotecan administration (Stringer et al, 2009).

Although MMPs share similar structural homology and are all classed as ECM-degrading proteases, they have been shown to have distinct functional differences. For example, MMP-2 and -9 have been shown to aid in inflammatory cell infiltration into tissue following primary cell damage while MMP-1 and -3 have been shown to be vital for inducing epithelial cell migration and tissue restitution following injury (Paris et al, 2001). These differences could be attributed to differences in domain structure, activation mechanism and cellular location (Clark et al, 2008). In our model of irinotecan-induced mucositis, MMP-1, -2, -3, -9 and -12 have shown differing expression profiles indicating possible differences in their roles in the pathogenesis of mucositis. The expression profiles of the MMPs of interest suggest they play the following roles: MMP-1, role in healing as it decreases early on then increases at 96h and 144h; MMP-2, MMP-9 and MMP-12, role in inflammation as expression decreases early on but increases at 48h, consistent with inflammatory influx and maximal morphological damage; MMP-3, possible role in initiation of inflammation as well as hypo-proliferation in jejunal and colonic crypts early following irinotecan as peak expression was noted within crypts at very early time points before dissipating. However, it should be noted that causation has not been proven in this study.

MMP-1 showed a very distinct expression pattern relative to other MMPs under observation. MMP-1 (along with MMP-8, -13 and -14) is one of only four members of the MMPs which have been shown to have fibrillar collagen degrading capacity (Pardo et al, 2005). Furthermore, MMP-1 promoter analysis studies have identified TATA box and AP-1 binding sites as well as multiple consensus and composite sites (Clark et al, 2008). The differential expression pattern for MMP-1 in this model may be attributed to its unique promoter conformation and hence the complexes by which it can be induced. A recent study by Salmela and colleagues (2004) investigated the expression of MMP-1 in *in vivo* as well as *ex vivo* models of gut injury. They found MMP-1 to be expressed by migrating enterocytes and aid primarily in wound closure (Salmela et al, 2004). Furthermore, they showed that MMP-1 expression was not up-regulated in response to different cytokine treatments but rather increased in response to EGF treatment; which is thought to have a vital role in maintenance of mucosal layer integrity as well as in acute gut repair (Salmela et al, 2004). These studies support the suggestion that MMP-1 may play a vital role in tissue healing following mucosal injury caused by irinotecan. However, further studies are still required to fully understand the precise role of MMP-1 in tissue restitution and healing following mucositis development.

A hallmark of mucositis development following primary tissue injury is the initiation of an acute inflammatory response (Sonis 2002; Sonis 2004; Bowen et al, 2007). Previous studies have shown early up-regulation of MAPK signalling, NF $\kappa$ B signalling, Fos/Jun signalling and Wnt signalling following irinotecan administration (Bowen et al, 2007; Bowen et al, 2010). Furthermore, there is a peak in tissue levels of pro-inflammatory cytokines TNF, IL-1 $\beta$  and IL-6 at 6h following the administration of irinotecan (Logan

et al, 2008). MMP genes have been shown to possess functional elements which respond to cell injury and inflammatory pathways, such as those up-regulated in mucositis. Previous studies have implicated MMP-2, -3, -9 and -12 in inflammatory responses where they are produced by infiltrating leukocytes in order to facilitate their transendothelial migration into the mucosa (Delclaux et al, 1996; Wu et al, 2007; Lin et al, 2008). In this study, inflammatory infiltrate was noted at 48-72h following treatment and is consistent with the expression of MMP-2, -3, -9 and -12 in epithelial cells and the underlying blood vessel-rich lamina propria. Maximum tissue injury seen in AT mucositis is also consistently seen at these time-points. This correlation between injurious signalling pathway activation, inflammatory infiltrate and the expression of MMPs implicates MMP-2, -3, -9 and -12 in the acute inflammation seen in mucositis in our model. However, the role of MMPs in mucositis development is unlikely to be restricted to inflammation as they may also contribute to the profound changes in cellular kinetics which are observed in AT mucositis.

MMPs are synthesised and secreted in their latent, inactive form. The regulatory mechanisms for MMP activation are complex and include allosteric activation, furin activation, serine proteinases and oxidation (Malemud, 2006; Clark et al, 2007). This study investigated the expression of the plasminogen activators uPA and tPA following irinotecan administration. An early increase in uPA and tPA was noted in this study; possibly aiding in activation of secreted MMPs. However, this study explored only one of many mechanisms for MMP activation. Further studies are now warranted to investigate the mechanisms responsible for MMP activation in tissue following irinotecan.

### **3.5 Conclusions**

In conclusion, an augmentation in the expression profiles of MMP-1, -2, -3, -9 and -12 and their inhibitors TIMP-1 and -2 correlated with the histopathological alterations in the tissue following irinotecan treatment. This prompts the consideration of MMPs as possible mediators of damage in the AT following chemotherapy. Further studies are now required in order to elucidate the specific roles of each of these MMPs in mucositis. These could include intervention studies with specific MMP inhibitors in this model.



### **3.6 Acknowledgments**

Noor Al-Dasooqi was supported by an Australian Postgraduate Award and a GlaxoSmithKline Postgraduate Support Grant; Dr. Rachel J Gibson was supported by a Cancer Council South Australia Post-Doctoral Fellowship; Dr. Joanne M Bowen was supported by a Postdoctoral Research Fellowship from the National Health and Medical Research Council; Andrea Stringer was supported by NHMRC Postgraduate Training Scholarship; Professor Dorothy Keefe is the Cancer Council SA Chair of Cancer Medicine.

## **4.0 Irinotecan-induced alterations in intestinal cell kinetics and extracellular matrix component expression**

[Al-Dasooqi et al (2011) *International Journal of Experimental Pathology* **92**(5):357-365]

### **4.1 Introduction**

In recent years, there has been increasing interest in characterising the histopathological features of alimentary tract (AT) mucositis. In general terms, mucositis refers to the damage caused by chemotherapy or radiation therapy to mucous membranes of the AT (Sonis 2004; Keefe et al, 2007). Different cytotoxic treatment regimens have been shown to affect different regions of the AT resulting in region-specific toxicities including, but not limited to, ulceration, pain, bloating, nausea and vomiting, diarrhoea and constipation (Sonis 2004; Keefe et al, 2007). Although these toxicities arise in a large proportion of patients receiving cytotoxic anti-cancer treatment and have detrimental effect on the treatment schedule and the patient's quality of life, an effective intervention has yet to be introduced.

Much progress has been made in understanding the molecular, cellular and tissue events that lead to the development of this condition (Sonis 2004). Historically, mucositis was thought to be purely an epithelium-mediated event which occurred as a result of non-specific effects of cytotoxic anti-cancer agents (Ijiri et al, 1983; Sonis et al, 2004). However, recent research has shown that development of this condition involves a multi-factorial process and a cascade of events in multiple tissue structures (Sonis 2004). In the gastrointestinal region, some of the main histopathological features of mucositis include the presence of degenerative enterocytes (Gibson et al, 2005; Logan et al, 2008), epithelial

atrophy (Gibson et al, 2005), damage of sub-epithelial vasculature (Paris et al, 2001), infiltration of inflammatory cells (Logan et al, 2008), hypersecretion of mucus (Stringer et al, 2009; Stringer et al, 2009) and increase in pathogenic bacteria (Stringer et al, 2008; Stringer et al, 2009; Stringer et al, 2009). Other submucosal components which have been suggested to play a role in the development of mucositis are the extracellular matrix (ECM) fibrous proteins (Sonis et al, 2000; Sonis 2004; Redding 2005).

The ECM is a complex structural network that contains fibrous proteins, proteoglycans and glycoproteins (Michael *et al*, 2003). The ECM provides structural support for the tissue. Furthermore, research in matrix biology has revealed a vital role for the ECM, in particular the fibrous proteins making up the basement membrane, in regulating epithelial cell kinetics (Yurchenco et al, 1990; Meredith et al, 1993; Beaulieu 1997). Potten and colleagues (1997) and Beaulieu (1997) have highlighted an important role for the basement membrane ECM in small intestinal and colonic crypt cell activity. Both groups demonstrated that ECM molecules are spatially expressed along the crypt-villus axis and include E-cadherin, tenascin, laminin, fibronectin, collagen IV and perlecan (Beaulieu 1997; Potten et al, 1997). Each of these proteins has a differential function on cell kinetics and hence the spatial organisation of these is paramount for maintenance of mucosal layer integrity (Table 1). This spatial expression is tightly regulated by matrix metalloproteinases (MMPs) to ensure the efficient turnover of gastrointestinal tissue.

MMPs are a group of zinc-dependent endopeptidases. Although MMPs are vital for ECM homeostasis, they are regulated heavily as a result of their highly proteolytic nature. Furthermore, dysregulated production and activation of MMPs has been shown to contribute to many pathological conditions involving excessive ECM remodelling and ultimately tissue injury (Meijer et al, 2007). We have shown previously an increase in MMPs in gastrointestinal tissue obtained from an animal model of irinotecan-induced mucositis (Al-Dasooqi et al, 2010). Although this is the case, the consequence of this increase on tissue ECM proteins has not yet been studied. Hence, the aim of the present study was to characterise the change in epithelial cell kinetics and investigate the expression of ECM proteins in the jejunum and colon following irinotecan treatment.

Table 1: basement membrane components and their roles in regulating epithelial cell kinetics

<b>ECM component</b>	<b>Spatial expression</b>	<b>Effect on cell kinetics</b>
Collagen IV	Villus	Promote migration
Fibronectin	Highest in crypts & decreasing towards tip of villus	Promote proliferation Inhibit differentiation
Laminin-1 ( $\alpha1\beta1\gamma1$ )	Crypt-villus junction to villus tip	Promote differentiation
Laminin-2 ( $\alpha2\beta1\gamma1$ )	Crypt	Unknown
Tenascin	Highest in villus and decreasing towards crypt	Prevent migration

## 4.2 Materials and Methods

### 4.2.1. *Animal study*

Forty-eight female dark agouti rats weighing 150-170g were used in this study. All experimental procedures were approved by the Animal Ethics Committees of the Institute of Medical and Veterinary Sciences and the University of Adelaide and complied with the National Health and Medical Research Council (Australia) Code of Practice for Animal Care in Research and Training (2004).

Rats were randomly allocated into control (n=6) or experimental groups (n=42). Experimental group rats received 0.01mg/kg subcutaneous atropine in order to reduce cholinergic reaction to irinotecan immediately prior to the administration of a single intraperitoneal dose of 200 mg/kg irinotecan; which has previously been shown to cause gastrointestinal mucositis (Gibson et al, 2007). Irinotecan (kindly supplied by Pfizer, Kalamazoo, USA) was administered in a sorbitol/ lactic acid buffer (45 mg/ml sorbitol /0.9 mg/ml lactic acid, pH 3.4), required for activation of the drug. Rats in the control group did not receive any treatment. Rats were assessed four times daily for morbidity, body weight and diarrhoea. Diarrhoea was graded as: none; mild diarrhoea (staining of anus); moderate diarrhoea (staining top of legs and lower abdomen); severe diarrhoea (staining over legs and higher abdomen as well as continual anal leakage).

Rats were killed at various time-points following irinotecan administration; 1, 6, 24, 48, 72, 96, 144 h, by cardiac puncture and cervical dislocation under 3% isoflurane in 100% Oxygen anaesthesia. The AT was dissected out from the pyloric sphincter to the rectum and flushed with chilled isotonic saline (0.9 w/v) to remove contents. A 1 cm sample of the

small intestine and the colon were taken at approximately 25% and 50% of the lengths, respectively. For histological analysis, samples were fixed in 10% neutral buffered formalin, processed and embedded in paraffin.

#### ***4.2.2 Histological assessment***

Samples of jejunum and colon were collected, processed and stained with haematoxylin and eosin as described in previous studies (Logan et al, 2008; Stringer et al, 2008; Stringer et al, 2009). Sections were examined by light microscopy and analysed by a professional veterinary pathologist for architectural disturbances, presence of degenerative enterocytes and inflammatory cell infiltrate.

#### ***4.2.3 TUNEL for apoptotic cells***

Apoptosis in the jejunum and colon was determined using an *In situ* cell death detection kit (Roche Diagnostics, Indianapolis, USA). Briefly, sections were cut from paraffin blocks at 4µm thickness and mounted onto slides. Sections were dewaxed in xylene and rehydrated through a graded series of alcohols. Sections were immersed in 0.1% TX-100 in 0.1% sodium citrate buffer for 8 minutes at room temperature. Following rinsing, sections were incubated with TUNEL buffer (containing Tris, 0.7M NaCaco, CoCl<sub>2</sub>, 10% BSA in water) for 10 minutes at room temperature. Sections were then incubated with the reaction mixture as specified by the manufacturer's instructions. Subsequently, tissue sections were incubated with anti-fluorescein antibody (labelled with alkaline phosphatase) in a humidified chamber for 1 hour. Apoptotic cells were visualised with precipitating substrate fast red in 0.1M Tris-HCl for 15 minutes at room temperature. Sections were counterstained with Lillie-Mayer's haematoxylin and blued in lithium carbonate before

being mounted in glycerol. Apoptotic cells were viewed by light microscopy. The total number of apoptotic cells was counted in the field of view; which includes 5 crypts.

#### ***4.2.4 Picro-Sirius red staining for collagen***

Sections were cut at 4µm and mounted on glass slides. The sections were dewaxed, rehydrated and stained with Weigert's haematoxylin for 10 minutes before washing in running tap water. Sections were then stained in picro-sirius red solution (0.5g Sirius red F3B in 500ml saturated aqueous picric acid solution) for 1 hour. Sections were washed in two changes of acidified water solution (5ml acetic acid in 1L water). Finally sections were dehydrated in three changes of 100% ethanol, cleared in xylene and mounted in a resinous medium. Sections were viewed under a light microscope. All qualitative assessments were conducted in a blinded fashion by one investigator (NA).

#### ***4.2.5 Masson's trichrome staining***

Sections were cut at 4 µm and mounted on glass slides. The sections were dewaxed, rehydrated and stained in Celestin blue-haematoxylin before differentiating in 1% acid alcohol. Sections were washed in tap water and stained in acid fuchsin solution (0.5 g acid fuchsin and 0.5 ml glacial acetic acid in 100 ml water) for 5 minutes. Slides were rinsed in distilled water before being treated with phosphomolybdic acid solution (1g phosphomolybdic acid in 100 ml water) for 5 minutes. Subsequently, sections were counter-stained in 1% light green in acetic acid for 5 minutes, rinsed in distilled water and treated with 1% acetic acid for 2 minutes. Finally, sections were dehydrated in graded alcohols, cleared in xylene and mounted. Sections were viewed under a light microscope.



#### ***4.2.6 Immunohistochemistry***

Control (n=6) and experimental (n=42) jejunum and colon sections were cut from paraffin blocks at 4 µm thickness and mounted onto silane-coated slides. Sections were dewaxed in xylene and rehydrated through a graded series of alcohols. For collagen IV and Ki67 staining, sections were immersed in 10 mM citrate buffer (pH 6.0) and antigen retrieval performed by heating sections in microwave on High until boiling and on Low for 10 minutes. Antigen retrieval for fibronectin and laminin was performed by enzymatic digestion. Endogenous peroxidase activity subsequently blocked with 3% H<sub>2</sub>O<sub>2</sub> in methanol. Non-specific antibody binding was blocked with 20% normal goat or horse serum (NHS or NGS) (Sigma, St Louis, MO, USA) in PBS for 30 minutes at room temperature (RT). Avidin-Biotin Blocking Kit (Vector Laboratories, Burlingame, CA, USA) was used to block endogenous avidin-biotin activity. Sections were incubated overnight with antibodies (diluted in 5% NGS or NHS) directed at Collagen IV at 1:250 (Abcam, Cambridge, UK), Fibronectin at 1:200 (Abcam, Cambridge, UK), Laminin at 1:1000 (Abcam, Cambridge, UK) and Ki67 at 1:250 (Abcam, Cambridge, UK) diluted in 5% NHS or NGS at 4 °C. Tissue sections were incubated with the appropriate secondary antibody (20 minutes at RT), ABC labelling reagent (30 min at RT) and developed with DAB. Sections were counterstained with Lillie-Mayer's haematoxylin, dehydrated and cleared in xylene before being mounted. Qualitative immunohistochemistry was performed. Staining intensity was graded as follows: 0 no staining, 1 weak staining, 2 moderate staining, 3 strong staining and 4 intense staining. This qualitative staining assessment has been previously validated by published grading systems (Bowen et al, 2005; Yeoh et al, 2005; Logan et al, 2007) and is routinely used within our laboratory. Ki67 staining was assessed by counting stained cells per 20 crypts and averaging out to

obtain the number of stained cells/crypt. All assessments were done in a blinded fashion by one investigator (NA).

#### ***4.2.7 Statistics***

Results were statistically analysed using a Kruskal-Wallis test. P-value cut offs for significance were adjusted to allow for multiple comparison according to the Stepdown Sidak procedure. Results were declared statistically significant at  $p < 0.05/\text{group number}$ .

### **4.3 Results**

#### ***4.3.1 Response to treatment and histological analysis***

As previously reported (Stringer et al, 2007; Logan et al, 2008), rats treated with irinotecan began demonstrating clinical signs of mucositis from 2 hours following irinotecan administration where diarrhoea was observed in 23% of rats. The prevalence of diarrhoea peaked at 24 hours where 39% of rats had mild diarrhoea and 5% had moderate diarrhoea. At 72 h, 33% of treated rats had mild diarrhoea. All diarrhoea was resolved at 144h after irinotecan administration. None of the rats in the control groups developed diarrhoea. Irinotecan-induced death did not occur in this study (Stringer et al, 2007; Logan et al, 2008).

As reported previously, marked histological evidence of mucositis was observed in the jejunum and colon following irinotecan treatment. These changes were evident as early as 6h following treatment and included the presence of degenerative enterocytes within the crypts. This was followed by more gross architectural disturbances at later time points. In the jejunum, these changes included villus blunting, epithelial atrophy and increased intensity of inflammatory cell infiltrate through mucosal tissue. Similar damage was evident in the colon at later time points with focal complete crypt ablation observed at 72h after treatment. Tissue restitution was initiated at 144 h (Stringer et al, 2007; Logan et al, 2008).

#### ***4.3.2 Proliferation and Apoptosis following irinotecan***

The time-course of the effect of irinotecan on cell proliferation and apoptosis are shown in Figures 1 and 2, respectively. Following irinotecan, there was a significant decrease in proliferation in both the jejunum and the colon. Furthermore, the number of positively

stained cells in the proliferative zones of both regions decreased significantly at 6 h following treatment (Figure 1). In the jejunal crypts, this decrease was evident between 6-48 h while in the basal colon this decrease was evident between 6-72 h, indicating a more profound effect of treatment on the colon. In both regions there was a significant increase in the number of proliferative cells at 96 and 144 h above that evident in control, untreated tissue (Figure 1).

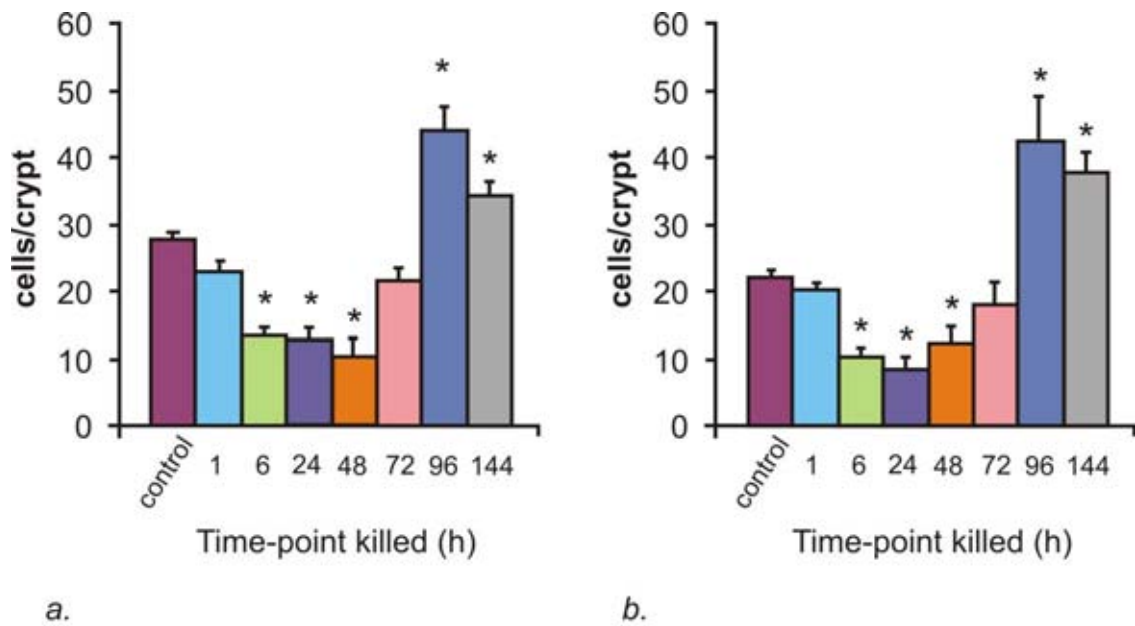


Figure 1: Changes in cell proliferation as indicated by Ki67 immunostaining in the *a.* jejunum and *b.* colon at 1, 6, 24, 48, 72, 96 and 144h following the administration of 200 mg/kg irinotecan intraperitoneally. Cells positively stained for Ki67 were counted in 20 crypts and averaged. The data are mean number of stained cells/crypt + standard error; \* $p < 0.05$ : compared to untreated controls.

A significant change in cell apoptosis was also noted in the jejunum and colon following irinotecan administration (Figure 2). The number of stained cells in control, untreated tissue was 0.64 and 0.81 cells/5 crypts in the jejunum and colon, respectively. There was a significant increase in apoptotic cell numbers at 6 h following irinotecan where 47.4 and 56.2 apoptotic cells/5 crypts were observed in the jejunum and colon, respectively (Figure 2). A certain degree of recovery was indicated at 24-144 h where the number of apoptotic cells decreased but these were still significantly elevated in comparison to control tissue (Figure 2).

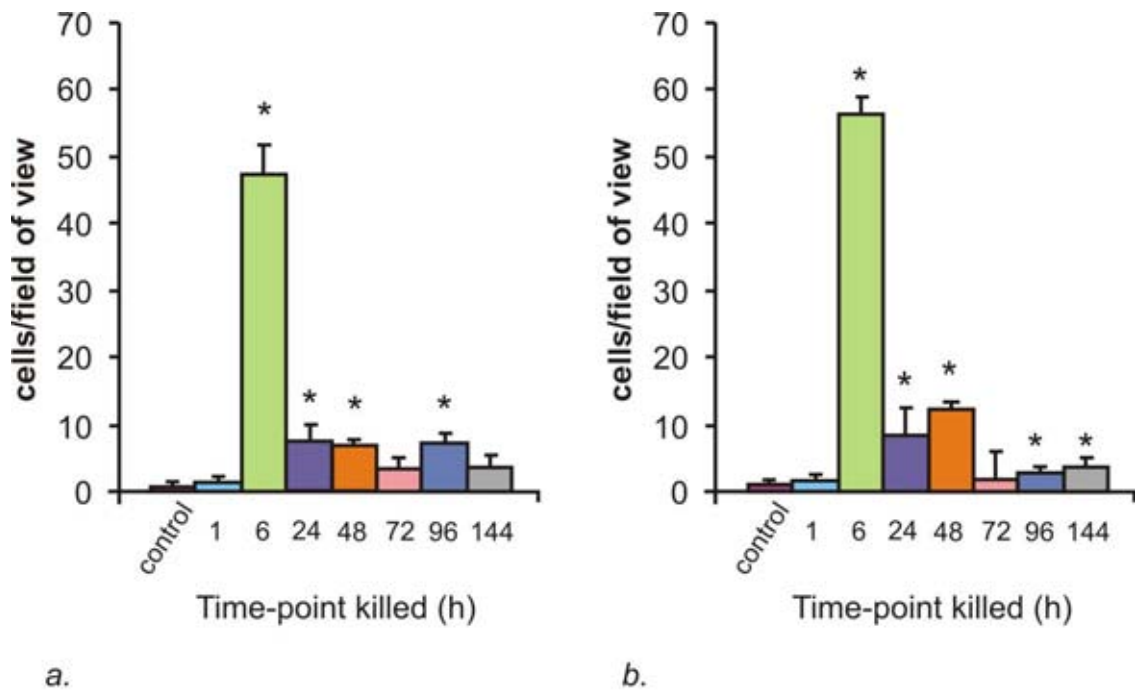


Figure 2: Changes in cell apoptosis as identified by TUNEL assay in the *a.* jejunum and *b.* colon at 1, 6, 24, 48, 72, 96 and 144h following the administration of 200 mg/kg irinotecan intraperitoneally. The data are mean number of stained cells/field of view + standard error; \* $p < 0.05$ : compared to untreated controls.

### ***4.3.3 Collagen fibres and basement membrane collagen following irinotecan***

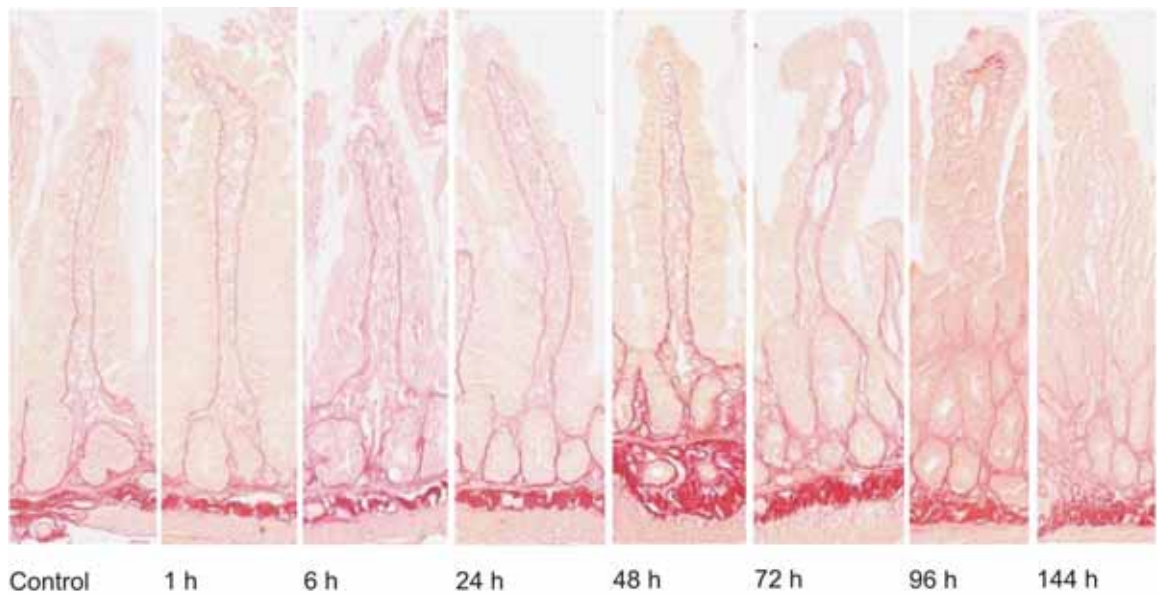
Picro-sirius red and masson trichrome staining were used to illustrate collagen deposits in jejunum and colon samples (Figure 3 & 4).

*Jejunum.* In this region, control untreated tissue showed a distinct presence of collagen in the basement membrane with moderate staining surrounding the crypts and intense staining in the submucosa (Figure 3a & 4a). From 1-24 h following irinotecan, a thicker, moderate staining was noted in the basement membrane underneath the villi and crypts. There was also an increase in collagen staining in the lamina propria and serosa. Between 48-72 h, the basement membrane underlying the crypts stained more intensely (moderate-intense) and an increase in staining was noted underneath the villi as compared to earlier time-points (Figure 3a & 4a). An increase in submucosal staining was also illustrated. In the healing phase of mucositis (96-144 h), no/very weak collagen staining was observed under the epithelial layer and a decrease in staining was noted under the crypts as compared to 48 and 72 h (Figure 3a & 4a). Submucosal, muscle and serosa staining were not altered at these later time-points. Collagen staining under the crypts returned to basal level by 144 h (Figure 3a & 4a).

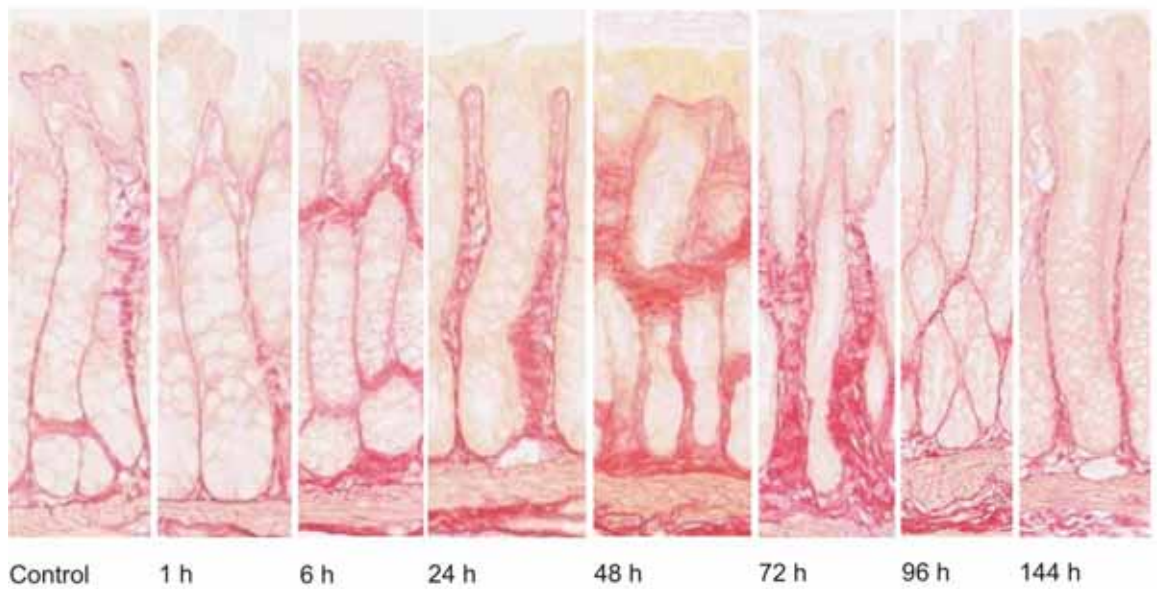
*Colon.* Similar expression patterns were noted for collagen in the colon. Collagen expression was uniformly moderate along the entire crypt in control, untreated tissue (Figure 3b & 4b). A gradual increase in collagen deposits was noted from 6 h through to 48 h after chemotherapy. At 48 h, thick collagen deposits seemed to appear in the submucosa around the base of the crypts and also along the apical region (Figure 3b & 4b). However at 72 h, this thick deposit decreased in the apical region and was localised around the base



of crypts. A thinning in the basement membrane underlying the apical region of the colon was also noted at this time-point. Between 96-144 h, submucosal collagen content returned to that of untreated tissue (Figure 3b & 4b). However, a significant thinning in the basement membrane was noted in the apical region which was below the basal level expression for collagen in untreated controls (Figure 3b & 4b).

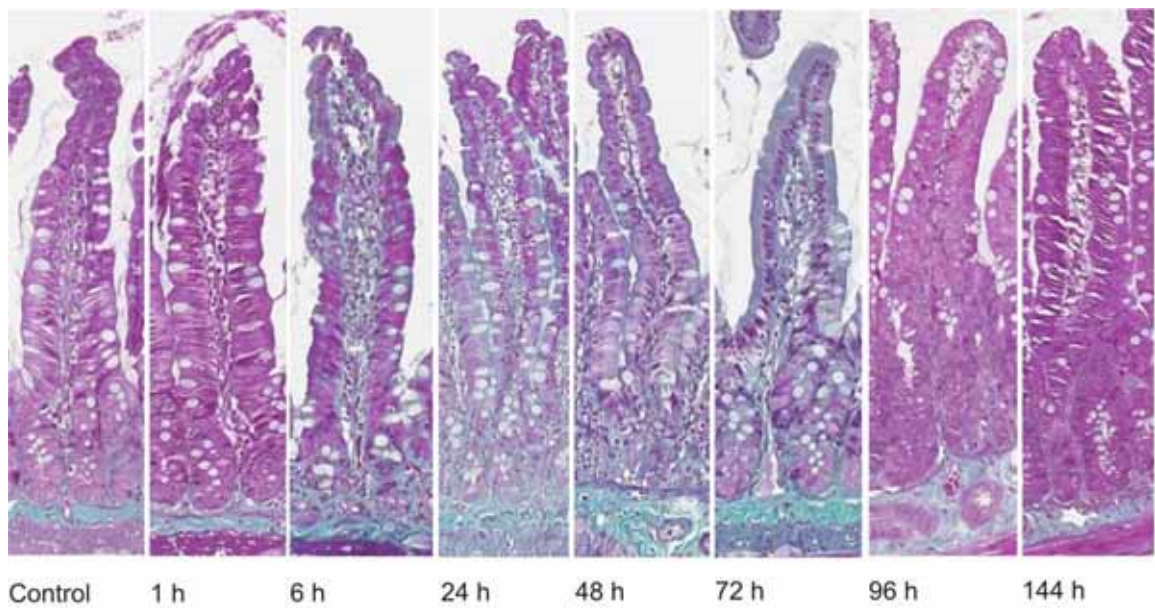


**a)**

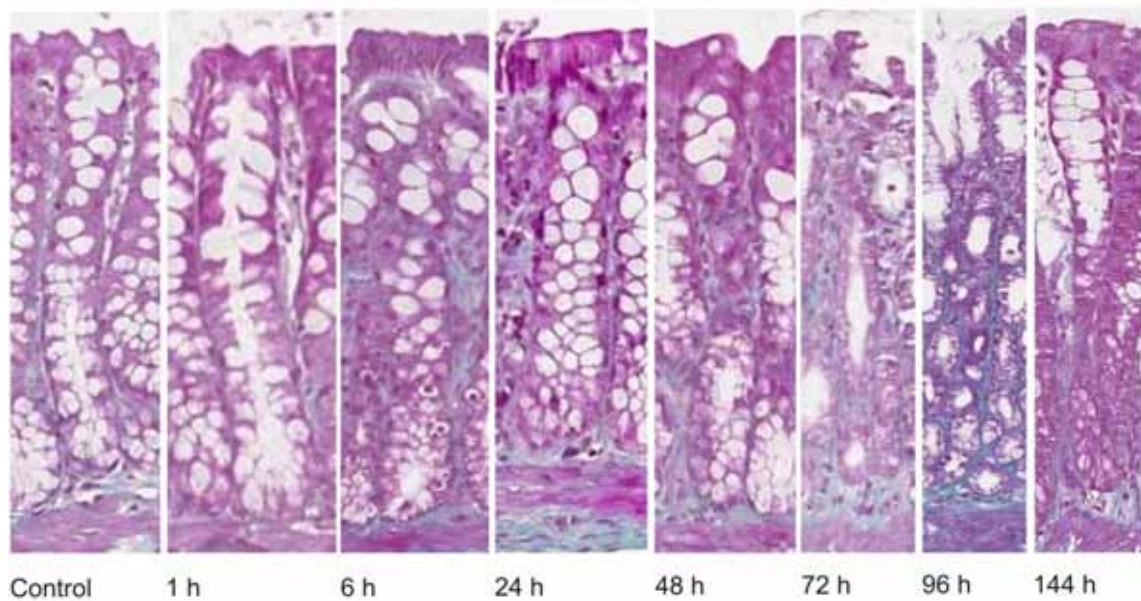


**b)**

Figure 3: Pico-sirius red staining demonstrating collagen in the a) jejunum and b) colon in a time-course model of irinotecan-induced mucositis. Staining demonstrates collagen including the finest fibres and basement membranes, in red on a yellow background. Photomicrographs taken at 20x objective.



**a)**



**b)**

Figure 4: Masson trichrome staining demonstrating fibrous collagen in the a) jejunum and b) colon in a time-course model of irinotecan-induced mucositis. Fibrous collagen is stained green on a purple background. Photomicrographs taken at 20x objective.

#### ***4.3.4 The expression of extracellular matrix proteins following irinotecan***

*Jejunum.* The expression of three extracellular components was determined following irinotecan treatment. In this region, collagen IV levels decreased significantly at the later time points of 96 and 144 h following treatment in the crypts ( $p < 0.05$ ). This decrease in intensity was from moderate staining in control, untreated tissue to very weak at the later time points (Figure 5). Fibronectin expression was also investigated. In control, untreated tissue, fibronectin was expressed moderately. A decrease in expression was noted at 6-24 h following treatment in the basement membrane and submucosa underlying the villi but not the crypts, although this was not statistically significant (Figure 5). Laminin 1 and 2 levels were also investigated however, there was no change in expression throughout the time-course (Figure 5).

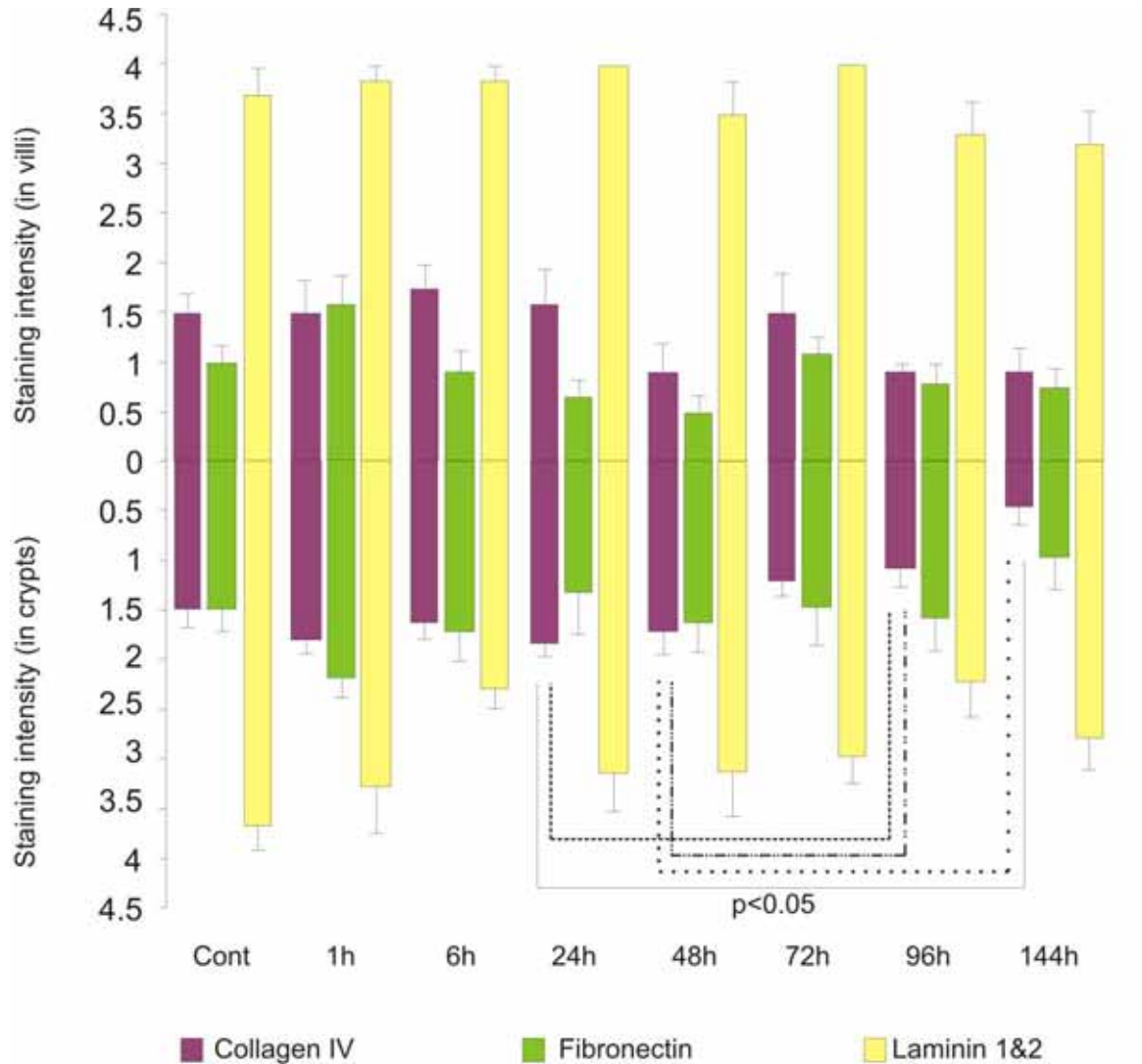


Figure 5: Extracellular matrix component staining in the jejunum. Top bars illustrate staining in villi while bottom bars illustrate staining in crypts at 1, 6, 24, 48, 72, 96 and 144h following the administration of 200mg/kg irinotecan intraperitoneally. All control and experimental tissue were graded by a qualitative scale. The data are means + standard error; significance indicated on the graph.

*Colon.* In this region, there was no change in collagen IV or laminin 1 and 2 expression throughout the time-course (Figure 6). However, fibronectin levels significantly decreased at 6 h following treatment in comparison to the untreated, control tissue ( $p < 0.05$ ). Furthermore, this change was noted in the basement membrane and submucosa underlying the basal colon only. Fibronectin expression was restored to normal from 24 h following irinotecan onwards (Figure 6).

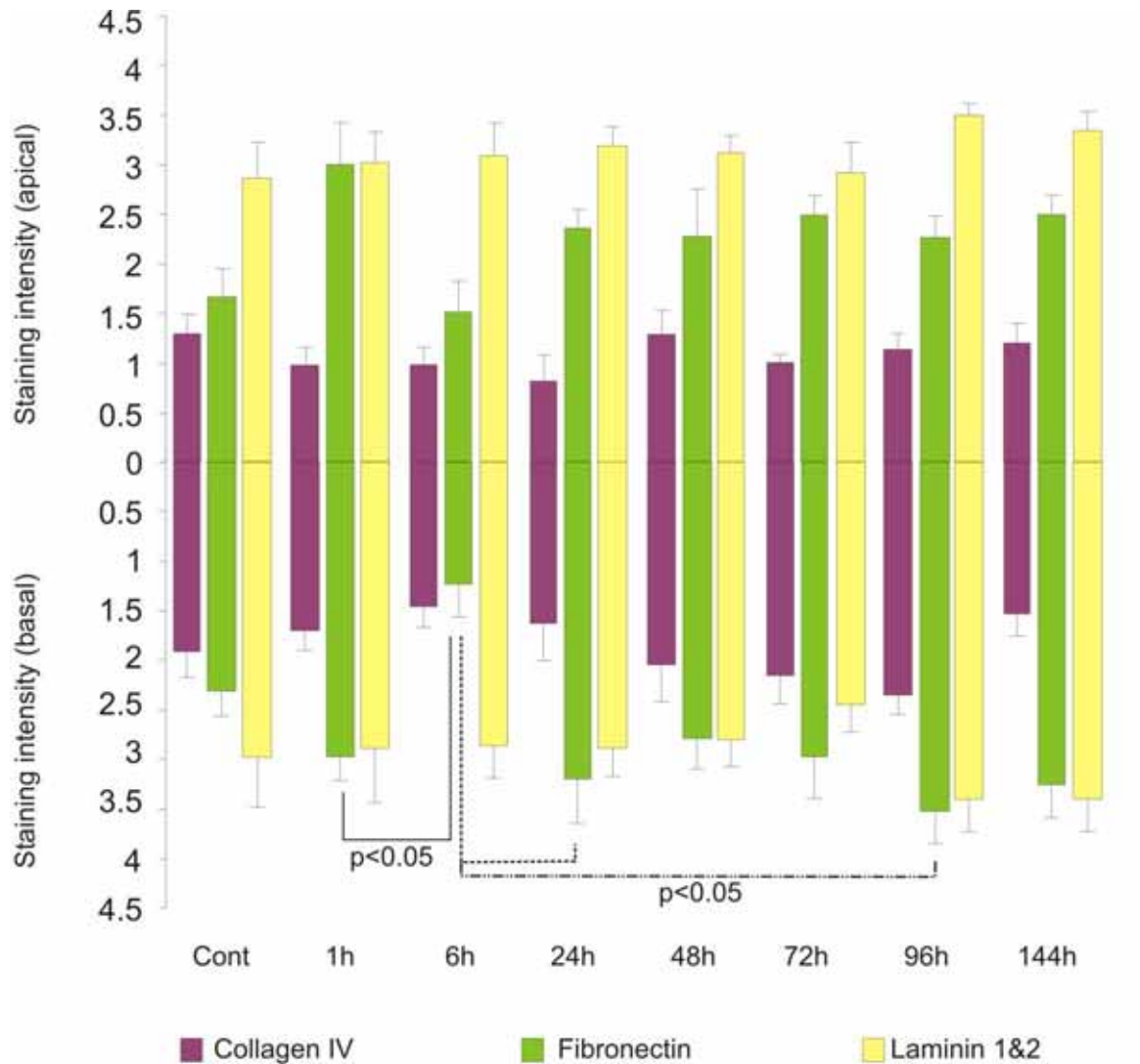


Figure 6: Extracellular matrix component staining in the colon. Top bars illustrate staining in the apical colon while bottom bars illustrate staining in the basal colon at 1, 6, 24, 48, 72, 96 and 144h following the administration of 200mg/kg irinotecan intraperitoneally. All control and experimental tissue were graded by a qualitative scale. The data are means + standard error; significance indicated on the graph.

#### 4.4 Discussion

It has been previously demonstrated that administration of irinotecan causes gross histopathological changes throughout the AT consistent with mucositis development (Gibson et al, 2003; Logan et al, 2008). Although many morphological studies have been carried out, the changes in ECM proteins and their subsequent effect on cell kinetics has not been well characterised to date. Key findings from the present study indicate a substantial augmentation in cell kinetics, in particular cell proliferation and apoptosis, in response to irinotecan. Furthermore, this is accompanied by an increase in collagen deposits during the period of maximal damage. This study has also demonstrated that fibronectin may be a key player in the damage event evident following irinotecan.

The main mechanism by which chemotherapeutic drugs, such as irinotecan, induce their anti-tumour activity is by causing direct DNA damage to ultimately alter tumour cell kinetics (Ma et al, 2003). However, in the healthy AT irinotecan causes mucositis by inducing both DNA as well as non-DNA damage. Through inhibiting DNA topoisomerase I, irinotecan is capable of halting DNA replication and causing DNA strand breaks resulting in altered epithelial cell kinetics (Gibson et al., 2007). However, the majority of the initiation phase events for mucositis are due to non-DNA damage; which encompasses a cascade of biological events. Reactive oxygen species (ROS) have been shown to be a primary initiating factor for these events as a result of their broad downstream signalling (Sonis 2004). Some of the signalling pathways induced by ROS are NF $\kappa$ B signalling, Wnt/B-catenin signalling, MAPK signalling and integrin signalling and these affect many tissue structures, such as the extracellular matrix, hence causing tissue damage (Sonis 2004; Sonis 2004).



In the AT, the ECM is vital for maintenance of normal tissue morphology and wound healing. At the cellular level, it has been previously shown that the ability of stem cells to remain anchored at the base of the crypts or daughter cells to move away from this position, results from increased or decreased affinity to ECM components (Potten *et al*, 1997). Alteration of the affinity of ECM molecules to the cell occurs through spatial changes in expression of ECM molecules or their cellular receptors. Hence, ECM components have been shown to play a key role in regulating cell behaviours including proliferation, migration, apoptosis and differentiation. We have shown in this study that there was a significant alteration in collagen deposits in the jejunum and colon following irinotecan. Specifically, an increase in collagen deposits was noted in the basement membranes and the underlying submucosal region 48-72 h following irinotecan. This increase could serve two purposes; 1- to provide overlying tissue with sufficient structural integrity and strength especially following injury (Orberg et al, 1982) and 2- to allow cells to move up along the crypt-villus axis following primary tissue injury. Gibson and colleagues (2003) illustrated an increase in crypt length and a decrease in villus area 72-96 h following irinotecan administration in rats (Gibson et al, 2003). Furthermore, an extension in the mesenchyme has also been noted following chemotherapy treatment as indicated by Ki67 staining in this study and the work of others (Gibson et al, 2003; Koning et al, 2007). The anti-adhesive function of collagen on epithelial cell migration is well documented (Potten et al, 1990; Yurchenco et al, 1990; Gibson et al, 2003; Koning et al, 2007). In the context of this study, an increase in collagen may play a role in the process of intestinal and colonic cell migration along the crypt axis following the injury induced by irinotecan in an attempt to repopulate the villi.

This study also showed a decrease in collagen, specifically type IV collagen, late following irinotecan (96-144h). Collagen IV is a unique member of the large collagen family as it is occurs only in basement membranes. In addition to providing a scaffold for assembly and mechanical stability, collagen IV is also a vital component in interaction of cells with the underlying basement membrane (Kuhn 1994). Cell culture studies have shown that collagen IV is the binding substrate for a large number of cell types (Khoshnoodi et al). In the gut, collagen IV forms a three-dimensional network in order to provide binding sites for glycoproteins and soluble growth factors, which act as modulators of cell activity (Kuhn 1994; Groos et al, 2003). In the intestine, Potten and colleagues (1997) have suggested a role for collagen IV in cell migration along the villi. In the present study, we have shown that collagen IV expression decreased at 96 and 144 h following irinotecan treatment in jejunal crypts and villi. The expression of this ECM component is tightly regulated specifically by gelatinaseA (MMP2). Previous research within our laboratory has demonstrated the largest increase in MMP2 tissue levels occurs during the healing phase of mucositis (ie 96-144 h following irinotecan treatment) (Al-Dasooqi et al, 2010). This is possibly due to the anti-adhesive properties of collagen IV no longer being required for migration of cells and extension of crypts at these time points. However, even though tissues may appear normal at these later time-points, it is important to note that a dysregulated structure is still present as shown here.

Another key finding in this study is the decrease in fibronectin expression noted in the jejunum as well as the colon 6-24 h following irinotecan. This is consistent with significant cell death and a decrease in proliferative activity of cells during these time-points in both regions. As previously indicated by Potten (1997), fibronectin has adhesive properties and

is hence a key player in the control of proliferation and differentiation. Fibronectin carries out this role by binding to specific integrin receptors in the basement membrane in a process known as fibrillogenesis. This process encompasses the formation of specialised ECM-cell contact structures known as fibrillar adhesion points through which fibronectin-mediated signalling is initiated (Gagne et al, 2010). Gagne and colleagues (2010) illustrated the effects of fibronectin on cell kinetics of human intestinal epithelial cells. They concluded that the presence of this ECM component is vital for regulating migration and proliferation of these cells through activation of the PINCH-ILK-parvin (PIP) complex; which is vital for control of key regulatory cell-cycle progression elements including cyclin D1, p27 and hypophosphorylated pRb (Gagne et al, 2010). Hence, a decrease in fibronectin expression or its receptors could deregulate the balance of proliferation and migration hence jeopardising mucosal integrity and the restitution of intestinal tissue following irinotecan.

#### **4.5 Conclusions:**

In conclusion, this study has provided evidence of alteration in subepithelial components which are important in maintaining tissue structure and homeostasis. This suggests treatment aimed at maintaining extracellular tissue compartments may be an effective intervention for irinotecan-induced intestinal injury.

#### **4.6 Acknowledgements**

Noor Al-Dasooqi was supported by an Australian Postgraduate Award and a GlaxoSmithKline Postgraduate Support Grant; Dr. Rachel J Gibson was supported by a Cancer Council Post-Doctoral Fellowship and received funding from Cure Cancer and Cancer Australia; Dr. Joanne M Bowen was supported by a Postdoctoral Research Fellowship from the National Health and Medical Research Council; Dr Andrea M Stringer was supported by NHMRC Postgraduate Training Scholarship; Professor Dorothy Keefe is the Cancer Council South Australia Chair of Cancer Medicine. Assistance with the statistical analysis for this study was provided by Mr Thomas Sullivan from the Department of Public Health, The University of Adelaide. The authors also acknowledge Ms Gail Hermanis, Discipline of Anatomy and Pathology, The University of Adelaide for performing the histological techniques.

## **5.0 Pilot study of circulating matrix metalloproteinases as potential biomarkers of chemotherapy-induced gastrointestinal toxicity**

### **5.1 Introduction**

Chemotherapy-induced AT mucositis presents a major oncological problem. Clinically, mucositis is characterised by ulceration, nausea and vomiting, bloating, diarrhoea and constipation (Keefe et al., 2007). Furthermore, it is estimated that 40% of patients receiving standard dose chemotherapy and 100% of patients receiving high dose chemotherapy experience this debilitating condition (Sonis et al., 2004; Keefe et al., 2007). Although highly prevalent, there are currently no diagnostic biomarkers for mucositis and the only method by which it can be diagnosed is through assessment of symptoms according to clinical mucositis grading scales. However to date, there is no established scale that is universally accepted or meets all the criteria a clinical mucositis scoring system should achieve (Sonis et al., 2004). Furthermore, accurate evaluation of mucositis development is made impossible due to the difficulty of obtaining sequential biopsies before, during and after treatment and the inaccessibility of important segments of the AT (Sonis et al., 2004). This has great implications when conducting clinical evaluation of mucositis interventions; where accurate evaluation of mucositis is required.

Although the pathobiology of mucositis is complex, much progress has been made in recent years in terms of our understanding of the pathological (Gibson et al., 2005; Logan et al., 2008) and signalling alterations (Sonis et al., 2002; Bowen et al., 2007; Bowen et al.,

2007) occurring in the AT subsequent to chemotherapy treatment. Briefly, these include clonogenic cell death (Keefe, 2000; Paris et al., 2001; Gibson et al., 2003), the induction of inflammatory responses (Yeoh et al., 2005; Manzano et al., 2007; Logan et al., 2008; Logan et al., 2009), changes in the gut microbiome (Stringer et al., 2007; Stringer et al., 2009; Stringer et al., 2009) and activation of submucosal signalling and damage of submucosal structures (Paris et al., 2001). The gene expression changes which occur in the gut following chemotherapy treatment have also been investigated. The pathways that govern mucositis development include mitogen activated protein kinase (MAPK) signalling, nuclear factor  $\kappa$ B (NF $\kappa$ B) signalling, Fos/Jun signalling and Wnt signalling (Bowen et al., 2007; Bowen et al., 2007). Furthermore, the downstream mediators of this damage include cytokines, matrix metalloproteinases, ceramide and cyclooxygenase-2 (Yeoh et al., 2005; Logan et al., 2008; Al-Dasooqi et al., 2010).

Matrix metalloproteinases (MMPs) are a group of zinc-dependent endopeptidases which participate in extracellular matrix turnover (Stamenkovic, 2003; Pender et al., 2004; Page-McCaw et al., 2007). Recent research within our laboratory has identified these proteases as major mediators of chemotherapy-induced gut damage in rats (Al-Dasooqi et al., 2010). Hence, MMPs can be used as tissue-specific markers of gut injury following chemotherapy. However, it is not known whether these changes in MMPs are translated systemically and hence whether or not they could be useful in identifying impending toxicity. This small pilot study aims to investigate the potential of MMPs as systemic biomarkers to reflect the development of gut toxicity in patients receiving chemotherapy regimens containing 5-fluorouracil, capecitabine or irinotecan.

## **5.2 Methods**

### ***5.2.1 Patient cohort***

Patients scheduled to receive anti-cancer regimens containing 5-fluorouracil, capecitabine or irinotecan were recruited from a single institution during 2009 (Table 1). Patients were excluded if they were receiving concurrent radiotherapy. None of the patients presented with conditions associated with a known increase in serum MMPs (including rheumatoid arthritis, pulmonary fibrosis and liver cirrhosis). Stool and blood samples were collected before a chemotherapy cycle commenced, and on days 2, 5, and 10 of one chemotherapy cycle. Stool samples were used for determination of Calprotectin levels. Blood samples were used for serum collection for determination of circulating MMPs.

Five healthy, cancer-naive, control subjects were also enrolled in this study as cancer patients are known to have elevated serum MMP levels (Lukaszewicz-Zajac et al., 2009; Daniele et al., 2010; Motovali-Bashi et al., 2010; Stankovic et al., 2010).

This study was approved by the Human Research Ethics Committee of the Royal Adelaide Hospital and was carried out in accordance with the Declaration of Helsinki.

### ***5.2.2 Analysis of medical records***

To identify the toxicities associated with anti-cancer regimens, patient case-note reviews were undertaken. The toxicities to record were as identified by the National Cancer Institute common gastrointestinal tract (GIT) toxicity criteria following anti-cancer treatment. These included oral symptoms, stomatitis, nausea and vomiting, diarrhoea, constipation, abdominal pain and bloating.



### ***5.2.3 Sample preparation for enzyme-linked immunosorbent assay (ELISA) detection of fecal calprotectin***

Upon collection, stool samples were frozen and stored at -80 °C until use. Samples were extracted by adding 5 mls of extraction buffer (containing 0.1 M Tris, 0.15 M NaCl, 1.0 M urea, 10 mM CaCl<sub>2</sub>, 0.1 M citric acid monohydrate 5 g/l BSA and 0.25 mM thimerosal at pH 8.0) to 100 mg of sample before being vortexed and filtered. Filtrates were centrifuged at 10,000 xg at 4 °C for 20 minutes. The supernatant was used for analysis. Calprotectin levels were determined using a human calprotectin ELISA kit (Hycult Biotechnology, Netherlands) according to the manufacturer's instructions (catalog number HK325). All samples were tested in duplicates.

### ***5.2.4 Sample preparation for enzyme-linked immunosorbent assay (ELISA) detection of serum MMP-2, -3 and -9***

Whole blood samples were drawn from controls and patients receiving anti-cancer treatment at various time-points during one chemotherapy cycle. Serum samples were separated by centrifugation and stored at -80 °C until use. Serum levels of MMP-2, -3 and -9 were measured using quantikine immunoassay ELISA kits specific to the MMP of interest (RnD Systems, MN, USA) according to the manufacturer's instructions (Catalog numbers DMP2F0, DMP300, DMP900). All samples were tested in duplicates.

### ***5.2.5 Statistics***

Repeated measures analyses were applied to analyse the changes over time in MMP-2, -3 and -9 levels. This utilised a linear mixed effects model where time was included as a categorical predictor (fixed effect), while patient was included as a random effect. The

significance level was set at  $p < 0.05$ . Correlations between changes in serum MMPs and GI toxicity was also investigated using a Fisher Exact test. All analyses were performed using SAS Version 9.2 (SAS Institute Inc., Cary, NC, USA).

### 5.3 Results

#### 5.3.1 Patient characteristics

Eight patients were recruited for this pilot study. Patients had a mean age of 62 years (40-77). Patients were scheduled to receive a range of treatment regimens including FOLFOX4, FOLFOX6, FOLFIRI or capecitabine for breast as well as various gastrointestinal tumours (Table 1). Patients and healthy controls were not age-matched and hence no comparisons have been made. Results from healthy controls were included only to demonstrate that patients with cancer have altered MMP levels. This is recognised as a flaw in the study and any future larger scale studies will need to have age-matched controls.

Table 1: Characteristics of the patient group

Patient	Gender	Age	Diagnosis	Treatment	Cycle	GI Toxicity
1	F	60	Infiltrating ductal carcinoma	FOLFOX4	1	Yes
2	M	65	Rectal Carcinoma	FOLFIRI	1	Yes
3	M	77	Descending colon cancer	FOLFIRI	6	Yes
4	M	62	Metastatic colorectal	FOLFOX6	4	No
5	M	40	Metastatic colorectal	FOLFOX4	6	Yes
6	M	72	Rectal Carcinoma	FOLFIRI	1	No
7	M	51	Metastatic colorectal	FOLFOX4	6	No
8	M	71	Metastatic colorectal	Capecitabine	3	No
Control	Gender	Age				
1	F	25	Cancer naive, No chemotherapy			
2	F	30	Cancer naive, No chemotherapy			
3	F	25	Cancer naive, No chemotherapy			
4	F	29	Cancer naive, No chemotherapy			
5	M	23	Cancer naive, No chemotherapy			

### ***Toxicities induced following cytotoxic chemotherapy***

The most prevalent gastrointestinal toxicities were nausea and vomiting (3/8 patients- 37.5%) and diarrhoea (3/8 patients- 37.5%). Oral tenderness was also reported by one patient (12.5%).

### ***5.3.2 Fecal levels of calprotectin***

Fecal calprotectin levels in healthy, cancer-naive, control subjects were found to be  $1.82 \pm 0.94$  ng/ml. In patients with gastrointestinal cancers, fecal calprotectin was significantly increased in comparison to healthy controls ( $10.98 \pm 1.69$  vs  $1.82 \pm 0.94$ ,  $p < 0.05$ ). Calprotectin levels remained significantly elevated compared to healthy controls at 2, 5 and 10 days following treatment (data not shown). However, there was no significant change in calprotectin levels pre- and post-treatment (data not shown) indicating the difficulty of using calprotectin as a mucosal injury marker in patients with gastrointestinal cancers (Loitsch et al., 2008).

### ***5.3.3 Serum levels of MMP-2, -3 and -9***

***MMP-2.*** The change in MMP-2 levels over time was assessed using a linear mixed effects model. According to this model, there was no significant difference in mean MMP-2 levels across the three post-treatment time points in comparison to the pre-treatment serum levels ( $p = 0.64$ ) (Figure 1, Table 2).

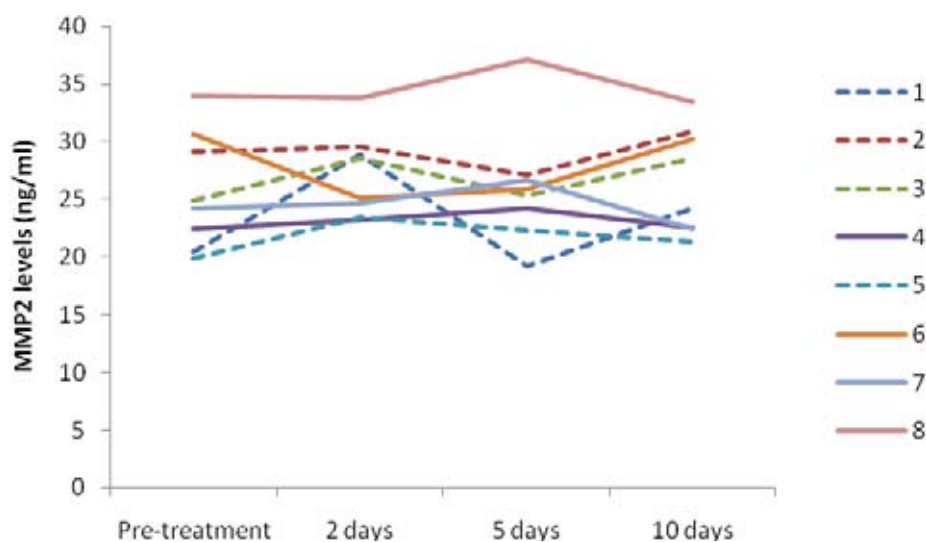


Figure 1: Changes in serum levels of MMP-2 pre- and post-treatment (2, 5, and 10 days). Series indicate patient number (1-8). Dashed line indicates that patient experienced GI toxicity in response to treatment. There was no significant difference detected in serum levels of MMP-2.

Table 2: Mean changes in serum MMP-2 levels (ng/ml) post treatment.

	Healthy control	Pre-treatment	2 days	5 days	10 days
<b>MMP-2</b>	18.38	25.6961	27.12806	28.54081	26.68544

*MMP-3*. A significant change in mean MMP-3 levels was noted in serum of patients post-chemotherapy treatment ( $p=0.0002$ ) (Figure 2, Table 3). Pre-treatment MMP-3 levels were measured to be 0.3 ng/ml. MMP-3 levels were significantly increased at 2 and 5 days post-treatment in comparison to pre-treatment. At 2 days following treatment MMP-3 levels increased to 1.74 ng/ml ( $p=0.0001$ ). At 5 days, circulating MMP-3 levels were 1.03 ng/ml ( $p=0.01$ ). MMP-3 levels returned to pre-treatment levels even at 10 days following treatment (MMP-3= 0.48 ng/ml).

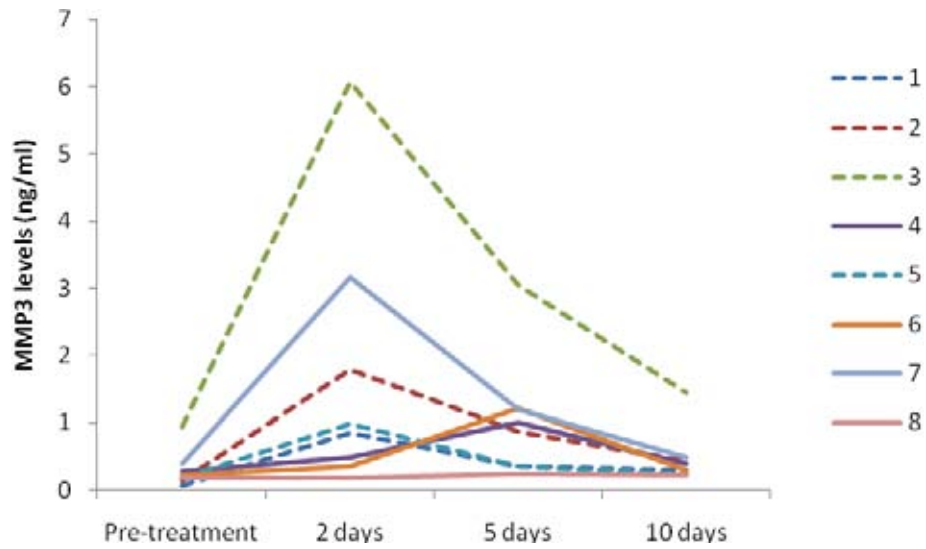


Figure 2: Changes in serum levels of MMP-3 pre- and post-treatment (2, 5, and 10 days). Series indicate patient number (1-8). Dashed line indicates that patient experienced GI toxicity in response to treatment. Overall there was a significant increase in MMP-3 following chemotherapy.

Table 3: Mean changes in serum MMP-3 levels (ng/ml) post treatment.

	Healthy control	Pre-treatment	2 days	5 days	10 days
<b>MMP-3</b>	0.1345	0.30325	1.740125*	1.035688**	0.479938

\*p=0.0001, \*\*p=0.01

*MMP-9*. A significant change in mean MMP-9 levels was noted in serum of patients post-chemotherapy treatment ( $p=0.02$ ) (Figure 3, Table 4). Pre-treatment MMP-9 levels were measured to be 6 ng/ml. MMP-9 levels were significantly increased at 2 days post-treatment. At 2 days following treatment, MMP-9 levels significantly increased to 11.30 ng/ml ( $p=0.02$ ). There was no significant change in MMP-9 at 5 and 10 days post-treatment in comparison to pre-treatment sample.



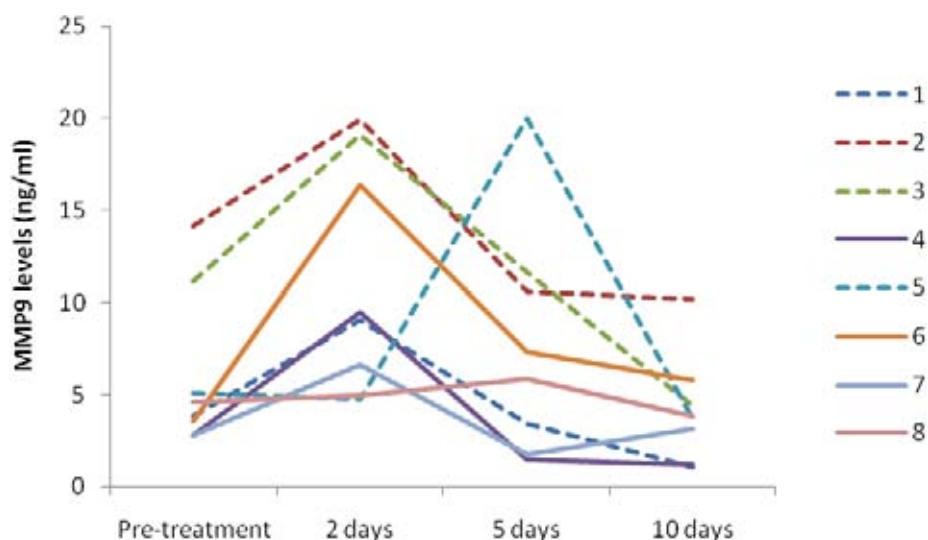


Figure 3: Changes in serum levels of MMP-9 pre- and post-treatment (2, 5, and 10 days). Series indicate patient number (1-8). Dashed line indicates that patient experienced GI toxicity in response to treatment.

Table 4: Mean changes in serum MMP-9 levels (ng/ml) post treatment.

	Healthy control	Pre-treatment	2 days	5 days	10 days
<b>MMP-9</b>	9.487	6.00694	11.2975*	7.770438	4.168313

\*p=0.02

*5.3.4 Association between serum MMPs and GI toxicity in patients*

The association between circulating MMP levels and manifestation of GI toxicity was investigated. The Fisher Exact test was used to indicate significant association. There was no significant association ( $p>0.05$ ) between MMP-2, -3 or -9 levels and the observation of GI toxicity.

#### **5.4 Discussion**

The current pilot study investigated the potential of MMPs as systemic biomarkers of gut toxicity in a small number of patients receiving chemotherapy regimens containing 5-fluorouracil, capecitabine or irinotecan. Key findings from this pilot study indicated a change in circulating MMP-3 and MMP-9 following chemotherapy treatment. Correlative analyses indicated no significant association between MMP levels following treatment and the occurrence of GI toxicity.

Mucositis remains a major oncological problem. It affects 40% of patients receiving standard dose chemotherapy and 100% of patients receiving high dose chemotherapy (Keefe et al., 2007). However, there is currently no prophylactic intervention available for this condition (Keefe et al., 2007). Furthermore, there are no validated grading systems for the assessment of mucositis development in patients (Sonis et al., 2004). This has prompted the need for the identification of a biomarker of gut toxicity in response to cytotoxic anti-cancer treatment. To date, a wide range of biomarkers have been investigated in relation to gut toxicity including citrulline, calprotectin and the proinflammatory cytokines (Roseth, 2003; Lutgens et al., 2005; Logan et al., 2008). Findings from such studies have highlighted the difficulties in identifying a biomarker for mucositis. This is due to 1) our lack of understanding its pathobiology and 2) the fact that mucositis is multifactorial, often arising from a combination of pathologies.

Although pilot in nature, the present study has demonstrated an increase in circulating MMP-3 and MMP-9 levels following chemotherapy treatment. Past studies have demonstrated that MMPs play a key role in the pathogenesis of mucositis (Al-Dasooqi et

al., 2009; Al-Dasooqi et al., 2010). Hence, it is plausible to suggest that an increase in circulating MMPs may potentially serve as an excellent marker of the inflammatory response induced by chemotherapeutic agents. To date, no studies have been conducted to explore whether tissue changes in MMP levels are translated systemically. Although an increase in serum MMPs was noted in this study, no association was found between MMP levels and the observation of GI toxicity. These findings suggest that 1) there is an inflammatory response after treatment which is not confined to the gastrointestinal tract or 2) the symptoms reported following treatment are a poor indicator of underlying pathology (Gibson et al., 2011). The latter is a more plausible explanation for the lack of association observed in this small study. Confirmation of these findings in a larger patient cohort is now required as biomarker studies require adequate sample size calculation above all else in order to rule out false negative or false positive results.

Past studies have illustrated the complexity of mucositis pathogenesis and emphasised the importance of assaying a combination of biomarkers rather than just one when assessing mucositis (Gibson et al., 2011). Furthermore, Lutgens and colleagues (2005) have identified two criteria for a biomarker of gastrointestinal toxicity which are 1) that it is easily accessible to clinicians and 2) that it must work independently of each patient's medication and metabolic activities such as individual diets and nutrition (Lutgens et al., 2005). The latter of these criteria means that any one biomarker would require extensive validation for us to be able to make an association with gut injury as not all physiological changes occurring after cytotoxic treatment are reflective of tissue damage (Gibson & Bowen, 2011). In the present study, patients were on various treatment regimens, at different cycle numbers and not controlled for age or gender. All of these factors are

crucial when investigating the relation between pathological and physiological responses. Hence, larger, multi-institutional studies are now required to follow-up on these preliminary findings.

### **5.5 Conclusions**

Preliminary findings from this study suggest that MMP-3 and MMP-9 are potential biomarkers of gastrointestinal toxicity induced by 5-fluorouracil, capecitabine or irinotecan. Larger prospective studies are required to determine if biomarker levels correlate with pathology. Confirmation of these findings in a larger cohort would aid in the diagnosis of mucositis development and aid in the clinical evaluation of mucositis interventions.

## **5.6 Acknowledgments**

Noor Al-Dasooqi was supported by an Australian Postgraduate Award and a GlaxoSmithKline Postgraduate Support Grant; Dr. Rachel J Gibson was supported by a Cancer Council Post-Doctoral Fellowship and received funding from Cure Cancer and Cancer Australia; Dr. Joanne M Bowen was supported by a Postdoctoral Research Fellowship from the National Health and Medical Research Council; Dr Andrea M Stringer was supported by NHMRC Postgraduate Training Scholarship; Professor Dorothy Keefe is the Cancer Council SA Chair of Cancer Medicine.

## **6.0 General Discussion**

### **6.1 Introduction**

Mucositis is recognised as a major clinical problem; however the mechanisms underlying this condition remain incompletely understood. Previous studies have described to some extent the histology, ultrastructural and protein changes which lead to mucositis (Keefe, 2000; Gibson et al., 2003; Gibson et al., 2005; Logan et al., 2008); however much of the molecular mechanisms of this condition remain unknown. The studies conducted as part of this thesis utilised an established animal model to characterise the expression of matrix metalloproteinases and extracellular matrix components in an attempt to elucidate the role of tissue remodelling in the development of mucositis. Furthermore, a small pilot study was also carried out in the clinical setting to investigate the appropriateness of matrix metalloproteinases as biomarkers of chemotherapy-induced mucositis development.

### **6.2 Chemotherapy-induced mucositis**

Mucositis refers to the damage caused by anti-cancer therapies to mucous membranes of the alimentary tract (AT). It has been shown that epithelial atrophy, breakage and ulceration occur in the AT following chemotherapy (Keefe, 2004; Sonis, 2004). This causes pain and ulceration, vomiting, bloating and diarrhoea, depending on the area of the AT affected. Although treatment is available for a small subset of patients suffering from mucositis, the majority rely on pain relief as their only treatment option. Furthermore, there is currently limited non-invasive tests determination of mucositis development (such as breath tests and sugar permeability tests; which have problems with sensitivity). Histopathological data is the current gold standard for mucositis, which can only be



obtained invasively. Better understanding of the pathobiology of chemotherapy- induced mucositis is required in order to diagnose the development of this condition and target appropriate treatment strategies.

Much progress has been made in recent years in understanding the pathobiology underlying the development of mucositis. Past studies have focused on oral mucositis in response to radiotherapy (Paris et al., 2001; Sonis et al., 2002; Sonis, 2007). Specifically, the pioneering research of Sonis and colleagues in this area has led to the development of the 5-phase model of mucositis development (Sonis, 2004; Sonis, 2004; Sonis, 2007). Briefly, this hypothesis proposes that there are five biological phases of mucositis; describing the histopathological alterations and implicating a variety of signalling pathways in the development of this condition (Sonis, 2004; Sonis, 2007). Much of the evidence from which this model was developed comes from data obtained following radiotherapy. Nevertheless, this model has also been assumed for chemotherapy-induced mucositis since both radiotherapy and chemotherapy act by causing DNA damage (Sonis, 2004). However, this model also stresses that anti-cancer agents initiate mucositis by non-DNA damage (Sonis, 2004). This suggests that differences in the mechanisms of radiotherapy- and chemotherapy-induced mucosal injury may exist. Although the biological phases of chemotherapy-induced mucositis have been shown to be compatible to those induced by radiotherapy, there is still a gap in our knowledge regarding the explicit signalling pathways involved.

Recent research efforts have focused on characterising chemotherapy-induced mucositis. Historically, mucositis was thought to be purely an epithelium-mediated event which

occurred as a result of non-specific effects of chemotherapeutic agents (Ijiri et al., 1983; Sonis et al., 2004). Initial studies by Keefe and colleagues (2000) and Gibson and colleagues (2005) focused on characterising the histological and ultrastructural changes which occur following chemotherapy administration throughout the alimentary tract. They were able to show that chemotherapy causes prominent oral, small intestinal and colonic damage which is not only specific to the epithelium. Furthermore, in the gastrointestinal region, some of the main histopathological features of mucositis include the presence of degenerative enterocytes (Gibson et al., 2005; Logan et al., 2008), epithelial atrophy (Gibson et al., 2005), damage of submucosal vasculature (Paris et al., 2001), infiltration of inflammatory cells (Logan et al., 2008), hypersecretion of mucus (Stringer et al., 2009; Stringer et al., 2009) and increase in pathogenic bacteria (Stringer et al., 2008; Stringer et al., 2009; Stringer et al., 2009). Further microarray studies by Bowen and colleagues (2007) illustrate the signalling disarray that occurs in alimentary tract tissue following chemotherapy (Bowen et al., 2007). These studies were able to show that tissue damage caused by cytotoxic chemotherapy in mucositis is mediated by a range of pathways including mitogen activated protein kinases (MAPK), NF $\kappa$ B & cyclooxygenase-2 (COX-2), Wnt, SAPK/JNK and ceramide signalling (Bowen et al., 2005; Bowen et al., 2007; Bowen et al., 2007; Logan et al., 2008; Logan et al., 2009; Bowen et al., 2010). Similar to the aforementioned studies, the results presented in this thesis have added further evidence to support the 5-phase hypothesis for mucositis development and lent further support to the complexity of mucositis pathogenesis in response to chemotherapy.

### 6.3 Housekeeping genes in mucositis

One of the major hurdles in studying the molecular mechanism of mucositis is that lack of validated techniques for use in specific animal models. Furthermore, this is hampered by the fact that there are differences in the pathobiology of mucositis caused by different chemotherapeutic agents (Logan et al., 2009). This is especially true when utilising RT-PCR methodology to investigate gene expression changes during mucositis. The use of this technique relies on the availability of a stably expressed housekeeping gene in a given animal model in order to detect changes in the genes of interest. Previous studies have highlighted the importance of accurate validation of housekeeping genes to ensure stable expression that is not regulated by the experimental conditions or treatments (van Wijngaarden et al., 2007; Langnaese et al., 2008).

Currently, there is no universally valid internal control gene (Schmittgen et al., 2000; Bustin, 2002; Bustin, 2002) therefore it is important to identify the suitable normalisation gene in specific animal models under investigation. This thesis demonstrated that amidst the signalling disarray seen in mucositis, there are stably expressed genes which can be used as housekeeping genes. Key findings from this thesis indicated differential gene expression profiles for the eleven housekeeping genes under observation following chemotherapy treatment, highlighting the importance of pre-study validation. Furthermore, the two most stably expressed genes were found to be *Ywhaz* and *UBC* for the jejunum and  $\beta$ -actin and *UBC* for the colon. To date no detailed evaluation of housekeeping genes has been carried out for models of chemotherapy-induced intestinal damage. Despite this, multiple studies have used housekeeping genes, including 18S (Bowen et al., 2007; Sukhotnik et al., 2008) and  $\beta$ -actin (Feng et al., 2008), for normalisation to control for gene

expression in chemotherapy and radiation-induced mucositis development in rats (Bowen et al., 2007; Feng et al., 2008; Sukhotnik et al., 2008). This was the first study to provide an appropriate evaluation of multiple housekeeping genes in a chemotherapy-induced mucositis model.

#### **6.4 Gastrointestinal matrix metalloproteinase expression following chemotherapy**

To date, research efforts on the mechanism of chemotherapy-induced mucositis have revealed a complex pathobiology for this condition. Currently, it is known that the biological events underlying mucositis occur in an interdependent sequence and that the tissue and cellular sources of the upregulated genes are associated with the endothelium, muscle, inflammatory infiltrate and epithelial cells. However, better understanding of the mediators of tissue damage is required in order to target appropriate treatment strategies.

Some of the main histopathological features of mucositis include the presence of degenerative enterocytes (Gibson et al., 2005; Logan et al., 2008), epithelial atrophy (Gibson et al., 2005), damage of submucosal vasculature (Paris et al., 2001), infiltration of inflammatory cells (Logan et al., 2008), hypersecretion of mucus (Stringer et al., 2009; Stringer et al., 2009) and increase in pathogenic bacteria (Stringer et al., 2008; Stringer et al., 2009; Stringer et al., 2009). The mediators of these events are not well characterised. This thesis focused on characterising MMP expression following irinotecan-induced mucositis in a time-course model. For the first time, MMP expression was shown to be altered in multiple regions of the AT after chemotherapy administration. Furthermore, the expression profiles of these MMPs in correlation with the histopathological damage seen in the tissue suggest varying roles for the MMPs in the different stages of mucositis

development within the alimentary tract. Originally, the 5-phase hypothesis for mucositis development implicates MMPs in the ulcerative phase of mucositis through fibronectin degradation (Sonis, 2004; Sonis, 2004). Findings of the current study further the suggestions made by Sonis and colleagues (2004) and provide strong evidence for a role of MMPs in various stages of mucositis.

MMPs are becoming well known for their ability to modulate inflammatory processes, innate immunity and repair following injury. Parks and colleagues (2004) describe the inflammatory process as comprising of a series of cellular responses. Furthermore, inflammatory responses relies on integrating information associated with the following: 1. detection of an injury and/or the presence of microorganisms, 2. the accumulation and intervention of cells that eliminate invading microorganisms and infected host cells and 3. the repair of tissues that are damaged by the initial insult, trauma or the response of the host (Parks et al, 2004). Although this process is vital for tissue recovery and repair, inflammation can lead to persistent tissue damage if targeted destruction and assisted repair are not properly phased. A review by Nathan (2002) implicated MMPs in many diseases that are characterised by inflammation (Nathan, 2002). The host response to cytotoxic chemotherapy, specifically irinotecan, involves the initiation of an inflammatory response at 48 h - 72 h following treatment. Data from this thesis indicate the involvement of MMP-2, -9 and -12 in the inflammatory response induced in the gut by chemotherapy at 48 h following treatment. This is evident by the close correlation of inflammatory cell infiltrate and maximal morphological disturbance with the expression of those MMPs in epithelial cells and the underlying blood vessel-rich lamina propria. This is consistent with mouse studies which describe a decreased inflammatory phenotype for MMP2<sup>-/-</sup>, MMP9<sup>-/-</sup> and

MMP12<sup>-/-</sup> mice (Shiple et al., 1996; Hautamaki et al., 1997; Betsuyaku et al., 2000; Warner et al., 2001; Itoh et al., 2002; Lanone et al., 2002; Nathan, 2002; Churg et al., 2003; Corry et al., 2004). However, it should be noted that newly emerging data in the literature suggests that the up-regulation of MMPs in some inflammatory conditions may also aid in alleviating the inflammatory process (Mudgett et al., 1998; Hartzell et al., 1999; Corry et al., 2002; Itoh et al., 2002).

Surprisingly, MMPs have also been shown to be involved in innate immunity and repair following injury. In the injured mucosal epithelium, a wound repair program is rapidly recruited by cells to heal wound through cell proliferation, spreading and migration. MMPs are key downstream mediators of this wound repair program (Parks, 1999). In this thesis, MMP-1 levels were significantly elevated between 72 h and 144 h following irinotecan treatment in the jejunum and colon. Hence, data from this thesis support the suggestion that MMP-1 may play a vital role in tissue healing following mucosal injury caused by irinotecan. The mechanism by which MMP-1 carries out this role is not clear, however, past studies have suggested the MMP-1 carries out this role by altering the migratory substratum to drive the forward movement of repairing cells. MMPs have also been shown capable of killing bacteria. Studies by Hartzell and colleagues (1999) were able to show that MMP-12<sup>-/-</sup> mice develop necrotic lesions in the gut, liver and kidneys and this was associated with the presence of Gram-positive cocci in areas of tissue necrosis (Hartzell et al., 1999). Furthermore, it has been suggested that degradative pathways, including MMP signalling, are initiated by colonising bacteria as well as host cell signalling (through pro-inflammatory cytokines) and are a vital initiators of the innate immune response (Birkedal-Hansen H, 1993). In regions of the gut where mucositis is present, a significant increase in

pathogenic bacteria, pro-inflammatory cytokines as well as MMPs is noted in the mucosa. These observations suggest some level of functional linkage between these in the immune response observed following chemotherapy.

### **6.5 The upstream regulators of MMP expression**

Data from this thesis has shed light on the mechanisms of MMP regulation in mucositis. Generally, the catalytic activity of MMPs is controlled at four levels. These points of regulation are at: 1. the gene expression level; 2. compartmentalisation; 3. pro-enzyme activation; and 4. enzyme inactivation and substrate availability and affinity. These mechanisms of regulation are altered during various pathologies where a skewed expression of MMPs is noted such as in irinotecan-induced mucositis. This skewed expression of MMPs can be attributed to an alteration in one or more of these control mechanisms. In this thesis, both mRNA and protease levels were investigated for MMP-2, -9 and -12. In this model of irinotecan-induced mucositis, MMP-2, -9 and -12 mRNA and protease levels reflected an individualised/unique mode of regulation for each of these MMPs. In the jejunum for example, MMP2 mRNA and protease levels were closely correlated suggesting that transcription and translation occurs concurrently. In contrast, MMP-9 and -12 mRNA were not reflective of protease levels. MMP-9 mRNA levels were not altered during the time-course, however, an increase in tissue protease levels was noted suggesting a post-translational regulation, such as rate of deactivation or degradation of MMP-9. MMP-12 mRNA and protease levels also show a weak correlation where an increase in mRNA precedes protease level increase. The delay in translation of mRNA into protein suggests a post-transcriptional level of regulation, most likely influencing mRNA stability in the cell cytoplasm.

Previous studies have indicated that MMP mRNA stability is mediated by RNA-binding proteins (including cytokines) and microRNAs (Vincenti et al., 1996; Akool el et al., 2003; Rydzziel et al., 2004). MMP-12 is known to be strongly regulated by microRNAs (Garbacki et al., 2009). MicroRNAs are small 21-25 nucleotide RNAs that negatively regulate gene expression by causing either inhibition of translation or mRNA degradation. MicroRNA-mediated regulation is referred to as post-translational and evidence in the literature suggest that approximately 30% of the human genome is regulated this way (Lewis et al., 2003). The role of microRNAs in mucositis has not been well established and although it is theoretically possible for microRNAs to be influencing MMP expression, further research is still required to establish this.

This thesis has also provided evidence in relation to the post-translational regulation of MMPs by demonstrating an increase in plasminogen activators uPA and tPA; both of which are potent activators of pro-MMPs, following irinotecan administration. This lends strong evidence that the increase in MMPs observed in gastrointestinal tissue is accompanied by an increase in MMP activation hence increasing the potency of these proteases in tissue. Although many theories could be offered regarding the transcriptional and translational regulation of MMPs in mucositis, it is vital to note that these mechanisms of regulation are complex and unique to each MMP, hence adding further difficulty in determining the precise regulatory mechanism which may be involved in the dysregulated expression of MMPs in mucositis.



### **6.6 What could be the downstream targets of MMPs in mucositis?**

Recent studies have focused on exploring the substrate specificity of MMPs in an attempt to understand the roles of specific MMPs in disease. *In vitro* studies have shown considerable overlap in the substrates that MMPs can cleave, particularly in relation to ECM substrates (Sternlicht et al., 2001). Hence, although this thesis has characterised changes in MMP expression as well as ECM components following chemotherapy, it is difficult to predict which MMP impacted on which ECM component. From past literature, it is known that growth factors, cytokines, chemokines and adhesion receptors are downstream targets of MMPs (Chapter 1, Table 2). Furthermore, these MMP substrates have been implicated in mucositis development.

Previous evidence in the literature show that MMP substrate selectivity in tissue is perfected by two processes: compartmentalisation and enzyme affinity (Parks et al., 2004). Kinetic studies have shown that some MMPs degrade particular substrates more efficiently than others. For example, MMP-2 and -9 have been shown to cleave collagen more efficiently than other MMPs (Mackay et al., 1990). Compartmentalisation; which is where and how an MMP is released in the pericellular environment, is another major player in predicting substrate specificity of an MMP. However, substrate identification for a particular MMP is not straightforward and biologically relevant approaches are still being developed for this purpose. Techniques including affinity-based approaches (McQuibban et al., 2000), proteomics (Guo et al., 2002; Tam et al., 2004) and deduction have been used in the past to identify natural physiological substrates for MMPs. Gain of function studies as well as MMP-deficient animal models have also been employed for phenotype identification.

Due to the complicated nature of substrate identification techniques, it is only possible to correlate the expression profiles of the known substrates with MMP expression in order to draw conclusions on the possible roles of individual MMPs. In the model of chemotherapy-induced mucositis, used in this thesis, it is known that there is an alteration in MMPs (Al-Dasooqi et al., 2010) and the known substrates including ECM components (Al-Dasooqi et al., 2011) and cytokines (Logan et al., 2008; Logan et al., 2009). The concurrent changes in these in our time-course model of irinotecan-induced mucositis suggest a role for MMPs in ECM turnover as well as cytokine activity in mucositis. For example, an increase in MMP-2 and -9 precedes excessive collagen degradation at 96-144h following chemotherapy, suggesting a role for these MMPs in collagen breakdown.

The precise consequence of each MMP in mucositis can further be investigated by specific-MMP inhibition studies or knock-out model studies. Such studies can potentially reveal the usefulness of MMP inhibition as a therapeutic strategy for chemotherapy-induced mucositis.

### **6.7 Structure of the extracellular matrix following chemotherapy**

MMPs are believed to be the main mediators of extracellular matrix component degradation and are hence the primary initiators of tissue remodelling (Birkedal-Hansen et al., 1993; Parks, 1999; Vu et al., 2000; Stamenkovic, 2003; Page-McCaw et al., 2007; Clark et al., 2008). These proteases drive physiological processes including embryonic development, morphogenesis, postnatal development as well as pathological processes. In the alimentary tract, the ECM plays a vital role in maintaining tissue architecture and homeostasis. As indicated by previous studies, the ECM is capable of being remodelled in

response to a variety of tissue stimuli (Vu et al., 2000; Stamenkovic, 2003). These stimuli include dynamic homeostatic remodelling in resting-state organs to vigorous remodelling in normal development, inflammation, wound healing and cancer. Furthermore, these changes include both structural as well as composition changes in the ECM. In this thesis, an increase in MMPs was noted following chemotherapy and this was associated with changes in essential ECM components including collagen and fibronectin. For the purpose of this study only ECM composition was investigated and no structural changes in the ECM were explored. Further studies are now warranted to investigate the effects of chemotherapy on the structural organisation of the ECM. This thesis focused on the fibrous components of the ECM and did not investigate the non-fibrous components of the extracellular matrix including proteoglycans and cell adhesion molecules (integrins). These play vital roles in binding and organising the fibrous proteins within the ECM and hence are capable of influencing a variety of biological activities. Further research is required to fully understand their role in mucositis development.

### ***6.7.1 Collagen***

In the alimentary tract, the ECM undergoes low level of continuous tissue turnover to regulate such phenomena including apoptosis, proliferation and differentiation (Meredith et al., 1993; Beaulieu et al., 1997). Collagen is in one of the major constituents of the gut ECM and its anti-adhesive properties have been well documented in relation to epithelial cell migration (Potten et al., 1990; Yurchenco et al., 1990; Gibson et al., 2003; Koning et al., 2007). This thesis has shown that there was a significant alteration in collagen deposits in the jejunum and colon following irinotecan. Specifically, an increase in collagen

deposits was noted in the basement membranes and the underlying submucosal region 48-72 h following irinotecan as indicated by Sirius red staining.

The increase in collagen noted following irinotecan could serve two purposes; 1- to provide overlying tissue with sufficient structural integrity and strength especially following injury (Orberg et al., 1982) and 2- to allow cells to move up along the crypt-villus axis following primary tissue injury. Gibson and colleagues (2003) illustrated an increase in crypt length and a decrease in villus area 72-96 h following irinotecan administration in rats (Gibson et al., 2003). Furthermore, an extension in the mesenchyme has also been noted following chemotherapy treatment as indicated by Ki67 staining in this study and the work of others (Gibson et al., 2003; Koning et al., 2007). In the context of this study, an increase in collagen may play a role in the process of intestinal and colonic cell migration along the crypt axis following the injury induced by irinotecan in an attempt to repopulate the villi. Furthermore, data from this study indicate that collagen changes are more prolonged than cell kinetic changes where collagen expression does not return to normal even at 144 h following treatment. This has provided a novel way of thinking about damage by highlighting the role fibrotic processes play in the development of chemotherapy-induced mucositis. It is now necessary to examine the consequence of this pathophysiological process on normal functions of the AT.

Fibrotic responses (as indicated by increased collagen deposits) have been implicated in gut function disturbances, most notably diarrhoea (Burgel et al., 2002; Freeman, 2005). The pathogenesis of diarrhoea in mucositis is far from clear and many underlying causes could be contributing. These include microflora changes (Stringer et al., 2009; Stringer et

al., 2009) and possibly lamina propria oedema, bile acid malabsorption (Freeman, 2005), brush border enzyme alteration as well as an increase in subepithelial collagen (Burgel et al., 2002; Freeman, 2005). An increase in subepithelial collagen has been illustrated in many gastrointestinal diseases where diarrhoea is frequently seen including collagenous colitis and celiac disease (Freeman, 2005). In this model of irinotecan-induced mucositis, all animals were checked four times daily for the entire course of the experiment and diarrhoea recorded according to previous gradings (Gibson et al., 2003). Furthermore, logistic regression analyses indicate an association between an increase in collagen and diarrhoea prevalence in these animals (data not shown). Hence, it is plausible to suggest that remodelling of gut collagen could be contributing to irinotecan-induced diarrhoea.

One of the clinical determinants of irinotecan-induced diarrhoea is prior anti-cancer treatment. It has been shown that patients who have received prior chemotherapy or radiotherapy to the abdomen or pelvis are at an increased risk of developing delayed-onset diarrhoea (which is characteristic of mucositis) (Freyer et al., 2000; Kweekel et al., 2008). Although the pathobiological implications of such observations are not well understood, it is suggestive of chronic histopathological alterations in the gut following exposure to anti-cancer agents. Chronic ECM tissue remodelling could contribute to the increasing risk of toxicity following repeated cycles of anti-cancer treatment. Indeed, findings from the animal model described within this thesis indicate that irinotecan causes an alteration in collagen expression which is not restored even at 144 h following treatment (this is considered to be the healing phase of mucositis). For the first time, these results suggest that chemotherapy treatment could be resulting in fibrotic changes in the gut which are not resolved upon cessation of the treatment cycle. Furthermore, it is likely that alteration of

collagen in the gut would result in gastrointestinal complications including digestive and motility functions well beyond the chemotherapy cycle. Chronic alterations in the gut would also predispose patients to toxicity from subsequent anti-cancer treatment cycles (Ma et al., 2010). However, the timeframe to which the alterations noted in this study are sustained need to be established by further investigations.

### **6.7.2 Fibronectin**

In the 5 phase model of mucositis, fibronectin has been suggested to play a role in the up-regulation and message generation phase. Sonis (2004) suggests that primary tissue damage induced by an increase in reactive oxygen species activates a plethora of pathways including NFκB, sphingomyelinase, ceramide synthase (Sonis et al., 2004). These pathways in turn cause the breakdown of fibronectin hence contributing to the early apoptosis observed in mucositis as well as the activation of macrophages and subsequently matrix metalloproteinases and exacerbating tissue injury. However, to date, there is no experimental data to suggest the truthfulness of these suggestions. This study utilised the timecourse model of irinotecan-induced mucositis to examine these events. A decrease in fibronectin was demonstrated at 6 h following irinotecan treatment. This decrease coincided with a peak in apoptosis and cytostasis of jejunum and colon crypt cells. Furthermore, it was demonstrated that the breakdown of fibronectin is followed by inflammatory cell infiltrate into the mucosa. Together, these data provide solid evidence in support of the 5-phase model for mucositis.

An increase in MMP-2, -9 and -12 has also been illustrated in this model following fibronectin breakdown. This timing is surprising since MMPs were initially hypothesised

to induce fibronectin breakdown. From this data, it appears that fibronectin breakdown is being initiated by other enzymes, possibly ROS, and not MMPs. Furthermore, fibronectin breakdown may be initiating an increase in MMP levels in tissue possibly to facilitate immune cell influx. This increase in MMPs, subsequent to fibronectin breakdown, is capable of providing positive feedback by digesting more fibronectin and causing a further decrease in fibronectin levels. This is observed at the later timepoint of 48 h in the jejunum where fibronectin levels are at their lowest. This inturn exacerbates tissue injury in the gut by altering cell kinetics and mediating an inflammatory response. Alternatively, the actions of MMPs on fibronectin (and collagen IV also) could be viewed favourably. Emerging evidence in the literature suggests that matrix degradation leads to the release of various matrix-bound growth factors and cytokines following injury hence aiding in tissue repair (Arthur 1997; Pender 2008). Furthermore, a recent review by Pender (2008) discusses the possible contrasting roles of MMP-mediated ECM degradation in gut inflammation and repair. This review highlights the complexity of MMP-mediated ECM degradation and proposes the need for investigation of cell-specific MMP production and its consequence of local ECM degradation in order to gain an understanding into the precise function of MMPs and ECM in the gut.

### **6.8 Serum matrix metalloproteinases as biomarkers of mucositis**

Chemotherapy-induced AT toxicity is highly prevalent amongst cancer patients. Research into the gastrointestinal toxicity of chemotherapeutic agents and anti-mucotoxic interventions has utilised symptom scores to assess toxicity, even though symptoms are an unreliable measure of underlying pathology. As such, the need for a gastrointestinal mucositis biomarker has become increasingly important, especially when conducting

clinical evaluation of mucositis interventions; where accurate evaluation of mucositis is required. The current study investigated the potential of MMPs as systemic biomarkers of gut toxicity in a small number of patients receiving chemotherapy regimens containing 5-fluorouracil, capecitabine or irinotecan. Key findings from this study indicated a significant increase in circulating MMP-3 and MMP-9 following chemotherapy treatment.

MMPs are a group of zinc-dependent endopeptidases; which play a vital role in tissue injury and the inflammatory response. This study was not able to suggest an association between serum MMP levels and symptom prevalence, however, it is not known if this is reflective of gut health. Gibson and Bowen (2011) suggest that symptoms are an unreliable measure of toxicity in the gastrointestinal tract. Hence, it is difficult to draw any conclusions regarding the validity of MMPs as biomarkers of gastrointestinal mucositis from this study due to the small patient numbers. Future studies should investigate the potential of MMPs as biomarkers in an animal-model of chemotherapy-induced mucositis. This would allow the direct correlation between gastrointestinal tissue integrity and serum MMP levels.

## **6.9 Conclusions**

In conclusion, this thesis has provided clear evidence that irinotecan treatment results in the alteration of MMP expression profiles in the AT, potentially contributing to the development of mucositis. There is also clear evidence of changes in subepithelial components which are important in maintaining tissue structure and homeostasis, including collagen and fibronectin. Furthermore, these changes in extracellular tissue compartments may contribute to irinotecan-induced intestinal injury through changes in epithelial cell



kinetics and induction of the inflammatory response. Preliminary findings from this thesis suggest that MMP-3 and MMP-9 are increased following chemotherapy, and may have potential as biomarkers of AT toxicity induced by 5-fluorouracil, capecitabine or irinotecan. Confirmation of these findings in a larger cohort would aid in the diagnosis of mucositis development and aid in the clinical evaluation of mucositis interventions. This research has broadened the understanding of the pathobiology of mucositis. Furthermore, this thesis has identified new areas of research into mucositis, in particular for mucositis interventions and serum biomarkers of mucositis.

## 7.0 References

NetPrimer from <http://www.premierbiosoft.com/netprimer/index.html>.

Adams J and Watt F (1993). Regulation of development and differentiation by extracellular matrix. *Development* **117**: 1183-1198.

Akool el S, Kleinert H, Hamada F, Abdelwahab M, Forstermann U, Pfeilschifter J and Eberhardt W (2003). Nitric oxide increases the decay of matrix metalloproteinase 9 mRNA by inhibiting the expression of mRNA-stabilizing factor HuR. *Mol Cell Biol* **23**: 4901-4916.

Al-Bader M and Al-Sarraf H (2005). Housekeeping gene expression during fetal brain development in the rat-validation by semi-quantitative RT-PCR. *Brain Res Dev Brain Res* **156**: 38-45.

Al-Dasooqi N, Gibson R, Bowen J and Keefe D (2009). Matrix metalloproteinases: key regulators in the pathogenesis of chemotherapy-induced mucositis? *Cancer Chemotherapy and Pharmacology* **64**: 1-9.

Al-Dasooqi N, Gibson R, Bowen J, Logan R, Stringer A and Keefe D (2010). Matrix metalloproteinases are possible mediators for the development of alimentary tract mucositis in the DA rat. *Exp Biol Med* **235**: 1244-1256.

Al-Dasooqi N, Bowen JM, Gibson RJ, Logan RM, Stringer A & Keefe DM (2011). Selection of housekeeping genes for gene expression studies in a rat model of irinotecan-induced mucositis. *Chemotherapy* **57**(1):43-53.

Al-Dasooqi N, Bowen JM, Gibson RJ, Logan RM, Stringer A & Keefe DM (2011). Irinotecan-induced alterations in intestinal cell kinetics and extracellular matrix component expression. *International Journal of Experimental Pathology* **92**(5):357-365

Almarza A, Augustine S and Woo S (2008). Changes in gene expression of matrix constituents with respect to passage of ligament and tendon fibroblasts. *Annals of Biomedical Engineering* **36**: 1927-1933.

Andersen C, Jensen J and Orntoft T (2004). Normalization of real-time quantitative reverse transcription-PCR data: a model-based variance estimation approach to identify genes suitable for normalisation, applied to bladder and colon cancer data sets. *Cancer Research* **64**: 5245-5250.

Aprile G, Ramoni M, Keefe D M and Sonis S (2008). Application of distance matrices to define associations between acute toxicities in colorectal cancer patients receiving chemotherapy. *Cancer* **112**: 284-292.

Bamba S, Andoh A, Yasui H, Araki Y, Bamba T and Fujiyama Y (2003). Matrix metalloproteinase-3 secretion from human colonic subepithelial myofibroblasts: role of interleukin-17. *Journal of Gastroenterology* **38**: 548-554.

Beaulieu J (1997). Extracellular matrix components and integrins in relationship to human intestinal epithelial cell differentiation. *Progress in Histochemistry and Cytochemistry* **31**: 1-78.

Betsuyaku T, Fukuda Y, Parks W, Shipley J and Senior R (2000). Gelatinase B is required for alveolar bronchiolization after intratracheal bleomycin. *Am J Pathol* **157**: 525-535.

Birkedal-Hansen H, Moore W, Bodden M, Windsor L, Birkedal-Hansen B, DeCarlo A and Engler J (1993). Matrix metalloproteinases: a review. *Crit Rev Oral Biol Med* **4**: 197-250.

Blau H and Baltimore D (1991). Differentiation requires continuous regulation. *Journal of Cell Biology* **112**: 781-783.

Booth D and Potten C (2001). Protection against mucosal injury by growth factors and cytokines. *Journal of the National Cancer Institute* **29**: 16-20.

Borden P and Heller R (1997). Transcriptional control of matrix metalloproteinases and the tissue inhibitors of matrix metalloproteinases. *Critical Reviews in Eukaryotic Gene Expression* **7**: 159-178.

Bourboulia D and Stetler-Stevenson W (2010). Matrix metalloproteinases (MMPs) and tissue inhibitors of metalloproteinases (TIMPs): positive and negative regulators in tumor cell adhesion. *Semin Cancer Biol* **20**: 161-168.

Bowen J, Gibson R, Cummins A, Tyskin A and Keefe D (2007). Irinotecan changes gene expression in the small intestine of the rat with breast cancer. *Cancer Chemother Pharmacol* **59**: 337-348.

Bowen J, Gibson R, Keefe D and Cummins A (2005). Cytotoxic chemotherapy up-regulates pro-apoptotic Bax and Bak in the small intestine of rats and humans. *Pathology* **37**: 56-62.

Bowen J, Gibson R, Tsykin A, Stringer A, Logan R and Keefe D (2007). Gene expression analysis of multiple gastrointestinal regions reveals activation of common cell regulatory pathways following cytotoxic chemotherapy. *Int J Cancer* **121**: 1847-1856.

Bowen J, Tsykin A, Stringer A, Logan R, Gibson R and Keefe D (2010). Kinetics and regional specificity of irinotecan-induced gene expression in the gastrointestinal tract. *Toxicology* **269**: 1-12.

Bullard K, Lund L, NMudgett J, Mellin T, Hunt T, Murphy B, Ronan J, Werb Z and Banda M (1999). Impaired wound contraction in stromelysin-1-deficient mice. *Annals of Surgery* **230**: 260-265.

Burgel N, Bojarski C, Mankertz J, Zeitz M, Fromm M and Schulzke J (2002). Mechanisms of diarrhea in collagenous colitis. *Gastroenterology* **123**: 433-443.

Bustin S (2002). Quantification of mRNA using real-time reverse transcription PCR (RT-PCR): trends and problems. *Journal of Molecular Endocrinology* **29**: 23-39.

Cai J, Deng S, Kumpf S, Lee P, Zagouras P, Ryan A and Gallagher D (2007). Validation of rat reference genes for improved quantitative gene expression analysis using low density arrays. *Biotechniques* **42**: 503-512.

Capp A, Inostroza-Ponta M, Bill D, Moscato P, Lai C, Christie D, Lamb D, Turner S, Joseph D, Matthews J, Atkinson C, North J, Poulsen M, Spry NA, Tai KH, Wynne C, Duchesne G, Steigler A and Denham JW (2009). Is there more than one proctitis syndrome? A revisitiation using data from the TROG 96.01 trial. *Radiother Oncol* **90**: 400-407.

Carneiro-Filho B, Lima I, Araujo D, Cavalcante M, Carvalho G, Brito G, Lima V, Monteiro S, Santos F, Ribeiro R and Lima A (2004). Intestinal barrier function and secretion in methotrexate-induced rat intestinal mucositis. *Digestive Diseases and Sciences* **49**: 65-72.

Carroll K, Wong T, Drabik D and Chang E (1988). Differentiation of rat small intestinal epithelial cells by extracellular matrix. *American Journal of Physiology* **254**: g355-360.

Castro M, Rizzi E, Figueiredo-Lopes L, Fernandes K, Bendhack L, Pitol D, Gerlach R and Tanus-Santos J (2008). Metalloproteinase inhibition ameliorates hypertension and prevents

vascular dysfunction and remodeling in renovascular hypertensive rats. *Atherosclerosis* **198**: 320-331.

Chakraborti S, Mandal M, Das S, Mandal A and Chakraborti T (2003). Regulation of matrix metalloproteinases: an overview. *Molecular and Cellular Biochemistry* **253**: 269-285.

Chen J, Rider D and Ruan R (2006). Identification of valid housekeeping genes and antioxidant enzyme gene expression change in the aging rat liver. *Journal of Gerontology: Biological Sciences* **61A**: 20-27.

Churg A, Wang R, Tai H, Wang X, Xie C, Dai J, Shapiro S and Wright J (2003). Macrophase metalloelastase mediates acute cigarette smoke-induced inflammation via tumor necrosis factor- $\alpha$  release. *Am J Respir Crit Care Med* **167**: 1083-1089.

Clark I, Swingler T, Sampieri C and Edwards D (2008). The regulation of matrix metalloproteinases and their inhibitors. *International Journal of Biochemistry & Cell Biology* **40**: 1362-1378.

Corry D, Kiss A, Song L, Song L, Xu J, Lee S, Werb Z and Kheradmand F (2004). Overlapping and independent contributions of MMP2 and MMP9 to lung allergic inflammatory cell egression through decreased CC chemokines *FASEB J* **18**: 995-997.

Corry D, Rishi K, Kanellis J, Kiss A, Song L, Xu J, Feng L, Werb Z and Kheradmand F (2002). Decreased allergic lung inflammatory cell egression and increased susceptibility to asphyxiation in MMP2-deficiency *Nature Immunology* **3**: 347-353.

Cutler L (1990). The role of extracellular matrix in the morphogenesis and differentiation of salivary glands. *Advanced Dental Research* **4**: 27-33.

Daniele A, Zito A, Giannelli G, Divella R, Asselti M, Mazzocca A, Paradiso A and Quaranta M (2010). Expression of metalloproteinases MMP-2 and MMP-9 in sentinel lymph node and serum of patients with metastatic and non-metastatic breast cancer. *Anticancer Research* **30**: 3521-3527.

Delclaux C, Delacourt C, D'Ortho M, Boyer V, Lafuma C and Harf A (1996). Role of gelatinase B and elastase in human polymorphonuclear neutrophil migration across basement membrane. *American Journal of Respiratory Cell and Molecular Biology* **14**: 288-295.

Denhardt D, Feng B, Edwards D, Cocuzzi E and Malyankar U (1993). Tissue inhibitor of metalloproteinases (TIMP, aka EPA): structure, control of expression and biological functions. *Pharmacology & Therapeutics* **59**: 329-341.

Dhaouadi T, Sfar I, Abdelmoula L, Jendoubi-Ayed S, Aouadi H, Ben Abdellah T, Ayed K, Zouari R and Gorgi Y (2007). Role of immune system, apoptosis and angiogenesis in



pathogenesis of rheumatoid arthritis and joint destruction, a systematic review. *Tunis Med* **85**: 991-998.

Durigan J, Peviani S, Russo T, Delfino G, Ribeiro J, Cominetti M, Selistre-de-Araujo H and Salvini T (2008). Effects of alternagin-C from *Bothrops alternatus* on gene expression and activity of metalloproteinases in regenerating skeletal muscle. *Toxicon* **52**: 687-694.

Feng C, Guo J, Jiang H, Zhu S, Li C, Cheng B, Chen Y and Wang H (2008). Spatio-temporal localization of HIF-1alpha and COX-2 during irradiation-induced oral mucositis in a rat model system. *International Journal of Radiation Biology* **84**: 35-45.

Freeman H (2005). Collagenous mucosal inflammatory diseases of the gastrointestinal tract. *Gastroenterology* **129**: 338-350.

Freyer G, Rougier P, Bugat R, Droz J, Marty M, Bleiberg H, Mignard D, Awad L, Herait P, Culine S and Trillet-Lenoir V (2000). Prognostic factors for tumour response, progression-free survival and toxicity in metastatic colorectal cancer patients given irinotecan (CPT-11) as second-line chemotherapy after 5FU failure. *Br J Cancer* **83**: 431-437.

Frisch S and Francis H (1994). Disruption of epithelial cell-matrix interactions induces apoptosis. *Journal of Cell Biology* **124**: 619-626.

Fu X, Parks W and Heinecke J (2008). Activation and silencing of matrix metalloproteinases. *Seminars in Cell & Developmental Biology* **19**: 2-13.

Fujisaki K, Tanabe N, Suzuki N, Mitsui N, Oka H, Ito K and Maeno M (2006). The effect of IL-1 $\alpha$  on the expression of matrix metalloproteinases, plasminogen activators, and their inhibitors in osteoblastic ROS 17/2.8 cells. . *Life Sciences* **78**: 1975-1982.

Gagne D, Groulx J, Benoit Y, Basora N, Herring E, Vachon P and Beaulieu J (2010). Integrin-linked kinase regulates migration and proliferation of human intestinal cells under a fibronectin-dependent mechanism. *Journal of Cellular Physiology* **222**: 387-400.

Garbacki N, Di Valentin E, Piette J, Cataldo D, Crahay C and Colige A (2009). Matrix metalloproteinase 12 silencing: a therapeutic approach to treat pathological lung tissue remodelling? *Pulm Pharmacol Ther* **22**: 267-278.

Gibson R and Bowen J (2011). Biomarkers of regimen-related mucosal injury. *Cancer Treatment Reviews* **37**: 487-493.

Gibson R, Bowen J, Alvarez E, Finnie J and Keefe D (2007). Establishment of a single-dose irinotecan model of gastrointestinal mucositis. *Chemotherapy* **53**: 360-369.

Gibson R, Bowen J, Cummins A and Keefe D (2005). Relationship between dose of methotrexate, apoptosis, p53/p21 Expression and intestinal crypt proliferation in the rat. *Clinical and Experimental Medicine* **4**: 188-195.

Gibson R, Bowen J, Inglis M, Cummins A and Keefe D (2003). Irinotecan causes severe small intestinal damage, as well as colonic damage, in the rat with implanted breast cancer. *Journal of Gastroenterology and Hepatology* **18**: 1095-1100.

Gill S and Parks W (2007). Metalloproteinases and their inhibitors: Regulators of wound healing. *International Journal of Biochemistry & Cell Biology* **40**: 1334-1347.

Groos S, Reale E, Hunefeld G and Luciano L (2003). Changes in epithelial cell turnover and extracellular matrix in human small intestine after TPN. *Journal of Surgical Research* **109**: 74-85.

Guo L, Eisenman J, Mahimkar R, Peschon J, Paxton R, Black R and Johnson R (2002). A proteomic approach for the identification of cell-surface proteins shed by metalloproteases. *Mol Cell Proteomics* **1**: 30-36.

Hahn U, Stallmach A, Hahn E and Riecken E (1990). Basement membrane components are potent promoters of rat intestinal epithelial cell differentiation in vitro. *Gastroenterology* **98**: 322-335.

Hartzell W and Shapiro S (1999). Macrophage elastase prevents *Gemella morbillorum* infection and improves outcome following murine bone marrow transplantation. *Chest* **116**: 31S-32S.

Hautamaki R, Kobayashi D, Senior R and Shapiro S (1997). Requirement of macrophage elastase for cigarette smoke-induced emphysema. *Science* **277**: 2002-2004.

Huggett J, Dheda K, Bustin S and Zumla A (2005). Real-time RT-PCR normalisation; strategies and considerations. *Genes & Immunology* **6**: 279-284.

Ijiri K and Potten C (1983). Response of intestinal cells of differing topographical and hierarchical status to ten cytotoxic drugs and five sources of radiation. *British Journal of Cancer* **47**: 175-185.

Itoh T, Matsuda H, Tanioka M, Kuwabara K, Itohara S and Suzuki R (2002). The role of matrix metalloproteinase-2 and matrix metalloproteinase-9 in antibody-induced arthritis. *J Immunol* **169**: 2643-2647.

Keefe D (2000). Chemotherapy for cancer causes apoptosis that precedes hypoplasia in crypts of the small intestine in humans. *Gut* **47**: 632-637.

Keefe D (2004). Gastrointestinal mucositis: A new biological model. *Supportive Care in Cancer* **12**: 6-9.

Keefe D, Schubert M, Elting L, Sonis S, Epstein J, Raber-Durlacher J, Migliorati C, McGuire D, Hutchins R and Peterson D (2007). Updated clinical practice guidelines for the prevention and treatment of mucositis. *Cancer* **109**: 820-831.

Kessenbrock K, Plaks V and Werb Z (2010). Matrix metalloproteinases: regulators of the tumor microenvironment. *Cell* **141**: 52-67.

Kim Y, Song M and Ryu J (2009). Mechanisms underlying methotrexate-induced pulmonary toxicity. *Expert Opin Drug Saf* **8**: 451-458.

Kolli V, Abraham P, Isaac B and Selvakumar D (2009). Neutrophil infiltration and oxidative stress may play a critical role in methotrexate-induced renal damage. *Chemotherapy* **55**: 83-90.

Koning B, Lindenbergh-Kortleve D, Pieters R, Buller H, Renes I and Einerhand A (2007). Alterations in epithelial and mesenchymal intestinal gene expression during doxorubicin-induced mucositis in mice. *Dig Dis Sci* **52**: 1814-1825.

Kuhn K (1994). Basement membrane (type IV) collagen. *Matrix Biology* **14**: 439-445.

Kweekel D, Guchelaar H and Gelderblom H (2008). Clinical and pharmacogenetic factors associated with irinotecan toxicity. *Cancer Treatment Reviews* **34**: 656-669.

Langnaese K, John R, Schweizer H, Ebmeyer U and Keilhoff G (2008). Selection of reference genes for quantitative real-time PCR in a rat asphyxial cardiac arrest model. *BMC Molecular Biology* **9**: 53.

Lanone S, Zheng T, Zhu Z, Liu W, Lee C, Ma B, Chen Q, Homer R, Wang J, Rabach L, Rabach M, Shipley J, Shapiro S, Senior R and Elias J (2002). Overlapping and enzyme-specific contributions of matrix metalloproteinases-9 and -12 in IL-13-induced inflammation and remodeling *J Clin Invest* **110**: 463-474.

Lewis B, Shih I, Jones-Rhoades M, Bartel D and Burge C (2003). Prediction of mammalian microRNA targets. *Cell* **115**: 787-798.

Lin C, Tseng H, Hsieh H, Lee C, Wu C, Cheng C and Yang C (2008). Tumor necrosis factor-alpha induced MMP9 expression via p42/p44 MAPK, JNK, and nuclear factor-kappaB in A549 cells. *Toxicology and Applied Pharmacology* **229**: 386-398.

Lint P and Libert C (2007). Chemokine and cytokine processing by matrix metalloproteinases and its effect on leukocyte migration and inflammation. *Journal of Leukocyte Biology* **82**: 1375-1381.

Logan R, Gibson R, Bowen J, Stringer A, Sonis S and Keefe D (2008). Characterisation of mucosal changes in the alimentary tract following administration of irinotecan: implications for the pathobiology of mucositis. *Cancer Chemotherapy and Pharmacology* **62**: 33-41.

Logan R, Stringer A, Bowen J, Gibson R, Sonis S and Keefe D (2008). Serum levels of NFkappaB and pro-inflammatory cytokines following administration of mucotoxic drugs. *Cancer Biology & Therapy* **7**: 1139-1145.

Logan R, Stringer A, Bowen J, Gibson R, Sonis S and Keefe D (2009). Is the pathobiology of chemotherapy-induced alimentary tract mucositis influenced by the type of mucotoxic drug administered? *Cancer Chemother Pharmacol* **63**: 239-251.

Logan R, Stringer A, Bowen J, Yeoh A, Gibson R, Sonis S and Keefe D (2007). The role of pro-inflammatory cytokines in cancer treatment-induced alimentary tract mucositis: pathobiology, animal models and cytotoxic drugs. *Cancer Treatment Reviews* **33**: 448-460.

Loitsch S, Shastri Y and Stein J (2008). Stool test for colorectal cancer screening- it's time to move! *Clin Lab* **54**: 473-484.

Louis E, Ribbens C, Godon A, Franchimont D, De Groote D, Hardy N, Boniver J, Belaiche J and Malaise M (2000). Increased production of matrix metalloproteinase-3 and tissue inhibitor of metalloproteinase-1 by inflamed mucosa in inflammatory bowel disease. *Clinical and Experimental Immunology* **120**: 241-246.

Lukaszewicz-Zajac M, Mroczko B, Kozlowski M, Niklinski J, Laudanski J and Szmitkowski M (2009). Elevated levels of serum metalloproteinase 9 in patients with esophageal squamous cell carcinoma. *Pol Arch Med Wewn* **119**: 558-563.

Lutgens L, Blijlevens N, Deutz N, Donnelly J, Lambin P and De Pauw B (2005). Monitoring myeloablative therapy-induced small bowel toxicity by serum citrulline concentration: a comparison with sugar permeability tests. *Cancer* **103**: 191-199.

Lutgens L, Deutz N, Granzier-Peters M and al e (2004). Plasma citrulline concentration: a surrogate end point for radiation-induced mucosal atrophy of the small bowel. A feasibility study in 23 patients. *Int J Radiat Oncol Biol Phys* **60**: 275-285.

Ma B, Hui E and Mok T (2010). Population-based differences in treatment outcome following anti-cancer drug therapies. *Lancet Oncology* **11**: 75-84.

Ma M and McLeod H (2003). Lessons learned from the irinotecan metabolic pathway. *Current Medicinal Chemistry* **10**: 41-49.

MacDonald T and Pender S (1998). Proteolytic enzymes in inflammatory bowel disease. *Inflammatory Bowel Diseases* **4**: 157-164.

Mackay A, Hartzler J, Pelina M and Thorgeirsson U (1990). Studies on the ability of 65-kDA and 92-kDA tumor cell gelatinases to degrade type IV collagen. *J Biol Chem* **265**: 21929-21934.

Malemud C (2006). Matrix metalloproteinases (MMPs) in health and disease: an overview. *Frontiers in Bioscience* **11**: 1696-1701.

Manicone A and McGuire J (2008). Matrix metalloproteinases as modulators of inflammation. *Seminars in Cell & Developmental Biology* **19**: 34-41.



Manzano M, Bueno P, Rueda R, Ramirez-Tortosa C, Prieto P and Lopez-Pedrosa J (2007). Intestinal toxicity induced by 5-fluorouracil in pigs: a new preclinical model. *Chemotherapy* **53**: 344-355.

McQuibban G, Gong J, Tam E, McCulloch C, Clark-Lewis I and Overall C (2000). Inflammation dampened by gelatinase A cleavage of monocyte chemoattractant protein-3. *Science* **289**: 1202-1206.

Meijer M, Mieremet-Ooms M, Van Der Zon A, Van Duijn W, Van Hogezaand R, Sier C, Hommes D, Lamers C and Verspaget H (2007). Increased mucosal matrix metalloproteinase-1, -2, -3 and -9 activity in patients with inflammatory bowel disease and the relation with Crohn's disease phenotype. *Digestive and Liver Disease* **39**: 733-739.

Meredith J, Fazeli B and Schwartz M (1993). The extracellular matrix as a cell survival factor. *Molecular Biology of the Cell* **4**: 953-961.

Michael H, Gordon I and Wojciech P (2003). Histology: a text and atlas, Lippincott Williams & Wilkins.

Morvan F, Baroukh B, Ledoux D, Caruelle J, Barritault D, Godeau G and Saffar J (2004). An engineered biopolymer prevents mucositis induced by 5-fluorouracil in hamsters. *American Journal of Pathology* **164**: 739-746.

Motovali-Bashi M, Sadeghi M and Hemmati S (2010). Serum MMP-9 level associated

with initiation and progression steps of breast cancer in iranian population. *Reproductive Sciences* **17**: 585-589.

Mudgett J, Hutchinson N, Chartrain N, Forsyth A, McDonnell J, Singer I, Bayne E, Flanagan J, Kawka D, Shen C, Stevens K, Chen H, Trumbauer M and Visco D (1998). Susceptibility of stromelysin-1 deficient mice to collagen-induced arthritis and cartilage destruction. *Arthritis Rheum* **41**: 110-121.

Murphy B (2007). Clinical and economic consequences of mucositis induced by chemotherapy and/or radiation therapy. *Journal of Supportive Oncology* **5**: 13-21.

Murphy G and Nagase H (2008). Reappraising metalloproteinases in rheumatoid arthritis and osteoarthritis: destruction or repair? *Nat Clin Pract Rheumatol* **4**: 128-135.

Nathan C (2002). Points of control in inflammation. *Nature* **420**: 846-852.

Nuti E, Tuccinardi T and Rossello A (2007). Matrix metalloproteinase inhibitors: new challenges in the era of post broad-spectrum inhibitors. *Curr Pharm Des* **13**: 2087-2100.

Orberg J, Klein L and Hiltner A (1982). Scanning electron microscopy of collagen fibers in intestine. *Connective Tissue Research* **9**: 187-193.

Orga P, Mestecky J, Lamm M, Strober W, Bienenstock J and McGhee J (1994). Mucosal immunology, Academic press.

Page-McCaw A, Ewald A and Werb Z (2007). Matrix metalloproteinases and the regulation of tissue remodelling. *Nature Reviews Molecular Cell Biology* **8**: 221-233.

Pardo A and Selman M (2005). MMP-1: the elder of the family. *International Journal of Biochemistry & Cell Biology* **37**: 283-288.

Paris F, Fuks Z, Kang A, Capodiceci P, Juan G, Ehleiter D, Haimovitz-Friedman A, Cordon-Cardo C and Kolesnick R (2001). Endothelial apoptosis as the primary lesion initiating intestinal radiation damage in mice. *Science* **293**: 293-297.

Parks W (1999). Matrix metalloproteinases in repair. *Wound Repair and Regeneration* **7**: 423-432.

Parks W, Wilson C and Lopez-Boado Y (2004). Matrix metalloproteinases as modulators of inflammation and innate immunity. *Nature Reviews Immunology* **4**: 617-629.

Pender S and MacDonald T (2004). Matrix metalloproteinases and the gut- new roles for old enzymes. *Current Opinion in Pharmacology* **4**: 546-550.

Potten C, Booth C and Pritchard D (1997). The intestinal epithelial stem cell: the mucosal governor. *International Journal of Experimental Pathology* **78**: 219-243.

Potten C and Loeffler M (1990). Stem cells: attributes, cycles, spirals, pitfalls and uncertainties. Lessons for and from the crypt. *Development* **110**: 1001-1020.

Ra H and Parks W (2007). Control of matrix metalloproteinase catalytic activity. *Matrix Biology* **26**: 587-596.

Redding S (2005). Cancer therapy-related oral mucositis. *J Dent Educ* **69**: 919-929.

Reynolds J (1996). Collagenases and tissue inhibitors of metalloproteinases: a functional balance in tissue degradation. *Oral Diseases* **2**: 70-76.

Roseth A (2003). Determination of faecal calprotectin, a novel marker of organic gastrointestinal disorders. *Digestive and Liver Disease* **35**: 607-609.

Rozen S and Skaletsky H (2000). Primer3 on the WWW for general users and for biologist programmers. *Methods in Molecular Biology* **132**: 365-386.

Rydziel S, Delany A and Canalis E (2004). AU-rich elements in the collagenase 3 mRNA mediate stabilization of the transcript by cortisol in osteoblasts. *J Biol Chem* **279**: 5397-5404.

Saalbach A, Arnhold J, Lessig J, Simon J and Anderegg U (2008). Human Thy-1 induces secretion of matrix metalloproteinase-9 and CXCL8 from human neutrophils. *European Journal of Immunology* **38**: 1391-1403.

Saleh S, Ain-Shoka A, El-Demerdash E and Khalef M (2009). Protective effects of the

angiotensin II receptor blocker losartan on cisplatin-induced kidney injury. *Chemotherapy* **55**: 399-406.

Salmela M, Pender S L, Karjalainen-Lindsberg M, Puolakkainen P, MacDonald T and Saarialho-Kere U (2004). Collagenase-1 (MMP-1), matrilysin-1 (MMP-7), and stromelysin-2 (MMP-10) are expressed by migrating enterocytes during intestinal wound healing. *Scandinavian Journal of Gastroenterology* **39**: 1095-1104.

Schmittgen T and Zakrajsek B (2000). Effect of experimental treatment on housekeeping gene expression: validation by real-time, quantitative RT-PCR. *J Biochem Biophys Methods* **46**: 69-81.

Sengupta N and MacDonald T (2007). The role of matrix metalloproteinases in stromal/epithelial interactions in the gut. *Physiology* **22**: 401-409.

Sharma R, Tobin P and Clarke S (2005). Management of chemotherapy-induced nausea, vomiting, oral mucositis, and diarrhoea. *Lancet Oncology* **6**: 93-102.

Shiple J, Wesselschmidt R, Kobayashi D, Ley T and Shapiro S (1996). Metalloelastase is required for macrophage-mediated proteolysis and matrix invasion in mice. *Proc Natl Acad Sci* **93**: 3942-3946.

Shoval L, Kushner J, Sukhu B, Wood R, Kiss T, Lawrence H and Tenenbaum H (2005). The relationship between mouthrinse matrix metalloproteinases (MMP-1, 8, 13) and<sub>170</sub>

albumin levels with the degree of oral mucositis in allogeneic stem cell transplant patients.

*Bone marrow transplant* **36**: 33-38.

Solberg A, Holmdahl L, Falk P, Palmgren I and Ivarsson M (2008). A local imbalance between MMP and TIMP may have an implication on the severity and course of appendicitis. *International Journal of Colorectal Disease* **23**: 611-618.

Sonis S (2002). The biologic role for nuclear factor-kappaB in disease and its potential involvement in mucosal injury associated with anti-neoplastic therapy. *Critical Reviews in Oral Biology and Medicine* **13**: 380-389.

Sonis S (2004). A biological approach to mucositis. *J Support Oncol* **2**: 21-32.

Sonis S (2004). The pathobiology of mucositis. *Nature Reviews Cancer* **4**: 277-284.

Sonis S (2007). Pathobiology of oral mucositis: novel insights and opportunities. *Journal of Supportive Oncology* **5**: s3-11.

Sonis S, Elting L, Keefe D, Peterson D and M S (2004). Perspectives on cancer therapy-induced mucosal injury: pathogenesis, measurement, epidemiology, and consequences for patients. *Cancer* **100**: 1995-2025.

Sonis S, Peterson R, Edwards L, Lucey C, Wang L, Mason L, Login G, Ymamkawa M, Moses G, Bouchard P, Hayes L, Bedrosian C and Dorner A (2000). Defining<sub>171</sub>

mechanisms of action of interleukin-11 on the progression of radiation-induced oral mucositis in hamsters. *Oral Oncology* **36**: 373-381.

Sonis S, Scherer J, Phelan S, Lucey C, Barron J, O'Donnell K, Brennan R, Pan H, Busse P and Haley J (2002). The gene expression sequence of radiated mucosa in an animal mucositis model. *Cell Prolif* **35**: s92-s102.

Sorsa T, Tjaderhane L, Kontinen Y, Lauhio A, Salo T, Lee H, Golub L, Brown D and Mantyla P (2006). Matrix metalloproteinases: contribution to pathogenesis, diagnosis and treatment of periodontal inflammation. *Ann Med* **38**: 306-321.

Stamenkovic I (2003). Extracellular matrix remodelling: the role of matrix metalloproteinases. *Journal of Pathology* **200**: 448-464.

Stankovic S, Konjevic G, Gopcevic K, Jovic V, Inic M and Jurisic V (2010). Activity of MMP-2 and MMP-9 in sera of breast cancer patients. *Pathology, research and practice* **206**: 241-247.

Sternlicht M and Werb Z (2001). How matrix metalloproteinases regulate cell behaviour. *Annu Rev Cell Dev Biol* **17**: 463-516.

Stringer A, Gibson R, Bowen J, Ashton K, Logan R, Al-Dasooqi N, Yeoh A and Keefe D (2009). Irinotecan-induced mucositis manifesting as diarrhoea corresponds with an amended intestinal flora and mucin profile. *Int J Exp Pathol* **90**: 489-499.

Stringer A, Gibson R, Bowen J and Keefe D (2009). Chemotherapy-induced changes to microflora: Evidence and implications of change. *Current Drug Metab* **10**: 79-83.

Stringer A, Gibson R, Logan R, Bowen J, Yeoh A, Burns J and Keefe D (2007). Chemotherapy-induced diarrhea is associated with changes in the luminal environment in the DA rat. *Experimental Biology and Medicine* **232**: 96-106.

Stringer A, Gibson R, Logan R, Bowen J, Yeoh A and Keefe D (2008). Faecal microflora and  $\beta$ -glucuronidase expression are altered in an irinotecan-induced diarrhoea model in rats. *Cancer Biol Ther* **7** 1919-1925

Stringer A, Gibson R, Logan R, Bowen J, Yeoh A and Keefe D (2009). Gastrointestinal microflora and mucins play a role in the development of 5-Fluorouracil-induced gastrointestinal mucositis in rats. *Exp Biol Med* **234**: 430-441.

Sukhotnik I, Shteinberg D, Ben Lulu S, Bashenko Y, Mogilner J, Ure B, Shaoul R and Coran A (2008). Effect of transforming growth factor-alpha on enterocyte apoptosis is correlated with EGF receptor expression along the villus-crypt axis during methotrexate-induced intestinal mucositis in a rat. *Apoptosis* **13**: 1344-1355.

Takaishi H, Kimura T, Dalal S, Okada Y and D'Armiento J (2008). Joint diseases and matrix metalloproteinases: a role for MMP-13. *Curr Pharm Biotechnol* **9**: 47-54.



Tam E, Morrison C, Wu Y, Stack M and Overall C (2004). Membrane protease proteomics: isotope-coded affinity tag MS identification of undescribed MT1-matrix metalloproteinase substrates. *Proc Natl Acad Sci* **101**: 6917-6922.

Tanic N, Perovic M, Mladenovic A, Ruzdijic S and Kanazir S (2007). Effects of aging, dietary restriction and glucocorticoid treatment on housekeeping gene expression in rat cortex and hippocampus-evaluation by real time RT-PCR. *J Mol Neurosci* **32**: 38-46.

Tooley K, Howarth G, Lymn K and Butler R (2009). Optimization of the non-invasive (13)C-sucrose breath test in a rat model of methotrexate-induced mucositis. *Cancer Chemother Pharmacol* **65**: 913-921.

Van Wart H and Birkedal-Hansen H (1990). The cysteine switch: a principle of regulation of metalloproteinase activity with potential applicability to the entire matrix metalloproteinase gene family. *Proceedings of the National Academy of Sciences USA* **87**: 5578-5582.

van Wijngaarden P, Brereton H, Coster D and Williams K (2007). Stability of housekeeping gene expression in the rat retina during exposure to cyclic hyperoxia. *Molecular Vision* **13**: 1508-1515.

Vandenbroucke R, Dejonckheere E and Libert C (2011). A therapeutic role for MMP inhibitors in lung diseases? *Eur Respir J* [**Epub ahead of print**].

Vikman K, Ansar S and Edvinsson L (2007). Transcriptional regulation of inflammatory and extracellular matrix-regulating genes in cerebral arteries following subarachnoid hemorrhage in rats. *Journal of Neurosurgery* **107**: 1015-1055.

Vincenti M, White L, Schroen D, Benbow U and Brinckerhoff C (1996). Regulating expression of the gene for matrix metalloproteinase-1 (collagenase): mechanisms that control enzyme activity, transcription, and mRNA stability. *Crit Rev Eukaryot Gene Exp* **6**: 391-411.

Visse R and Nagase H (2003). Matrix metalloproteinases and tissue inhibitors of metalloproteinases: structure, function, and biochemistry. . *Circulation Research* **92**: 827-839.

Vu T and Werb Z (2000). Matrix metalloproteinases: effectors of development and normal physiology. *Genes & Development* **14**: 2123-2133.

Vuotila T, Ylikontiola L, Sorsa T, Luoto H, Hanemaaijer R, Salo T and Tjäderhane L (2002). The relationship between MMPs and pH in whole saliva of radiated head and neck cancer patients. *Journal of Oral Pathology & Medicine* **31**: 329-338.

Warner R, Lewis C, Beltran L, Younkin E, Varani J and Johnson K (2001). The role of metalloelastase in immune complex-induced acute lung injury *Am J Pathol* **158**: 2139-2144.

Wasserman J, Zhu X and Schlichter L (2007). Evolution of the inflammatory response in the brain following intracerebral hemorrhage and effects of delayed minocycline treatment. *Brain Research* **1180**: 140-154.

Wedlake L, McGough C, Hackett C and al e (2008). Can biological markers act as non-invasive sensitive indicators of radiation-induced effects in the gastrointestinal mucosa? *Aliment Pharmacol Ther* **27**: 980-987.

Westermarck J, Seth A and Kahari V (1997). Differential regulation of interstitial collagenase (MMP-1) gene expression by ETS transcription factors. *Oncogene* **14**: 2651-2660.

Wheatley D (2003). Diffusion, perfusion and the exclusion principles in the structural and functional organisation of the living cell: reappraisal of the properties of the 'ground substance'. *Journal of Experimental Biology* **206**: 1955-1961.

Wolf M, Albrecht S and Marki C (2007). Proteolytic processing of chemokines: Implications in physiological and pathological conditions. *International Journal of Biochemistry & Cell Biology*.

Wolf M, Albrecht S and Marki C (2008). Proteolytic processing of chemokines: Implications in physiological and pathological conditions. *International Journal of Biochemistry & Cell Biology* **40**: 1185-1198.

Wu B, Crampton S and Hughes C (2007). Wnt signaling induces matrix metalloproteinase expression and regulates T cell transmigration. *Immunity* **26**: 227-239.

Yeoh A, Bowen J, Gibson R and Keefe D (2005). Nuclear Factor  $\kappa$ B (NF $\kappa$ B) and Cyclooxygenase-2 (COX-2) expression in the irradiated colorectum is associated with subsequent histopathological changes. *International Journal of Radiation Oncology, Biology, Physics* **63**: 1295-1303.

Yurchenco P and Schittny J (1990). Molecular architecture of basement membranes. *The FASEB Journal* **4**: 1577-1590.

Zucker S, Cao J and Chen W (2000). Critical appraisal of the use of matrix metalloproteinase inhibitors in cancer treatment. *Oncogene* **19**: 6642-6650.

Al-Dasooqi, N., Gibson, R.J., Bowen, J.M. and Keefe, D.M. (2009) Matrix metalloproteinases: key regulators in the pathogenesis of chemotherapy-induced mucositis?  
*Cancer Chemotherapy and Pharmacology*, v.64 (1), pp. 1-9, July 2009

NOTE: This publication is included in the print copy of the thesis held in the University of Adelaide Library.

It is also available online to authorised users at:

<http://dx.doi.org/10.1007/s00280-009-0984-y>

Al-Dasooqi, N., Bowen, J.M., Gibson, R.J., Logan, R.M., Stringer, A.M. and Keefe, D.M. (2011) Selection of Housekeeping Genes for Gene Expression Studies in a Rat Model of Irinotecan-Induced Mucositis.  
*Chemotherapy*, v.57 (1), pp. 43-53, March 2011

NOTE: This publication is included in the print copy of the thesis held in the University of Adelaide Library.

It is also available online to authorised users at:

<http://dx.doi.org/10.1159/000321477>

Al-Dasooqi, N., Bowen, J.M., Gibson, R.J., Logan, R.M., Stringer, A.M. and Keefe, D.M. (2010) Matrix metalloproteinases are possible mediators for the development of alimentary tract mucositis in the dark agouti rat. *Experimental Biology and Medicine*, v. 235 (10), pp. 1244-1256, October 2010

NOTE: This publication is included in the print copy of the thesis held in the University of Adelaide Library.

It is also available online to authorised users at:

<http://dx.doi.org/10.1258/ebm.2010.010082>

Al-Dasooqi, N., Bowen, J.M., Gibson, R.J., Logan, R.M., Stringer, A.M. and Keefe, D.M. (2011) Irinotecan-induced alterations in intestinal cell kinetics and extracellular matrix component expression in the dark agouti rat. *International Journal of Experimental Pathology*, v. 92 (5), pp. 357-365, October 2011

NOTE: This publication is included in the print copy of the thesis held in the University of Adelaide Library.

It is also available online to authorised users at:

<http://dx.doi.org/10.1111/j.1365-2613.2011.00771.x>