

Emu Oil Promotes Intestinal Repair in Rat Models
of Enteric Inflammation

SUZANNE MASHTOUB ABIMOSLEH

Discipline of Physiology, School of Medical Sciences

The University of Adelaide

A thesis submitted to The University of Adelaide
in fulfilment of the requirements for the degree of

DOCTOR OF PHILOSOPHY

December 2012

TABLE OF CONTENTS

Abstract.....	viii
Declaration.....	x
Acknowledgements.....	xii
Publications arising from this thesis.....	xiv
Thesis structure.....	xviii
Chapter 1. Review of the Literature.....	1
Abstract	4
Introduction	4
Fatty acids and intestinal inflammation	4
Ratites	5
Emu Oil	5
Emu Oil composition	5
Therapeutic properties of Emu Oil	5
Potential mechanisms of action	6
Emu Oil and gastrointestinal disorders	6
Conclusions	6
Acknowledgements	6
References	7
Chapter 2. Emu Oil Increases Colonic Crypt Depth in a Rat Model of Ulcerative Colitis.....	9
Abstract	14
Introduction	14

Materials and methods	15
<i>General experimental procedures</i>	15
<i>Disease activity index and daily metabolic data</i>	16
¹³ C-sucrose breath test	17
<i>Tissue collection</i>	17
<i>Histological analyses</i>	17
<i>Statistical analyses</i>	17
Results	17
<i>Disease activity index and daily metabolic data</i>	17
<i>Visceral and gastrointestinal organ weights and lengths</i>	17
¹³ C-sucrose breath test	18
<i>Colonic histology</i>	19
Discussion	19
Acknowledgments	22
References	22

Chapter 3. Emu Oil Expedites Small Intestinal Repair Following

5-Fluorouracil-Induced Mucositis in Rats.....	24
Title Page	28
Abstract	29
Introduction	30
Materials and methods	33
<i>General experimental procedures</i>	33
<i>Animal studies</i>	33
<i>Emu Oil and Olive Oil preparation</i>	33
<i>Daily metabolic data and disease activity index</i>	34

<i>¹³C-sucrose breath test</i>	34
<i>Tissue collection</i>	35
<i>Histological analyses</i>	35
<i>Mucosal measurements</i>	35
<i>Neutral mucin-secreting goblet cell count</i>	36
<i>Biochemical analyses</i>	36
<i>Myeloperoxidase activity</i>	36
<i>Cytokine analyses</i>	37
<i>Statistical analyses</i>	38
Results	39
<i>Daily metabolic data</i>	39
<i>Disease activity index</i>	40
<i>¹³C-sucrose breath test</i>	40
<i>Visceral and gastrointestinal organ weights and lengths</i>	41
<i>Villus height and crypt depth measurements</i>	42
<i>Neutral mucin-secreting goblet cells</i>	44
<i>Myeloperoxidase activity</i>	44
<i>Cytokine analyses</i>	44
Discussion	45
Statement of author contributions and acknowledgments	51
References	52
Figure legends	58

Chapter 4. Emu Oil Reduces Small Intestinal Inflammation in the Absence of Clinical Improvement in a Rat Model of Indomethacin-Induced Enteropathy.....	75
Title page	78

Abstract	79
Introduction	80
Materials and methods	83
<i>General experimental procedures</i>	83
<i>Animal studies</i>	83
<i>Emu Oil and Olive Oil preparation</i>	84
<i>Daily metabolic data and disease activity index</i>	84
¹³ C-sucrose breath test	85
<i>Tissue collection</i>	85
<i>Intestinal damage severity scoring</i>	85
<i>Biochemical analysis</i>	86
<i>Myeloperoxidase activity</i>	86
<i>Statistical analyses</i>	87
Results	88
<i>Daily metabolic data</i>	88
<i>Disease activity index</i>	89
¹³ C-sucrose breath test	89
<i>Visceral and gastrointestinal organ weights and lengths</i>	89
<i>Intestinal damage severity scoring</i>	90
<i>Myeloperoxidase activity</i>	90
Discussion	91
Conclusions	96
Acknowledgments	97
References	98
Figure Legends	104

Chapter 5. Processing of Ratite Oils Affects Primary Oxidation Status, Resulting in Greater Radical Scavenging Properties for Emu Oil Compared to Rhea and Ostrich Oils.....	121
Title Page	125
Abstract	126
Introduction	127
Materials and methods	130
<i>Oil samples</i>	130
<i>2,2-diphenyl-1-picryl hydracyl radical (DPPH) assay</i>	131
<i>Oxidation analysis</i>	131
<i>Statistical analyses</i>	132
Results	133
<i>Free radical scavenging activity (RSA)</i>	133
<i>Primary oxidation</i>	133
<i>Correlation between primary oxidation and RSA</i>	134
Discussion	135
<i>Ratite Oil comparisons</i>	135
<i>Time period since oil render</i>	136
<i>Emu Oil inter-batch variations and manufacturer comparisons</i>	137
<i>Storage Procedure</i>	137
<i>Conclusions</i>	138
Acknowledgments	140
References	141
Chapter 6. Conclusions and Future Directions.....	149

Appendices.....	156
Appendix 1	157
<i>Grape Seed Extract Reduces Selected Disease Markers in the Proximal</i>	
<i>Colon of Dextran Sulphate Sodium-Induced Colitis in Rats</i>	160
Appendix 2	168
<i>Microbial fingerprinting detects unique bacterial communities in the</i>	
<i>faecal microbiota of rats with experimentally-induced colitis</i>	171
Appendix 3	179
<i>Current and Novel Treatments for Ulcerative Colitis</i>	181
Appendix 4	215
<i>Dietary emu oil supplementation suppresses 5-fluorouracil chemotherapy-</i>	
<i>induced inflammation, osteoclast formation, and bone loss</i>	218

ABSTRACT

Several disorders of the gastrointestinal (GI) tract including ulcerative colitis, chemotherapy-induced mucositis and non-steroidal anti-inflammatory drug (NSAID)-induced enteropathy, are characterised by inflammation, ulceration, mucosal damage and malabsorption. Treatment options are variably effective, highlighting the need to broaden therapeutic approaches, including adjunctive strategies. Emu Oil, derived from subcutaneous and retroperitoneal Emu adipose tissue, is a rich source of fatty acids (FA). Despite limited rigorous scientific studies, topically applied Emu Oil has demonstrated potent anti-inflammatory properties *in vivo*. Previously, orally administered Emu Oil improved intestinal architecture in a rat model of mucositis, with early indications of enhanced intestinal repair. Accordingly, this thesis investigated the effects of orally administered Emu Oil in rat models of colitis (colonic damage), NSAID-enteropathy (small intestinal [SI] damage) and on the time course of SI repair in chemotherapy-induced mucositis.

In the current study, Emu Oil improved colonic tissue damage associated with dextran sulphate sodium-induced colitis in Sprague Dawley rats and facilitated the repair process (**Chapter 2**). Improvements were indicated histologically by reduced intestinal damage severity scores and enhanced crypt compensatory elongation in the colon. These findings suggested the potential for Emu Oil to augment conventional treatment approaches for colitis. The effectiveness of Emu Oil in the colon provided impetus to further investigate Emu Oil action proximally, in the SI. In a rat model of chemotherapy (5-Fluorouracil; 5-FU)-induced mucositis, Emu Oil maintained SI villus height and crypt depth during the phase of maximal damage (**Chapter 3**). This was followed by an enhanced compensatory mucosal thickening, suggesting an acceleration of the repair process. Furthermore, Emu

Oil significantly decreased myeloperoxidase (MPO) activity, indicative of acute inflammation, in the jejunum and ileum of 5-FU-injected rats. Potent anti-inflammatory properties of Emu Oil were reaffirmed in NSAID (Indomethacin)-induced enteropathy, whereby MPO activity in the jejunum and ileum of Indomethacin-treated rats was markedly decreased following Emu Oil administration (**Chapter 4**).

Treatments for diseases such as coronary artery disease and GI disorders seek to minimise oxidative damage by free radicals through the use of antioxidants. Oils derived from ratites (flightless birds) predominantly comprise FA varying in composition between ratite species. The influence of farm location, rendering method, duration and storage mode was investigated for free radical scavenging activity (RSA) against 2,2-diphenyl-1-picrylhydrazyl and primary oxidation status of Ratite Oils (**Chapter 5**). Emu Oil conferred the greatest RSA compared to Ostrich and Rhea Oil, potentially attributed to its high unsaturated FA: saturated FA ratio and non-triglyceride fraction minor constituents. Rendering and storage variables impacted on Emu Oil RSA and primary oxidation.

This thesis identified Emu Oil as a safe, renewable and economical means to augment pharmaceutical options for GI disorders. A new mechanism of action for Emu Oil could represent a promotion of repair from injury together with decreased SI inflammation. This suggests potential for Emu Oil as an adjunct to conventional treatment approaches for colitis, cancer management and long-term NSAID usage.

DECLARATION

This work contains no material which has been accepted for the award of any other degree or diploma in any university or other tertiary institution and, to the best of my knowledge and belief, contains no material previously published or written by another person, except where due reference has been made in the text.

I give consent to this copy of my thesis when deposited in the University Library, being made available for loan and photocopying, subject to the provisions of the Copyright Act 1968. I also give permission for the digital version of my thesis to be made available on the web, via the University's digital research repository, the Library catalogue, and also through web search engines, unless permission has been granted by the University to restrict access for a period of time.

The author acknowledges that copyright of published works contained within this thesis (as listed below) resides with the copyright holder(s) of those works.

(1) SM Abimosleh, CD Tran, GS Howarth. Emu Oil: a novel therapeutic for disorders of the gastrointestinal tract? *Journal of Gastroenterology and Hepatology* 2012 May;27(5):857-61

Copyright: © *Journal of Gastroenterology and Hepatology Foundation and Blackwell Publishing Asia Pty Ltd.*

(2) SM Abimosleh, RJ Lindsay, RN Butler, AG Cummins, GS Howarth. Emu oil increases colonic crypt depth in a rat model of ulcerative colitis. *Digestive Diseases and Sciences* 2012 Apr;57(4):887-96

Copyright: © 2011, Springer Science+Business Media, LLC

Appendices

(3) KY Cheah, SEP Bastian, TMV Acott, **SM Abimosleh**, KA Lymn, GS Howarth. Grape Seed Extract Reduces Selected Disease Markers in the Proximal Colon of Dextran Sulphate Sodium-Induced Colitis in Rats. *Digestive Diseases and Sciences* 2012 Nov (epub ahead of print) DOI 10.1007/s10620-012-2464-1

Copyright: © 2012, Springer Science+Business Media New York

(4) AK Samanta, VA Torok, NJ Percy, **SM Abimosleh**, GS Howarth. Microbial fingerprinting detects unique bacterial communities in the faecal microbiota of rats with experimentally-induced colitis. *Journal of Microbiology* 2012 Apr;50(2):218-2

Copyright: © 2012, The Microbiological Society of Korea

(5) CD Tran, R Katsikeros, **SM Abimosleh**. Current and Novel Treatments for Ulcerative Colitis. *Ulcerative Colitis from Genetics to Complications*. InTech 2012: 189-211

Copyright: © 2004-2012, InTech – Open Access Company

(6) R Raghu Nadhanan, **SM Abimosleh**, YW Su, MA Scherer, GS Howarth, CJ Xian. Dietary emu oil supplementation suppresses 5-fluorouracil chemotherapy-induced inflammation, osteoclast formation, and bone loss. *American Journal of Physiology Endocrinology and Metabolism* 2012 Jun;302(11):E1440-9

Copyright: © 2012 the American Physiological Society

Suzanne Mashtoub Abimosleh

Date

ACKNOWLEDGMENTS

I am sincerely grateful to my principal supervisor, Professor Gordon Howarth, for his outstanding mentorship, wisdom, encouragement, friendship and spirit of adventure throughout my exciting PhD journey. It has been a true privilege to work with Professor Howarth who has the substance of pure genius, an unimaginable wealth of knowledge and a fantastic sense of humour. I am also extremely grateful to Professor Howarth for providing me with the opportunity to publish and present my work extensively around the world.

I would like to thank my co-supervisor Dr Cuong Tran who has provided invaluable research input and encouraged me throughout my PhD candidature.

I wish to extend my deepest appreciation to the Gastroenterology Department, Women's and Children's Hospital including the Head of Department, Dr David Moore. I will forever treasure the support, fun times and company provided by the Gastroenterology family.

A special thanks to Kerry Lymn, "World's Fastest Gavage Expert", for her friendship, support and significant assistance with animal trials. I would also like to acknowledge my dear friend and colleague Dr Amy Cheah for her great company and help with animal trials. Sincere thanks to Chris Gregory from Emu Tracks Pty Ltd for supplying the Emu Oil used throughout my PhD and for assisting with oil oxidation analyses.

I would like to acknowledge the Discipline of Physiology, School of Medical Sciences, The University of Adelaide, in particular, the Postgraduate Coordinator, Dr David O'Carroll.

I wish to extend my heartfelt gratitude and deepest love to my wonderful husband, soul mate and best friend, Walid Abimosleh. I am extremely grateful for his endless love, support and fantastic company throughout my PhD journey.

My beautiful mum, Ann Asma Mashtoub, to whom I am eternally indebted; without her unconditional love, continual encouragement to strive for the best, strength (and delicious food!), I would be forever lost. To my dad, Steve Zouhair Mashtoub, my amazing siblings Nawal, Joanne, Kamahl, Leanne, brother-in-law Samir and my niece, princess Eva; their love, support and friendship have been my guiding light.

I gratefully acknowledge the funding sources of my PhD Scholarships; The Australian Postgraduate Award and the Rural Industries Research and Development Corporation. I appreciate the generous travel support provided by The 2010 Trevor Prescott Freemasons Memorial Scholarship, Nutrition Society of Australia, Gastroenterological Society of Australia, AstraZeneca Junior Travel Award, Healthy Development Adelaide and Rural Industries Research and Development Corporation.

~ In loving memory of my dear friend Pat ~

*“If we never had a cloudy day with wind and rain and thunder,
we would never see a rainbow and rejoice in all its wonder...” Pat Westin*

PUBLICATIONS ARISING FROM THIS THESIS

SM Abimosleh, CD Tran, GS Howarth. Emu Oil: a novel therapeutic for disorders of the gastrointestinal tract? *Journal of Gastroenterology and Hepatology* 2012 May;27(5):857-61

SM Abimosleh, RJ Lindsay, RN Butler, AG Cummins, GS Howarth. Emu oil increases colonic crypt depth in a rat model of ulcerative colitis. *Digestive Diseases and Sciences* 2012 Apr;57(4):887-96

R Raghu Nadhanan, **SM Abimosleh**, YW Su, MA Scherer, GS Howarth, CJ Xian. Dietary emu oil supplementation suppresses 5-fluorouracil chemotherapy-induced inflammation, osteoclast formation, and bone loss. *American Journal of Physiology Endocrinology and Metabolism* 2012 Jun;302(11):E1440-9

AK Samanta, VA Torok, NJ Percy, **SM Abimosleh**, GS Howarth. Microbial fingerprinting detects unique bacterial communities in the faecal microbiota of rats with experimentally-induced colitis. *Journal of Microbiology* 2012 Apr;50(2):218-2

KY Cheah, SEP Bastian, TMV Acott, **SM Abimosleh**, KA Lymn, GS Howarth. Grape Seed Extract Reduces Selected Disease Markers in the Proximal Colon of Dextran Sulphate Sodium-Induced Colitis in Rats. *Digestive Diseases Sciences* 2012 Nov (epub ahead of print) DOI 10.1007/s10620-012-2464-1

CD Tran, R Katsikeros, **SM Abimosleh**. Current and Novel Treatments for Ulcerative Colitis. *Ulcerative Colitis from Genetics to Complications* InTech 2012: 189-211

SM Abimosleh, DC Bennett, CD Tran, GS Howarth. Processing of Ratite Oils Affects Primary Oxidation Status, Resulting in Greater Radical Scavenging Properties for Emu Oil Compared to Rhea and Ostrich Oils. *Journal of Food Science* 2012; Under review

SM Abimosleh, CD Tran, GS Howarth. Emu Oil Expedites Small Intestinal Repair Following 5-Fluorouracil-Induced Mucositis in Rats. *Experimental Biology and Medicine* 2012; Under review

SM Abimosleh, CD Tran, GS Howarth. Emu Oil Reduces Small Intestinal Inflammation in the Absence of Clinical Improvement in a Rat Model of Indomethacin-Induced Enteropathy. *Evidence-Based Complementary and Alternative Medicine* 2012; Under review

Publications arising from conferences

SM Abimosleh, Z Lotfollahi, J Papini, L Hoyle, D Stomaci, E Penascoza, CD Tran, KA Lymn, RN Butler and GS Howarth. Orally-administered Emu Oil maintains intestinal goblet cell numbers and improves barrier function in a rat model of chemotherapy-induced mucositis.

1. Multinational Association of Supportive Care in Cancer (MASCC), New York, USA. *Supportive Care in Cancer* 2012; 20(1):627
2. Australian Gastroenterology Week (AGW), Adelaide, South Australia. *Journal of Gastroenterology and Hepatology* 2012; 27(4):17

AK Samanta, VA Torok, NJ Percy, **SM Abimosleh** and GS Howarth. Microbial fingerprinting detects unique bacterial communities in the faecal microbiota of rats with experimentally-induced colitis. AGW, Adelaide, South Australia. *Journal of Gastroenterology and Hepatology* 2012; 27(4):28

SM Abimosleh, CD Tran and GS Howarth. Emu Oil enhances histological repair in a rat model of chemotherapy-induced intestinal mucositis. Joint Annual Scientific Meeting of the Nutrition Society of New Zealand and the Nutrition Society of Australia, Queenstown, New Zealand. *Australasian Medical Journal* 2011; 4(12):104-716

2nd Prize for Best Oral Presentation

SM Abimosleh, CD Tran, GS Howarth. Emu Oil Promotes Repair From Chemotherapy-Induced Intestinal Mucositis In Rats

1. MASCC, Athens, Greece. *Supportive Care in Cancer* 2011; 19(2):67-370
2. AGW, Brisbane, Queensland. *Journal of Gastroenterology and Hepatology* 2011; 26:15-21

SM Abimosleh, RN Butler, GS Howarth. Effects of emu oil during the recovery phase of chemotherapy-induced intestinal mucositis in rats.

1. AGW, Gold Coast, Queensland. *Journal of Gastroenterology and Hepatology* 2010; 25:A2-A17
2. Nutrition Society of Australia, Perth, WA. *Australasian Medical Journal* 2010; 3

S Mashtoub, RJ Lindsay, KA Lymn, MS Geier, RN Butler, GS Howarth. Emu Oil Improves Parameters of Intestinal Integrity in Rat Models of Inflammatory Bowel Disease and Intestinal Mucositis. MASCC, Rome, Italy. *Supportive Care in Cancer* 2009; 17(7):857-1039

M Vu, B Hoang, XD Ding, M Sultani, **S Mashtoub**, RJ Lindsay, KA Lymn, RN Butler, GS Howarth. A safety study of emu oil as a potential adjunctive treatment for ulcerative colitis and mucositis. AGW, Sydney, NSW. *Journal of Gastroenterology and Hepatology* 2009; 24:A239-A247

Poster of Merit Prize

S Mashtoub, RJ Lindsay, KA Lymn, TWV Acott, R Yazbeck, AG Cummins, RN Butler, GS Howarth. Emu oil increases crypt depth but only minimally affects other indicators of colonic integrity in a rat model of colitis. AGW, Sydney, NSW. *J Gastro Hepatol* 27: A239-A247 (2009)

THESIS STRUCTURE

This thesis is presented as a ‘Thesis by Publication’ and includes a combination of published manuscripts and papers under review. Each manuscript is formatted according to the journal specifications.

Furthermore, additional publications arising from the research described in this thesis are included as Appendices.

CHAPTER 1

REVIEW OF THE LITERATURE

CONTEXT STATEMENT

The work contained in this chapter has been published in the *Journal of Gastroenterology and Hepatology*.

SM Abimosleh, CD Tran, GS Howarth. Emu Oil: a novel therapeutic for disorders of the gastrointestinal tract? *Journal of Gastroenterology and Hepatology* 2012 May;27(5):857-61

Chapter 1 provides an overview of intestinal disorders characterised by inflammation and identifies the need to broaden therapeutic approaches to attenuate the inflammatory response and facilitate mucosal healing. Furthermore, this chapter explores Emu Oil literature, leading to identification of Emu Oil as potential treatment option for inflammatory intestinal disorders.

STATEMENT OF AUTHORSHIP

Emu Oil: A novel therapeutic for disorders of the gastrointestinal tract?

Journal of Gastroenterology and Hepatology 2012; 27: 857-61

Suzanne Mashtoub ABIMOSLEH (Candidate)

Conducted a thorough review of the literature, prepared manuscript.

I hereby certify that the statement of contribution is accurate.

Signed

Date 3/12/12

Cuong D. Tran

Contributed to manuscript preparation.

I hereby certify that the statement of contribution is accurate.

Signed

Date 27/11/12

Gordon S. Howarth

Contributed to manuscript preparation and revision.

I hereby certify that the statement of contribution is accurate.

Signed

Date 27/11/12

Abimosleh, S.M., Tran, C.D. & Howarth, G.S. (2012) Emu oil: a novel therapeutic for disorders of the gastrointestinal tract?

Journal of Gastroenterology and Hepatology, v. 27(5), pp. 857-861

NOTE:

This publication is included on pages 4-8 in the print copy of the thesis held in the University of Adelaide Library.

It is also available online to authorised users at:

<http://doi.org/10.1111/j.1440-1746.2012.07098.x>

CHAPTER 2

EMU OIL INCREASES COLONIC CRYPT DEPTH IN A RAT

MODEL OF ULCERATIVE COLITIS

CONTEXT STATEMENT

The work contained in this chapter has been published in *Digestive Diseases and Sciences*.

SM Abimosleh, RJ Lindsay, RN Butler, AG Cummins, GS Howarth. Emu oil increases colonic crypt depth in a rat model of ulcerative colitis. *Digestive Diseases and Sciences* 2012 Apr;57(4):887-96

Previous literature identified topically applied Emu Oil as a potent anti-inflammatory agent in a mouse model of Croton Oil-induced auricular swelling (Yoganathan *et al.* 2003) and experimentally-induced polyarthritis (Snowden and Whitehouse 1997). More recently, orally administered Emu Oil improved small intestinal damage associated with chemotherapy-induced mucositis (Lindsay *et al.* 2010). This prompted further investigation into the effects of orally administered Emu Oil in the context of colitic damage, as described in **Chapter 2**.

The work contained in this chapter formed the basis of my Honours research, awarded in 2008. This work was completed and the manuscript was published in 2012 during the tenure of my PhD. It was important to include this manuscript as **Chapter 2** of my thesis to identify dose-dependent effects of Emu Oil and for subsequent applications in **Chapters 3 and 4**. Furthermore, this manuscript provides greater insight into the potential efficacy of Emu Oil in the colon, highlighting its bioactivity in the distal GI tract.

Further publications arising from this chapter included **Appendices 1, 2 and 3**. **Appendix 1** describes the partial protective properties of grape seed extract assessed histologically, utilising the same rat model of colitis to that employed in **Chapter 2**. Furthermore,

Appendix 2 identified the changes in microbiota associated with colitis in rats, using faecal microbial profiling. Restoring microbial homeostasis by targeting colitis-associated bacteria was implicated as a novel therapeutic strategy for colitis. **Appendix 3** is a published book chapter which provides a thorough literature review on the current and novel treatments for ulcerative colitis, including animal models.

Appendix 1

KY Cheah, SEP Bastian, TMV Acott, **SM Abimosleh**, KA Lynn, GS Howarth. Grape Seed Extract Reduces Selected Disease Markers in the Proximal Colon of Dextran Sulphate Sodium-Induced Colitis in Rats. *Digestive Diseases Sciences* 2012 Nov (epub ahead of print) DOI 10.1007/s10620-012-2464-1

Appendix 2

AK Samanta, VA Torok, NJ Percy, **SM Abimosleh**, GS Howarth. Microbial fingerprinting detects unique bacterial communities in the faecal microbiota of rats with experimentally-induced colitis. *Journal of Microbiology* 2012 Apr;50(2):218-2

Appendix 3

CD Tran, R Katsikeros, **SM Abimosleh**. Current and Novel Treatments for Ulcerative Colitis. *Ulcerative Colitis from Genetics to Complications* InTech 2012: 189-211

STATEMENT OF AUTHORSHIP

Emu oil Increases Colonic Crypt Depth in a Rat Model of Ulcerative Colitis

Digestive Diseases and Sciences 2012; 57: 887-96

Suzanne Mashtoub ABIMOSLEH (Candidate)

Conducted all animal trials and experimental work, analysed data, interpreted results, prepared figures and manuscript.

I hereby certify that the statement of contribution is accurate.

Signed

Date 3/12/12

Ruth J. Lindsay

Assisted with animal trials, experimental work and data analyses.

I hereby certify that the statement of contribution is accurate.

Signed

Date 24/11/12

Ross N. Butler

Contributed to experimental conceptualisation and design, data interpretation.

I hereby certify that the statement of contribution is accurate.

Signed

Date 27/11/2012

Adrian G. Cummins

Contributed to experimental conceptualisation and design, data interpretation.

I hereby certify that the statement of contribution is accurate.

Signed

Date 25/11/2012

Gordon S. Howarth

Contributed to experimental conceptualisation and design, data interpretation, critical manuscript evaluation.

I hereby certify that the statement of contribution is accurate.

Signed

Date 27/11/12

Abimosleh, S.M., Lindsay, R.J., Butler, R.N., Cummins, A.G. & Howarth, G.S. (2012) Emu oil increases colonic crypt depth in a rat model of ulcerative colitis. *Digestive Diseases and Sciences*, v. 57(4), pp. 887-896

NOTE:

This publication is included on pages 14-23 in the print copy of the thesis held in the University of Adelaide Library.

It is also available online to authorised users at:

<http://doi.org/10.1007/s10620-011-1979-1>

CHAPTER 3

**EMU OIL EXPEDITES SMALL INTESTINAL REPAIR FOLLOWING
5-FLUOROURACIL-INDUCED MUCOSITIS IN RATS**

CONTEXT STATEMENT

The work contained in this chapter is currently under review in *Experimental Biology and Medicine*.

SM Abimosleh, CD Tran, GS Howarth. Emu Oil Expedites Small Intestinal Repair Following 5-Fluorouracil-Induced Mucositis in Rats. *Experimental Biology and Medicine* 2012; Under review

The effectiveness of Emu Oil in the colon (**Chapter 2**) provided impetus to further investigate Emu Oil action proximally, in the SI. Furthermore, Lindsay *et al.* (2010) in a rat model of mucositis, proposed a potential mechanism of action for Emu Oil, speculating on the possibility of a more rapid rate of recovery. **Chapter 3** therefore describes the effect of orally-administered Emu Oil on the time course of intestinal repair in a rat model of chemotherapy-induced mucositis.

The experimental model of mucositis employed in **Chapter 3** was also utilised in a jointly-authored manuscript published in *Cancer, Biology and Therapy*.

Wright TH, Yazbeck R, Lymn KA, Whitford EJ, Cheah KY, Butler RN, Feinle-Bisset C, Pilichiewicz AN, **Mashtoub S**, GS Howarth. The herbal extract, Iberogast, improves jejunal integrity in rats with 5-Fluorouracil (5-FU)-induced mucositis. *Cancer, Biology and Therapy* 2009 May;8(10):923-9

Appendix 4 used bone extracted from the Chapter 4 animal trial. The manuscript demonstrated that Emu Oil could counter chemotherapy (5-FU)-induced inflammation in

bone, preserved osteoblasts and suppressed osteoclast formation. Overall, Emu Oil was identified as a useful agent in preventing chemotherapy-induced bone loss.

Appendix 4

R Raghu Nadhanan, **SM Abimosleh**, YW Su, MA Scherer, GS Howarth, CJ Xian. Dietary emu oil supplementation suppresses 5-fluorouracil chemotherapy-induced inflammation, osteoclast formation, and bone loss. *American Journal of Physiology Endocrinology and Metabolism* 2012 Jun;302(11):E1440-9

STATEMENT OF AUTHORSHIP

Emu Oil Expedites Small Intestinal Repair Following 5-Fluorouracil-Induced Mucositis in Rats

Experimental Biology and Medicine 2012; Under review

Suzanne Mashtoub ABIMOSLEH (Candidate)

Conducted all animal trials, experimental work, analysed data, interpreted results, prepared figures and manuscript.

I hereby certify that the statement of contribution is accurate.

Signed

Date 3/12/12

Cuong D. Tran

Contributed to experimental conceptualisation and design, data interpretation.

I hereby certify that the statement of contribution is accurate.

Signed

Date 27/11/12

Gordon S. Howarth

Contributed to experimental conceptualisation and design, data interpretation, critical manuscript evaluation.

I hereby certify that the statement of contribution is accurate.

Signed

Date 27/11/12

Emu Oil Expedites Small Intestinal Repair Following 5-Fluorouracil-Induced Mucositis in Rats

Suzanne M Abimosleh^{1,2}, Cuong D Tran^{1,2} and Gordon S Howarth^{1,2,3*}

¹Department of Gastroenterology, Women's and Children's Hospital, North Adelaide, South Australia

²Discipline of Physiology, School of Medical Sciences, Faculty of Health Sciences, The University of Adelaide, Adelaide, South Australia

³School of Animal and Veterinary Sciences, The University of Adelaide, Roseworthy Campus, Roseworthy, South Australia

*Corresponding author:

Professor Gordon S Howarth

School of Animal and Veterinary Sciences

The University of Adelaide

Roseworthy Campus,

South Australia

Australia, 5371

Phone: 618-8313-7885

Fax: 618-8313-7972

Email: gordon.howarth@adelaide.edu.au

Short Title: Emu Oil expedites intestinal repair in mucositis

ABSTRACT

Mucositis resulting from cancer chemotherapy is characterized by intestinal inflammation and ulceration. Previously, Emu Oil (EO) improved intestinal architecture (Br J Nutr, 2010) in a rat model of chemotherapy-induced mucositis. We investigated EO for its further potential to promote intestinal repair in this mucositis model. Female Dark Agouti rats (n=8/group) were gavaged with water, Olive Oil (OO) or EO once daily (1ml), injected with 5-Fluorouracil (5-FU) or saline, on day 5 and euthanized on day 8, 9, 10 or 11. Intestinal villus height (VH) and crypt depth (CD), neutral mucin-secreting goblet cell [GC] count, myeloperoxidase (MPO) activity and selected cytokines were quantified. $p < 0.05$ was considered significant. In 5-FU-injected rats, only EO administration significantly increased VH in the ileum (day 8), jejunum and JI (days 8 and 9) compared to 5-FU controls ($p < 0.05$). GC count was significantly reduced by 5-FU (jejunum: days 8 and 9; ileum: day 8; $p < 0.05$) and EO increased ileal GC on days 10 and 11 compared to 5-FU controls. MPO activity was significantly increased in jejunum (days 8 and 9) and ileum (day 8) following 5-FU injection, compared to normal controls ($p < 0.05$). Both EO and OO significantly reduced jejunal MPO on days 8 and 9, however, only EO decreased ileal MPO on day 8. Cytokine levels were not significantly affected by either oil or 5-FU administration at the day 8 time point. Promotion of repair from injury could represent a new mechanism of action for Emu Oil, suggesting potential as an adjunct to conventional treatment approaches for cancer management.

Keywords: chemotherapy, intestinal mucositis, Emu Oil, repair, rat

INTRODUCTION

Mucositis is one of the most common and debilitating side-effects of cancer treatment¹, developing in approximately 40% of patients undergoing chemotherapy and up to 60% of patients undergoing high-dose chemotherapy^{2, 3}. This condition manifests due to the inability of chemotherapy agents to discriminate between normal and neoplastic cells⁴, resulting in ulcerating lesions, inflammation and deterioration of the mucosal membranes lining the alimentary tract⁵. The mucosa of the mouth (oral mucositis) and small intestine (gastrointestinal mucositis) is most commonly affected.

Symptoms of oral and gastrointestinal mucositis can be extremely debilitating, and severely impact on quality of life for the patient. Incidence and severity can vary, depending on intensity, class of drug and radiation dosing protocol². Sufferers of mucositis may experience nausea, bloating, diarrhea and severe abdominal pain^{2, 5}.

The pathogenesis of mucositis is believed to be a 5 stage process^{2, 6-8}. Two of the principles of mucositis development are the generation of reactive oxygen species which directly damage cells, tissue and blood vessels⁷ and the up-regulation of pro-inflammatory cytokines including tumor necrosis factor- α (TNF- α), interferon- γ (IFN- γ), interleukin-1 β (IL-1 β) and interleukin-6 (IL-6) eliciting further tissue damage⁶. Accordingly, agents capable of neutralizing reactive oxygen species and decreasing inflammation could be valuable adjuncts to mucositis treatment.

Developing treatments for intestinal mucositis has proven problematic, as not all treatments are effective for both oral and gastrointestinal mucositis. Furthermore, potential anti-mucotoxic agents must protect the mucosa without interfering with effects of cytotoxins on the neoplasm. Thus far, considerable effort has been expended to find an

effective method for treating mucositis, however it continues to be a dose limiting complication of cancer therapy⁹. Recent studies into mucositis treatment have focused on hormones, growth factors and cytokines which modulate immune responses, cell proliferation and apoptosis¹. Many naturally-sourced compounds have suggested potential such as grape seed extract,¹⁰ attributed to proanthocyanidin-mediated antioxidant and anti-inflammatory effects, certain probiotics^{11, 12} which modulate the microbiota and inhibit pro-inflammatory cytokine expression and even plant-extracts such as Iberogast¹³.

Efforts to ameliorate chronic inflammatory conditions, including ulcerative colitis and rheumatoid arthritis, have been directed towards increasing dietary levels of polyunsaturated fatty acids (PUFAs) which include omega-3 and omega-6 found in marine-derived oils including Fish Oil^{14, 15} and the New Zealand Green-Lipped mussel extract, Lyprinol^{16, 17}. Recently, attention has been directed towards animal-derived oils with high levels of PUFAs, for example, oil derived from the Australian ratite bird, the Emu (*Dromaius novaehollandiae*).

Traditionally endemic to Australia, the Emu is now farmed around the world for its meat, leather and most recently, its FA-rich oil^{18, 19}. Indigenous Australians first used Emu Oil to facilitate wound healing, pain alleviation and treatment of inflamed joints^{20, 21}. Topical application of Emu Oil to mice with adjuvant-induced inflammation decreased levels of TNF- α and other pro-inflammatory cytokines²², involved in the pathogenesis of mucositis⁶. In a preliminary study in rats, Abimosleh *et al.*¹⁸ indicated that orally-administered Emu Oil improved selected parameters associated with the manifestation of experimentally-induced colitis, characterized by inflammation and ulceration of the large bowel. Furthermore, Lindsay *et al.*,²³ in a rat model of mucositis, proposed a potential mechanism

of action for Emu Oil, speculating on the possibility of a more rapid rate of recovery during the recovery phase of mucositis.

Accordingly, we hypothesized that orally-administered Emu Oil would accelerate recovery of the intestine following chemotherapy damage. To this end, we investigated the effects of Emu Oil on the time-course of intestinal repair in a rat model of 5-Fluorouracil (5-FU)-induced mucositis.

MATERIALS AND METHODS

General Experimental Procedures

Animal Studies. Throughout acclimatization and the experimental period, Female Dark Agouti rats (120-140g) were individually housed in metabolism cages (Tecniplast, Exton, PA, USA), at room temperature with a light:dark cycle of 12 hours. All rats were given *ad libitum* access to food (standard 18% casein-based diet²⁴) and water, and were acclimatized for 2 days prior to experimentation. Animal experimentation was conducted across several identical trials in which lower numbers of rats from all treatment groups (usually 2-3) were represented. All animal studies were conducted in compliance with the Australian Code of Practice for the Care and Use of Animals, and were approved by the Animal Ethics Committees of the Children, Youth and Women's Health Service and The University of Adelaide.

Rats were randomly assigned to six groups (n=8/group); Group 1: Saline+Water, Group 2: Saline+Olive Oil, Group 3: Saline+Emu Oil, Group 4: 5-FU+Water, Group 5: 5-FU+Olive Oil and Group 6: 5-FU+Emu Oil. Water, Olive Oil or Emu Oil (1ml) was administered once daily via oro-gastric gavage from days 0 to 8, 9, 10 or 11. On day 5, all rats were intraperitoneally injected with a single dose of saline or the chemotherapeutic agent, 5-Fluorouracil (5-FU, Mayne Pharma Pty Ltd, Mulgrave, Victoria, Australia; 150mg/kg). 5-FU is a pyrimidine analogue belonging to the anti-metabolite group of drugs that has customarily required intravenous administration due to poor bioavailability when administered orally²⁵.

Emu and Olive Oil Preparation. Emu Oil, sourced from Emus farmed in North-Eastern South Australia, was prepared utilizing specific methodologies developed for Technology Investment Corporation by Emu Tracks (Marleston, Adelaide, South Australia). Briefly,

these processes involved the rendering and filtration of Emu adipose tissue, with appropriate considerations for delivery of quality assurance and product consistency. Fatty acid analysis of Emu Oil and Olive Oil was carried out using gas chromatography, as described previously²⁶ (Table 1). Olive Oil (Conga Foods, Spain) was selected as the control oil due to its high level of oleic acid; similar to that of Emu Oil. The Olive Oil control was included to determine any non-specific oil-related effects for subsequent comparison with Emu Oil. Both Emu Oil and Olive Oil were individually stored at 4°C in 50ml opaque containers.

Daily Metabolic Data and Disease Activity Index

Body weight, food and water intake, and fecal and urine output were monitored and measured daily. The severity of mucositis was assessed daily, using a disease activity index (DAI), which scored body weight loss, rectal bleeding, stool consistency, and overall general condition of the animal, increasing in severity on a scale of 0-3 for each parameter, which was totaled to achieve an overall DAI, as described previously^{27, 28}. Overall condition was determined by (1) mobility/agility: healthy rats were considered quite active, whereas rats affected by 5-FU characteristically became very weak and feeble, sitting hunched with very little movement and (2) fur: healthy rats were well-groomed with fur flat to the body, whereas 5-FU-injected rats became scruffy in appearance, with ruffled fur.

¹³C- Sucrose Breath Test

Immediately prior to kill (day 8, 9, 10 or 11), the ¹³C-sucrose breath test (SBT) was performed as a non-invasive assessment of the functional status of small intestinal health and to ensure safety of Emu Oil²⁹. Briefly, following an overnight fast, a baseline breath sample was collected at t=0. Rats were then gavaged with 1ml of a 25% ¹³C-labeled sucrose solution (BDH, Merck Pty Ltd, Kilsyth, Victoria, Australia); breath samples

collected every 15 minutes for 120 minutes, and samples were analyzed for $^{13}\text{CO}_2$ concentration using an isotope ratio mass spectrometer (Europa Scientific, Crewe, Cheshire, UK)⁴. Data were expressed as mean percentage cumulative dose of ^{13}C recovered at 90 minutes post-sucrose administration (%CD90). This provides an indirect indication of the rate at which sucrose is cleaved by the enzyme sucrase in the small intestine, and therefore, the level of sucrase present on small intestinal enterocytes (brush border).

Tissue Collection

On day 8, 9, 10 or 11, rats were sacrificed by CO_2 asphyxiation followed by cervical dislocation. Cardiac puncture was performed to remove whole blood for subsequent cytokine analysis of serum. The gastrointestinal tract was removed, measured, emptied of contents and weighed. Segments of the small intestinal tract (jejunum, jejunum-ileum junction [JI] and ileum; 2cm) were removed and placed in 10% buffered formalin for histological analyses. Additionally, segments (4cm) directly adjacent to the corresponding histological samples were collected and snap-frozen in liquid nitrogen for biochemical analysis. Samples were stored at -80°C until prepared for analysis by homogenization in 10mM phosphate buffer. The remaining visceral organs (thymus, lungs, heart, liver, kidneys and spleen) were weighed and discarded.

Histological Analyses

Mucosal Measurements. Small intestinal samples were transferred from 10% buffered formalin to 70% ethanol 24 hours post-collection. Specimens were then routinely processed and embedded in paraffin wax and sections ($4\mu\text{m}$) were stained with haematoxylin and eosin (H&E). Measurements of villus height (VH) and crypt depth (CD)

in the small intestine were determined for 40 well-orientated villi and crypts per small intestinal tissue section per rat and a mean value was then obtained³⁰.

Neutral Mucin-Secreting Goblet Cell Count. Following routine processing and embedding in paraffin wax, additional 4µm sections were mounted on poly-L-lysine-coated slides. Sections were deparaffinized using Histolene (Fronine Laboratory Supplies Pty Ltd, Riverstone, New South Wales, Australia) and rehydrated in preparation for neutral mucin-secreting goblet cell staining. Sections were subjected to mild acid hydrolysis to eliminate the contribution of sialic acid residues prior to periodic acid-Schiff staining, which involved immersing sections in sulphuric acid for 60 minutes at 80⁰C in a water bath. After rinsing with tap and distilled water, sections were immersed in periodic acid solution (Sigma, St. Louis, MO, USA) for 20 minutes, washed and immersed in Schiff's reagent (Sigma, St. Louis, MO, USA) for a further 20 minutes. Sections were rinsed in tap water for 10 minutes and dehydrated. Neutral mucin-secreting goblet cells stained pink-purple and were counted in a blinded fashion on one side of 40 well-orientated villi per small intestinal tissue section per rat.

All histological analyses were performed in a blinded fashion, using an Olympus BH-2 light microscope (Tokyo, Japan) with Sony digital camera (Tokyo, Japan) and Image Pro Plus Software Package Version 4.5.1.27 (Media Cybernetics, Silver Spring, MD, USA) for villus and crypt measurements and Image J Software Version 1.44p (National Institutes of Health, USA) for neutral mucin-secreting goblet cell counting.

Biochemical Analyses

Myeloperoxidase Activity. Myeloperoxidase (MPO) levels in the small intestine were determined as an indicator of neutrophil infiltration, and hence, acute inflammation, using

techniques described by Howarth *et al*³¹. Thawed, homogenised samples were centrifuged at 13,000g for 12 minutes, after which the supernatant was discarded, and the tissue homogenate was re-suspended in 200 μ L of 0.5% hexadecyltrimethyl ammonium bromide buffer, a detergent (Sigma Chemicals, Castle Hill, NSW, Australia). After vortexing for 2 minutes, samples were again centrifuged at 13,000g for 2 minutes. Background, negative and positive control samples (50 μ L) and the supernatants of each test sample were then aliquoted into duplicate wells of a microtitre 96-well plate. Following the addition of a reaction solution (200 μ L to each well; 4.2mg of O-dianisidine dihydrochloride reagent, 12.5 μ L H₂O₂, 2.5ml potassium phosphate buffer [pH 6.0], 22.5ml distilled water) the change in absorbance was measured at 450 nm at 1 minute intervals for 15 minutes with a spectrophotometer (Victor X4 Multilabel Reader, Perkin Elmer, Singapore). Data were expressed as units of MPO per gram of tissue.

Cytokine Analyses. Whole blood collected via cardiac puncture during kill was immediately refrigerated at 4⁰C for approximately 2 hours to allow for clotting. Blood samples collected on day 8 were centrifuged at 1,000g for 10 minutes at 4⁰C, serum collected and stored at -80⁰C for subsequent cytokine analysis.

Multiplexed analyses of cytokines with the Bio-Plex system utilizes suspension array of 12 sets of beads (Bio-Plex Rat Cytokine 12-plex panel; Bio-Rad Laboratories, Hercules, CA, USA) internally dyed with different ratios of two spectrally distinct fluorochromes. Each set of beads is coupled with a monoclonal antibody raised against granulocyte macrophage-colony stimulating factor (GM-CSF), interferon- γ (IFN- γ), interleukins (IL)-1 α , 1 β , 2, 4, 5, 6, 10, 12p70 and 13 and tumor necrosis factor- α (TNF- α). Briefly, the beads were successively incubated (1 hour, shaking in the dark at room temperature) with duplicates of diluted standards and thawed serum samples (50 μ L), followed by a further

incubation (30 minutes, shaking in the dark at room temperature) with biotinylated detector antibodies (25µL) and a final incubation (10 minutes, shaking in the dark at room temperature) with phycoerythrin (PE)-conjugated streptavidine (50µL; PE serves as the fluorescence indicator) in a 96-well plate. Between each incubation, beads were washed to remove unbound protein using wash buffer via magnetic separation (Bio-Plex Pro II wash station, Bio-Rad Laboratories, Hercules, CA, USA). Cytokine levels were measured on a Bio-Plex 200 system (Bio-Rad Laboratories, Hercules, CA, USA). Principally, a red laser excites the beads whilst a green laser excites PE to quantify the capture analyte. Eight point standard curves were obtained and serum cytokine concentration values (expressed as pg/ml) were analysed by Bio-Plex Manager 6.0 Software (Bio-Rad Laboratories, Hercules, CA, USA).

Statistical Analyses

Statistical comparisons were conducted using SPSS version 16.0 for Windows (SPSS Inc., Chicago, IL, USA). All data sets were tested for normality of distribution using the Shapiro-Wilk statistic. Body weight and food intake data were analysed using a repeated measures analysis of variance (ANOVA) with LSD pair-wise comparisons *post hoc* test to compare the differences both amongst groups and within groups across the duration of the trial. All other metabolic data were analysed using a one-way ANOVA and Tukey's *post hoc* test to compare groups during each period; prior to (days 0-4) and post (days 5-8, 9, 10 or 11) saline or 5-FU injection. SBT, kill data, villus height and crypt depth, neutral mucin-secreting goblet cell count, MPO activity and cytokines were analysed using a one-way ANOVA with Tukey's *post hoc* test. All parametric data were expressed as mean with their standard errors. DAI comparisons between groups each day were made using a Kruskal Wallis test with Mann-Whitney U-tests and expressed as median (range). For all analyses, $p < 0.05$ was considered significant.

RESULTS

Daily Metabolic Data

Prior to saline or 5-FU injection (days 0-4), all rats gained body weight ($p < 0.001$), with no significant differences amongst groups ($p > 0.05$; Figure 1a). Following saline administration, all normal rats gained body weight on days 5-10, including those treated with Olive Oil and Emu Oil ($p < 0.001$). However, between days 6-10, Emu Oil treatment resulted in a reduced gain in body weight compared to normal controls (days 7 and 8; $p < 0.01$, days 6, 9 and 10; $p < 0.05$; Figure 1b). A temporal effect was observed following 5-FU injection, such that body weight significantly decreased from days 6-8 and then began to increase from days 8-10 (6%; $p < 0.01$). Furthermore, in 5-FU-injected rats, body weight significantly decreased following Olive Oil and Emu Oil administration from days 6-9 (Olive Oil: 4%; Emu Oil: 5%) which then began to increase on day 10 ($p < 0.001$). Body weight was significantly lower in 5-FU-injected rats treated with Emu Oil compared to Olive Oil treatment on days 9 ($p < 0.05$) and 10 ($p < 0.05$; Figure 1b).

During the period prior to saline or 5-FU injection (days 1-4), food intake was significantly lower ($p < 0.001$) following Olive Oil (23%) and Emu Oil (22%) administration compared to normal controls (Figure 2a). This effect was also observed throughout the post-saline injection period (days 5-10; $p < 0.001$; Figure 2b). 5-FU significantly reduced food intake between days 5-9 ($p < 0.001$) compared to normal controls (maximal decrease on day 8: 58%), which was normalized by day 10. In 5-FU-injected rats, Olive Oil and Emu Oil administration significantly decreased daily food intake compared to 5-FU controls (days 6-10; $p < 0.001$). A temporal effect was observed in all 5-FU groups, such that the lowest food intake occurred on day 8, which increased across days 8-10 ($p < 0.001$; Figure 2b).

Total water intake, urine and fecal output were not significantly affected by oil treatments or 5-FU across all kill groups for time periods prior to (days 0-4) and post (days 5-8, 9, 10 or 11) saline or 5-FU injection (data not shown).

Disease Activity Index (DAI)

DAI was not significantly affected following Olive Oil or Emu Oil treatment in normal animals ($p > 0.05$; Table 2). 5-FU significantly increased DAI on days 7-11 compared to normal controls (days 7-10; $p < 0.001$, day 11; $p < 0.05$), with maximal disease activity on day 8 [median score 3 (range: 2-10)]. In 5-FU-injected rats, Olive Oil significantly increased DAI on days 6 ($p < 0.05$) and 8-10 ($p < 0.001$) compared to 5-FU controls, attributed to increases in all DAI parameters (Table 2). Emu Oil administration in 5-FU-injected rats significantly increased DAI on days 6 ($p < 0.05$), 7 ($p < 0.01$) and 8 ($p < 0.05$) compared to 5-FU controls, primarily attributed to increased stool consistency scores. In 5-FU-injected rats, DAI was significantly lower following Emu Oil treatment compared to Olive Oil treatment on days 8 and 9 ($p < 0.001$).

¹³C- Sucrose Breath Test

Brush border sucrase activity was used as an indicator of the health and maturity of epithelial cells which line the small intestine (SI), assessed using the SBT. Oil treatment did not significantly affect overall functional SI health status in normal animals on any kill day ($p > 0.05$; Figure 3). On day 8, 5-FU significantly decreased percentage cumulative dose of ¹³C at 90 minutes (%CD90) compared to healthy controls (67% decrease; $p < 0.05$), however, this was normalised by day 9 (Figure 3).

Visceral and Gastrointestinal Organ Weights and Lengths

Organ weights were expressed as a proportion of body weight. There were no significant differences in visceral organ weights including heart, lungs, left kidney, right kidney, spleen, liver, stomach, duodenum, caecum and colon ($p>0.05$; data not shown). Thymus weight was significantly decreased in normal rats treated with Olive Oil (26%; $p<0.01$) and Emu Oil (21%; $p<0.05$) on day 10 and in 5-FU-injected rats (56% average; days 8 and 11; $p<0.01$, days 9 and 10; $p<0.001$) compared to normal controls (Figure 4).

SI (proximal jejunum to distal ileum) weight was significantly increased in normal rats treated with Olive Oil and Emu Oil compared to healthy controls on days 8 ($p<0.001$) and 11 (Olive Oil; $p<0.01$, Emu Oil; $p<0.001$; Figure 5). 5-FU significantly increased SI weight on day 11 (28%; $p<0.05$) compared to normal controls. Furthermore, SI weight was significantly greater in chemotherapy-injected rats administered Olive Oil (44%; day 11; $p<0.001$) and Emu Oil (33%; days 8 and 10; $p<0.001$, day 11; $p<0.05$) compared to 5-FU controls (Figure 5).

SI length was significantly increased in normal rats treated with Olive Oil (day 8: $75.3\pm 2.2\text{cm}$ and day 11: $77.3\pm 1.7\text{cm}$; $p<0.05$) and Emu Oil (day 11: $77.5\pm 1.3\text{cm}$; $p<0.01$) compared to healthy controls (day 8: $72\pm 0.9\text{cm}$ and day 11: $73.3\pm 1.3\text{cm}$). Emu Oil treatment in 5-FU-injected rats resulted in an 8.5% increase in SI length compared to 5-FU controls on days 8 ($74\pm 0.9\text{cm}$ and $68.5\pm 1.3\text{cm}$ respectively; $p<0.05$) and 11 ($82.6\pm 1.1\text{cm}$ and $75.8\pm 1.5\text{cm}$ respectively; $p<0.001$). Furthermore, SI length was significantly greater in 5-FU-injected rats treated with Olive Oil ($80\pm 1.1\text{cm}$), compared to 5-FU controls on day 11 ($p<0.001$). Duodenum and colon lengths were not significantly affected by oil treatments or 5-FU ($p>0.05$; data not shown).

Villus Height (VH) and Crypt Depth (CD) Measurements

Day 8

VH was increased in the jejunum and ileum of normal rats following Olive Oil and Emu Oil administration, respectively, compared to healthy controls ($p < 0.05$; Figure 6a). 5-FU significantly decreased VH across all small intestinal sections compared to normal controls ($p < 0.001$). Only Emu Oil significantly increased VH in the ileum of 5-FU-injected rats (33%), compared to 5-FU controls and 5-FU-injected rats treated with Olive Oil (37%; $p < 0.05$; Figure 6a). In the mid-small intestine (JI), crypts were lengthened by both Olive Oil ($p < 0.001$) and Emu Oil ($p < 0.01$) treatment in healthy rats compared with normal controls. 5-FU significantly decreased CD in the jejunum (22%; $p < 0.01$) and JI (19%; $p < 0.05$), compared with normal controls (Figure 6a).

Day 9

Emu Oil increased VH in the jejunum ($p < 0.05$) and JI ($p < 0.001$) of healthy rats compared with normal controls (Figures 6b and 7). VH was decreased in the jejunum (15%) and JI (25%) following 5-FU administration compared with 5-FU controls ($p < 0.05$). This effect was normalised by Emu Oil in 5-FU-injected rats, leading to significantly lengthened jejunal (29%) and JI (45%) villi compared with 5-FU controls ($p < 0.01$; Figure 6b and 7). Furthermore, 5-FU-injected rats treated with Emu Oil resulted in significant lengthening of jejunal villi compared with Olive Oil treatment (21%; $p < 0.05$). JI crypts in healthy rats were significantly increased by Emu Oil compared to normal controls ($p < 0.05$). 5-FU significantly lengthened JI crypts compared with normal controls (20%; $p < 0.05$), which was further increased following Olive Oil ($p < 0.01$) and Emu Oil ($p < 0.001$) administration compared to 5-FU controls (Figure 6b). Moreover, 5-FU-injected rats administered Emu Oil exhibited significantly lengthened ileal crypts compared with 5-FU controls (25%; $p < 0.05$).

Day 10

VH was significantly increased following administration of both Olive Oil and Emu Oil in the jejunum and JI; and by Emu Oil in the ileum, compared with healthy controls ($p < 0.01$; Figure 6c). 5-FU administration in normal rats did not significantly affect VH on day 10 ($p > 0.05$). However, in 5-FU-injected rats, VH was greater following Emu Oil administration (17%; jejunum), both Olive Oil (21%) and Emu Oil treatment (24%; JI), and Olive Oil administration (29%; ileum), compared to 5-FU-controls ($p < 0.05$). JI crypt depth was significantly increased following Emu Oil administration in healthy rats compared to controls ($p < 0.01$). On day 10, 5-FU significantly increased JI (26%; $p < 0.01$) and ileal (22%; $p < 0.05$) CD compared with normal controls, which was further increased following both Olive Oil (30%) and Emu Oil (35%; JI; $p < 0.01$) and Olive Oil (20%; ileum; $p < 0.05$) administration (Figure 6c).

Day 11

Emu Oil administration in normal rats significantly lengthened villi in the jejunum ($p < 0.01$) and JI ($p < 0.05$) compared to healthy controls (Figure 6d). Furthermore, villus lengthening was observed in the JI (27%) and ileum (34%) of 5-FU-injected rats following Emu Oil administration ($p < 0.01$). Both Emu Oil and Olive Oil significantly lengthened jejunal (Olive Oil; $p < 0.05$, Emu Oil; $p < 0.01$) and JI ($p < 0.05$) crypts in normal animals compared with controls. Jejunal crypt lengthening occurred following 5-FU-injection compared with normal controls (22%; $p < 0.01$), which was further lengthened by Emu Oil administration in 5-FU-injected rats compared to 5-FU controls (19%; $p < 0.01$). In 5-FU-injected rats, both Olive Oil ($p < 0.01$) and Emu Oil ($p < 0.001$) significantly increased JI CD compared with chemotherapy-injected controls (Figure 6d).

Neutral mucin-secreting goblet cells

In the jejunum, 5-FU significantly decreased numbers of neutral mucin-secreting goblet cells on days 8 (41%; $p < 0.001$) and 9 (30%; $p < 0.05$) compared to normal controls (Figures 8a and 9). This decrease was also observed in the ileum on day 8 (47%; $p < 0.01$; Figure). Both Olive Oil (75%) and Emu Oil (75%) significantly increased ileal goblet cell count in 5-FU-injected rats on day 10 compared to 5-FU controls ($p < 0.01$). Moreover, on day 11, only Emu Oil significantly increased ileal goblet cell numbers compared to 5-FU controls (54%; $p < 0.05$; Figure 8b).

Myeloperoxidase (MPO) Activity

MPO activity, indicative of acute inflammation, was significantly elevated on days 8 (277%; $p < 0.001$) and 9 (137%; $p < 0.05$) in the jejunum following 5-FU administration compared to normal controls (Figure 10a). Both Olive Oil and Emu Oil treatment in 5-FU-injected rats significantly decreased MPO activity on days 8 (Olive Oil: 45%; $p < 0.05$, Emu Oil: 62%; $p < 0.001$) and 9 (Olive Oil: 71%; $p < 0.01$, Emu Oil: 83%; $p < 0.001$) compared to 5-FU controls. This effect was also observed on day 11 ($p < 0.05$; Figure 10a). In the ileum, 5-FU increased MPO levels 6-fold on day 8 compared to healthy controls ($p < 0.001$; Figure 10b). Only Emu Oil significantly reduced day 8 ileal MPO activity compared to 5-FU controls (55%) and 5-FU-injected rats treated with Olive Oil (50%; $p < 0.05$). Furthermore, in chemotherapy-injected rats, Emu Oil significantly decreased MPO levels on days 9 and 10 compared to 5-FU controls ($p < 0.05$; Figure 10b).

Cytokine Analyses

Cytokine concentration including GM-CSF, IFN- γ , IL-1 α , IL-1 β , IL-2, IL-4, IL-5, IL-6, IL-10, IL-12p70 and IL-13 and TNF- α were not significantly affected by either oil treatment or 5-FU administration at the day 8 time point ($p > 0.05$; Table 3).

DISCUSSION

Mucositis remains a significant problem faced by cancer patients undergoing chemotherapy and radiotherapy. The present study indicated a promotion of intestinal repair from chemotherapy-induced injury, through oral administration of Emu Oil.

Daily Emu Oil administration to normal rats resulted in decreased intake of 18% casein-based diet throughout the trial. This could have been accounted for by the lipid-rich constituents of Emu Oil and thus maintenance of overall caloric intake, as evidenced by the absence of changes in body weight compared to normal rats. Furthermore, Olive Oil elicited a similar reduction in food intake in normal animals, suggesting a non-specific oil effect. Consistent with a previous study by Abimosleh *et al.*¹⁸, Emu Oil increased SI weights in normal rats on days 8 and 10, relative to untreated controls, possibly attributed to concomitant increases in SI, villus and crypt lengthening. Additionally, the high oil viscosity could have resulted in adherence of Emu Oil to the luminal epithelial surface, thereby increasing SI weight¹⁸. Increases in SI weight on days 8 and 10 were observed following Olive Oil treatment, highlighting a generalized oil effect. In the current study, histological assessment revealed that Emu Oil consistently lengthened villi and crypts throughout the SI in normal rats. Although villus height was increased in the ileum on days 8 and 10 following Emu Oil administration, the most prominent increase in overall mucosal thickening was evident in the more proximal (jejunum) to mid SI (JI).

Villus and crypt lengthening could have resulted from increased crypt cell proliferation (hyperplasia) and hence villus elongation following differentiation and upward migration, a decrease in the rate of crypt cell apoptosis, cell hypertrophy, or a combination of these factors¹⁸. Tazuke *et al.*³² demonstrated an increase in small intestinal crypt cell proliferation following glutamine administration in a rat model of chemotherapy

(cisplatin)-induced mucosal injury. In this study, the proliferative cell nuclear antigen, expressed in the nuclei of cells during the DNA synthesis phase of the cell cycle (late G1- and S-phase), was assessed as an indicator of the proliferative state of the cell using immunostaining techniques. Furthermore, Gibson *et al.*³ demonstrated that keratinocyte growth factor and the chemotherapeutic agent, methotrexate, synergistically increased apoptosis in intestinal crypts and breast cancer using tumor-bearing rats; assessed using the TUNEL assay. Accordingly, proliferation and apoptosis would be important parameters to define in future experimental studies of Emu Oil and chemotherapy, utilizing these well established techniques.

Change *et al.*³³ reported that diets containing a combination of Fish Oil (high in omega-3 FAs) and pectin (FO/P) resulted in a lower colonic tumor incidence in rats than diets rich in Corn Oil (high in omega-6 FAs) and cellulose. FO/P was protective against colon cancer due to the induction of apoptosis and suppression of cell proliferation^{33, 34}. Moreover, pectin is a highly fermentable fiber that yields higher levels of the short-chain FA, butyrate, upon microbial fermentation, whereas cellulose is poorly fermented. It remains unclear whether the long-chain FAs present in Emu Oil would exert similar effects to butyrate. Although the omega-3 FAs present in Emu Oil (total approximately 1.1% [α -linolenic acid]; Table 1) are not as pronounced as Fish Oil (total approximately 30% [20:5n-3: 18%, 22:6n-3: 12%]²²), future studies in the chemotherapy and cancer setting could benefit from further examination of Emu Oil in combination with pectin. The spontaneous tumor-bearing rat model (Dark Agouti mammary adenocarcinoma) would be appropriate to assess the impact of Emu Oil and pectin on breast tumor growth coincident with the enhancement of small intestinal repair following chemotherapy.

Proximal to mid SI changes in mucosal thickness suggested that Emu Oil metabolism in the duodenum and subsequent bioactivity of Emu Oil downstream, could have led to the observed jejunal and JI mucosal lengthening. However, Abimosleh *et al.*¹⁸ demonstrated increased crypt depth in the distal colon following Emu Oil administration to normal rats, highlighting its activity throughout the gastrointestinal tract. Despite these alterations of SI parameters, overall functional health status of the SI in the current study was maintained by Emu Oil as evidenced by the SBT, supporting the safety of Emu Oil as an oral administration.

As previously reported^{10, 16, 35, 36}, injection of 5-FU resulted in significant weight loss, reduction of food intake, increased disease activity index, decreased thymus weight and severe SI injury, 3 days post-mucositis induction (day 8). This damage was characterized by a reduction of brush border sucrase activity, as assessed indirectly by the SBT²⁹, decreased protective barrier function via a reduction of neutral mucin-secreting goblet cells³⁷ and increased MPO activity indicative of acute inflammation³⁸. Furthermore, chemotherapy-induced damage manifested histologically as shortened villi and crypts, due to reduced cellularity^{6, 10}. However, consistent with previous studies, during the recovery phase of mucositis (5 days post-5-FU injection; day 10), villus height and crypt depth elongated to a greater extent than normal, as a compensatory mechanism of stimulated cell proliferation to repair damage sustained from 5-FU administration^{23, 39}. Moreover, at this repair stage, SI injury subsided, as evidenced by the normalised SBT, goblet cell count and MPO activity. Interestingly, in the present study, pro-inflammatory cytokines including TNF- α , IFN- γ , IL-1 β and IL-6, known to be directly involved in the pathogenesis of mucositis, were not elevated 3 days post-mucositis induction. Logan *et al.*⁴⁰ demonstrated that at this time point following 5-FU injection (150mg/kg) in female Dark Agouti rats, alimentary tract (oral, jejunal and colonic) tissue expression of nuclear factor- κ B, TNF- α ,

IL-1 β and IL-6, as indicated by the intensity of immunohistochemical staining, was not altered⁴⁰. This may suggest that the T-helper 1 (Th1) and Th2 inflammatory response was not yet elicited 3 days post-mucositis induction (day 8). Future experimental studies could benefit from a complete time course of cytokine profiling in serum and intestinal tissue samples.

In the present study, Emu Oil gave indications of accelerated repair in the chemotherapy-damaged intestine. On day 8 during maximal intestinal damage, only Emu Oil administration maintained villus height in the ileum and by day 9, only Emu Oil was able to significantly increase jejunal and JI villi compared with untreated 5-FU controls. Previous studies have indicated an adaptive response of mucosal growth in an adjacent region following severe intestinal damage or small bowel resection (SBR)⁴¹. Haxhija *et al.*⁴² reported that proximal SBR resulted in ileal enterocytes becoming hypertrophic. However, these same authors noted that jejunal cells became hyperplastic in response to ileal resection⁴².

5-FU preferentially damages the proximal SI (jejunum) due to the higher cell turnover rate in this region⁴³. Therefore, in the current study, the observed compensatory crypt and subsequent villus elongation in the JI and ileum may have represented cell hypertrophy which could potentially be quantified in further studies. Indeed a compensatory mucosal thickening was evident in the jejunum by day 11. This effect was consistently enhanced by Emu Oil administration, suggesting an acceleration of the repair process. Although Olive Oil exerted similar effects, it failed to maintain mucosal thickness, unlike Emu Oil, further supporting a specific Emu Oil effect.

The increased acute inflammation, indicated by enhanced MPO activity in 5-FU controls on days 8 and 9, was significantly lowered following Emu Oil administration. Lindsay *et al.*²³ also reported decreased acute SI inflammation 4 days after 5-FU-injection with daily Emu Oil administration. Furthermore, the anti-inflammatory properties of topically applied Emu Oil have been well documented^{21, 22, 44, 45}.

The mechanism by which Emu Oil exerts its anti-inflammatory effects remains unclear. One potential mechanism could be attributed to the omega-3 and -9 FAs present in Emu Oil. Omega-3 FAs typically reduce inflammation both directly (via down-regulation of the inflammatory eicosanoid pathways, which produce thromboxane B₂, prostaglandin E₂ and leukotriene B₄) and indirectly (by altering the expression of inflammatory genes through effects on transcription factor activation)⁴⁶, whereas omega-9 FAs are believed to promote anti-inflammatory effects by inhibition of macrophage migration. Moreover, Yoganathan *et al.*²² indicated that the anti-inflammatory properties of Emu Oil are not fully accounted for by the FA profile alone²². Components in the non-triglyceride fraction of Emu Oil including carotenoids, flavones, tocopherols and skin-permeation enhancing factors may confer additional anti-inflammatory and antioxidant effects^{22, 47}. Bennett *et al.*⁴⁷ supported these antioxidant claims *in vitro* demonstrating that Emu Oil scavenges free radicals and exerts a protective role against oxidative damage. These antioxidants may have impacted on levels of damaging reactive oxygen species which are generated in the first stage of mucositis. MPO combines with hydrogen peroxide during the de-granulation process and produces hypochlorous acid and various radical oxygen species⁴⁸. These toxic agents are responsible for the damage to cells, tissues and blood vessels⁸ and contribute to the increase in levels of secondary messengers, transcription factors such as NF- κ B⁶ and subsequent pro-inflammatory cytokines.

Promotion of repair from injury could represent a new mechanism of action for Emu Oil, suggesting potential as an adjunct to conventional treatment approaches for cancer management. Future studies should focus on the identification of bioactive Emu Oil constituents to gain a more thorough understanding of its mechanism of action, thereby facilitating the development of more potent Emu Oil preparations.

STATEMENT OF AUTHOR CONTRIBUTIONS AND ACKNOWLEDGMENTS

The authors would like to thank Kerry Lymn for significantly contributing towards the animal trials, Esther Burt, Betty Zacharakis and Katie Lowe for analysis of breath samples using isotope ratio mass spectrometry and Dr Jennifer Hardingham for use of equipment for cytokine analyses. S.M.A. conducted all animal trials, experiments and data analyses and prepared the final manuscript. C.D.T. assisted with experimental planning and analysis of data. G.S.H. contributed to the experimental design, analysis of data and manuscript preparation. G.S.H. is supported by the Sally Birch Cancer Council Australia Research Fellowship in Cancer Control.

REFERENCES

- 1 Choi K, Lee SS, Oh SJ, Lim SY, Jeon WK, Oh TY, Kim JW. The effect of oral glutamine on 5-fluorouracil/leucovorin-induced mucositis/stomatitis assessed by intestinal permeability test. *Clin Nutr.* 2007 Feb;26(1):57-62.
- 2 Lalla RV, Peterson DE. Treatment of mucositis, including new medications. *Cancer J.* 2006 Sep-Oct;12(5):348-54.
- 3 Gibson RJ, Keefe DM, Clarke JM, Regester GO, Thompson FM, Goland GJ, Edwards BG, Cummins AG. The effect of keratinocyte growth factor on tumour growth and small intestinal mucositis after chemotherapy in the rat with breast cancer. *Cancer Chemother Pharmacol.* 2002 Jul;50(1):53-8.
- 4 Tooley KL, Howarth GS, Butler RN. Mucositis and non-invasive markers of small intestinal function. *Cancer Biol Ther.* 2009 May;8(9):753-8.
- 5 Gibson RJ, Bowen JM, Keefe DM. Palifermin reduces diarrhea and increases survival following irinotecan treatment in tumor-bearing DA rats. *Int J Cancer.* 2005 Sep 1;116(3):464-70.
- 6 Logan RM, Stringer AM, Bowen JM, Yeoh AS, Gibson RJ, Sonis ST, Keefe DM. The role of pro-inflammatory cytokines in cancer treatment-induced alimentary tract mucositis: Pathobiology, animal models and cytotoxic drugs. *Cancer Treat Rev.* 2007 Aug;33(5):448-60.
- 7 Sonis ST. Pathobiology of mucositis. *Semin Oncol Nurs.* 2004 Feb;20(1):11-5.
- 8 Sonis ST, Elting LS, Keefe D, Peterson DE, Schubert M, Hauer-Jensen M, Bekele BN, Raber-Durlacher J, Donnelly JP, Rubenstein EB. Perspectives on cancer therapy-induced mucosal injury: pathogenesis, measurement, epidemiology, and consequences for patients. *Cancer.* 2004 May 1;100(9 Suppl):1995-2025.
- 9 Melo ML, Brito GA, Soares RC, Carvalho SB, Silva JV, Soares PM, Vale ML, Souza MH, Cunha FQ, Ribeiro RA. Role of cytokines (TNF-alpha, IL-1beta and KC) in

the pathogenesis of CPT-11-induced intestinal mucositis in mice: effect of pentoxifylline and thalidomide. *Cancer Chemother Pharmacol.* 2007 Jul 12.

10 Cheah KY, Howarth GS, Yazbeck R, Wright TH, Whitford EJ, Payne C, Butler RN, Bastian SEP. Grape seed extract protects IEC-6 cells from chemotherapy-induced cytotoxicity and improves parameters of small intestinal mucositis in rats with experimentally-induced mucositis. *Cancer Biol Ther.* 2009 Feb 15;8(4):382-90.

11 Prisciandaro LD, Geier MS, Butler RN, Cummins AG, Howarth GS. Probiotic factors partially improve parameters of 5-fluorouracil-induced intestinal mucositis in rats. *Cancer Biol Ther.* 2011 Apr 1;11(7):671-7.

12 Prisciandaro LD, Geier MS, Butler RN, Cummins AG, Howarth GS. Evidence supporting the use of probiotics for the prevention and treatment of chemotherapy-induced intestinal mucositis. *Crit Rev Food Sci Nutr.* 2011 Mar;51(3):239-47.

13 Wright TH, Yazbeck R, Lynn KA, Whitford EJ, Cheah KY, Butler RN, Feinle-Bisset C, Pilichiewicz AN, Mashtoub S, Howarth GS. The herbal extract, Iberogast, improves jejunal integrity in rats with 5-Fluorouracil (5-FU)-induced mucositis. *Cancer Biol Ther.* 2009 May;8(10):923-9.

14 Al-Okbi SY. Nutraceuticals of anti-inflammatory activity as complementary therapy for rheumatoid arthritis. *Toxicol Ind Health.* 2012 Oct 26.

15 Miles EA, Calder PC. Influence of marine n-3 polyunsaturated fatty acids on immune function and a systematic review of their effects on clinical outcomes in rheumatoid arthritis. *Br J Nutr.* 2012 Jun;107 Suppl 2:S171-84.

16 Torres DM, Tooley KL, Butler RN, Smith CL, Geier MS, Howarth GS. Lyprinol only partially improves indicators of small intestinal integrity in a rat model of 5-fluorouracil-induced mucositis. *Cancer Biol Ther.* 2008 Feb;7(2):295-302.

- 17 Tenikoff D, Murphy KJ, Le M, Howe PR, Howarth GS. Lyprinol (stabilised lipid extract of New Zealand green-lipped mussel): a potential preventative treatment modality for inflammatory bowel disease. *J Gastroenterol*. 2005 Apr;40(4):361-5.
- 18 Abimosleh SM, Lindsay RJ, Butler RN, Cummins AG, Howarth GS. Emu oil increases colonic crypt depth in a rat model of ulcerative colitis. *Digestive Diseases and Sciences*. 2012 Apr;57(4):887-96.
- 19 Abimosleh SM, Tran CD, Howarth GS. Emu Oil: a novel therapeutic for disorders of the gastrointestinal tract? *J Gastroen Hepatol*. 2012 May;27(5):857-61.
- 20 Whitehouse MW, Turner AG, Davis CK, Roberts MS. Emu oil(s): A source of non-toxic transdermal anti-inflammatory agents in aboriginal medicine. *Inflammopharmacology*. 1998;6(1):1-8.
- 21 Snowden JM, Whitehouse MW. Anti-inflammatory activity of emu oils in rats. *Inflammopharmacology*. 1997;5(2):127-32.
- 22 Yoganathan S, Nicolosi R, Wilson T, Handelman G, Scollin P, Tao R, Binford P, Orthoefer F. Antagonism of croton oil inflammation by topical emu oil in CD-1 mice. *Lipids*. 2003 Jun;38(6):603-7.
- 23 Lindsay RJ, Geier MS, Yazbeck R, Butler RN, Howarth GS. Orally administered emu oil decreases acute inflammation and alters selected small intestinal parameters in a rat model of mucositis. *British Journal of Nutrition*. 2010 Aug;104(4):513-9.
- 24 Tomas FM, Knowles SE, Owens PC, Read LC, Chandler CS, Gargosky SE, Ballard FJ. Effects of full-length and truncated insulin-like growth factor-I on nitrogen balance and muscle protein metabolism in nitrogen-restricted rats. *J Endocrinol*. 1991 Jan;128(1):97-105.
- 25 Grem JL. 5-Fluorouracil: forty-plus and still ticking. A review of its preclinical and clinical development. *Investigational New Drugs*. 2000;18:299-313.

- 26 Portolesi R, Powell BC, Gibson RA. Competition between 24:5n-3 and ALA for Delta 6 desaturase may limit the accumulation of DHA in HepG2 cell membranes. *J Lipid Res.* 2007 Jul;48(7):1592-8.
- 27 Murthy SN, Cooper HS, Shim H, Shah RS, Ibrahim SA, Sedergran DJ. Treatment of dextran sulfate sodium-induced murine colitis by intracolonic cyclosporin. *Dig Dis Sci.* 1993 Sep;38(9):1722-34.
- 28 Howarth GS, Xian CJ, Read LC. Predisposition to colonic dysplasia is unaffected by continuous administration of insulin-like growth factor-I for twenty weeks in a rat model of chronic inflammatory bowel disease. *Growth Factors.* 2000;18(2):119-33.
- 29 Pelton NC, Tivey DR, Howarth GS, Davidson GP, Butler RN. A novel breath test for the non-invasive assessment of small intestinal mucosal injury following methotrexate administration in the rat. *Scand J Gastroenterol.* 2004;39:1015-6.
- 30 Yazbeck R, Howarth GS, Geier MS, Demuth HU, Abbott CA. Inhibiting dipeptidyl peptidase activity partially ameliorates colitis in mice. *Front Biosci.* 2008;13:6850-8.
- 31 Howarth GS, Francis GL, Cool JC, Xu X, Byard RW, Read LC. Milk growth factors enriched from cheese whey ameliorate intestinal damage by methotrexate when administered orally to rats. *J Nutr.* 1996 Oct;126(10):2519-30.
- 32 Tazuke Y, Maeda K, Wasa M, Satoko N, Fukuzawa M. Protective mechanism of glutamine on the expression of proliferating cell nuclear antigen after cisplatin-induced intestinal mucosal injury. *Pediatr Surg Int.* 2011 Feb;27(2):151-8.
- 33 Chang WC, Chapkin RS, Lupton JR. Predictive value of proliferation, differentiation and apoptosis as intermediate markers for colon tumorigenesis. *Carcinogenesis.* 1997 Apr;18(4):721-30.
- 34 Hong MY, Lupton JR, Morris JS, Wang N, Carroll RJ, Davidson LA, Elder RH, Chapkin RS. Dietary fish oil reduces O6-methylguanine DNA adduct levels in rat colon in

- part by increasing apoptosis during tumor initiation. *Cancer Epidemiol Biomarkers Prev.* 2000 Aug;9(8):819-26.
- 35 Smith CL, Geier MS, Yazbeck R, Torres DM, Butler RN, Howarth GS. Lactobacillus fermentum BR11 and fructo-oligosaccharide partially reduce jejunal inflammation in a model of intestinal mucositis in rats. *Nutr Cancer.* 2008;60(6):757-67.
- 36 Cool JC, Dyer JL, Xian CJ, Butler RN, Geier MS, Howarth GS. Pre-treatment with insulin-like growth factor-I partially ameliorates 5-fluorouracil-induced intestinal mucositis in rats. *Growth Horm IGF Res.* 2005 Feb;15(1):72-82.
- 37 Stringer AM, Gibson RJ, Logan RM, Bowen JM, Yeoh AS, Hamilton J, Keefe DM. Gastrointestinal microflora and mucins may play a critical role in the development of 5-Fluorouracil-induced gastrointestinal mucositis. *Exp Biol Med (Maywood).* 2009 Apr;234(4):430-41.
- 38 Soares PM, Mota JM, Gomes AS, Oliveira RB, Assreuy AM, Brito GA, Santos AA, Ribeiro RA, Souza MH. Gastrointestinal dysmotility in 5-fluorouracil-induced intestinal mucositis outlasts inflammatory process resolution. *Cancer Chemother Pharmacol.* 2008 Dec;63(1):91-8.
- 39 Cheng H, Bjerknes M. Whole population cell kinetics of mouse duodenal, jejunal, ileal, and colonic epithelia as determined by radioautography and flow cytometry. *Anat Rec.* 1982 Jun;203(2):251-64.
- 40 Logan RM, Stringer AM, Bowen JM, Gibson RJ, Sonis ST, Keefe DM. Is the pathobiology of chemotherapy-induced alimentary tract mucositis influenced by the type of mucotoxic drug administered? *Cancer Chemother Pharmacol.* 2009 Jan;63(2):239-51.
- 41 Drozdowski L, Thomson AB. Intestinal mucosal adaptation. *World J Gastroenterol.* 2006 Aug 7;12(29):4614-27.

- 42 Haxhija EQ, Yang H, Spencer AU, Sun X, Teitelbaum DH. Intestinal epithelial cell proliferation is dependent on the site of massive small bowel resection. *Pediatr Surg Int.* 2007 May;23(5):379-90.
- 43 Duncan M, Grant G. Oral and intestinal mucositis - causes and possible treatments. *Aliment Pharmacol Ther.* 2003 Nov 1;18(9):853-74.
- 44 Lopez A, Sims DE, Ablett RF, Skinner RE, Leger LW, Lariviere CM, Jamieson LA, Martinez-Burnes J, Zawadzka GG. Effect of emu oil on auricular inflammation induced with croton oil in mice. *Am J Vet Res.* 1999 Dec;60(12):1558-61.
- 45 Qiu XW, Wang JH, Fang XW, Gong ZY, Li ZQ, Yi ZH. [Anti-inflammatory activity and healing-promoting effects of topical application of emu oil on wound in scalded rats]. *Di Yi Jun Yi Da Xue Xue Bao.* 2005 Apr;25(4):407-10.
- 46 Calder PC. n-3 polyunsaturated fatty acids, inflammation, and inflammatory diseases. *Am J Clin Nutr.* 2006 Jun;83(6 Suppl):1505S-19S.
- 47 Bennett DC, Code WE, Godin DV, Cheng KM. Comparison of the antioxidant properties of emu oil with other avian oils. *Australian Journal of Experimental Agriculture.* 2008;48:1345-50.
- 48 Klebanoff SJ. Myeloperoxidase: friend and foe. *Journal of leukocyte biology.* 2005 May;77(5):598-625.

FIGURE LEGENDS

Figure 1. Daily body weight change of (a) healthy and (b) saline or 5-FU-injected rats on day 5, gavaged daily with 1ml water, Olive Oil or Emu Oil. Days 0 and 5 represent data from fasted rats. Body weight of fasted rats on kill days were not included in overall data analysis (kill days 8, 9, 10 and 11). Data are expressed as mean (body weight change from day 0 starting bodyweight; %) \pm standard error of the mean. *** indicates $p < 0.001$, ** indicates $p < 0.01$, * indicates $p < 0.05$ compared to Saline+Water; ^^ indicates $p < 0.001$, ^ indicates $p < 0.05$ compared to 5-FU+Water; ## indicates $p < 0.01$, # indicates $p < 0.05$ compared to 5-FU+Olive Oil.

Figure 2. Daily food (18% casein-based diet) intake of (a) healthy and (b) saline or 5-FU-injected rats on day 5, gavaged daily with 1ml water, Olive Oil or Emu Oil. Days 0 and 5 represent data from fasted rats. Food intake of fasted rats on kill days was not included in overall data analysis (kill days 8, 9, 10 and 11). Data are expressed as mean (food intake; g) \pm standard error of the mean. *** indicates $p < 0.001$ compared to Saline+Water; ^^ indicates $p < 0.001$ compared to 5-FU+Water; ## indicates $p < 0.01$, # indicates $p < 0.05$ compared to 5-FU+Olive Oil.

Figure 3. Overall functional status of small intestinal health in rats assessed utilizing the ^{13}C sucrose breath test on day of kill (days 8, 9, 10 and 11). Rats were gavaged daily with 1ml water, Olive Oil or Emu Oil and intraperitoneally injected with saline or 5-FU on day 5. Data are expressed as mean (% cumulative dose of ^{13}C at 90 minutes; %CD90) \pm standard error of the mean. * indicates $p < 0.05$ compared to Saline+Water.

Figure 4. Thymus weights of rats from each kill group (days 8, 9, 10 and 11) following body weight adjustment. Rats were gavaged daily with 1ml water, Olive Oil or Emu Oil

and intraperitoneally injected with saline or 5-FU on day 5. Data are expressed as mean (% relative to bodyweight; BW) \pm standard error of the mean. *** indicates $p < 0.001$, ** indicates $p < 0.01$, * indicates $p < 0.05$ compared to Saline+Water.

Figure 5. Small intestinal (SI; proximal jejunum to distal ileum) weights of rats from each kill group (days 8, 9, 10 and 11) following body weight adjustment. Rats were gavaged daily with 1ml water, Olive Oil or Emu Oil and intraperitoneally injected with saline or 5-FU on day 5. Data are expressed as mean (% relative to body weight; BW) \pm standard error of the mean. *** indicates $p < 0.001$, ** indicates $p < 0.01$, * indicates $p < 0.05$ compared to Saline+Water; ^^^ indicates $p < 0.001$, ^ indicates $p < 0.05$ compared to 5-FU+Water.

Figure 6. Villus height and crypt depth measurements in the rat jejunum, jejunum-ileum junction (JI) and the ileum for each kill group (a) day 8, (b) day 9, (c) day 10 and (d) day 11. Rats were daily gavaged with 1ml water, Olive Oil or Emu Oil and intraperitoneally injected with saline or 5-FU on day 5. Data are expressed as mean (length; μm) \pm standard error of the mean. *** indicates $p < 0.001$, ** indicates $p < 0.01$, * indicates $p < 0.05$ compared to Saline+Water; ^^^ indicates $p < 0.001$, ^^ indicates $p < 0.01$, ^ indicates $p < 0.05$ compared to 5-FU+Water; # indicates $p < 0.05$ compared to 5-FU+Olive Oil.

Figure 7. Representative photomicrographs of 4 μm rat jejunum sections on day 9 stained with haematoxylin and eosin (4x magnification). (a) Saline+Water, (b) Saline+Olive Oil, (c) Saline+Emu Oil, (d) 5-FU+Water, (e) 5-FU+Olive Oil and (f) 5-FU+Emu Oil.

Figure 8. Neutral mucin-secreting goblet cell counts of rat (a) jejunum and (b) ileum for each kill group (days 8, 9, 10 and 11) following daily gavages of 1ml water, Olive Oil or Emu Oil and intraperitoneal saline or 5-FU injections on day 5. Data are expressed as mean

(goblet cell count) \pm standard error of the mean. *** indicates $p < 0.001$, ** indicates $p < 0.01$, * indicates $p < 0.05$ compared to Saline+Water; ^^ indicates $p < 0.01$, ^ indicates $p < 0.05$ compared to 5-FU+Water.

Figure 9. Representative photomicrographs of 4 μ m rat jejunum sections on day 9 stained with periodic acid-Schiff reagent (4x magnification). Neutral mucin-secreting goblet cells stain pink-purple. (a) Saline+Water, (b) Saline+Olive Oil, (c) Saline+Emu Oil, (d) 5-FU+Water, (e) 5-FU+Olive Oil and (f) 5-FU+Emu Oil.

Figure 10. Myeloperoxidase activity indicative of acute inflammation in the rat (a) jejunum and (b) ileum for each kill group (days 8, 9, 10 and 11) following daily gavages of 1ml water, Olive Oil or Emu Oil and intraperitoneal saline or 5-FU injections on day 5. Data are expressed as mean (myeloperoxidase activity; units per gram; U/g) \pm standard error of the mean. *** indicates $p < 0.001$, * indicates $p < 0.05$ compared to Saline+Water; ^^ indicates $p < 0.01$, ^ indicates $p < 0.05$ compared to 5-FU+Water; # indicates $p < 0.05$ compared to 5-FU+Olive Oil.

Table 1. Major fatty acid (FA) composition of Emu and Olive Oils used in the current study including unsaturated fatty acid (UFA) and saturated fatty acid (SFA) ratios. Monounsaturated fatty acid (MUFA); polyunsaturated fatty acid (PUFA).

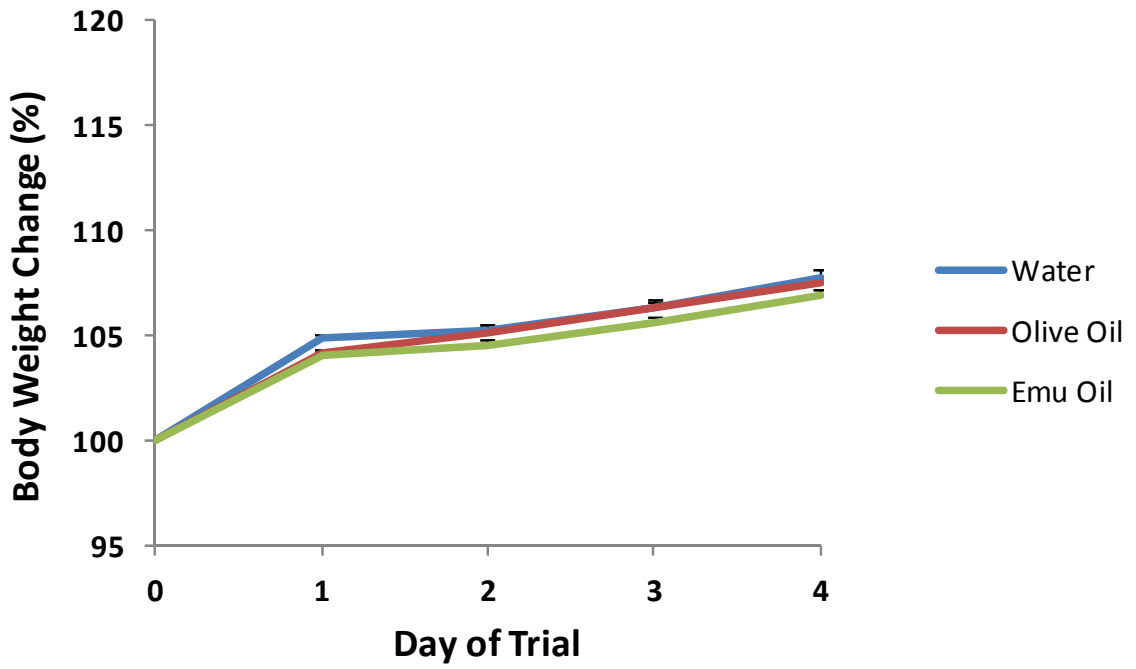
Major FA Composition of Emu and Olive Oils			
Fatty Acid	Common Name	Emu	Olive
16:0	Palmitic acid	24	10.4
16:1n-7	Palmitoleic acid	4.3	0.7
18:0	Stearic acid	8.5	3.1
18:1n-9	Oleic acid	49.1	73.9
18:2n-6	Linoleic acid	9.5	8.4
18:3n-3	α -Linolenic acid	1.1	0.7
Saturated		32.5	13.5
MUFA		53.4	74.6
PUFA		10.6	9.1
UFA:SFA ratio		2	6.2

Table 2. Disease activity index (DAI) for each kill group (days 8, 9, 10 and 11) of rats gavaged daily with 1ml of water, Olive Oil or Emu Oil and intraperitoneally injected with saline or 5-FU on day 5. Data are expressed as median disease activity index score (range). *** indicates p<0.001, * indicates p<0.05 compared to Saline+Water; ^^^ indicates p<0.001, ^^ indicates p<0.01, ^ indicates p<0.05 compared to 5-FU+Water; ### indicates p<0.001 compared to 5-FU+Olive Oil.

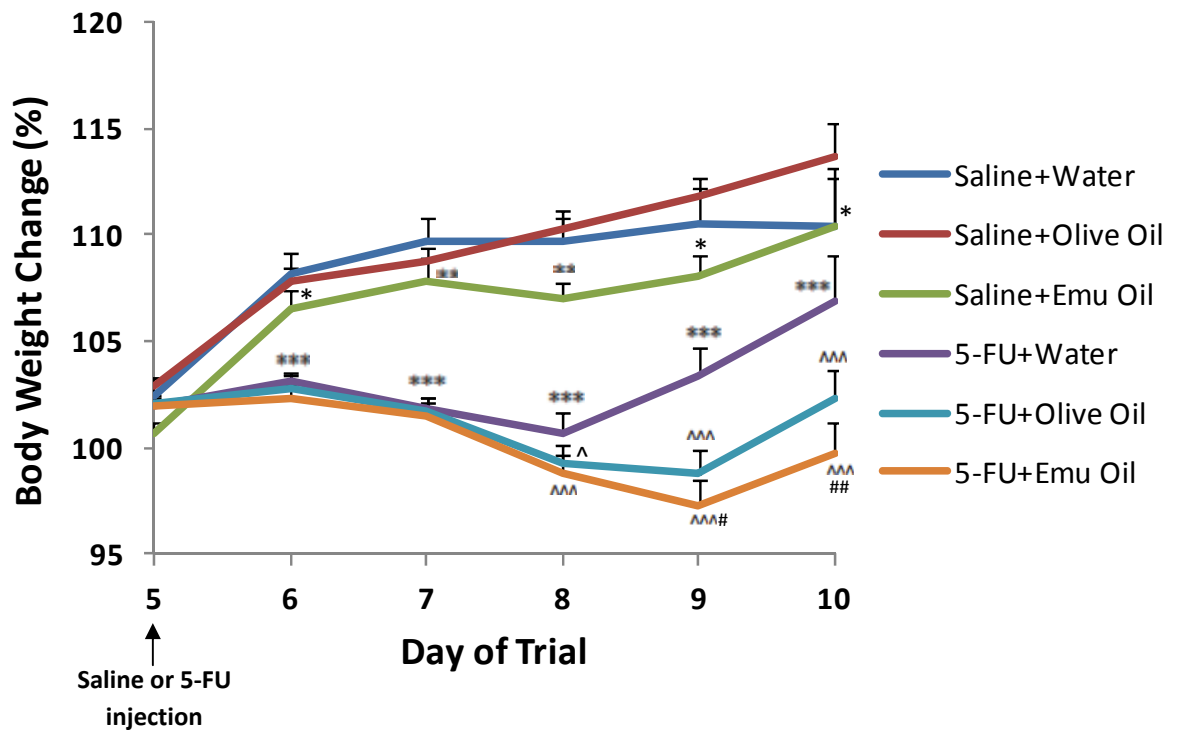
Day of trial	Saline			5-FU		
	Water	Olive Oil	Emu Oil	Water	Olive Oil	Emu Oil
6	0 (0)	0 (0)	0 (0)	0 (0-1)	0 (0-2)^	0 (0-3)^
7	0 (0-2)	0 (0-1)	0 (0)	1 (0-3)***	1 (0-5)	1 (0-3)^^
8	0 (0-1)	0 (0-1)	0 (0-1)	3 (2-10)***	7 (0-11)^^^	4 (0-9)^###
9	0 (0-2)	0 (0-1)	0 (0)	2 (1-8)***	6.5 (0-10)^^^	3 (0-10)###
10	0 (0)	0 (0)	0 (0-1)	1 (0-5)***	3 (1-8)^^^	3 (0-6)
11	0 (0)	0 (0-1)	0 (0)	1 (0-2)*	2 (1-5)	2 (0-4)

Table 3. Analysis of cytokine concentration from rat serum on day 8. Rats were gavaged daily with of 1ml water, Olive Oil or Emu Oil and intraperitoneal saline or 5-FU injections on day 5. Data are expressed as mean (concentration; pg/ml) \pm standard error of the mean. Granulocyte macrophage-colony stimulating factor (GM-CSF); interferon- γ (IFN- γ); interleukins (IL)-1 α , 1 β , 2, 4, 5, 6, 10, 12p70 and 13; tumor necrosis factor- α (TNF- α).

Cytokine conc (pg/ml)	GM-CSF	IFN- γ	IL-1 α	IL-1 β	IL-2	IL-4	IL-5	IL-6	IL-10	IL-12p70	IL-13	TNF- α
Saline+Water	72 \pm 6	129 \pm 14	100 \pm 9	514 \pm 22	603 \pm 29	145 \pm 11	101 \pm 4	301 \pm 37	828 \pm 47	44 \pm 4	61 \pm 4	29 \pm 3
5-FU+Water	68 \pm 10	132 \pm 14	97 \pm 13	408 \pm 38	553 \pm 36	137 \pm 17	99 \pm 7	292 \pm 32	676 \pm 54	41 \pm 7	55 \pm 6	24 \pm 2
5-FU+Olive Oil	78 \pm 5	145 \pm 8	111 \pm 7	541 \pm 43	681 \pm 34	158 \pm 10	108 \pm 3	348 \pm 22	873 \pm 54	52 \pm 4	67 \pm 4	33 \pm 3
5-FU+Emu Oil	76 \pm 9	135 \pm 15	108 \pm 12	566 \pm 32	717 \pm 31	155 \pm 15	105 \pm 6	319 \pm 39	886 \pm 46	50 \pm 5	65 \pm 6	33 \pm 3

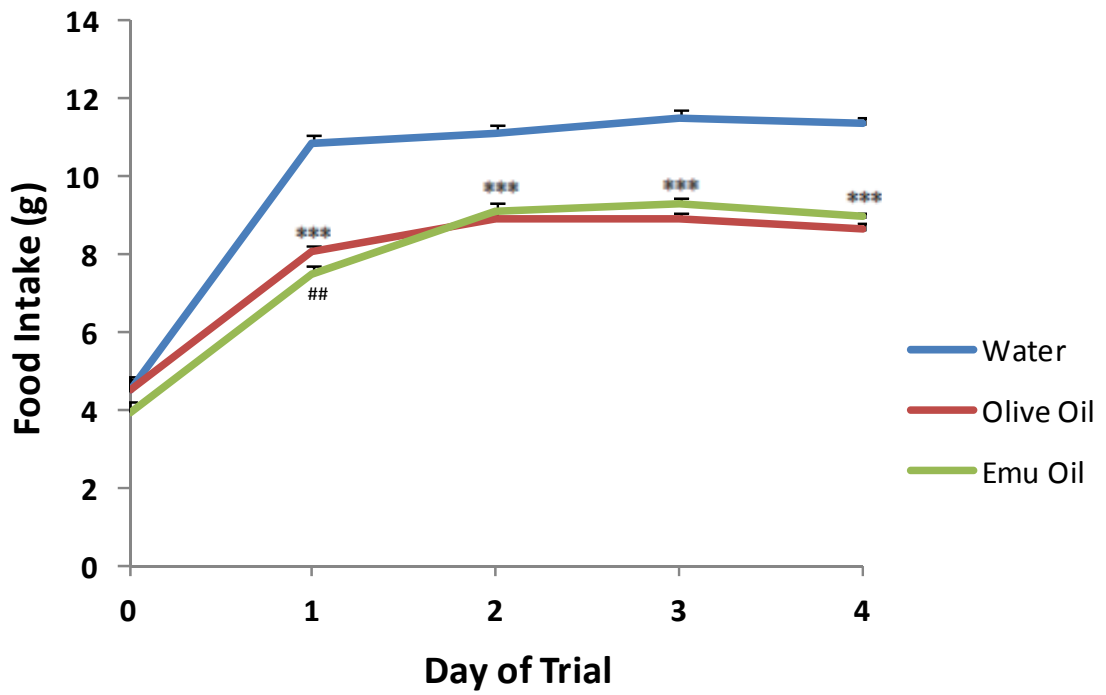


(a)

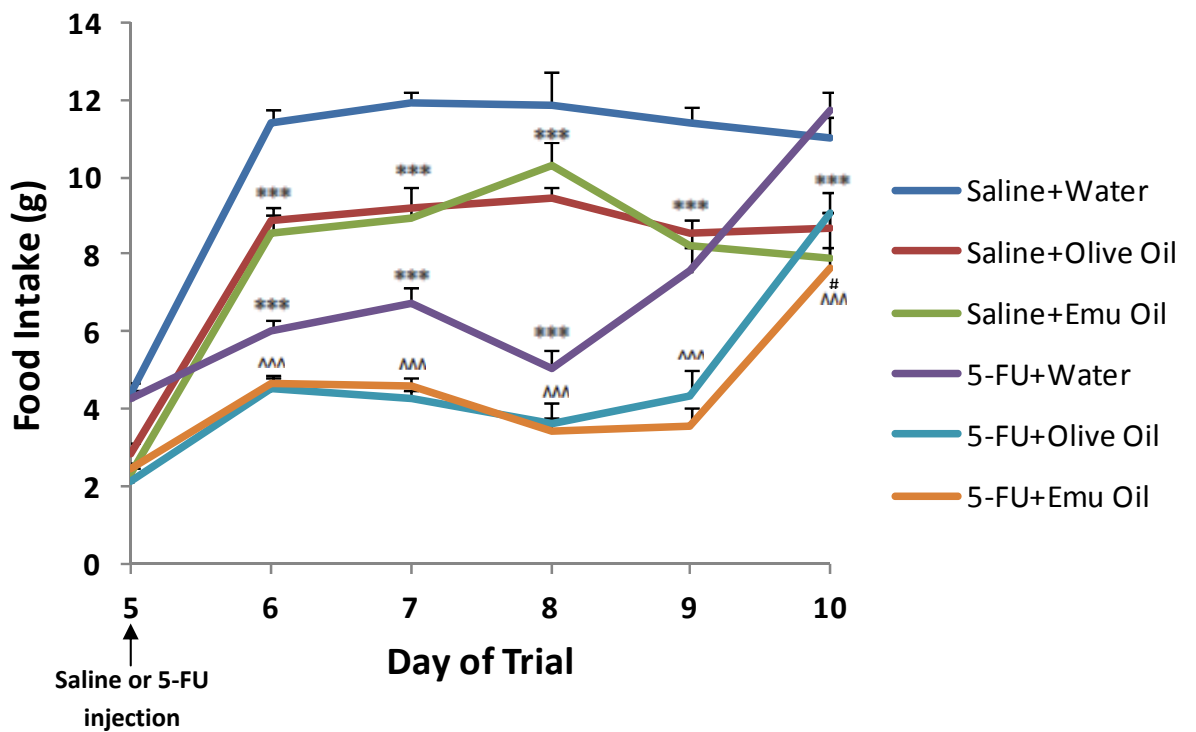


(b)

Figure 1.



(a)



(b)

Figure 2.

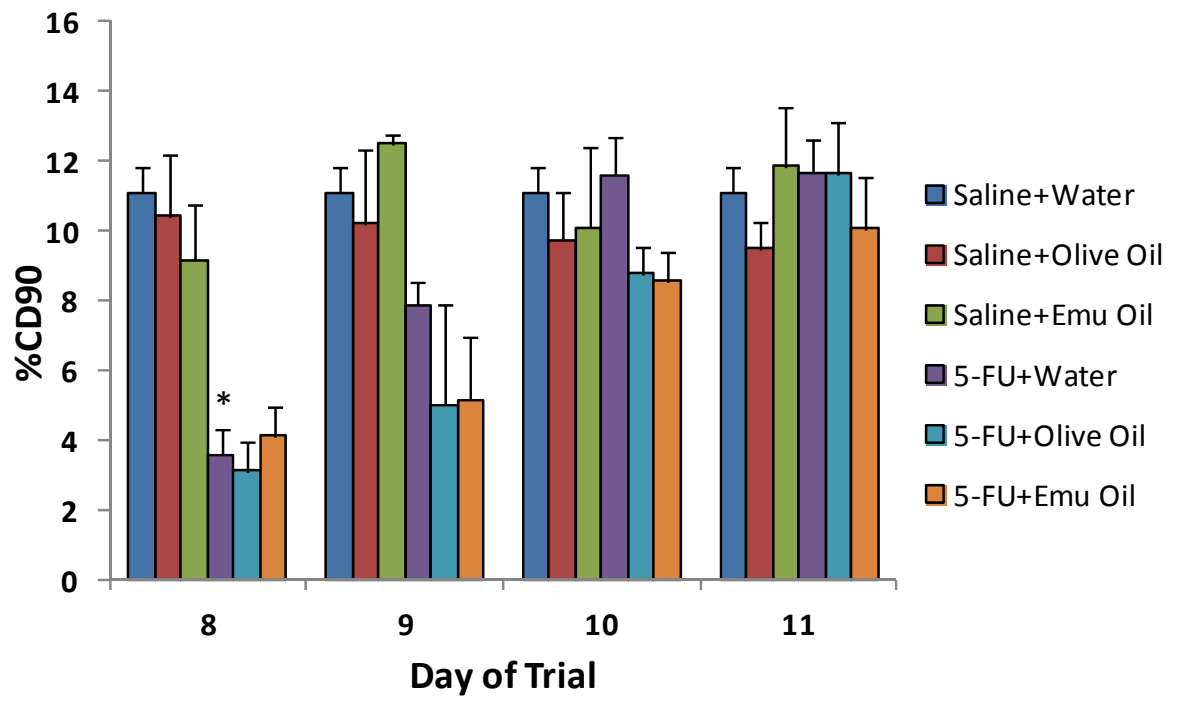


Figure 3.

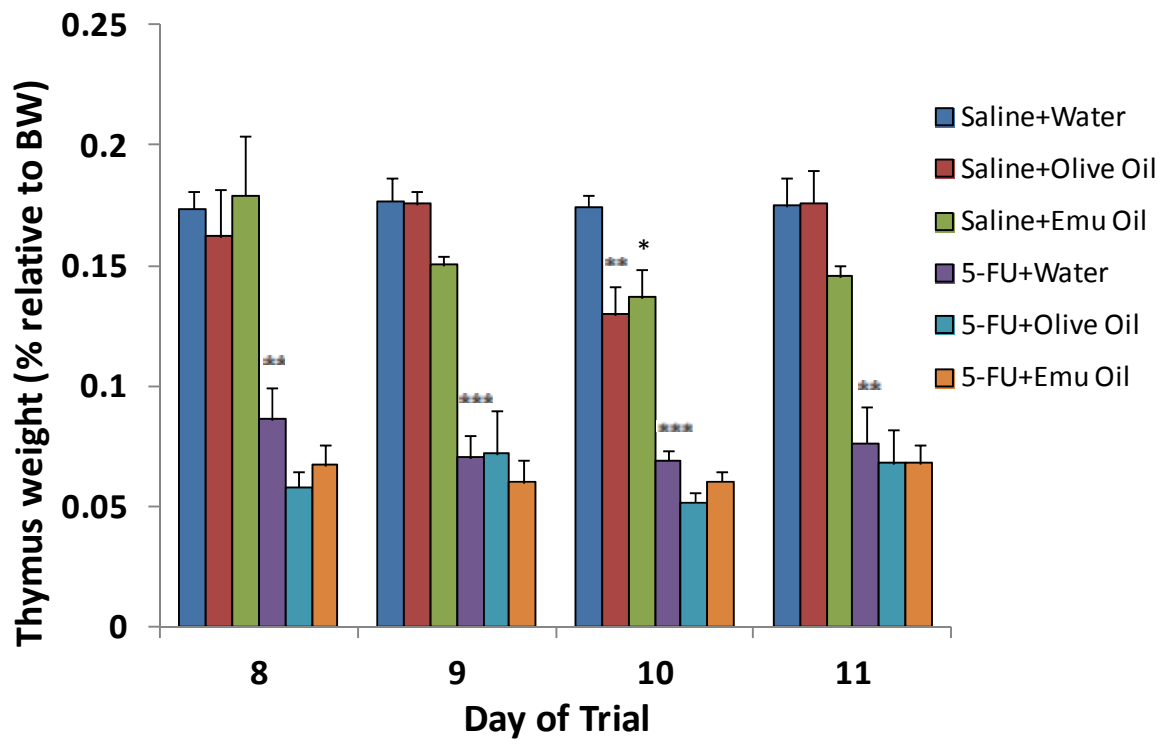


Figure 4.

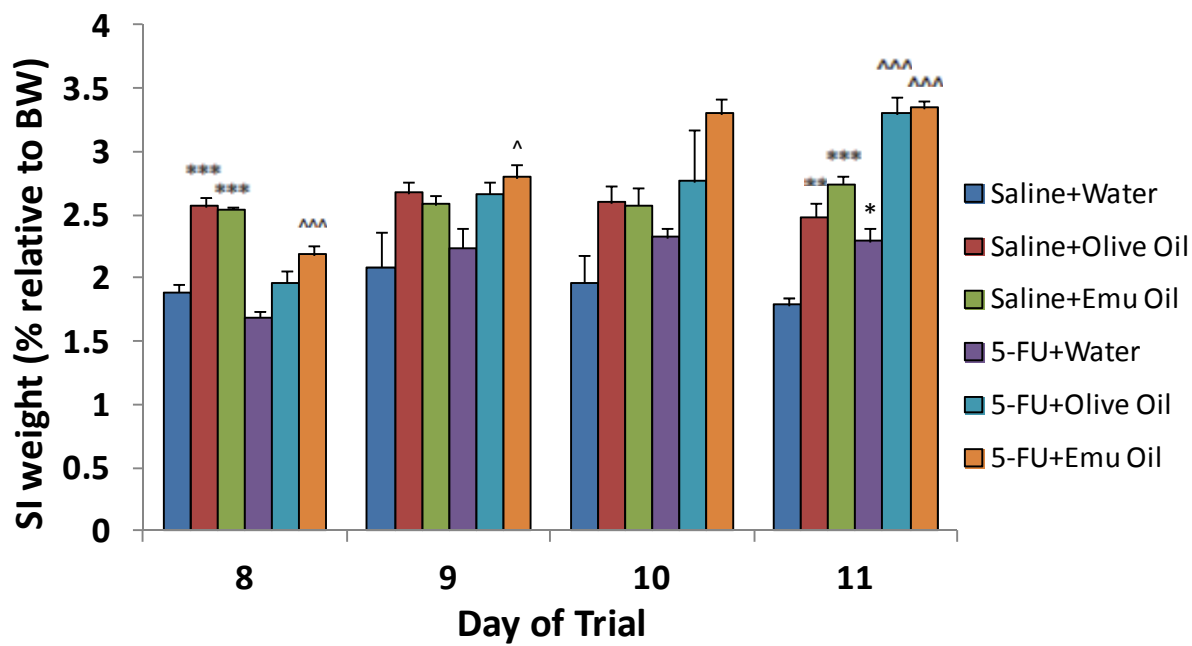
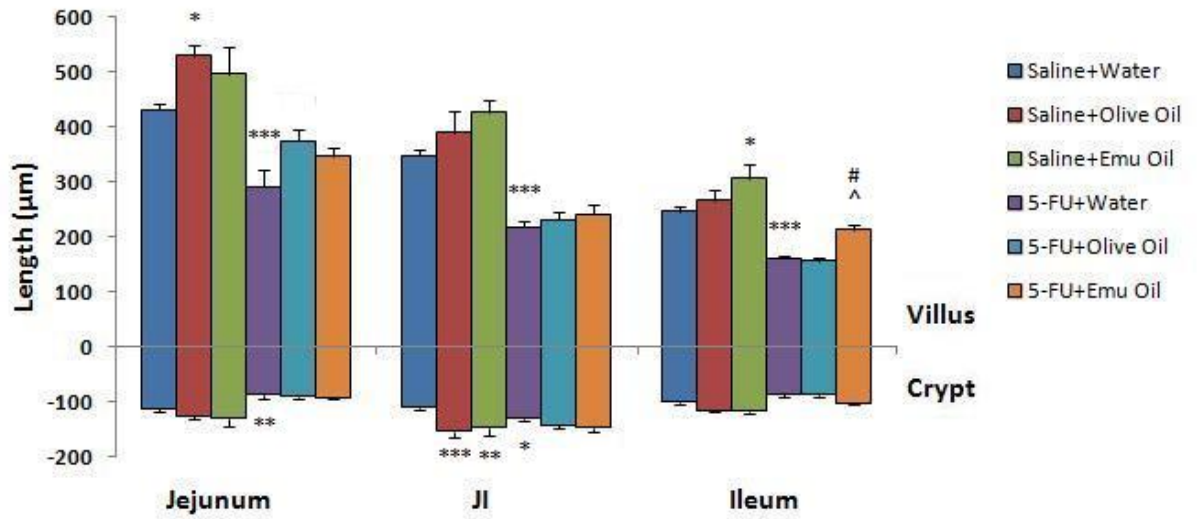
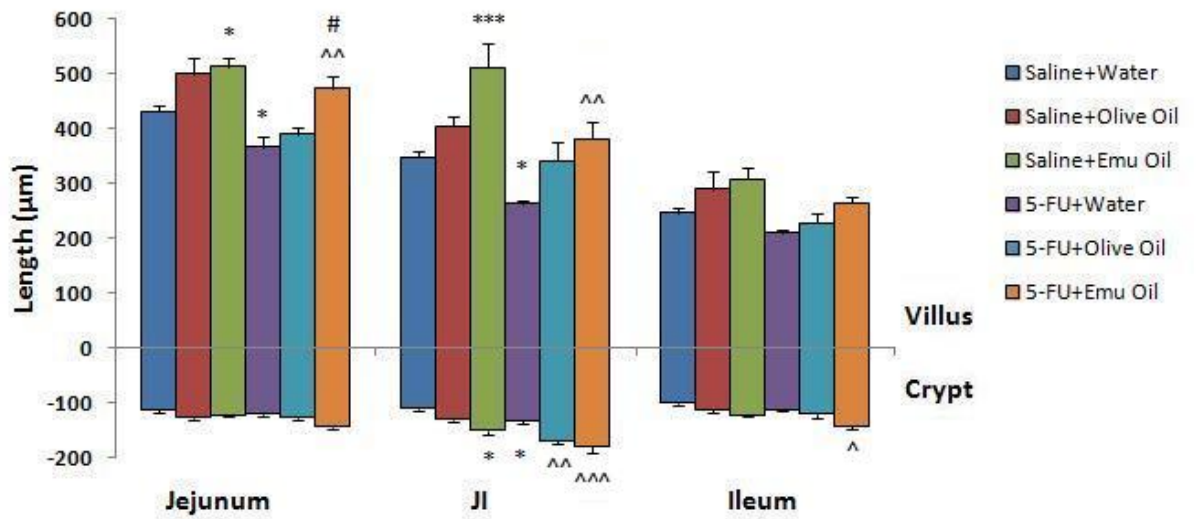


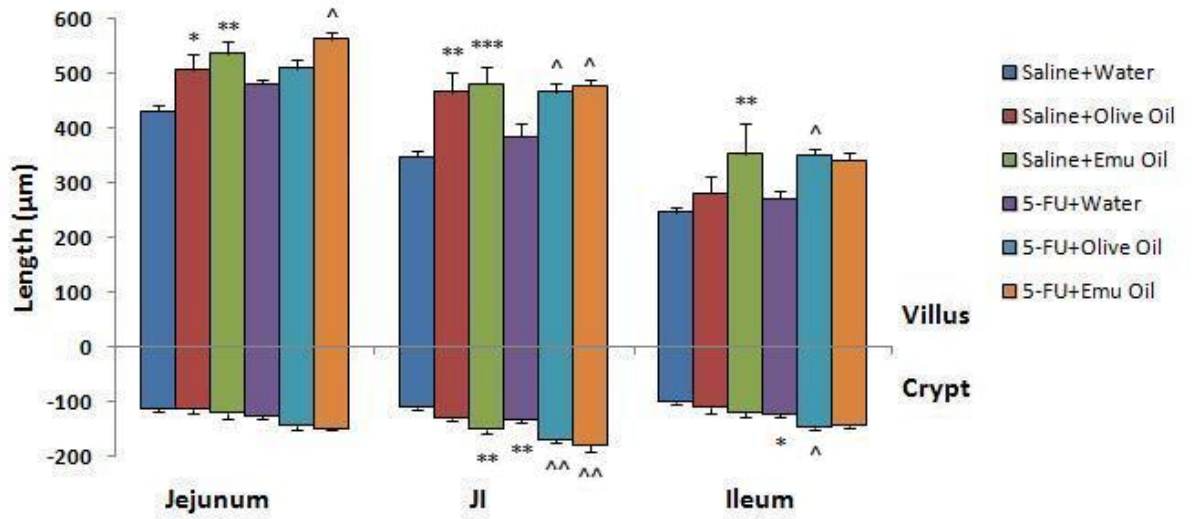
Figure 5.



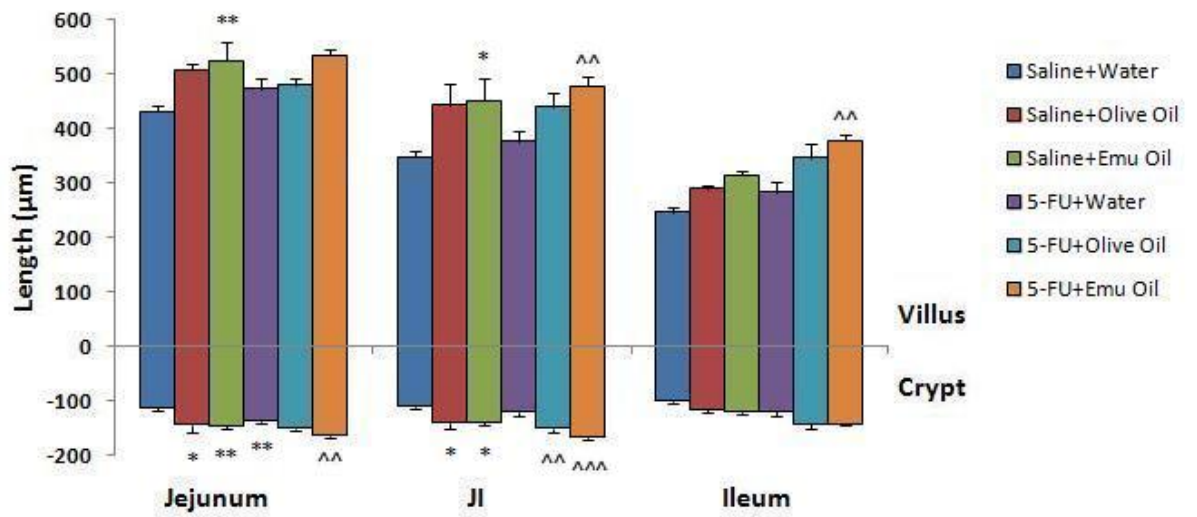
(a)



(b)



(c)



(d)

Figure 6.

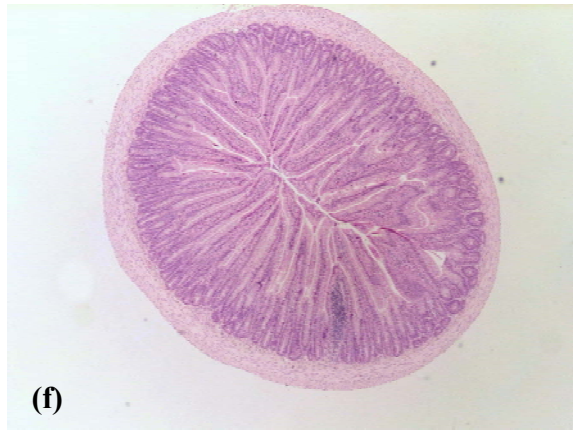
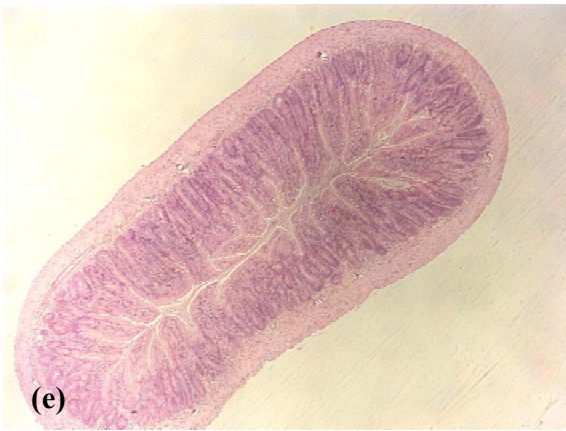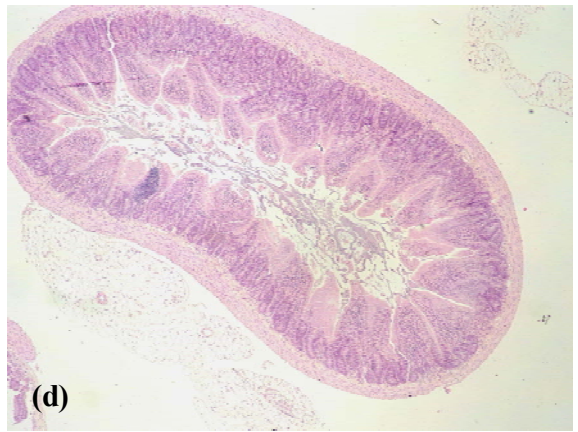
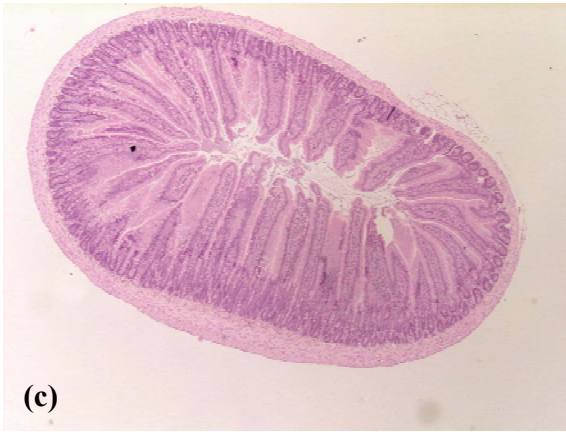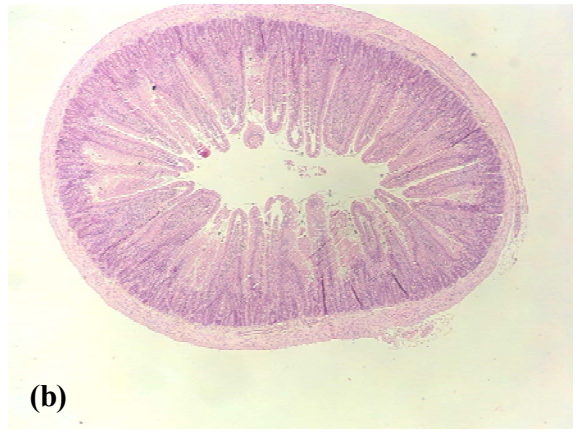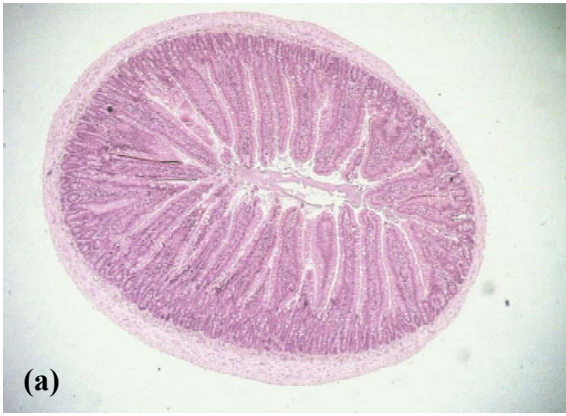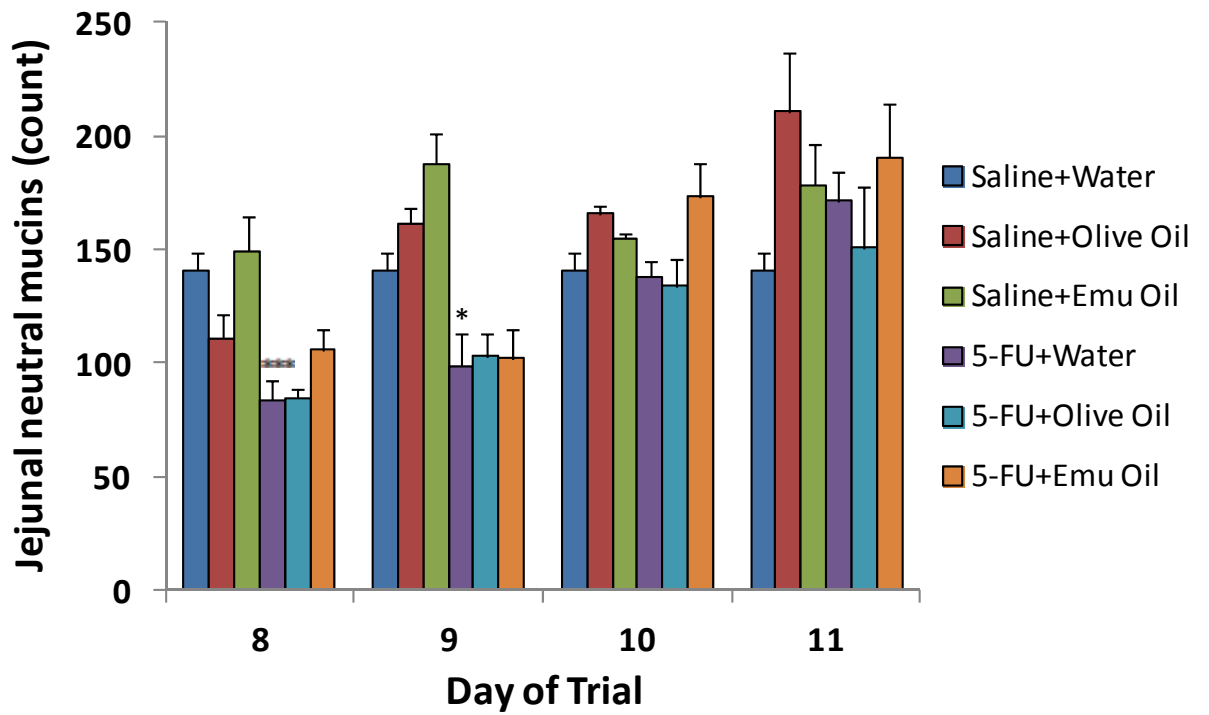
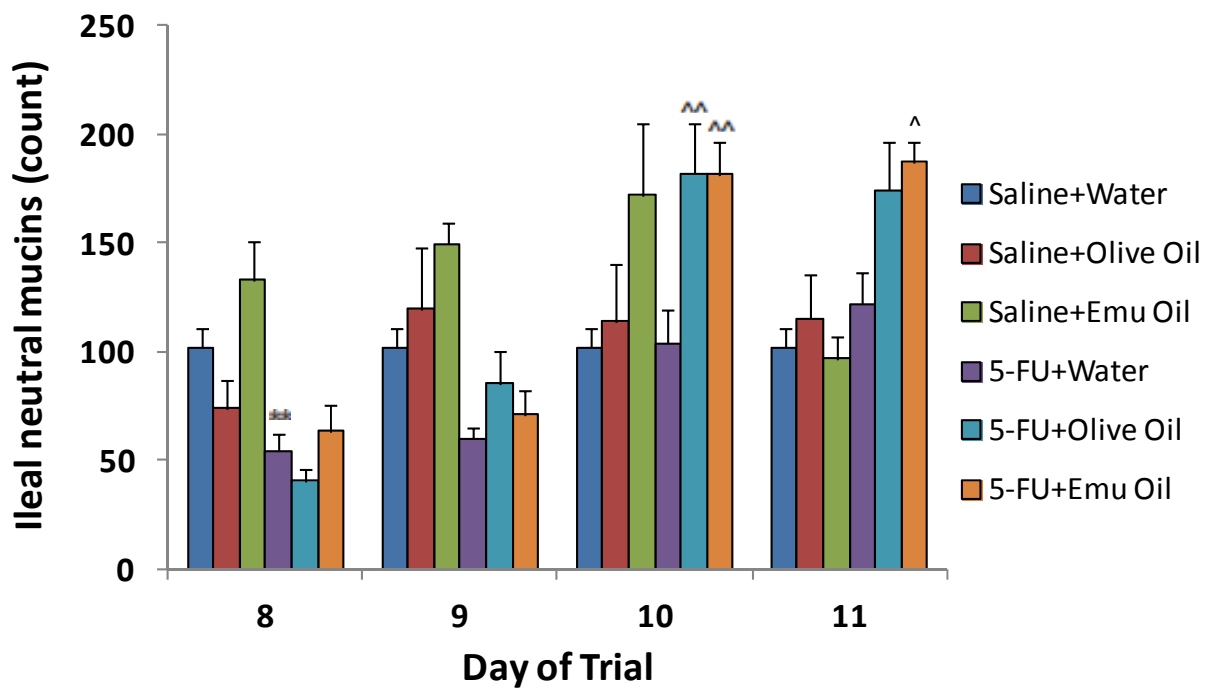


Figure 7.



(a)



(b)

Figure 8.

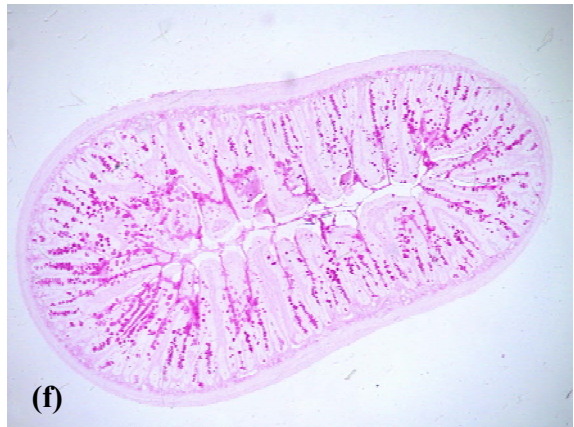
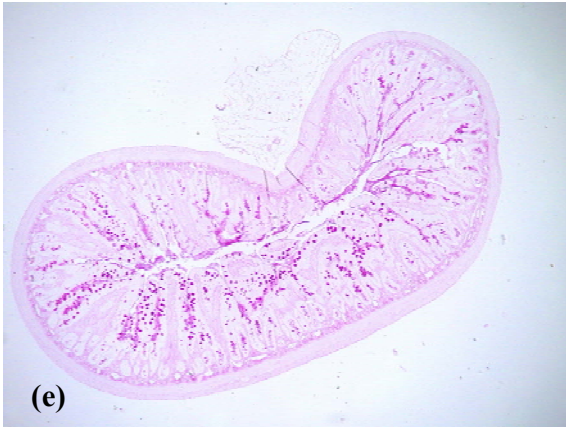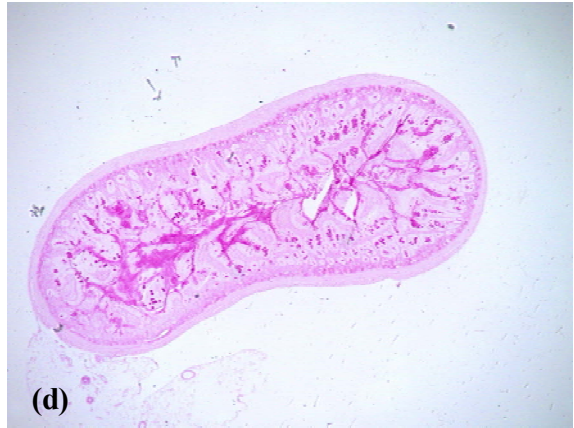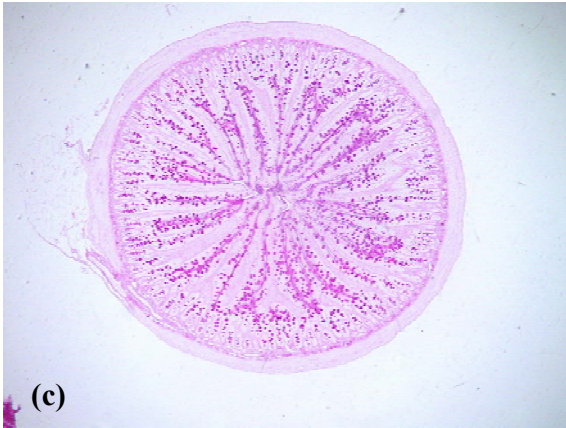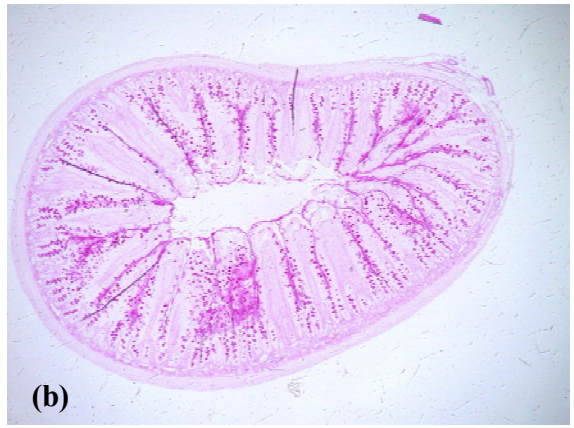
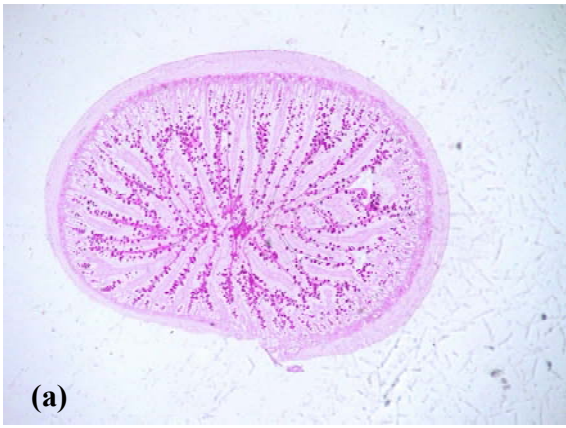
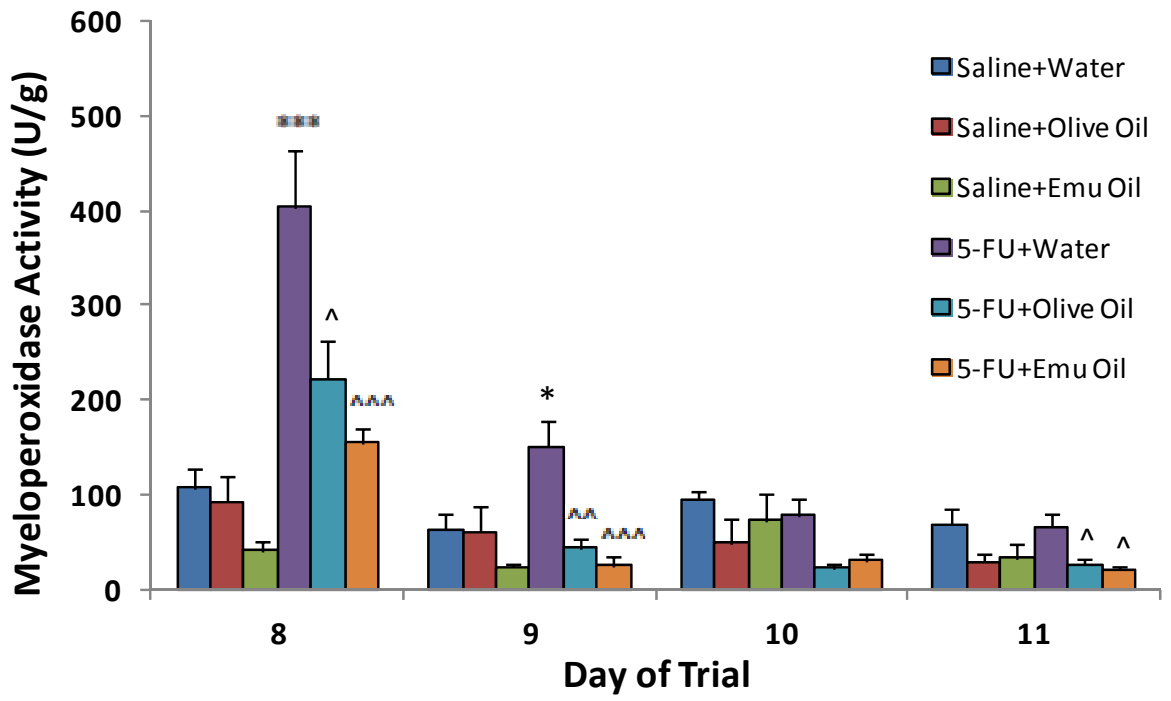
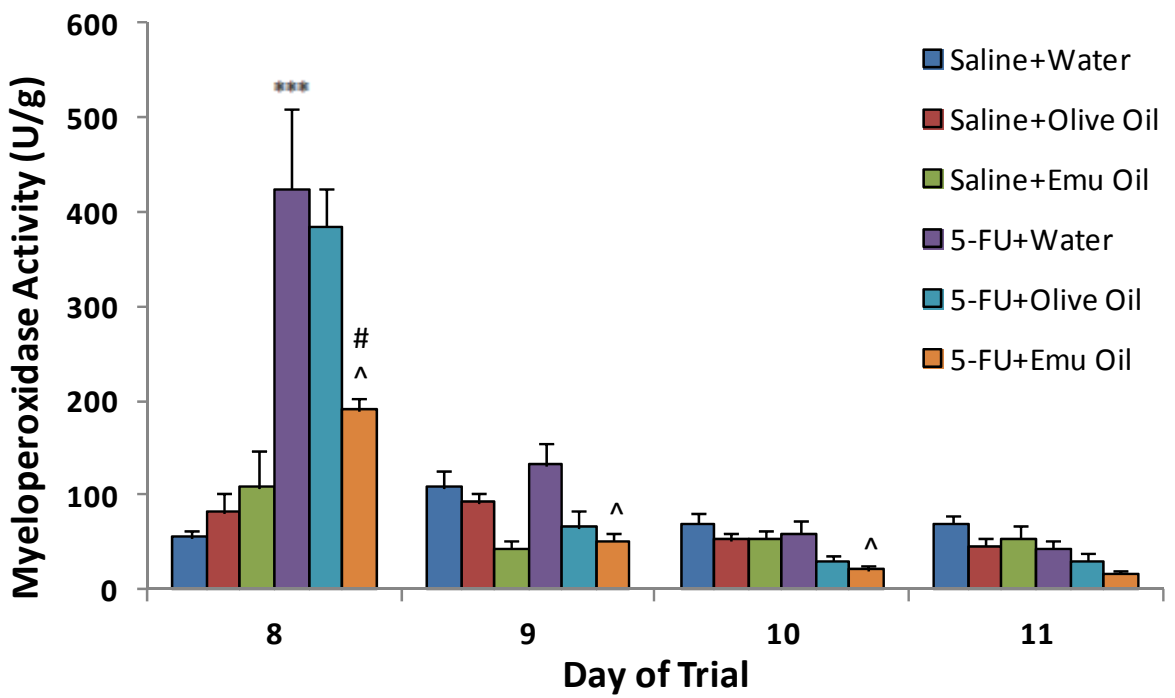


Figure 9.



(a)



(b)

Figure 10.

CHAPTER 4

**EMU OIL REDUCES SMALL INTESTINAL INFLAMMATION IN
THE ABSENCE OF CLINICAL IMPROVEMENT IN A RAT MODEL
OF INDOMETHACIN-INDUCED ENTEROPATHY**

CONTEXT STATEMENT

The work contained in this chapter is currently under review in *Evidence-Based Complementary and Alternative Medicine*.

SM Abimosleh, CD Tran, GS Howarth. Emu Oil Reduces Small Intestinal Inflammation in the Absence of Clinical Improvement in a Rat Model of Indomethacin-Induced Enteropathy. *Evidence-Based Complementary and Alternative Medicine* 2012; Under review

Chapter 4 describes the effects of orally-administered Emu Oil in a rat model of NSAID-induced enteropathy, characterised by SI inflammation and ulceration. This study was undertaken to ensure consistency of Emu Oil efficacy in the SI using a different model of intestinal damage compared to **Chapter 3**.

STATEMENT OF AUTHORSHIP

Emu Oil Reduces Small Intestinal Inflammation in the Absence of Clinical Improvement in a Rat Model of Indomethacin-Induced Enteropathy

Evidence-Based Complementary and Alternative Medicine 2012; Under review

Suzanne Mashtoub ABIMOSLEH (Candidate)

Conducted all animal trials, experimental work, analysed data, interpreted results, prepared figures and manuscript.

I hereby certify that the statement of contribution is accurate.

Signed

Date 4/12/12

Cuong D. Tran

Contributed to experimental conceptualisation and design, data interpretation.

I hereby certify that the statement of contribution is accurate.

Signed

Date 3/12/12

Gordon S. Howarth

Contributed to experimental conceptualisation and design, data interpretation, critical manuscript evaluation.

I hereby certify that the statement of contribution is accurate.

Signed

Date 4/12/12

Emu Oil Reduces Small Intestinal Inflammation in the Absence of Clinical Improvement in a Rat Model of Indomethacin-Induced Enteropathy

Suzanne M Abimosleh^{1,2}, Cuong D Tran^{1,2} and Gordon S Howarth^{1,2,3*}

¹Department of Gastroenterology, Women's and Children's Hospital, North Adelaide, South Australia, 5006

²Discipline of Physiology, School of Medical Sciences, Faculty of Health Sciences, The University of Adelaide, Adelaide, South Australia, 5005

³School of Animal and Veterinary Sciences, The University of Adelaide, Roseworthy Campus, Roseworthy, South Australia, 5371

*Corresponding author:

Professor Gordon S Howarth

School of Animal and Veterinary Sciences

The University of Adelaide

Roseworthy Campus,

South Australia

Australia, 5371

Phone: 618-8313-7885

Fax: 618-8313-7972

Email: gordon.howarth@adelaide.edu.au

Suzanne Mashtoub Abimosleh

Email: suzanne.mashtoub@gmail.com

Cuong D Tran

Email: cuong.tran@adelaide.edu.au

ABSTRACT

Background. Non-steroidal anti-inflammatory drug (NSAID)-induced enteropathy is characterized by small intestinal (SI) damage and inflammation. Emu Oil (EO) has previously been reported to reduce intestinal inflammation in experimental models of mucositis and inflammatory bowel disease. **Aim.** We investigated EO for its potential to attenuate NSAID-induced enteropathy in rats. **Methods.** Male Sprague Dawley rats (n=10/group) were gavaged with Water, Olive Oil (OO) or EO (0.5ml; days 0-12) and with 0.5ml Water or the NSAID, Indomethacin (8mg/kg; days 5-12) daily. Disease activity index (DAI), ¹³C-sucrose breath test (SBT), organ weights, intestinal damage severity (IDS) and myeloperoxidase (MPO) activity were assessed. p<0.05 was considered significant. **Results.** In Indomethacin-treated rats, DAI was elevated (days 10-12) and SBT values (56%) and thymus weight (55%) were decreased, relative to normal controls. Furthermore, Indomethacin increased duodenum (68%), colon (24%), SI (48%), caecum (48%), liver (51%) and spleen (88%) weights, IDS scores and MPO levels (jejunum: 195%, ileum: 104%) compared to normal controls. Both EO and OO decreased (64%) jejunal MPO levels; however, only EO decreased ileal MPO levels (50%), compared to Indomethacin controls. **Conclusions.** EO reduced acute intestinal inflammation, although other parameters of Indomethacin-induced intestinal injury were not affected significantly.

INTRODUCTION

Non-steroidal anti-inflammatory drugs (NSAIDs) are among the most widely prescribed pharmaceutical agents, with approximately 30 million patients worldwide ingesting NSAIDs daily^(1, 2). NSAIDs have been indicated as an effective treatment option for rheumatic and musculoskeletal conditions⁽³⁾ and to potentially lower the risk of cardiovascular and cerebrovascular insults. Indeed, recent studies have indicated efficacy for the treatment of colon cancer^(2, 4). NSAIDs represent a highly effective class of drug; however, their use is often associated with a broad spectrum of adverse effects, predominantly within the gastrointestinal (GI) tract^(2, 3). The adverse events in the stomach, duodenum, jejunum and ileum are collectively termed NSAID-enteropathy⁽⁵⁾.

NSAID-associated intestinal toxicity has several manifestations including increased mucosal permeability, inflammation and ulceration, and in severe cases, bowel perforation⁽⁵⁾. Clinically evident features include anaemia, bleeding, mucosal diaphragms, strictures and chronic bowel inflammation⁽⁶⁾. Serious injury to the small intestine (SI) has been estimated to account for one-third of all NSAID-associated complications⁽⁶⁾.

The pathogenesis of NSAID-enteropathy is proposed to commence via a direct intestinal insult together with its enterohepatic and consequent systemic effects^(3, 5, 7). Entrance of the acidic NSAID into enterocytes induces severe stress in the endoplasmic reticulum of mitochondria leading to cell death^(3, 8). An increase in mucosal permeability follows, which facilitates the translocation and action of luminal factors such as bile acids, dietary macromolecules, components of pancreatic juice and bacteria, thereby activating the inflammatory cascade^(8, 9). Within the mucosa, tumor necrosis factor- α (TNF- α) expression promotes auto-regulation and expression of other pro-inflammatory cytokines including

interleukin-1 β (IL-1 β) and IL-6⁽¹⁰⁾. Furthermore, neutrophils are recruited and infiltrate at the area of ulceration^(3, 5, 10).

Commonly prescribed NSAIDs include Aspirin, Ibuprofen, Naproxen, Ketoprofen and Indomethacin⁽⁴⁾. The enzyme, cyclooxygenase (COX), which exists as two isoforms, is the target for NSAID action. COX converts arachidonic acid (AA) to prostaglandin G₂ (PGG₂), the common precursor of major prostanoids which include PGD₂, PGE₂, prostacyclin (PGI₂) and thromboxane (TXA₂)⁽¹¹⁾. The two isoforms of COX generally have distinct functions; COX-1-derived PGs maintain mucosal integrity whereas COX-2 is rapidly induced in response to pro-inflammatory stimuli leading to PG production at inflammatory sites⁽¹²⁾.

Historically, GI injury has been primarily associated with non-selective COX-1/2 inhibitors. On the basis of these findings, selective COX-2 inhibitors including Celecoxib and Meloxicam were developed. These were initially reported to elicit analgesic properties accompanied by minimal GI inflammatory side-effects⁽¹³⁾. However, a number of recent reports have suggested that the incidence of jejunal and ileal injury induced by chronic use of selective COX-2 inhibitors may be as high as non-selective therapies^(5, 14-16). The development of new therapies is therefore imperative to ameliorate the side-effects of NSAID use, particularly in patients undergoing long-term NSAID-treatment.

Favorable effects of diets high in n-3 polyunsaturated fatty acids (PUFAs) have been well documented in inflammatory conditions including rheumatoid arthritis⁽¹⁷⁾ and inflammatory bowel disease (IBD)⁽¹⁸⁾. Cell culture studies with n-3 PUFAs have shown inhibition of COX-2 production and pro-inflammatory cytokines including TNF- α , interleukin-1 (IL-1), IL-6, IL-8 and IL-12⁽¹⁹⁻²¹⁾. Furthermore, animal studies with marine

oils rich in n-3 PUFAs support the *in vitro* observations. For example, Fish Oil reduced levels of TNF- α , IL-12 and IL-1 β in a mouse model of IBD⁽²²⁾. Recently, attention has been directed towards animal-derived oils with high levels of PUFAs, such as the oil derived from the Australian ratite bird, the Emu (*Dromaius novaehollandiae*)^(23, 24).

Indigenous Australians first used Emu Oil to facilitate wound healing, pain alleviation and treatment of inflamed joints^(23, 25, 26). Topical application of Emu Oil decreased levels of TNF- α and IL-1 α in a mouse model of adjuvant-induced inflammation⁽²⁷⁾. These cytokines are involved in the pathogenesis of NSAID-enteropathy⁽⁵⁾. Abimosleh *et al.*⁽²⁴⁾ reported that orally-administered Emu Oil improved selected parameters associated with the manifestation of experimental IBD in rats. Furthermore, Lindsay *et al.*⁽²⁸⁾ demonstrated that Emu Oil reduced ileal myeloperoxidase activity indicative of neutrophil infiltration and improved mucosal architecture., in a rat model of intestinal mucositis.

Therefore, we hypothesized that orally-administered Emu Oil would protect against Indomethacin-induced enteropathy in rats.

MATERIALS AND METHODS

General Experimental Procedures

Animal Studies. Throughout acclimatization and the experimental period, male Sprague Dawley rats (140-170g) were individually housed in metabolism cages (Tecniplast, PA, USA) at room temperature with a light:dark cycle of 12 hours. All rats were given *ad libitum* access to food (standard 18% casein-based diet⁽²⁹⁾) and water, and were acclimatized for 2 days prior to experimentation. Animal experimentation was conducted across several identical trials in which lower numbers of rats from all treatment groups (usually 2-3) were represented. All animal studies were conducted in compliance with the Australian Code of Practice for the Care and Use of Animals, and were approved by the Animal Ethics Committees of the Children, Youth and Women's Health Service and The University of Adelaide.

Rats were randomly assigned to four groups (n=10/group); Group 1: Water+Water, Group 2: Indomethacin+Water, Group 3: Indomethacin+Olive Oil and Group 4: Indomethacin+Emu Oil. Water, Olive Oil or Emu Oil (0.5ml) was administered once daily via oro-gastric gavage from days 0 to 12. Between days 5 and 12, rats were administered Water (0.5ml) or Indomethacin (Sigma-Aldrich, MO, USA; 8mg/kg) via oro-gastric gavage.

The dose of Indomethacin (8mg/kg) was determined from a pilot study using male Sprague Dawley rats, which was performed immediately prior to the current study. Indomethacin dosages (6mg/kg, 8mg/kg and 10mg/kg) were tested and 8mg/kg was deemed to be the most appropriate for the current investigation, based upon metabolic parameters, disease activity index (DAI) and kill data.

Emu Oil and Olive Oil Preparation. Emu Oil, sourced from Emus farmed in North-Eastern South Australia, was prepared utilizing specific methodologies developed for Technology Investment Corporation by Emu Tracks (Marleston, Adelaide, South Australia). Briefly, these processes involved the rendering and filtration of Emu adipose tissue, with appropriate considerations for delivery of quality assurance and product consistency. Fatty acid analysis of Emu Oil and Olive Oil was carried out using gas chromatography, as described previously⁽³⁰⁾ (Table 1). Olive Oil (Conga Foods, Spain) was selected as the control oil due to its high level of oleic acid; similar to that of Emu Oil. The Olive Oil control was included to determine any non-specific oil-related effects for subsequent comparison with Emu Oil. Both Emu Oil and Olive Oil were individually stored at 4°C in 50ml opaque containers.

Daily Metabolic Data and Disease Activity Index

Body weight, food and water intake, and fecal and urine output were monitored and measured daily. The severity of NSAID-induced enteropathy was assessed daily, using a DAI, which scored body weight loss, rectal bleeding, stool consistency, and overall general condition of the animal, increasing in severity on a scale of 0-3 for each parameter, which was totaled to achieve an overall DAI, as described previously^(31, 32). Overall condition was determined by (1) mobility/agility: healthy rats are considered quite active, whereas rats affected by Indomethacin characteristically become very weak and feeble, sitting hunched with very little movement and (2) fur: healthy rats are well-groomed with fur flat to the body, whereas rats administered Indomethacin become scruffy in appearance, with ruffled fur.

¹³C- Sucrose Breath Test

Immediately prior to kill (day 12), the ¹³C-sucrose breath test (SBT) was performed as a non-invasive assessment of the functional status of SI health and to ensure safety of Emu Oil⁽³³⁾. Briefly, following an overnight fast, a baseline breath sample was collected at t=0. Rats were then gavaged with 1ml of a 25% ¹³C-labeled sucrose solution (BDH, Merck Pty Ltd, Victoria, Australia); breath samples collected every 15 minutes for 120 minutes, and samples were analyzed for ¹³CO₂ concentration using an isotope ratio mass spectrometer (Europa Scientific, Crewe, UK)⁽³⁴⁾. Data were expressed as mean percentage cumulative dose of ¹³C recovered at 90 minutes post-sucrose administration (%CD90). This provides an indirect indication of the rate at which sucrose is cleaved by the enzyme sucrase in the SI, and therefore, the level of sucrase present on SI enterocytes (brush border).

Tissue Collection

On day 12, rats were sacrificed by CO₂ asphyxiation followed by cervical dislocation. The GI tract was removed, measured, emptied of contents and weighed. Furthermore, the SI tract (jejunum, jejunum-ileum junction [JI] and the ileum) was opened for intestinal damage severity assessment. Segments of the SI tract (jejunum, and ileum; 4cm) were collected and snap-frozen in liquid nitrogen for biochemical analysis. Samples were stored at -80°C until prepared for analysis by homogenization in 10mM phosphate buffer. The remaining visceral organs (thymus, lungs, heart, liver, kidneys and spleen) were weighed and discarded.

Intestinal Damage Severity Scoring

Intestinal damage severity (IDS) was assessed utilizing a quantitative scoring system based on thirteen parameters. Opened intestinal sections (jejunum, JI and ileum) were inspected and quantified for erythema (small: <2cm, large: ≥2cm; Figure 1b), mild hemorrhage

(small: <2cm, large: \geq 2cm; Figure 1b), severe hemorrhage (small: <2cm, large: \geq 2cm; Figure 1c), single ulcers (small: <0.5cm, medium: \sim 0.5cm, large: >0.5cm; Figure 1d), cluster of ulcers (small: <4, large: \geq 5; Figure 1e) and perforations (small: <0.5cm, large: \geq 0.5cm; Figure 1f), in which number, size and location were recorded on a schematic intestinal diagram during kill. Assessment was performed in a blinded fashion using a dissecting microscope (Leica Microsystems, Wetzlar, Germany). Raw parameter data were totaled to achieve an overall score for each intestinal section from each rat.

Biochemical Analysis

Myeloperoxidase Activity. Myeloperoxidase (MPO) levels in the SI were determined as an indicator of neutrophil infiltration, and hence, acute inflammation, using techniques described by Howarth *et al*⁽³⁵⁾. Thawed, homogenised samples were centrifuged at 13,000g for 12 minutes, after which the supernatant was discarded, and the tissue homogenate was re-suspended in 200 μ L of 0.5% hexadecyltrimethyl ammonium bromide buffer, a detergent (Sigma Chemicals, Sydney, Australia). After vortexing for 2 minutes, samples were again centrifuged at 13,000g for 2 minutes. Background, negative and positive control samples (50 μ L) and the supernatants of each test sample were then aliquoted into duplicate wells of a microtitre 96-well plate. Following the addition of a reaction solution (200 μ L to each well; 4.2mg of O-dianisidine dihydrochloride reagent, 12.5 μ L H₂O₂, 2.5ml potassium phosphate buffer [pH 6.0], 22.5ml distilled water) the change in absorbance was measured at 450 nm at 1 minute intervals for 15 minutes with a spectrophotometer (Victor X4 Multilabel Reader, Perkin Elmer, Singapore). Data were expressed as units of MPO per gram of tissue.

Statistical Analyses

Statistical comparisons were conducted using SPSS version 16.0 for Windows (SPSS Inc., Chicago, Illinois, USA). All data sets were tested for normality of distribution using the Shapiro-Wilk statistic. Metabolic data were analysed using a one-way ANOVA and Tukey's *post hoc* test to compare groups during each period; prior to (days 0-4) and during (days 5-12) Indomethacin administration. SBT, kill data, intestinal damage severity and MPO activity were analysed using a one-way ANOVA with Tukey's *post hoc* test. All parametric data were expressed as mean with their standard errors. DAI comparisons between groups each day were made using a Kruskal Wallis test with Mann-Whitney U-tests and expressed as median (range). For all analyses, $p < 0.05$ was considered significant.

RESULTS

Daily Metabolic Data

During the period prior to commencement of Indomethacin administration (days 0-4), Olive Oil and Emu Oil did not significantly affect body weight gain, total food and water intake and total urine output ($p>0.05$; Table 2) compared to normal, healthy controls. However, Olive Oil significantly reduced total fecal output in normal rats, compared to normal controls (25%; days 0-4; $p<0.05$).

Body weight was determined as a mean percentage change from the commencement of Indomethacin or water administration (days 5-11). Water-gavaged rats gained approximately 25% body weight from day 5 to 11, whereas Indomethacin administration resulted in significantly reduced weight gain in normal rats compared to normal controls ($p<0.001$; Figure 2). Neither oil treatment increased body weight in Indomethacin-treated rats compared to Indomethacin-treated controls ($p>0.05$; Figure 2).

Indomethacin significantly decreased total food intake (41%) and increased water intake (72%) in normal rats compared to healthy controls during days 5-12 ($p<0.001$; Figures 3a and 3b). Olive Oil and Emu Oil did not significantly affect total food or water intake in Indomethacin treated rats compared to Indomethacin controls ($p>0.05$). Indomethacin significantly decreased (21%; $p<0.01$) total fecal output during days 5-12 compared to healthy controls, which was subsequently normalized following Olive Oil and Emu Oil treatment ($p<0.05$; Figure 3c). Neither Indomethacin nor the oil treatments significantly affected total urine output ($p>0.05$; Figure 3d).

Disease Activity Index (DAI)

Indomethacin significantly increased DAI in normal rats on day 10 [median score 1 (range: 0-7); $p < 0.01$], 11 [2 (1-7); $p < 0.001$] and 12 [2 (1-8); $p < 0.001$] compared to healthy controls [0 (0); Table 3]. Oil treatments did not significantly affect DAI in Indomethacin-treated rats compared to Indomethacin controls ($p > 0.05$).

¹³C- Sucrose Breath Test (SBT)

Indomethacin significantly decreased percentage cumulative dose of ¹³C at 90 minutes (%CD90) compared to healthy controls (56% decrease; $p < 0.001$; Figure 4). However, both oil treatments failed to significantly increase %CD90 in Indomethacin-administered animals compared to Indomethacin controls ($p > 0.05$; Figure 4).

Visceral and Gastrointestinal Organ Weights and Lengths

Organ weights were expressed as a proportion of body weight. Significant increases in duodenum (68%; $p < 0.05$), SI (48%; $p < 0.001$), caecum (48%; $p < 0.001$) and colon (24%; $p < 0.05$) weights were evident in normal rats administered Indomethacin compared to healthy controls (Table 4). Oil treatments did not significantly affect duodenum, SI, caecum or colon weights in Indomethacin-treated rats ($p > 0.05$). There were no significant differences in visceral organ weights including heart, lungs, left kidney, right kidney, and stomach following Indomethacin or oil treatments ($p > 0.05$; Table 4).

Indomethacin significantly increased (51%) liver weight in normal rats compared to healthy controls ($p < 0.001$; Figure 5). Thymus weight in Indomethacin treated rats was decreased (55%) compared to healthy controls ($p < 0.001$; Figure 6). Indomethacin significantly increased spleen weight in normal rats compared to healthy controls (88%; $p < 0.001$; Figure 6). Neither Olive Oil nor Emu Oil treatment significantly affected liver,

thymus or spleen weights in rats administered Indomethacin compared to Indomethacin controls ($p>0.05$; Figures 5 and 6).

Neither Indomethacin nor oil treatments significantly affected duodenum or colon length ($p>0.05$; Table 5). SI length in rats administered Indomethacin was significantly decreased compared to normal controls (41%; $p<0.001$; Table 5), however, neither Emu Oil nor Olive Oil affected SI length compared to Indomethacin controls.

Intestinal Damage Severity (IDS) Scoring

IDS scores in the jejunum, JI and ileum were significantly greater in rats administered Indomethacin, compared to normal controls ($p<0.001$; Figure 7). Neither oil treatment decreased the overall IDS in rats administered Indomethacin, compared to Indomethacin controls ($p>0.05$; Figure 7).

Myeloperoxidase (MPO) Activity

Jejunal MPO activity, indicative of acute inflammation, was increased by 195% following Indomethacin administration, compared to healthy controls ($p<0.01$; Figure 8a). In the jejunum, both Olive Oil and Emu Oil significantly decreased MPO activity in Indomethacin-treated rats compared to Indomethacin controls (64%; $p<0.01$). Ileal MPO activity was significantly elevated in normal rats administered Indomethacin compared to healthy controls (104%; $p<0.01$; Figure 8b). However, in the ileum, only Emu Oil significantly reduced MPO activity in Indomethacin-administered rats compared to Indomethacin controls (50%; $p<0.05$; Figure 8b). Olive Oil did not significantly affect ileal MPO activity ($p>0.05$).

DISCUSSION

NSAIDs have been widely used to achieve analgesic, anti-nociceptive and anti-inflammatory effects; however, a major limitation of NSAID usage has been related to GI side-effects. Emu Oil has been reported to reduce the severity of experimentally-induced inflammatory GI disorders including IBD⁽²⁴⁾ and chemotherapy-induced intestinal mucositis⁽²⁸⁾. The current study indicated that Emu Oil reduced SI neutrophil infiltration and normalized total fecal output in a rat model of Indomethacin-induced enteropathy. Furthermore, Emu Oil treatment significantly increased liver and spleen weight and decreased thymus weight relative to Indomethacin controls. However, Emu Oil treatment failed to improve most other parameters associated with Indomethacin-induced SI damage.

In the current study, an 8mg/kg Indomethacin dose was employed, resulting in clinical manifestations which included significantly decreased food intake accompanied by weight loss and reduced fecal output and increased water intake, with no changes in urine output. Furthermore, elevated DAI, reduced brush border sucrase activity, as assessed indirectly by the SBT and elevated IDS were observed. In a study by Kamil *et al.*⁽²⁾, rats were administered Indomethacin daily at 6mg/kg for 7 days to induce enteropathy. Interestingly, no clinical signs of enteropathy were observed, highlighting the clinical significance of minor dosage increases of Indomethacin. Clinical manifestations of Indomethacin-enteropathy were not improved by Olive Oil or Emu Oil treatment. Moreover, fecal output was increased following oil treatment relative to Indomethacin controls, consistent with the study by Abimosleh *et al.*⁽²⁴⁾ in a rat model of IBD. This may have represented a normalization of fecal output compared to Indomethacin controls. Alternatively, increased water intake coincident with an absence of changes in urine output may have indicated water loss in stools and subsequent dehydration.

In the current study, Indomethacin decreased SI length, a phenomenon reported to be a compensatory mechanism in response to intestinal damage to increase mucosal surface area⁽³⁶⁾ and potentially protect the intestine from pathogenic invasion. Furthermore, Indomethacin increased duodenum, SI and colonic weight. Although not quantified, these weight increases may have represented mucosal, submucosal or muscularis hyperemia and oedema, potentially combined with inflammatory cell infiltration and the associated exudate. This would likely cause an increase in GI weight. Emu Oil did not improve Indomethacin-enteropathy manifestations associated with intestinal weights.

Recent studies have hypothesized that neutrophil activation is an important primary event preceding Indomethacin-induced SI injury⁽³⁷⁾. Fukumoto *et al.*⁽¹⁰⁾ demonstrated that tissue-associated neutrophil accumulation, assessed by MPO activity, and keratinocyte chemoattractant (KC) mRNA expression, involved in chemotaxis and neutrophil activation, were significantly increased in Indomethacin-treated SI mucosa⁽¹⁰⁾. Furthermore, MPO levels and KC mRNA expression were reduced in TNF- α -deficient mice treated with Indomethacin compared to wild-type. This indicated a protective role of TNF- α deficiency in decreasing Indomethacin-induced SI mucosal injury⁽¹⁰⁾. In the current study, Indomethacin increased MPO activity in the jejunum and ileum. Both Olive Oil and Emu Oil treatment significantly decreased MPO activity, indicative of neutrophil infiltration, in the Indomethacin-damaged jejunum. Importantly, only Emu Oil decreased MPO levels in the ileum, relative to Indomethacin controls. Emu Oil has previously been shown to reduce levels of TNF- α in a croton-oil induced model of auricular swelling⁽²⁷⁾. Therefore, the observed decrease in MPO levels following Emu Oil administration in the current study may have been the result of suppressed TNF- α expression.

PUFAs influence cytokine production, lymphocyte proliferation and macrophage activation state through modulation of AA (common n-6 PUFA) metabolism⁽³⁸⁾. n-3 PUFAs replace AA from phospholipid membranes, thereby reducing the availability of AA to COX and thus reducing the production of PGs involved in the inflammatory cascade such as the 2-series eicosanoids. Furthermore, n-3 PUFAs can be directly metabolized by COX, resulting in the production of anti-inflammatory 3-series eicosanoids⁽³⁸⁾. Cell culture studies with n-3 PUFAs eicosapentanoic acid (EPA) and docosahexaenoic acid (DHA) have been shown to inhibit lipopolysaccharide-induced production of COX-2, and pro-inflammatory cytokines including TNF- α , IL-1, IL-6, IL-8 and IL-12 in endothelial cells^(19, 20). Furthermore, animal feeding studies with Fish Oil, a source of EPA and DHA, supported in vitro observations of decreased cytokine production^(22, 39, 40). Further studies of Emu Oil could benefit from a complete time-course of cytokine profiling to identify potential effects on pro-inflammatory cytokine antagonism.

Liver weight was significantly increased in the current study following Indomethacin (8mg/kg), compared to normal controls. In a previous rat model of Indomethacin-enteropathy, daily administration of Indomethacin at 6mg/kg did not result in significant liver weight changes. The impact of Indomethacin on liver weight therefore appears to be dose-dependent as Ilic *et al.*⁽⁴¹⁾, consistent with the current findings, demonstrated liver weight increases in male albino Wistar rats injected daily for three days with 12.5mg/kg of diclofenac (NSAID). The authors observed pronounced parenchymal necrosis, elevated eosinophilic hepatocytes, extensive microvesicular steatosis and sinusoidal dilation⁽⁴¹⁾. Moreover, TNF- α , cytokine directly linked to the pathogenesis of enteropathy, binds to TNF-RI cell death receptors leading to hepatocyte apoptosis followed by accumulation of neutrophils⁽⁴²⁾. Future studies would benefit from liver enzyme analyses including gamma-glutamyl transpeptidase (GGT), alanine aminotransaminase (ALT), alkaline phosphatase

(ALP) and bilirubin, which elevate in NSAID-induced toxicity⁽⁴³⁾. Furthermore, histological assessment of Kupffer cells, resident liver macrophages⁽⁴⁴⁾, hepatotoxic lymphocytes including CD4⁺, CD8⁺ T cells and natural killer cells and apoptotic hepatocytes⁽⁴⁵⁾ would provide greater insight into the hepatic impact of Indomethacin.

In the current study, Olive Oil and Emu Oil treatment to rats administered Indomethacin did not significantly affect liver weight, relative to Indomethacin controls. Abimosleh *et al.*⁽²⁴⁾ examined liver weight in healthy Sprague Dawley rats, which was not significantly affected by Olive Oil or Emu Oil. This indicated that the current findings were directly related to Indomethacin administration with no effect of oil administration. Valenzuela *et al.*⁽⁴⁶⁾ demonstrated that n-3 long-chain PUFA supplementation induced an antioxidant response preventing liver steatosis in mice fed a high fat diet. This was further supported by a study in which Fish Oil in combination with Indomethacin decreased the severity of liver steatosis in a mouse model of familial hypercholesterolemia⁽³⁸⁾. Based upon the n-3 PUFAs present in Emu Oil and its reported antioxidant activity⁽⁴⁷⁾, liver steatosis seems less likely in the current study. However, a high n-6/n-3 PUFA ratio has been implicated in non-alcoholic FA liver disease⁽⁴⁸⁾ and therefore it would be beneficial to determine the effects of FA ratio and n-9 FA levels on liver function in future studies.

Thymus weight was significantly decreased following administration of 8mg/kg Indomethacin in the current study, relative to normal controls. Kamil *et al.*⁽²⁾ did not report any thymus weight changes using 6mg/kg of oral Indomethacin. However, a single subcutaneous injection of Indomethacin at 35mg/kg significantly decreased thymus weight in rats after three days in a study⁽³⁶⁾ by Filaretova *et al.*⁽³⁶⁾, consistent with the current study. Furthermore, the increased spleen weight evident following Indomethacin administration in the current study should be pursued in relation to the thymus weight decreases. Such

studies could determine the contribution of T (CD4⁺ and CD8⁺) and B lymphocyte upregulation or suppression in the thymus and spleen, respectively. However, neither Olive Oil nor Emu Oil significantly affected thymus or spleen weight.

CONCLUSIONS

In summary, Emu Oil significantly reduced SI MPO activity associated with Indomethacin-induced enteropathy. However, EO failed to improve other clinical manifestations of enteropathy. It remains unclear whether the reduction in acute inflammation would translate to improved clinical manifestation if Emu Oil dose was increased. Increased Emu Oil dose or frequency of administration could further decrease the extent of small bowel inflammation in NSAID-enteropathy and potentially achieve demonstrable clinical benefit.

ACKNOWLEDGEMENTS

The authors would like to thank Kerry Lymn for significantly contributing towards the animal trials and Esther Burt, Betty Zacharakis and Katie Lowe for analysis of breath samples. S.M.A. conducted all animal trials, experiments and data analyses and prepared the final manuscript. C.D.T. assisted with experimental planning and analysis of data. G.S.H. contributed to the experimental design, analysis of data and manuscript preparation. G.S.H. is supported by a South Australian Health and Medical Research Institute Cancer Council South Australia Senior Research Fellowship.

REFERENCES

1. Green GA. Understanding NSAIDs: from aspirin to COX-2. *Clin Cornerstone*. 2001;3(5):50-60.
2. Kamil R, Geier MS, Butler RN, *et al*. *Lactobacillus rhamnosus* GG exacerbates intestinal ulceration in a model of indomethacin-induced enteropathy. *Dig Dis Sci*. 2007 May;52(5):1247-52.
3. Scarpignato C. NSAID-induced intestinal damage: are luminal bacteria the therapeutic target? *Gut*. 2008 Feb;57(2):145-8.
4. Hawcroft G, D'Amico M, Albanese C, *et al*. Indomethacin induces differential expression of beta-catenin, gamma-catenin and T-cell factor target genes in human colorectal cancer cells. *Carcinogenesis*. 2002 Jan;23(1):107-14.
5. Boelsterli UA, Redinbo MR, Saitta K. Multiple NSAID-induced hits injure the small intestine: Underlying mechanisms and novel strategies. *Toxicol Sci*. 2012 Oct 22.
6. Scarpignato C, Hunt RH. Nonsteroidal antiinflammatory drug-related injury to the gastrointestinal tract: clinical picture, pathogenesis, and prevention. *Gastroenterol Clin North Am*. 2010 Sep;39(3):433-64.
7. Reuter BK, Davies NM, Wallace JL. Nonsteroidal anti-inflammatory drug enteropathy in rats: role of permeability, bacteria, and enterohepatic circulation. *Gastroenterology*. 1997 Jan;112(1):109-17.
8. Somasundaram S, Sigthorsson G, Simpson RJ, *et al*. Uncoupling of intestinal mitochondrial oxidative phosphorylation and inhibition of cyclooxygenase are required for the development of NSAID-enteropathy in the rat. *Aliment Pharmacol Ther*. 2000 May;14(5):639-50.
9. Lanas A, Scarpignato C. Microbial flora in NSAID-induced intestinal damage: a role for antibiotics? *Digestion*. 2006;73 Suppl 1:136-50.

10. Fukumoto K, Naito Y, Takagi T, *et al.* Role of tumor necrosis factor-alpha in the pathogenesis of indomethacin-induced small intestinal injury in mice. *Int J Mol Med.* 2011 Mar;27(3):353-9.
11. Takeuchi K, Tanigami M, Amagase K, *et al.* Endogenous prostaglandin E2 accelerates healing of indomethacin-induced small intestinal lesions through upregulation of vascular endothelial growth factor expression by activation of EP4 receptors. *J Gastroenterol Hepatol.* 2010 May;25 Suppl 1:S67-74.
12. Takeuchi K, Tanaka A, Kato S, *et al.* Roles of COX inhibition in pathogenesis of NSAID-induced small intestinal damage. *Clin Chim Acta.* 2010 Apr 2;411(7-8):459-66.
13. Patrignani P, Tacconelli S, Sciulli MG, *et al.* New insights into COX-2 biology and inhibition. *Brain Res Brain Res Rev.* 2005 Apr;48(2):352-9.
14. Sigthorsson G, Simpson RJ, Walley M, *et al.* COX-1 and 2, intestinal integrity, and pathogenesis of nonsteroidal anti-inflammatory drug enteropathy in mice. *Gastroenterology.* 2002 Jun;122(7):1913-23.
15. Maehata Y, Esaki M, Morishita T, *et al.* Small bowel injury induced by selective cyclooxygenase-2 inhibitors: a prospective, double-blind, randomized clinical trial comparing celecoxib and meloxicam. *J Gastroenterol.* 2012 Apr;47(4):387-93.
16. Maiden L, Thjodleifsson B, Seigal A, *et al.* Long-term effects of nonsteroidal anti-inflammatory drugs and cyclooxygenase-2 selective agents on the small bowel: a cross-sectional capsule enteroscopy study. *Clin Gastroenterol Hepatol.* 2007 Sep;5(9):1040-5.
17. Miles EA, Calder PC. Influence of marine n-3 polyunsaturated fatty acids on immune function and a systematic review of their effects on clinical outcomes in rheumatoid arthritis. *Br J Nutr.* 2012 Jun;107 Suppl 2:S171-84.
18. Tenikoff D, Murphy KJ, Le M, *et al.* Lyprinol (stabilised lipid extract of New Zealand green-lipped mussel): a potential preventative treatment modality for inflammatory bowel disease. *J Gastroenterol.* 2005 Apr;40(4):361-5.

19. Lo CJ, Chiu KC, Fu M, *et al.* Fish oil decreases macrophage tumor necrosis factor gene transcription by altering the NF kappa B activity. *J Surg Res.* 1999 Apr;82(2):216-21.
20. Khalfoun B, Thibault F, Watier H, *et al.* Docosahexaenoic and eicosapentaenoic acids inhibit in vitro human endothelial cell production of interleukin-6. *Adv Exp Med Biol.* 1997;400B:589-97.
21. De Caterina R, Libby P. Control of endothelial leukocyte adhesion molecules by fatty acids. *Lipids.* 1996 Mar;31 Suppl:S57-63.
22. Whiting CV, Bland PW, Tarlton JF. Dietary n-3 polyunsaturated fatty acids reduce disease and colonic proinflammatory cytokines in a mouse model of colitis. *Inflamm Bowel Dis.* 2005 Apr;11(4):340-9.
23. Abimosleh SM, Tran CD, Howarth GS. Emu Oil: a novel therapeutic for disorders of the gastrointestinal tract? *J Gastroen Hepatol.* 2012 May;27(5):857-61.
24. Abimosleh SM, Lindsay RJ, Butler RN, *et al.* Emu oil increases colonic crypt depth in a rat model of ulcerative colitis. *Digestive Diseases and Sciences.* 2012 Apr;57(4):887-96.
25. Whitehouse MW, Turner AG, Davis CK, *et al.* Emu oil(s): A source of non-toxic transdermal anti-inflammatory agents in aboriginal medicine. *Inflammopharmacology.* 1998;6(1):1-8.
26. Snowden JM, Whitehouse MW. Anti-inflammatory activity of emu oils in rats. *Inflammopharmacology.* 1997;5(2):127-32.
27. Yoganathan S, Nicolosi R, Wilson T, *et al.* Antagonism of croton oil inflammation by topical emu oil in CD-1 mice. *Lipids.* 2003 Jun;38(6):603-7.
28. Lindsay RJ, Geier MS, Yazbeck R, *et al.* Orally administered emu oil decreases acute inflammation and alters selected small intestinal parameters in a rat model of mucositis. *British Journal of Nutrition.* 2010 Aug;104(4):513-9.

29. Tomas FM, Knowles SE, Owens PC, *et al.* Effects of full-length and truncated insulin-like growth factor-I on nitrogen balance and muscle protein metabolism in nitrogen-restricted rats. *J Endocrinol.* 1991 Jan;128(1):97-105.
30. Portolesi R, Powell BC, Gibson RA. Competition between 24:5n-3 and ALA for Delta 6 desaturase may limit the accumulation of DHA in HepG2 cell membranes. *J Lipid Res.* 2007 Jul;48(7):1592-8.
31. Murthy SN, Cooper HS, Shim H, *et al.* Treatment of dextran sulfate sodium-induced murine colitis by intracolonic cyclosporin. *Dig Dis Sci.* 1993 Sep;38(9):1722-34.
32. Howarth GS, Xian CJ, Read LC. Predisposition to colonic dysplasia is unaffected by continuous administration of insulin-like growth factor-I for twenty weeks in a rat model of chronic inflammatory bowel disease. *Growth Factors.* 2000;18(2):119-33.
33. Pelton NC, Tivey DR, Howarth GS, Davidson GP, Butler RN. A novel breath test for the non-invasive assessment of small intestinal mucosal injury following methotrexate administration in the rat. *Scand J Gastroenterol* 2004;39:1015-6.
34. Tooley KL, Howarth GS, Butler RN. Mucositis and non-invasive markers of small intestinal function. *Cancer Biol Ther.* 2009 May;8(9):753-8.
35. Howarth GS, Francis GL, Cool JC, *et al.* Milk growth factors enriched from cheese whey ameliorate intestinal damage by methotrexate when administered orally to rats. *J Nutr.* 1996 Oct;126(10):2519-30.
36. Filaretova LP, Bagaeva TR, Morozova OY, *et al.* The healing of NSAID-induced gastric lesion may be followed by small intestinal and cardiovascular side effects. *J Physiol Pharmacol.* 2011 Dec;62(6):619-25.
37. Santucci L, Fiorucci S, Di Matteo FM, *et al.* Role of tumor necrosis factor alpha release and leukocyte margination in indomethacin-induced gastric injury in rats. *Gastroenterology.* 1995 Feb;108(2):393-401.

38. Murali G, Milne GL, Webb CD, *et al.* Fish oil and indomethacin in combination potently reduce dyslipidemia and hepatic steatosis in LDLR(-/-) mice. *J Lipid Res.* 2012 Oct;53(10):2186-97.
39. Renier G, Skamene E, DeSanctis J, *et al.* Dietary n-3 polyunsaturated fatty acids prevent the development of atherosclerotic lesions in mice. Modulation of macrophage secretory activities. *Arterioscler Thromb.* 1993 Oct;13(10):1515-24.
40. Yaqoob P, Calder P. Effects of dietary lipid manipulation upon inflammatory mediator production by murine macrophages. *Cell Immunol.* 1995 Jun;163(1):120-8.
41. Ilic S, Drmic D, Franjic S, *et al.* Pentadecapeptide BPC 157 and its effects on a NSAID toxicity model: diclofenac-induced gastrointestinal, liver, and encephalopathy lesions. *Life Sci.* 2011 Mar 14;88(11-12):535-42.
42. Mouzaoui S, Rahim I, Djerdjouri B. Aminoguanidine and curcumin attenuated tumor necrosis factor (TNF)-alpha-induced oxidative stress, colitis and hepatotoxicity in mice. *Int Immunopharmacol.* 2012 Jan;12(1):302-11.
43. Herath CB, Mak K, Burrell LM, *et al.* Angiotensin-(1-7) reduces the portal pressure response to angiotensin II and methoxamine via an endothelial nitric oxide mediated pathway in cirrhotic rat liver. *Am J Physiol Gastrointest Liver Physiol.* 2012 Oct 18.
44. Abdel-Zaher AO, Abdel-Rahman MM, Hafez MM, *et al.* Role of nitric oxide and reduced glutathione in the protective effects of aminoguanidine, gadolinium chloride and oleanolic acid against acetaminophen-induced hepatic and renal damage. *Toxicology.* 2007 May 5;234(1-2):124-34.
45. Wakabayashi H, Ito T, Fushimi S, *et al.* Spred-2 deficiency exacerbates acetaminophen-induced hepatotoxicity in mice. *Clin Immunol.* 2012 Sep;144(3):272-82.
46. Valenzuela R, Espinosa A, Gonzalez-Manan D, *et al.* N-3 long-chain polyunsaturated Fatty Acid supplementation significantly reduces liver oxidative stress in high fat induced steatosis. *PLoS One.* 2012;7(10):e46400.

47. Bennett DC, Code WE, Godin DV, *et al.* Comparison of the antioxidant properties of emu oil with other avian oils. *Australian Journal of Experimental Agriculture.* 2008;48:1345-50.
48. Araya J, Rodrigo R, Videla LA, *et al.* Increase in long-chain polyunsaturated fatty acid n - 6/n - 3 ratio in relation to hepatic steatosis in patients with non-alcoholic fatty liver disease. *Clin Sci (Lond).* 2004 Jun;106(6):635-43.

FIGURE LEGENDS

Figure 1. Macroscopic aspects of opened rat small intestinal sections representing (a) no damage (b) erythema and hemorrhage (c) severe hemorrhage (d) large single ulcer (e) large cluster of ulcers and (f) perforations. These parameters were utilized in the intestinal damage severity scoring system.

Figure 2. Percentage change of body weight in rats from day 5 to day 11 (during Indomethacin administration). Rats were gavaged daily with water, Olive Oil or Emu Oil (0.5ml) throughout the experimental period and commenced daily gavage with water or Indomethacin (8mg/kg) on day 5. Rats were fasted overnight on day 11 and therefore day 12 body weight data was not included. Data are expressed as mean (% change in body weight) \pm standard error of the mean. *** indicates $p < 0.001$ compared to Water+Water.

Figure 3. Total (a) food intake (b) water intake (c) fecal output and (d) urine output in rats during Indomethacin administration (days 5-12). Rats were gavaged daily with water, Olive Oil or Emu Oil (0.5ml). Data are expressed as mean (g or ml) \pm standard error of the mean. *** indicates $p < 0.001$, ** indicates $p < 0.01$ compared to Water+Water; ^ indicates $p < 0.05$ compared to Indomethacin+Water.

Figure 4. Overall functional status of small intestinal health in rats assessed utilizing the ^{13}C sucrose breath test on day 12. Rats were gavaged daily with water, Olive Oil or Emu Oil (0.5ml) throughout the experimental period and commenced daily gavage with water or Indomethacin (8mg/kg) on day 5. Data are expressed as mean (% cumulative dose of ^{13}C at 90 minutes; %CD90) \pm standard error of the mean. *** indicates $p < 0.001$ compared to Water+Water.

Figure 5. Liver weights following adjustment for rat body weight on day 12. Rats were gavaged daily with 0.5ml of water, Olive Oil or Emu Oil throughout the experimental period (days 0-12) and administered water or Indomethacin (Indo; 8mg/kg) daily from day 5. Data are expressed as mean (% relative to bodyweight; BW) \pm standard error of the mean. *** indicates $p < 0.001$ compared to Water+Water.

Figure 6. Thymus and spleen weights following adjustment for rat body weight on day 12. Rats were gavaged daily with 0.5ml of water, Olive Oil or Emu Oil throughout the experimental period (days 0-12) and administered water or Indomethacin (Indo; 8mg/kg) daily from day 5. Data are expressed as mean (% relative to bodyweight; BW) \pm standard error of the mean. *** indicates $p < 0.001$ compared to Water+Water.

Figure 7. Intestinal damage severity score in the rat jejunum, jejunum-ileum junction (JI) and ileum on day 12. Rats were gavaged daily with 0.5ml of water, Olive Oil or Emu Oil throughout the experimental period (days 0-12) and administered water or Indomethacin (Indo; 8mg/kg) daily from day 5. Data are expressed as mean (severity score) \pm standard error of the mean. *** indicates $p < 0.001$ compared to Water+Water.

Figure 8. Myeloperoxidase activity indicative of acute inflammation in the rat (a) jejunum and (b) ileum on day 12. Data are expressed as mean (myeloperoxidase activity; units per gram; U/g) \pm standard error of the mean. Rats were gavaged daily with 0.5ml of water, Olive Oil or Emu Oil throughout the experimental period (days 0-12) and administered water or Indomethacin (Indo; 8mg/kg) daily from day 5. ** indicates $p < 0.01$ compared to Water+Water; ^^ indicates $p < 0.01$, ^ indicates $p < 0.05$ compared to Indomethacin+Water.

Table 1. Major fatty acid (FA) composition of Emu and Olive Oils used in the current study including unsaturated fatty acid (UFA) and saturated fatty acid (SFA) ratios. Monounsaturated fatty acid (MUFA); polyunsaturated fatty acid (PUFA).

Major FA Composition of Emu and Olive Oils			
Fatty Acid	Common Name	Emu	Olive
16:0	Palmitic acid	24	10.4
16:1n-7	Palmitoleic acid	4.3	0.7
18:0	Stearic acid	8.5	3.1
18:1n-9	Oleic acid	49.1	73.9
18:2n-6	Linoleic acid	9.5	8.4
18:3n-3	α -Linolenic acid	1.1	0.7
Saturated		32.5	13.5
MUFA		53.4	74.6
PUFA		10.6	9.1
UFA:SFA ratio		2	6.2

Table 2. Body weight (% change from starting body weight), total food (g) and water (ml) intake and total fecal (g) and urine (ml) output in normal rats during the period prior to Indomethacin administration (days 0-4). Rats were gavaged daily with water, Olive Oil or Emu Oil (0.5ml). Data are expressed as mean (% , g or ml) \pm standard error of the mean. * indicates $p < 0.05$ compared to Water group.

	Water	Olive Oil	Emu Oil
Body weight (%)	14.8 \pm 0.5	14.8 \pm 0.6	14.4 \pm 0.6
Food Intake (g)	85.1 \pm 1.5	83.4 \pm 1.9	84.6 \pm 2
Water Intake (ml)	353.6 \pm 38.9	429.4 \pm 50.6	425.6 \pm 58.6
Fecal Ouput (g)	7.8 \pm 0.4	6.1 \pm 0.5*	7.1 \pm 0.3
Urine Ouput (ml)	65.2 \pm 3.6	66.9 \pm 6.5	68.2 \pm 4.2

Table 3. Disease activity index (DAI) of rats gavaged daily with 0.5ml of water, Olive Oil or Emu Oil throughout the experimental period (days 0-12) and administered water or Indomethacin (Indo; 8mg/kg) daily on day 5. Data are expressed as median disease activity index score (range). *** indicates $p < 0.001$, ** indicates $p < 0.01$ compared to Water+Water.


Day of trial	Water+Water	Indo+Water	Indo+Olive Oil	Indo+Emu Oil
6	0 (0)	0 (0)	0 (0)	0 (0)
7	0 (0)	0 (0)	0 (0)	0 (0)
8	0 (0)	0 (0-2)	0 (0)	0 (0)
9	0 (0)	0 (0-6)	0 (0-1)	0 (0-3)
10	0 (0)	1 (0-7)**	1 (0-3)	0 (0-4)
11	0 (0)	2 (1-7)***	2 (0-4)	1 (0-5)
12	0 (0)	2 (1-8)***	3 (0-5)	2 (0-7)

Table 4. Organ weight following adjustment for rat body weight. Rats were gavaged daily with 0.5ml of water, Olive Oil or Emu Oil throughout the experimental period (days 0-12) and administered water or Indomethacin (Indo; 8mg/kg) daily from day 5. Data are expressed as mean (% relative to body weight) \pm standard error of the mean. All values $\times 10^{-2}$. *** indicates $p < 0.001$, * indicates $p < 0.05$ compared to Water+Water.

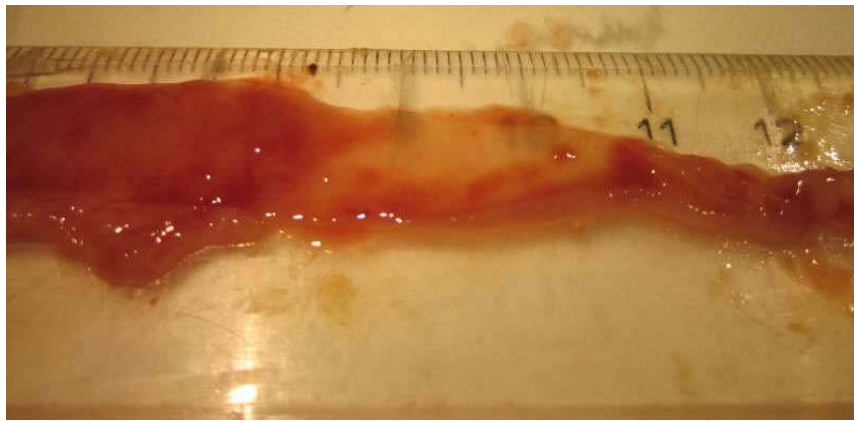
Weight (%)	Water+Water	Indo+Water	Indo+Olive Oil	Indo+Emu Oil
Heart	42 \pm 0	41 \pm 2	42 \pm 2	40 \pm 1
Lungs	62 \pm 3	59 \pm 4	61 \pm 4	57 \pm 3
L Kidney	40 \pm 1	43 \pm 1	41 \pm 1	41 \pm 2
R Kidney	44 \pm 4	42 \pm 1	52 \pm 6	42 \pm 2
Stomach	56 \pm 2	66 \pm 7	59 \pm 11	57 \pm 4
Duodenum	22 \pm 1	37 \pm 5*	49 \pm 5	39 \pm 6
SI	178 \pm 5	263 \pm 38***	330 \pm 17	270 \pm 40
Caecum	29 \pm 1	43 \pm 2***	46 \pm 3	46 \pm 3
Colon	38 \pm 1	47 \pm 1*	50 \pm 2	49 \pm 3

Table 5. Gastrointestinal organ length of rats gavaged daily with 0.5ml of water, Olive Oil or Emu Oil throughout the experimental period (days 0-12) and administered water or Indomethacin (Indo; 8mg/kg) daily from day 5. Data are expressed as mean (cm) \pm standard error of the mean. *** indicates $p < 0.001$ compared to Water+Water.

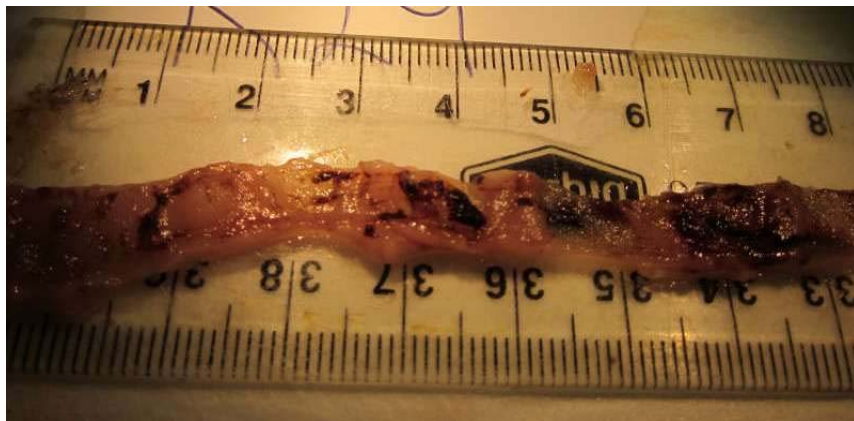
Length (cm)	Water+Water	Indo+Water	Indo+Olive Oil	Indo+Emu Oil
Duodenum	6.5 \pm 0.3	5.6 \pm 0.3	6.6 \pm 0.4	6.2 \pm 0.4
SI	78.5 \pm 2.2	46.2 \pm 2.1***	51.0 \pm 3.4	51.0 \pm 3.4
Colon	12.9 \pm 0.4	11.8 \pm 0.6	12.0 \pm 0.4	12.2 \pm 0.5



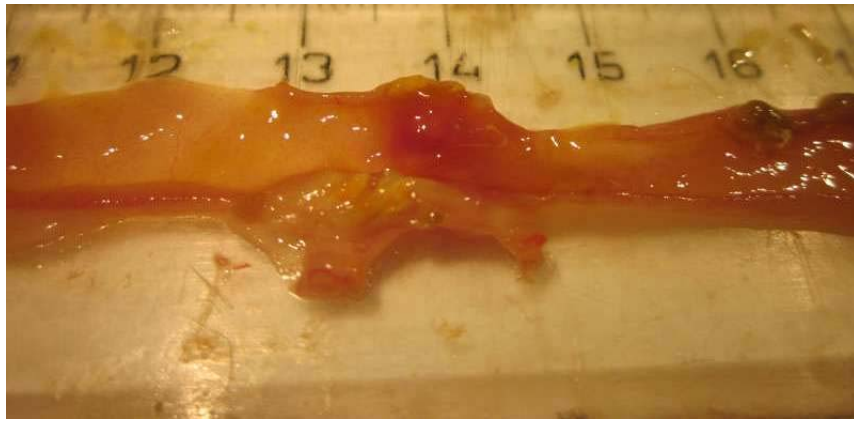
(a)



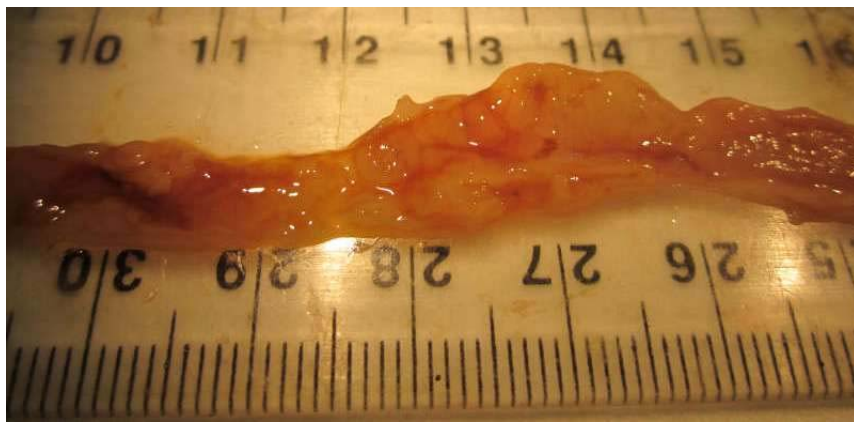
(b)



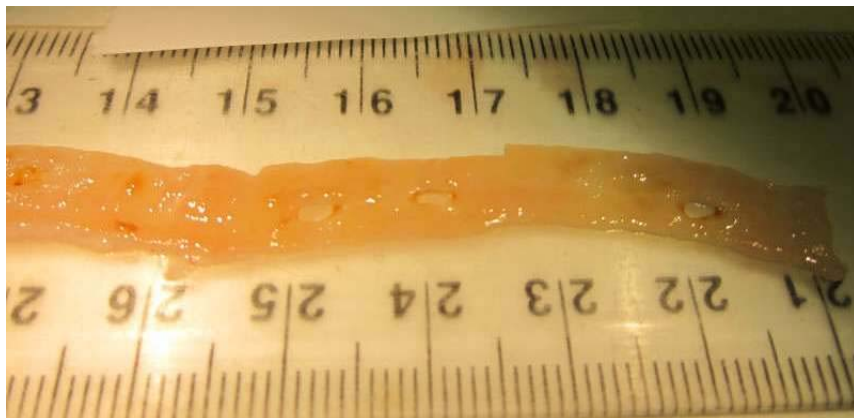
(c)



(d)



(e)



(f)

Figure 1.

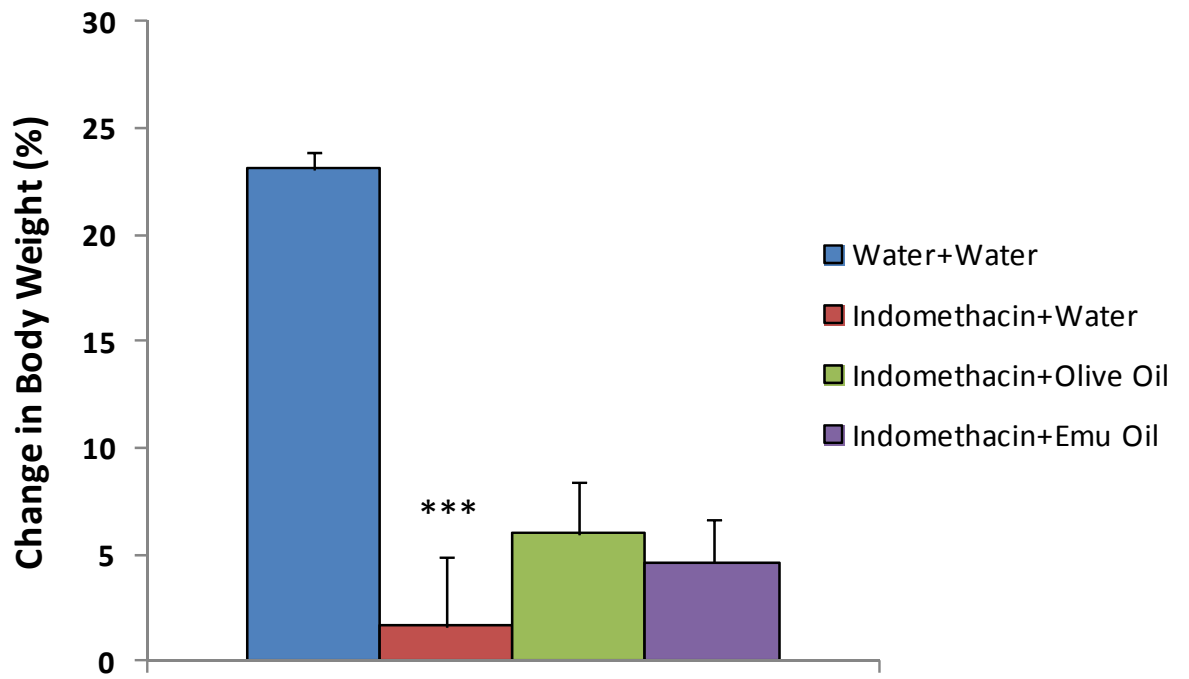
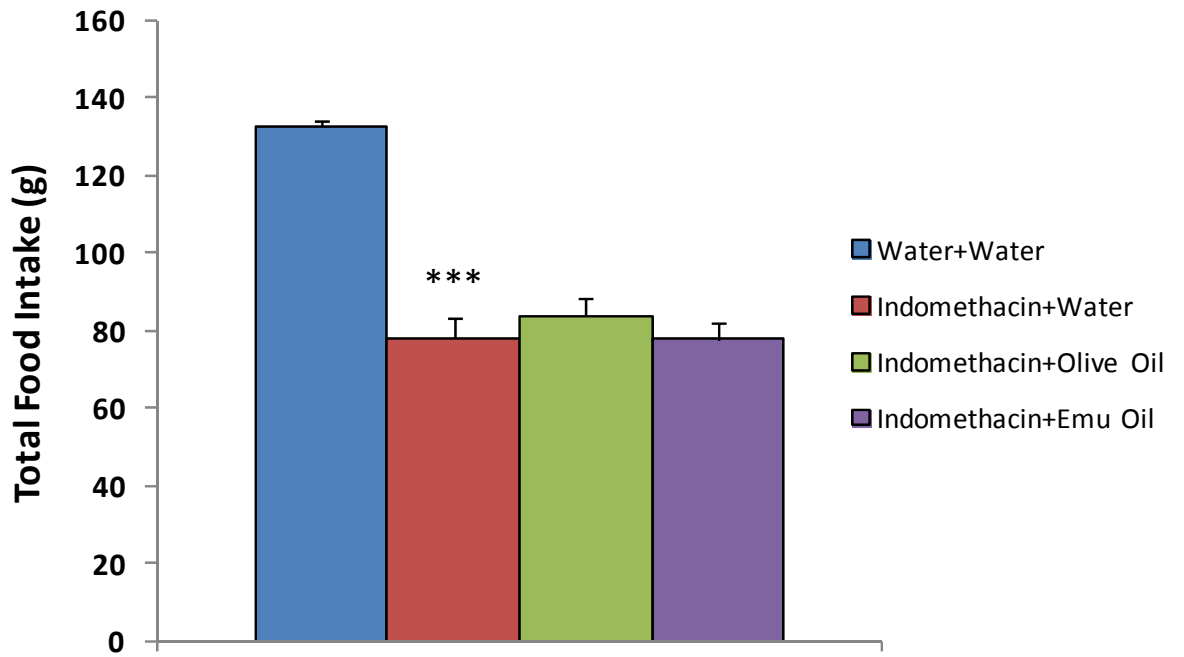
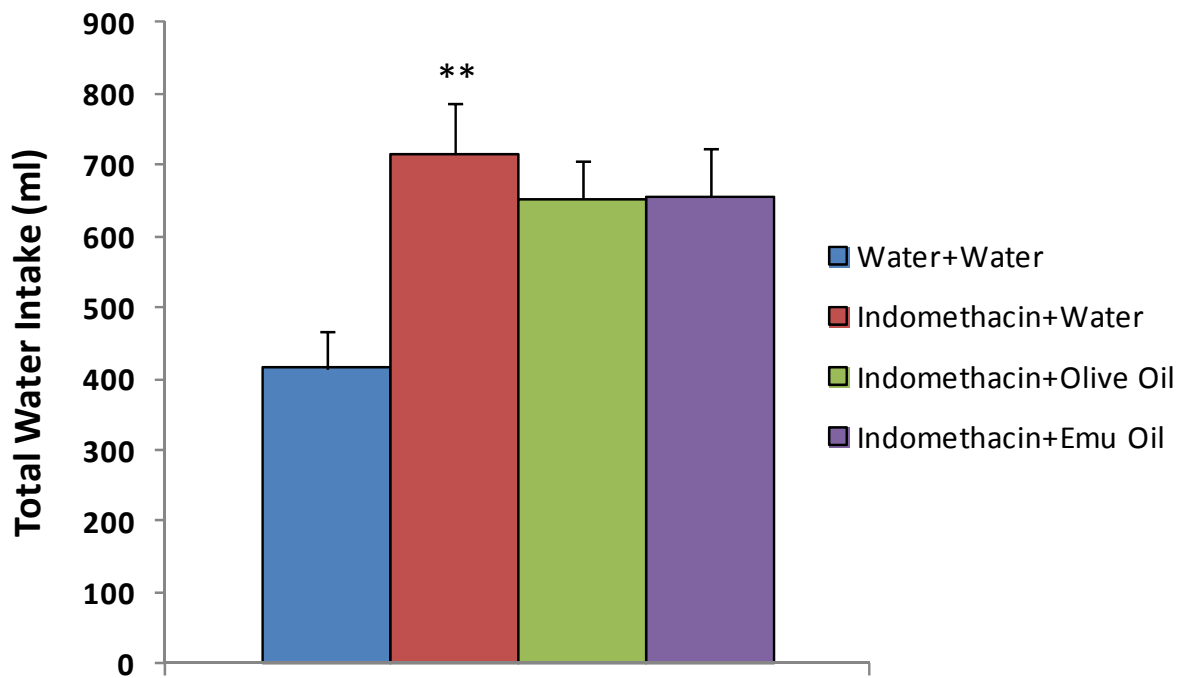


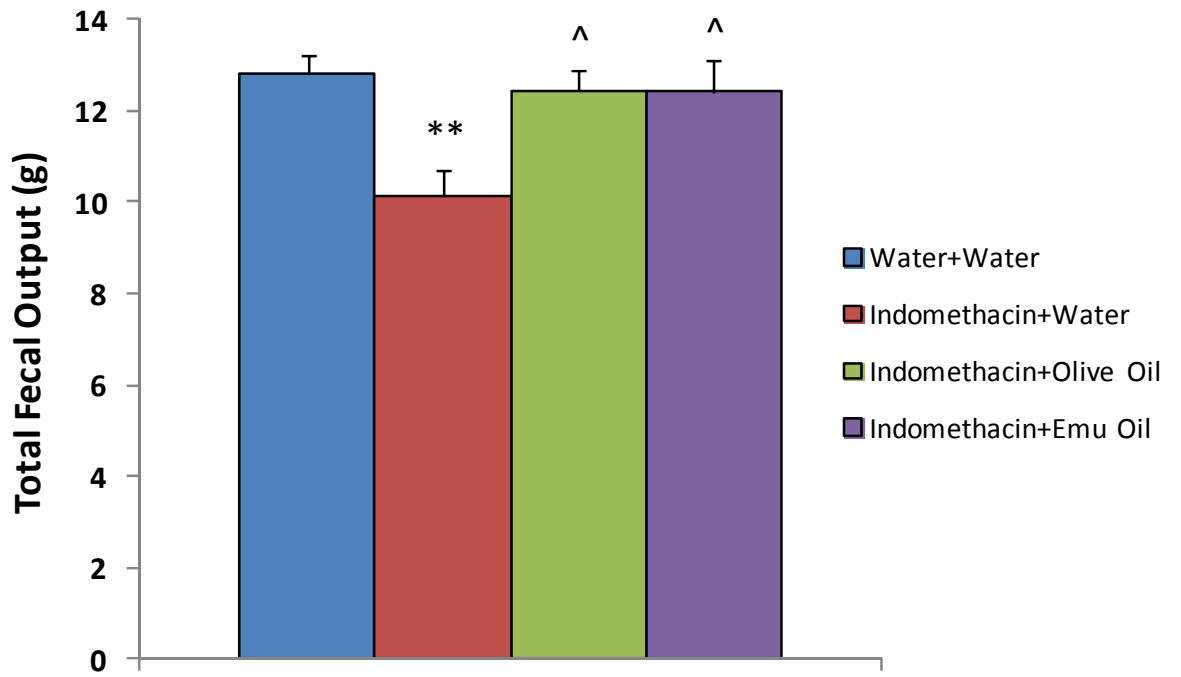
Figure 2.



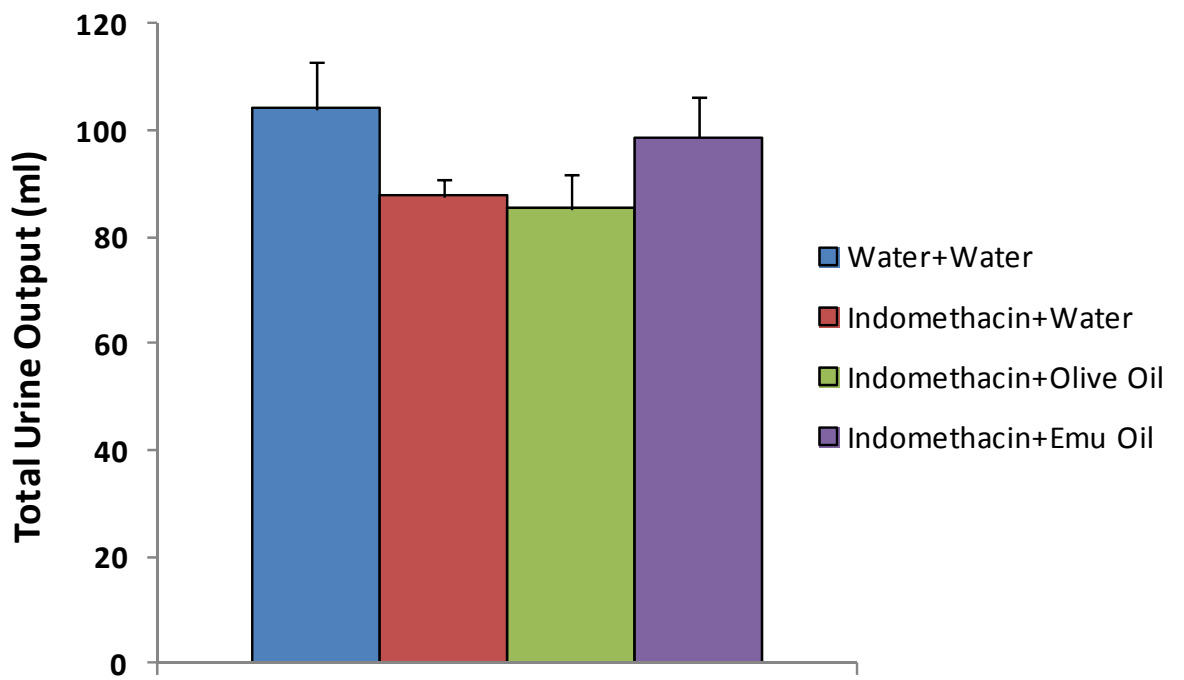
(a)



(b)



(c)



(d)

Figure 3.

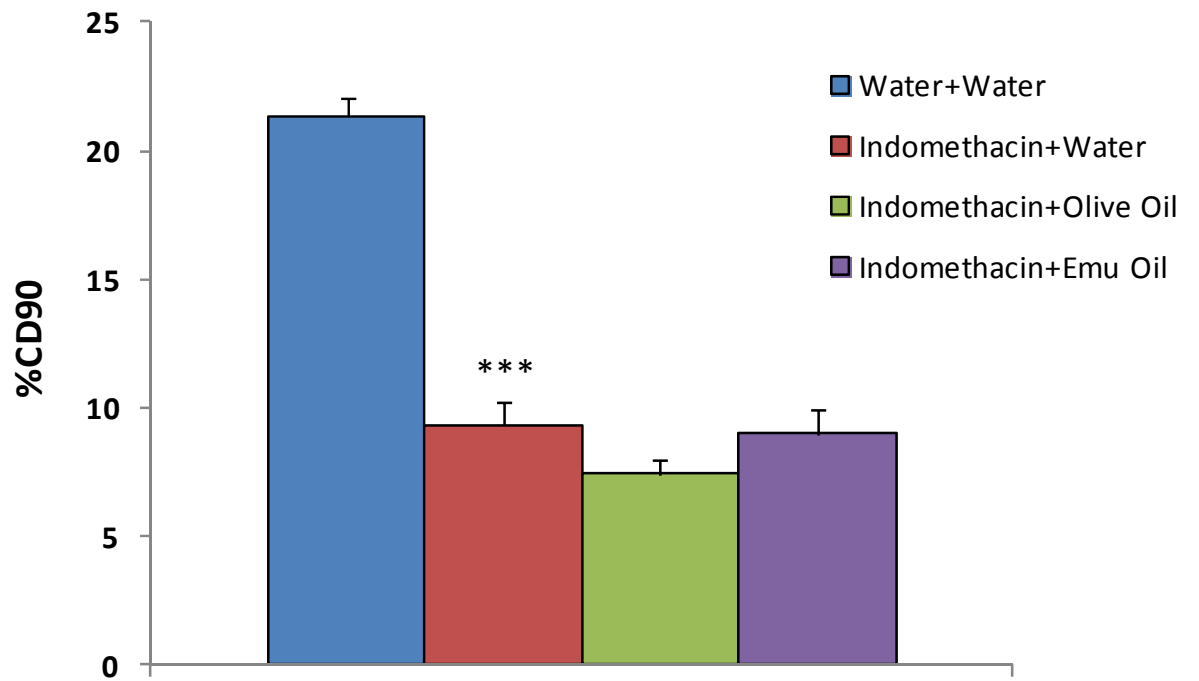


Figure 4.

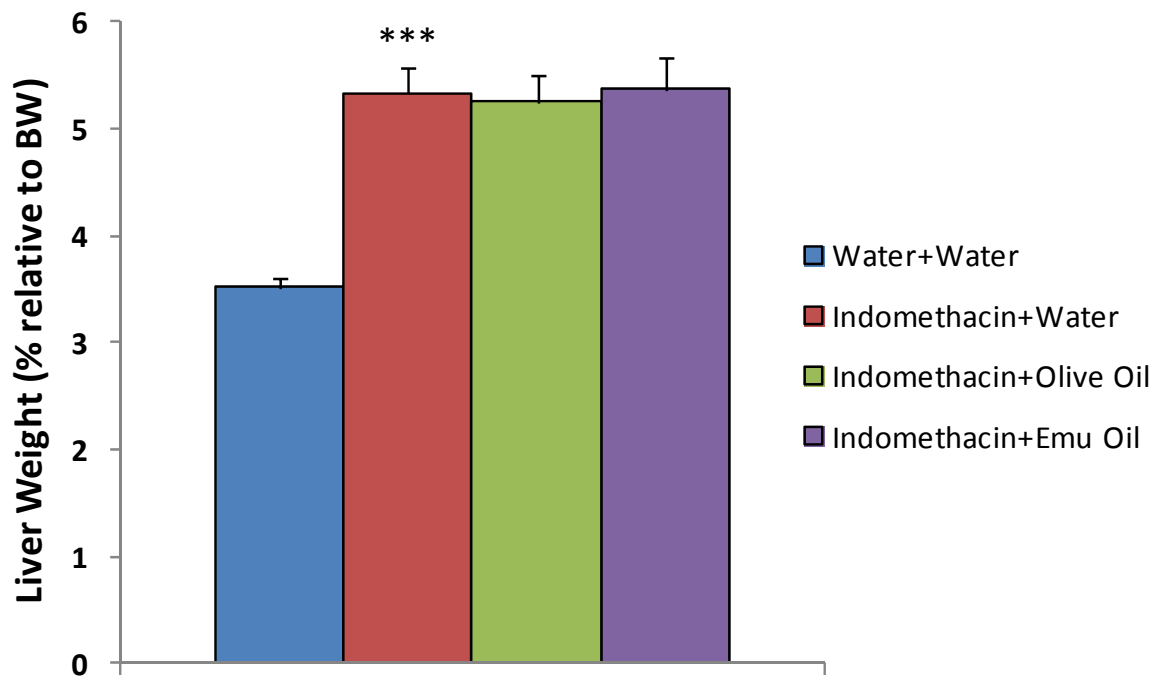


Figure 5.

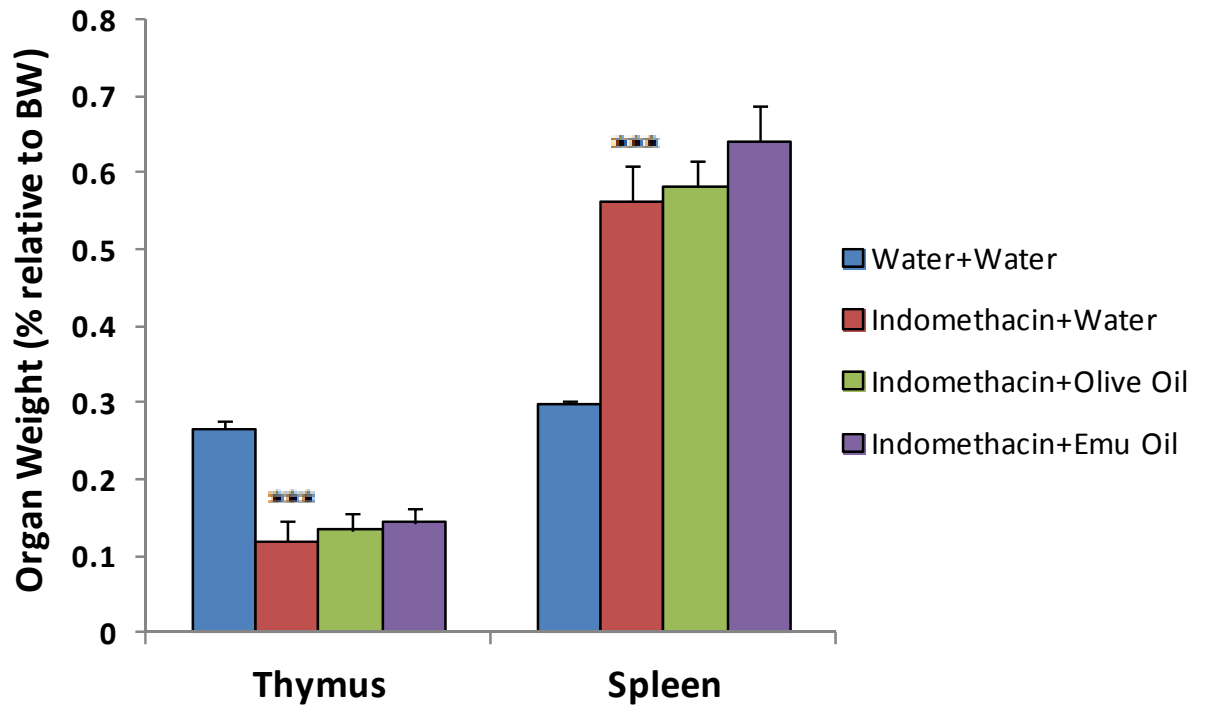


Figure 6.

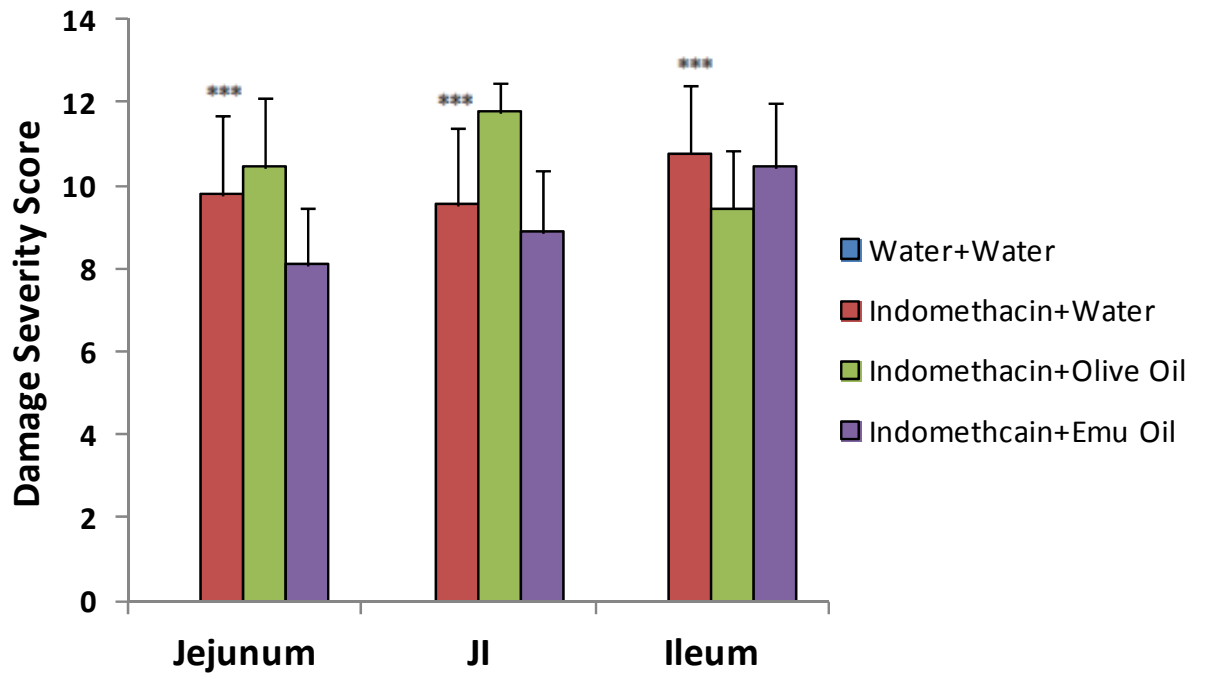
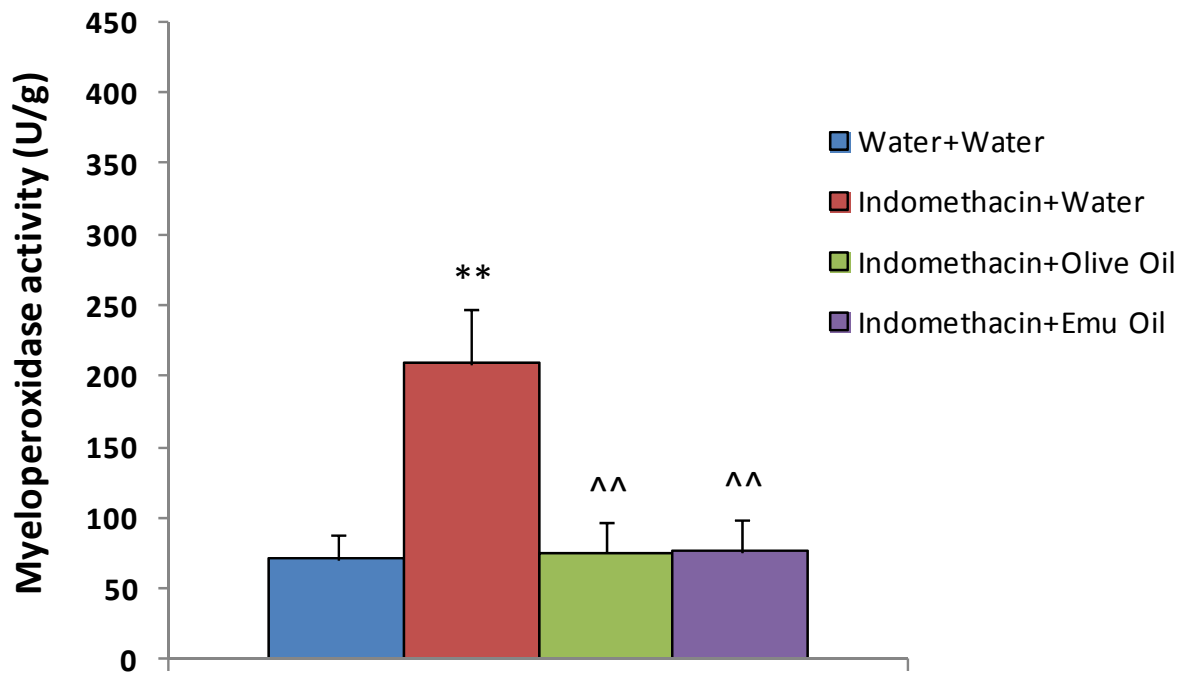
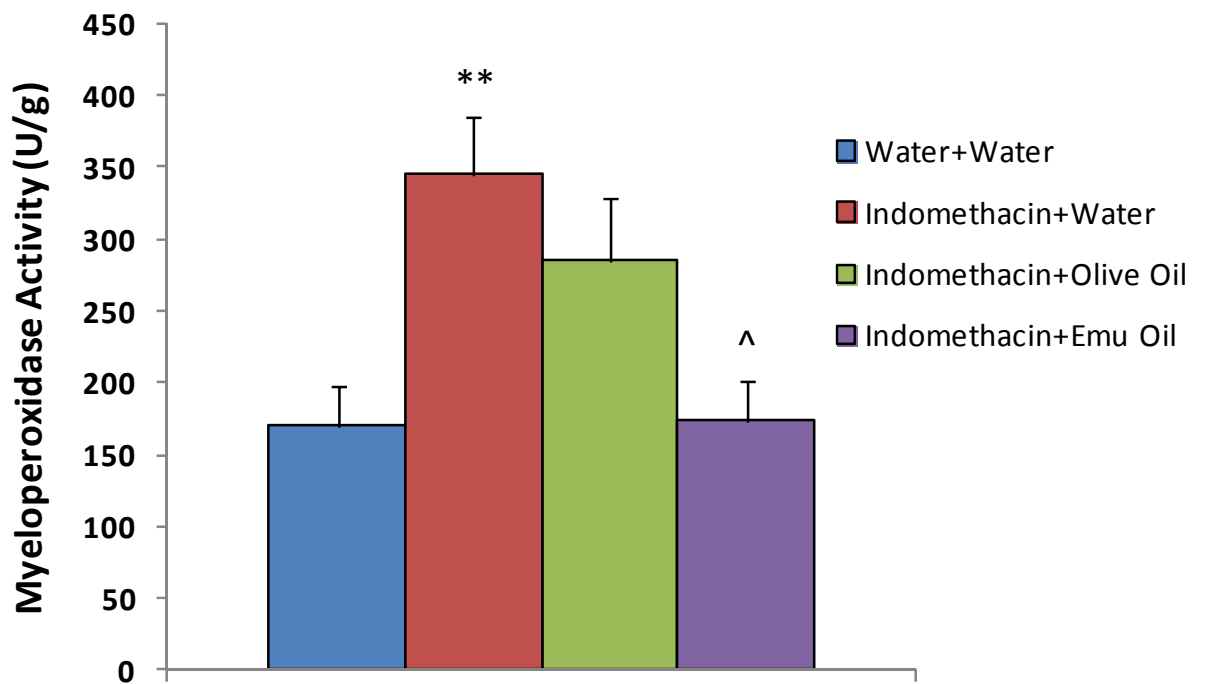


Figure 7.



(a)



(b)

Figure 8.

CHAPTER 5

**PROCESSING OF RATITE OILS AFFECTS PRIMARY OXIDATION
STATUS, RESULTING IN GREATER RADICAL SCAVENGING
PROPERTIES FOR EMU OIL COMPARED TO RHEA AND
OSTRICH OILS**

CONTEXT STATEMENT

The work contained in this chapter is currently under review in the *Journal of Food Science*.

SM Abimosleh, DC Bennett, CD Tran, GS Howarth. Processing of Ratite Oils Affects Primary Oxidation Status, Resulting in Greater Radical Scavenging Properties for Emu Oil Compared to Rhea and Ostrich Oils. *Journal of Food Science* 2012; Under review

Chapter 5 describes the influence of farm location, rendering method, duration and storage mode on free radical scavenging activity and primary oxidation status of Ratite Oils. Different batches of Emu Oil were compared with Ostrich Oil, Rhea Oil and Olive Oil.

STATEMENT OF AUTHORSHIP

Processing of Ratite Oils Affects Primary Oxidation Status, Resulting in Greater Radical Scavenging Properties for Emu Oil Compared to Rhea and Ostrich Oils

Journal of Food Science 2012; Under review

Suzanne Mashtoub ABIMOSLEH (Candidate)

Conducted all experimental work, analysed data, interpreted results, prepared figures and manuscript.

I hereby certify that the statement of contribution is accurate.

Signed

Date 3/12/12

Darin C. Bennett

Contributed to experimental conceptualisation and design, data analyses and interpretation of results.

I hereby certify that the statement of contribution is accurate.

Signed

Date 22 Nov 2012

Cuong D. Tran

Contributed to experimental conceptualisation and design, data interpretation.

I hereby certify that the statement of contribution is accurate.

Signed

Date 3/12/12

Gordon S. Howarth

Contributed to experimental conceptualisation and design, data interpretation, critical manuscript evaluation.

I hereby certify that the statement of contribution is accurate.

Signed

Date 3/12/12.

Processing of Ratite Oils Affects Primary Oxidation Status, Resulting in Greater Radical Scavenging Properties for Emu Oil Compared to Rhea and Ostrich Oils

Suzanne M. Abimosleh^{1,2,3}, Darin C. Bennett³, Cuong D. Tran^{1,2}, Gordon S. Howarth^{1,2,4*}

¹Department of Gastroenterology, Women's and Children's Hospital, North Adelaide, Australia

²Discipline of Physiology, School of Medical Sciences, Faculty of Health Sciences, The University of Adelaide, Adelaide, Australia

³Avian Research Centre, Faculty of Land and Food Systems, University of British Columbia, British Columbia, Canada

⁴School of Animal and Veterinary Sciences, The University of Adelaide, Roseworthy, Australia

*Corresponding author: Gordon S. Howarth, School of Animal and Veterinary Sciences, The University of Adelaide, Roseworthy Campus, South Australia, Australia, 5371

Phone: 618-8313-7885 Fax: 618-8313-7972 Email: gordon.howarth@adelaide.edu.au

Word Count: 4, 077

Short Title: Ratite Oils- Antioxidants & Oxidation

Choice of Journal: The Journal of Food Science

Abstract

Background. Treatments for diseases such as coronary artery disease and gastrointestinal disorders seek to minimise oxidative damage by free radicals through the use of antioxidants. Oils derived from ratites (flightless birds) predominantly comprise fatty acids varying in composition between ratite species. **Aim.** The current study investigated the influence of farm location, rendering method, duration and storage mode on radical scavenging activity (RSA) and primary oxidation status of Ratite Oils. **Methods.** Emu Oil (n=8; EO1, EO2a/b, EO3-7; varying processing and storage factors), Ostrich Oil (OsO), Rhea Oil (RO) and Olive Oil (OIO) were tested for free RSA against 2,2-diphenyl-1-picrylhydracyl (expressed as 1/IC50 g/ml) and primary oxidation (peroxide mEqO₂/Kg). p<0.05 was considered significant. **Results.** RSA (g/ml) of EO1 (558±22) was greater than EO2a (8±0.6), EO5 (413±26), EO6 (16±0.3) and EO7 (2±0.2), OsO (313±12), RO (32±12) and OIO (196±4), and less than EO3 (717±32; p<0.001). Antioxidant properties of OsO were more pronounced than RO (p<0.001). Primary oxidation (mEqO₂/Kg) of EO1 (97±0.6) was greater than EO2a (57±0.6), EO2b (28±0.2), EO5 (11±0.6), OsO (50±0.9) and OIO (61±0.9). **Conclusions.** Emu Oil conferred the greatest RSA compared to Ostrich and Rhea Oil, possibly attributed to its high UFA:SFA ratio and non-triglyceride fraction minor constituents. Rendering and storage variables impacted on Emu Oil RSA and primary oxidation.

Keywords: Ratite Oil, Emu Oil, primary oxidation, radical scavenging activity

Practical Application

The current research highlights the importance to standardise industrial rendering and storage procedures for Ratite Oils, to ensure consistent consumer health benefits.

Introduction

The pathology of a broad spectrum of chronic diseases and disorders, including coronary artery disease, gastrointestinal ulcers, inflammatory bowel disease, cancer and the side-effects of cancer therapy (mucositis), is characterised by damage to cellular components via reactive oxygen species (ROS)(Abimosleh and others 2012a; Lindsay and others 2010; Marnett 2000; Uchida 2000; Brzozowski and others 2001). Preventative therapies and treatments for these conditions are aimed at minimising oxidative damage by free radicals through the use of antioxidants(Aruoma 1998). Natural antioxidants are defined as compounds that function as free radical scavengers, reducing agents, chelators of pro-oxidant metals or as quenchers of singlet oxygen(Miraliakbari and Shahidi 2008). Antioxidants such as carotenoids, flavanoids, polyphenols, phytosterols and vitamin E, are widely found in beverages (red wine(Ghiselli and others 1998) and grape juices) and plant extracts (grape seed(Cheah and others 2009) and elderberry(Dubey and others 2012)), plant-based foods (fruits and vegetables, whole grains, nuts and seeds)(Hu 2003; Kalt and others 1999), plant-based oils (flaxseed, canola, tree nut(Miraliakbari and Shahidi 2008), olive(Owen and others 2000) and other vegetable oils) and marine-based oils (Fish Oil(Kris-Etherton and others 2003)). However, less attention has been directed towards the antioxidant potential of animal- and avian-derived oils.

Polyunsaturated fatty acids (PUFAs) found in many oils, such as Fish Oil and Olive Oil, react with oxygen and form peroxides during the initial step of oxidation, known as primary oxidation(Ottestad and others 2011). Primary oxidation determines a subsequent series of chain reactions (accelerated by high temperature and light and oxygen exposure) that generate the production of more stable secondary oxidation products including aldehydes and ketones(Choe and Min 2006; Ottestad and others 2011). Oxidative stability and deterioration of oils depend upon oil composition including concentration of

antioxidants, degree of processing and storage conditions. The unfavourable consequences of oxidation determine the rancidity of oils and degradation of functional and nutritional properties(Crapiste and others 1999). However, it remains unclear whether oil FA oxidation significantly affects radical-scavenging activity of antioxidants.

Ratites are flightless birds with a raft-like breastbone devoid of a keel and vestigial to non-existent breast muscles(Angel 1996). The principal members of the ratite family are the Australian Emu (*Dromaius novaehollandiae*), the African Ostrich (*Struthio camelus*), the three New Zealand Kiwi species (*Apteryx sp.*), the New Guinea Cassowary (*Casuarius sp.*), the Rhea or South American Ostrich (*Rhea americana*) and the South American Choique (*Pterocnemia pennata*). Certain ratites are farmed globally for commercialization of their meat, skin, feathers, eggs and more recently, their oil(Grompone and others 2005). Ratite Oil is derived from subcutaneous and retroperitoneal adipose tissue of the bird, by first rendering the macerated tissue and then passing the liquefied fat through a series of filters to extract a purified oil(Beckerbauer and others 2001). However, the composition of Rhea, Ostrich and Emu Oils is not identical(Grompone and others 2005; Bennett and others 2008).

Emu Oil was first used by Native Australian Aboriginals and early white settlers to facilitate wound healing, pain alleviation and treatment of inflamed joints(Whitehouse and others 1998; Snowden and Whitehouse 1997; Abimosleh and others 2012b). FAs represent the predominating component of Emu Oil, with a lipid content of 98.8% for subcutaneous adipose tissue, and 98.0% for retroperitoneal adipose tissue(Beckerbauer and others 2001). It has been suggested that the remaining 1-2% undefined non-triglyceride fraction comprises variable levels of compounds including carotenoids, flavones, polyphenols, tocopherols and phospholipids, which may confer therapeutic benefits including

antioxidant properties(Bennett and others 2008; Whitehouse and others 1998; Abimosleh and others 2012b). Other factors impacting on clinical efficacy of Emu Oil could include farm location, diet composition, rendering procedures, time of render and duration of storage.

We sought to investigate the influence of farm location, rendering method, duration and method of storage on radical scavenging activity and primary oxidation status of Ratite Oils.

Methods

Oil samples

Emu Oil samples (n=8) supplied by Emu Oil manufacturers from Australia and Canada were utilised. Emu Oil 1 (EO1), EO2 (EO2a and EO2b; differing in storage procedure [see below]) and EO3 were extracted from Emus farmed in North-Eastern South Australia. EO4 was extracted from a South-Eastern Emu farm in South Australia. EO1 and EO4 were rendered in 2009, whilst EO2 was rendered in 2011 and EO3 in 2010. EOs1-4 were rendered by an Emu Oil manufacturer in South Australia. EO5 was extracted from Emus farmed in Victoria, Australia and processed in 2011 by a Victorian manufacturer. EO6 and EO7 were extracted from Emus farmed in Duncan, British Columbia, Canada and both oils were rendered onsite in 2001. Ostrich Oil (OsO) and Rhea Oil (RO) adipose tissues were extracted in South Africa and Argentina, respectively, and were also rendered in Duncan, British Columbia, Canada in 2001. Olive Oil (OIO) was rendered in 2009 using olives grown in Spain.

Although general processing procedures varied amongst manufacturers, briefly, the process involved the rendering and filtration of Emu adipose tissue (for example, Emu Oil manufacturer of EOs 1-4 filtered at 0.2 μ m to remove bacteria including Salmonella and Listeria), with appropriate considerations for delivery of quality assurance and product consistency. Furthermore, storage of oil samples varied such that EOs1, 2a, 5 and 6 and OIO were individually stored at 4⁰C in 50ml opaque containers, EO2b was stored at -20⁰C for 6 months following render and left thawed for 2 months in a large 10L opaque bucket, and EOs 3 and 4, OsO and RO were stored in opaque containers (EOs 3 and 4: 100ml containers and OsO and RO: large 10L containers) at room temperature following render.

2,2-diphenyl-1-picryl hydracyl radical (DPPH) assay

The free radical scavenging activity (RSA) of oil samples against the 2,2-diphenyl-1-picryl hydracyl radical (DPPH) was determined by colorimetric absorbance. Principally, ionised DPPH produces a deep purple colour, which changes to pale yellow when the radicals are reduced by an antioxidant (hydrogen donor; Figure 1). Briefly, 5mL of each oil sample was weighed and dissolved in 25mL of toluene (Fisher Scientific, Ottawa, Canada) using a volumetric flask and allowed to mix for 24 hours. To obtain the required test concentrations, increasing volumes of the oil-toluene mixture were adjusted to 3.6mL with toluene. Finally, 0.4mL of a freshly prepared toluenic solution of 1mM DPPH (Sigma-Aldrich Canada Ltd, Oakville, Canada) was added to the oil-toluene mixture and vortexed for 20 seconds at room temperature. Absorbance of the test solutions at 517nm was measured after 15 mins using a spectrophotometer (Shimadzu, Kyoto, Japan). The RSA was calculated as the differences in absorbance of the DPPH radical solution with and without (control) sample:

$$\text{Percentage inhibition} = (\text{Absorbance}_{\text{control}} - \text{Absorbance}_{\text{sample}}) / \text{Absorbance}_{\text{control}} \times 100.$$

Overall, the RSA of the oil sample was expressed as reciprocal of the oil concentration that provided 50% inhibition using linear regression (1/IC50 g/ml). This analysis was repeated three times for each oil sample to obtain an average reading during month 1.

Oxidation analysis

Primary oxidation of oils, and hence rancidity, was assessed through determinations of peroxide values by colorimetric absorbance. Principally, R-O-O-R peroxides oxidize Fe²⁺ ions. The Fe³⁺ ions resulting from oxidation are grouped and form a red complex. Briefly, oil samples (volume depended upon dilution) were transferred into individual pre-filled cuvettes, vortexed and incubated in the spectrophotometer (cdr Foodlab Fat, Florence,

Italy), according to the manufacturer's instructions. Colorimetric intensity, measured at 505 nm, is directly proportional to the concentration of peroxides in the sample. Results were expressed as milli equivalents of oxygen per kilogram of oil sample (mEqO₂/Kg). Initially, four oil samples (EOs 1-4; 2.5µl of each sample) were analysed once during month 1, using the peroxide reference range of 1-50mEqO₂/Kg in a quality control study. During month 9, the peroxide levels of these four samples were determined once again. EOs 1, 3 and 4 were diluted to achieve an appropriate reference range of 4-275mEqO₂/Kg (100µl of each sample was pipetted into a cuvette pre-filled with diluent and 5µl of this mixture was then transferred to another pre-filled cuvette for analysis). EO5, OIO, OsO and EO2 top and bottom layers separated naturally at room temperature) were also diluted and analysed utilising a 4-275mEqO₂/Kg reference range according to the manufacturer's instructions (cdr Foodlab Fat, Florence, Italy). This analysis was repeated three times for each oil sample to obtain an average reading during month 9.

Statistical Analyses

Statistical comparisons were performed using SPSS version 16.0 for Windows software (SPSS Inc. Chicago, Illinois, USA). The IC₅₀ value for scavenging activity of the DPPH radical was expressed as the reciprocal of the mean ± standard error of the mean (SEM). Furthermore, peroxide values indicative of primary oxidation were expressed as mean ± SEM. Data from all analyses were analysed using a one-way ANOVA with a Tukey's *post hoc* test. For all analyses, p<0.05 was considered statistically significant.

Results

Free radical scavenging activity (RSA)

The reciprocal concentration of EO1 in the test solution that produced 50% neutralisation (1/IC50) of the DPPH radical was significantly greater than EOs 2a, 5, 6 and 7 ($p < 0.001$; Figure 2). Compared to EO3, the RSA of EO1 was significantly less ($p < 0.001$). Furthermore, the RSA value for EO7 was not significantly different to EO2a nor EO6 ($p > 0.01$). Moreover, the antioxidant properties of OsO were more pronounced than RO ($p < 0.001$). However, the RSA values of both ratite-derived oils OsO and RO and OIO were significantly less than EOs 1, 3, 4 and 5 ($p < 0.001$).

Primary oxidation

Primary oxidation, assessed through peroxide value determinations, was greatest in EOs 1, 3 and 4 (49.72mEqO₂/kg) compared to EO2a and OIO (4.5 and 31.35mEqO₂/kg, respectively), during month 1. The peroxide value of EO1, assessed during month 9, was significantly greater than EO2a, EO2b and EO5 ($p < 0.001$; Figure 3). However, primary oxidation was significantly less in EO1 compared to EO4 ($p < 0.001$). The peroxide value of EO2a was significantly greater than EO2b, and interestingly, upon separation, primary oxidation of the top layer of EO2a was significantly greater than the bottom layer ($p < 0.001$). Furthermore, the peroxide value of EO2a was significantly less than its top layer ($p < 0.001$) and significantly greater than its bottom layer ($p < 0.05$) upon separation. Amongst all EO samples, EO5 possessed the lowest peroxide value ($p < 0.001$). Compared to EO1, the primary oxidation values for OsO and OIO were significantly less pronounced ($p < 0.001$; Figure 3).

Correlation between primary oxidation and radical scavenging activity

Based upon EOs 1-4 and OIO, a highly significant correlation was evident ($R^2=0.9914$) relating peroxide value with radical scavenging capabilities for oil samples analysed during month 1 (Figure 4). The significantly correlating power trend-line indicated an ability for oils with increasing primary oxidation to act as antioxidants (Figure 4).

Discussion

Ratite Oil comparisons

Bennett and others (2008) have demonstrated that Emu Oil exhibits both antioxidant properties *in vitro* (radical scavenging activities) and a protective role against oxidative damage (assessed by measuring the ability to inhibit lipid peroxidation of erythrocytes) in a biological membrane model system. Furthermore, these investigators reported that Emu Oil afforded greater protection than Ostrich and Rhea Oils against oxidative damage *in vitro* (Bennett and others 2008).

In the current study, Emu Oil samples 1, 3, 4 and 5 possessed a greater ability to scavenge free radicals *in vitro* compared to oils derived from the Ostrich and Rhea. Furthermore, this antioxidant property was more pronounced in Emu Oil than Olive Oil. These differences in radical scavenging ability may have been attributed to the varying composition of oils sourced from these flightless birds (Table 1). It has been proposed that a high UFA:SFA ratio may confer protection against oxidative damage (Bennett and others 2008; Abimosleh and others 2012b). The high ratio of 2.0 in Emu Oil compared to lower ratios of 1.4 in Ostrich and Rhea Oils, may therefore have accounted for the greater antioxidant properties of Emu Oil detected in this setting. However, in the current study, although the UFA:SFA ratio of Olive Oil (6.2) was greater than for Emu Oil, it did not confer greater radical scavenging ability compared to Emu Oils 1, 3, 4 and 5. This implied that the antioxidant properties of Emu Oil may have resided in the 1-2% non-triglyceride fraction proposed to contain variable levels of antioxidant compounds including carotenoids, flavones, polyphenols, tocopherol and phospholipids (Whitehouse and others 1998; Abimosleh and others 2012b; Bennett and others 2008).

Time period since oil render

Oxidation of UFAs is the primary reaction responsible for the degradation of lipids. Indeed, the oxidation level of biologically-sourced oil is an important quality criterion for the food industry. Oxidation of oils not only produces rancid flavours but can also decrease nutritional quality and safety by the formation of oxidation products, which may play a role in the pathogenesis of atherosclerosis and even cancer (Staprans and others 1996; Kanazawa and others 2002). It is therefore imperative to determine the effect of oxidation and 'shelf-life' of oils on their ability to act as antioxidants.

In the current study, primary oxidation of Emu Oil was time-dependent, as indicated by the greater peroxide values of oils rendered at earlier stages. This was also evident with Ostrich Oil and Olive Oil, highlighting a non-specific oxidation process. Although the primary oxidation of Emu Oil 2a was not pronounced due to later rendering time, separation of the two oil layers at room temperature indicated significant levels of peroxide in the top layer, whilst peroxide levels in the bottom layer remained low. This suggests that the UFAs are concentrated in the top layer, based upon their high susceptibility to oxidation, whilst the more stable SFAs remain in the bottom layer. Furthermore, the peroxide value of EO2a was greater than its bottom layer upon separation, highlighting the greater stability of SFAs. This could be considered a useful determinant for oxidative stability and hence shelf-life extension. However, the radical scavenging properties and overall functional benefits of each layer remain unclear, warranting further investigation. Additionally, it is well documented that PUFAs such as omega-3 confer favourable health effects which range from reduced cardiovascular disease risk through to immunomodulatory effects in rheumatoid arthritis and even a role in brain development (Ruxton and others 2004). Therefore, it would be undesirable to eliminate these fatty acids from oil preparations.

Interestingly, a striking correlation was evident between radical scavenging activity and peroxide values which indicated an ability for oils with increasing primary oxidation to act as more effective antioxidants.

Emu Oil inter-batch variations and manufacturer comparisons

Ratite Oil composition can significantly differ depending upon diet, age of bird, farm location, methods and procedures used to render the fat into oil and the degree of processing and refining. Currently, there is no global standardized procedure to counteract these varying factors, which was reflected in the current study. Emu Oils 1-4 significantly varied in radical scavenging abilities and primary oxidation. However, considerations of rendering times minimised this variation, as evidenced by Emu Oils 1 and 4. Interestingly, there was a significant difference between Emu Oil derived from different manufacturers within the same year. Although extracted and processed within the same year, Emu Oil 5 possessed significantly greater radical scavenging ability than Emu Oil 2a; oils processed by differing manufacturing procedures. Furthermore, primary oxidation of Emu Oil 5 was significantly less pronounced than Emu Oil 2a. This highlights the importance of standardised extraction and processing procedures to optimize Emu Oil efficacy and ensure consistent therapeutic benefits for a range of medical conditions.

Storage procedure

Lipid oxidation is the cause of deteriorative modifications in edible oils as the chemical, sensory and nutritional properties are affected. Hence, lipid oxidation is often a decisive factor determining useful storage life (Martin-Polvillo and others 2004). However, rigorous scientific studies are limited to determine the optimal storage conditions for improvement of shelf-life. In the current study, various storage techniques were employed including freezing, refrigerating and duration at room temperature, small or large containers and a

combination of these factors. When comparing the same Emu Oil sample, there were notable differences in primary oxidation of samples stored refrigerated in small volumes (2a) compared to samples stored frozen and thawed in a large volume (2b). The freeze and thaw method proved most successful to minimise primary oxidation. Moreover, Crapiste *and others* (1999) described a dependent relationship between oil oxidation rate and oil surface area exposed to air; with sample volume contributing further to oxidation rate. Based upon these factors, auto-oxidation was significantly higher for a capped flask with 22.5g of sunflower oil than for an open flask with 45g of oil at the same temperature (47⁰C). In the current study, the dissolution and diffusion of oxygen and dilution of oxidation compounds in the bulk oil may have accounted for the differences in peroxide values observed for the two storage methods of Emu Oil 2. However, the significant correlation between increasing peroxide values and improved radical scavenging abilities (Figure 4) suggests a fine balance in the determination of oxidation status versus antioxidant activity.

Conclusions

In the current study, Emu Oil conferred the greatest radical scavenging ability compared to Ostrich and Rhea Oil, possibly attributed to its higher UFA:SFA ratio and minor constituents in the non-triglyceride fraction. Other factors influencing Emu Oil radical scavenging activity and primary oxidation include farm location, rendering time, rendering methods and storage techniques. Method of storage was a critical factor for primary oxidation, whereby freeze-thaw technique and storage in larger volumes proved to be most effective. Furthermore, the rendering protocol was identified as an important factor in radical scavenging abilities and oil stability. It is recommended that future studies should carefully consider oxidation and radical scavenging activity of oil samples prior to *in vitro* and *in vivo* studies in order to standardise bioactivity. Moreover, the minor non-FA

constituents of Emu Oil possessing antioxidant properties should be identified and quantified. Such further studies would facilitate standardisation of Emu Oil bioactivity to ensure consistent health benefits.

Acknowledgements

The authors would like to thank the Avian Research Centre, Faculty of Land and Food Systems, University of British Columbia for hosting Suzanne Mashtoub Abimosleh (S.M.A) in undertaking the oil radical scavenging assay. Dr Kimberley Cheng contributed to the experimental design and Deepa Menon provided technical advice. S.M.A. conducted all experiments and data analyses and prepared the final manuscript. D.C.B. provided placement supervision and contributed to the experimental design and data analyses. C.D.T. assisted with analysis of data. G.S.H. contributed to the experimental design, analysis of data and manuscript preparation. G.S.H. is supported by the Sally Birch Cancer Council Australia Research Fellowship in Cancer Control. This project was funded in part by Rural Industries Research and Development Corporation Australia. S.M.A. was further supported by The 2011 Freemasons Trevor Prescott Memorial Travel Scholarship. No other conflicts of interest or financial agreements are in place.

References

- Abimosleh SM, Lindsay RJ, Butler RN, Cummins AG, Howarth GS. 2012a. Emu oil increases colonic crypt depth in a rat model of ulcerative colitis. *Dig Dis Sci* 57(4):887-96.
- Abimosleh SM, Tran CD, Howarth GS. 2012b. Emu Oil: a novel therapeutic for disorders of the gastrointestinal tract? *J Gastroen Hepatol* 27(5):857-61.
- Angel R. 1996. A review of ratite nutrition. *Anim Feed Sci Tech* 60:241-6.
- Aruoma OI. 1998. Free radicals, oxidative stress, and antioxidants in human health and disease. *J Am Oil Chem Soc* 75(2):199-212.
- Beckerbauer LM, Thiel-Cooper R, Ahn DU, Sell JL, Parrish FC, Jr., Beitz DC. 2001. Influence of two dietary fats on the composition of emu oil and meat. *Poultry Sci* 80(2):187-94.
- Bennett DC, Code WE, Godin DV, Cheng KM. 2008. Comparison of the antioxidant properties of emu oil with other avian oils. *Aust J Exp Agr* 48:1345-50.
- Brzozowski T, Kwiecien S, Konturek PC, Konturek SJ, Mitis-Musiol M, Duda A, Bielanski W, Hahn EG. 2001. Comparison of nitric oxide-releasing NSAID and vitamin C with classic NSAID in healing of chronic gastric ulcers; involvement of reactive oxygen species. *Med Sci Monitor* 7(4):592-9.
- Cheah KY, Howarth GS, Yazbeck R, Wright TH, Whitford EJ, Payne C, Butler RN, Bastian SEP. 2009. Grape seed extract protects IEC-6 cells from chemotherapy-induced cytotoxicity and improves parameters of small intestinal mucositis in rats with experimentally-induced mucositis. *Cancer Biol Ther* 8(4):382-90.
- Choe E, Min DB. 2006. Mechanisms and factors for edible oil oxidation. *Compr Rev Food Sci F* 5(4):169-86.
- Crapiste GH, Bredan MIV, Carelli AA. 1999. Oxidation of sunflower oil during storage. *J Am Oil Chem Soc* 76(12):1437-43.

- Dubey P, Jayasooriya AP, Cheema SK. 2012. Fish oil induced hyperlipidemia and oxidative stress in BioF1B hamsters is attenuated by elderberry extract. *Appl Physiol Nutr Me* 37(3):472-9.
- Ghiselli A, Nardini M, Baldi A, Scaccini C. 1998. Antioxidant activity of different phenolic fractions separated from an Italian red wine. *J Agr Food Chem* 46(2):361-7.
- Grompone MA, Irigaray B, Gil M. 2005. Composition and thermal properties of Rhea oil and its fractions. *Eur J Lipid Sci Tech* 107(10):762-6.
- Hu FB. 2003. Plant-based foods and prevention of cardiovascular disease: an overview. *Am J Clin Nutr* 78(3 Suppl):544S-51S.
- Kalt W, Forney CF, Martin A, Prior RL. 1999. Antioxidant capacity, vitamin C, phenolics, and anthocyanins after fresh storage of small fruits. *J Agr Food Chem* 47(11):4638-44.
- Kanazawa A, Sawa T, Akaike T, Maeda H. 2002. Dietary lipid peroxidation products and DNA damage in colon carcinogenesis. *Eur J Lipid Sci Tech* 104(7):439-47.
- Kris-Etherton PM, Harris WS, Appel LJ. 2003. Fish consumption, fish oil, omega-3 fatty acids, and cardiovascular disease. *Arterioscl Throm Vas* 23(2):e20-30.
- Lindsay RJ, Geier MS, Yazbeck R, Butler RN, Howarth GS. 2010. Orally administered emu oil decreases acute inflammation and alters selected small intestinal parameters in a rat model of mucositis. *Br J Nutr* 104(4):513-9.
- Marnett LJ. 2000. Oxyradicals and DNA damage. *Carcinogenesis* 21(3):361-70.
- Martin-Polvillo M, Marquez-Ruiz G, Dobarganes MC. 2004. Oxidative stability of sunflower oils differing in unsaturation degree during long-term storage at room temperature. *J Am Oil Chem Soc* 81(6):577-83.
- Miraliakbari H, Shahidi F. 2008. Antioxidant activity of minor components of tree nut oils. *Food Chem* 111(2):421-7.

- Ottestad I, Vogt G, Retterstol K, Myhrstad MC, Haugen JE, Nilsson A, Ravn-Haren G, Nordvi B, Bronner KW, Andersen LF, Holven KB, Ulven SM. 2011. Oxidised fish oil does not influence established markers of oxidative stress in healthy human subjects: a randomised controlled trial. *Br J Nutr*:1-12.
- Owen RW, Giacosa A, Hull WE, Haubner R, Wurtele G, Spiegelhalder B, Bartsch H. 2000. Olive-oil consumption and health: the possible role of antioxidants. *Lancet Oncol* 1:107-12.
- Ruxton CH, Reed SC, Simpson MJ, Millington KJ. 2004. The health benefits of omega-3 polyunsaturated fatty acids: a review of the evidence. *J Hum Nutr Diet* 17(5):449-59.
- Snowden JM, Whitehouse MW. 1997. Anti-inflammatory activity of emu oils in rats. *Inflammopharmacology* 5(2):127-32.
- Staprans I, Rapp JH, Pan XM, Hardman DA, Feingold KR. 1996. Oxidized lipids in the diet accelerate the development of fatty streaks in cholesterol-fed rabbits. *Arterioscl Throm Vas* 16(4):533-8.
- Uchida K. 2000. Role of reactive aldehyde in cardiovascular diseases. *Free Radical Bio Med* 28(12):1685-96.
- Whitehouse MW, Turner AG, Davis CK, Roberts MS. 1998. Emu oil(s): A source of non-toxic transdermal anti-inflammatory agents in aboriginal medicine. *Inflammopharmacology* 6(1):1-8.

Table 1. Major fatty acid composition of Emu, Ostrich, Rhea and Olive Oils including unsaturated fatty acid (UFA): saturated fatty acid (SFA) ratios. The Emu Oil and Olive Oil presented in this table were used in the current study (EO1 and OIO respectively). Ostrich Oil and Rhea Oil values were obtained from Grompone *and others*, 2005. Monounsaturated fatty acids (MUFA); polyunsaturated fatty acids (PUFA).

Major FA Composition of Emu, Ostrich, Rhea and Olive Oils					
Fatty Acid	Common Name	Emu	Ostrich	Rhea	Olive
16:0	Palmitic acid	24	34.9	34.4	10.4
16:1n-7	Palmitoleic acid	4.3	7.4	4.5	0.7
18:0	Stearic acid	8.5	5.7	5.4	3.1
18:1n-9	Oleic acid	49.1	30.5	30.6	73.9
18:2n-6	Linoleic acid	9.5	16	21	8.4
18:3n-3	α -Linolenic acid	1.1	2.1	1.9	0.7
Saturated		32.5	40.6	41.1	13.5
MUFA		53.4	37.9	35.1	74.6
PUFA		10.6	18.1	22.9	9.1
UFA:SFA ratio		2	1.4	1.4	6.2




Figure 1. The reduction of the 2,2-diphenyl-1-picrylhydracyl stable radical (DPPH[•]) by an antioxidant (AH). In its radical form, DPPH[•] absorbs at 517nm and produces a deep violet colour, however, absorption diminishes (decolourises) upon reduction by an antioxidant (hydrogen donor).

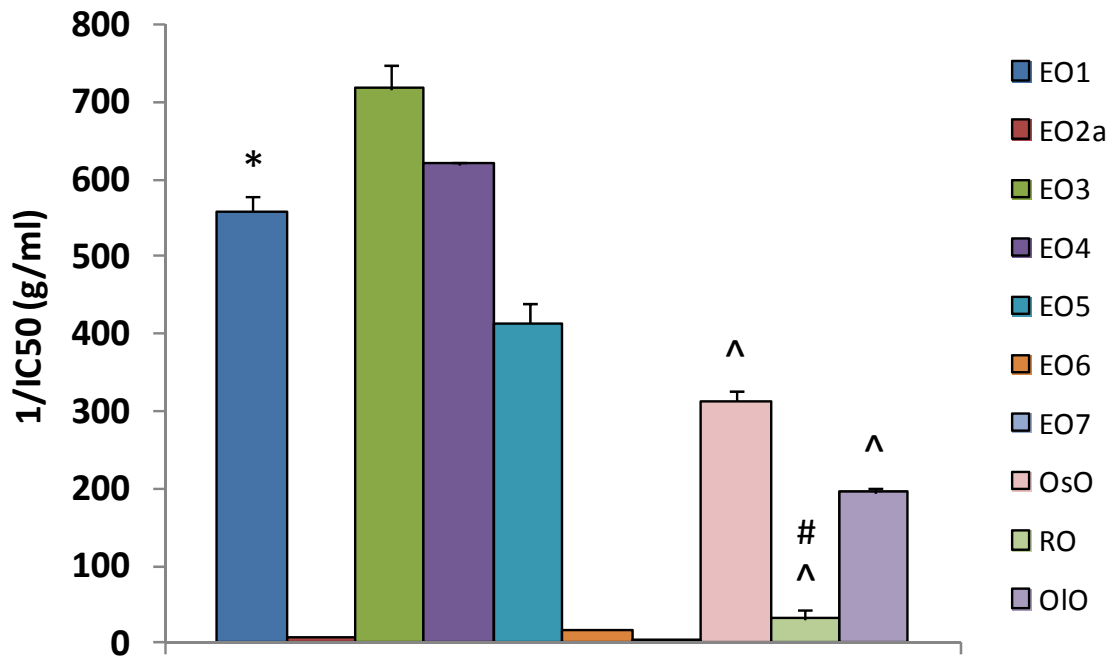


Figure 2. Reciprocal concentrations of oils producing 50% inhibition (1/IC₅₀; g/ml) for scavenging activity of the DPPH radical (n=3 replicates), assessed during month 1 [Emu Oil (EO); Ostrich Oil (OsO); Rhea Oil (RO); Olive Oil (OIO)]. Data are expressed as mean (1/IC₅₀ g/ml) ± SEM. * indicates p<0.001 compared to all test samples except EO4; # indicates p<0.001 compared to OsO; ^ indicates p<0.001 compared to EOs 1, 3, 4 and 5.

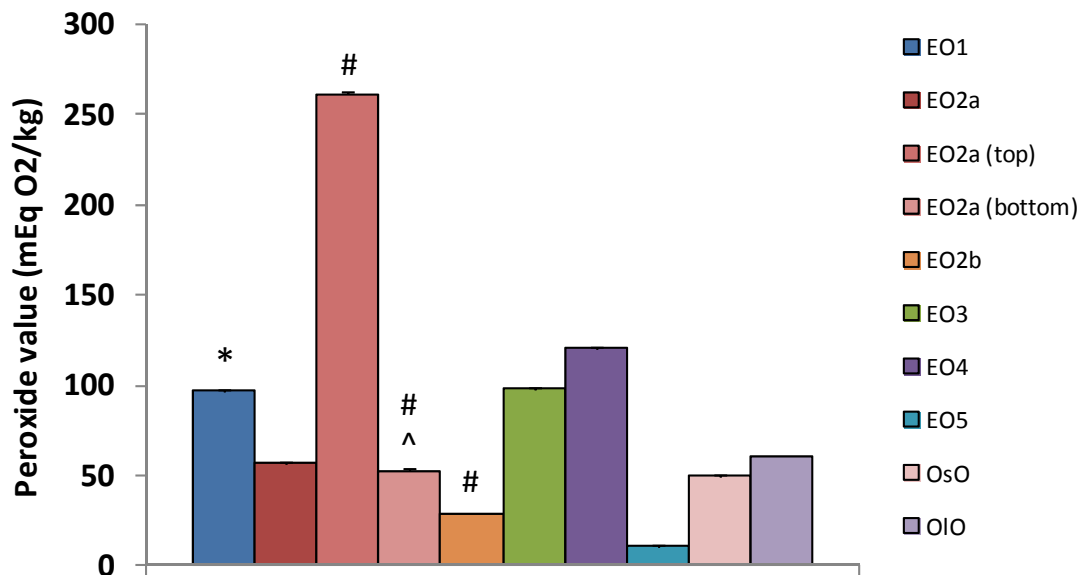


Figure 3. Peroxide values of oil samples indicative of primary oxidation (n=3 replicates), assessed during month 9 [Emu Oil (EO); Ostrich Oil (OsO); Olive Oil (OIO)]. Data are expressed as mean (Peroxide value mEqO₂/kg) ± SEM. * indicates p<0.001 compared to all test samples except EO3; # indicates p<0.05 compared to EO2a; ^ indicates p<0.001 compared to EO2a (top).

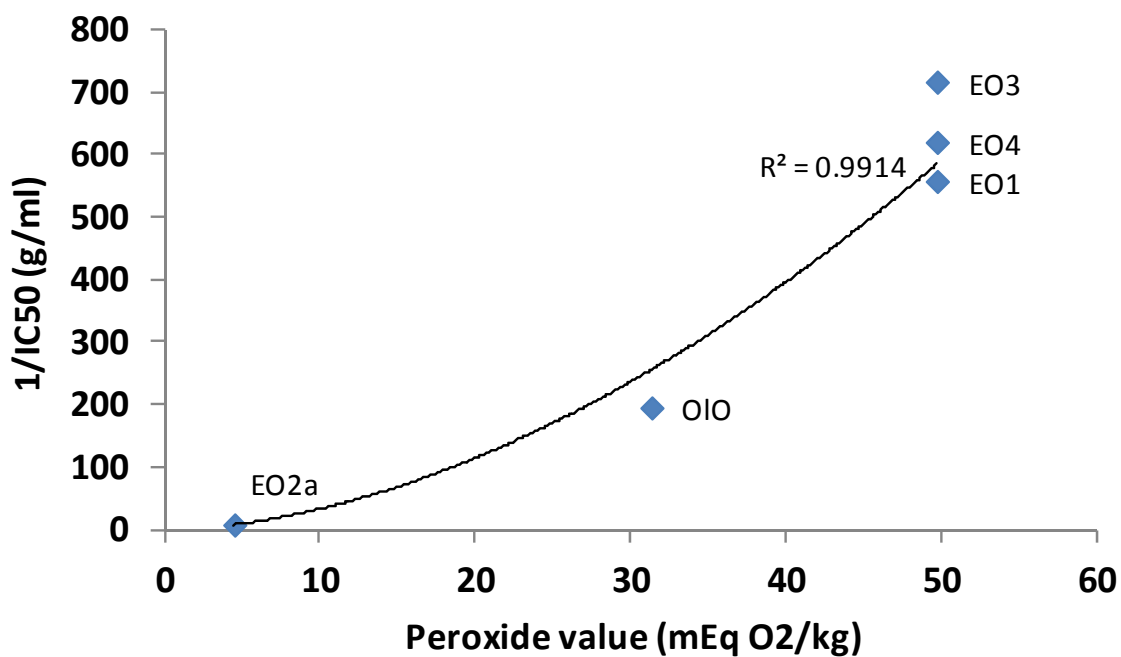


Figure 4. Correlation between oil peroxide value (mEqO₂/kg) and its radical scavenging capability (1/IC₅₀ g/ml) during month 1 [Emu Oil (EO); Olive Oil (OIO)]. R²=0.9914 for power trendline.

CHAPTER 6

CONCLUSIONS AND FUTURE DIRECTIONS

CONCLUSIONS AND FUTURE DIRECTIONS

In support of Emu Oil as a potential orally-administered nutraceutical, Emu Oil reduced colonic damage associated with dextran sulphate sodium-induced colitis in rats and accelerated the repair process (**Chapter 2**). Improvements were indicated histologically by reduced intestinal damage severity scores and enhanced compensatory crypt elongation in the colon. Furthermore, distal colonic crypts were elongated by Emu Oil in normal rats, which could have represented a modulation of the proliferation and apoptosis balance. Therefore, proliferation and apoptosis would be important parameters to define in this setting to determine the mechanism of Emu Oil action. In future studies, assessment of cell proliferation in paraffin-embedded tissue sections could be determined by 5-bromodeoxyuridine (BrdU) immunohistochemistry. BrdU, injected intraperitoneally, is a thymidine analogue incorporated into the DNA of proliferating cells during the S phase of the cell cycle and is detected via an anti-BrdU antibody. Additionally, immunostaining of proliferative cell nuclear antigen, expressed in the nuclei of cells during the DNA synthesis phase of the cell cycle (late G1- and S-phase), could be assessed as an indicator of crypt cell proliferative state. Furthermore, TUNEL assay and immunohistochemistry for caspase-3, gatekeeper in the caspase cascade, could be undertaken to establish the degree of epithelial cell apoptosis. Moreover, a high Bax/Bcl-2 ratio of tissue mRNA expression has been correlated with enhanced apoptosis. Techniques to define this ratio could therefore be considered for future mechanistic determinations of Emu Oil action.

Continual stimulation of mucosal thickening by Emu Oil beyond the experimental days assessed in the current study could potentially, yet improbably, be a safety concern. For example, proliferation and apoptosis imbalance could lead to neoplasia. Further investigations are warranted to assess mucosal thickening beyond the experimental period

of the current study. Future studies could determine whether Emu Oil elicits any changes in cellular pathways associated with colonic neoplasia such as P13-K signalling pathway. Nevertheless, although untested, continual crypt lengthening would appear unlikely based upon the decreased histological damage severity observed in the colon, indicating that rats administered Emu Oil suffered a lesser degree of tissue damage. Rat models of azoxymethane-induced colon cancer or mammary adenocarcinoma in spontaneous tumor-bearing Dark Agouti rats would be appropriate to assess the impact of Emu Oil on tumor growth, coincident with the enhancement of small intestinal (SI) repair following chemotherapy.

Animal models have contributed greatly to the understanding of colitis pathogenesis, revealing that intestinal inflammation occurs only in the presence of the microbiota, as animals raised under germ free conditions do not develop colitis. Restoring microbial homeostasis by targeting colitis-associated bacteria such as *Bacteriodes* spp, has been implicated as a novel therapeutic strategy for colitis. We identified microbiota changes associated with colitis in rats in **Appendix 2**. The effect of Emu Oil in this context is yet to be defined. In future studies, terminal restriction fragment length polymorphism analysis would be useful to quantify fecal bacterial communities from colitic rats treated with Emu Oil. This would define whether the anti-inflammatory properties of Emu Oil were related to its direct effect on the inflammatory response, or indirectly through restoration of the gut microbiota.

Clinical manifestations of 5-Fluorouracil (5-FU)-induced mucositis included decreased body weight and food intake and elevated disease activity index together with reduced SI functional health status (**Chapter 3**). These parameters and reduced thymus weight were not improved following Emu Oil treatment. However, in the 5-FU-damaged SI, Emu Oil

maintained villus height and crypt depth during maximal damage followed by an enhanced compensatory elongation, suggesting an acceleration of the repair process. Similar to **Chapter 2**, Emu Oil administration to normal rats resulted in SI mucosal thickening. Further studies are warranted to determine the kinetic mechanism of Emu Oil action in regards to enterocyte apoptosis and proliferation. SI and colonic changes in mucosal thickness described in **Chapters 2 and 3** suggested that Emu Oil maintains its bioactivity throughout the gastrointestinal tract. Future studies could employ radio-labelled Emu Oil constituents to determine the rate of degradation with passage through the gastrointestinal tract. Moreover, intestinal permeability changes following Emu Oil treatment could be quantified in future studies utilizing tests such as serum citrulline levels or urinary lactulose, rhamnose and mannose excretion.

Emu Oil decreased MPO activity, indicative of acute inflammation, in the jejunum and ileum of 5-FU-injected rats (**Chapter 3**). These findings further support the bioavailability of Emu Oil throughout the SI, evidenced by measurable anti-inflammatory effects in the distal SI. In future studies, increased Emu Oil dose or frequency of administration could further decrease the extent of small bowel inflammation in mucositis, potentially achieving clinical benefit.

The mechanism by which Emu Oil exerts its anti-inflammatory effects remains unclear. Potential mechanisms could be attributed to the omega-3 and -9 FAs present in Emu Oil or constituents in the non-triglyceride fraction including carotenoids, flavones, tocopherols and skin-permeation enhancing factors, which may confer additional anti-inflammatory and antioxidant effects. Further studies of Emu Oil could benefit from a complete time-course of cytokine profiling, including TNF- α , IFN- γ , IL-1 β , IL-6 and IL-10, in serum and tissue samples, to identify potential effects on pro-inflammatory cytokine antagonism or

agonism of anti-inflammatory cytokines in the current inflammatory intestinal disorders. More specifically, upon fractionation of Emu Oil, individual constituents could be examined to determine effects on cyclooxygenase 1 or 2 pathways and pro-inflammatory cytokine levels *in vitro*, thereby facilitating the development of more potent Emu Oil preparations.

Indomethacin-induced enteropathy resulted in increased liver, spleen, duodenum, SI, caecum and colon weights (**Chapter 4**). Emu Oil treatment did not improve these parameters. Together with **Chapters 2 and 3**, this highlighted the overall absence of systemic improvements by Emu Oil. MPO activity in the jejunum and ileum of Indomethacin-treated rats was decreased following Emu Oil administration. **Chapter 3 and 4** reaffirm the anti-inflammatory properties of Emu Oil, confirming its therapeutic application in intestinal disorders characterised by inflammation.

In all of the *in vivo* experimental studies conducted within this thesis, Emu Oil did not significantly impact daily metabolic parameters which included body weight, water intake, faecal output and urine output in normal rats. However, food intake was decreased, presumably the result of lipid-rich constituents of Emu Oil. Consequently, overall caloric intake was maintained, as evidenced by the absence of changes in body weight compared to normal rats (**Chapter 3**). ¹³C-sucrose breath test results confirmed the maintenance of SI functional health by Emu Oil and contributed to the data supporting its safety for oral administration. High oil viscosity could have resulted in adherence of Emu Oil to the luminal epithelial surface, contributing to the increased SI weight described in **Chapters 2 and 3**. Furthermore, concomitant increases in SI, villus and crypt lengthening could have contributed to SI weight increases in experimentally-induced mucositis (**Chapter 3**).

However, Emu Oil did not significantly affect other visceral organ weights highlighting its safety for oral administration.

Based on the current findings, further studies could focus on the potential for Emu Oil to combat other intestinal conditions characterised by inflammation. For example, as Emu Oil is gluten-free, it could represent an adjunctive treatment-strategy for celiac disease, especially in refractory disease. Moreover, anti-inflammatory effects of Emu Oil should be investigated in other bowel conditions characterised by low-grade inflammation such as irritable bowel syndrome and infective gastroenteritis. Furthermore, it would be useful to quantify the coincident benefits of Emu Oil in arthritis and the associated co-morbidity of NSAID-induced enteropathy.

Radical scavenging activity and primary oxidation of Emu Oil were influenced by farm location, rendering time, rendering methods and storage techniques (**Chapter 5**). Method of storage was determined to be a critical factor for primary oxidation, whereby freeze-thaw technique and storage in larger volumes proved to be most effective. Future studies should investigate the influence of oxidation and radical scavenging activity of oil samples using intestinal epithelial cell lines (IEC-6) and organ culture systems. Furthermore, clinical efficacy of different Emu Oil preparations should be explored using the currently employed rat models of intestinal damage. Such studies would facilitate standardisation of Emu Oil bioactivity to ensure consistent health benefits.

Emu Oil conferred greater radical scavenging ability than Ostrich and Rhea Oil, likely attributed to its higher unsaturated fatty acid (FA): saturated FA ratio together, with minor constituents in the non-triglyceride fraction (**Chapter 5**). Comparisons of these constituents between Ratite Oils would assist in identifying the antioxidant properties of

Emu Oil. This could be achieved utilising the solid phase extraction technique for fractionation of antioxidant compounds in the oils.

In conclusion, Emu Oil could represent a safe, renewable and economical means to augment pharmaceutical options for a range of intestinal conditions, not necessarily restricted to colitis, NSAID-enteropathy or mucositis.

APPENDICES

APPENDIX 1

**GRAPE SEED EXTRACT REDUCES THE SEVERITY OF
SELECTED DISEASE MARKERS IN THE PROXIMAL COLON OF
DEXTRAN SULPHATE SODIUM-INDUCED COLITIS IN RATS**

STATEMENT OF AUTHORSHIP

Grape Seed Extract Reduces the Severity of Selected Disease Markers in the Proximal Colon of Dextran Sulphate Sodium-Induced Colitis in Rats

Digestive Diseases and Sciences 2012; Nov 10: DOI 10.1007/s10620-012-2464-1

Ker Y. Cheah

Analysed data, interpreted results, prepared manuscript.

I hereby certify that the statement of contribution is accurate.

Signed

Date 28/11/2012

Susan E.P. Bastian

Contributed to experimental conceptualisation and design, data interpretation and manuscript preparation.

I hereby certify that the statement of contribution is accurate.

Signed

Date 27.11.12

Thomas M.V. Acott

Conducted animal trials and experimental work, analysed data, interpreted results.

I hereby certify that the statement of contribution is accurate.

Signed

Date 26/11/12

Suzanne Mashtoub ABIMOSLEH (Candidate)

Conducted animal trials, experimental work and data analyses.

I hereby certify that the statement of contribution is accurate.

Signed

Date 3/12/12

Kerry A. Lymn

Conducted animal trials.

I hereby certify that the statement of contribution is accurate.

Signed

Date 30/11/2012.

Gordon S. Howarth

Contributed to experimental conceptualisation and design, data interpretation, critical manuscript evaluation.

I hereby certify that the statement of contribution is accurate.

Signed

Date 3/12/12

Cheah, K.Y., Bastian, S.E.P., Acott, T.M.V., Abimosleh, S.M., Lymn, K.A. & Howarth, G.S. (2012)
Grape seed extract reduces the severity of selected disease markers in the proximal colon of dextran sulphate sodium-induced colitis in rats.
Digestive Diseases and Sciences, v. 58(4), pp. 970-977

NOTE:

This publication is included on pages 160-167 in the print copy
of the thesis held in the University of Adelaide Library.

It is also available online to authorised users at:

<http://doi.org/10.1007/s10620-012-2464-1>

APPENDIX 2

**MICROBIAL FINGERPRINTING DETECTS UNIQUE BACTERIAL
COMMUNITIES IN THE FAECAL MICROBIOTA OF RATS WITH
EXPERIMENTALLY-INDUCED COLITIS**

STATEMENT OF AUTHORSHIP

Microbial Fingerprinting Detects Unique Bacterial Communities in the Faecal Microbiota of Rats with Experimentally-Induced Colitis

The Journal of Microbiology 2012; 50 (2): 218-25

Ashis K. Samanta

Conducted experimental work, analysed data, interpreted results.

I hereby certify that the statement of contribution is accurate.

Signed

Date 23.11.12

Valeria A. Torok

Contributed to experimental conceptualisation and design, experimental work, data analyses and interpretation of results, manuscript preparation.

I hereby certify that the statement of contribution is accurate.

Signed

Date 23/11/2012

Nigel J. Percy

Assisted with data analyses and interpretation of results.

I hereby certify that the statement of contribution is accurate.

Signed

Date 23/11/2012

Suzanne Mashtoub ABIMOSLEH (Candidate)

Conducted animal trials, contributed to experimental work, data analyses and interpretation of results, prepared manuscript.

I hereby certify that the statement of contribution is accurate.

Signed

Date 3/12/12

Gordon S. Howarth

Contributed to experimental conceptualisation and design, data interpretation, manuscript preparation.

I hereby certify that the statement of contribution is accurate.

Signed

Date 27/11/12

Samanta, A.K., Torok, V.A., Percy, N.J., Abimosleh, S.M. & Howarth, G.S. (2012) Microbial fingerprinting detects unique bacterial communities in the faecal microbiota of rats with experimentally-induced colitis.

The Journal of Microbiology, v. 50(2), pp. 218-225

NOTE:

This publication is included on pages 171-178 in the print copy of the thesis held in the University of Adelaide Library.

It is also available online to authorised users at:

<http://doi.org/10.1007/s12275-012-1362-8>

APPENDIX 3

CURRENT AND NOVEL TREATMENTS FOR ULCERATIVE COLITIS

STATEMENT OF AUTHORSHIP

Current and Novel Treatments for Ulcerative Colitis

Ulcerative Colitis from Genetics to Complications 2012; ISBN 978-953-307-853-3, InTech

Cuong D. Tran

Conducted a thorough review of the literature, prepared manuscript.

I hereby certify that the statement of contribution is accurate.

Signed

Date

27/11/12

Rosa Katsikeros

Conducted a thorough review of the literature, prepared manuscript.

I hereby certify that the statement of contribution is accurate.

Signed

Date 27-11-12 .

Suzanne Mashtoub ABIMOSLEH (Candidate)

Conducted a thorough review of the literature, prepared manuscript.

I hereby certify that the statement of contribution is accurate.

Signed

Date 3/12/12

Current and Novel Treatments for Ulcerative Colitis

Cuong D. Tran, Rosa Katsikeros and Suzanne M. Abimosleh
*Gastroenterology Unit, Women's and Children's Health Network, North Adelaide
Discipline of Physiology, School of Medical Sciences, University of Adelaide
Australia*

1. Introduction

Ulcerative colitis and Crohn's disease are defined by a common term of inflammatory bowel disease. These chronic diseases result in significant morbidity and mortality. While there are no cures for these diseases, the last two decades have been a period of major advancement in our understanding of the biology of intestinal inflammation. This can be attributed to a steadily increasing number of experimental animal models with some clinical manifestation similar to those observed in human inflammatory bowel disease. These experimental animal models have also contributed greatly to our current understanding of the immunological, pathological and physiological features of chronic intestinal inflammation. However, specific causes of ulcerative colitis and Crohn's disease remain unknown. Conventional treatments for the disease include corticosteroids and immunosuppressives, however treatments in many patients are not entirely effective with many therapies associated with significant adverse effects. Thus, treatments that are effective and have little or no side effects remain an unmet need. There are numerous emerging therapeutic strategies which may be useful in the alleviation of chronic intestinal inflammation and this chapter will focus on novel therapies that may be effective for ulcerative colitis in the future.

2. Etiology of ulcerative colitis

While the precise etiology of inflammatory bowel disease is unknown, genetic susceptibility, environmental factors, impaired barrier function, imbalances or disruption to the commensal host microflora and an abnormal intestinal immune response are thought to play an important role in its manifestation.

2.1 The immune response

It is clear that not one single component of inflammatory bowel disease pathogenesis can trigger and maintain the disease. Understanding mucosal immunity in Crohn's disease and ulcerative colitis is fundamental in unraveling the complex mechanisms of chronic gut inflammation which can then provide some insight into the treatment of inflammatory bowel disease. The immune response is divided into two components, innate immunity and adaptive immunity.

2.2 Innate immunity

In the normal intestine, macrophages are conditioned by the mucosal microenvironment to express a non-inflammatory phenotype which is translated by a down-regulated expression of innate immunity receptors and constrained production of pro-inflammatory cytokines (1). In contrast, in inflammatory bowel disease-affected intestinal tissue, macrophages newly recruited from the peripheral blood still express monocyte CD14 markers but are primed for the production of various pro-inflammatory cytokines such as interleukin (IL)1 α , IL1 β , and tumour necrosis factor (TNF) α (2-3). It has been reported that in Crohn's disease these CD14⁺ pro-inflammatory macrophages are increased and subsequently result in more IL23 and TNF α production compared to controls and ulcerative colitis and contribute to the production of interferon (IFN) γ by T cells (4).

Intestinal dendritic cells (DC) are antigen-presenting cells involved in the initiation and regulation of local innate immune response but also play a role in adaptive immunity (5). Similar to macrophages, their function is dependent on the mucosal microenvironment and function to provide protection and defense, induce tolerance or mediate inflammation (6). It has been shown that in inflammatory bowel disease, intestinal DC is activated, increasing the expression of microbial receptors and production of pro-inflammatory cytokines like IL12 and IL6 (7).

2.3 Adaptive immunity

B cell immunity

There is limited focus given to B cell immunity in inflammatory bowel disease even though in active inflammatory bowel disease there is antibody production and secretion of immunoglobulin (Ig)M, IgG and IgA, by both peripheral blood and mucosal mononuclear cells (8). The patterns of antibody class production differ in ulcerative colitis and Crohn's disease; in ulcerative colitis there is a disproportional increase in IgG1 secretion, whereas in Crohn's disease IgG1, IgG2 and IgG3 are increased compared to control cells (9).

T cell immunity

There has been a considerable increase in our understanding of adaptive immunity since the identification of CD4⁺ T helper 1 (Th1) and T helper 2 (Th2) subsets in mice (10) and humans (11). The T cell immunity field is still evolving and in addition to IFN γ -producing Th1 cells and IL4, IL5 and IL13-producing Th2 cells, new Th subsets have been identified including IL17 producing Th17 cells (12) and dual IFN γ - and IL17-producing Th17 cells (13). More recently, two new subsets of CD4⁺ effector Th cells have been described, Th9 and Th22, however, their function are not clearly understood (14). Furthermore, Cosmi et al. (15) reported that Th cells can produce both IL17 and IL4 which is a dual Th17 and Th2-mediated immune response.

In addition to Th cells, another major subset is made up of T regulatory (Treg) cells whose function is to monitor the immune response and prevent an excessive and potentially harmful immune response (16-17). It has been speculated that Th17 and Treg cells share common pathways, suggesting developmental and functional links between Treg and Th17 cells (18-19). Regulatory T cells are accepted to be key players in the maintenance of tolerance and prevention of autoimmunity (20). Of particular interest are the CD4⁺ CD25^{bright} Foxp3⁺ Regulatory T cell (Treg), where mutations of the transcription factor Foxp3, crucial in the development and function of Tregs, manifest in multiple autoimmune

diseases in both mice and humans (21). In both cases a severe early onset of inflammatory bowel disease is observed as part of the pathology. A deficiency of number and/or function of Tregs are also seen in other autoimmune diseases including multiple sclerosis and systemic lupus, and the transfer of Tregs has been shown to treat experimental murine colitis and type 1 diabetes.

The Th17 effector cell is a relatively new effector cell lineage distinct from the Th1/Th2 dichotomy, and is driven by the transcription factor retinoic acid-related orphan receptor- γ t, (ROR γ t). Th17 cells secrete predominately IL17 and potentially provide critical protection against fungi and extra cellular bacteria which are not covered by Th1/Th2 immunity (22). There is good evidence that Crohn's disease has a dominant Th1 component as shown by an elevated production of IFN γ and IL12 by lamina propria mononuclear cells (23-24). As well there is an increased production of IL-17 by Th17 cells and dual IFN γ - and IL17-producing mucosal Th cells (13, 25). In contrast, ulcerative colitis is considered an atypical Th2 response based on studies demonstrating increased IL5 and IL13 production of Th cells and also IL13 by natural killer (NK) T cells in the inflamed mucosa (26). The increased production of IL13 has been shown to induce cytotoxicity and apoptosis and impair mucosal barrier function (27), which may be a contributor to the overall pathogenesis of ulcerative colitis.

3. Characteristics of ulcerative colitis

The remainder of the chapter will focus on animal models of ulcerative colitis and novel therapeutic approaches in treating this condition. The clinical symptoms of ulcerative colitis consist of severe abdominal pain and increased frequency of bloody diarrhoea. Unlike Crohn's disease, ulcerative colitis is characterized by inflammation contained to the large intestine, which affects only the mucosal layer and is superficial in comparison to the inflammation seen in Crohn's disease. Inflammation commonly extends proximally from the rectum, and extensive superficial ulceration is typical (28). Inflammation is accompanied by ulceration, edema, and hemorrhage along the length of the colon. Complications of ulcerative colitis differ from Crohn's disease, with increased risk of perforation, toxic megacolon and a higher incidence of bowel cancer. Histopathological features include the presence of neutrophil infiltrates which form crypt abscesses (29).

4. Animal models of experimental ulcerative colitis

Even with a wealth of information on the etiology of ulcerative colitis there is still no cure. As a consequence numerous animal models of ulcerative colitis have been established to elucidate the potential mechanism of ulcerative colitis and to develop therapeutic strategies within the preclinical phase.

5. Chemical-induced colitis

5.1 Dextran Sulphate Sodium(DSS)-induced colitis

Features of DSS-induced colitis

The DSS model of experimental colitis (30) is one of the most popular and widely utilized and characterized animal models of ulcerative colitis. DSS is a synthetic sulphated polysaccharide composed of dextran and sulphated anhydroglucose unit (31).

Supplementing the drinking water of rodents with low molecular weight DSS (54,000 mol. wt.) results in histopathological and symptomatic features resembling ulcerative colitis (31-32). Histologically, DSS-induced colitis resembles the damage manifested in human ulcerative colitis patients with an inflammatory response consistent with human inflammatory bowel disease (33). DSS administration also produces visual signs of disease activity including rectal bleeding, weight loss and diarrhea (32), all common features of ulcerative colitis.

The DSS-induced ulcerative colitis model has been well characterized morphologically and biochemically (34-35). After a four-day treatment with 3% DSS in the drinking water, mice show signs of acute colitis including weight loss, bloody stools, and diarrhoea (34). Histologically, DSS produces submucosal erosions, ulceration, inflammatory cell infiltration and crypt abscesses as well as epithelioglandular hyperplasia (35). The luminal bacteria in the colon induce the production of the inflammatory cytokines, IL6 and TNF α , which cause colitis. The damage induced by DSS has been reported to affect the distal colon and caecum preferentially, with lesser damage evident in the proximal colon (32). This model is particularly useful to study the contribution of the innate immune mechanism towards colitis as well as for the study of epithelial repair mechanisms.

Mechanism of action

The mouse model of colitis induced by DSS histologically resembles human ulcerative colitis, and although the exact mechanism of DSS-induced mucosal injury is not fully understood, a topical toxic effect of DSS on the colonic epithelial cells has been proposed (36). This results in loss of barrier function which would likely result in an increased uptake of luminal antigens (bacteria and bacterial products) as well as activation of lamina propria immune cells and the inflammatory response (37). It has been reported that DSS-induced colitis alters the tight junction complex resulting in the loss of barrier function thereby facilitating the development of the inflammatory infiltrate and development of intestinal inflammation (38).

Chronic model of DSS-induced colitis

DSS is commonly administered in a dose range of 3-10% for 7-10 days to induce an acute inflammation depending on the susceptibility of the species or the molecular weight of DSS (39). The DSS-induced acute colitis model may be extrapolated to a chronic colitis model by simply prolonging the administration of DSS. It has been suggested that to induce chronicity, DSS is normally administered in three to five cycles with a 1- to 2-week rest between cycles (40-41). This is useful in understanding disease progression as well as pathological inflammatory changes observed in ulcerative colitis. Interestingly, in inbred rats administered 5% DSS for 215 days, intestinal tumors (adenomas, adenocarcinomas as well as papillomas) were seen (42) predominantly in the colon and caecum.

5.2.2, 4, 6-Trinitrobenzene sulfonic acid (TNBS)-induced colitis

Features of TNBS-induced colitis

Another model that has been used widely is the well characterized haptene reagent TNBS-induced colitis. This model of chronic colitis also resembles human ulcerative colitis in its various histological features including infiltration of colonic mucosa by neutrophils and macrophages. There is also increased production of inflammatory mediators including Th1 profile of cytokines (IFN γ , TNF α and IL12) resulting in substantial inflammation and tissue

injury (43). Studies (44-45) have indicated that the TNBS-induced colitis model is useful for testing therapeutic strategies for humans. More specifically, when TNBS is introduced into the colon of susceptible mice it induces a T cell-mediated immune response within the colonic mucosa, leading to dense infiltration of T cells and macrophages throughout the entire wall of the large bowel (46). In addition, this histopathologic characteristic is accompanied by clinical features of progressive weight loss, bloody diarrhoea, rectal prolapse and large bowel wall thickening (47). The TNBS-induced colitis model has been very useful in studying many important aspects of gut inflammation, including cytokine secretion patterns, mechanisms of oral tolerance, cell adhesion and immunotherapy.

Induction of TNBS colitis

In 2001, Scheiffele and Fuss (48) described the induction of TNBS colitis in mice. Colitis is induced by the administration of TNBS through a trocar needle using a rubber catheter inserted via the anus (49). Scheiffele and Fuss (48) recommended using 0.5 to 4.0 mg TNBS in 45% to 50% ethanol intra-rectally. Inherent in this model and other similar models is the need for ethanol at high concentrations as a vehicle for intra-colonic administration of the hapten. It seems that ethanol is a prerequisite since it acts as a barrier breaker, and allows TNBS to enter the mucosa to induce colitis (50). Ethanol by itself causes severe inflammation in the intestinal mucosa therefore it is difficult to distinguish between the ethanol-induced inflammation and hapten-induced inflammation (51). There are no standard practices for this model subsequently a critical appraisal of the various studies using TNBS colitis and a recommendation for future use of this model has been extensively reviewed by te Velde et al. (52). Intra-rectal administration of TNBS results in ulceration and thickening of the bowel wall which may persist for at least 8 weeks (53). Furthermore, granulomas and Langhans-type giant cells were also observed at the site of ulceration and inflammation. The inflammation was characterized by high myeloperoxidase and decreased glutathione levels (53).

Mechanism of action

TNBS dissolved in ethanol is required to break the mucosal barrier. TNBS can bind covalently to the E-amino group of lysine and modify cell surface proteins. Colitis may develop when pre-sensitized T lymphocytes lyse hapten-modified autologous cells (54-55). T-lymphocytes will lyse hapten-modified autologous cells only if the animal has been pre-sensitized, whereas macrophages will destroy TNBS-modified autologous cells in the absence of pre-sensitization (56). In addition, TNBS may be metabolized to yield O_2^- and H_2O_2 from the interaction between ascorbate and TNBS (57) indicating that TNBS-induced colitis may partly be mediated by cytotoxic reactive oxygen species generated by the oxidative metabolism of TNBS.

A variety of inflammatory mediators may be involved in TNBS-induced colitis. The predominant arachidonate metabolites found in TNBS colitis are leukotriene B₄ (LTB₄) and the monhydroxyl fatty acids 5-HETE, 12-HETE and 15-HETE (58). The synthesis of LTB₄ increased within 4 h and peaked 24-72 h after the administration of TNBS and this increase is correlated with colonic myeloperoxidase activity (59). Furthermore, it has been shown that a significant level of luminal eicosanoids such as prostaglandin E₂ (PGE₂), 6-keto PGF₁ α , TXB₂ and LTB₄ were increased 3 days after intracolonic instillation of TNBS (59) suggesting that eicosanoids play an important role in the pathogenesis of TNBS-induced colitis. Another potential mechanism of TNBS-induced colitis may be the increased level of platelet-activating factor (PAF). High PAF production was not seen during the time of

maximal neutrophil infiltration (1-4 days after TNBS) but was seen 1-3 weeks after the induction of colitis (60). This finding suggests that PAF is unlikely to play an important role in the acute inflammatory response but may be important in the prolongation of the inflammation in this model.

Types of TNBS-induced colitis models

The TNBS-induced colitis model may be used in 3 different scenarios, (i) in acute TNBS-induced colitis in which the primary phase of the induction of Th1 response, a nonspecific inflammatory response, is analyzed (ii) established TNBS-induced colitis in which the local delayed-type hypersensitivity response is mimicked and a specific response can be analyzed and (iii) chronic TNBS-induced colitis in which repeated local induction of DTH response will lead to fibrotic lesions and a Crohn's disease-like cytokine profile (52). These forms are not well described and documented in current practices therefore it is essential to predefine the objective for using this type of experimental colitis to better understand the pathophysiology of the chosen type of colitis.

5.3 Dinitrobenzene sulfonic acid (DNBS) model of colitis

Features of DNBS-induced colitis

DNBS is another hapten which can be used to induce colonic inflammation. DNBS is less hazardous than TNBS and can be used safely in a well-ventilated room with personnel wearing protective gloves, clothing and goggles. The DNBS model produces acute and chronic inflammation and ulceration in the colon similar to TNBS (61). The feature of colitis in this model is similar to that of the TNBS model with bloody diarrhea and significant loss of body weight evident. Four days after DNBS administration, colon damage was characterized by areas of mucosal necrosis and neutrophil infiltration and the colon appeared flaccid and filled with liquid stool. The macroscopic inspection of caecum, colon and rectum showed presence of mucosal congestion, erosion, and hemorrhagic ulcerations (62). The histopathological features included a transmural necrosis and oedema and diffuse leukocyte cellular infiltrate in the submucosa.

In comparison, rats treated with DNBS have no granulomas whereas about half of the TNBS rats have granulomas (53). In the rat, DNBS causes an overproduction of nitric oxide (NO) due to induction of inducible nitric oxide synthase (iNOS), which contributes to the inflammatory process (63-64). As in the TNBS model, DNBS induces a strong inflammatory response and a significant increase in myeloperoxidase (MPO) activity compared to controls (60). Since TNBS is no longer available in the United States, DNBS can be an alternative compound for inducing experimental models of ulcerative colitis.

Induction of TNBS colitis

Colitis was induced by using a technique of acid-induced colon inflammation as described by Morris et al., (53). In fasted rats lightly anaesthetized with isoflurane, a 3.5 F catheter was inserted into the colon via the anus until the splenicflexure was reached (approximately 8 cm from the anus). 2,4-dinitrobenzenesulphonic acid (DNBS; 25 mg/rat), dissolved in 50% ethanol (total volume, 0.8 ml) was administered as an enema. While other investigator have modified the method that was first described (53), where colitis was induced in lightly anesthetized mice by an intra-rectal injection of 3 mg of DNBS in 100 µl of 50% ethanol, delivered 3 cm into the colon via a polyethylene catheter (65).

Mechanism of action

DNBS and TNBS both bind to proteins, but TNBS has an additional active nitro group and binds more readily at lower concentrations. However, DNBS is more selective and binds only to the ϵ -amino group of lysine (61).

5.4 Oxazolone-induced colitis

Features of oxazolone-induced colitis

A number of experimental models of colitis have been proposed. However, there are limited colitis models that have a Th2 profile. The oxazolone-induced colitis model is Th2-mediated and has important implications for investigating the pathogenesis and treatment of ulcerative colitis (66-67). The administration of low intrarectal doses of an inducing agent (oxazolone) in ethanol to BALB/c mice every 7 days for 10 weeks showed that in the first 3 weeks of this treatment, the mice lost about 10-15% of their starting weight and exhibited ruffled coats, hunched posture, and restricted movement. During this period 10-15% of animals died. Over the next 3 weeks the surviving mice regained weight and no longer exhibited obvious signs of chronic illness. Repetitive administration of intra-rectal ethanol alone led to a weight loss of up to 5% in the early phase of the disease (68).

Induction of oxazolone colitis

The oxazolone-induced colitis model is established by painting the skin with 0.2 ml 3% oxazolone in 100% ethanol on days 0 and 1 followed by intrarectal administration of 0.15 ml 1% oxazolone in 50% ethanol on day 7 (66). However, another study (51) used carmellose sodium/peanut oil as a non-irritating vehicle in place of ethanol and found that the oxazolone-induced colitis model was still a reproducible animal model of human colonic inflammation. The oxazolone challenge resulted in rapid development of inflammation characterized by diarrhoea, mild ulcerations, hyperemia, infiltration of inflammatory cells, epithelial damage and submucosal edema.

More recently, oxazolone-induced colitis has been established as a chronic model via repeated intrarectal administration of oxazolone in ethanol. This allows the model to be used to define specific features of the inflammatory milieu that favors tumor development (69). Chronic oxazolone-induced colitis begins as severe inflammation with corresponding weight loss, which transforms into chronic inflammation and partial weight recovery. The inflammation is marked by the rapid increase in the production of IL13 in the lamina propria and the appearance of NK T cells, which are both immunologic features of acute oxazolone-induced colitis (69). The authors also concluded that the chronic oxazolone-induced colitis model supports epithelial tumour development induced by administration of a carcinogenic agent, azoxymethane.

Mechanism of action

Similar to the TNBS-induced colitis model, oxazolone, a hapten, induces delayed-type hypersensitivity and contact hypersensitivity reactions to subsequently induce inflammation. Oxazolone-induced colitis has been suggested to be dependent on the presence of IL13 producing invariant NK T cells (70). Thus the oxazolone-induced colitis model is one of the few models suitable for the study of the Th2 dependent immune response in intestinal inflammation.

5.5 Carrageenin-induced colitis

Carrageenan is a high molecular weight sulfated polygalactan, derived from several species of red seaweeds (*Rhodophyceae*) including *Gigartina*, *Chondrus*, and *Euचेuma* (71). The most common forms of carrageenan are lambda (λ), kappa (κ), and iota (ι) (71). Carrageenans are used by the food industry to improve the texture of food products by thickening, stabilizing, or emulsifying dairy products, salad dressings, infant formulas, processed meat, soy milk, and other food products (72-73). Its use has increased markedly during the last half century, and is known to induce inflammation in rheumatological models and in intestinal models of colitis (71).

Features of carrageenan-induced colitis

Early work in animal models has demonstrated that carrageenan may cause gastrointestinal pathology, including ulcerations and tumours of the gastrointestinal tract (71-72). In guinea pigs deprived of ascorbic acid, the oral administration of degraded *E. spinosum* carrageenan induced mild to moderate colitis, while *E. cottonii* carrageenan consistently induced severe colitis. The severe colitis induced by *E. cottonii* in scorbutic animals markedly affected the mid and distal colon and showed histological changes similar to human ulcerative colitis (74). Delivery of 10% carrageen (degraded carrageenan) for 10 days in the drinking water of CF1 mice induced bloody diarrhoea and pericryptal inflammation, and produced marked dilatation of the cecum and ascending colon (75). Histologically, the mucosa was characterized by distorted crypt architecture, inflammatory infiltration of the lamina propria, and ulceration, conditions which were more pronounced in the proximal colon but were also present in the distal colon.

Induction of carrageenan colitis

Carrageenan causes a reproducible inflammatory reaction and remains a standard chemical for examining acute inflammation and effects of anti-inflammatory drugs. With or without sensitizing the animals with carrageenan, colitis is induced by supplementing the drinking water of 2-10% degraded carrageenan (74-75).

Mechanism of action

Carrageenan has been widely used to induce inflammation in experimental models of colitis in animal models (72-73), that resemble human ulcerative colitis. NF κ B is a key determinant of the intestinal epithelial inflammatory cascade and occupies a central role in the transcriptional activation of pro-inflammatory genes (76). Furthermore, Borthakur et al. (71) suggested that activation of NF κ B in the intestinal cells following carrageenan exposure is largely attributable to an increase in Bcl10. Bcl10 resides in the cytoplasm which relays receptor mediated signals to activate NF κ B (77).

6. Genetic-induced colitis

More recently, various experimental animal model of colitis, especially transgenic mice models with spontaneous colitis (78-79) have been reported and demonstrated that T cells are necessary for involvement and initiation of intestinal inflammation. New genetically engineered animals with spontaneous colitis, such as IL2 and IL10 knockout mice models, are promising tools for further understanding of the etiology of intestinal inflammation.

6.1 IL2 knockout mice

When reared and maintained under conventional specific pathogen-free conditions, IL2 deficient (IL2^{-/-}) mice spontaneously develop disorders of the hemopoietic and immune system characterized by anemia, lymphocytic hyperplasia, progressive loss of B cells, and disturbances in bone marrow hemopoietic cells. Animals that survive more than 8-9 weeks of age also develop a chronic, non-granulomatous inflammation of the colonic and caecal submucosa and mucosa. (80).

Features of IL2 deficiency-induced colitis

The histopathology of colitis observed in IL2^{-/-} mice seems to vary depending on the method of induction and the location of animal housing. The original paper (80) described the features of spontaneously developing colitis in IL2^{-/-} mice which included ulceration, crypt abscesses, destruction of the mucosal layer with epithelial dysplasia, but also mononuclear cell infiltration of the mucosa and submucosa. However, the histopathology of immunization-induced colitis and spontaneously-developing colitis in mice reared at the NIH animal facility, seem to resemble human Crohn's disease (transmural inflammation, lymphoid hyperplasia) (81). These findings suggest that the histopathological characteristics in these animals may not only be dependent on genetic but also on environmental factors.

Mechanism of action

IL2^{-/-} mice reared and maintained under gnotobiotic conditions do not develop intestinal lesions (82). Furthermore, colitis that develops in IL2^{-/-} mice under conventional conditions suggests a direct result of an abnormal immune response in the colonic mucosa to intestinal bacterial flora. It is not known specifically how the absence of IL2 accounts for colitis in IL2^{-/-} mice and the role this cytokine plays in homeostatic regulation of mucosal immunity. However, Baumgart et al. (83) suggests that IL2 is required for the generation and the function of a regulatory population of mucosal T cells or is directly involved in preventing the development of inflammatory responses to enteric antigens.

6.2 IL10 knockout mice

Only a small number of spontaneous models of chronic colitis have been employed by researchers to yield detailed information on the penetrance, severity and reproducibility of the gut inflammation (84). The most widely used of the gene-targeted models of spontaneous colitis is the IL10 deficient (IL10^{-/-}) mouse model. The IL10^{-/-} model is a well established Th1-mediated model of transmural colitis (85). IL10^{-/-} mice were generated by disrupting the IL10 gene in embryonic stem cells and although the mice were considered to have normal lymphocyte development and antibody response, growth retardation and anemia were observed (86).

Features of IL-10 deficiency-induced colitis

Mice with targeted disruption of the IL10 gene develop spontaneous pancolitis and caecal inflammation by 2-4 months of age (85). Histopathological examination of the colons obtained from mice with active disease show many of the same characteristics as those observed in human inflammatory bowel disease. The initial changes in intestinal inflammation consisted of small, focal infiltrates of inflammatory cells in the lamina propria with minimal or no epithelial hyperplasia (85, 87). Inflammatory infiltrates consisted of a mixture of lymphocytes, plasma cells, and macrophages with smaller numbers of

neutrophils and eosinophils. IL10^{-/-} mice also develop ulcers and crypt abscesses, exhibit epithelial hyperplasia, mucin production is reduced, an increased numbers of mitotic figures were observed and increased expression of major histocompatibility complex class II molecule were also observed in the intestinal epithelial cells (85-87). As mice become older, inflammation involved the submucosa or less frequently became transmural (87).

Mechanism of action

It has been demonstrated that there is a lower number of caecal bacteria observed before colitis (7 weeks of age) in IL10^{-/-} compared to C57Bl/6J mice. This suggests differences in intestinal bacteria that might be associated with the genotype which could contribute to the development of colitis in this mouse model (88).

6.3 CD45RB^{Hi} T cell transfer model of colitis

CD4⁺ T cells can be separated on the basis of their CD45RB expression into populations expressing high (CD4⁺ CD45RB^{Hi}) or low (CD4⁺ CD45RB^{Lo}) levels of this antigen (89). CD4⁺ CD45RB^{Hi} T cells isolated via fluorescence activated cell sorting from spleens of donor mice transferred to immuno-deficient SCID or RAG1/2^{-/-} recipient mice cause a wasting syndrome with transmural intestinal inflammation primarily in the colon starting 5-10 weeks after cell transfer (90-91).

Features of CD45RB^{Hi} T cell transfer model of colitis

Initial lesions consisted of minimal multifocal or diffuse inflammatory cell infiltrates in the lamina propria. In mice with more severe colitis, changes were diffuse and sometimes transmural (90). Inflammatory infiltrates consisted of macrophages and lymphocytes, accompanied by smaller numbers of neutrophils and eosinophils (90-91). Occasional multinucleated giant cells and ulcers were observed, whereas crypt abscesses were sparse (90-91). Epithelial changes included hyperplasia with lengthening and branching of glands, mucin depletion, increased numbers of mitotic figures, and enhanced levels of major histocompatibility complex class II molecule expression on intestinal epithelial cells (90).

Mechanism of action

Recipient mice repopulated with the CD⁺CD45RB^{Lo} T cell subset or both populations (CD⁺CD45RB^{Hi} and CD⁺CD45RB^{Lo} T cell subsets) do not develop colitis. CD25⁺FoxP3⁺ cells within the CD⁺CD45RB^{Lo} population account for the prevention of colitis since depletion of CD25⁺ cells from CD45RB^{Lo} cells abrogates their colitis prevention potential (92). Treg cells which produce IL-10 due to co-culture with IL-10, prevent the onset of gut inflammation and antigen-specific immune responses when transferred together with pathogenic CD4⁺CD45RB^{Hi} T cells. Furthermore, SCID mice administered both CD45RB^{Hi} T cells and Treg cells together with anti-IL10 receptor antibodies develop colitis (93). These results suggest that the progeny of CD45RB^{Hi} T cells mount a pathogenic Th1-like response in the colon of these immuno-deficient mice.

6.4 Which colitis model to use?

As increasingly more sophisticated experimental colitis models are being described and characterized, researchers have the potential to exploit the unique potential of each model to ask specific questions. No single experimental model of colitis recapitulates all of the pathogenic and clinical features of human ulcerative colitis, however each animal model has

contributed to our understanding of the mechanisms underlying initiation and perpetuation of chronic intestinal inflammation.

7. Current treatments for ulcerative colitis

At present, conventional therapies or pharmaceutical treatments have remained the mainstay of treatment for most patients suffering from ulcerative colitis. However, these treatments are variably effective with significant adverse effects and approximately 25 to 40% of patients will eventually require colectomy (94). The aim of these treatments is to induce and maintain the patient in remission. First line therapy for mild to moderate ulcerative colitis comprise of anti-inflammatory drugs containing 5-aminosalicylic acid (5-ASA), such as oral and rectal mesalamine. Sulfasalazine, the archetype for this class of medications, is cleaved upon reaching the colon releasing mesalamine. Second generation 5-ASA medications include olsalazine and balsalazide (95). Approximately 60 and 80% of patients are adequately treated with these medications and the remainder who exhibit severe ulcerative colitis are treated with a combination of corticosteroids (prednisolone). Immunosuppressives or immunomodulators such as azathioprine and mercaptopurine that treat severe inflammatory bowel disease and/or administered to patients who have inadequate response to corticosteroids can be beneficial but there is little information about their effectiveness in treating ulcerative colitis and are also associated with risks of infection and malignancy (96). Up to 20% of inflammatory bowel disease sufferers discontinue immunosuppressant therapy because of side effects (97). Biologic drugs that interfere with the inflammatory response such as the anti-TNF α agent infliximab can be effective in inducing remission for ulcerative colitis patients that are refractory to initial treatments.

It has been demonstrated that colonic bacteria may initiate inflammation of inflammatory bowel disease (97-98) and a combination therapy with antibiotics has been shown to offer significant benefit in ulcerative colitis (99-100). Most clinicians use antibiotics as an adjuvant therapy for severe ulcerative colitis despite relatively few trials conducted on their use. Although recent advances have been made in understanding the etiology and pathophysiological mechanisms underlying the pathogenesis of ulcerative colitis, the problem still remains for patients refractory to conventional treatments or not responding and being able to maintain remission effectively with maintenance treatments (101).

Currently, there is no cure for ulcerative colitis and there is increasing evidence that alternative therapies (102-103) may provide some insights into developing a potential successful treatment. The remainder of this chapter will focus on the potential therapeutic interventions which target various aspects of the etiology of ulcerative colitis including the use of pre- and probiotics to manipulate the gut microflora and molecules that mediate the action of inflammatory cells (104). Biological therapies for ulcerative colitis will not be covered in this chapter as this area is reviewed by Rutgeerts et al. (105).

8. Novel therapies for ulcerative colitis

8.1 n-3 fatty acids

Over the years, dietary n-3 fatty acids have gained a reputation in preventing and treating several disorders including cardiovascular diseases, rheumatoid arthritis and Alzheimer's disease by way of anti-inflammatory, antithrombotic, antiarrhythmic, hypolipidemic and vasodilatory activities (101, 106-111). It has been shown in human and animal studies that

these n-3 fatty acids have potent immunomodulatory and anti-inflammatory effects by inhibiting the production of inflammatory mediators, eicosanoids, PGE2 and LTB4 and cytokines, TNF α and IL1 β (112). It stands to reason that supplemental n-3 fatty acids might therefore be beneficial in treating or preventing relapse in chronic inflammatory diseases such as ulcerative colitis (113).

Animal studies

There have been numerous studies utilising experimentally induced colitis animal models to define the role of dietary n-3 fatty acids in disease prevention and progression. In a severe combined immunodeficient (SCID) mouse model of colitis, Whiting et al. (114) found that dietary n-3 fatty acids reduced clinical colitis and colonic immunopathology by decreasing the synthesis of proinflammatory cytokines, reducing myeloid cell recruitment and activation, and enhancing epithelial barrier function and mucosal wound healing mechanisms. Li et al. (115) demonstrated within the TNBS rat colitis model that rats pretreated with n-3 fatty acids showed significant attenuation of colonic injury and protection. Compromised epithelial barrier in ulcerative colitis by chronic immune cell activation might be explained by the altered expression and distribution of tight junction proteins in tight junction membrane microdomains of the intestinal mucosa, and n-3 fatty acids have been shown to positively affect this altered expression and distribution (115). Many studies have shown adiponectin, a protein hormone produced and secreted primarily by adipocytes and more recently by colonic myofibroblasts to play a beneficial role in ulcerative colitis due to its anti-inflammatory effect (116-118). Interestingly, Matsunaga et al. (119) who found a decrease in adiponectin expression in DSS-induced colitic mice also found a further decrease in adiponectin expression in colitic mice fed with n-3 fatty acids, which could have contributed to the observed exacerbated colitis for this group. This is in contrast to the beneficial effects other studies have shown regarding dietary n-3 fatty acids and colitis.

Human studies

Fish oil is the best source of n-3 fatty acids. Although numerous studies have focused on oral supplementation in patients with inflammatory bowel disease which ultimately results in the incorporation of n-3 fatty acids into the gut mucosal tissue thereby modifying inflammatory mediators (120-121), the evidence of clinical benefits remains unclear due to conflicting results. A systematic review of the effects of fish oil in human ulcerative colitis by MacLean et al. (113) found significant improvements in clinical scores in three studies at one or more time points relative to the comparative study arm. Studies that were restricted to patients with ulcerative colitis (122-123) reported a statistical improvement in the endoscopic score with fish oil relative to comparative treatment. Together with studies that observed induction of remission (122, 124), prevention of relapse (124-128) and the requirement for immunosuppressive agents (122, 124, 129). MacLean et al. (113) deduced that there were insufficient data to draw any conclusions. However, the observed efficacy of fish oil delivered by enteric coated capsule on reducing steroid requirements did warrant more attention (113).

Another systematic review and meta-analyses by Turner et al. (101) looked at the efficacy and safety of n-3 fatty acid or fish oil therapy in maintaining remission in inflammatory bowel disease. Of the nine studies eligible for inclusion, only three involved ulcerative colitis. There was no difference in the relapse rate between the n-3 fatty acid therapy (fish

oil) and control groups. Pooled analysis showed an increase in diarrhea and symptoms of the upper gastrointestinal tract in the n-3 fatty acid group (fish oil) suggesting troublesome side effects. In short, there was insufficient data to recommend the use of n-3 fatty acids for the maintenance of remission of ulcerative colitis. Given the biologic rationale and the benefit of n-3 fatty acid therapy derived from tissue samples and animal models, it is difficult to explain the lack of clinical benefit in inflammatory bowel disease, although it has been suggested that the dosing regimen may be inadequate or the formulation not optimal (101). Enterically coated n-3 fatty acid that has a timed release of 60 minutes upon ingestion was found to be more beneficial with the lowest adverse events compared with other timed release points and triglyceride compounds (130). In conclusion, further studies are warranted to address appropriate dosing and delivery systems of fish oil for the treatment of ulcerative colitis.

8.2 Plant derived therapies

Other novel therapies that possess anti-oxidant, anti-inflammatory and immunomodulatory properties have been investigated in experimentally-induced animal colitis models and to some extent in human trials for the treatment of ulcerative colitis. Persistent ulcerative colitis is associated with a 10-fold increased risk of colorectal cancer (131) and therefore limiting chronic colonic inflammation will appear to reduce this risk.

Resveratrol

Resveratrol is a natural polyphenol found in fruits and vegetables and abundantly in grapes and red wine. Sanchez-Fidalgo et al. (132) investigated the protective/preventive effects of dietary resveratrol in the DSS-induced colitis mouse model. There were significant attenuations of clinical signs of colitis such as loss of body weight, diarrhea and rectal bleeding. All mice fed the resveratrol diet survived and finished the treatment while mice fed the standard diet showed a 40% mortality rate. Resveratrol caused significant reductions in TNF α and IL1 β and an increase in IL10, an anti-inflammatory cytokine. Expression of prostaglandin E synthase-1 (PGES-1), cyclooxygenase (COX-2) and iNOS, proteins involved in the inflammatory response, were also reduced. Cui et al. (133) investigated the protective/preventive effects as well as the chemopreventive properties of dietary resveratrol in the chronic DSS-induced colitis mouse model. Resveratrol was shown to ameliorate colitis in a dose dependant manner and reduce the tumour incidence by 60%. The number of tumours per animal was also reduced. Resveratrol is tolerated at high doses and a diet rich in this polyphenol could represent a novel approach to treating ulcerative colitis and preventing colon cancer associated with ulcerative colitis.

Andrographis paniculata

Andrographis paniculata, a member of the plant family Acanthaceae, is used extensively in Asian countries, Sweden and Chile for the treatment of various inflammatory and infectious diseases. HMPL-004, an aqueous ethanol herbal extract of Andrographis paniculata has been shown to inhibit TNF α and IL1 β and prevent colitis in animal models. A pilot human clinical trial conducted by Tang et al. (134) investigated the efficacy and safety of HMPL-004 in patients with mild to moderate ulcerative colitis. In comparison to a parallel group treated with the standard first line therapy, mesalazine, there were no significant differences observed for clinical remission and disease activity. 13% of patients treated with HMPL-004 and 27% treated with mesalazine had at least one adverse event although the majority of

events were not strongly linked to the study medications. In conclusion, HMPL-004 could be an efficacious alternative to mesalazine for the treatment of ulcerative colitis.

Black raspberries

As well as exhibiting ability to limit the inflammatory response in cell culture (135-137), black raspberries (BRB) have the highest concentration of antioxidant polyphenols compared to other dark berries (138-139). These antioxidants (anthocyanins and ellagic acid) have been shown to scavenge free radicals, increase expression of detoxification enzymes and increase the capacity of the cell to absorb radicals (140-143). A study conducted by Montrose et al. (144), the first to utilise a DSS-induced mouse model of ulcerative colitis to explore the effects of freeze-dried BRB on disease severity, demonstrated the high anti-inflammatory potency of BRB. Dietary BRB markedly reduced colonic injury to the epithelium and tissue levels of TNF α and IL1 β were suppressed. Biomarkers of oxidative stress remained unaffected by BRB treatment, however the findings still demonstrated potent anti-inflammatory properties which support a possible therapeutic role for the treatment of ulcerative colitis.

American ginseng

American ginseng (AG), a natural herb, has been shown to improve mental performance and end points associated with conditions such as cardiovascular disease, cancer and diabetes (145-147). In a study by Jin et al. (148), AG extract was mixed in with the chow of DSS-induced colitic mice and given before and after the onset of colitis. Results showed prevention and treatment of colitis with AG along with the downregulation of iNOS and COX-2 and p53 (induced by inflammatory stress). In part, leukocyte activation in colitis causes mucosal and DNA damage which was shown to be inhibited by AG *in vitro* and *in vivo*. A dysfunctional intestinal immune system is a major mechanism by which chronic inflammation occurs in ulcerative colitis and defects in apoptosis of mucosal inflammatory cells is critical in the pathogenesis of ulcerative colitis. Another study conducted by Jin et al. (149), showed that AG extract can drive apoptosis of inflammatory cells through the p53 mechanism *in vitro* which is consistent with dietary AG protecting against DSS-induced colitis in the mouse model.

Ginkgo biloba

Ginkgo biloba extract (EGB) is derived from the green leaves of the Ginkgo biloba tree and has been used extensively in conditions associated with inflammatory mediators such as acute pancreatitis, central neural system disorders, heart and intestine injury/reperfusion injury (150-152). Zhou et al. (153) investigated the mechanism by which EGB ameliorates inflammation in TNBS-induced colitic rats and its effects on the production of inflammatory mediators. Four weeks of EGB therapy provided protection in ulcerative colitis possibly by radical scavenging and down regulating some of the inflammatory mediators including TNF α , NF κ Bp65 and IL6. All inflammatory mediators in this study were affected by EGB in a dose dependant manner resulting in the improvement of ulcerative colitis. Another study by Kotakadi et al (154) showed that EGBs have anti-inflammatory properties *in vitro* and prevent and treat colitis in the DSS-induced mouse model. The mechanism underlying the treatment of ulcerative colitis is in part due to the ability of EGB to drive CD4⁺ effector T cell apoptosis which is fundamental in regulating many chronic inflammatory and autoimmune diseases (155-156).

8.3 Other potential therapies

Crocin

Crocin, a carotenoid compound derived from *Crocus sativus L* (saffron) has been used to treat different diseases (157). In the TNBS-induced colitis mouse model, it was revealed that treatment with 50 mg/kg/day intragastrically for 8 days significantly ameliorated diarrhea, inflammation and colonic tissue injury (158). The mechanisms by which crocin exerted these beneficial effects is through the reduction of neutrophil infiltration and MDA in the inflamed colon. Increased production of NO by iNOS and activation of NF κ B, known to play a central role in the early steps of inflammation were also reduced. With further investigation, crocin could prove to be an alternative therapy or perhaps be used alongside conventional therapies.

Pomegranate

Punica granatum or the pomegranate is used in traditional medicine in China, India, Europe and South Africa. Studies have shown that pomegranate has protective properties against liver fibrosis and ultraviolet-induced pigmentation (159-160). Furthermore, it has antibacterial, anti-inflammatory, anti-diabetic effects and is cardio-protective (161-163). Singh et al. (164) explored the effect of *Punica granatum* extract and its component, ellagic acid, in the DSS-induced colitis mouse model and found significant attenuation of colonic inflammation. Mast cell degranulation, which releases various inflammatory mediators, including histamine, has been implicated in the pathogenesis of ulcerative colitis and the use of mast cell stabilizers have been documented to attenuate the severity of ulcerative colitis in humans (165). Singh et al (164) found that *Punica granatum* extract and its ellagic acid component had anti-ulcerative effects comparable to sodium cromoglycate (mast cell stabiliser) and sulphasalazine (standard first line treatment for ulcerative colitis).

Helminths

Immune-mediated diseases such as inflammatory bowel disease are becoming more prevalent in highly developed and industrialized countries (166). It is suggested that the adoption of hygienic lifestyles in these countries have contributed to a decline in helminths or parasitic worm infections (166). Epidemiological studies (167-169) have suggested that helminths may provide protection against some immune-mediated diseases and the eradication may in fact promote these diseases. Animal studies have shown helminth protection by promoting regulatory immune responses. In a DNBS-induced mouse colitis model Melon et al. (170) showed that mice infected with the tapeworm, *Hymenolepis diminuta*, increased the production of IL4 and IL10 that protected them from colitis, in contrast to steroid treatment (dexamethasone) which offered little benefit. Khan et al. (171) also showed protection with the nematode, *Trichinella spiralis*, in the TNBS- induced colitis mouse model. However, it was found that helminth infection enhanced disease severity in the oxazolone induced colitis mouse model (172). In a human randomized crossover trial conducted by Summers et al (173), a significant percentage of patients with ulcerative colitis receiving the porcine whipworm, *Trichuris suis*, improved when compared to placebo. As well, the treatment seemed to be safe with no reported side effects. In conclusion, there is potential value for helminth therapy for specific inflammatory bowel disease patients however further studies are needed to fully understand the mechanisms underlying the pathophysiology of ulcerative colitis and the type of helminth therapy required to avoid the possibility of disease aggravation.

8.4 Prebiotics

There is a diverse and large population of micro-organisms naturally living on the mucosal surfaces or in the lumen of the human intestine. The number of resident bacteria increases along the small bowel, with the colon being the most heavily populated region of intestine. The microbiota refers to the particular ecological niche of a host individual in which the community of living micro-organisms is assembled (174). A healthy or balanced microbiota has been considered to be predominantly saccharolytic and comprises of significant numbers of lactobacilli and bifidobacteria (175). A prebiotic can be defined as a non-digestible food ingredient that exerts a beneficial effect on the host through the selective stimulation and metabolism in the intestine, thereby improving host health (176). Inulin and oligofructose are prebiotic carbohydrates that resist digestion by intestinal and pancreatic enzymes in the human gastrointestinal tract and are fermented by bacteria living in the intestinal ecosystem. Prebiotics increase saccharolytic activity within the gut and selectively promote the growth of bifidobacteria when administered in significant amounts (177-178).

Animal models

Videla et al. (179) investigated the effectiveness of inulin, which stimulates intracolonic generation of butyrate and growth of lactic acid bacteria, in the protection against colitis. In a rat model of DSS-induced colitis, oral inulin treatment significantly reduced colonic tissue MPO activity and mucosal release of inflammatory mediators (179). Histologically, oral inulin treatment reduced the extent of damaged mucosa, decreased the severity of crypt disruption and lowered histological damage severity scores compared with controls. Inulin induced an acidic environment from the caecum to the left colon and increased counts of Lactobacilli (179).

Fructooligosaccharides (FOS) increase the growth of lactic acid bacteria and promote butyrate and lactate production, therefore possessing beneficial properties for intestinal inflammation (180). Intracolonic TNBS-induced colitic rats treated with intragastric infusions of FOS resulted in a reduction of pH and inflammation assessed by MPO activity. Furthermore, FOS treatment increased lactate and butyrate concentrations including lactic acid bacteria counts in the caecum (180).

Madsen et al. (181) investigated the role of colonic aerobic luminal bacteria and lactobacillus species in IL10 gene-deficient mice that spontaneously develop colitis. These knockout mice have a decreased level of lactobacillus species in the colon and an increase in adherent and translocated bacteria in the neonatal period. Normalising Lactobacillus levels via oral lactulose therapy reduced colonic mucosal bacteria and prevented colitis (181). Similarly, lactulose treatment has demonstrated protective effects against DSS- and TNBS-models of colitis (182-183). Rumi et al. (182) demonstrated that lactulose therapy ameliorated DSS-induced colitis in a dose-dependent manner and significantly reduced the severity of colonic lesions and decreased MPO activity. Furthermore, Camuesco et al. (183) indicated that lactulose treatment in TNBS-induced colitis exerted a preventive anti-inflammatory effect as evidenced by a significant reduction of MPO activity, a decrease of colonic TNF α and leukotriene B4 production and an inhibition of colonic inducible nitric oxygen synthase expression, which is a result of the inflammatory process (183). Furthermore, this effect was associated with increased levels of lactobacilli and bifidoacteria species in colonic content when compared with untreated colitic rats (183). Overall, the experimental evidence provides significant indications of the anti-inflammatory and beneficial properties of prebiotics in settings of ulcerative colitis.

Clinical studies

Recently, Casellas et al. (184) tested the effect of oligofructose-enriched inulin, which promote the selective growth of saccharolytic bacteria with low inflammatory potential, in patients with active ulcerative colitis. Eligible patients in the randomized, placebo-controlled double blinded pilot trial had been previously in remission with mesalazine as maintenance therapy or no drug, and presented with a relapse of mild to moderate activity (184). Nineteen subjects were treated with mesalazine and randomly allocated to receive either oligofructose-enriched inulin or placebo for two weeks. Patients treated with oligofructose-enriched inulin displayed a reduction of faecal calprotectin, a protein found in granulocytes that resist metabolic degradation (184).

8.5 Probiotics

Probiotics are defined as living, non-pathogenic bacteria which are able to exert beneficial therapeutic or physiologic activities when administered in sufficient numbers (185). Bacteria can be derived from various sources such as cultured food and the normal human microbiota. *Lactobacillus* or *bifidobacterium* genera are the most common strains of probiotic bacteria and have also been identified from enterococcus, streptococcus, and lactococcus species, while certain non-pathogenic *Escherichia* strains are also classified as probiotics (186). Furthermore, genetic engineering of probiotic strains can ensure the release of bioactive compounds¹⁶. The beneficial effects of probiotics are highly species and strain specific and therefore the mechanism of action is not well understood. Common mechanisms of action identified in probiotics include improvement of epithelial barrier function, inhibition of pathogenic enteric bacteria and manipulation of host immunoregulation (185).

In vitro models

The effects of probiotics have been investigated using recent comprehensive cell culture experiments which are model systems of inflammation and infection similar to ulcerative colitis. Schlee et al. (187) investigated the ability and mechanism by which different probiotic *Lactobacillus* strains, including *L. Acidophilus* PZ1138, *L. Fermentum* PZ-1138, *E. coli Nissle 1917* and VSL#3 (a combination of 8 bacterial strains), stabilize gut barrier function via induction of the anti-microbial peptide human beta defensin-2 (hBD2) gene. The expression of hBD2 gene by probiotic bacteria was both time- and dosage-dependent, and the promoter activation by probiotics was completely inhibited via deletion of NFκB and activator protein-1 (AP1) binding sites on the hBD-2 promoter (187). Furthermore, hBD-2 induction was also hindered by the inhibition of mitogen-activated protein kinase (MAPK). Overall, Schlee et al. (187) demonstrated that *Lactobacilli* and the VSL#3 bacterial combination strengthened intestinal barrier functions via the up-regulation of hBD-2 through induction of MAPKs and pro-inflammatory pathways including NFκB and AP1. In support of the finding of Schlee et al. (187), *E. coli Nissle 1917* was further demonstrated to strengthen intestinal barrier function using a polarized T84 epithelial monolayer model to monitor barrier disruption by *E. coli* infection (188). Co-incubation of the enteropathogenic *E. coli* strain with *E. coli Nissle 1917* or addition of *E. coli Nissle 1917* following infection abolished barrier disruption and restored barrier integrity (188). DNA-microarray analysis of T84 cells incubated with the enteropathogenic *E. coli* identified altered expression of over 300 genes, including the distribution of zonula occludens-2 (ZO-2) protein and of distinct

protein kinase C isotypes, all of which are involved in the maintenance of epithelial tight junctions (188).

Furthermore, *E. coli Nissle 1917* has been shown to exert anti-inflammatory effects on human colonic epithelial cells *in vitro* (189). Enzyme-linked immunosorbent assays and real-time quantitative PCR demonstrated that *E. coli Nissle 1917* treatment *in vitro* suppressed TNF α -induced IL8 transcription and production and inhibited IL8 promoter activity. These properties, in conjunction with the hBD2 results from Schlee et al (187) and T84 epithelial monolayer model results from Zyrek et al. (188) contribute to the reported efficacy in the treatment of inflammatory bowel diseases. Due to the unfortunate idiopathic nature of IBD, pre-treatment with probiotics may be more beneficial for either genetically susceptible individuals or to help IBD sufferers maintain remission.

Animal models

Several murine models of intestinal damage have been utilised to assess the efficacy of probiotics *in vivo* (190-192). Ukena et al. (191) orally administered the probiotic *E. coli Nissle 1917* to BALB/c mice with acute dextran sulphate sodium (DSS)-induced colitis. The probiotic treatment resulted in an upregulation of the tight junction molecule ZO-1 in intestinal epithelial cells at both mRNA and protein levels and reduced intestinal barrier permeability (191). Additionally, infiltration of the colon with leukocytes was ameliorated in *E. coli Nissle 1917* inoculated mice (191). Furthermore, Grabig et al (193) demonstrated that *E. coli Nissle 1917* treatment in a wildtype DSS-induced colitis mouse model significantly reduced pro-inflammatory cytokine expression, myeloperoxidase (found in the intracellular granules of neutrophils) activity and disease activity. The inability of *E. coli Nissle 1917* to exert its beneficial effect in the absence of toll-like receptor (TLR)-2 and TLR4 signaling using TLR2 and TLR4 knockout mice indicates that the amelioration of experimentally-induced colitis in mice was elicited via TLR2- and TLR4-dependent pathways (193). This finding highlights the fact that *E. coli Nissle 1917* may improve the ability of TLRs, which are key components of the innate immune system that trigger antimicrobial host defence responses, to recognise microbial pathogens, improving the host immune response.

Lee et al. (194) demonstrated that oral *L. plantarum HY115* treatment to mice with DSS-induced colitis inhibited colon shortening and MPO production. Furthermore, *L. plantarum HY115* repressed the mRNA expressions of IL1 β , TNF α and IFN γ , including colonic IL1 beta and IL6 protein expression and reduced the degradation activities of chondroitin sulphate and hyaluronic acid of intestinal bacteria (194). Similarly, Schultz et al. (195) immune-mediated colitic (induced by IL10 deficiency) mice treated with *L. plantarum* had decreased levels of mucosal IL12, IFN γ and immunoglobulin G2a (195).

A study by Peran et al. (196) assessed the intestinal anti-inflammatory effects of probiotics with immunomodulatory properties in the TNBS rat model of colitis. *L. casei*, *L. acidophilus* and bifidobacterium lactis elicited intestinal anti-inflammatory effects, evidenced macroscopically by a decreased colonic weight/length ratio and biochemically, all probiotics restored colonic glutathione levels, depleted due to oxidative stress (196). Interestingly, each probiotic displayed a unique anti-inflammatory profile; bifidobacterium lactis reduced colonic TNF α production, *L. casei* decreased colonic COX-2 expression and *L. acidophilus* reduced leukotriene B4 production and MPO activity (196). These findings indicate that probiotics exert their beneficial effects via different mechanisms. Menard et al. (197) inoculated gnotobiotic mice with bifidobacterium longum NCC2705 and nine bifidobacterium strains isolated from infants' faecal flora to investigate the effect of these

probiotics on the Th1/Th2 balance. Immunomodulatory responses including induction of the Th1 and Th2 cytokines, increased ileal IL10, IL4, TNF α and IFN γ secretions and TGF β 1 gene expressions, were observed from only specific strains (197). It was concluded that bifidobacterium's capacity to stimulate immunity is species specific however its influence on the orientation of the immune system is strain specific.

Clinical trials

To date, probiotics have been investigated in several clinical trials as treatments for ulcerative colitis, with conflicting results. However, there have been relatively few large, placebo-controlled, randomised and double-blinded clinical studies to test the efficacy of probiotics in humans (198). Tsuda et al. (199) evaluated the efficacy of the probiotics combination therapy BIO-THREE, comprising of *Streptococcus faecalis* T-110, *Clostridium butyricum* TO-A and *Bacillus mesentericus* TO-A, in patients with mild to moderate distal ulcerative colitis. Patients ingested nine BIO-THREE tablets per day for four weeks. Clinical symptoms and endoscopic findings were evaluated as ulcerative colitis disease activity index and faecal samples were collected to assess the microflora, pre- and post-treatment (199). Remission was observed in nine patients (45%), response in two patients (10%), no response in eight patients (40%) and worsening in one patient (5%) (199). Interestingly, terminal restriction fragment length polymorphism (T-RFLP) analysis indicated that the principal alteration in microflora was an increase in bifidobacteria (199); an unusual finding as no bifidobacteria was administered in the probiotic supplement.

8.6 Zinc

Zinc is ubiquitous in biologic systems and has abundant and varied functions. The zinc atom has the ability to participate in readily exchangeable ligand binding in addition to assuming a number of coordination geometries to provide functional needs to other ligands (200). Zinc has numerous central roles in DNA and RNA metabolism (201). Zinc metalloenzymes and zinc-dependent enzymes have been identified and are involved in nucleic acid metabolism and cellular proliferation, differentiation and growth (202). Zinc also plays a regulatory role in apoptosis (203), with cytoprotective functions that suppress major pathways, leading to programmed cell death.

Animal studies

Zinc administration has been shown to suppress the development of DSS-induced colitis in mice as indicated by decreased clinical disease activity index and histological severity scores (204-206). Ohkawara et al. (205) demonstrated that polaprezinc (N-(3-Aminopropionyl)-L-histidinato zinc), an anti-ulcer drug, suppresses DSS-induced colitis in mice, partly through inhibition of production of pro-inflammatory cytokines, suppression of neutrophils accumulation and cytoprotection by overexpression of heat shock proteins. This is consistent with Iwaya et al (207) whom reported that marginal zinc deficiency exacerbated colitis by modulating the immune response through the impairment of TNF α production and TNFR1 expression, rather than through the impairment of epithelial barrier function. Another potential mechanism of action of zinc in ulcerative colitis has been suggested by Luk et al. (208) by reducing inflammation, inhibiting mast cell degranulation and histamine release. In addition, high dose of zinc has been shown to improve tight-junction permeability (209). A novel zinc compound, Z-103, a chelate compound consisting of zinc ion and L-carnosine, was utilized to assess the protective effect against colonic damage

induced by TNBS in rats (210). The authors demonstrated that treatment with Z-103 reduced the inflammatory responses induced by TNBS, suggesting Z-103 may be as effective against TNBS-induced colitis.

Metallothioneins (MTs) are zinc-binding proteins whose overexpression may lead to sequestration of zinc ions. We have shown that the absence of MT was beneficial in the suppression of colitis in MT knockout (MT^{-/-}) mice receiving DSS, suggesting that the presence of MT may have promoted the induction of colitis. Similarly, as indicated by the histological severity scores, MT wildtype mice appeared more susceptible to DSS-induced colitis compared to MT^{-/-} animals (204). Furthermore, Bruewer et al. (211) reported that MT overexpression may represent an important early step in the development of carcinogenesis of ulcerative colitis independent of p53 expression. This should be further investigated in the long term as an independent cancer risk factor in ulcerative colitis.

Human studies

The only double-blind controlled trial of oral zinc sulphate as adjuvant treatment in idiopathic ulcerative colitis or proctitis in relapse was reported by Dronfield et al. (212). In this trial, 51 patients were treated with zinc and the clinical and sigmoidoscopic improvement was similar in the treated and placebo group. Furthermore, it has been shown that zinc administration decreased peripheral blood natural killer cell activity in 13 inflammatory bowel disease patients, with stable disease and mild-moderate disease activity, in a double-blind randomized cross-over trial (213).

9. Conclusions

Animal models of acute and chronic intestinal inflammation are indispensable for our understanding of the pathogenesis of ulcerative colitis and Crohn's disease, even though the etiology of inflammatory bowel disease remains unclear. In conclusion, administration of the above novel therapies have potential benefits in suppressing clinical features, histological pathology scores and inflammatory indicators in colitis in experimental models. There are four types of experimental animal models of colitis; spontaneous colitis models, inducible colitis models with normal immune system, adoptive transfer models in immunocompromised hosts, and genetically engineered models (knockout and transgenic mice). There is not one single experimental model of colitis that incorporates all the clinical and histopathological characteristics of human inflammatory bowel disease, however, information gained from studies using these different types of colitis models has revealed three fundamental underlying principles. Firstly, chronic intestinal inflammation is mainly mediated by T cells. Secondly, commensal enteric bacteria are required to initiate and achieve intestinal inflammation and finally, the genetic background of the animal is a pivotal factor of disease onset and severity (84). Using these different models of colitis, *in vitro* and *in vivo* studies have shown a variety of novel therapies including, pre- and probiotics, n-3 fatty acids, plant bioactives (resveratrol, black raspberries, ginseng, ginkgo) and helminthes which have potential benefits in suppressing clinical features, histological pathology scores and inflammatory indicators. These novel therapies act on specific mechanisms of action such as intestinal barrier function, mucosal immune function and intestinal microbiota, however, there are no single therapies that have a multifunctional mechanism of action to prevent and treat ulcerative colitis. Newer therapies which use a combination of agents to restore gut homeostasis should be more promising and closer to

achieving long-term remission of ulcerative colitis. Thus, further studies are warranted to determine the mechanism of action by which these agents are able to protect against ulcerative colitis and to explore whether combination therapy could produce synergistic effects.

10. Acknowledgement

CDT was a recipient of the MS McLeod Post-Doctoral Fellowship funded by the Women's and Children's Hospital Foundation.

11. References

- [1] Smith PD, Ochsenauber-Jambor C, Smythies LE. Intestinal macrophages: unique effector cells of the innate immune system. *Immunol Rev* 2005;206:149-59.
- [2] Rugtveit J, Brandtzaeg P, Halstensen TS, Fausa O, Scott H. Increased macrophage subset in inflammatory bowel disease: apparent recruitment from peripheral blood monocytes. *Gut* 1994;35(5):669-74.
- [3] Rugtveit J, Nilsen EM, Bakka A, Carlsen H, Brandtzaeg P, Scott H. Cytokine profiles differ in newly recruited and resident subsets of mucosal macrophages from inflammatory bowel disease. *Gastroenterol* 1997;112(5):1493-505.
- [4] Kamada N, Hisamatsu T, Okamoto S, Chinen H, Kobayashi T, Sato T, Sakuraba A, Kitazume MT, Sugita A, Koganei K, Akagawa KS, Hibi T. Unique CD14 intestinal macrophages contribute to the pathogenesis of Crohn's disease via IL-23/IFN-gamma axis. *J Clin Invest* 2008;118(6):2269-80.
- [5] Rescigno M, Di Sabatino A. Dendritic cells in intestinal homeostasis and disease. *J Clin Invest* 2009;119(9):2441-50.
- [6] Billsborough J, Viney JL. Gastrointestinal dendritic cells play a role in immunity, tolerance, and disease. *Gastroenterol* 2004;127(1):300-9.
- [7] Hart AL, Al-Hassi HO, Rigby RJ, Bell SJ, Emmanuel AV, Knight SC, Kamm MA, Stagg AJ. Characteristics of intestinal dendritic cells in inflammatory bowel diseases. *Gastroenterol* 2005;129(1):50-65.
- [8] MacDermott RP, Nash GS, Bertovich MJ, Seiden MV, Bragdon MJ, Beale MG. Alterations of IgM, IgG, and IgA Synthesis and secretion by peripheral blood and intestinal mononuclear cells from patients with ulcerative colitis and Crohn's disease. *Gastroenterol* 1981;81(5):844-52.
- [9] Scott MG, Nahm MH, Macke K, Nash GS, Bertovich MJ, MacDermott RP. Spontaneous secretion of IgG subclasses by intestinal mononuclear cells: differences between ulcerative colitis, Crohn's disease, and controls. *Clin Exp Immunol* 1986;66(1):209-15
- [10] Mosmann TR, Cherwinski H, Bond MW, Giedlin MA, Coffman RL. Two types of murine helper T cell clone. I. Definition according to profiles of lymphokine activities and secreted proteins. *J Immunol* 1986;136(7):2348-57.
- [11] Romagnani S. Human TH1 and TH2 subsets: regulation of differentiation and role in protection and immunopathology. *Int Arch Allergy Immunol* 1992;98(4):279-85.
- [12] Annunziato F, Romagnani S. Do studies in humans better depict Th17 cells? *Blood* 2009;114(11):2213-9.

- [13] Annunziato F, Cosmi L, Santarlasci V, Maggi L, Liotta F, Mazzinghi B, Parente E, Fili L, Ferri S, Frosali F, Giudici F, Romagnani P, Parronchi P, Tonelli F, Maggi E, Romagnani S. Phenotypic and functional features of human Th17 cells. *J Exp Med* 2007;204(8):1849-61.
- [14] Annunziato F, Romagnani S. Heterogeneity of human effector CD4⁺ T cells. *Arthritis Res Ther* 2009;11(6):257.
- [15] Cosmi L, Maggi L, Santarlasci V, Capone M, Cardilicchia E, Frosali F, Querci V, Angeli R, Matucci A, Fambrini M, Liotta F, Parronchi P, Maggi E, Romagnani S, Annunziato F. Identification of a novel subset of human circulating memory CD4⁺ T cells that produce both IL-17A and IL-4. *J Allergy Clin Immunol* 2010;125(1):222-30.
- [16] Jiang H, Chess L. An integrated view of suppressor T cell subsets in immunoregulation. *J Clin Invest* 2004;114(9):1198-208.
- [17] Feuerer M, Hill JA, Mathis D, Benoist C. Foxp3⁺ regulatory T cells: differentiation, specification, subphenotypes. *Nat Immunol* 2009;10(7):689-95.
- [18] Weaver CT, Harrington LE, Mangan PR, Gavrieli M, Murphy KM. Th17: an effector CD4⁺ T cell lineage with regulatory T cell ties. *Immunity* 2006;24(6):677-88.
- [19] Weaver CT, Hatton RD. Interplay between the TH17 and TReg cell lineages: a (co-)evolutionary perspective. *Nat Rev Immunol* 2009;9(12):883-9.
- [20] Sakaguchi, S. Naturally arising Foxp3-expressing CD25⁺CD4⁺ regulatory T cells in immunological tolerance to self and non-self. *Nat Immunol* 2005; 6: 345-52.
- [21] Fontenot JD, Gavin MA, Rudensky AY. Foxp3 programs the development and function of CD4⁺CD25⁺ regulatory T cells. *Nat Immunol* 2003;4: 330-36.
- [22] Korn T, Oukka M, Kuchroo V, et al. Th17 cells: effector T cells with inflammatory properties. *Sem Immunol* 2007;19: 362-71.
- [23] Parronchi P, Romagnani P, Annunziato F, Sampognaro S, Becchio A, Giannarini L, Maggi E, Pupilli C, Tonelli F, Romagnani S. Type 1 T-helper cell predominance and interleukin-12 expression in the gut of patients with Crohn's disease. *Am J Pathol* 1997;150(3):823-32.
- [24] Monteleone G, Biancone L, Marasco R, Morrone G, Marasco O, Luzzza F, Pallone F. Interleukin 12 is expressed and actively released by Crohn's disease intestinal lamina propria mononuclear cells. *Gastroenterol* 1997;112(4):1169-78.
- [25] Fujino S, Andoh A, Bamba S, Ogawa A, Hata K, Araki Y, Bamba T, Fujiyama Y. Increased expression of interleukin 17 in inflammatory bowel disease. *Gut* 2003;52(1):65-70.
- [26] Fuss IJ, Heller F, Boirivant M, Leon F, Yoshida M, Fichtner-Feigl S, Yang Z, Exley M, Kitani A, Blumberg RS, Mannon P, Strober W. Nonclassical CD1d-restricted NK T cells that produce IL-13 characterize an atypical Th2 response in ulcerative colitis. *J Clin Invest* 2004;113(10):1490-7.
- [27] Heller F, Florian P, Bojarski C, Richter J, Christ M, Hillenbrand B, Mankertz J, Gitter AH, Bürgel N, Fromm M, Zeitz M, Fuss I, Strober W, Schulzke JD. Interleukin-13 is the key effector Th2 cytokine in ulcerative colitis that affects epithelial tight junctions, apoptosis, and cell restitution. *Gastroenterol* 2005;129(2):550-64.
- [28] Cotran RS, Kumar V, Collins T. *Pathologic Basis of Disease* (6th edition). W.B. Saunders Company, USA; 1999.

- [29] Xavier RJ, Podolsky DK. Unravelling the pathogenesis of inflammatory bowel disease. *Nature* 2007;448:427-34.
- [30] Geier MS, Butler RN, Giffard PM, Howarth GS. *Lactobacillus fermentum* BR11, a potential new probiotic, alleviates symptoms of colitis induced by dextran sulfate sodium (DSS) in rats. *Int J Food Microbiol* 2007;114(3):267-74.
- [31] Ishioka T, Kuwabara N, Oohashi Y, Wakabayashi K. Induction of colorectal tumors in rats by sulfated polysaccharides. *Crit Rev Toxicol* 1987;17(3):215-44.
- [32] Geier MS TD, Yazbeck R, McCaughan GW, Abbott CA, Howarth GS. Development and resolution of experimental colitis in mice with targeted deletion of dipeptidyl peptidase IV. *J Cell Physiol* 2005;204:687-92.
- [33] Vowinkel T KT, Mori M, Krieglstein CF, Granger DN. Impact of dextran sulfate sodium load on the severity of inflammation in experimental colitis. *Dig Dis Sci* 2004;49:556-64.
- [34] Whittem CG, Williams AD, Williams CS. Murine Colitis modeling using Dextran Sulfate Sodium (DSS). *J Vis Exp* 2010;(35).
- [35] Huang TC, Tsai SS, Liu LF, Liu YL, Liu HJ, Chuang KP. Effect of *Arctium lappa* L. in the dextran sulfate sodium colitis mouse model. *World J Gastroenterol* 2010;16(33):4193-9.
- [36] Ni J, Chen SF, Hollander D. Effects of dextran sulphate sodium on intestinal epithelial cells and intestinal lymphocytes. *Gut* 1996;39(2):234-41.
- [37] Sartor RB. Microbial influences in inflammatory bowel diseases. *Gastroenterol* 2008;134(2):577-94.
- [38] Poritz LS, Garver KI, Green C, Fitzpatrick L, Ruggiero F, Koltun WA. Loss of the tight junction protein ZO-1 in dextran sulfate sodium induced colitis. *J Surg Res* 2007;140(1):12-9.
- [39] Kitajima S, Takuma S, Morimoto M. Histological analysis of murine colitis induced by dextran sulfate sodium of different molecular weights. *Exp Anim* 2000;49(1):9-15.
- [40] Okayasu I, Hatakeyama S, Yamada M, Ohkusa T, Inagaki Y, Nakaya R. A novel method in the induction of reliable experimental acute and chronic ulcerative colitis in mice. *Gastroenterol* 1990;98(3):694-702.
- [41] Melgar S, Karlsson A, Michaëlsson E. Acute colitis induced by dextran sulfate sodium progresses to chronicity in C57BL/6 but not in BALB/c mice: correlation between symptoms and inflammation. *Am J Physiol Gastrointest Liver Physiol* 2005;288(6):G1328-38.
- [42] Hirono I, Kuhara K, Hosaka S, Tomizawa S, Golberg L. Induction of intestinal tumors in rats by dextran sulfate sodium. *J Natl Cancer Inst* 1981;66(3):579-83.
- [43] Parronchi P, Romagnani P, Annunziato F, Sampognaro S, Becchio A, Giannarini L, Maggi E, Pupilli C, Tonelli F, Romagnani S. Type 1 T-helper cell predominance and interleukin-12 expression in the gut of patients with Crohn's disease. *Am J Pathol* 1997;150(3):823-32.
- [44] Neurath MF, Fuss I, Kelsall B, Meyer zum Büschenfelde KH, Strober W. Effect of IL-12 and antibodies to IL-12 on established granulomatous colitis in mice. *Ann N Y Acad Sci* 1996;795:368-70.
- [45] Fuss IJ, Marth T, Neurath MF, Pearlstein GR, Jain A, Strober W. Anti-interleukin 12 treatment regulates apoptosis of Th1 T cells in experimental colitis in mice. *Gastroenterol* 1999;117(5):1078-88.

- [46] Neurath MF, Fuss I, Kelsall BL, Stüber E, Strober W. Antibodies to interleukin 12 abrogate established experimental colitis in mice. *J Exp Med* 1995;182(5):1281-90.
- [47] Neurath M, Fuss I, Strober W. TNBS-colitis. *Int Rev Immunol* 2000;19(1):51-62.
- [48] Scheiffele F, Fuss IJ. Induction of TNBS colitis in mice. *Curr Protoc Immunol* 2002;Chapter 15:Unit 15.19.
- [49] Kazi HA, Qian Z. Crocetin reduces TNBS-induced experimental colitis in mice by downregulation of NFκB. *Saudi J Gastroenterol* 2009;15(3):181-7.
- [50] Yamada Y, Marshall S, Specian RD, Grisham MB. A comparative analysis of two models of colitis in rats. *Gastroenterol* 1992;102(5):1524-34.
- [51] Ekström GM. Oxazolone-induced colitis in rats: effects of budesonide, cyclosporin A, and 5-aminosalicylic acid. *Scand J Gastroenterol* 1998;33(2):174-9.
- [52] te Velde AA, Verstege MI, Hommes DW. Critical appraisal of the current practice in murine TNBS-induced colitis. *Inflamm Bowel Dis* 2006;12(10):995-9.
- [53] Morris GP, Beck PL, Herridge MS, Depew WT, Szewczuk MR, Wallace JL. Hapten-induced model of chronic inflammation and ulceration in the rat colon. *Gastroenterol* 1989;96(3):795-803.
- [54] Allgayer H, Deschryver K, Stenson WF. Treatment with 16,16'-dimethyl prostaglandin E2 before and after induction of colitis with trinitrobenzenesulfonic acid in rats decreases inflammation. *Gastroenterol* 1989;96(5 Pt 1):1290-300.
- [55] Teh HS, Phillips RA, Miller RG. Quantitative studies on the precursors of cytotoxic lymphocytes. V. The cellular basis for the cross-reactivity of TNP-specific clones. *J Immunol* 1978;121(5):1711-7.
- [56] Kunin S, Gallily R. Recognition and lysis of altered-self cells by macrophages. I. Modification of target cells by 2,4,6-trinitrobenzene sulphonic acid. *Immunol* 1983;48(2):265-72.
- [57] Grisham MB, Volkmer C, Tso P, Yamada T. Metabolism of trinitrobenzene sulfonic acid by the rat colon produces reactive oxygen species. *Gastroenterol* 1991;101(2):540-7.
- [58] MacNaughton WK, Wallace JL. A role for dopamine as an endogenous protective factor in the rat stomach. *Gastroenterol* 1989;96(4):972-80.
- [59] Vilaseca J, Salas A, Guarner F, Rodriguez R, Malagelada JR. Participation of thromboxane and other eicosanoid synthesis in the course of experimental inflammatory colitis. *Gastroenterol* 1990;98(2):269-77.
- [60] Wallace JL. Release of platelet-activating factor (PAF) and accelerated healing induced by a PAF antagonist in an animal model of chronic colitis. *Can J Physiol Pharmacol* 1988;66(4):422-5.
- [61] Hawkins JV, Emmel EL, Feuer JJ, Nedelman MA, Harvey CJ, Klein HJ, Rozmiarek H, Kennedy AR, Lichtenstein GR, Billings PC. Protease activity in a hapten-induced model of ulcerative colitis in rats. *Dig Dis Sci* 1997;42(9):1969-80.
- [62] Mazzon E, Puzzolo D, Caputi AP, Cuzzocrea S. Role of IL-10 in hepatocyte tight junction alteration in mouse model of experimental colitis. *Mol Med* 2002;8(7):353-66.
- [63] Zingarelli B, Cuzzocrea S, Szabo C, Salzman AL. Mercaptoethylguanidine, a combined inhibitor of nitric oxide synthase and peroxynitrite scavenger, reduces trinitrobenzene sulfonic acid-induced colon damage in rats. *J Pharmacol Exp Ther* 1998;287:1048-1055.

- [64] Zingarelli B, Szaboá C, Salzman AL. Reduced oxidative and nitrosative damage in murine experimental colitis in the absence of inducible nitric oxide synthase. 1999 *Gut* 45: 199-209.
- [65] Qui BS, Vallance BA., Blennerhassett PA, Collins SM. The role of CD4 lymphocytes in the susceptibility of mice to stress-induced reactivation of experimental colitis. *Nat Med* 1999;5:1178-1182.
- [66] Wang X, Ouyang Q, Luo WJ. Oxazolone-induced murine model of ulcerative colitis. *Chin J Dig Dis* 2004;5(4):165-8.
- [67] Kojima R, Kuroda S, Ohkishi T, Nakamaru K, Hatakeyama S. Oxazolone-induced colitis in BALB/C mice: a new method to evaluate the efficacy of therapeutic agents for ulcerative colitis. *J Pharmacol Sci* 2004;96(3):307-13.
- [68] Schiechl G, Bauer B, Fuss I, Lang SA, Moser C, Ruemmele P, Rose-John S, Neurath MF, Geissler EK, Schlitt HJ, Strober W, Fichtner-Feigl S. Tumor development in murine ulcerative colitis depends on MyD88 signaling of colonic F4/80+CD11b(high)Gr1(low) macrophages. *J Clin Invest* 2011;121(5):1692-708.
- [69] Schiechl G, Bauer B, Fuss I, Lang SA, Moser C, Ruemmele P, Rose-John S, Neurath MF, Geissler EK, Schlitt HJ, Strober W, Fichtner-Feigl S. Tumor development in murine ulcerative colitis depends on MyD88 signaling of colonic F4/80+CD11b(high)Gr1(low) macrophages. *J Clin Invest* 2011;121(5):1692-708.
- [70] Heller F, Fuss IJ, Nieuwenhuis EE, Blumberg RS, Strober W: Oxazolone colitis, a Th2 colitis model resembling ulcerative colitis, is mediated by IL-13 producing NK-T cells. *Immunity* 2002; 17:629-638.
- [71] Borthakur A, Bhattacharyya S, Dudeja PK, Tobacman JK. Carrageenan induces interleukin-8 production through distinct Bcl10 pathway in normal human colonic epithelial cells. *Am J Physiol Gastrointest Liver Physiol* 2007;292(3):G829-38.
- [72] Tobacman JK. Review of harmful gastrointestinal effects of carrageenan in animal experiments. *Environ Health Perspect* 109: 983-994, 2001.
- [73] Tobacman JK. Toxic considerations related to ingestion of carrageenan. In: *Reviews in Food and Nutrition Toxicity*, edited by Preedy VR and Watson RR. New York: Taylor & Francis, 2003, p. 204-229.
- [74] Langman JM, Rowland R, Vernon-Roberts B. Carrageenan colitis in the guinea pig: pathological changes and the importance of ascorbic acid deficiency in disease induction. *Aust J Exp Biol Med Sci* 1985;63 (Pt 5):545-53.
- [75] Fath RB Jr, Deschner EE, Winawer SJ, Dworkin BM. Degraded carrageenan-induced colitis in CF1 mice. A clinical, histopathological and kinetic analysis. *Digestion* 1984;29(4):197-203.
- [76] Jobin C, Sartor RB. The I kappa B/NF-kappa B system: a key determinant of mucosal inflammation and protection. *Am J Physiol Cell Physiol* 2000;278(3):C451-62.
- [77] Ruland J, Duncan GS, Elia A, del Barco Barrantes I, Nguyen L, Plyte S, Millar DG, Bouchard D, Wakeham A, Ohashi PS, Mak TW. Bcl10 is a positive regulator of antigen receptor-induced activation of NF-kappaB and neural tube closure. *Cell* 2001;104(1):33-42.
- [78] Willerford DM, Chen J, Ferry JA, Davidson L, Ma A, Alt FW. Interleukin-2 receptor alpha chain regulates the size and content of the peripheral lymphoid compartment. *Immunit.* 1995;3(4):521-30.

- [79] Rudolph U, Finegold MJ, Rich SS, Harriman GR, Srinivasan Y, Brabet P, Boulay G, Bradley A, Birnbaumer L. Ulcerative colitis and adenocarcinoma of the colon in G alpha i2-deficient mice. *Nat Genet* 1995;10(2):143-50.
- [80] Sadlack B, Merz H, Schorle H, Schimpl A, Feller AC, Horak I. Ulcerative colitis-like disease in mice with a disrupted interleukin-2 gene. *Cell* 1993;75(2):253-61.
- [81] Ehrhardt RO, Ludviksson B. Induction of colitis in IL2-deficient-mice: the role of thymic and peripheral dysregulation in the generation of autoreactive T cells. *Res Immunol* 1997;148(8-9):582-8.
- [82] Contractor NV, Bassiri H, Reya T, Park AY, Baumgart DC, Wasik MA, Emerson SG, Carding SR. Lymphoid hyperplasia, autoimmunity, and compromised intestinal intraepithelial lymphocyte development in colitis-free gnotobiotic IL-2-deficient mice. *J Immunol* 1998;160(1):385-94.
- [83] Baumgart DC, Olivier WA, Reya T, Peritt D, Rombeau JL, Carding SR. Mechanisms of intestinal epithelial cell injury and colitis in interleukin 2 (IL2)-deficient mice. *Cell Immunol* 1998;187(1):52-66.
- [84] Ostanin DV, Bao J, Koboziev I, Gray L, Robinson-Jackson SA, Kosloski-Davidson M, Price VH, Grisham MB. T cell transfer model of chronic colitis: concepts, considerations, and tricks of the trade. *Am J Physiol Gastrointest Liver Physiol* 2009;296(2):G135-46.
- [85] Berg DJ, Davidson N, Kühn R, Müller W, Menon S, Holland G, Thompson-Snipes L, Leach MW, Rennick D. Enterocolitis and colon cancer in interleukin-10-deficient mice are associated with aberrant cytokine production and CD4(+) TH1-like responses. *J Clin Invest* 1996;98(4):1010-20.
- [86] Kühn R, Löhler J, Rennick D, Rajewsky K, Müller W. Interleukin-10-deficient mice develop chronic enterocolitis. *Cell* 1993;75(2):263-74.
- [87] Davidson NJ, Fort MM, Müller W, Leach MW, Rennick DM. Chronic colitis in IL-10-/- mice: insufficient counter regulation of a Th1 response. *Int Rev Immunol* 2000;19(1):91-121.
- [88] Knoch B, Nones K, Barnett MP, McNabb WC, Roy NC. Diversity of caecal bacteria is altered in interleukin-10 gene-deficient mice before and after colitis onset and when fed polyunsaturated fatty acids. *Microbiol* 2010;156(Pt 11):3306-16.
- [89] Thomas ML. The leukocyte common antigen family. *Annu Rev Immunol*. 1989;7:339-69.
- [90] Leach MW, Bean AG, Mauze S, Coffman RL, Powrie F. Inflammatory bowel disease in C.B-17 scid mice reconstituted with the CD45RBhigh subset of CD4+ T cells. *Am J Pathol* 1996;148(5):1503-15.
- [91] Powrie F, Leach MW, Mauze S, Caddle LB, Coffman RL. Phenotypically distinct subsets of CD4+ T cells induce or protect from chronic intestinal inflammation in C. B-17 scid mice. *Int Immunol* 1993;5(11):1461-71.
- [92] Read S, Malmström V, Powrie F. Cytotoxic T lymphocyte-associated antigen 4 plays an essential role in the function of CD25(+)CD4(+) regulatory cells that control intestinal inflammation. *J Exp Med* 2000;192(2):295-302.
- [93] Asseman C, Mauze S, Leach MW, Coffman RL, Powrie F. An essential role for interleukin 10 in the function of regulatory T cells that inhibit intestinal inflammation. *J Exp Med* 1999;190(7):995-1004.
- [94] Hendrickson BA GR, Cho JH. Clinical aspects and pathophysiology of inflammatory bowel disease. *Clin Microbiol Rev* 2002;15(79-94).

- [95] Pithadia AB, Jain S. Treatment of inflammatory bowel disease (IBD). *Pharmacol Rep* 2011;63(3):629-42.
- [96] Toruner M, Loftus EV, Harmsen WS, Zinsmeister AR, Orenstein R, Sandborn WJ, Colombel JF, Egan LJ. Risk factors for opportunistic infections in inflammatory bowel diseases: a case control study. *Gastroenterology* 2008; 134: 929-36.
- [97] Sartor RB. Current concepts of the etiology and pathogenesis of ulcerative colitis and Crohn's disease. *Gastroenterol Clin North Am* 1995;24(3):475-507.
- [98] Sartor RB: Microbial factors in the pathogenesis of Crohn's disease, ulcerative colitis and experimental intestinal inflammation. In: *Inflammatory Bowel Disease*. 5th edn., Eds Kirsner JB, Hanauer S, Saunders, Philadelphia, 1999, 153-178.
- [99] Uehara T, Kato K, Ohkusa T, Sugitani M, Ishii Y, Nemoto N, Moriyama M. Efficacy of antibiotic combination therapy in patients with active ulcerative colitis, including refractory or steroid-dependent cases. *J Gastroenterol Hepatol* 2010;25 Suppl 1:S62-6.
- [100] Ohkusa T, Kato K, Terao S, Chiba T, Mabe K, Murakami K, Mizokami Y, Sugiyama T, Yanaka A, Takeuchi Y, Yamato S, Yokoyama T, Okayasu I, Watanabe S, Tajiri H, Sato N; Japan UC Antibiotic Therapy Study Group. Newly developed antibiotic combination therapy for ulcerative colitis: a double-blind placebo-controlled multicenter trial. *Am J Gastroenterol* 2010;105(8):1820-9.
- [101] Turner D, Shah PS, Steinhart AH, Zlotkin S, Griffiths AM. Maintenance of remission in inflammatory bowel disease using omega-3 fatty acids (fish oil): a systematic review and meta-analyses. *Inflamm Bowel Dis* 2011;17:336-345.
- [102] Hilsden RJ, Verhoef MJ, Best A, Pocobelli G. Complementary and alternative medicine use by Canadian patients with inflammatory bowel disease: results from a national survey. *Am J Gastroenterol* 2003;98(7):1563-8.
- [103] Head K, Jurenka JS. Inflammatory bowel disease. Part II: Crohn's disease--pathophysiology and conventional and alternative treatment options. *Altern Med Rev* 2004;9(4):360-401.
- [104] Korzenik JR, Podolsky DK. Evolving knowledge and therapy of inflammatory bowel disease. *Nat Rev Drug Discov* 2006;5(3):197-209.
- [105] Rutgeerts P, Vermeire S, Van Assche G. Biological therapies for inflammatory bowel diseases. *Gastroenterol* 2009;136(4):1182-97.
- [106] Akabas SR, Deckelbaum RJ. Summary of a workshop on n-3 fatty acids: current status of recommendations and future directions. *Am J Clin Nutr*. 2006;83:1536S-1538S.
- [107] Ergas D, Eilat E, Mendlovic S, Sthoeger ZM. n-3 fatty acids and the immune system in autoimmunity. *Isr Med Assoc J*. 2002;4:34-38.
- [108] Hooper L, Thompson RL, Harrison RA, Summerbell CD, Moore H, Worthington HV, Durrington PN, Ness AR, Capps NE, Davey Smith G, Riemersma RA, Ebrahim SB. Omega-3 fatty acids for prevention and treatment of cardiovascular disease [Systematic Review]. *Cochrane Database Syst Rev*. 2004;CD003177.
- [109] Ruxton CH, Reed SC, Simpson MJ, Millington KJ. The health benefits of omega-3 polyunsaturated fatty acids: a review of the evidence. *J Hum Nutr Diet* 2004;17(5):449-59.
- [110] Simopoulos AP. Omega-3 fatty acids in inflammation and autoimmune diseases. *J Am Coll Nutr*.2002;21:495-505.

- [111] Mayer K, Seeger W. Fish oil in critical illness. *Curr Opin Vlin Nutr Metab Care.* 2008;11:121-127.
- [112] James MJ, Gibson RA, Cleland LG. Dietary polyunsaturated fatty acids and inflammatory mediator production. *Am J Clin Nutr* 2000;71(suppl):343S-8S.
- [113] MacLean CH, Mojica WA, Newberry SJ, Pencharz J, Garland RH, Tu W, Hilton LG, Gralnek IM, Rhodes S, Khanna P, Morton SC. Systematic review of the effects of n-3 fatty acids in inflammatory bowel disease. *Am J Clin Nutr* 2005;82:611-9.
- [114] Whiting CV, Bland P, Tarlton JF. Dietary n-3 polyunsaturated fatty acids reduce disease and colonic proinflammatory cytokines in a mouse model of colitis. *Inflamm Bowel Dis* 2005;11:340-349.
- [115] Li Q, Zhang Q, Zhang M, Wang C, Zhu Z, Li N, Li J. Effect of n-3 polyunsaturated fatty acids on membrane microdomain localization of tight junction proteins in experimental colitis.
- [116] Nishihara T, Matsuda M, Araki H, Oshima K, Kihara S, Funahashi T, Shimomura I. Effect of adiponectin on murine colitis induced by dextran sulfate sodium. *Gastroenterol* 2006;131(3):853-61.
- [117] Fayad R, Pini M, Sennello JA, Cabay RJ, Chan L, Xu A, Fantuzzi G. Adiponectin deficiency protects mice from chemically induced colonic inflammation. *Gastroenterol* 2007;132(2):601-14.
- [118] Yamamoto K, Kiyohara T, Murayama Y, Kihara S, Okamoto Y, Funahashi T, Ito T, Nezu R, Tsutsui S, Miyagawa JI, Tamura S, Matsuzawa Y, Shimomura I, Shinomura Y. Production of adiponectin, an anti-inflammatory protein, in mesenteric adipose tissue in Crohn's disease. *Gut* 2005;54(6):789-96.
- [119] Matsunaga H, Hokari R, Kurihara C, Okada Y, Takebayashi K, Okudaira K, Watanabe C, Komoto S, Nakamura M, Tsuzuki Y, Kawaguchi A, Nagao S, Itoh K, Miura S. Omega-3 fatty acids exacerbate DSS-induced colitis through decreased adiponectin in colonic subepithelial myofibroblasts. *Inflamm Bowel Dis* 2008;14(10):1348-57.
- [120] Hillier K, Jewell R, Dorrell L, Smith CL. Incorporation of fatty acids from fish oil and olive oil into colonic mucosal lipids and effects upon eicosanoid synthesis in inflammatory bowel disease. *Gut.* 1991;32:1151-1155.
- [121] McCall TB, O'Leary D, Bloomfield J, O'Morain CA. Therapeutic potential of fish oil in the treatment of ulcerative colitis. *Aliment Pharmacol Ther.* 1989;3:415-424.
- [122] Almallah YZ, Richardson S, O'Hanrahan T, Mowat NA, Brunt PW, Sinclair TS, Ewen S, Heys SD, Eremin O. Distal procto-colitis, natural cytotoxicity, and essential fatty acids. *Am J Gastroenterol* 1998;93:804-9.
- [123] Varghese TJ, Coomansingh D. Clinical response of ulcerative colitis with dietary omega-3 fatty acids: a double-blind randomized study. *Br J Surg* 2000;87(suppl):73 (abstr).
- [124] Hawthorne AB, Daneshmend TK, Hawkey CJ, Belluzzi A, Everitt SJ, Holmes GK, Malkinson C, Shaheen MZ, Willars JE. Treatment of ulcerative colitis with fish oil supplementation: a prospective 12 month randomised controlled trial. *Gut* 1992;33(7):922-8.
- [125] Greenfield SM, Green AT, Teare JP, Jenkins AP, Punchedard NA, Ainley CC, Thompson RP. A randomized controlled study of evening primrose oil and fish oil in ulcerative colitis. *Aliment Pharmacol Ther.* 1993;7(2):159-66.

- [126] Loeschke K, Ueberschaer B, Pietsch A, Gruber E, Ewe K, Wiebecke B, Heldwein W, Lorenz R. n-3 fatty acids only delay early relapse of ulcerative colitis in remission. *Dig Dis Sci*. 1996 ;41(10):2087-94.
- [127] Mantzaris GJ, Archavlis E, Zografos C, Petraki K, Spiliades C, Triantafyllou G. A prospective, randomized, placebo-controlled study of fish oil in ulcerative colitis. *Hellen J Gastroenterol* 1996;9:138-141.
- [128] Middleton SJ, Naylor S, Woolner J, Hunter JO. A double-blind, randomized, placebo-controlled trial of essential fatty acid supplementation in the maintenance of remission of ulcerative colitis. *Aliment Pharmacol Ther* 2002;16(6):1131-5.
- [129] Hawthorne AB, Daneshmend TK, Hawkey CJ et al. Fish oil in ulcerative colitis: final results of a controlled clinical trial. *Gastroenterol* 1990;98:A174(abstr).
- [130] Belluzzi A, Brignola C, Campieri M, Camporesi EP, Gionchetti P, Rizzello F, Belloli C, De Simone G, Boschi S, Miglioli M, et al. Effects of new fish oil derivative on fatty acid phospholipid-membrane pattern in a group of Crohn's disease patients. *Dig Dis Sci*. 1994;39:2589-2594.
- [131] Seril DN, Liao J, Yang GY, Yang CS. Oxidative stress and ulcerative colitis-associated carcinogenesis: studies in humans and animal models. *Carcinogenesis* 2003;24(3):353-62.
- [132] Sánchez-Fidalgo S, Cárdeno A, Villegas I, Talero E, de la Lastra CA. Dietary supplementation of resveratrol attenuates chronic colonic inflammation in mice. *Eur J Pharmacol*. 2010;633(1-3):78-84.
- [133] Cui X, Jin Y, Hofseth AB, Pena E, Habiger J, Chumanevich A, Poudyal D, Nagarkatti M, Nagarkatti PS, Singh UP, Hofseth LJ. Resveratrol suppresses colitis and colon cancer associated with colitis. *Cancer Prev Res (Phila)* 2010;3(4):549-59.
- [134] Tang T, Targan SR, Li ZS, Xu C, Byers VS, Sandborn WJ. Randomised clinical trial: herbal extract HMPL-004 in active ulcerative colitis - a double-blind comparison with sustained release mesalazine. *Aliment Pharmacol Ther* 2011;33(2):194-202.
- [135] Afaq F, Saleem M, Krueger CG, Reed JD, Mukhtar H. Anthocyanin- and hydrolyzable tannin-rich pomegranate fruit extract modulates MAPK and NF-kappaB pathways and inhibits skin tumorigenesis in CD-1 mice. *Int J Cancer* 2005;113(3):423-33.
- [136] Reddy MK, Alexander-Lindo RL, Nair MG. Relative inhibition of lipid peroxidation, cyclooxygenase enzymes, and human tumor cell proliferation by natural food colors. *J Agric Food Chem* 2005;53(23):9268-73.
- [137] Rodrigo KA, Rawal Y, Renner RJ, Schwartz SJ, Tian Q, Larsen PE, Mallery SR. Suppression of the tumorigenic phenotype in human oral squamous cell carcinoma cells by an ethanol extract derived from freeze-dried black raspberries. *Nutr Cancer* 2006;54(1):58-68.
- [138] Daniel E. Extraction, stability and quantitation of ellagic acid in various fruits and nuts. *J Food Comp Anal* 1989; 2:338-349.
- [139] Wada L, Ou B. Antioxidant activity and phenolic content of Oregon caneberries. *J Agric Food Chem* 2002;50(12):3495-500.
- [140] Olsson ME, Gustavsson KE, Andersson S, Nilsson A, Duan RD. Inhibition of cancer cell proliferation in vitro by fruit and berry extracts and correlations with antioxidant levels. *J Agric Food Chem* 2004;52(24):7264-71.

- [141] Parry J, Su L, Moore J, Cheng Z, Luther M, Rao JN, Wang JY, Yu LL. Chemical compositions, antioxidant capacities, and antiproliferative activities of selected fruit seed flours. *J Agric Food Chem* 2006;54(11):3773-8.
- [142] Renis M, Calandra L, Scifo C, Tomasello B, Cardile V, Vanella L, Bei R, La Fauci L, Galvano F. Response of cell cycle/stress-related protein expression and DNA damage upon treatment of CaCo2 cells with anthocyanins. *Br J Nutr* 2008;100(1):27-35.
- [143] Shih PH, Yeh CT, Yen GC. Anthocyanins induce the activation of phase II enzymes through the antioxidant response element pathway against oxidative stress-induced apoptosis. *J Agric Food Chem* 2007;55(23):9427-35.
- [144] Montrose DC, Horelik NA, Madigan JP, Stoner GD, Wang LS, Bruno RS, Park HJ, Giardina C, Rosenberg DW. Anti-inflammatory effects of freeze-dried black raspberry powder in ulcerative colitis. *Carcinogenesis* 2011;32(3):343-50.
- [145] Hofseth LJ. Ginseng and Cancer. *Healthy Aging* 2006:53-58.
- [146] Hofseth LJ, Wargovich MJ. Inflammation, cancer, and targets of ginseng. *J Nutr* 2007;137(1 Suppl):183S-185S.
- [147] Hofseth LJ. Nitric oxide as a target of complementary and alternative medicines to prevent and treat inflammation and cancer. *Cancer Lett* 2008;268(1):10-30.
- [148] Jin Y, Kotakadi VS, Ying L, Hofseth AB, Cui X, Wood PA, Windust A, Matesic LE, Pena EA, Chiuzan C, Singh NP, Nagarkatti M, Nagarkatti PS, Wargovich MJ, Hofseth LJ. American ginseng suppresses inflammation and DNA damage associated with mouse colitis. *Carcinogenesis* 2008;29(12):2351-9.
- [149] Jin Y, Hofseth AB, Cui X, Windust AJ, Poudyal D, Chumanevich AA, Matesic LE, Singh NP, Nagarkatti M, Nagarkatti PS, Hofseth LJ. American ginseng suppresses colitis through p53-mediated apoptosis of inflammatory cells. *Cancer Prev Res (Phila)* 2010;3(3):339-47.
- [150] Pehlivan M, Dalbeler Y, Hazinedaroglu S, Arikan Y, Erkek AB, Günel O, Türkçapar N, Türkçapar AG. An assessment of the effect of Ginkgo Biloba EGb 761 on ischemia reperfusion injury of intestine. *Hepatogastroenterol* 2002;49(43):201-4.
- [151] Maitra I, Marcocci L, Droy-Lefaix MT, Packer L. Peroxyl radical scavenging activity of Ginkgo biloba extract EGb 761. *Biochem Pharmacol* 1995;49(11):1649-55.
- [152] Kusmic C, Basta G, Lazzerini G, Vesentini N, Barsacchi R. The effect of Ginkgo biloba in isolated ischemic/reperfused rat heart: a link between vitamin E preservation and prostaglandin biosynthesis. *J Cardiovasc Pharmacol* 2004;44(3):356-62.
- [153] Zhou YH, Yu JP, Liu YF, Teng XJ, Ming M, Lv P, An P, Liu SQ, Yu HG. Effects of Ginkgo biloba extract on inflammatory mediators (SOD, MDA, TNF-alpha, NF-kappaBp65, IL-6) in TNBS-induced colitis in rats. *Mediators Inflamm*. 2006;2006(5):92642.
- [154] Kotakadi VS, Jin Y, Hofseth AB, Ying L, Cui X, Volate S, Chumanevich A, Wood PA, Price RL, McNeal A, Singh UP, Singh NP, Nagarkatti M, Nagarkatti PS, Matesic LE, Auclair K, Wargovich MJ, Hofseth LJ. Ginkgo biloba extract EGb 761 has anti-inflammatory properties and ameliorates colitis in mice by driving effector T cell apoptosis. *Carcinogenesis* 2008;29(9):1799-806.
- [155] Prasad KV, Prabhakar BS. Apoptosis and autoimmune disorders. *Autoimmunity* 2003;36(6-7):323-30.

- [156] Anderson GP. Resolution of chronic inflammation by therapeutic induction of apoptosis. *Trends Pharmacol Sci* 1996;17(12):438-42.
- [157] Abdullaev FI. Cancer chemopreventive and tumoricidal properties of saffron (*Crocus sativus* L.). *Exp Biol Med* (Maywood) 2002;227(1):20-5.
- [158] Kazi HA, Qian Z. Crocetin reduces TNBS-induced experimental colitis in mice by downregulation of NFkB. *Saudi J Gastroenterol* 2009 ;15(3):181-7.
- [159] Toklu HZ, Dumlu MU, Sehirli O, Ercan F, Gedik N, Gökmen V, Sener G. Pomegranate peel extract prevents liver fibrosis in biliary-obstructed rats. *J Pharm Pharmacol* 2007;59(9):1287-95.
- [160] Kasai K, Yoshimura M, Koga T, Arai M, Kawasaki S. Effects of oral administration of ellagic acid-rich pomegranate extract on ultraviolet-induced pigmentation in the human skin. *J Nutr Sci Vitaminol* (Tokyo) 2006;52(5):383-8.
- [161] Gracious Ross R, Selvasubramanian S, Jayasundar S. Immunomodulatory activity of *Punica granatum* in rabbits--a preliminary study. *Ethnopharmacol* 2001;78(1):85-7.
- [162] Aviram M, Dornfeld L. 2003. Methods of using pomegranate extracts for causing regression in lesions due to arteriosclerosis in humans. US patent. 6: 641, 850.
- [163] Huang TH, Peng G, Kota BP, Li GQ, Yamahara J, Roufogalis BD, Li Y. Anti-diabetic action of *Punica granatum* flower extract: activation of PPAR-gamma and identification of an active component. *Toxicol Appl Pharmacol* 2005;207(2):160-9.
- [164] Singh K, Jaggi AS, Singh N. Exploring the ameliorative potential of *Punica granatum* in dextran sulfate sodium induced ulcerative colitis in mice. *Phytother Res* 2009;23(11):1565-74.
- [165] Marshall JK, Irvine EJ. Ketotifen treatment of active colitis in patients with 5-aminosalicylate intolerance. *Can J Gastroenterol* 1998;12(4):273-5.
- [166] Elliott DE, Summers RW, Weinstock JV. Helminths as governors of immune-mediated inflammation. *Int J Parasitol* 2007;37(5):457-64.
- [167] van den Biggelaar AH, Rodrigues LC, van Ree R, van der Zee JS, Hoeksma-Kruize YC, Souverein JH, Missinou MA, Borrmann S, Kreamsner PG, Yazdanbakhsh M. Long-term treatment of intestinal helminths increases mite skin-test reactivity in Gabonese schoolchildren. *J Infect Dis* 2004;189(5):892-900.
- [168] Araújo MI, Hoppe BS, Medeiros M Jr, Carvalho EM. *Schistosoma mansoni* infection modulates the immune response against allergic and auto-immune diseases. *Mem Inst Oswaldo Cruz* 2004;99(5 Suppl 1):27-32.
- [169] van den Biggelaar AH, van Ree R, Rodrigues LC, Lell B, Deelder AM, Kreamsner PG, Yazdanbakhsh M. Decreased atopy in children infected with *Schistosoma haematobium*: a role for parasite-induced interleukin-10. *Lancet* 2000;356(9243):1723-7.
- [170] Melon A, Wang A, Phan V, McKay DM. Infection with *Hymenolepis diminuta* is more effective than daily corticosteroids in blocking chemically induced colitis in mice. *J Biomed Biotechnol* 2010;2010:384523, 1-7.
- [171] Khan WI, Blennerhasset PA, Varghese AK, Chowdhury SK, Omsted P, Deng Y, Collins SM. Intestinal nematode infection ameliorates experimental colitis in mice. *Infect Immun.* 2002;70(11):5931-7.
- [172] Wang A, Fernando M, Leung G, Phan V, Smyth D, McKay DM. Exacerbation of oxazolone colitis by infection with the helminth *Hymenolepis diminuta*: involvement of IL-5 and eosinophils. *Am J Pathol* 2010;177(6):2850-9.

- [173] Summers RW, Elliott DE, Urban JF Jr, Thompson RA, Weinstock JV. Trichuris suis therapy for active ulcerative colitis: a randomized controlled trial. *Gastroenterol* 2005;128(4):825-32.
- [174] Guarner F, Malagelada JR. Gut flora in health and disease. *Lancet* 2003;361:512-9.
- [175] Cummings JH, Antoine JM, Azpiroz F, Bourdet-Sicard R, Brandtzaeg P, Calder PC, Gibson GR, Guarner F, Isolauri E, Pannemans D, Shortt C, Tuijelaars S, Watzl B. PASSCLAIM--gut health and immunity. *Eur J Nutr* 2004;43 Suppl 2:II118-II173.
- [176] Gibson GR, Probert HM, Loo JV, Rastall RA, Roberfroid MB. Dietary modulation of the human colonic microbiota: updating the concept of prebiotics. *Nutr Res Rev* 2004;17:259-75.
- [177] Guarner F. Prebiotics in inflammatory bowel diseases. *Br J Nutr* 2007;98 Suppl 1:S85-9.
- [178] Marteau P. Probiotics, prebiotics, synbiotics: ecological treatment for inflammatory bowel disease? *Gut* 2006;55:1692-3.
- [179] Videla S, Vilaseca J, Antolin M, Garcia-Lafuente A, Guarner F, Crespo E, Casals J, Salas A, Malagelada JR. Dietary inulin improves distal colitis induced by dextran sodium sulfate in the rat. *Am J Gastroenterol* 2001;96:1486-93.
- [180] Cherbut C, Michel C, Lecannu G. The prebiotic characteristics of fructooligosaccharides are necessary for reduction of TNBS-induced colitis in rats. *J Nutr* 2003;133:21-7.
- [181] Madsen KL, Doyle JS, Jewell LD, Tavernini MM, Fedorak RN. Lactobacillus species prevents colitis in interleukin 10 gene-deficient mice. *Gastroenterology* 1999;116:1107-14.
- [182] Rumi G, Tsubouchi R, Okayama M, Kato S, Mozsik G, Takeuchi K. Protective effect of lactulose on dextran sulfate sodium-induced colonic inflammation in rats. *Dig Dis Sci* 2004;49:1466-72.
- [183] Camuesco D, Peran L, Comalada M, Nieto A, Di Stasi LC, Rodriguez-Cabezas ME, Concha A, Zarzuelo A, Galvez J. Preventative effects of lactulose in the trinitrobenzenesulphonic acid model of rat colitis. *Inflamm Bowel Dis* 2005;11:265-71.
- [184] Casellas F, Borrueal N, Torrejon A, Varela E, Antolin M, Guarner F, Malagelada JR. Oral oligofructose-enriched inulin supplementation in acute ulcerative colitis is well tolerated and associated with lowered faecal calprotectin. *Aliment Pharmacol Ther* 2007;25:1061-7.
- [185] Sartor RB. Therapeutic manipulation of the enteric microflora in inflammatory bowel diseases: antibiotics, probiotics, and prebiotics. *Gastroenterology* 2004;126:1620-33.
- [186] Borchers AT, Selmi C, Meyers FJ, Keen CL, Gershwin ME. Probiotics and immunity. *J Gastroenterol* 2009;44:26-46.
- [187] Schlee M, Harder J, Kotten B, Stange EF, Wehkamp J, Fellermann K. Probiotic lactobacilli and VSL#3 induce enterocyte beta-defensin 2. *Clin Exp Immunol* 2008;151:528-35.
- [188] Zyrek AA, Cichon C, Helms S, Enders C, Sonnenborn U, Schmidt MA. Molecular mechanisms underlying the probiotic effects of *Escherichia coli* Nissle 1917 involve ZO-2 and PKCzeta redistribution resulting in tight junction and epithelial barrier repair. *Cell Microbiol* 2007;9:804-16.
- [189] Kamada N, Maeda K, Inoue N, Hisamatsu T, Okamoto S, Hong KS, Yamada T, Watanabe N, Tsuchimoto K, Ogata H, Hibi T. Nonpathogenic *Escherichia coli*

- strain Nissle 1917 inhibits signal transduction in intestinal epithelial cells. *Infect Immun* 2008;76:214-20.
- [190] Dunne C, Murphy L, Flynn S, O'Mahony L, O'Halloran S, Feeney M, Morrissey D, Thornton G, Fitzgerald G, Daly C, Kiely B, Quigley EM, O'Sullivan GC, Shanahan F, Collins JK. Probiotics: from myth to reality. Demonstration of functionality in animal models of disease and in human clinical trials. *Antonie Van Leeuwenhoek* 1999;76:279-92.
- [191] Ukena SN, Singh A, Dringenberg U, Engelhardt R, Seidler U, Hansen W, Bleich A, Bruder D, Franzke A, Rogler G, Suerbaum S, Buer J, Gunzer F, Westendorf AM. Probiotic *Escherichia coli* Nissle 1917 inhibits leaky gut by enhancing mucosal integrity. *PLoS One* 2007;2:e1308.
- [192] Schultz M, Lindstrom AL. Rationale for probiotic treatment strategies in inflammatory bowel disease. *Expert Rev Gastroenterol Hepatol* 2008;2:337-55.
- [193] Grabig A, Paclik D, Guzy C, Dankof A, Baumgart DC, Erckenbrecht J, Raupach B, Sonnenborn U, Eckert J, Schumann RR, Wiedenmann B, Dignass AU, Sturm A. *Escherichia coli* strain Nissle 1917 ameliorates experimental colitis via toll-like receptor 2- and toll-like receptor 4-dependent pathways. *Infect Immun* 2006;74:4075-82.
- [194] Lee HS, Han SY, Bae EA, Huh CS, Ahn YT, Lee JH, Kim DH. Lactic acid bacteria inhibit proinflammatory cytokine expression and bacterial glycosaminoglycan degradation activity in dextran sulfate sodium-induced colitic mice. *Int Immunopharmacol* 2008;8:574-80.
- [195] Schultz M, Veltkamp C, Dieleman LA, Grenther WB, Wyrick PB, Tonkonogy SL, Sartor RB. *Lactobacillus plantarum* 299V in the treatment and prevention of spontaneous colitis in interleukin-10-deficient mice. *Inflamm Bowel Dis* 2002;8:71-80.
- [196] Peran L, Camuesco D, Comalada M, Bailon E, Henriksson A, Xaus J, Zarzuelo A, Galvez J. A comparative study of the preventative effects exerted by three probiotics, *Bifidobacterium lactis*, *Lactobacillus casei* and *Lactobacillus acidophilus*, in the TNBS model of rat colitis. *J Appl Microbiol* 2007;103:836-44.
- [197] Menard O, Butel MJ, Gaboriau-Routhiau V, Waligora-Dupriet AJ. Gnotobiotic mouse immune response induced by *Bifidobacterium* sp. strains isolated from infants. *Appl Environ Microbiol* 2008;74:660-6.
- [198] Hedin C, Whelan K, Lindsay JO. Evidence for the use of probiotics and prebiotics in inflammatory bowel disease: a review of clinical trials. *Proc Nutr Soc* 2007;66:307-15.
- [199] Tsuda Y, Yoshimatsu Y, Aoki H, Nakamura K, Irie M, Fukuda K, Hosoe N, Takada N, Shirai K, Suzuki Y. Clinical effectiveness of probiotics therapy (BIO-THREE) in patients with ulcerative colitis refractory to conventional therapy. *Scand J Gastroenterol* 2007;42:1306-11.
- [200] Vallee BL, Falchuk KH. The biochemical basis of zinc physiology. *Physiol Rev* 1993;73(1):79-118.
- [201] MacDonald RS. The role of zinc in growth and cell proliferation. *J Nutr.* 2000;130(5S Suppl):1500S-8S.
- [202] Chesters JK. Biochemical functions of zinc in animals. *World Rev Nutr Diet.* 1978;32:135-64.

- [203] Zalewski PD, Forbes IJ, Seamark RF, Borlinghaus R, Betts WH, Lincoln SF, Ward AD. Flux of intracellular labile zinc during apoptosis (gene-directed cell death) revealed by a specific chemical probe, Zinquin. *Chem Biol.* 1994;1(3):153-61.
- [204] Tran CD, Ball JM, Sundar S, Coyle P, Howarth GS. The role of zinc and metallothionein in the dextran sulfate sodium-induced colitis mouse model. *Dig Dis Sci.* 2007;52(9):2113-21.
- [205] Ohkawara T, Takeda H, Kato K, Miyashita K, Kato M, Iwanaga T, Asaka M. Polaprezinc (N-(3-aminopropionyl)-L-histidinato zinc) ameliorates dextran sulfate sodium-induced colitis in mice. *Scand J Gastroenterol* 2005;40(11):1321-7.
- [206] Chen BW, Wang HH, Liu JX, Liu XG. Zinc sulphate solution enema decreases inflammation in experimental colitis in rats. *J Gastroenterol Hepatol* 1999;14(11):1088-92.
- [207] Iwaya H, Kashiwaya M, Shinoki A, Lee JS, Hayashi K, Hara H, Ishizuka S. Marginal zinc deficiency exacerbates experimental colitis induced by dextran sulfate sodium in rats. *J Nutr* 2011;141(6):1077-82.
- [208] Luk HH, Ko JK, Fung HS, Cho CH. Delineation of the protective action of zinc sulfate on ulcerative colitis in rats. *Eur J Pharmacol* 2002;443(1-3):197-204.
- [209] Sturniolo GC, Fries W, Mazzon E, Di Leo V, Barollo M, D'inca R. Effect of zinc supplementation on intestinal permeability in experimental colitis. *J Lab Clin Med* 2002;139(5):311-5.
- [210] Yoshikawa T, Yamaguchi T, Yoshida N, Yamamoto H, Kitazumi S, Takahashi S, Naito Y, Kondo M. Effect of Z-103 on TNB-induced colitis in rats. *Digestion* 1997;58(5):464-8.
- [211] Bruewer M, Schmid KW, Krieglstein CF, Senninger N, Schuermann G. Metallothionein: early marker in the carcinogenesis of ulcerative colitis-associated colorectal carcinoma. *World J Surg* 2002;26(6):726-31.
- [212] Dronfield MW, Malone JD, Langman MJ. Zinc in ulcerative colitis: a therapeutic trial and report on plasma levels. *Gut* 1977;18(1):33-6.
- [213] Van de Wal Y, Van der Sluys Veer A, Verspaget HW, Mulder TP, Griffioen G, Van Tol EA, Peña AS, Lamers CB. Effect of zinc therapy on natural killer cell activity in inflammatory bowel disease. *Aliment Pharmacol Ther* 1993;7(3):281-6.

APPENDIX 4

**DIETARY EMU OIL SUPPLEMENTATION SUPPRESSES 5-
FLUOROURACIL CHEMOTHERAPY-INDUCED INFLAMMATION,
OSTEOCLAST FORMATION, AND BONE LOSS**

STATEMENT OF AUTHORSHIP

Dietary emu oil supplementation suppresses 5-fluorouracil chemotherapy-induced inflammation, osteoclast formation and bone loss

American Journal of Physiology: Endocrinology and Metabolism 2012; 302 (11): E1440-9

Rethi Raghu Nadhanan

Performed bone experiments, analysed data, interpreted results, prepared figures and manuscript.

I hereby certify that the statement of contribution is accurate.

Signed

Date 27/11/2012

Suzanne Mashtoub ABIMOSLEH (Candidate)

Conducted all animal trials, contributed to experimental conceptualisation and design.

I hereby certify that the statement of contribution is accurate.

Signed

Date 4/12/12

Yu-Wen Su

Assisted with bone removal and experiments.

I hereby certify that the statement of contribution is accurate.

Signed

Date: 26th Nov 2012

Micheala A. Scherer

Interpreted experimental results.

I hereby certify that the statement of contribution is accurate.

Signed

Date 27/11/12

Gordon S. Howarth

Contributed to experimental conceptualisation and design.

I hereby certify that the statement of contribution is accurate.

Signed

Date 4/12/12

Cory J. Xian

Contributed to experimental conceptualisation and data interpretation, critical manuscript evaluation.

I hereby certify that the statement of contribution is accurate.

Signed

Date: 27/11/2012

Nadhanan, R.R., Abimosleh, S.M., Su, Y-W., Scherer, M.A., Howarth, G.S. & Xian, C.J. (2012)
Dietary emu oil supplementation suppresses 5-fluorouracil chemotherapy-induced inflammation,
osteoclast formation, and bone loss.

American Journal of Physiology: Endocrinology and Metabolism, v. 302(11), pp. E1440-E1449

NOTE:

This publication is included on pages 218-227 in the print copy
of the thesis held in the University of Adelaide Library.

It is also available online to authorised users at:

<http://doi.org/10.1152/ajpendo.00587.2011>