

AN INVESTIGATION INTO THE ROLE OF RANKL AND SCLEROSTIN IN DENTOALVEOLAR ANKYLOSIS



A thesis submitted in partial fulfilment of the requirements for the degree of
Doctor of Clinical Dentistry (Orthodontics)

Dr Shelley Coburn, BDS (University of Otago)

Orthodontic Unit
School of Dentistry
Faculty of Health Science
The University of Adelaide
South Australia
AUSTRALIA

June 2015

1 CONTENTS

1.1 Table of Contents

1	CONTENTS	2
1.1	Table of Contents.....	2
1.2	List of Figures	5
1.3	List of Tables.....	6
1.4	List of abbreviations	8
2	ACKNOWLEDGEMENTS.....	10
3	THESIS DECLARATION	11
4	ABSTRACT	12
5	LITERATURE REVIEW	15
5.1	The Periodontal Complex.....	15
5.1.1	The Periodontal Ligament	15
5.1.2	Cementum	18
5.1.3	Bone	21
5.2	The Bone Remodelling Cycle.....	29
5.2.1	Activation of the remodelling cycle	31
5.2.2	Bone resorption	31
5.2.3	The reversal phase.....	38
5.2.4	Bone formation	39
5.2.5	Termination of the remodelling cycle	40
5.3	The OPG/RANK/RANKL Triad.....	41
5.3.1	Discovery of the molecular triad OPG/RANK/RANKL.....	41
5.3.2	RANKL expression by osteocytes	49
5.4	Sclerostin	54
5.4.1	Role of sclerostin	54
5.4.2	Sclerostin deficiency in humans	55
5.4.3	Expression of SOST/Sclerostin	56
5.4.4	Possible mechanisms of action	59

5.4.5	Regulation of SOST/Sclerostin expression.....	65
5.4.6	Clinical applications of sclerostin	67
5.4.7	Dentistry and sclerostin	67
5.5	Dentoalveolar ankylosis	69
5.5.1	Prevalence	70
5.5.2	Aetiology.....	72
5.5.3	Diagnosis.....	73
5.5.4	Histology.....	75
5.5.5	Sequelae and treatment of ankylosed teeth	76
5.5.6	Experimentally induced ankylosis.....	78
5.6	Features of the rodent dentoalveolar complex.....	80
5.7	References.....	82
6	STATEMENT OF PURPOSE	96
6.1	Aims.....	96
6.2	Null Hypothesis	97
6.2.1	Article 1:	97
6.2.2	Article 2:	97
7	ARTICLE 1	98
	Expression of RANKL in a rat model of dentoalveolar ankylosis following hypothermal insult 98	
7.1	Abstract.....	99
7.2	Introduction	100
7.3	Methods and Materials.....	105
7.4	Results.....	109
7.5	Discussion.....	123
7.6	Conclusions	127
7.7	References.....	128
8	ARTICLE 2	131
	Expression of sclerostin in a rat model of dentoalveolar ankylosis following hypothermal insult.....	131
8.1	Abstract.....	132

8.2	Introduction	133
8.3	Methods and materials.....	137
8.4	Results	141
8.4.1	Summary of results.....	157
8.5	Discussion.....	157
8.6	Conclusions	161
8.7	References.....	162
9	CONCLUDING REMARKS.....	166
9.1	Conclusions	166
9.2	Limitations of the study	167
9.3	Suggestions for future work:	168
10	APPENDICES	169
10.1	Optimisation of immunohistochemical detection for RANKL and sclerostin ...	169
10.2	Materials Utilised.....	169
10.3	Tartrate-resistant acid phosphatase (TRAP) staining protocol.....	174
10.4	Immunohistological staining protocol	175
10.4.1	RANKL	175
10.4.2	Sclerostin	177

1.2 List of Figures

Literature Review:

Figure 1. Histological stains for cementum	18
Figure 2. Cellular stratified cementum.....	20
Figure 3. Expression of markers during osteoblast-to-osteocyte ontogeny.....	26
Figure 4. Visualisation of early embedding osteocytes in 12-day murine calvaria	27
Figure 5. Schematic illustration of the local communication mechanisms involved in the remodelling of bone.....	30
Figure 6. Proposed roles of osteocytes under different mechanical conditions.....	36
Figure 7. Mechanisms of action for OPG, RANKL and RANK	44
Figure 8. Essential signalling pathways activated by RANKL interactions with RANK..	49
Figure 9. Micro-CT reconstruction of femurs of 12 week mice	51
Figure 10. Chronological portraits of a patient with sclerosteosis from the age of 3.....	55
Figure 11. Canaliculi and/or lacunae of osteocytes in human bone positive for sclerostin.	56
Figure 12. Sclerostin expression by cementocytes in a human third permanent molar.	56
Figure 13. Schematic diagram of the proposed regulation of a remodelling cortical osteon by osteocytic sclerostin expression	58
Figure 14. The Wnt/ β -catenin signalling pathway	62
Figure 15. The potential role of osteocyte-derived sclerostin in regulating the expression of osteocyte RANKL.....	64
Figure 16. Schematic model for the regulation of the control of bone formation by sclerostin.....	66
Figure 17. Infra-occlusion of a primary molar tooth below the level of the occlusal plane	69
Figure 18. Tooth 11 demonstrates infra-occlusion and ankylosis subsequent to avulsion and replantation	69

Article 1:

Figure 1. Essential signaling pathways activated by RANKL interactions with RANK.	101
Figure 2. Sampling regions in the rat molar tooth.....	108
Figure 3. Positive and negative controls for RANKL	109
Figure 4. H and E sections of experimental tooth (external control, day 0).....	111
Figure 5. H and E sections of experimental tooth (day 4, day 7).....	112
Figure 6. H and E sections of experimental tooth (day 14, day 28).....	113
Figure 7. TRAP-positive cells (external control, day 0)	114
Figure 8. TRAP-positive cells (day 7, day 14)	115
Figure 9. TRAP-positive cells (day 28).....	116
Figure 10. Expression of RANKL	117
Figure 11. RANKL expression in the pulp of a rat in the experimental teeth	119
Figure 12. RANKL expression in the PDL of a rat in the experimental teeth.....	121
Figure 13. Epithelial rests of Malassez.....	121
Figure 14. Osteocytes stain negatively for RANKL	122
Figure 15. Alveolar bone at day 14 (maximal ankylosis).....	123

Article 2:

Figure 1. Sampling regions in the rat molar tooth.....	140
Figure 2. H and E sections of experimental tooth (external control, day 0).....	143
Figure 3. H and E sections of experimental tooth (day 4, day 7).....	144
Figure 4. H and E sections of experimental tooth (day 14, day 28).....	145
Figure 5. Negative control	146
Figure 6. Lack of positive sclerostin expression in pulp and PDL.....	147
Figure 7. Positive sclerostin expression (cementocytes, osteocytes).....	148
Figure 8. Osteocytes showing positive staining for sclerostin	149
Figure 9. Empty lacunae and positive sclerostin staining.....	149
Figure 10. Empty lacunae and lack of osteocytes near the furcation area	151
Figure 11. Expression of sclerostin in osteocytes in alveolar bone in the experimental teeth	152

1.3 List of Tables

Literature Review:

Table 1. Acronyms and synonyms for proteins from the OPG/RANKL/RANK pathway.	42
Table 2. Expression patterns of OPG, RANKL, RANK.....	48

Article 1:

Table 1: Expression patterns of RANKL and RANK.....	100
Table 2: Percentage of bone in the sampled area of the experimental tooth	111

Article 2:

Table 1. Intraclass Correlation Coefficients.....	141
Table 2. Percentage of bone in the sampled area of PDL of the experimental tooth ..	143
Table 3. Empty lacunae counts: Interaction of group and day of sacrifice	150
Table 4. Empty lacunae counts: Interaction of group and zone	150
Table 5. Least squares means for outcome: sclerostin positive cells vs time, zone and side	153
Table 6. Global P values for outcome: sclerostin positive cells vs time, zone and side	153
Table 7. Differences of Least Squares Means for outcome: positive cells vs zone	154
Table 8. Least Squares Means for outcome: sclerostin positive cells vs time and zone*side	154
Table 9. Global P values for outcome: positive cells versus time and zone*side	155
Table 10. Differences of Least Squares Means for outcome: positive cells vs time and zone*side	155
Table 11. Global P values for outcome: sclerostin positive cells vs zone and time*side	156
Table 12. Positive cell counts: interaction of zone and day of sacrifice, adjusting for group.....	156

1.4 List of abbreviations

Ab	Antibody
ABC	Avidin-biotin complex
AEC	3-Amino-9-ethylcarbazole
Ag	Antigen
ALP	Alkaline phosphatase
ATP	Adenosine-5'-triphosphate
BMP	Bone morphogenetic protein
BMU	Basic metabolic unit
CSF	Colony stimulating factor
ECM	Extracellular matrix
EDTA	Ethylenediaminetetra-acetic acid
ERM	Epithelial rests of Malassez
Ig	Immunoglobulin
IGF	Insulin-like growth factor
IL	Interleukin
M	Molar (molarity)
M-CSF	Macrophage colony-stimulating factor
MMP	Matrix metalloproteinases
<i>mRNA</i>	Messenger ribonucleic acid
OPG	Osteoprotegerin
OY	Osteocyte
PBS	Phosphate buffered solution
PDL	Periodontal ligament

PTH	Parathyroid hormone
PTHrP	Parathyroid hormone-related protein
RANK	Receptor activator of nuclear factor kappa- β
RANKL	Receptor activator of nuclear factor kappa- β ligand
RNA	Ribonucleic acid
SCL	Sclerostin
SOST	The gene encoding for sclerostin
TGF	Transforming growth factor
TNF	Tumour necrosis factor
TRAP	Tartrate-resistant acid phosphatase

Abbreviations of length

mm	Millimetre
μm	Micrometre

Abbreviations of volume

ml	Millilitre
μl	Microlitre

Abbreviations of weight

g	Gram
kg	Kilogram
mg	Milligram
ng	Nanogram

2 ACKNOWLEDGEMENTS

I wish to express my appreciation and gratitude to the following people for their invaluable assistance in the completion of this thesis.

Professor W.J. Sampson, Emeritus Professor and Visiting Research Fellow, The University of Adelaide, for his advice and guidance. His patience and enthusiasm for teaching and research is invaluable.

Professor C.W. Dreyer, P.R. Begg Chair of Orthodontics, The University of Adelaide, for his comprehensive knowledge of the subject matter and pragmatic advice.

Dr Kencana Dharmapatni, School of Medical Sciences, The University of Adelaide, for her expertise and assistance especially with the laboratory work. Without her dedicated input this project would never have been completed.

Ms Suzanne Edwards, Discipline of Public Health, The University of Adelaide, for her expert statistical advice.

Mr Jim Manavis, Laboratory Manager, Hanson Institute Centre for Neurological Diseases, for his assistance in using the Nanozoomer Digital Microscope.

And finally, to my parents, Marion and Derek. Thank you for raising me to believe I can accomplish whatever I set my mind to.

3 THESIS DECLARATION

I certify that this work contains no material which has been accepted for the award of any other degree or diploma in my name, in any university or other tertiary institution and, to the best of my knowledge and belief, contains no material previously published or written by another person, except where due reference has been made in the text. In addition, I certify that no part of this work will, in the future, be used in a submission in my name, for any other degree or diploma in any university or other tertiary institution without the prior approval of the University of Adelaide and where applicable, any partner institution responsible for the joint-award of this degree.

I give consent to this copy of my thesis when deposited in the University Library, being made available for loan and photocopying, subject to the provisions of the Copyright Act 1968.

The author acknowledges that copyright of published works contained within this thesis resides with the copyright holder(s) of those works.

I also give permission for the digital version of my thesis to be made available on the web, via the University's digital research repository, the Library Search and also through web search engines, unless permission has been granted by the University to restrict access for a period of time.

Shelley Coburn

30th June 2015

4 ABSTRACT

Background: Dentoalveolar ankylosis may occur spontaneously or as a sequela to dental trauma and results in an area of bone fusing to the tooth (Kuroi 1981). Infra-occlusion following dentoalveolar ankylosis results in a number of significant orthodontic sequelae. These include over-eruption of the opposing tooth, tipping of adjacent teeth towards the ankylosed tooth, a loss of arch length, space loss and a shift of the dental midline (Messer and Cline 1980; Andlaw 1974; Ponduri et al. 2009). Vertical alveolar growth may also be hindered (Kjaer et al. 2008). The understanding of the biological processes behind the formation and repair of the ankylotic lesion is incomplete. Following dental trauma, the periodontal ligament (PDL) may be the source of the cells that repopulate a tooth root defect that determine whether ankylosis occurs (Erasquin and Devoto 1970; Lin et al. 2000; Melcher 1970; Line et al. 1974). When the PDL space is repopulated by cells from a source outside the true PDL tissues (such as the alveolar bone) healing may occur by way of dentoalveolar ankylosis.

Research in the field of bone biology has recently focused on the role of the osteocyte. This cell, with its unique location embedded in bone, may have an essential role in bone metabolism. Osteocytes produce sclerostin, a protein that inhibits bone formation. There is also evidence that the osteocyte may be a major source of receptor activator of NF- κ B (RANKL) which is essential for osteoclastogenesis. This project aims to investigate the expression of RANKL and sclerostin in a rat model of dentoalveolar ankylosis induced by a hypothermal insult.

The null hypothesis is that an applied cold insult and subsequent ankylosis does not affect the expression of RANKL and sclerostin within the dentoalveolar complex.

Methods: Dentoalveolar ankylosis was induced in fifteen, eight week old, male, Sprague-Dawley rats (5 groups of 3 rats each) by application of dry ice to the upper right first molar tooth. An additional 3 rats served as untreated controls and the experimental rats were sacrificed at days 0, 4, 7, 14 and 28. Immunohistochemical detection of RANKL and sclerostin was performed and the number of RANKL and sclerostin positive and negative cells as well as the number of empty lacunae representing dead osteocytes were calculated and compared between groups.

Results: The cold insult resulted in dentoalveolar ankylosis, with the periodontal ligament (PDL) almost completely replaced by bone in the furcation region of the root 14 days after injury with regeneration of the PDL evident after 28 days. Resorption of the ankylotic bone and cementum was evident in the furcation region. There was also a statistically significant increase in the number of empty lacunae due to osteocyte death that coincides with the incidence of maximal ankylosis.

RANKL was detected in bone marrow stromal cells, osteoblasts and bone lining cells, osteoclasts, endothelial-like cells lining vessels, epithelial cells, odontoblasts and periodontal fibroblasts. However, clear staining in osteocytes was not evident. Epithelial rests of Malassez showed strong expression of RANKL.

When ankylosis was present, there was a statistically significant difference in sclerostin expression between the areas of bone closest to, and farthest away, from the furcation area. There was a non-statistically significant trend towards reduced sclerostin expression at days 7 and 14 followed by a slight increase in expression at day 28. The slight increase in sclerostin expression at day 28 may indicate the establishment of a healing response.

In considering these results, it should be noted that this experiment uses a model of ankylosis in which the ankylotic lesion develops following a thermal insult. The factors that initiate ankylosis in a clinical situation are incompletely understood and may differ from this model.

Conclusions: Whilst RANKL was not detected in osteocytes in this model of ankylosis there was strong expression of RANKL by ERM in the PDL and a significant change in sclerostin expression near the area of ankylosis. This may contribute evidence that RANKL, sclerostin and the osteocyte might have a role in influencing the regeneration of the PDL following dentoalveolar ankylosis.

The null hypothesis that an applied cold insult and subsequent ankylosis does not affect the expression of RANKL and sclerostin within the dentoalveolar complex is rejected.

5 LITERATURE REVIEW

5.1 The Periodontal Complex

The periodontium can be defined as those tissues supporting and investing the tooth. It is comprised of root cementum, the periodontal ligament (PDL), the bone lining the tooth socket (the alveolar bone) and the part of the gingival tissue facing the tooth (dentogingival junction).

5.1.1 The Periodontal Ligament

The periodontal ligament is of key importance in dentistry and orthodontics. It is reportedly involved in tooth eruption; it provides support for the tooth and resists the forces of mastication; its proprioception permits positioning of the jaws and the control of the muscle forces during mastication and animal experiments suggest it provides a cell reservoir for tissue homeostasis, repair and regeneration. The ability of the PDL to remodel facilitates orthodontic tooth movement (Berkovitz 1990; Nanci and Bosshardt 2006).

Whilst reviewing research on the PDL, it must be noted that the majority of investigations into the periodontal ligament have been performed using animal material (Berkovitz 1990). The periodontal ligament consists of a fibrous stroma in a matrix of ground substance which contains cells, blood vessels and nerves. The fibrous stroma mainly consists of collagen and the majority of the cells are fibroblasts (Berkovitz 1990). The PDL measures 0.15mm to 0.38mm in width with the thinnest area at the middle third of the root and the thickness of which decreases with age (Nanci and Bosshardt 2006).

The periodontal ligament is approximately 70% water, which may provide support to the ligament in its ability to withstand loading. In areas of injury and inflammation, an

increase in tissue fluids in the ground substance may be observed (Nanci and Bosshardt 2006).

Type I collagen is the major fibrous component of the PDL, which is also the major protein found in skin, bones, tendons and dentine (Berkovitz 1990). Approximately 20% of PDL collagen is type III (Butler et al. 1975) and this is spread throughout the ligament (Wang et al. 1980). It is thought that type III collagen may be related to the overall turnover and determination of fibre diameter and provision of mobility (Berkovitz 1990). Type XII collagen (a non-fibril linking form) has also been shown to be present but its function is yet to be determined (Berkovitz 1990).

The PDL collagen fibres are arranged in principal bundles of different orientations according to function in different parts of the ligament. Branching networks course around neurovascular bundles. Near cementum the PDL fibres are 3-10µm wide while near the alveolar wall the fibres are less numerous but are 10-20µm wide. Most fibres measure 1-4µm in diameter. The fibres have a complex 3-D arrangement which ensures that, irrespective of the direction of force applied, some bundles are always placed in tension (Berkovitz 1990).

Collagen has a rapid turnover with a half-life of several days (Sodek 1977; Orłowski 1978; Rippin 1976). PDL collagen turnover is approximately 5 times faster than the turnover of collagen in skin (Imberman et al. 1986). This high turnover may be in relation to the need for rapid adaptation of the tissue and has also been suggested to be related to masticatory forces (Rippin 1976).

Approximately 50% of the PDL (excluding blood vessels) is taken up by cells (Berkovitz 1990) with the principal cell of the PDL being the fibroblast. It is a large cell with an extensive cytoplasm and a large number of organelles associated with protein synthesis and secretion. It has a well-developed cytoskeleton and frequent adherens and gap junctions. Fibroblasts are aligned along the general direction of the PDL fibre bundles

and may extend cytoplasmic processes in close fibre approximation (Nanci and Bosshardt 2006).

The fibroblast shape is difficult to determine in routine histological sections because the cell's cytoplasm takes up little stain and consequently is deduced mainly from the nucleus which stains more intensely (Berkovitz 1990). Scanning electron microscopy has led to the suggestion that the fibroblasts are pleomorphic and four general cell types exist: Irregular oblong-shaped cells that are oriented along principal PDL fibres characterised by roughened surfaces and the absence of cell processes; stellate-shaped, fibroblast-like cells with multiple cellular processes observed in lacunar spaces among the principal PDL fibres; nodular, spheroid shaped cells often seen in perivascular areas; and cells of an elongated, stellate shape usually oriented along principal PDL fibres and with numerous pseudopodia-like cellular processes (Roberts and Chamberlain 1978). However, care must be taken before accepting this classification as it is possible that specimen preparation could result in the introduction of artefacts. Cells may have the same basic shape but a lack of preferential orientation could give an appearance of pleomorphism (Berkovitz 1990). Although periodontal fibroblasts may appear polarised when viewed in longitudinal section, their outline in other planes suggest that they are flat, irregular discs, lacking any polarity in either morphology or distribution of intra-cytoplasmic contents (Shore and Berkovitz 1979).

The epithelial cells in the PDL are remnants of Hertwig's Root Sheath (HERS) and are known as the epithelial cell rests of Malassez. The cells lie close to cementum as clusters which form an epithelial network and seem to be more evident or abundant in furcation areas (Nanci and Bosshardt 2006). It has been postulated that the HERS give rise to cementoblasts and may also be the source of a special subpopulation of fibroblasts that contributes to the pool of periodontal ligament fibroblasts (Bosshardt 2005). Clinical studies in animals have demonstrated that the presence of epithelial cell rests of Malassez may prevent root resorption (Wallace and Vergona 1990; Fujiyama et al. 2004) and induce acellular cementum formation (Fujiyama et al. 2004). It has been suggested that the HERS may be the ultimate regulator of the PDL, responsible for

maintaining its width, homeostasis and providing a shield against resorption and ankylosis (Luan et al. 2006).

The PDL also contains undifferentiated mesenchymal cells or progenitor cells (Nanci and Bosshardt 2006). New cells are produced whilst the total cell population of the ligament remains steady. This indicates that the selective deletion of cells by apoptosis must be occurring to balance the production of new cells. These cells may be used not only for periodontal ligament repair but may also provide cells for cementum and bone formation (Nanci and Bosshardt 2006).

5.1.2 Cementum

Cementum is a thin, avascular, mineralised connective tissue which coats the root surfaces and acts as an interface between the periodontal fibres and the tooth dentine (Cho and Garant 2000; Nanci and Bosshardt 2006). Cementum is traditionally classified as cellular or acellular based on the presence or absence of cementocytes within the cementum. It is further classified as intrinsic or extrinsic fibre cementum based on whether the collagen fibres in the matrix are formed by cementoblasts or fibroblasts respectively (Figure 1) (Cho and Garant 2000; Nanci and Bosshardt 2006).

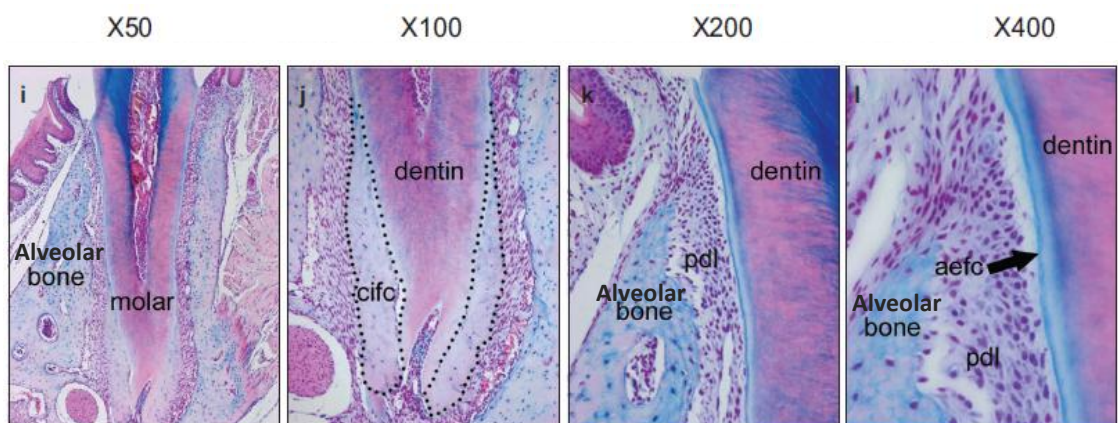


Figure 1. Histological stains for cementum

Mouse mandibular molar stained with Alcian blue and nuclear fast red (AB-NFR) to visualise acellular extrinsic fibre cementum (AEFC) and cellular intrinsic fibre cementum (CIFC). Magnifications are indicated above the panels [adapted from (Foster 2012)]

Acellular afibrillar cementum is located over cervical enamel at the cemento-enamel junction and its functional significance is, as yet, unknown (Cho and Garant 2000).

Acellular extrinsic fibre cementum (AEFC) is found on the cervical half to two-thirds of the root and is considered to be acellular as the cells that form it remain on the surface (Nanci and Bosshardt 2006). A large number of principal PDL fibres insert into this type of cementum (where they are called Sharpey's fibres) demonstrating that this tissue plays a major role in attaching the tooth to the PDL (Cho and Garant 2000; Nanci and Bosshardt 2006). AEFC is thin (50-200 μ m) (Yamamoto et al. 2010) and forms slowly (Nanci and Bosshardt 2006).

Cellular intrinsic fibre cementum (CIFC) is found along the apical third of the root and in furcation areas (Nanci and Bosshardt 2006) and is much thicker than acellular extrinsic cementum (Yamamoto et al. 2010). Characteristic features of this type of cementum include the presence of cementocytes trapped within the matrix they produce and collagen produced by cementoblasts with fibres arranged mostly parallel to the root (Cho and Garant 2000). This type of cementum forms rapidly and is less well mineralised than AEFC (Nanci and Bosshardt 2006). CIFC may also be produced as a repair tissue that fills resorptive defects and root fractures and consequently may be found further coronally in this situation (Nanci and Bosshardt 2006).

Cellular mixed stratified cementum is derived from consecutively deposited, alternating layers of AEFC and CIF (Figure 2) (Nanci and Bosshardt 2006). Individual layers of CIFC are 10-100 μ m thick (Yamamoto et al. 2010). This stratified cementum forms in response to functional movement of the teeth within their alveolar sockets (Yamamoto et al. 2010). Reshaping of the root surface is required to compensate for tooth movement and cellular intrinsic fibre cementum with few or no extrinsic fibres is deposited (Yamamoto et al. 2010). Whilst present in human teeth, cellular mixed stratified cementum is not found in rodent teeth (Nanci and Bosshardt 2006).

Cementum composition resembles bone with approximately 50% mineralised and 50% unmineralised matrix (Nanci and Bosshardt 2006). Type I collagen is the primary component of the unmineralised matrix accounting for up to 90% with other collagen fibres also present in small amounts. Non-collagenous proteins found in cementum are similar to those found in bone and include bone sialoprotein, dentin matrix protein 1 (DMP-1), dentin sialoprotein, fibronectin, osteocalcin, osteonectin, osteopontin, tenascin, proteoglycans, proteolipids, and several growth factors (Bosshardt 2005).

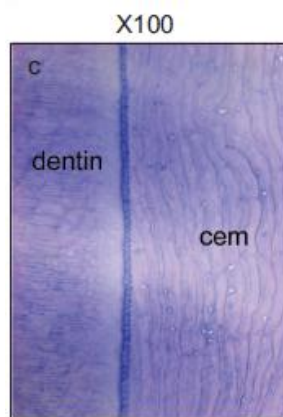


Figure 2. Cellular stratified cementum

H and E staining of human cementum illustrating the stratified layers [adapted from (Foster 2012)]

Developmental differences between bone and cementum and between AEFC and CIFC are unclear. Historically, it has been suggested that cementoblasts are positional osteoblasts and that cementum is a type of bone; although cementum is avascular, non-innervated and does not remodel or undergo physiological turnover (Foster 2012). A newer model (Bosshardt 2005) suggests that that cementoblasts producing both AEFC and CIFC are unique phenotypes that differ from osteoblasts. This theory proposes that cells descending from HERS may give direct rise to cells that form new cementum and periodontal ligament tissues, or play an indirect role by producing the necessary signalling molecules for cell recruitment and differentiation.

5.1.3 Bone

The human skeleton has many functions beyond acting as the structural support system for the body. Bone is a dynamic connective tissue and must constantly respond to external forces such as loading of the skeleton and to internal and external signals such as cytokines, growth factors and hormones (Jähn and Bonewald 2012). In addition, bone cells constantly communicate with each other and the cells of the immune and haematopoietic systems through factors such as osteoprotegerin (OPG), receptor activator of NF- κ B (RANKL), ephrins and sclerostin (Jähn and Bonewald 2012).

5.1.3.1 Histological structure of bone

The adult human skeleton is composed of 80% cortical bone and 20% trabecular bone (Clarke 2008). Cortical bone is dense and solid and surrounds the marrow space whereas the trabecular bone is composed of a honeycomb-like network of trabecular plates and rods interspersed in the bone marrow compartment. Both types are comprised of osteons. Cortical osteons are called Haversian systems which are cylindrical in shape and form a branching network within the cortical bone. Trabecular bone also comprises osteons that are semilunar in shape (Clarke 2008). Cortical and trabecular bone are normally formed in a lamellar pattern in which collagen fibrils are laid down in alternating orientations which provides the bone with significant strength. Woven bone is where the lamellar pattern is absent and collagen fibrils are laid down in a disorganised manner. Woven bone is weaker than lamellar bone and is normally produced during formation of primary bone. It may also be seen in high turnover states such as Paget's disease (Clarke 2008).

The outer surface of cortical bone is surrounded by the periosteum which is comprised of fibrous connective tissue. The periosteum contains blood vessels, nerve fibres, osteoblasts and osteoclasts. The endosteum is a membranous structure that covers the inner surface of the cortical bone, trabecular bone and blood vessel canals (Volkman's canals). It also contains blood vessels, osteoblasts and osteoclasts (Clarke 2008).

5.1.3.2 Bone biochemistry

Bone consists of 50 to 70% mineral, 20 to 40% organic matrix, 5 to 10% water and less than 3% lipids. The mineral content is mostly hydroxyapatite with small amounts of carbonate, magnesium and acid phosphate. Bone mineral provides mechanical rigidity and load bearing strength and organic matrix provides elasticity and flexibility (Clarke 2008).

Matrix maturation is associated with expression of alkaline phosphatase and non-collagenous proteins including osteocalcin, osteopontin and bone sialoprotein that are present in bone. These calcium and phosphate binding proteins may help regulate ordered deposition of mineral by regulating the size of hydroxyapatite crystals formed (Clarke 2008). Confirmed mineralisation promoters include dentin matrix protein 1 and bone sialoprotein. Vitamin D has an indirect role in stimulating mineralisation of unmineralised bone matrix and is responsible for maintaining serum calcium and phosphorus in adequate concentrations to allow passive mineralisation of unmineralised bone matrix (Clarke 2008).

5.1.3.3 The Alveolar Process

The alveolar process consists of the jaw bone that houses the sockets for the teeth. It includes the buccal and oral cortical plates of compact bone, and central spongiosa and bone lining the alveolus. The cortical plate and the bone lining the alveolar sockets meet at the alveolar crest (Nanci and Bosshardt 2006; Cho and Garant 2000).

The alveolar wall has a double fibre orientation and is known as bundle bone and provides attachment for the PDL fibre bundles. The bundle bone consists of Sharpey's fibres (which become mineralised once they insert into bone) and bone laid down by osteoblasts between the Sharpey's fibres which is irregularly arranged and less dense (Saffar et al. 1997). Bundle bone covers the entire socket so that the supporting bone never contacts the PDL. Alveolar bone must respond to the functional demand placed on it by the forces of mastication so the bone of the socket wall is constantly remodelled

and its structural organisation varies along the wall (Saffar et al. 1997; Cho and Garant 2000; Nanci and Bosshardt 2006). In humans this layer of bundle bone is 100 - 200µm thick (Saffar et al. 1997).

The cortical plates consist of surface layers (lamellae) of bone supported by Haversian systems and the central part of the alveolar process is occupied by trabecular (or spongy) bone. Inter-trabecular spaces can be filled by yellow marrow, rich in adipose cells, and there may also be some red or hematopoietic marrow. In the region of the anterior teeth the cortical plate and alveolar bone are fused together with the absence of trabecular bone (Nanci and Bosshardt 2006).

5.1.3.4 Cellular Components

Bone is a living tissue which is created and maintained by three major cell types – osteoclasts, osteoblasts and osteocytes.

5.1.3.4.1 Osteoclasts

Osteoclasts resorb the mineralised extracellular matrix (ECM) of bone and arise from haemopoietic precursors that also give rise to macrophages. The precursor cells are recruited to the bone surface where they fuse to form multinucleated cells (Takahashi et al. 2008). Osteoclasts are rare in bone and only 2-3 cells per µm of bone are found (Jähn and Bonewald 2012). Active osteoclasts reside in specialised cavities on the bone surface known as Howship's lacunae. They have a ruffled border consisting of finger-like cytoplasmic projections that is turned to the bone surface (Roodman 1996). The osteoclast seals the cavity with its ruffled border and secretes proteins and proteolytic enzymes to break down the organic bone ECM (Hill 1998). Within the ruffled border the pH is reduced to 2-3 which enhances the mineral degradation (Roodman 1996). The sole function of these cells is to resorb bone. A mature osteoclast can be described histologically as a multinucleated, tartrate resistant, acid phosphatase (TRAP) positive cell with the presence of a resorption lacunae or 'pit' on a mineralised surface (Jähn and

Bonewald 2012). Osteoclast precursors require supporting factors for osteoclast formation such as macrophage colony-stimulating factor (M-CSF) (Kodama et al. 1991).

Although TRAP is expressed in a variety of other tissues including the gut, kidney, and lung, bone appears to express the highest levels of TRAP among normal tissues. As such, TRAP can serve as a marker enzyme for osteoclasts in bone (Roodman 1996).

5.1.3.4.2 Osteoblasts

Osteoblasts are the cells that form bone by secreting a type I collagen-rich ECM that eventually undergoes mineralisation. At least 4-5 maturation stages of the osteoblast cell lineage are commonly accepted: Pre-osteoblasts (immature osteoblasts), mature osteoblasts, osteoid osteocytes, early osteocytes and mature osteocytes (which are the terminally differentiated osteoblast embedded in the bone matrix) (Aubin 2008). Lining cells on the bone surface are also considered terminally differentiated osteoblasts but their lineage is not yet completely validated (Jähn and Bonewald 2012).

Osteoblasts arise from multipotent progenitor cells of mesenchyme origin, mesenchymal stem cells. These progenitor cells have the ability to also differentiate into chondrocytes or adipocytes under the appropriate conditions (Friedenstein et al. 1987). The osteoprogenitors are found in the periosteum, endosteum and the marrow stroma (Aubin 2008). The mature osteoblast has a cuboidal or polygonal shape with abundant endoplasmic reticulum and enlarged golgi apparatus (Jähn and Bonewald 2012).

Bone lining cells are of interest due to their controversial origin. They are thought to be resting osteoblasts, pre-osteoblasts or post-osteoblasts. They have been acknowledged as active cells that participate in bone resorption and formation and may be involved in haemostatic processes as a result of their communication with the osteocyte network and are an element of the strain sensing network (Jähn and Bonewald 2012). They could also be a source for active osteoblasts and reservoir for pre-osteoblasts if subjected to the right stimulus. For example, rats treated with parathyroid hormone

(PTH) led to the reactivation of bone lining cells to bone-forming osteoblasts (Dobnig and Turner 1995).

5.1.3.4.3 Osteocytes

Osteocytes have a very unique location in bone. They are trapped within spaces in bone called lacunae and their dendritic processes extend through small tunnels or canaliculi that connect the entire bone volume. Osteocytes compose 90% to 95% of all bone cells in adult bone and are the longest-lived bone cell, able to survive decades within their mineralised environment (Bonewald 2011).

Osteocytes are the terminally differentiated cell of the osteoblast lineage (Bonewald 2011). Osteoblasts synthesise osteoid, an unmineralised bone matrix composed of collagen and other organic components (Knothe Tate et al. 2004). The transformation from osteoblast to entrapped osteocyte takes about 3 days during which time the cell produces three times its own cell volume of extra-cellular matrix (Palumbo 1986). The differentiating osteoblasts undergo a significant morphological change as they become embedded in the ECM. The most significant of these changes include the development of long slender cell processes, the loss of many cytoplasmic organelles and the transformation into a stellate-shaped cell (Aubin 2008). In the transition from osteoblast to osteocyte a number of cellular markers are expressed (Figure 3). Matrix-producing osteoblasts express *Cbfa1* and *Osterix* which are necessary for osteoblast differentiation. This is followed by alkaline phosphatase and collagen, necessary for the production of osteoid. Osteocalcin is produced by the late osteoblast and the osteocyte and differentiation to a mature osteocyte may be indicated by expression of sclerostin (Bonewald 2011).

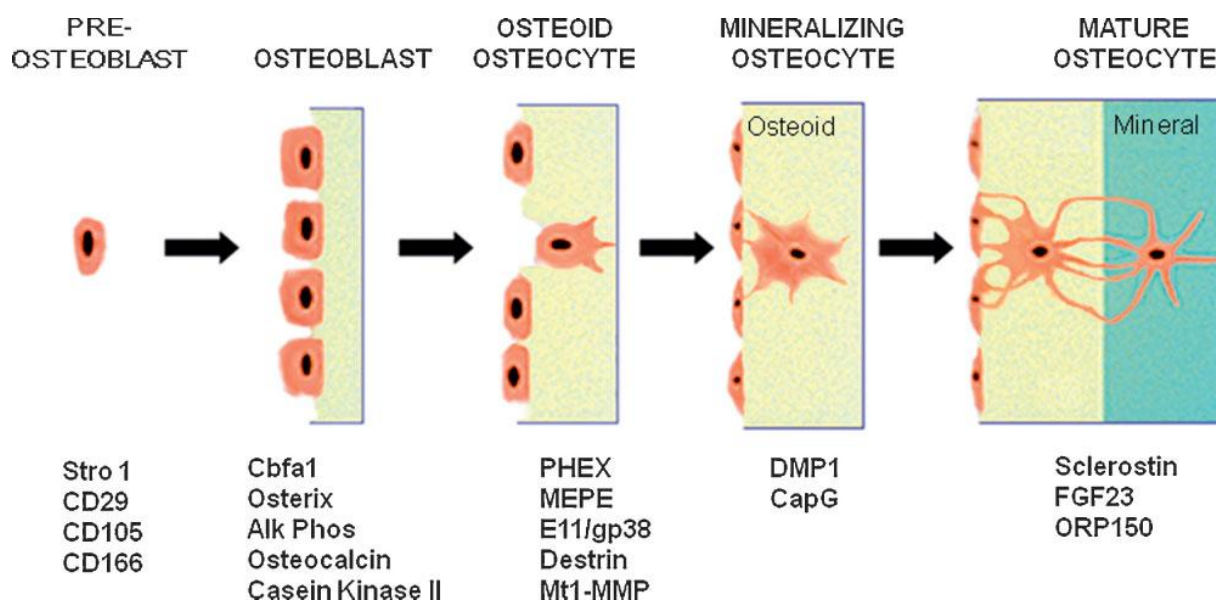


Figure 3. Expression of markers during osteoblast-to-osteocyte ontogeny
 [Adapted from (Bonewald 2011)].

Osteocyte processes make up a complex network that connects mature osteocytes to each other and to the osteoblasts lining the bone surface at the mineralising face (Figure 4) (Kamioka et al. 2001; Klein-Nulend and Bonewald 2008). Osteocytes also appear to be able to retract and extend their dendritic processes (Kamioka et al. 2001). A limited number of processes have been shown to reach the vascular facing surface of the osteoblast layer (Kamioka et al. 2001) and dynamic imaging of osteocytes has demonstrated dendritic processes extending into marrow spaces (Veno et al. 2006). On average 4.8 osteocyte processes contact one osteoblast (Kamioka et al. 2001). Osteoblasts closest to osteoid-osteocytes contain numerous processes and osteoblasts farther away contain only a few processes. It is rare to see an osteoblast connect with more than one osteocyte (Kamioka et al. 2001). Osteocytes communicate via gap junctions at the end of the processes (Doty 1981).

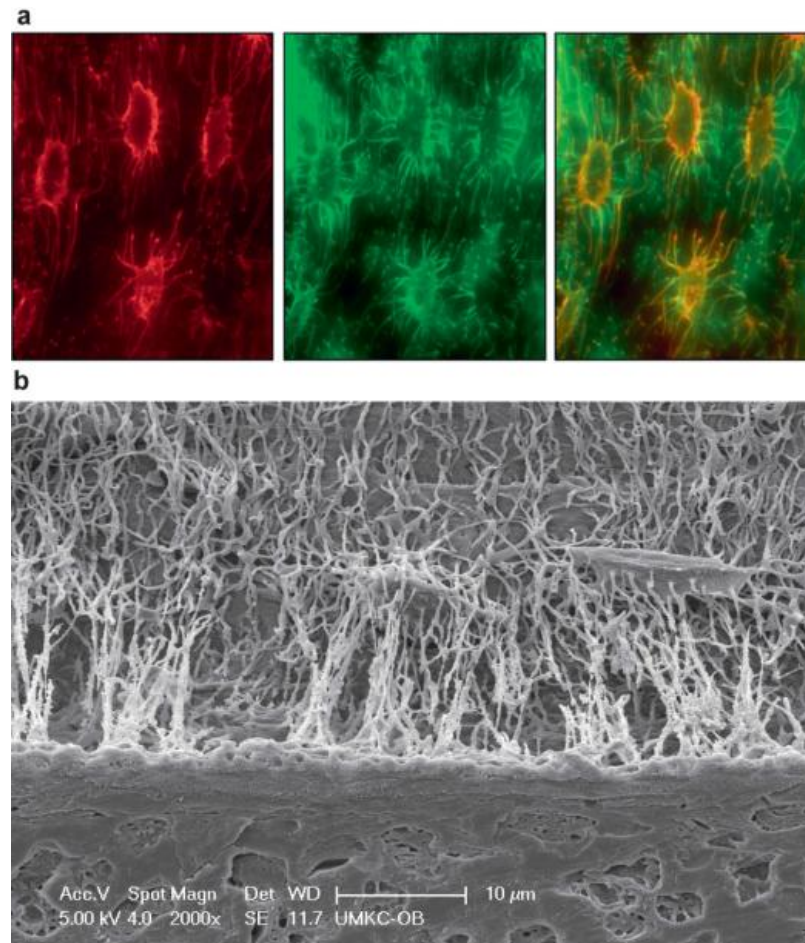


Figure 4. Visualisation of early embedding osteocytes in 12-day murine calvaria Immunofluorescent staining (a) and an acid-etched resin embedded sample visualised by transmission electron microscopy (b) illustrates the complexity of the osteocyte network and their interface with the bone surface. [Adapted from (Bonewald 2011)]

Mechanical stimulation may also induce cell signaling (Jähn and Bonewald 2012). The most commonly accepted theory as to how this occurs is load-induced fluid flow (Knothe Tate 2003) where interstitial fluid is squeezed through the porous ECM and the lacunar-canalicular system in response to bone deformation by physiological loading. The shear stresses then act on the outer structure of the osteocyte (Jähn and Bonewald 2012). Molecules involved in mechanotransduction in bone include nitric oxide, adenosine triphosphate (ATP), prostaglandin (PGE₂) and calcium (Jähn and Bonewald 2012).

Osteocytes are multi-functional and have a role in mineral homeostasis, regulating both calcium and phosphate availability (Klein-Nulend and Bonewald 2008; Bonewald 2011). The osteocyte has also been identified as the orchestrator of bone formation and resorption with the discovery of sclerostin, which inhibits osteoblastic bone formation (Winkler et al. 2003). Osteocytes can also support osteoclast formation via the production of RANKL and OPG (Kramer et al. 2010).

One osteocyte cell line has been generated for experimental study of osteocyte function, the MLO-Y4 cell. This cell line has dendritic processes and is very similar to primary osteocytes (Kato et al. 1997; Bonewald 1999). The role of the osteocyte in bone homeostasis and remodelling will be examined in more detail in a later section.

5.2 The Bone Remodelling Cycle

Bone is a dynamic tissue that is constantly formed and resorbed in response to changes in mechanical loading, serum calcium levels and a variety of paracrine and endocrine factors (Clarke 2008). The ability of alveolar bone to remodel rapidly allows the physiological drift of teeth which accompanies jaw development and also allows teeth to be re-positioned in response to functional and applied forces (Sodek and McKee 2000). The constant remodelling of bone ensures correct mineral homeostasis and maintenance of the bone's structural integrity and strength. This remodelling is achieved by a co-ordinated action of osteoclasts and osteoblasts and also from osteocytes embedded in bone matrix and osteoblast-derived lining cells that cover the surface of the bone. The co-ordinated action of these cells together is termed the "Basic Multicellular Unit" (BMU). The cellular activity within the BMU is matched or 'coupled' so that the amount of bone destroyed by osteoclasts matches that formed by osteoblasts (Sims and Gooi 2008). The sequential, cyclical manner in which bone remodelling occurs is often referred to as the Activation-Resorption-Formation (ARF) cycle (Henriksen et al. 2009). The stages of the bone remodelling cycle will be considered in further detail and the process is summarised in Figure 5.

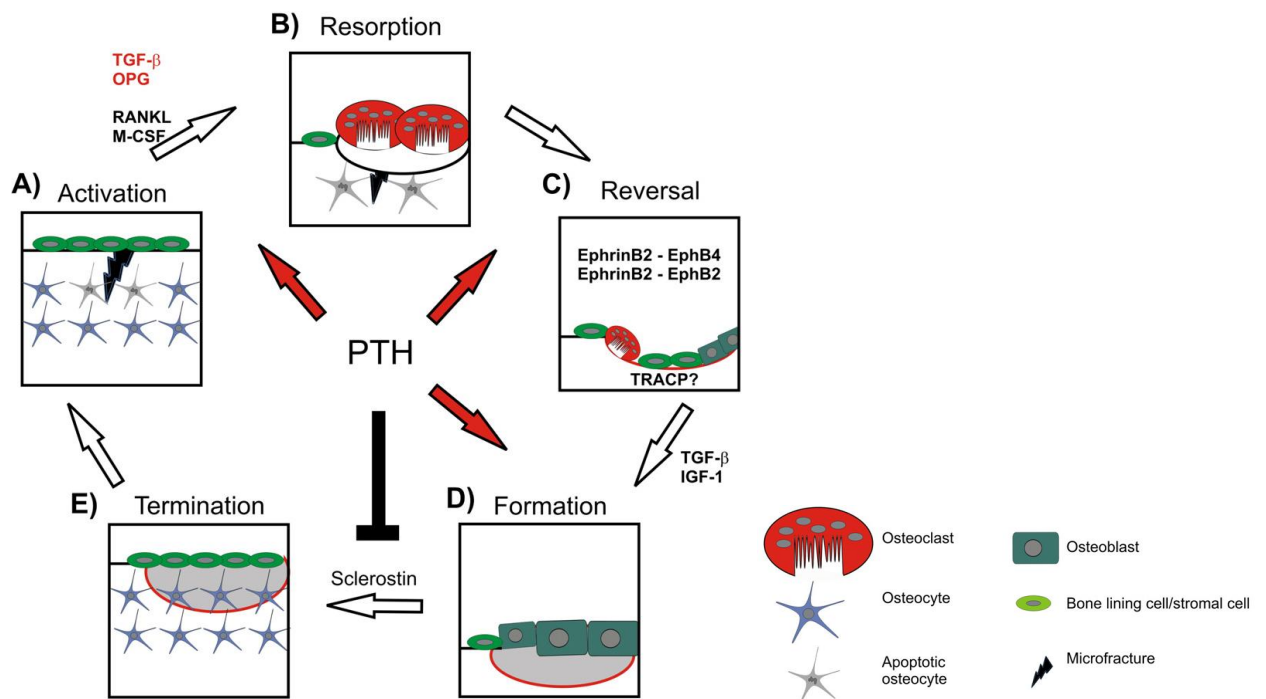


Figure 5. Schematic illustration of the local communication mechanisms involved in the remodelling of bone.

(A) Activation. Microcracks lead to osteocyte death and production of pro-osteoclastic signals or removal of inhibitory signals directly in the osteocytes or indirectly involving activation of RANKL and M-CSF production by the bone lining cells. Anti-osteoclastic cytokines OPG and TGF-β regulate the number of osteoclasts. (B) Osteoclasts resorb bone whilst producing signals that lead to initiation of; (C) the reversal phase, which involves cleaning of the resorption pit by bone lining cells followed by bone formation. Direct cell-to-cell contact through the Ephrin–Eph signaling may be important in this phase. (D) Bone lining cells differentiate into bone forming osteoblasts or are replaced by these through a process also controlled by osteoclast derived molecules (IGF-I, TGF-β). (E) When bone formation is complete secretion of sclerostin by the newly generated osteocytes may terminate the cycle leading to a resting state, where bone lining cells again cover the bone surface. PTH appears to be involved in the regulation of most steps in the cycle, i.e. it stimulates production of RANKL, EphrinB2–EphB2 signaling, works through IGF-I (red arrows) and finally reduces sclerostin expression (black repressor) by osteocytes. [from (Henriksen et al. 2009)]

5.2.1 Activation of the remodelling cycle

Evidence shows that osteocytes may be the central regulatory cell of the remodelling process. They play an important role in their response to mechanical stresses which create microcracks in bone. The osteocytes respond to mechanical stress by undergoing apoptosis which has been shown experimentally in osteocytes near the microcrack (Verborgt et al. 2000; Verborgt et al. 2002). It is this loss or damage of osteocytes that appears to be essential for osteoclastogenesis and increased resorption (Noble et al. 2003; Gu et al. 2005; Kurata et al. 2006; Henriksen et al. 2009).

5.2.2 Bone resorption

5.2.2.1 Osteoclast formation

For bone remodelling to begin, osteoclasts must be formed by the attraction of haemopoietic myelomonocytic precursors to the resorption site. Fusion of the mononuclear precursors occurs and the resultant multinucleated cell attaches to the bone surface to conduct its resorptive function. The osteoblast lineage plays a vital role in the control of this process (Henriksen et al. 2009).

Osteoclast formation may be initiated by a multitude of factors released from nearby cells (pre-osteoblasts, osteoblasts, lining cells, osteocytes) (Sims and Gooi 2008). Cytokines that stimulate osteoclast formation may also be released from immune cells within the bone marrow, although these must work through the osteoblast lineage cells (Sims and Gooi 2008). Most signalling mechanisms converge to a common mechanism to promote osteoclast formation which requires receptor activation of NF- κ B ligand (RANKL) as the essential mediator (Dougall et al. 1999). RANKL interacts with its receptor (RANK) which is expressed on the mononuclear haemopoietic osteoclast precursors to initiate osteoclast formation. Experiments have shown that mice lacking RANKL or RANK have few osteoclasts and severe osteopetrosis, indicating the critical importance of this interaction in osteoclast formation (Dougall et al. 1999).

The osteoblast is also responsible for the production of the non-signalling decoy receptor osteoprotegerin (OPG) which is a soluble member of the tumour necrosis factor (TNF) receptor super-family. It effectively inhibits osteoclast formation by binding to RANKL thereby preventing RANKL binding to RANK (Simonet et al. 1997). Osteoblasts, can therefore, regulate the formation of osteoclasts through the modulation of RANKL and OPG expression.

Another osteoblast-secreted factor required for osteoclast formation is macrophage colony stimulating factor-1 (M-CSF). A lack of M-CSF causes osteopetrosis in mice (Kodama et al. 1991; Hattersley et al. 1991). M-CSF is reported to act directly on osteoclast precursors but by itself cannot support osteoclast differentiation (Kodama et al. 1991). The main role of M-CSF in osteoclastogenesis is to stimulate cell survival and proliferation and to induce RANK expression (Arai et al. 1999).

5.2.2.2 Osteocyte control of osteoclastogenesis

It has been demonstrated that osteocytes secrete RANKL and M-CSF which would enable them to support osteoclastogenesis (Zhao et al. 2002). Recent research demonstrates that the role of the osteocyte is far from insignificant and has a central role in bone metabolism that warrants further investigation.

A number of studies have examined the role of osteocyte signalling following apoptosis. Verborgt and colleagues (2002), studied the expression of Bax, a pro-apoptotic gene product, and Bcl-2, an anti-apoptotic gene product in a rat model of fatigued bone. The results demonstrated that Bax and Bcl-2 in osteocytes were expressed differently as a function of distance from microdamage sites. The peak of the pro-apoptotic gene product was at the location of the microcrack whereas the anti-apoptotic gene product was at its greatest some distance from the damage. The study concluded that osteocytes near sites of micro-injury that do not undergo apoptosis are prevented from doing so by active protective mechanisms. The zone of apoptotic osteocytes near the

injury were surrounded by surviving osteocytes actively expressing the anti-apoptotic gene product, Bcl-2. The expression of these gene products may provide important signals in the guidance of resorption that occurs in association with osteocyte apoptosis following fatigue (Verborgt et al. 2002).

Apoptotic osteocytes could regulate osteoclastogenesis either directly (directly impacting osteoclast precursors) or indirectly (acting upon neighbouring healthy osteocytes that in turn impact osteoclast precursors). Al-Dujaili and colleagues (2011) used an in vitro conditioned medium based model and the MLO-Y4 cell line to delineate between the direct and indirect effects of osteocytes subject to serum starvation. The results indicated that apoptotic osteocytes regulated osteoclasts directly through soluble RANKL secretion and indirectly by M-CSF and VEGF secretion by neighbouring healthy osteocytes (Al-Dujaili et al. 2011). It appears that osteocytes have a role in the direct and indirect stimulation of osteoclast precursor recruitment and differentiation.

This division of labour between osteocyte populations was also reinforced by Kennedy et al. (2012). The experiment used cyclic loading of rat ulnae to induce bone fatigue. Expression of genes associated with osteoclastogenesis (RANKL, OPG, VEGF) and apoptosis (caspase-3) were assessed by qPCR. RANKL expression was low or absent in adult cortical bone osteocytes but was induced by injury. The results of the experiment demonstrated a spatial and temporal relationship between injury, osteocyte apoptosis and pro-osteoclastogenic signalling in response to fatigue-induced microdamage. Osteocyte apoptosis triggers a bone remodelling response following microdamage but it is the neighbouring non-apoptotic osteocytes that are the main source of the pro-osteoclastogenic signals exhibiting upregulated expression of RANKL and VEGF and decreased expression of OPG (Kennedy et al. 2012).

The size of the injury could also be critical in affecting the initiation of bone remodelling. An increase in microcrack size resulted in a proportionately greater release of RANKL and a decrease in OPG initially following the injury (Mulcahy et al. 2011). The high

levels of RANKL were indicative of the instigation of bone resorption (Mulcahy et al. 2011).

Osteocytes play an important role in maintaining the mineralising function of mature osteoblasts (Tatsumi et al. 2007). To investigate this Tatsumi and colleagues (2007) used targeted expression of diphtheria toxin (DT) receptor in a transgenic mouse model and selectively ablated osteocytes (Tatsumi et al. 2007). This resulted in the death of 70-80% of the osteocytes which was enough to cause a serious malfunction of the osteocyte network although osteoblasts remained intact. After eight days the transgenic mice demonstrated regions of empty lacunae, TRAP-positive osteoclasts and ALP-positive osteoblasts present in the cavities excavated by the osteoclasts. There were no change in the number of osteoblasts but the mineralising function of these cells was significantly reduced following the osteocyte ablation. The presence of unmineralised matrix, an increase in the osteoid surface of trabecular bone and micro-fractures in the cortical bone were observed (Tatsumi et al. 2007).

Osteocytes are also critical for the maintenance of structural integrity and mechanical competence of cortical bone. Forty days after DT receptor administration the bone strength was compromised with the continued presence of empty lacunae, thin cortical bone, increased intracortical porosity and microstructural changes in the trabeculae (Tatsumi et al. 2007). The changes following osteocyte ablation appeared to be reversible. Ninety days after DT receptor administration normal osteocytes resided in most lacunae and trabecular bone volume and bone strength returned to control levels (Tatsumi et al. 2007).

Tatsumi et al (2007) also used RT-PCR to conduct a gene analysis. It was found that mRNA for RANKL increased in transgenic mice two days after injection with DT. This suggested that osteocytes may control osteoclast differentiation indirectly through modulation of RANKL expression in osteoblasts. Osteocytes contact osteoblasts and lining cells on the bone surface via gap junctions and this cell to cell contact may

normally retrain RANKL gene activation from aberrant activation. When the osteocyte network is disrupted this may result in aberrantly elevated RANKL expression and osteoclastogenesis (Tatsumi et al. 2007). The gene analysis also revealed that the expression of sclerostin (a negative regulator of osteoclastic bone formation) mRNA decreased markedly following osteocyte ablation, which would cause stimulation of bone formation (Tatsumi et al. 2007). It is possible that in addition to negative regulators such as sclerostin, that one or more positive regulators are produced by osteocytes to maintain the mineralising function of osteoblasts. DMP1 and FGF-23 are osteocyte-derived factors that regulate mineralisation and phosphate homeostasis and their expression was also reduced in this model. The authors concluded that further studies are required to identify osteocyte products that regulate osteoblastic as well as osteoclastic activities (Tatsumi et al. 2007).

By using tail suspension or hind limb elevation, unloading can be simulated in mice (Bikle and Halloran 1999). Tatsumi et al. (2007) used the model of osteocyte ablation to study the role of osteocytes in mechanotransduction. Results showed that control mice lost a substantial portion of trabecular volume during a one week period of tail suspension; however, the osteocyte deficient mice were resistant to the unloading-induced bone loss. This suggested that the presence of osteocytes is essential for mechanotransduction in bone (Tatsumi et al. 2007). The osteocyte ablated mice showed no increase in RANKL and OPG mRNA during tail suspension in contrast to controls. This suggested that the increase in RANKL expression in osteoblasts during unloading did not occur in the absence of osteocytes and is illustrated in Figure 6. Sclerostin mRNA increased during tail suspension but did not in the osteocyte-ablated mice (Tatsumi et al. 2007).

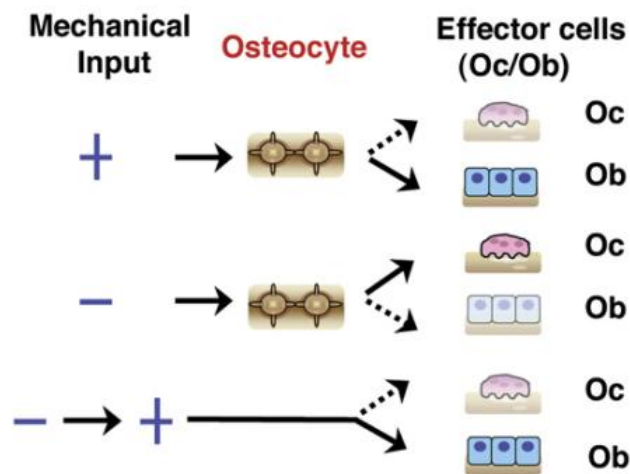


Figure 6. Proposed roles of osteocytes under different mechanical conditions

Under normal loading conditions (mechanical input +), osteocytes function to keep osteoclastic (Oc) bone resorption in check and to maintain mineralisation by osteoblasts (Ob). Thus, when osteocytes are ablated, atypically elevated bone resorption with impaired mineralisation takes place. In response to unloading (mechanical input -), osteocytes execute the stimulation of bone resorption and suppression of bone formation, resulting in marked bone loss and micro-structural deterioration in a short period. When osteocytes are ablated specifically during tail suspension, those changes do not take place, and bone is resistant to disuse-induced atrophy. During reloading experiments following unloading (mechanical input -/+), it is suggested that osteocytes are dispensable for this recovery phase and that osteoclasts (Oc) and osteoblasts (Ob) respond to the reloading stimulus, bypassing osteocytes, with reversal of elevated bone resorption and release from suppressed bone formation, respectively.

[Adapted from (Tatsumi et al. 2007)]

5.2.2.3 Attraction of precursors and attachment to the bone surface

Osteoblasts also govern osteoclast differentiation by controlling the attraction of osteoclast precursors towards each other (to result in fusion) and towards the bone surface (attachment) via the release of chemo-attractants. These may be deposited in bone matrix itself during formation, may be derived from active osteoblasts, or be released from apoptotic osteocytes (Sims and Gooi 2008). When the bone is demineralised in the first stage of bone resorption, bone matrix-derived factors such as α_2 HS glycoprotein and osteocalcin are released. There has been experimental evidence to suggest that these factors, along with collagen I fragments attract monocytic osteoclast precursors to the bone site (Malone et al. 1982). Osteocalcin and collagen I are also secreted by the osteoblast during osteoid formation and are involved in regulating mineralisation (Sims and Gooi 2008). However, when osteocalcin knockout mice are examined there is no osteoclast defect present and bone resorption occurs normally (Ducy et al. 1996).

5.2.2.4 Preparation of the bone surface

Bone-lining cells are essential to allow migration of osteoclast precursors, their fusion and attachment to the bony surface (Everts et al. 2002). These cells were initially thought to belong to the monocyte/macrophage lineage; however Everts and colleagues demonstrated that they belong to the osteoblast lineage (Everts et al. 2002) and are usually described as terminally differentiated osteoblasts.

Cytokines and prostanoids act to stimulate the bone lining cells to digest the thin layer of osteoid (non-mineralised matrix) via the release of collagenase. As a result the mineralised matrix is now exposed for osteoclastic resorption (Chambers et al. 1985). Hauge and colleagues described a specialised structure; the bone remodelling compartment (BRC) which forms after site selection osteoid degradation, when the lining cells separate from the underlying osteocytes (Hauge et al. 2001) possibly by a disruption of the gap junctions between their processes (Parfitt 2001). The resulting

BRC is a sinus that is lined on one side (marrow side) by flattened cells of osteoblastic origin and on the other (osseous side) by the remodelling surface, forming a canopy over the remodelling area. It is suggested that due to the vascularity of the BRC that osteoclasts may arrive through the circulation (Parfitt 2001), although there is still some uncertainty in this area. In particular, the arrival of the osteoblasts is mysterious due to their stromal origin.

5.2.3 The reversal phase

Once osteoclasts have resorbed the bone and have detached from the bone surface, remnants of demineralised non-digested bone collagen are left behind (Everts et al. 2002). Bone lining cells are essential to remove these remnants before new bone is formed. Lining cells move into resorption pits, possibly as a result of the action of the cysteine proteinases and matrix metalloproteinases (MMPs) and complete the process of bone resorption. This occurs by a degradation of the remaining demineralised collagen matrix and a modification of the bone surface within the resorption pits and the formation of a 'reversal' or 'cement' line represented by a thin layer of fibrillar collagen on the cleaned surfaces (Everts et al. 2002). In vitro studies have shown that osteoblasts or their precursors preferentially form bone in resorption pits (Gray et al. 1996; Jones et al. 1994) and that demineralisation promotes the proliferation of osteoblasts (Schwartz et al. 2000).

5.2.4 Bone formation

5.2.4.1 Osteoclastic control

There is evidence which suggests that during the reversal phase osteoclasts could initiate osteoblast differentiation and subsequent bone formation through the contact-dependent action of osteoclast-mediated expression of Ephrin B2 (a membrane-bound ligand) on EphB4, its receptor in the osteoblast. Signalling in the other direction (originating from the osteoblast) leads to a suppression of osteoclast differentiation (Zhao et al. 2006).

When bone matrix is resorbed by osteoclasts, factors that were embedded in bone matrix during formation are released. The osteoclast can activate selected factors which may then stimulate the osteoblast and bone formation (Sims and Gooi 2008). These factors include insulin-like growth factor (IGF) I and II, acidic and basic fibroblast growth factor (FGF), transforming growth factor β (TGF β) 1 and 2, bone morphogenic proteins (BMPs) 2, 3, 4, 6 and 7 and platelet-derived growth factor (PDGF) (Sims and Gooi 2008). The amount of bone resorbed determines the concentration of the released factors; however the concentration of these factors in the matrix was previously determined by the osteoblasts in their last remodelling cycle.

The important role of the osteoclast in osteoblast function can be demonstrated experimentally in mice. Colony-stimulating factor-1 receptor (CSF-1R) signalling is essential for osteoclastogenesis and *Csf1r*^{-/-} osteopetrotic mice show a significant osteoclast deficiency. The osteoblasts in these mice were shown to also be negative for CSF-1R. The *Csf1r*^{-/-} mice showed bone defects developing later than the development of osteoclasts in normal embryos and the transplanted *Csf1r*^{-/-} femoral anlagen developed normally in the presence of wild type osteoclasts. It is suggested that this is caused by a deficiency of the osteoclast-mediated regulation of osteoblasts (Dai et al. 2004).

5.2.4.2 Osteoblastic Control

Osteoblast differentiation and deposition of osteoid is also controlled by cells of the osteoblast lineage. Osteoblasts communicate via gap junctions and also membrane-bound and secreted factors. There are many factors but those of importance include ephrins, parathyroid hormone-related protein (PTHrP) and sclerostin (encoded by the SOST gene). The interaction of ephrinB2 with the EphB4 receptor has been shown to stimulate osteoblast differentiation via signalling from the osteoclast (Zhao et al. 2006). Recent research has demonstrated that parathyroid hormone (PTH) or PTHrP may regulate ephrinB2 to act in a paracrine or autocrine manner on EphB4 or EphB2 in the osteoblast. It has been demonstrated that the production of mRNA for ephrinB2 is increased by PTH and PTHrP in a dose-dependent manner. This will then favour osteoblast differentiation and bone formation (Allan et al. 2008). Circulating PTH is known to act as a systemic regulator of bone remodelling mainly in response to hypocalcaemia. PTHrP is a paracrine factor and is produced by pre-osteoblasts and bone marrow cells. Both act on pre-osteoblasts and osteoblasts through the PTH1R to promote osteoblast differentiation and inhibit apoptosis. PTHrP is also a stimulus of RANKL production (Sims and Gooi 2008).

5.2.5 Termination of the remodelling cycle

As the remodelling cycle ends osteoblasts differentiate into bone lining cells which remain on the bone surface or into osteocytes becoming embedded in the bone matrix. Bone matrix mineralisation continues which is dependent on osteocyte signaling (Sims and Gooi 2008). When the matrix is sufficiently mineralised it is presumed to be stable until a signal from within the matrix or from the cells on or near the bone surface trigger the cycle to begin again (Sims and Gooi 2008). A key development in recent years is the discovery of sclerostin which is encoded by the SOST gene and inhibits bone formation (Winkler et al. 2003). The role of this important protein is covered in detail in a later section.

5.3 The OPG/RANK/RANKL Triad

In 1965, Epker and Frost demonstrated that interactions between osteoblasts and osteoclasts are essential for bone remodelling. This equilibrium is tightly regulated by physical parameters and polypeptides and any disturbance in this equilibrium can lead to the development of skeletal abnormalities. It has been demonstrated experimentally that cell-cell contact is required between osteoblasts and osteoclasts in order for osteoblasts to induce osteoclastogenesis. The requirement of an osteoblastic stromal cell factor or factors that mediated osteoclastogenesis was hypothesised. In 1997 and 1998, four groups, working independently identified the novel set of cytokines within the TNF family that are required for bone remodelling. Whilst there are many synonyms in use (Table 1) these three important factors are osteoprotegerin (OPG), receptor activator of NF- κ B (RANK) and RANKL (RANK ligand).

5.3.1 Discovery of the molecular triad OPG/RANK/RANKL

Researchers in the Amgen group discovered the naturally occurring inhibitor of RANKL when work was being conducted on transgenic mice in an attempt to find molecules that could interfere with TNF signalling. It was observed that mice over-expressing a particular cDNA, developed osteopetrosis due to a lack of osteoclasts (Simonet et al. 1997). The bone protecting molecule was named osteoprotegerin (OPG). Independent from this work and at the same time, Yasuda and colleagues at the Snow Brand Milk Products Co. in Japan discovered a molecule when screening osteoclast inhibitory and stimulatory factors (Yasuda et al. 1998). This molecule inhibited osteoclastogenesis in bone marrow stromal cells by interfering in the interaction of stromal cells with osteoclasts which suppressed osteoclast survival (Akatsu et al. 1998). They named this factor osteoclastogenesis inhibitory factor (OCIF) and subsequent analysis (Akatsu et al. 1998; Lacey et al. 1998; Yasuda et al. 1998; Mizuno et al. 1998) has shown OPG and OCIF to be identical. OPG was shown to suppress osteoclast activity, survival and adhesion to bone surfaces (Kearns et al. 2008).

Table 1. Acronyms and synonyms for proteins from the OPG/RANKL/RANK pathway. Items in *italics* are the American Society for Bone and Mineral Research (ASBMR) preferred terms [adapted from (Kearns et al. 2008)]

Acronym	Synonym
Ligand	
<i>RANKL</i>	<i>RANK ligand</i>
OPGL	Osteoprotegerin ligand
ODF	Osteoclast differentiation factor
TRANCE	TNF-related activation-induced cytokine
SOFA	Stromal osteoclast-forming activity
TNFSF-11	TNF superfamily 11
Receptor	
<i>RANK</i>	<i>Receptor activator of NF-κB</i>
ODAR	Osteoclast differentiation and activation receptor
TNFRSF-11A	TNF superfamily receptor 11A
Decoy Receptor	
<i>OPG</i>	<i>Osteoprotegerin</i>
OCIF	Osteoclastogenesis inhibitory factor
TR-1	TNF receptor-like molecule 1
FDCR-1	Follicular dendritic receptor 1
TNFRSF-11B	TNF superfamily receptor 11B

Soon after the discovery of OPG, both groups, using OPG as a probe, identified its ligand, called OPG ligand (OPGL) and osteoclast differentiation factor (ODF) respectively (Yasuda et al. 1998; Lacey et al. 1998). This protein was identical to two previously described molecules: TNF-related activation induced cytokine (TRANCE) (Wong et al. 1997a; Wong et al. 1997b) and receptor activator of NF- κ B ligand (RANKL) (Anderson et al. 1997).

The receptor identified to mediate RANKL activity has been termed receptor activator of nuclear factor $\kappa\beta$ (RANK). RANK was discovered through sequencing cDNAs from a human bone-marrow-derived myeloid dendritic-cell cDNA library (Dougall et al. 1999). The essential role for RANK in bone resorption was identified by the high bone mass phenotype of RANK-knockout mice that were almost devoid of osteoclasts (Dougall et al. 1999). RANK and RANKL-knockout mice were virtual phenocopies of each other, indicating that they had few, if any roles beyond their mutual interactions (Kearns et al. 2008).

Research has led to the consensus that, in this molecular triad, OPG functions as a soluble decoy receptor by binding to RANKL, thereby preventing RANKL from binding and activating RANK (Figure 7). OPG inhibition of RANKL leads to the rapid arrest of osteoclast formation, attachment to bone, activation and survival.

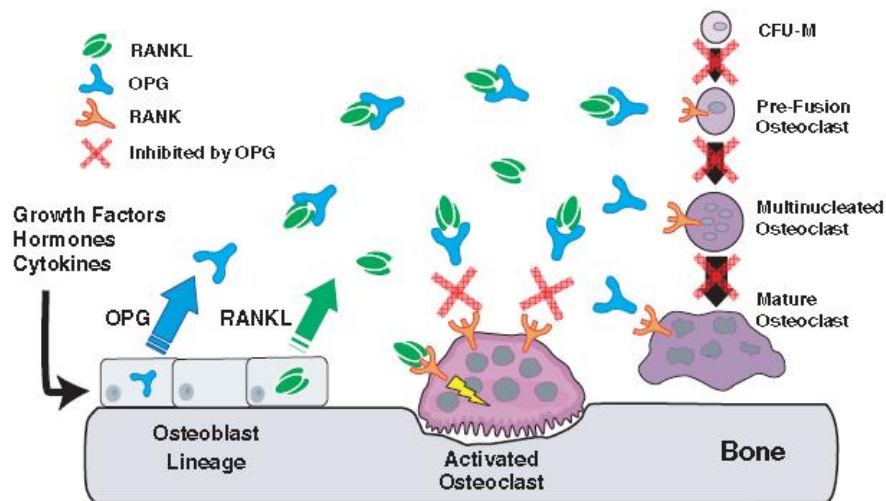


Figure 7. Mechanisms of action for OPG, RANKL and RANK

RANKL is produced by osteoblasts, bone marrow stromal cells, and other cells under the control of various pro-resorptive growth factors, hormones, and cytokines. Osteoblasts and stromal cells produce OPG, which binds to and thereby inactivates RANKL. In the absence of OPG, RANKL activates its receptor RANK, found on osteoclasts and preosteoclast precursors. RANK-RANKL interactions lead to preosteoclast recruitment, fusion into multinucleated osteoclasts, osteoclast activation, and osteoclast survival. Each of these RANK-mediated responses can be fully inhibited by OPG. [From (Kearns et al. 2008)]

5.3.1.1 OPG

OPG is an atypical member of the TNF receptor family in that it is a secreted protein with no transmembrane domain and no direct signalling properties (Simonet et al. 1997). OPG contains four cysteine rich TNF receptor homologous domains that are necessary and sufficient for binding to its target, RANKL. It also includes two death domain homologous (DDH) regions, the roles of which are unknown. OPG also possesses a heparin-binding domain that may limit its circulating half-life in mice, perhaps via binding to cell surfaces (Kearns et al. 2008).

OPG has been shown to be produced by numerous tissues and associated cells in addition to osteoblasts. The production of OPG by cultured osteoblasts was shown to increase with cell differentiation, suggesting that mature osteoblasts are not well suited to support osteoclastogenesis (Gori et al. 2000). Other cells that produce OPG include endothelial cells (Collin-Osdoby et al. 2001), vascular smooth muscle cells (Olesen et al. 2005) and fibroblasts in the synovial tissue (Haynes 2003).

Its production is stimulated by treatment with bone morphogenic protein, IL-1, TNF- α , TNF- β , vitamin D and oestrogen (Brändström et al. 1998; Hofbauer et al. 1998; Hofbauer et al. 1999; Vidal et al. 1998). Its secretion is suppressed by prostaglandin E₂, glucocorticoids, and PTH (Brändström et al. 1998; Lee and Lorenzo 1999; Vidal et al. 1998).

The importance of OPG in the regulation of bone remodelling was shown by Simonet and colleagues (Simonet et al. 1997) and their investigations in mice over-expressing OPG. The mice had a severe osteopetrosis that presented early after birth and progressively worsened. Interestingly and in contrast to other osteopetrotic animals, the affected mice had normally shaped and sized bones and tooth eruption was normal. Histologically, the animals showed a marked reduction in trabecular osteoclasts but no deficiency of osteoclast precursors. This suggested that OPG's role is in the latter stages of osteoclast differentiation. The key role of OPG was also demonstrated by the systemic administration of OPG which produces an increase in bone density and blocks the loss of bone induced by ovariectomy (Simonet et al. 1997).

The physiological role of OPG in bone remodelling was investigated by targeted deletion of the endogenous OPG gene in mice (Bucay et al. 1998; Mizuno et al. 1998). These studies show that endogenous OPG is not required for embryonic bone formation but is essential for maintenance of post-natal trabecular and cortical bone mass throughout the skeleton. By one month of age, there is a noticeable decrease in bone

mineral density of OPG^{-/-} mice and changes become more severe with increasing age. Some abnormalities noted include multiple fractures, kyphosis of the spine, and profound osteoporosis in the humerus, femur and tibia. Cortical bone is composed of mostly woven bone with an increased density of osteocytes which are features consistent with increased bone turnover. As previously shown, the numbers of osteoclast precursors are not affected and this suggests that the osteoporosis in OPG^{-/-} mice is most likely due to poorly regulated osteoclast recruitment and activation in vivo. Calcification was also noted in the large arteries including the aorta. Endogenous OPG expression is localised within the smooth muscle layer of the aortic and renal arteries, suggesting a role for OPG in maintaining normal structure in larger arteries (Bucay et al. 1998).

5.3.1.2 RANKL

RANKL is a type II transmembrane protein of 317 amino acids of which 3 isoforms exist (Ikeda et al. 2001). It is typically membrane-bound and found on osteoblasts and activated T-cells with RANKL1 and RANKL2 encoding for its trans-membrane forms. RANKL3 is a soluble form as it lacks the trans-membrane domain. The secreted protein is derived from the membrane form by either proteolytic cleavage or alternative splicing (Ikeda et al. 2001).

Most of the factors that are known to stimulate osteoclastic formation and activity induce RANKL expression via osteoblastic stromal cells although RANKL is expressed in a number of other tissues (Table 2). It is also expressed by synovial cells and activated T-cells in joints of patients with inflammatory arthritis and may contribute in part, to the joint destruction in patients with rheumatoid arthritis (Boyce and Xing 2008).

RANKL is involved in numerous aspects of osteoclast differentiation and function. It has been implicated in the fusion of osteoclast precursors into multinucleated cells (Lacey et al. 1998), their differentiation into mature osteoclasts (Lacey et al. 1998), their

attachment to bone surfaces (O'Brien et al. 2000), their activation to resorb bone (Burgess et al. 1999; Lacey et al. 1998) and osteoclast survival by avoiding apoptosis (Lacey et al. 2000).

RANKL plays a dominant role in the regulation of bone resorption and no factor or combination of factors has been shown to restore bone resorption when RANKL is not present. Udagawa and colleagues (1999) demonstrated that although M-CSF and RANKL both support the survival of osteoclasts in culture, only RANKL induced pit-forming activity of osteoclasts. The data shows that the survival of osteoclasts is necessary but not sufficient for inducing bone resorbing activity. Addition of osteotropic factors such as $1\alpha 25(\text{OH})_2\text{D}_3$ and PTH to M-CSF⁻ and RANKL⁻ bone marrow cultures did not stimulate pit-forming activity but when osteoblasts were added, it was found that RANKL mRNA was up-regulated by these osteotropic factors (Udagawa et al. 1999). Interestingly, in M-CSF deficient mice the osteoclast population has been shown to recover over time (Begg et al. 1993); a phenomenon that has not been shown to occur with a RANKL deficiency.

5.3.1.3 RANK

Receptor activator of nuclear factor $\kappa\beta$ (RANK) is the receptor that mediates all known activity for RANKL. RANK is a type I transmembrane protein of 616 amino acids and is a member of the TNF receptor family (Anderson et al. 1997). It is expressed primarily on cells of the macrophage/monocytic lineage, including preosteoclastic cells, T and B cells, dendritic cells, and fibroblasts (Anderson et al. 1997; Hsu et al. 1999). It is also found in numerous tissues including bone, bone marrow, spleen; skeletal muscle, liver, heart, lung, brain, mammary tissue and skin (see Table 2).

Table 2. Expression patterns of OPG, RANKL, RANK
[adapted from (Theoleyre et al. 2004)]

Molecule	Cells	Tissues
OPG	Bone marrow stromal cells, dendritic cells, follicular dendritic cells, lymphoid cells, endothelial cells, fibroblasts, monocytes, B and T lymphocytes, megakaryocytes	Arterial smooth muscle cells, bone, bone marrow, brain, calvaria, heart, intestines, kidney, liver, lung, mammary tissue, placenta, prostate, skin, spinal cord, spleen, stomach, thyroid
RANKL	Bone marrow stromal cells, fibroblast, mammary endothelial cells, epithelial cells, osteoblasts, osteoclasts, T lymphocytes,	Artery smooth muscle cells, bone, bone marrow, brain, heart, kidney, liver, lung, lymph nodes, mammary tissue, placenta, skeletal muscle, spleen, testes, thymus, thyroid
RANK	Dendritic cells, endothelial cells, fibroblasts, B and T lymphocytes, osteoclasts	Bone, bone marrow, brain, heart, kidney, liver, lung, mammary tissue, skeletal muscle, skin

The binding and activation of RANK involve direct interactions between the extracellular receptor binding domain of trimeric RANKL and the extracellular cysteine-rich domains of trimeric RANK. This interaction is thought to cause oligomerisation of RANK and subsequent activation of several signal transduction pathways (overview in Figure 8).

RANKL binds to RANK and leads to the activation of an adaptor protein, TRAF 6 (TNF receptor associated factor 6). TRAF 6 acts as a second messenger to activate various protein kinase pathways as well as transcription factors such as nuclear factor- κ B (NF- κ B). Activated NF- κ B is translocated to the nucleus and up-regulates the expression of c-fos, which then interacts with nuclear factor of activated T cells (NFAT)-c1 to trigger the transcription of osteoclastogenic genes. Activation of the above pathways is prevented by OPG which prevents RANKL from activating RANK in the extracellular environment (Kearns et al. 2008).

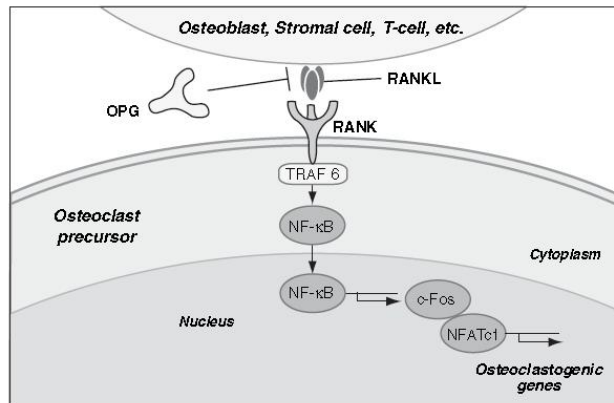


Figure 8. Essential signalling pathways activated by RANKL interactions with RANK [from (Kearns et al. 2008)]

5.3.2 RANKL expression by osteocytes

The discussion of RANKL has centred on its expression by osteoblasts. However, two independent studies have emerged that challenge this concept by providing evidence that osteocytes are a major source of RANKL and are essential for bone remodelling (Nakashima et al. 2011; Xiong and O'Brien 2012).

The research group from the Tokyo Medical and Dental University (Nakashima et al. 2011) set out to determine the most physiologically relevant osteoclastogenesis supporting cells amongst the mesenchymal lineage cells in bone. They purified osteoblast and osteocyte populations utilising known osteocyte-specific genes and demonstrated that the RANKL levels were significantly higher in the osteocytes when compared with osteoblasts and other mesenchymal cells. Osteoclast precursor cells were co-cultured with osteoblasts or osteocytes in the presence of 1,25-dihydroxy vitamin D₃ (1,25(OH)₂D₃) and prostaglandin E₂ (PGE₂) which revealed that the osteocytes have a stronger capacity to support osteoclastogenesis than osteoblasts. Osteocytes derived from long bones also showed higher levels of RANKL and a more potent ability to support osteoclastogenesis.

Nakashima and colleagues also created mice that were T cell specific *Tnfs-11* (encodes for RANKL) deficient. The mice did not show any discernible osteopetrotic phenotype which indicates that RANKL expressed on T cells does not significantly contribute to regulation of osteoclastogenesis. The *Tnfs-11* gene was specifically deleted in osteocytes. This diminished the osteoclastogenesis-supporting ability of osteocytes but not osteoblasts. These mice initially showed no gross abnormalities, no defects in tooth eruption or any growth retardation. However, bone volume was increased and at 12 weeks of age, the marrow cavity was abnormally filled with trabecular bone (Figure 9). These mice showed a severe osteopetrotic phenotype as a result of a reduction in the number of osteoclasts. There was no abnormality in osteocyte density, morphology or marker gene expression (including *SOST*) between wild-type and osteocyte-specific *Tnfs-11*-deficient mice, which suggested the crucial role of osteocyte-derived RANKL in the regulation of osteoclastogenesis in vivo. Because the mice showed no abnormal phenotype at birth but developed a post-natal phenotype and bone mass increased with age, the authors concluded that the RANKL expressed by osteocytes contributes more to bone remodelling after birth than to the skeletal development in the embryo. This suggests the other cells producing RANKL may have a larger role in the regulation of osteoclastic bone resorption in the embryonic stage and in tooth eruption and the growth of long bones (Nakashima et al. 2011).

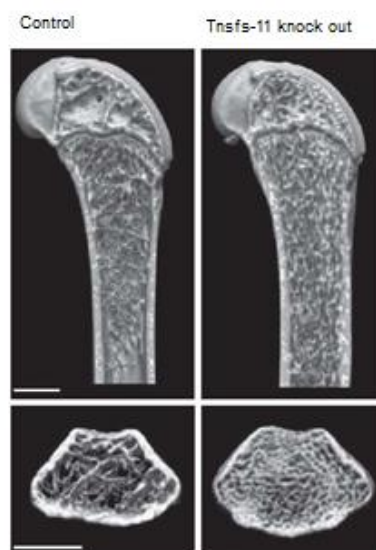


Figure 9. Micro-CT reconstruction of femurs of 12 week mice Longitudinal and axial views. [Adapted from (Nakashima et al. 2011)]

Xiong and colleagues (2011) generated mice in which RANKL was conditionally deleted in various genetically-defined cell populations corresponding to different stages of osteocyte and chondrocyte differentiation. RANKL produced by osteocytes was also found to be responsible for the majority of the osteoclast differentiation that drives the remodelling of cancellous bone, as their mice with deletion of the *Tnfs-11* (encoding for RANKL) gene had increasing bone mineral density with increasing age. Hypertrophic chondrocytes were proposed as the source of RANKL required for the resorption of the primary spongiosa.

In addition, a model of unloading-induced bone loss was used in which mice were tail-suspended in an attempt to demonstrate a role for osteocyte RANKL in pathological bone remodelling. Control mice showed an increase in RANKL mRNA and osteoclast numbers and an increase in trabecular spacing and decreased cortical thickness. Mice lacking RANKL in osteocytes were protected from the loss of bone and changes in the bone architecture. This was considered to indicate that osteocytes are important in the pathogenesis of diseases caused by abnormal bone remodelling (Xiong et al. 2011).

Expression of RANKL in osteoblast progenitors was stimulated by hormones known to increase bone resorption in vitro. However, the results show that RANKL expression in these cells does not participate in physiological bone remodelling. It was suggested (Xiong et al. 2011) that it may contribute to osteoclast differentiation under different circumstances such as dietary calcium deficiency or lactation. It must also be kept in mind that it is possible that RANKL expression in these cultures could be an in vitro phenomenon and not reflect a true physiological role.

Deleting RANKL from osteocytes leads to an increase in bone mass. In this model, deletion of RANKL led to the femoral cancellous bone volume doubling and osteoclast surface decreasing by 75%. It was concluded that RANKL produced by osteocytes is responsible for most of the osteoclastogenesis in cancellous bone (Xiong et al. 2011).

5.3.2.1 How RANKL from osteocytes reaches osteoblasts

If RANKL is produced by osteocytes which are the key cells in bone remodelling, it is important to examine how the RANKL produced by these cells which are embedded within mineralised matrix can reach the osteoblasts. Osteocytes have up to 50 cellular processes that extend through the bone matrix that connect osteocytes to each other and to the bone surface via gap junctions (Bonewald 2011). These connections and processes make up the lacuna-canalicular network (Bonewald 2011). Imaging studies (Kamioka et al. 2001) have shown that osteocytes widely spread their processes into the osteoblast layer, and that some of these processes elongate to the vascular-facing surface of the osteoblast layer. It is plausible that membrane-bound RANKL produced by osteocytes could be carried on these processes. Soluble RANKL has a small enough molecular weight that it can pass through the osteocyte lacunae-canalicular network (Xiong et al. 2011). Molecules travelling from the osteocyte to the osteoblast and osteoclast via these means may be involved in the regulation of RANKL in these cells (Tatsumi et al. 2007).

Osteocytes can be difficult to study in vitro as the dendritic processes are lost when osteocytes are isolated from bone matrix and placed into conventional 2D cultures (Honma et al. 2013). Honma et al (2013) developed a co-culture system of osteoclast precursors and osteocytes embedded in collagen gel that allowed the physiological properties of osteocytes to be maintained for about a week. Results showed that osteocytic RANKL was provided as a membrane-bound form to osteoclast precursors through osteocyte dendritic processes. The contribution of soluble RANKL to the osteoclastogenesis supported by osteocytes was found to be minor (Honma et al. 2013).

Tatsumi and colleagues (2007) have postulated that it is the cell-cell contact between osteocytes and osteoblasts that normally retracts RANKL gene expression from aberrant activation and that osteocyte ablation or disruption of the network releases this negative regulation. This would result in the aberrantly elevated RANKL expression and osteoclastogenesis that was found in their investigation.

5.4 Sclerostin

Osteocytes have been acknowledged to sense loading stimuli and to regulate remodelling and bone turnover processes, but little is known about how cells embedded in a mineralised matrix carry out this regulatory role. Research suggested that mature osteocytes send an inhibitory signal to osteoblasts at the bone-forming surface via canalicular processes and it was also proposed that the same signal maintained bone lining cells in a quiescent state against their natural tendency to reactivate the remodelling process (Martin 2000). This could explain the exponential decline in bone formation rates as new osteocytes were formed. If this signal was sensitive to mechanical loading the correct balance could be obtained between bone formation and its inhibition. This previously unknown signal has been identified as sclerostin, the secreted protein product of the SOST gene, located on chromosome 17q12-21. Sclerostin is a negative regulator of osteoblasts and inhibits bone formation and appears to be exclusively osteocyte derived (van Bezooijen et al. 2004). Information about sclerostin has mainly been obtained by studying rare human bone disorders and in vitro experimentation.

5.4.1 Role of sclerostin

Sclerostin has been proposed to have a number of roles in bone formation and homeostasis. It may have a role in bone modelling whereby it may keep bone lining cells in a quiescent state, preventing activation of osteoblasts and formation of bone without previous resorption. Its role in bone remodelling may be to serve as a negative feedback signal to osteoblasts to prevent over-filling of the basic multi-cellular unit (van Bezooijen et al. 2004; Poole et al. 2005).

The effects of sclerostin have been shown experimentally by using SOST knock-out mice which show increased radio-density, bone mineral density, cortical and trabecular volume, bone formation and bone strength (Poole et al. 2005).

5.4.2 Sclerostin deficiency in humans

A lack of sclerostin in humans results in the rare conditions of sclerosteosis and van Buchem disease, first described in the 1950's (van Buchem et al. 1955; Truswell 1958). The skeletal manifestations of both diseases are the result of endosteal hyperostosis and are characterised by progressive generalized osteosclerosis. The manifestations are most pronounced in the mandible, skull and include characteristic enlargement of the jaw and facial bones leading to facial distortion, increased intracranial pressure with entrapment of cranial nerves which is often associated with facial palsy, hearing loss, and/or loss of smell. Those patients with sclerosteosis have a more severe phenotype compared with patients with van Buchem disease and usually present with syndactyly (Figure 10). Bone biopsies of those affected show increased bone formation including a predominance of cuboidal active osteoblasts (Moester et al. 2010).

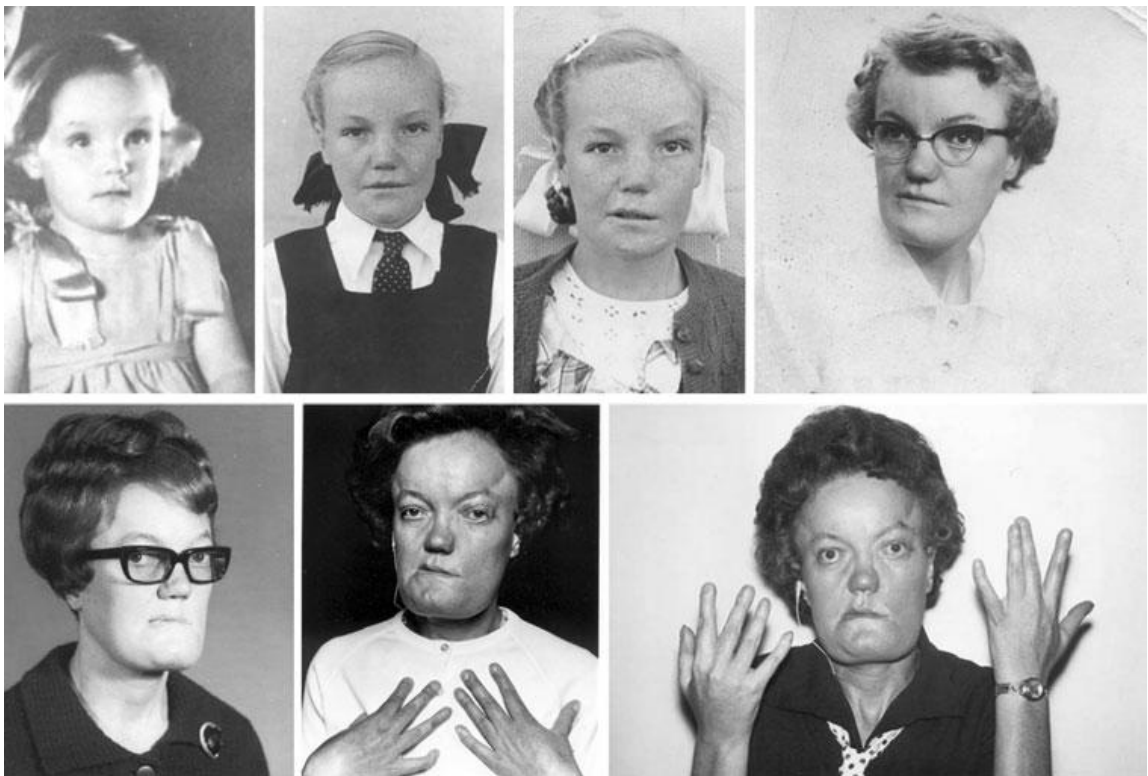

Figure 10. Chronological portraits of a patient with sclerosteosis from the age of 3 [From (Moester et al. 2010)]

5.4.3 Expression of SOST/Sclerostin

SOST mRNA is expressed in many tissues, especially during embryogenesis. In humans these tissues include the heart, aorta, liver and kidney. Expression of the sclerostin protein has only been reported in cells embedded within a mineralised matrix e.g. osteocytes (Figure 11), cementocytes (Figure 12) (van Bezooijen et al. 2004; Winkler et al. 2003) and mineralised hypertrophic chondrocytes in the human growth plate (van Bezooijen et al. 2009). Osteoclasts, as well as osteoblasts and lining cells (whether located in the Haversian canals or at the periosteum) have been shown to be consistently negative for sclerostin (Poole et al. 2005).

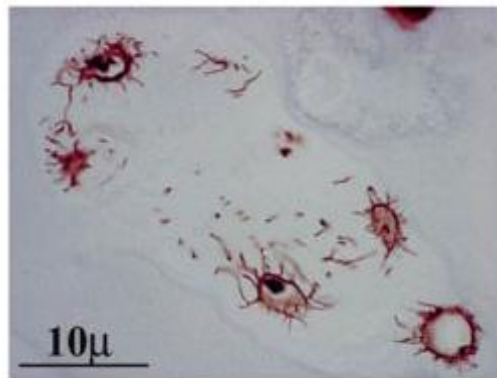


Figure 11. Canaliculi and/or lacunae of osteocytes in human bone positive for sclerostin. [from (Winkler et al. 2003)]

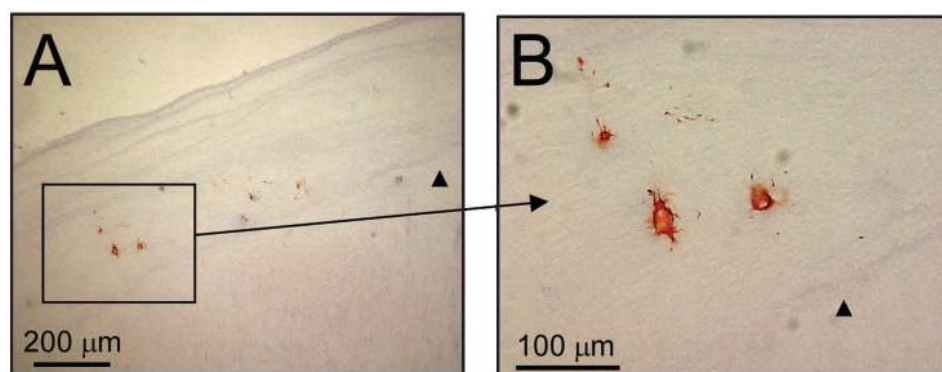


Figure 12. Sclerostin expression by cementocytes in a human third permanent molar. (B) Detail of (A) showing sclerostin-positive canaliculi of cementocytes [from (van Bezooijen et al. 2009)]

Sclerostin expression has been shown to be cell differentiation-dependent with detection only present in late-differentiated human and mouse cells, using in vitro experiments (van Bezooijen et al. 2004). Researchers have closely examined the stage at which normal osteocytes express sclerostin in human bone. It was concluded that sclerostin secretion by osteocytes is a delayed event in which the cells only secrete sclerostin after the onset of mineralisation to inhibit cortical bone formation and osteon infilling by cells of the osteoblast lineage (Figure 13) (Poole et al. 2005). The more sclerostin-negative osteocytes were found in an individual osteon, the more likely it was that the osteon was in the process of bone formation. Most new osteocytes were negative for sclerostin staining for at least 16 days. There was a trend towards a higher percentage of sclerostin-positive cells in the cortex than the cancellous bone and it was also demonstrated that sclerostin negative cells were located closer to surfaces (Haversian canal or endo/periosteal surface) than sclerostin positive cells (Poole et al. 2005). Late stage osteoblasts/early osteocytes are the target for sclerostin action (Wijenayaka et al. 2011) which was demonstrated experimentally by examining normal human bone derived osteoblastic cells (NHBC) treated throughout differentiation with recombinant sclerostin. Observation revealed that gene expression was primarily affected at the time of mineralisation.

Positive sclerostin staining is evident in osteocyte canaliculi and this may suggest that this could be a method whereby sclerostin is transported to neighbouring cells, intracellularly via the gap junctions present at the tips of the canaliculi. Sclerostin has also been demonstrated to be present in lacunar walls giving evidence that sclerostin is a secreted protein and its transport may occur extra-cellularly from lacunae to lacunae (van Bezooijen et al. 2004).

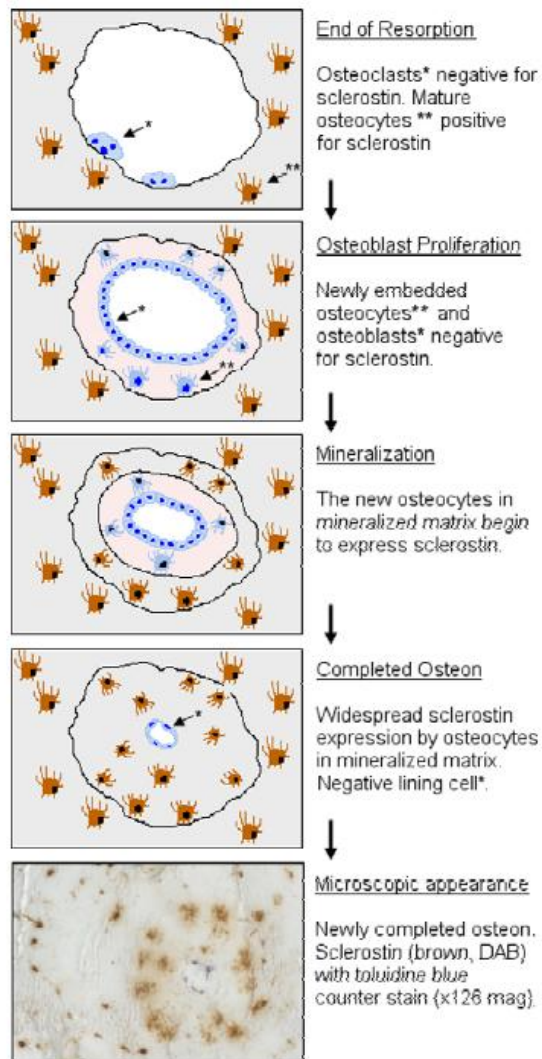


Figure 13. Schematic diagram of the proposed regulation of a remodelling cortical osteon by osteocytic sclerostin expression [from (Poole et al. 2005)]

5.4.4 Possible mechanisms of action

A number of experiments have demonstrated the role of sclerostin on bone formation.

5.4.4.1 Inhibition of bone formation

Clinically, patients with sclerosteosis show a high bone mass due to increased formation with premature termination codons in the SOST gene which suggests an inhibitory role of sclerostin on bone formation. Experimentally, this role has been demonstrated by adding sclerostin to osteogenic cultures which has been shown to result in inhibited proliferation and differentiation of mouse and human osteoblasts (Poole et al. 2005; Sutherland et al. 2004; van Bezooijen et al. 2004; Winkler et al. 2003) and overexpression of sclerostin in vivo induces osteopenia in mice in which bone formation decreased but resorption was unaffected (Winkler et al. 2003). van Bezooijen and colleagues (2004) suggested that sclerostin produced by osteocytes is transported to the bone surface where it inhibits the later stages of bone formation.

5.4.4.1.1 Osteoblast apoptosis

The balance of proliferation, cell differentiation and apoptosis affects the pool of osteoblasts available to maintain bone homeostasis. Many factors affect osteoblast survival and osteoblasts undergo programmed cell death due to increased sensitivity to apoptosis-inducing agents, decreased concentrations of vital growth factors or enhanced response to apoptosis-inducing factors (Jilka et al. 1998), for example TNF- α and high levels of glucocorticoids have been reported to increase the apoptosis of osteoblasts. Using cell cultures, sclerostin has also been shown to induce osteoblast apoptosis (Sutherland et al. 2004). The pathway by which sclerostin causes apoptosis has been likened to that reported for growth factor deprivation. This pathway may serve as the basis for the method by which sclerostin is able to modulate the survival of osteoblasts. By promoting osteoblast apoptosis a decrease in osteoblast numbers will result and this will ultimately lead to decreased bone formation.

5.4.4.2 Member of the DAN family of glycoproteins

Sclerostin has an amino acid sequence which indicates a cystine knot structure and has been assigned as part of the DAN (differential screening-selected gene aberrant in neuroblastoma) family of glycoproteins (Avsian-Kretchmer and Hsueh 2004). These proteins are largely bone morphogenic protein (BMP) antagonists. BMPs are secreted cytokines and although sclerostin has a relatively low binding affinity for BMPs, it has been shown to antagonise BMP-stimulated bone formation (van Bezooijen et al. 2004).

The mechanism by which sclerostin antagonised BMP-stimulated bone formation differs from that of classical BMP antagonists; however, it has since been suggested that sclerostin, like other DAN family members such as WISE (which shares 38% amino acid identity to sclerostin), acts to antagonise canonical Wnt signalling (van Bezooijen et al. 2004; Li et al. 2005; Semenov et al. 2005).

5.4.4.3 Antagonist to canonical Wnt signalling

5.4.4.3.1 Wnt/ β catenin signalling pathway

The canonical Wnt pathway is a complex biochemical sequence that when activated, results in increased osteoblastic cell differentiation and inhibition of bone resorption by blocking the receptor activator RANK-L/RANK (Jackson et al. 2005). There are over a dozen forms of Wnt proteins. Wnt proteins are secreted glycoproteins that play key roles in development and homeostasis through their roles in cell differentiation, proliferation and apoptosis (Johnson 2008).

The key components of the pathway in bone include (Johnson 2008):

- 1) Cell surface co-receptors, LRP5/6 and Frizzled
- 2) Intra-cellular proteins
- 3) TCF nuclear transcription factors that bind β -catenin and regulate gene expression.

The signalling pathway is controlled by two cell surface co-receptors, Frizzled and low-density lipoprotein receptor-related proteins (LRP) 5 or 6 that bind the Wnt protein ligand. In the absence of Wnt, there are a number of intracellular proteins including Dishevelled (Dsh), and the 'degradation complex' of Axin, adenomatous polyposis coli (APC), glycogen synthase kinase (GSK-3 β) and beta-catenin. The degradation complex in addition to other proteins co-ordinate the phosphorylation of β -catenin. The molecule ubiquitin ligase then binds to β -catenin which is then ubiquitinated and degraded by the proteasome. This maintains a low intra-cellular level of β -catenin. Transcription factor TCF and other proteins such as 'Groucho' bind to DNA and prevent DNA transcription.

In activation, Wnt binds to the trans-membrane receptor Frizzled and its co-receptor LRP5/6. This binding causes activation of the protein Dishevelled which results in phosphorylation of GSK-3 β inhibiting its activity and dissociation of the proteins of the degradation complex. β -catenin is no longer modified and destroyed and so it accumulates in the cytosol. As the amount of β -catenin rises, it migrates into the nucleus where it binds to TCF transcription factor to activate a RNA polymerase and gene transcription. Osteoblastic activity is stimulated (Figure 14). An increase in LRP5/6-mediated canonical Wnt signalling leads to an increase in bone mass (Li et al. 2005).

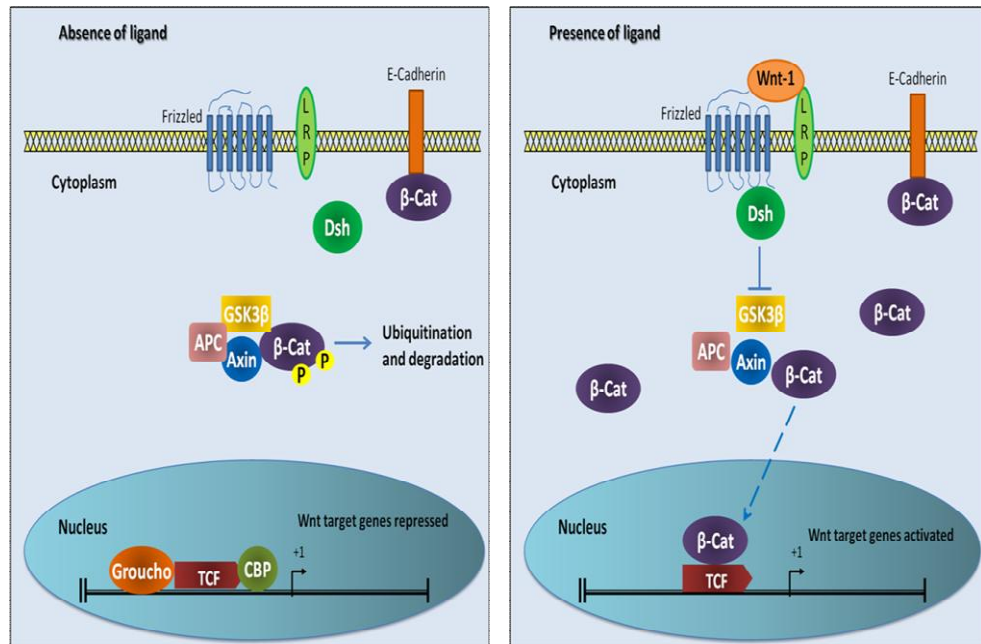


Figure 14. The Wnt/β-catenin signalling pathway

[from (<http://www.intechopen.com/source/html/42019/media/image2.png>)]

5.4.4.3.2 Sclerostin binds to low-density lipoprotein receptor-related protein

Sclerostin has been shown to inhibit the Wnt-signalling pathway. It does this by binding to LRP5 (low-density lipoprotein receptor-related protein) and its co-receptor LRP6 to inhibit canonical Wnt-signalling (Li et al. 2005; Semenov et al. 2005). Despite sclerostin binding to LRP5/6, it does not appear that Wnt proteins and sclerostin compete for binding of this co-receptor (Li 2005). When sclerostin binds, LRP5 cannot restrain axin and the Wnt pathway cannot be activated. The degradation complex remains intact and as β-catenin does not accumulate DNA transcription does not occur and osteoblast function is inhibited. Further research has also shown that LRP4 plays a role in skeletal development and bone metabolism as it has been demonstrated to bind sclerostin in addition to other BMP antagonists, Wise and Dickkopf1 (DKK1) (Choi et al. 2009; Leupin et al. 2009).

5.4.4.3.3 A catabolic action through promotion of osteoclast formation

Wijenayaka and colleagues (2011) have explored the possibility of a catabolic role for sclerostin in addition to the anti-anabolic roles already established. To investigate this experimentally, exogenous recombinant sclerostin (rhSCL) was added to cultures of human primary osteoblastic cells differentiated to an osteocyte-like stage and in MLO-Y4 cells (the mouse osteocyte-like cell line). It was found that a rhSCL dose-dependently up-regulated the expression of RANKL mRNA and down-regulated the expression of OPG, which caused a primarily RANKL driven increase in the RANKL:OPG mRNA ratio in both experimental cell types. To study the effects of rhSCL on resulting osteoclastic activity MLO-Y4 cells primed with rhSCL were co-cultured with mouse splenocytes or human peripheral blood mononuclear cells (PBMC). Osteoclastic resorption increased approximately 7-fold compared to untreated co-cultures with a moderate increase in number and size of TRAP-positive multinucleated osteoclast-like cells. The rhSCL did not induce apoptosis of MLO-Y4 cells which demonstrated that the increase in osteoclastic activity was not due to dying osteocytes. When recombinant OPG was added, the effects of rhSCL on osteoclast formation and activity were completely suppressed, demonstrating that RANKL signalling was essential for the sclerostin effect. The authors concluded that sclerostin may have a catabolic action, promoting osteoclastogenesis by its effect on osteocytes in a RANKL-dependent manner (Wijenayaka et al. 2011) (Figure 15).

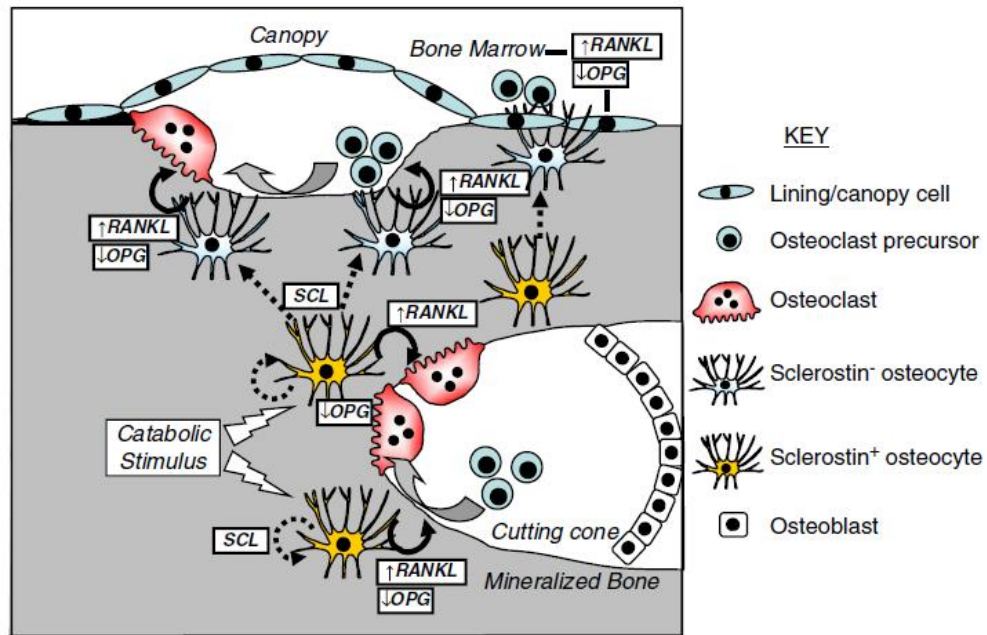


Figure 15. The potential role of osteocyte-derived sclerostin in regulating the expression of osteocyte RANKL.

A catabolic stimulus (e.g. mechanical unloading) may cause sclerostin expression in osteocytes (OY) to respond in an autocrine manner (curved dotted arrow), increasing the local expression of RANKL relative to OPG; or in a paracrine manner (straight dotted arrow) by inducing such expression in sclerostin-negative OY (including immature OY immediately below the osteoblastic lining cells and in the lining cells themselves). An effect of sclerostin and OY-derived RANKL on both endosteal and intra-cortical remodelling may occur either at the stage of osteoclast precursor recruitment/chemotaxis, proliferation/differentiation and/or on the activity of mature osteoclasts. Osteocytes may also ‘talk to’ cells in the bone marrow via a limited number of cell processes extending into the marrow space. This may result in effects on bone marrow stromal cell expression of RANKL and OPG and subsequent regulation of osteoclastogenesis by these cells. A role for apoptosing OY is not ruled out here as the initial stimulus for sclerostin expression - perhaps secondarily to microdamage and local bone unloading; or that the resorbing osteoclast is exposed to higher RANKL levels during engulfment of the expressing OY.

[adapted from (Wijenayaka et al. 2011)]

5.4.5 Regulation of SOST/Sclerostin expression

Osteocytes have long been implicated in mechano-sensing due to their location and morphology (Knothe Tate et al. 2004). The Wnt pathway may play an important role in the anabolic bone response to deformation and loading and increased Wnt signalling has been found after loading osteoblastic cells in vitro (Hens et al. 2005). Mechanical loading of ulnar limbs in mice has demonstrated a significant reduction in sclerostin levels which led the authors to hypothesise that the osteocytes detected the mechanical loading and this caused a reduction in secretion of sclerostin. This in turn reduced the inhibition of LRP5 signalling in nearby osteoblasts which led to enhanced osteogenesis (Robling et al. 2008). In the same study, the hind limbs were subject to unloading which yielded a significant increase in limb sclerostin expression (Robling et al. 2008). This was corroborated by Lin and colleagues (Lin et al. 2009) who demonstrated that, in response to unloading (tail suspension) in mice, an increased amount of sclerostin was secreted by osteocytes which inhibited Wnt/ β -catenin signalling, thereby inducing apoptosis and suppressing osteoblast activity. This led to decreased bone formation and as a result, bone mass decreased. SOST $-/-$ mice were also shown to be resistant to the usual unloading-induced bone loss.

It appears that the Wnt signalling pathway is held in the “off” position in bone due to the high levels of sclerostin produced by osteocytes. Therefore, activation of the pathway requires either a bypass of the inhibition of LRP5/6 by sclerostin or a decrease in levels of sclerostin to permit Wnt ligand-mediated activation of the pathway. It has been proposed that PTH stimulation of bone formation involves a reduction in SOST gene expression (Johnson 2008).

Other systemic factors that have been shown to affect SOST/sclerostin expression include 1,25 dihydroxy vitamin D₃ alone or in combination with retinoic acid, which increases SOST expression in human osteoblastic cells in vitro. Glucocorticoids affect sclerostin differently depending on the experimental conditions. In vitro, SOST expression on osteoblastic cells was suppressed by dexamethasone whilst in vivo,

SOST expression was increased in mice treated with prednisolone (Figure 16) (Moester et al. 2010).

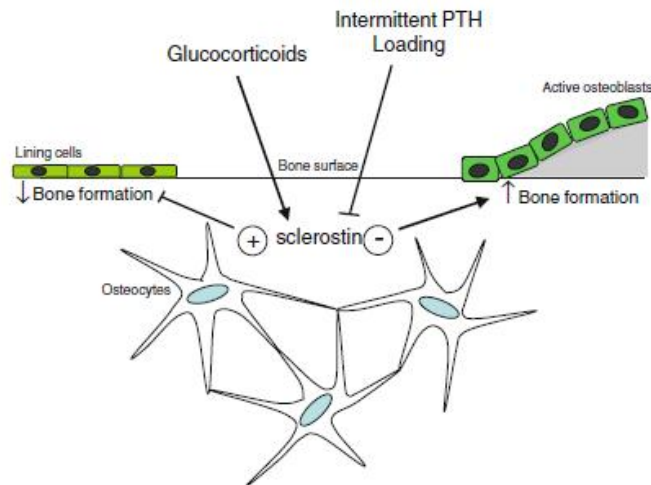


Figure 16. Schematic model for the regulation of the control of bone formation by sclerostin.

Sclerostin may exert its inhibitory effect on bone formation by preventing the activation of lining cells as well as the inactivation of active osteoblasts. Glucocorticoids stimulate sclerostin expression and, thereby, inhibit bone formation, whereas intermittent PTH and loading inhibit sclerostin expression in osteocytes and, thereby, stimulate bone formation. [from (Moester et al. 2010)]

The research to date indicates that sclerostin is an antagonist for Wnt signalling and the loss of SOST/sclerostin function likely leads to the hyperactivation of Wnt signalling that underlies bone growth characteristic of sclerosteosis patients. More research is required to determine the precise mechanisms by which sclerostin binding to LPR5/6 interferes with canonical Wnt signalling, to further identify factors that regulate SOST/sclerostin expression, and to determine any potential additional functions of sclerostin.

5.4.6 Clinical applications of sclerostin

Sclerostin has been the subject of intensive investigation in the medical field as research grows showing that the osteocyte plays a key role in bone homeostasis. Sclerostin is of particular interest because of its potential therapy for the stimulation of bone formation as required in the treatment of osteoporosis.

Antibodies to sclerostin have been developed that inhibit its biological activity. These antibodies have already been shown to increase the bone formation rate, density and strength in ovariectomised rats (Li et al. 2009). Clinical trials have also begun involving 48 healthy post-menopausal women who were given an injection of monoclonal antibody against sclerostin. Results showed increased bone formation markers and bone mineral density and the therapy was well tolerated (Padhi et al. 2011).

5.4.7 Dentistry and sclerostin

Research has been conducted on the role of sclerostin on the alveolar bone and the development of dental structures. When sclerostin was knocked out of mice, increased dimensions of mandibular basal bone but no differences in the tooth and the pulp chamber were shown. There was an increase in the width of the cementum and a moderate decrease in the width of the periodontal ligament (Kuchler et al. 2014). Sclerostin appears to affect the bone and cementum rather than producing anomalies in tooth structure such as dentine (Kuchler et al. 2014).

Sclerostin is not normally found in the periodontal ligament (PDL). When PDL cultures underwent mineralising treatment researchers were able to demonstrate increased levels of SOST mRNA using real time PCR, immunohistochemistry and western blots (Jäger et al. 2010).

There have been two clinically relevant investigations into possible applications of sclerostin utilising animal models. Pharmacologic inhibition of sclerostin using sclerostin-neutralising monoclonal antibody (Scl-Ab) is known to increase bone formation, bone mass and bone strength in models of osteopenia and fracture repair (Taut et al. 2013). Taut and colleagues designed an investigation to assess the therapeutic potential of Scl-Ab to stimulate alveolar bone regeneration after the establishment of experimental periodontitis in rats. Experimental periodontitis reduced bone volume fraction (BVF) by 30% and tissue mineral density (TMD) by 32%. After 6 weeks of treatment significant increases in alveolar bone volume and density were observed with no statistically significant difference between the animals with periodontitis and intact healthy animals.

The effect of orthodontic tooth movement has been studied using a Ni-Ti closed coil spring applied between the incisors and molars of mice (Nishiyama et al. 2015). After 4 days the mice were examined using multimodal confocal fluorescence imaging analysis. In the tensile areas of bone there was down-regulation of sclerostin and in areas of compression sclerostin was significantly higher than control sites. A study at the University of Adelaide (Sanmuganathan 2011), in which separators were placed between rat molars to provide the orthodontic force has found similar results. It seems that when significant local strains are sensed by the osteocyte population on the side of tension the sclerostin levels are decreased and the cells are released from their suppressed Wnt signalling state and new bone is formed. Conversely, on the side of compression, sclerostin levels are increased with continued Wnt signalling suppression, leading to a prevention of local bone formation.

5.5 Dentoalveolar ankylosis

Dentoalveolar ankylosis is defined as the fusing of cementum with alveolar bone (Kurol, 1981). Once ankylosis has occurred, further tooth eruption and bone deposition becomes impossible. Ankylosis is commonly found in two clinical situations: those of infra-occlusion which mainly affects deciduous or primary teeth (Figure 17) and in the permanent dentition in which it is associated with impaction or external root replacement resorption following trauma and is frequently observed after re-implantation of avulsed permanent teeth (Figure 18).

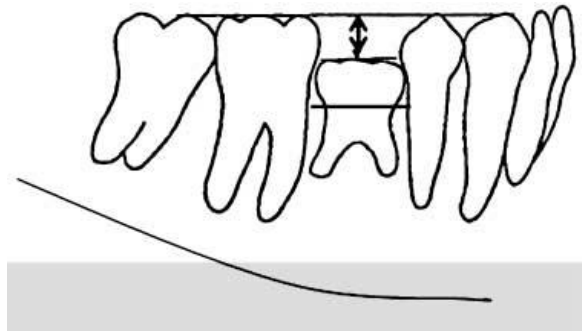


Figure 17. Infra-occlusion of a primary molar tooth below the level of the occlusal plane [from (Kjaer et al. 2008)]

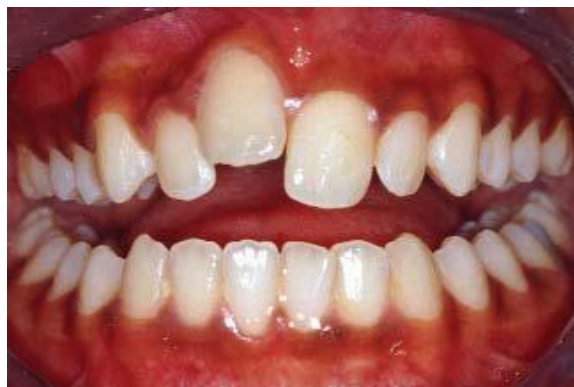

Figure 18. Tooth 11 demonstrates infra-occlusion and ankylosis subsequent to avulsion and replantation [from (Campbell et al. 2005)]

5.5.1 Prevalence

Ankylosed teeth often present at a level below the occlusal plane, a condition referred to as submergence or infra-occlusion, which results from the inability of the ankylosed tooth to follow the normal vertical development of the neighbouring teeth that are continuing to develop and erupt. The condition is as much as ten times more common in the deciduous dentition compared with the permanent dentition (Kurol 1981; Messer and Cline 1980; Biederman 1956), is twice as common in the mandible as the maxilla and does not appear to have a dominance in either the right or left side (Biederman 1962; Messer and Cline 1980) or between males and females (Kurol 1981). The most common tooth reportedly affected by ankylosis is the deciduous second molar (Biederman 1962; Biederman and Centre 1956), although some studies have found a higher prevalence of ankylosis in mandibular deciduous first molars (Messer and Cline 1980; Steigman et al. 1974). However, as this tooth shows only slight infra-occlusion and usually exfoliates on schedule, the diagnosis of ankylosis may be missed, explaining the higher prevalence of ankylosis reported in second molars (Messer and Cline 1980). Any tooth, deciduous or permanent, may become ankylosed anywhere along its eruptive path, either before or after emergence (Biederman and Centre 1956).

Infra-occlusion affecting primary molars can be found in children as young as 3 years of age with review articles citing prevalence ranging from 1.3-38.5% (Andlaw 1974; Kurol 1981). This most likely reflects the use of different inclusion criteria (e.g. no contact with opposing tooth, presence of permanent successors, degree of immobility), age of children investigated and ethnic factors (Andlaw 1974; Kurol 1981). Kurol (1981) reported a difference in prevalence between different age groups with the maximum prevalence reported as 14.3% in 8-9 year old children and the minimum of 1.9% in 12 year old children. This may reflect the normal exfoliation of teeth, including those that were in infra-occlusion. The prevalence amongst siblings is significantly higher at 18.1% suggesting a familial tendency in the infra-occlusion of primary molars and that a multifactorial, polygenic inheritance pattern is most likely with possible contribution from environmental factors (Kurol 1981).

In individuals with bilateral infra-occlusion of deciduous molars in which a successor was absent on one side only, the side with no successor showed more infra-occlusion and no infra-occluded molars with aplasia of the successor were found to exfoliate spontaneously (Kuroi and Thilander 1984).

Traumatic dental injuries commonly involve anterior teeth with effects on the dental hard tissues as well as the gingiva, periodontal tissue, pulp and alveolar bone. Healing of dental injuries depends on the stage of root development, the extent of damage particularly to the periodontal tissues, and the effect of bacterial contamination from the mouth. A significant complication following a traumatic injury is external root resorption which may be classified into surface resorption, inflammatory resorption, replacement resorption (ankylosis) (Andreasen 1975; Hecova et al. 2010) and in some cases transient replacement resorption (Andreasen 1975).

External root resorption is most common following avulsion rather than luxation injuries and more common following intrusive luxation compared with extrusive or lateral luxations. This is most likely due to higher damage to the PDL with intrusive luxation and avulsion injuries. In a study of 889 injured permanent teeth, replacement root resorption was present in 42.9% of avulsed and replanted teeth (Hecova et al. 2010). Of the replanted teeth, 12.2% required eventual extraction due to replacement resorption and marked infra-occlusion and an additional 26.5% were extracted due to inflammatory root resorption (Hecova et al. 2010). Root resorption has been observed predominantly on the apical part of the root (58%), while 29% was located coronally and 19% was located on the central part of the root (Crona-Larsson et al. 1991).

5.5.2 Aetiology

Ankylosis is preceded by a defective or discontinuous periodontal ligament (PDL) due to incomplete development of the periodontal membrane, local lysis or local ossification (Biederman and Centre 1956). Part of the bone surface is therefore obliterated and bone growth accompanying tooth eruption is halted (Biederman and Centre 1956). Early theories in an attempt to describe the alteration in the PDL included a genetic or congenital gap in the PDL, excessive masticatory pressure or trauma causing local injury to PDL which leads to ossification occurring as a healing process or a disturbance to local metabolism (Biederman and Centre 1956; Biederman 1962). Biederman postulated that masticatory trauma was unlikely to be the cause as there was not a greater incidence in ankylosis in adults who have higher masticatory forces. Neither was there a predominance of the incidence in left or right sides and Biederman suggested that if masticatory trauma was the cause then one side should predominate. He found that the same jaw was commonly affected and that this supported the concept of a disturbed local metabolism, whilst not being absolute proof.

Other causes of ankylosis that have been proposed include localised infection (Adamson 1952), chemical or thermal irritation (Line et al. 1974; Messer and Cline 1980; Kurol and Magnusson 1984), root canal treatment (Erasquin and Devoto 1970), tooth re-implantation (Löe and Waerhaug 1961), failure of normal eruptive process to keep pace with vertical alveolar growth (Dixon 1963) and an aberration of the normal process of resorption and deposition of bone and cementum during tooth exfoliation (Messer and Cline 1980).

In addition to an increased prevalence of infra-occlusion in siblings (Kurol 1981) suggesting a genetic origin, studies have shown that infra-occlusion is frequently observed in the presence of other dental anomalies such as tooth agenesis, microform teeth, delayed tooth development, palatally-displaced canines and mandibular second premolar distal angulation (Bjerklin et al. 1992; Baccetti 1998; Baccetti 2000; Garib et al. 2009; Shalish et al. 2010). These dental features arising in combination have been

named dental anomaly patterns (DAP) by Peck (2009). Their occurrence suggests that not only is infra-occlusion under genetic control, but that there is a common genetic origin. This is clinically relevant as an infra-occluded tooth may be considered a marker for future dental problems such as tooth agenesis and palatally-displaced canines.

Ankylosis may occur as a repair process following injury. A healthy periodontal ligament must have the capacity to resist induction to osteogenesis through cell signalling systems such as the release of cytokines and growth factors that accurately 'measure' and maintain the PDL width, ensuring separation of the root and alveolar bone (Melcher 1970; McCulloch 1995). Traumatic injury disrupts this homeostasis. A number of studies have demonstrated that it seems to be the source of the cells that repopulate the PDL space following trauma or injury that determine whether or not ankylosis occurs (Erasquin and Devoto 1970; Lin et al. 2000; Melcher 1970; Line et al. 1974). Following trauma to the PDL the root side progenitor cells lose their ability to differentiate into fibroblasts. When the space is repopulated by cells from a source outside the true PDL tissues (alveolar bone, bone marrow or soft connective tissue) osteoclasts and osteogenesis occur, resulting in healing via a dentoalveolar ankylosis. Having vital PDL cells present after trauma to the tissue appears crucial for repair and regeneration to a functional PDL. Experiments with the re-implantation of teeth after varied periods of extra-oral dry time demonstrated that the presence of a normal PDL over ankylotic repair may be related to the presence of epithelial rests of Malassez (Löe and Waerhaug 1961).

5.5.3 Diagnosis

Methods of detecting ankylosis in a clinical setting are limited to infra-occlusion of the tooth, sound on percussion and mobility, supported by radiographic examination of the PDL, but the lack of sensitivity of these methods can lead to a false negative diagnosis. Raghoobar and colleagues (1989) calculated the number of true positives and false negatives when comparing clinical (percussion sounds and radiographic appearance of

the PDL) to the histological presence of ankylosis and found a sensitivity of 23% and a specificity of 100%.

The sound produced on tooth percussion is a commonly employed diagnostic test. It has been demonstrated in an animal model that percussion sounds changed from dull to high pitched when ankylosis affected more than 20% of the root surface and these teeth had no mobility present (Andersson et al. 1984). However, if the amount of ankylosis is small it may not be detected by percussion. In the same animal model when ankylosis was present but consisted of less than 10% of the root surface, percussion sounds were normal (Andersson et al. 1984).

Despite the limitations of percussion it is still more sensitive than radiographic examination of the change in width of the PDL. Radiographs may be subject to errors from overlapping structures and bone marrow space which may result in incorrect identification of the PDL (Andersson et al. 1984). The location of the lesion is also important as while ankylosis can be detected proximally with radiographs, it cannot be detected when it occurs on the lingual and labial surfaces of the root (Andersson et al. 1984). After trauma, clinical tests such as mobility testing and percussion could detect ankylosis 3 weeks earlier than radiographic examination (Andreasen 1975) and a subsequent investigation found lack of mobility, a metallic percussion tone and no pain to percussion were highly reliable compared to radiographic obliteration of the PDL space which appeared to be only partly reliable (Andreasen et al. 2006)

Infra-occlusion of the tooth below the occlusal plane has been suggested as the most important and reliable clinical sign of ankylosis (Raghoobar et al. 1989) and this may be accompanied by tipping of adjacent teeth and over-eruption of opposing teeth.

5.5.4 Histology

Dentoalveolar ankylosis presents histologically as a bony union between tooth and bone. Studies on extracted teeth have provided information on the specific histological presentation. Kurol and Magnusson detected the presence of ankylosis at the inner surface of the roots in the apical third but not at the apex in younger children and more coronally in older children (Kurol and Magnusson 1984). Raghoobar and colleagues found ankylosis in the bifurcation and inter-radicular area 81% of the time with a few teeth showing ankylosis on the outer root surface (Raghoobar et al. 1989).

Kurol and Magnusson (1984) described the ankylotic area as repair of a previously resorbed root area by a hard tissue resembling bone directly contacting dentine. Cell inclusions were present in the hard tissue and resting lines were evident especially in the older children. The authors suggested that as ankylosis did not appear to be static it may be part of an ongoing remodelling process following root resorption and be intermittent in nature. The altered relationship between the tooth and surrounding tissues may be a developmental rather than a functional disturbance.

Andersson et al. (1984) described two types of ankylosis using a monkey experimental model. In most teeth the ankylosis was preceded by resorption of the cementum and dentine with no cementum present at the ankylotic site. In some teeth direct apposition of bone onto the cemental surface occurred without previous resorption of the cementum – this type was slightly more common in apical areas of the root. Ankylotic areas consisted of either thin bony trabeculae or wide bony areas with most teeth showing the presence of both.

Pulp changes were also observed with Raghoobar and colleagues finding occasional pulp calcifications in the root canal and Kurol and Magnusson noting that pulps of ankylosed teeth showed more degenerative changes such as fibrosis and calcification (Kurol and Magnusson 1984; Raghoobar et al. 1989).

5.5.5 Sequelae and treatment of ankylosed teeth

The presence of an ankylosed deciduous molar tooth does not appear to affect coronal morphology or cause hypoplasia/hypomineralisation of the succedaneous bicuspid as the crown of this tooth is usually fully formed by the time of the clinical diagnosis of ankylosis (Messer and Cline 1980). In addition, ankylosis does not appear to influence the rate of development of the successive tooth (Steigman et al. 1974). The successive bicuspids showed rotations of the crown associated with a lack of mesiodistal space in the arch and a higher incidence of periodontal pathology (Messer and Cline 1980). When the deciduous molar ankyloses very early, there have been reports of ectopic positioning of the permanent successor (Kjaer et al. 2008). In the initial stages of development the permanent tooth germ is located laterally to the deciduous molar. When the eruption of the deciduous molar is arrested the permanent tooth germ may fail to migrate to an inter-radicular position below the non-erupting deciduous molar (Kjaer et al. 2008). Instead, it has been shown to erupt independently to obtain a position occlusal to the ankylosed molar (Kjaer et al. 2008).

The majority of ankylosed first primary molars tended to occur bilaterally and future ankylosis of other molars, particularly the deciduous mandibular second molars, was likely. The ankylosed primary first molar tends to show only mild to moderate infra-occlusion and exfoliates on schedule. It is assumed that during the process of exfoliation, the ankylosing tissue is resorbed, thus allowing exfoliation (Messer and Cline 1980; Steigman et al. 1974). If the infra-occlusion is mild and the permanent successor is present the tooth may simply be observed for any progression in infra-occlusion and radiographic evidence of interference with the successive permanent tooth (Andlaw 1974). There has been shown to be no risk of subsequent bone loss of the first permanent molar when the deciduous second molar became ankylosed and was allowed to exfoliate naturally (Kurol and Olson, 1991).

However, the ankylosed primary mandibular second molar tends to have a later onset and becomes progressively more severely infra-occluded than first molars. The infra-

occlusion may result in over-eruption of the opposing tooth and tipping of adjacent teeth which may lead to a loss of arch length, space loss, a shift of the dental midline and difficulty with future extraction of the infra-occluded tooth (Messer and Cline 1980; Andlaw 1974; Ponduri et al. 2009). Treatment options for moderate infra-occlusion include prosthodontic build-up of the affected tooth to re-establish the occlusion (Andlaw 1974; Ekim and Hatibovic-Kofman 2001). Adjacent teeth that have tipped towards the infra-occluded teeth require orthodontic uprighting which will facilitate easier extraction or alignment (Ekim and Hatibovic-Kofman 2001). If the infra-occlusion is progressive it may also result in hindrance of the vertical alveolar growth which would lead to a poor prognosis for the succedaneous tooth in the case of primary molar teeth (Kjaer et al. 2008). In these situations extraction may be indicated with space maintenance if required (Messer and Cline 1980). When considering extraction of ankylosed permanent teeth the timing must take into account the patient's age and expected future growth in order to maximise the quality of alveolar bone for future prosthetic or implant placement (Steiner 1997). Luxation of the tooth to release the ankylosis and allow continued eruption of the tooth has also been proposed (Biederman 1962).

Where the ankylosed primary mandibular second molar has no successor early orthodontic and prosthodontic consultation is recommended and prosthetic replacement, implants and orthodontic space closure can be considered based on the patient's age, occlusal status and the development and condition of the infra-occluded tooth (Kurol and Thilander 1984; Ekim and Hatibovic-Kofman 2001). It has been observed that these molars without successors show very slow root resorption, particularly after the age of 13 years (Kurol and Thilander 1984). If the deciduous molar is considered useful it may be left in the arch and may remain for many years although progressive resorption may lead to eventual tooth loss. Where extraction is considered, early extraction maximises spontaneous mesial drift whereas late extraction may include the added risk of loss of additional alveolar bone. Both may require extensive orthodontic treatment (Kurol and Thilander 1984).

In the case of ankylosed maxillary primary molars there tends to be severe and progressive infra-occlusion and early extraction is almost always indicated to avoid tipping of adjacent teeth and subsequent loss of arch length (Messer and Cline 1980).

One case report has shown continued eruption and exfoliation of a severely infra-occluded maxillary deciduous second molar after using orthodontic appliances to create space around the tooth (Ponduri et al. 2009). However, this must be considered unusual and normally, ankylosed teeth cannot be moved using orthodontic force (Mitchell and West 1975). An ankylosed tooth is a difficult circumstance to manage in an orthodontic treatment plan. If surgical luxation is not successful the only remaining way to bring the tooth into correct alignment is to move the tooth with the alveolar bone using a segmental osteotomy and distraction of this segment. This is usually considered for ankylosed incisors in which orthodontic space closure is more difficult and disadvantageous than in the case of a primary molar. Various methods of this technique show success but these are isolated case reports (Medeiros and Bezerra 1997; Isaacson et al. 2001; Kofod et al. 2005; Alcan 2006). When all of these methods prove unsuccessful, extraction of the ankylosed tooth may be required.

5.5.6 Experimentally induced ankylosis

Ankylosis may be induced in an animal model in a laboratory setting. Studies using monkeys and dogs are limited in their possibilities because of costs, duration and ethical considerations. Therefore, researchers have looked to develop a method applicable to smaller research animals such as rats (Hellsing et al. 1993).

Removal and replantation of molars has been employed to generate dentoalveolar ankylosis in rats (Hellsing et al. 1993). Rat molars were extracted and the PDL was devitalised by submerging the tooth in 10% Dakin's solution or leaving to air dry before the teeth were replanted. Storage of the molars in Dakin's solution for 5 minutes before replantation resulted in the highest incidence of molar immobility (70%). Immobility as a

sign of ankylosis was established after 2 weeks and lasted until the 6th week when the teeth became mobile again. Histologically the ankylosed teeth showed replacement of the PDL with bone in addition to resorption of either the supra-crestal or peripheral part of the root. Pulpal changes included replacement of pulpal tissues by a collagenous connective tissue or the presence of a bone-like tissue. Some teeth showed extensive root resorption, mobility, inflammation of neighbouring soft tissue and necrotic pulps with bacterial invasion during the experimental period. Using this model only 17 of 37 rat molars became immobile illustrating the difficulty in reliably producing ankylosis with this method (Hellsing et al. 1993).

Dentoalveolar ankylosis may occur subsequent to intentional surgical injury as shown by Andreasen and Skougaard (1972). However, this type of ankylosis appears to be transient in nature as the surrounding periodontal membrane removed the ankylotic area by a resorption process and a new periodontal membrane was re-established.

Root canal treatment in rats using formaldehyde-containing cements has been shown to frequently cause partial and sometimes complete dentoalveolar ankylosis following necrosis of the periodontal tissues (Erausquin and Devoto 1970). A 50% formalin solution resulted in the appearance of thin bony trabeculae after 7 days and total ankylosis after 30 days (Erausquin and Devoto 1970)

A cold thermal insult applied to the occlusal surface of a rat molar has been demonstrated to induce aseptic resorption (Dreyer et al. 2000). The cold insult resulted in cell death with shrinkage and lysis of odontoblasts and other cells in the pulp as well as degeneration of the periodontal ligament and subsequent resorption of the root surface. Repair of the resorption occurred and was proportional to the level of thermal insult with shorter single exposures to cold having more rapid repair when compared to longer and multiple exposures. Ankylosis was seen in some but not all animals in this study (Dreyer et al. 2000).

5.6 Features of the rodent dentoalveolar complex

With any animal model, consideration must be given to the applicability to humans. Rodent models are able to be used for dental research as tooth shape and position between species tends to be highly conserved and significant variation is rare (Cobourne and Sharpe 2010). This is because interactions between the odontogenic epithelium and neural crest derived ectomesenchyme are mediated by a small number of signalling molecule families under close genetic control (Cobourne and Sharpe 2010). The rat is a good model as the rat molar has similar anatomical, genetic, radiographic and histological aspects to that of a human (Klausen 1991)

There are differences between the human and rodent dentition. In humans, the primary incisor, canine and molar teeth undergo successional replacement, whilst an accessional permanent molar dentition is added as the posterior jaw dimension increases (Cobourne and Sharpe 2010). In the rodent dentition, tooth replacement does not occur and the animals develop only a single primary dentition. The rodent dentition is also highly reduced in the number of teeth with each quadrant having only a single incisor tooth and three molars separated by a large edentulous region (Cobourne and Sharpe 2010).

Human teeth exhibit physiological mesial drift (Moorrees et al. 1969) whilst rat molars drift distally throughout life (Kraw and Enlow 1967) with the distal alveolar walls characterised by resorption (Milne et al. 2009). In rodents the inter-radicular bone is of the woven or cancellous type composed of osseous trabeculae enclosing a network of vascular channels, some of which are continuous with the PDL and there is no distinct lamina dura (Milne et al. 2009). Due to the small size of the jaws, secondary osteons are absent and marrow spaces are usually limited to the bone at the level of the apical third of the roots (Milne et al. 2009).

The alveolar bone in the rat shows a very high rate of activity under normal conditions compared with other bones in the rat skeleton and other species. There are 6 osteoclasts per mm of bone surface, compared to 0.1 in adult human trabecular bone. As such, the total duration of each remodelling cycle is about 6 days, as compared to 60 to 120 days in adult human trabecular bone (Vignery and Baron 1980). In addition, osteocytes in the bones of large animals, unlike in rodents, are organised into osteons (Atkins and Findlay 2012). It is possible that this additional degree of hierarchy and positioning results in increased complexity to the role of osteocytes, not observed in a rodent model (Atkins and Findlay 2012).

There are similarities between human and rat cementum. Primary cementum predominantly consists of radial collagen fibres in both species. Secondary human and rat cementum can be represented as a woven fabric with wide radial and narrower circumferential collagen fibres (Ho et al. 2009). Both species have cementum attached to root dentin via collagen fibre bridges. Cementum and the cemento-dentinal junction from a 9- to 12-month-old rat is more mineralised, with a higher packing density, and a noticeably decreased collagen fibre hydration when compared with a physiologically equivalent 40 to 55 year old human (Ho et al. 2009).

5.7 References

- Adamson, K., 1952. The problem of impacted teeth in orthodontics. *Australian Dental Journal*, 56, pp.74–84.
- Akatsu, T. et al., 1998. Osteoclastogenesis inhibitory factor suppresses osteoclast survival by interfering in the interaction of stromal cells with osteoclast. *Biochemical and biophysical research communications*, 250(2), pp.229–34.
- Alcan, T., 2006. A Miniature Tooth-borne Distractor for the Alignment of Ankylosed Teeth. *The Angle Orthodontist*, 76(1), pp.77–83.
- Al-Dujaili, S.A. et al., 2011. Apoptotic osteocytes regulate osteoclast precursor recruitment and differentiation in vitro. *Journal of cellular biochemistry*, 112(9), pp.2412–23.
- Allan, E.H. et al., 2008. EphrinB2 Regulation by PTH and PTHrP Revealed by Molecular Profiling in Differentiating Osteoblasts. *Journal of bone and mineral research*, 23(8), pp.1170–1181.
- Anderson, D.M. et al., 1997. A homologue of the TNF receptor and its ligand enhance T-cell growth and dendritic-cell function. *Nature*, 390(6656), pp.175–9.
- Andersson, L. et al., 1984. Tooth ankylosis. *International Journal of Oral Surgery*, 13, pp.423–431.
- Andlaw, R., 1974. Submerged Deciduous Molars. A Review, with Special Reference to the Rationale of Treatment. *Journal of the International Association of Dentistry for Children*, 5, pp.59–66.
- Andreasen, J.O., 1975. Periodontal healing after replantation of traumatically avulsed human teeth. Assessment by mobility testing and radiography. *Acta Odontologica Scandinavica*, 33, pp.325–335.
- Andreasen, J.O. et al., 2006. Traumatic intrusion of permanent teeth. Part 1. An epidemiological study of 216 intruded permanent teeth. *Dental traumatology*, 22(2), pp.83–9.
- Andreasen, J.O. & Skougaard, M.R., 1972. Reversibility of surgically induced dental ankylosis in rats. *International Journal of Oral Surgery*, 1, pp.98–102.
- Arai, F. et al., 1999. Commitment and differentiation of osteoclast precursor cells by the sequential expression of c-Fms and receptor activator of nuclear factor kappa β (RANK) receptors. *The Journal of experimental medicine*, 190(12), pp.1741–54.

- Atkins, G.J. & Findlay, D.M., 2012. Osteocyte regulation of bone mineral: a little give and take. *Osteoporosis international*, 23(8), pp.2067–79.
- Aubin, J.E., 2008. Mesenchymal Stem Cells and Osteoblast Differentiation. In J. Bilezikian, L. Raisz, & T.J. Martin, eds. *Principles of Bone Biology*. Academic Press, pp. 85–107.
- Avsian-Kretchmer, O. & Hsueh, A.J.W., 2004. Comparative genomic analysis of the eight-membered ring cystine knot-containing bone morphogenetic protein antagonists. *Molecular endocrinology*, 18(1), pp.1–12.
- Baccetti, T., 1998. A controlled study of associated dental anomalies. *The Angle Orthodontist*, 68(3), pp.267–274.
- Baccetti, T., 2000. Tooth anomalies associated with failure of eruption of first and second permanent molars. *American Journal of Orthodontics and Dentofacial Orthopedics*, 118(2), pp.608–610.
- Begg, S.K. et al., 1993. Delayed Hematopoietic Development in Osteopetrotic (op/op) Mice. *Journal of Experimental Medicine*, 177(January), pp.237–242.
- Berkovitz, B.K.B., 1990. The structure of the periodontal ligament: an update. *European journal of orthodontics*, 12(1), pp.51–76.
- Van Bezooijen, R.L. et al., 2004. Sclerostin is an osteocyte-expressed negative regulator of bone formation, but not a classical BMP antagonist. *The Journal of Experimental Medicine*, 199(6), pp.805–14.
- Van Bezooijen, R.L. et al., 2009. Sclerostin in mineralized matrices and van Buchem disease. *Journal of dental research*, 88(6), pp.569–74.
- Biederman, W., 1962. Etiology and treatment of tooth ankylosis. *American journal of orthodontics*, 48(9), pp.670–684.
- Biederman, W. & Centre, R., 1956. The incidence and etiology of tooth ankylosis. *American journal of orthodontics*, 42(12), pp.921–926.
- Bikle, D.D. & Halloran, B.P., 1999. The response of bone to unloading. *Journal of Bone and Mineral Metabolism*, 17, pp.233–244.
- Bjerklin, K., Kurol, J. & Valentin, J., 1992. Ectopic eruption of maxillary first permanent molars and association with other tooth and developmental disturbances. *European Journal of Orthodontics*, 14, pp.369–375.
- Bonewald, L.F., 1999. Establishment and characterization of an osteocyte- like cell line, MLO-Y4. *Journal of bone and mineral research*, 17, pp.61–65.

- Bonewald, L.F., 2011. The amazing osteocyte. *Journal of bone and mineral research*, 26(2), pp.229–38.
- Bosshardt, D.D., 2005. Are Cementoblasts a Subpopulation of Osteoblasts or a Unique Phenotype? *Journal of dental research*, 84(5), pp.390–406.
- Boyce, B. & Xing, L., 2008. Functions of RANKL/RANK/OPG in bone modeling and remodeling. *Archives of biochemistry and biophysics*, 473(2), pp.139–46.
- Brändström, H., Jonsson, K.B., Ohlsson, C., et al., 1998a. Regulation of osteoprotegerin mRNA levels by prostaglandin E2 in human bone marrow stroma cells. *Biochemical and biophysical research communications*, 247(2), pp.338–41.
- Brändström, H., Jonsson, K.B., Vidal, O., et al., 1998b. Tumor Necrosis Factor- α and - β Upregulate the Levels of Osteoprotegerin mRNA in Human Osteosarcoma MG-63 Cells. *Biochemical and biophysical research communications*, 248(3), pp.454–457.
- Bucay, N. et al., 1998. Osteoprotegerin-Deficient Mice Develop Early Onset Osteoporosis and Arterial Calcification. *Genes & development*, 12(9), pp.1260–8.
- Van Buchem, F., Hadders, H. & Ubbens, R., 1955. An uncommon familial systemic disease of the skeleton: Hyperostosis corticalis generalisata familiaris. *Acta Radiologica*, 44, pp.109–120.
- Burgess, T.L. et al., 1999. The ligand for osteoprotegerin (OPGL) directly activates mature osteoclasts. *The Journal of cell biology*, 145(3), pp.527–38.
- Butler, W. et al., 1975. Proteins of the periodontium. *Journal of Biological Chemistry*, 250(23), pp.8907–8912.
- Campbell, K.M., Casas, M.J. & Kenny, D.J., 2005. Ankylosis of Traumatized Permanent Incisors: Pathogenesis and Current Approaches to Diagnosis and Management. *Journal of the Canadian Dental Association*, 71(10), pp.763–768.
- Chambers, T.J., Darby, J.A. & Fuller, K., 1985. Mammalian collagenase predisposes bone surfaces to osteoclastic resorption. *Cell and tissue research*, 241(3), pp.671–5.
- Cho, M.I. & Garant, P., 2000. Development and general structure of the periodontium. *Periodontology 2000*, 24, pp.9–27.
- Choi, H.Y. et al., 2009. Lrp4, a novel receptor for Dickkopf 1 and sclerostin, is expressed by osteoblasts and regulates bone growth and turnover in vivo. *PLoS one*, 4(11), p.e7930.

- Clarke, B., 2008. Normal bone anatomy and physiology. *Clinical journal of the American Society of Nephrology*, 3 Suppl 3, pp.S131–9.
- Cobourne, M.T. & Sharpe, P.T., 2010. Making up the numbers: The molecular control of mammalian dental formula. *Seminars in cell & developmental biology*, 21(3), pp.314–24.
- Collin-Osdoby, P. et al., 2001. Receptor activator of NF-kappa β and osteoprotegerin expression by human microvascular endothelial cells, regulation by inflammatory cytokines, and role in human osteoclastogenesis. *The Journal of biological chemistry*, 276(23), pp.20659–72.
- Crona-Larsson, G., Bjarnason, S. & Norén, J.G., 1991. Effect of luxation injuries on permanent teeth. *Endodontics & Dental Traumatology*, 7, pp.199–206.
- Dai, X.-M. et al., 2004. Osteoclast deficiency results in disorganized matrix, reduced mineralization, and abnormal osteoblast behavior in developing bone. *Journal of bone and mineral research*, 19(9), pp.1441–51.
- Dixon, D., 1963. Observations on submerging deciduous molars. *Dental Pract*, 13, pp.303–315.
- Dobnig, H. & Turner, R.T., 1995. Evidence that Intermittent Treatment with Parathyroid Hormone Increases Bone Formation in Adult Rats by Activation of Bone Lining Cells. *Endocrinology*, 136(8), pp.3632–3638.
- Doty, S.B., 1981. Morphological Evidence of Gap Junctions Between Bone Cells. *Calcified Tissue International*, 33, pp.509–512.
- Dougall, W.C. et al., 1999. RANK is essential for osteoclast and lymph node development. *Genes and Development*, 13, pp.2412–2424.
- Dreyer, C., Pierce, A. & Lindskog, S., 2000. Hypothermic insult to the periodontium: a model for the study of aseptic tooth resorption. *Endodontics & Dental Traumatology*, 16, pp.9–15.
- Ducy, P. et al., 1996. Increased bone formation in osteocalcin-deficient mice. *Nature*, 382, pp.448–452.
- Ekim, S. & Hatibovic-Kofman, S., 2001. A treatment decision-making model for infra-occluded primary molars. *International Journal of Paediatric Dentistry*, 11, pp.340–346.
- Epker, B.N. & Frost, H.M., 1965a. A histological study of remodeling at the periosteal, haversian canal, cortical endosteal, and trabecular endosteal surfaces in human rib. *Anatomical Record*, 152, pp129-135

- Epker, B.N. & Frost, H.M. 1965b. Correlation of bone resorption and formation with the physical behavior of loaded bone. *Journal of Dental Research*, 44, pp.33-41
- Erausquin, J. & Devoto, F.C., 1970. Alveolodental ankylosis induced by root canal treatment in rat molars. *Oral Surgery*, 30(1), pp.105–116.
- Everts, V. et al., 2002. The Bone Lining Cell: Its Role in Cleaning Howship's Lacunae and Initiating Bone Formation. *Journal of bone and mineral research*, 17(1), pp.77–90.
- Foster, B.L., 2012. Methods for studying tooth root cementum by light microscopy. *International journal of oral science*, 4(3), pp.119–28.
- Friedenstein, A.J., Chailakhyan, R.K. & Gerasimov, U. V, 1987. Bone marrow osteogenic stem cells: in vitro cultivation and transplantation in diffusion chambers. *Cell and Tissue Kinetics*, 20(3), pp.263–272.
- Fujiyama, K. et al., 2004. Denervation Resulting in Dento-Alveolar Ankylosis Associated with Decreased Malassez Epithelium. *Journal of Dental Research*, 83(3), pp.625–629.
- Garib, D.G., Peck, S. & Gomes, S.C., 2009. Increased occurrence of dental anomalies associated with second-premolar agenesis. *The Angle Orthodontist*, 79(3), pp.436–41.
- Gori, F. et al., 2000. The expression of osteoprotegerin and RANK ligand and the support of osteoclast formation by stromal-osteoblast lineage cells is developmentally regulated. *Endocrinology*, 141(12), pp.4768–76.
- Gray, C., Boyde, a & Jones, S.J., 1996. Topographically induced bone formation in vitro: implications for bone implants and bone grafts. *Bone*, 18(2), pp.115–23.
- Hattersley, G. et al., 1991. Macrophage colony stimulating factor (M-CSF) is essential for osteoclast formation in vitro. *Biochemical and biophysical research communications*, 177(1), pp.526–531.
- Hauge, E.M. et al., 2001. Cancellous bone remodeling occurs in specialized compartments lined by cells expressing osteoblastic markers. *Journal of bone and mineral research*, 16(9), pp.1575–82.
- Haynes, D.R., 2003. Osteoprotegerin expression in synovial tissue from patients with rheumatoid arthritis, spondyloarthropathies and osteoarthritis and normal controls. *Rheumatology*, 42(1), pp.123–134.
- Hecova, H. et al., 2010. A retrospective study of 889 injured permanent teeth. *Dental traumatology*, 26(6), pp.466–75.

- Hellsing, E., Alatli-Kut, I. & Hammarstrom, L., 1993. Experimentally induced dento-alveolar ankylosis in rats. *International Endodontic Journal*, 26, pp.93–98.
- Henriksen, K. et al., 2009. Local communication on and within bone controls bone remodeling. *Bone*, 44(6), pp.1026–33.
- Hens, J.R. et al., 2005. TOPGAL mice show that the canonical Wnt signaling pathway is active during bone development and growth and is activated by mechanical loading in vitro. *Journal of bone and mineral research*, 20(7), pp.1103–13.
- Hill, P.A., 1998. Bone Remodelling. *British Journal of Orthodontics*, 25, pp.101–107.
- Ho, S.P. et al., 2009. Structure, chemical composition and mechanical properties of human and rat cementum and its interface with root dentin. *Acta Biomaterialia*, 5(2), pp.707–18.
- Hofbauer, L.C. et al., 1998. Osteoprotegerin Production by Human Osteoblast Lineage Cells Is Stimulated by Vitamin D , Bone Morphogenic Protein-2, and Cytokines. *Biochemical and biophysical research communications*, 250(3), pp.776–781.
- Hofbauer, L.C. et al., 1999. Estrogen stimulates gene expression and protein production of osteoprotegerin in human osteoblastic cells. *Endocrinology*, 140(9), pp.4367–4370.
- Honma, M. et al., 2013. RANKL subcellular trafficking and regulatory mechanisms in osteocytes. *Journal of bone and mineral research*, 28(9), pp. 1936-1949
- Hsu, H. et al., 1999. Tumor necrosis factor receptor family member RANK mediates osteoclast differentiation and activation induced by osteoprotegerin ligand. *Proceedings of the National Academy of Sciences of the United States of America*, 96(7), pp.3540–3545.
- Ikeda, T. et al., 2001. Determination of Three Isoforms of the Receptor Activator of Nuclear Factor- κ B Ligand and Their Differential Expression in Bone and Thymus. *Endocrinology*, 142(4), pp.1419–1426.
- Imberman, M. et al., 1986. A reassessment of collagen half-life in rat periodontal tissues: application of the pool-expansion approach. *Journal of periodontal research*, 21(4), pp.396–402.
- Isaacson, R.J. et al., 2001. Moving an Ankylosed Central Incisor Using Orthodontics, Surgery and Distraction Osteogenesis. *The Angle Orthodontist*, 71(5), pp.411–418.
- Jackson, A. et al., 2005. Gene array analysis of Wnt-regulated genes in C3H10T1/2 cells. *Bone*, 36(4), pp.585–98.

- Jäger, A. et al., 2010. Localization of SOST/sclerostin in cementocytes in vivo and in mineralizing periodontal ligament cells in vitro. *Journal of Periodontal Research*, 45(2), pp.246–54.
- Jähn, K. & Bonewald, L., 2012. Bone Cell Biology: Osteoclasts, Osteoblasts, Osteocytes. In F.H. Glorieux, J.M. Pettifor, & H.Jüppner, eds. *Pediatric Bone: Biology & Diseases*. Academic Press, pp. 1–8.
- Jilka, R.L. et al., 1998. Osteoblast Programmed Cell Death (Apoptosis): Modulation by Growth Factors and Cytokines. *Journal of bone and mineral research*, 13(5), pp.793–802.
- Johnson, M.L., 2008. Wnt Signaling and Bone. In J. Bilezikian, L. Raisz, & T.J. Martin, eds. *Principles of Bone Biology*. Academic Press, pp. 121–137.
- Jones, S.J., Gray, C. & Boyde, A., 1994. Simulation of bone resorption-repair coupling in vitro. *Anatomy and Embryology*, 190(4), pp.339–349.
- Kamioka, H., Honjo, T. & Takano-Yamamoto, T., 2001. A Three-dimensional Distribution of Osteocyte Processes Revealed by the Combination of Confocal Laser Scanning Microscopy and Differential Interference Contrast Microscopy. *Bone*, 28(2), pp.145–149.
- Kato, Y. et al., 1997. Establishment of an osteocyte-like cell line, MLO-Y4. *Journal of bone and mineral research*, 12(12), pp.2014–23.
- Kearns, A.E., Khosla, S. & Kostenuik, P.J., 2008. Receptor activator of nuclear factor kappa β ligand and osteoprotegerin regulation of bone remodeling in health and disease. *Endocrine reviews*, 29(2), pp.155–92.
- Kennedy, O.D. et al., 2012. Activation of resorption in fatigue-loaded bone involves both apoptosis and active pro-osteoclastogenic signaling by distinct osteocyte populations. *Bone*, 50(5), pp.1115–22.
- Kjaer, I., Fink-Jensen, M. & Andreasen, J.O., 2008. Classification and sequelae of arrested eruption of primary molars. *International journal of paediatric dentistry*, 18(1), pp.11–7.
- Klausen, B., 1991. Microbiological and Immunological Aspects of Experimental Periodontal Disease in Rats: A Review Article. *Journal of Periodontology*, 62, pp.59–73.
- Klein-Nulend, J. & Bonewald, L.F., 2008. The Osteocyte. In J. Bilezikian, L. Raisz, & T.J. Martin, eds. *Principles of Bone Biology*. Academic Press, pp. 153–174.

- Knothe Tate, M.L., 2003. "Whither flows the fluid in bone?" An osteocyte's perspective. *Journal of Biomechanics*, 36(10), pp.1409–1424.
- Knothe Tate, M.L. et al., 2004. The osteocyte. *The International Journal of Biochemistry & Cell Biology*, 36(1), pp.1–8.
- Kodama, H. et al., 1991. Essential role of macrophage colony-stimulating factor in the osteoclast differentiation supported by stromal cells. *The Journal of experimental medicine*, 173(5), pp.1291–4.
- Kofod, T., Würtz, V. & Melsen, B., 2005. Treatment of an ankylosed central incisor by single tooth dento-osseous osteotomy and a simple distraction device. *American journal of orthodontics and dentofacial orthopedics*, 127(1), pp.72–80.
- Kramer, I. et al., 2010. Osteocyte Wnt/beta-catenin signaling is required for normal bone homeostasis. *Molecular and cellular biology*, 30(12), pp.3071–85.
- Kraw, A.G. & Enlow, D.H., 1967. Continuous Attachment of the Periodontal Membrane. *American Journal of Anatomy*, 120, pp.133–148.
- Kuchler, U. et al., 2014. Dental and periodontal phenotype in sclerostin knockout mice. *International Journal of Oral Science*, 6(2), pp.70–6.
- Kurata, K. et al., 2006. Bone Marrow Cell Differentiation Induced by Mechanically Damaged Osteocytes in 3D Gel-Embedded Culture. *Journal of Bone and Mineral Research*, 21(4), pp.616–625.
- Kurol, J., 1981. Infraocclusion of primary molars: an epidemiologic and familial study. *Community Dentistry and Oral Epidemiology*, 9, pp.94–102.
- Kurol, J. & Magnusson, B.C., 1984. Infraocclusion of primary molars: a histologic study. *Scandinavian Journal of Dental Research*, 92, pp.564–76.
- Kurol, J. & Olson, L., 1991. Ankylosis of primary molars — a future periodontal threat to the first permanent molars? *European journal of orthodontics*, 13, pp.404–409.
- Kurol, J. & Thilander, B., 1984. Infra-occlusion of Primary Molars with Aplasia of the Permanent Successor. A Longitudinal Study. *The Angle Orthodontist*, 54(4), pp.283–294.
- Lacey, D.L. et al., 1998. Osteoprotegerin ligand is a cytokine that regulates osteoclast differentiation and activation. *Cell*, 93(2), pp.165–76.
- Lacey, D.L. et al., 2000. Osteoprotegerin ligand modulates murine osteoclast survival in vitro and in vivo. *The American journal of pathology*, 157(2), pp.435–48.

- Lee, S.K. & Lorenzo, J. a, 1999. Parathyroid hormone stimulates TRANCE and inhibits osteoprotegerin messenger ribonucleic acid expression in murine bone marrow cultures: correlation with osteoclast-like cell formation. *Endocrinology*, 140(8), pp.3552–61.
- Leupin, O. et al., 2009. LRP4 is a novel osteoblast and osteocyte expressed specific facilitator of SOST-mediated inhibition of in vitro bone formation. *Journal of bone and mineral research*, 24 (Suppl), pp.S77.
- Li, X. et al., 2005. Sclerostin binds to LRP5/6 and antagonizes canonical Wnt signaling. *The Journal of biological chemistry*, 280(20), pp.19883–7.
- Li, X. et al., 2009. Sclerostin Antibody Treatment Increases Bone Formation, Bone Mass, and Bone Strength in a Rat Model of Postmenopausal Osteoporosis. *Journal of bone and mineral research*, 24(4), pp.578–588.
- Lin, C. et al., 2009. Sclerostin mediates bone response to mechanical unloading through antagonizing Wnt/beta-catenin signaling. *Journal of bone and mineral research*, 24(10), pp.1651–61.
- Lin, D.G. et al., 2000. Storage conditions of avulsed teeth affect the phenotype of cultured human periodontal ligament cells. *Journal of periodontal research*, 35(1), pp.42–50.
- Line, S.E., Polson, A.M. & Zander, H.A., 1974. Relationship between periodontal injury, selective cell repopulation and ankylosis. *Journal of periodontology*, 45(10), pp.725–730.
- Löe, H. & Waerhaug, J., 1961. Experimental replantation of teeth in dogs and monkeys. *Archives of oral biology*, 3(1935), pp.176–84.
- Luan, X., Ito, Y. & Diekwisch, T.G.H., 2006. Evolution and development of Hertwig's epithelial root sheath. *Developmental dynamics*, 235(5), pp.1167–80.
- Malone, J.D. et al., 1982. Recruitment of osteoclast precursors by purified bone matrix constituents. *The Journal of cell biology*, 92(1), pp.227–30.
- Martin, R.B., 2000. Does Osteocyte Formation Cause the Nonlinear Refilling of Osteons? *Bone*, 26(1), pp.71–78.
- McCulloch, C., 1995. Origins and functions of cells essential for periodontal repair: the role of fibroblasts in tissue homeostasis. *Oral Diseases*, 1, pp.271–278.
- Medeiros, P.J. & Bezerra, A.R., 1997. Treatment of an ankylosed central incisor by single-tooth dento-osseous osteotomy. *American Journal of Orthodontics and Dentofacial Orthopedics*, 112, pp.496–501.

- Melcher, A., 1970. Repair of Wounds in the Periodontium of the Rat. Influence of the Periodontal Ligament on Osteogenesis. *Archives of Oral Biology*, 15, pp.1183–1204.
- Messer, L.B. & Cline, J.T., 1980. Ankylosed primary molars: Results and treatment recommendations from an eight-year longitudinal study. *Pediatric Dentistry*, 2(1), pp.37–47.
- Milne, T.J. et al., 2009. Induction of osteopenia during experimental tooth movement in the rat: alveolar bone remodelling and the mechanostat theory. *European journal of orthodontics*, 31(3), pp.221–31.
- Mitchell, D.L. & West, J.D., 1975. Attempted orthodontic movement in the presence of suspected ankylosis. *American Journal of Orthodontics*, 68(4), pp.404–411.
- Mizuno, A et al., 1998. Severe osteoporosis in mice lacking osteoclastogenesis inhibitory factor/osteoprotegerin. *Biochemical and biophysical research communications*, 247(3), pp.610–5.
- Moester, M.J.C. et al., 2010. Sclerostin: current knowledge and future perspectives. *Calcified tissue international*, 87(2), pp.99–107.
- Moorrees, C.F.A. et al., 1969. Growth studies of the dentition: A review. *American Journal of Orthodontics*, 55(5), pp.600–616.
- Mulcahy, L.E. et al., 2011. RANKL and OPG activity is regulated by injury size in networks of osteocyte-like cells. *Bone*, 48(2), pp.182–8.
- Nakashima, T. et al., 2011. Evidence for osteocyte regulation of bone homeostasis through RANKL expression. *Nature medicine*, 17(10), pp.1231–4.
- Nanci, A. & Bosshardt, D.D., 2006. Structure of periodontal tissues in health and disease. *Periodontology 2000*, 40, pp.11–28.
- Nishiyama, Y. et al., 2015. Changes in the spatial distribution of sclerostin in the osteocytic lacuno-canalicular system in alveolar bone due to orthodontic forces, as detected on multimodal confocal fluorescence imaging analyses. *Archives of Oral Biology*, 60(1), pp.45–54.
- Noble, B.S. et al., 2003. Mechanical loading: biphasic osteocyte survival and targeting of osteoclasts for bone destruction in rat cortical bone. *American journal of physiology. Cell physiology*, 284(4), pp.C934–43.
- O'Brien, E. a, Williams, J.H. & Marshall, M.J., 2000. Osteoprotegerin ligand regulates osteoclast adherence to the bone surface in mouse calvaria. *Biochemical and biophysical research communications*, 274(2), pp.281–90.

- Olesen, P., Ledet, T. & Rasmussen, L.M., 2005. Arterial osteoprotegerin: increased amounts in diabetes and modifiable synthesis from vascular smooth muscle cells by insulin and TNF-alpha. *Diabetologia*, 48(3), pp.561–8.
- Orlowski, W. a., 1978. Biochemical study of collagen turnover in rat incisor periodontal ligament. *Archives of Oral Biology*, 23(12), pp.1163–1165.
- Padhi, D. et al., 2011. Single-dose, placebo-controlled, randomized study of AMG 785, a sclerostin monoclonal antibody. *Journal of bone and mineral research*, 26(1), pp.19–26.
- Palumbo, C., 1986. A three-dimensional ultrastructural study of osteoid-osteocytes in the tibia of chick embryos. *Cell and tissue research*, 246, pp.125–131.
- Parfitt, A.M., 2001. The bone remodeling compartment: a circulatory function for bone lining cells. *Journal of bone and mineral research*, 16(9), pp.1583–5.
- Peck, S., 2009. Dental Anomaly Patterns (DAP). *The Angle Orthodontist*, 79(5), pp.1015–1016.
- Ponduri, S., Birnie, D.J. & Sandy, J.R., 2009. Infra-occlusion of secondary deciduous molars - an unusual outcome. *Journal of Orthodontics*, 36, pp.186–189.
- Poole, K.E.S. et al., 2005. Sclerostin is a delayed secreted product of osteocytes that inhibits bone formation. *FASEB journal*, 19(13), pp.1842–4.
- Raghoobar, G. et al., 1989. Secondary retention of permanent molars: a histologic study. *Oral Pathology*, 18(8), pp.427–431.
- Rippin, J.W., 1976. Collagen turnover in the periodontal ligament under normal and altered functional forces. I. Young rat molars. *Journal of Periodontal Research*, 11, pp.101–107.
- Roberts, W.E. & Chamberlain, J.G., 1978. Scanning electron microscopy of the cellular elements of rat periodontal ligament. *Archives of oral biology*, 23(7), pp.587–9.
- Robling, A.G. et al., 2008. Mechanical stimulation of bone in vivo reduces osteocyte expression of Sost/sclerostin. *The Journal of biological chemistry*, 283(9), pp.5866–75.
- Roodman, G.D., 1996. Advances in Bone Biology: The Osteoclast. *Endocrine Reviews*, 17(4), pp.308–332.
- Saffar, J.L., Lasfargues, J.J. & Cherruau, M., 1997. Alveolar bone and the alveolar process: the socket that is never stable. *Periodontology 2000*, 13, pp.76–90.

- Sanmuganathan, D., 2011. *The role of the osteocyte in orthodontic tooth movement in the rat dento-alveolar complex*. Doctor of Clinical Dentistry thesis. The University of Adelaide, South Australia
- Schwartz, Z. et al., 2000. Osteoblast proliferation and differentiation on dentin slices are modulated by pretreatment of the surface with tetracycline or osteoclasts. *Journal of periodontology*, 71(4), pp.586–97.
- Semënov, M., Tamai, K. & He, X., 2005. SOST is a ligand for LRP5/LRP6 and a Wnt signaling inhibitor. *The Journal of biological chemistry*, 280(29), pp.26770–5.
- Shalish, M. et al., 2010. Increased occurrence of dental anomalies associated with infra-occlusion of deciduous molars. *The Angle Orthodontist*, 80(3), pp.440–5.
- Shore, R.C. & Berkovitz, B.K.B., 1979. An ultrastructural study of periodontal ligament fibroblasts in relation to their possible role in tooth eruption and intracellular collagen degradation in the rat. *Archives of Oral Biology*, 24(2), pp.155–164.
- Simonet, W. et al., 1997. Osteoprotegerin: a novel secreted protein involved in the regulation of bone density. *Cell*, 89(2), pp.309–19.
- Sims, N.A. & Gooi, J.H., 2008. Bone remodeling: Multiple cellular interactions required for coupling of bone formation and resorption. *Seminars in cell & developmental biology*, 19(5), pp.444–51.
- Sodek, J., 1977. A comparison of the rates of synthesis and turnover of collagen and non-collagen proteins in adult rat periodontal tissues and skin using a microassay. *Archives of oral biology*, 22(12), pp.655–65.
- Sodek, J. & McKee, M.D., 2000. Molecular and cellular biology of alveolar bone. *Periodontology 2000*, 24, pp.99–126.
- Steigman, S., Koyoumdjisky-Kaye, E. & Matrai, Y., 1974. Relationship of Submerged Deciduous Molars to Root Resorption and Development of Permanent Successors. *Journal of Dental Research*, 53(1), pp.88–93.
- Steiner, D.R., 1997. Timing of Extraction of Ankylosed Teeth to Maximize Ridge Development. *Journal of Endodontics*, 23(4), pp.242–245.
- Sutherland, M.K. et al., 2004. Sclerostin promotes the apoptosis of human osteoblastic cells: a novel regulation of bone formation. *Bone*, 35(4), pp.828–35.
- Takahashi, N. et al., 2008. Osteoclast Generation. In J. Bilezikian, L. Raisz, & T. J. Martin, eds. *Principles of Bone Biology*. Academic Press, pp. 175–192.

- Tatsumi, S. et al., 2007. Targeted ablation of osteocytes induces osteoporosis with defective mechanotransduction. *Cell metabolism*, 5(6), pp.464–75.
- Taut, A.D. et al., 2013. Sclerostin antibody stimulates bone regeneration after experimental periodontitis. *Journal of Bone and Mineral Research*, 28(11), pp.2347–56.
- Theoleyre, S. et al., 2004. The molecular triad OPG/RANK/RANKL: involvement in the orchestration of pathophysiological bone remodeling. *Cytokine & growth factor reviews*, 15(6), pp.457–75.
- Truswell, A.S., 1958. Osteopetrosis with syndactyly. A morphological variant of Albers-Schonberg's disease. *The Journal of Bone and Joint Surgery*, 40B(2), pp.209–218.
- Udagawa, N. et al., 1999. Osteoblasts/stromal cells stimulate osteoclast activation through expression of osteoclast differentiation factor/RANKL but not macrophage colony-stimulating factor. *Bone*, 25(5), pp.517–523.
- Veno, P. et al., 2006. Live imaging of osteocytes within their lacunae reveals cell body and dendrite motions. *Journal of bone and mineral research*, 21(S1), pp.38–39.
- Verborgt, O. et al., 2002. Spatial Distribution of Bax and Bcl-2 in Osteocytes After Bone Fatigue: Complementary Roles in Bone Remodeling Regulation? *Journal of Bone and Mineral Research*, 17(5), pp.60–7.
- Verborgt, O., Gibson, G.J. & Schaffler, M.B., 2000. Loss of osteocyte integrity in association with microdamage and bone remodeling after fatigue in vivo. *Journal of bone and mineral research*, 15(1), pp.60–7.
- Vidal, O., Brändström, H., et al., 1998. Osteoprotegerin mRNA is expressed in primary human osteoblast-like cells: down-regulation by glucocorticoids. *The Journal of endocrinology*, 159(1), pp.191–5.
- Vidal, O., Sjogren, K., et al., 1998. Osteoprotegerin mRNA Is Increased by Interleukin-1 α in the Human Osteosarcoma Cell Line MG-63 and in Human Osteoblast-Like Cells. *Biochemical and biophysical research communications*, 248(3), pp.696–700.
- Vignery, A. & Baron, R., 1980. Dynamic Histomorphometry of Alveolar Bone Remodeling in the Adult Rat. *The Anatomical Record*, 196, pp.191–200.
- Wallace, J.A. & Vergona, K., 1990. Epithelial rests' function in replantation: Is splinting necessary in replantation? *Oral Surg Oral Med Oral Pathol*, 70(5), pp.644–649.
- Wang, H.M. et al., 1980. Specific immunohistochemical localization of type III collagen in porcine periodontal tissues using the peroxidase-antiperoxidase method. *Journal of Histochemistry & Cytochemistry*, 28(11), pp.1215–1223.

- Wijenayaka, A.R. et al., 2011. Sclerostin stimulates osteocyte support of osteoclast activity by a RANKL-dependent pathway. *PLoS one*, 6(10), p.e25900.
- Winkler, D.G. et al., 2003. Osteocyte control of bone formation via sclerostin, a novel BMP antagonist. *The EMBO journal*, 22(23), pp.6267–76.
- Wong, B.R., Josien, R., et al., 1997a. TRANCE (Tumor Necrosis Factor [TNF]-related Activation-induced cytokine), a New TNF Family Member Predominantly Expressed in T cells, is a Dendritic Cell-Specific Survival Factor. *Journal of Experimental Medicine*, 186(12), pp.2075–2080.
- Wong, B.R., Rho, J., et al., 1997b. TRANCE is a novel ligand of the tumor necrosis factor receptor family that activates c-Jun N-terminal kinase in T cells. *The Journal of biological chemistry*, 272(40), pp.25190–4.
- Xiong, J. et al., 2011. Matrix-embedded cells control osteoclast formation. *Nature medicine*, 17(10), pp.1235–41.
- Xiong, J. & O'Brien, C., 2012. Osteocyte RANKL: new insights into the control of bone remodeling. *Journal of bone and mineral research*, 27(3), pp.499–505.
- Yamamoto, T. et al., 2010. Histological review of the human cellular cementum with special reference to an alternating lamellar pattern. *Odontology*, 98(2), pp.102–9.
- Yasuda, H., Shima, N., Nakagawa, N., Mochizuki, S., et al., 1998a. Identity of osteoclastogenesis inhibitory factor (OCIF) and osteoprotegerin (OPG): a mechanism by which OPG/OCIF inhibits osteoclastogenesis in vitro. *Endocrinology*, 139(3), pp.1329–37.
- Yasuda, H., Shima, N., Nakagawa, N., Yamaguchi, K., et al., 1998b. Osteoclast differentiation factor is a ligand for osteoprotegerin/osteoclastogenesis-inhibitory factor and is identical to TRANCE/RANKL. *Proceedings of the National Academy of Sciences of the United States of America*, 95(7), pp.3597–602.
- Zhao, C. et al., 2006. Bidirectional ephrinB2-EphB4 signaling controls bone homeostasis. *Cell metabolism*, 4(2), pp.111–21.
- Zhao, S. et al., 2002. MLO-Y4 Osteocyte-Like Cells Support Osteoclast Formation and Activation. *Journal of Bone and Mineral Research*, 17(11), pp.2068–2079.

6 STATEMENT OF PURPOSE

In health, the periodontal ligament acts to keep cementum and alveolar bone from contacting each other. When they do make contact following a defect in the periodontal ligament, dentoalveolar ankylosis occurs. The presence of ankylosed teeth results in a complicated clinical situation which requires treatment and expertise from many areas of dentistry. The purpose of this research is to investigate the biological mechanisms which underlie the formation and repair of dentoalveolar ankylosis as the process is incompletely understood. Specifically this study will investigate RANKL, an essential molecule in osteoclastogenesis; and sclerostin, an osteocyte produced protein that inhibits bone formation.

6.1 Aims

- To confirm the location of RANKL and sclerostin within the rat maxillary dentoalveolar region using immunohistochemistry
- To investigate the relationship between RANKL and the different regions within the rat dentoalveolar region in an ankylosis model.
- To investigate the relationship between sclerostin and the different regions within the rat dentoalveolar region in an ankylosis model
- To investigate the change in RANKL and sclerostin expression across the varying time points.

6.2 Null Hypothesis

6.2.1 Article 1:

An applied cold insult and subsequent dentoalveolar ankylosis of a rat molar tooth does not affect the production of RANKL in the dentoalveolar complex when compared with an untreated control tooth. The amount and distribution of RANKL will not be affected.

6.2.2 Article 2:

An applied cold insult and subsequent dentoalveolar ankylosis of a rat molar tooth does not affect the expression of sclerostin within the alveolar bone when compared with an untreated control tooth. The amount and distribution of sclerostin will not be affected.

7 ARTICLE 1



Expression of RANKL in a rat model of dentoalveolar ankylosis following hypothermal insult

Written in the style of the European Journal of Orthodontics

7.1 Abstract

Background: RANKL is essential for osteoclastogenesis and is known to be produced by osteoblasts. However, recent research indicates that the osteocyte could be a major source of RANKL in supporting bone resorption. This study utilises a rat model of dentoalveolar ankylosis to investigate the expression of RANKL in the dentoalveolar complex and, particularly, in the osteocyte.

Methods: Dentoalveolar ankylosis was induced in fifteen eight week old male Sprague-Dawley rats (5 groups of 3 rats each) by application of dry ice to the upper right first molar tooth. An additional 3 rats served as untreated controls and the experimental rats were sacrificed at days 0, 4, 7, 14 and 28. Immunohistochemical detection of RANKL was performed and the number of RANKL positive and negative cells as well as the number of empty lacunae representing dead osteocytes were calculated and compared between groups.

Results: The cold insult resulted in dentoalveolar ankylosis with the periodontal ligament (PDL) almost completely replaced with bone in the furcation region of the root 14 days after injury and regeneration of the PDL noted after 28 days. Resorption of the ankylotic bone and cementum was evident in the furcation region. RANKL was detected in bone marrow stromal cells, osteoblasts and bone lining cells, osteoclasts, endothelial-like cells lining vessels, epithelial cells, odontoblasts and periodontal fibroblasts. However, clear staining in osteocytes was not evident. Epithelial rests of Malassez strongly expressed RANKL.

Conclusion: Previous research indicates a role for osteocyte derived RANKL in bone remodelling. In this model of dentoalveolar ankyloses, osteocyte-derived RANKL was not detected. ERM strongly expressed RANKL and their presence or absence may play a role in the regeneration of the PDL following dentoalveolar ankylosis.

Key words: RANKL, ankylosis, dentoalveolar, osteocyte, immunohistochemistry

7.2 Introduction

Interactions between osteoblasts and osteoclasts are essential for bone remodelling (Epker and Frost, 1965). The three cytokines required for maintenance of this tight equilibrium are osteoprotegerin (OPG), receptor activator of NF- κ B (RANK) and RANKL (RANK ligand) (Simonet et al. 1997; Yasuda et al. 1998).

RANKL is a transmembrane protein that is typically membrane bound but is also found in a soluble form (Ikeda et al. 2001). RANKL is mainly expressed via osteoblastic stromal cells but it is also expressed in a number of other cells (Table 1). RANKL is involved in numerous aspects of osteoclast differentiation and function. It has been implicated in the fusion of osteoclast precursors into multinucleated cells (Lacey et al. 1998), the differentiation of osteoclast precursors into mature osteoclasts (Lacey et al. 1998), attachment of osteoclasts to bone surfaces (O'Brien et al. 2000), osteoclast activation to resorb bone (Burgess et al. 1999; Lacey et al. 1998) and osteoclast survival by avoiding apoptosis (Lacey et al. 2000). The role of RANKL is so essential that no factor or combination of factors has been shown to restore bone resorption when RANKL is not present.

Table 1. Expression patterns of RANKL and RANK
[adapted from (Theoleyre et al. 2004)]

Molecule	Cells	Tissues
RANKL	Bone marrow stromal cells, fibroblast, mammary endothelial cells, epithelial cells, osteoblasts, osteoclasts, T lymphocytes,	Artery smooth muscle cells, bone, bone marrow, brain, heart, kidney, liver, lung, lymph nodes, mammary tissue, placenta, skeletal muscle, spleen, testes, thymus, thyroid
RANK	Dendritic cells, endothelial cells, fibroblasts, B and T lymphocytes, osteoclasts	Bone, bone marrow, brain, heart, kidney, liver, lung, mammary tissue, skeletal muscle, skin

RANK is the receptor that mediates all known activity for RANKL (Anderson et al. 1997). The interaction of RANK and RANKL is thought to cause oligomerisation of RANK and subsequent activation of several signal transduction pathways which result in the transcription of osteoclastogenic genes (Figure 1). The activation of the above pathways might be prevented by OPG (Kearns et al. 2008).

OPG is a secreted protein with no transmembrane domain and no direct signalling properties (Simonet et al. 1997). OPG functions as a soluble decoy receptor that binds to RANKL, therefore, precluding RANKL from binding to, and activating RANK (Kearns et al. 2008). The important role that OPG plays in bone remodelling can be demonstrated when OPG is deleted from mice. These animals showed a decrease in bone mineral density which became more severe with increasing age in addition to an increase in bone turnover (Bucay et al. 1998; Mizuno et al. 1998).

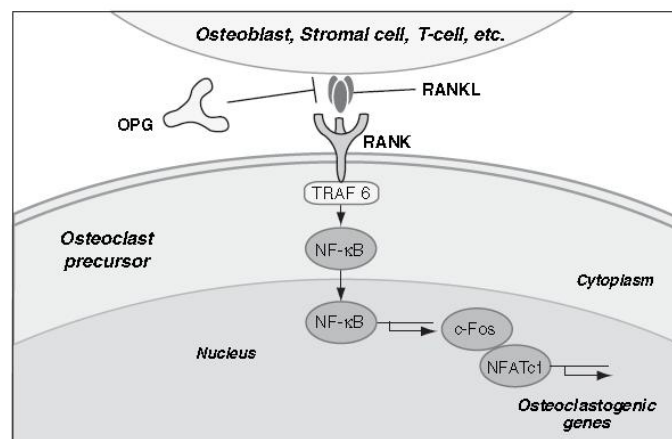


Figure 1. Essential signaling pathways activated by RANKL interactions with RANK [from (Kearns et al. 2008)]

Osteocytes have a central role in the bone remodeling process, particularly in the activation of bone resorption and may have a central role in bone metabolism. Osteocytes are well placed in bone to sense mechanical stress and strain and osteocyte apoptosis following injury has been shown to induce osteoclastogenesis and bone resorption (Noble et al. 2003; Gu et al. 2005; Kurata et al. 2006; Henriksen et al. 2009). It has been demonstrated that osteocytes secrete receptor activator of NF- κ B ligand (RANKL) and macrophage colony stimulating factor (M-CSF) which would enable them to support osteoclastogenesis (Zhao et al. 2002).

Following microdamage, osteocytes may be divided into two groups represented by those near and those neighbouring the injury. The nearby osteocytes apoptose and release pro-osteoblastic signals whereas the neighbouring healthy osteocytes released protective anti-apoptotic signals and upregulated factors such as M-CSF and VEGF whilst downregulating OPG (Verborgt et al. 2002). In conflicting studies, RANKL has been shown to be upregulated in association with both apoptotic and non-apoptotic osteocytes (Al-Dujaili et al. 2011; Kennedy et al. 2012). The difference may be due to study design as one was in vivo (Al-Dujaili et al. 2011) and the other in vitro (Kennedy et al. 2012). The essential role osteocytes play can be demonstrated when they are ablated (Tatsumi et al. 2007). The lack of a functioning osteocyte network led to decreased bone formation, impaired osteoblast mineralising function and decreased bone strength (Tatsumi et al. 2007).

Two independent studies have put forward the proposition that osteocytes, not osteoblasts, are a major source of RANKL (Nakashima et al. 2011; Xiong and O'Brien 2012).

Nakashima et al. (2011) purified osteoblast and osteocyte populations and demonstrated that RANKL levels were significantly higher in osteocytes when compared with osteoblasts and other mesenchymal cells. The researchers also co-cultured osteoclast precursor cells with either osteoblasts or osteocytes in the presence of 1,25-dihydroxy vitamin D₃ (1,25(OH)₂D₃) and prostaglandin E₂ (PGE₂), which revealed that

the osteocytes had a stronger capacity to support osteoclastogenesis (Nakashima et al. 2011). When RANKL was specifically deleted in osteocytes (but not in osteoblasts) the mice initially showed no abnormalities but after 12 weeks they showed an osteopetrotic phenotype with a reduction in the number of osteoclasts. As this phenotype developed post-natally, the authors concluded that RANKL expressed by osteocytes contributes to bone remodelling after birth rather than embryonic skeletal development.

Xiong and colleagues (2011) generated mice in which RANKL was conditionally deleted in various genetically-defined cell populations corresponding to different stages of osteocyte and chondrocyte differentiation. Mice with deletion of RANKL had increasing bone mineral density with increasing age. Deletion of RANKL led to the femoral cancellous bone volume doubling and the osteoclast surface decreasing by 75%. Xiong et al. (2011) concluded that RANKL produced by osteocytes is responsible for most of the osteoclastogenesis in cancellous bone.

Osteocytes are also the major source of sclerostin, a negative regulator of osteoblasts which inhibits bone formation (van Bezooijen et al. 2004; Poole et al. 2005). Wijenayaka and colleagues (2011) have suggested that sclerostin has a paracrine and/or autocrine action on the osteocyte. Exogenous recombinant sclerostin (rhSCL) dose-dependently upregulated the expression of RANKL mRNA and downregulated the expression of OPG, which caused a largely RANKL mediated change in the RANKL: OPG mRNA ratio in cultures of human bone-derived osteocyte-like cells and in MLO-Y4 cells (the mouse osteocyte-like cell line). Osteoclastic resorption was demonstrated to have increased by 7-fold with an increase in both the number and size of osteoclasts. As the rhSCL did not induce apoptosis of MLO-Y4 cells, the increase in osteoclastic activity was not due to dying osteocytes. Addition of recombinant OPG suppressed the effects of rhSCL on both osteoclast formation and activity, demonstrating that RANKL signalling was essential for the sclerostin effect. This may mean that in situations where sclerostin is increased, a catabolic response may occur, promoting osteoclastogenesis by its effect on osteocytes in a RANKL-dependent manner (Wijenayaka et al. 2011).

Dentoalveolar ankylosis occurs when tooth cementum fuses with the alveolar bone (Kuroi 1981). Affected teeth often present at a level below the occlusal plane and are clinically referred to as submerged or infra-occluded teeth. This clinical presentation is a result of the inability of the tooth to follow the normal vertical development of the neighbouring teeth. The condition is commonly found in two clinical situations: cases of infra-occlusion mainly affecting deciduous teeth and in association with trauma or impaction in the permanent dentition. In cases of trauma, it is frequently observed after re-implantation of avulsed teeth.

Normally the periodontal ligament resists induction to osteogenesis via cell signalling systems. These systems act to measure and maintain the width of the PDL, ensuring the root and alveolar bone remain separate (Melcher 1970; McCulloch 1995). When dental trauma occurs this homeostasis is disrupted. It has been shown that the source of the cells that repopulate a PDL defect following trauma determines whether or not ankylosis occurs as part of the healing and repair process (Erasquin and Devoto 1970; Lin et al. 2000; Melcher 1970; Line et al. 1974). If the defect is repopulated with cells from outside the PDL (such as the alveolar bone), then osteoclasts and osteogenesis occur and the PDL defect heals with the formation of ankylotic bone.

Previous research has shown that the expression of RANKL may have increased in the region of blood vessels in the ankylotic area following hypothermal insult in a rat model (Curl et al. 2014) but the alveolar bone, in particular the osteocytes, have not been investigated. Research has suggested that osteocytes may be a major source of RANKL but this has not been investigated in a model of dentoalveolar ankylosis. The aim of this investigation is to determine if the production and expression of RANKL in the dentoalveolar region, particularly in the osteocyte, is altered during the formation of dentoalveolar ankylosis using a rat model. The null hypothesis states that 'an applied cold insult and subsequent ankylosis does not affect the production of RANKL in the dentoalveolar complex. The amount and distribution of RANKL will not be affected'.

7.3 Methods and Materials

The experimental procedures were reviewed and approved by the University of Adelaide Animal Ethics Committee for a previous study (M-083-2007).

Experimental procedure:

The experimental sample consisted of 18 eight week old, male, Sprague-Dawley rats. Fifteen rats were subject to a hypothermal insult and 3 rats served as an untreated control. The rats were anaesthetised before the procedure and sacrificed using an intramuscular injection of Hypnorm® (fentanyl citrate 0.315mg/ml and fluanisone 10mg/ml, Janssen-Cilag Ltd., High Wycombe, Buckinghamshire, UK) and Hypnovel® (midazolam hydrochloride 5mg/ml, Roche Products Pty Ltd., Dee Why, Australia). The anaesthetic agents were diluted in a 1:1 ratio with sterile water, combined and administered at a dosage of 2.7ml/kg of body weight. The animals were restrained in a head holding device and underwent a single 10 minute application of dry ice (compressed carbon dioxide gas at -81°C, BOC Gases, Adelaide, Australia) to the occlusal surface of the right maxillary first molar crown in order to produce aseptic necrosis within the PDL and induce ankylosis (protocol developed by Dreyer et al. 2000). The upper left first molar was untreated and provided an internal control.

The rats were sacrificed on days 0, 4, 7, 14 and 28 respectively. The 3 animals in the control group did not undergo hypothermal insult and were also sacrificed on day 0. Following administration of anaesthetic, the rats were sacrificed via cardiac perfusion with 4% paraformaldehyde fixative. On completion of perfusion the maxillae were dissected out and immersed in the same fixative for 24 hours and then stored in phosphate buffered saline (PBS) at pH 7.3 for a further 24 hours. Specimens were decalcified using 4% ethylenediaminetetraacetic acid (EDTA) solution and were dehydrated using a graded alcohol series and embedded in paraffin wax. The paraffin blocks were mounted onto a Leitz 1512 Microtome (Leica, Nussloch, Germany) and 5µm sections were cut coronally through the root furcation. Sections were mounted onto aminopropyltriethoxysilane (APTS) coated glass slides.

Randomly selected sections were stained with haematoxylin and eosin (H and E) to check for orientation, identification of ankylotic areas and suitability for immunohistological staining. The preceding experimental protocol and H and E staining was carried out as part of a prior study (Tan 2011).

Immunohistochemistry (IHC):

Fifty-four sections were randomly selected from within the region of the furcation as previous research has shown this area to have the most ankylosis (Dreyer et al. 2000). Antibody optimisation was performed prior to immunohistological staining to determine the optimal method for antigen retrieval and antibody dilution required to achieve minimal background staining and optimal antibody specific staining. As a negative control the RANKL antibody was omitted. The positive control used was human liver tissue.

The sections underwent paraffin removal and were then immersed in 10 mM tris-EDTA buffer pH 9.0 in a 65°C water bath for 10 minutes before cooling for 20 minutes, followed by washing with 1x PBS three times for 5 minutes. The immunohistological staining protocol was based on the alkaline phosphatase (AP) reaction using the ImPRESS AP rabbit reagent kit (Cat No. MP-5401, Vector Laboratories, USA). Ready to use horse blocking serum (yellow bottle in the kit) was applied to all sections and incubated for 30 minutes. Excess solution was removed and no washing was performed. The primary RANKL antibody was prepared (rabbit polyclonal anti-mouse antibody [ab62516, Abcam, United Kingdom] 2µg/ml in 1x Tris-PBS and applied to all sections except negative controls. Sections were incubated at room temperature overnight in a wet chamber. The sections were then washed in 1x Tris-PBS 3 times for 5 minutes and the secondary antibody (blue bottle in the kit) was applied and left for 30 minutes at room temperature. The sections were again washed in 1x Tris-PBS 3 times for 5 minutes before development of colour. Vector® Red (Vector Red Substrate Kit, SK-5100, Vector Laboratories, USA) was applied to all sections for 10 minutes at room temperature, covered, in a dark cupboard. Sections were then rinsed in MilliQ water,

counter-stained with haematoxylin (10 seconds) and lithium carbonate (30 seconds) before final washing with tap water and mounting using Aquamount.

Histomorphometry:

The immuno-stained sections were digitised via a Nanozoomer Slide Scanner 2.0 series (Hamamatsu Photonics K.K. 325-6 Sunayama-cho, Hamamatsu City, Shizuoka) and viewed on a personal computer (Lenovo X220) using the Nanozoomer Digital Pathology (NDP) software. Areas were then defined to enable analysis of the sections.

Using NDP software, the periodontal ligament was divided into 5 regions of 0.01mm^2 at the furcation region and the percentage of bone within the PDL was determined to quantitatively assess the degree of ankylosis viewed at a magnification factor of 20 (Figure 2). Alveolar bone was delineated into 4 zones with zone 1 closest to the root furcation and zone 4 closest to the root apex (Figure 2). To ensure consistency of the sampling area across numerous sections, the boxes in zone 1 were placed $200\ \mu\text{m}$ from the mid-point of the furcation area of the tooth. Each zone contained 2 boxes of 0.04mm^2 . Counting of RANKL positive and negative cells as well as empty lacunae was performed at a magnification factor of 20 using Image J software 1.47v (Wayne Rasband, National Institutes of Health, USA).

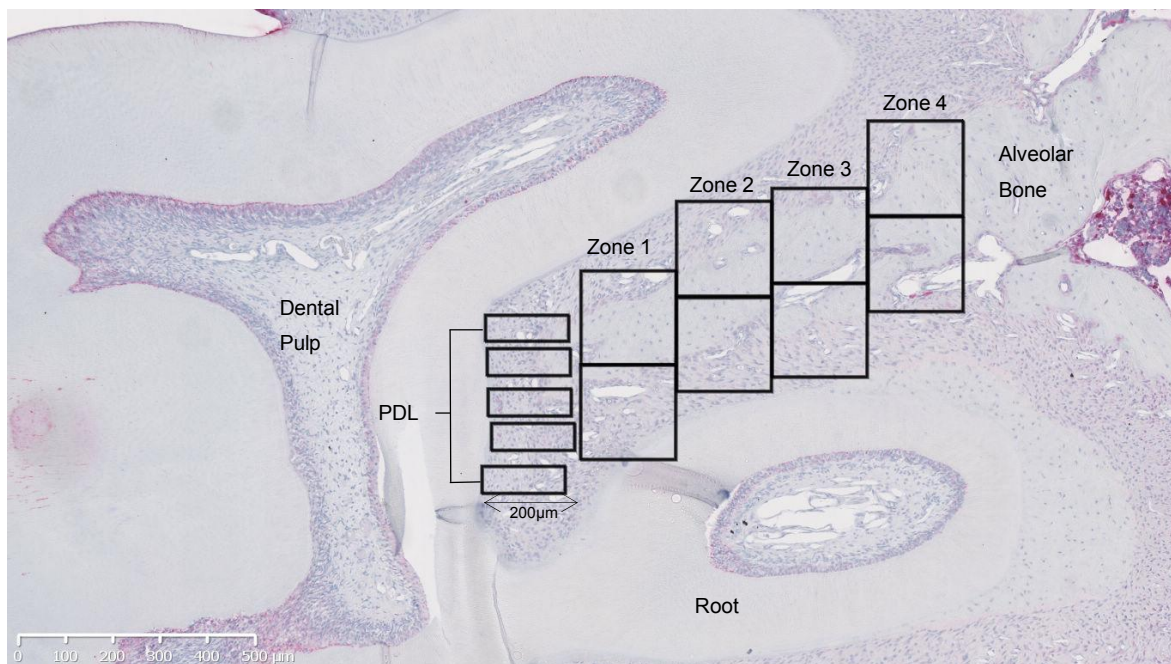


Figure 2. Sampling regions in the rat molar tooth

7.4 Results

Positive and negative controls

Positive and negative controls were performed to assess antibody specificity. The positive control was human liver tissue (Figure 3A). Negative controls were omission of the primary antibody and application of isotype control universal rabbit Ig's (catalogue number N1699, Dako Australia Pty. Ltd, NSW) (Figure 3B, C).

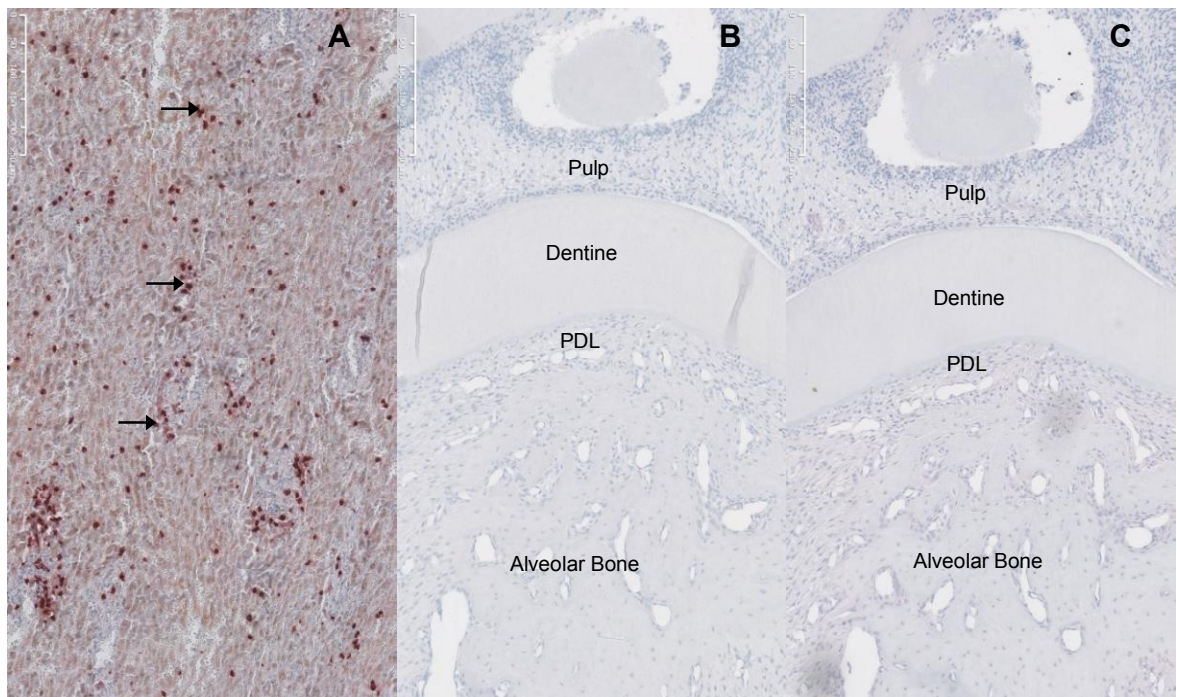


Figure 3. Positive and negative controls for RANKL

Positive control using human liver (A) showing positive RANKL staining (dark red, indicated by arrows). Negative controls showing lack of positive RANKL staining: (B) omission of primary antibody, (C) application of universal rabbit negative control. (Counterstained with H and E, x 10 magnification, ruler 0-250 μ m)

Histology

Haematoxylin and eosin stained sections were examined to assess the pulp, periodontal ligament and the alveolar bone. When the experimental tooth and the internal control tooth were compared at day 0, no differences were observed (Figure 4). The internal control teeth showed no change or loss of integrity of the pulp, PDL and alveolar bone throughout the duration of the experiment.

Pulp: At days 4 and 7, the experimental tooth showed a reduction in cellularity in the central stromal region in addition to a reduction in thickness and continuity of the odontoblast layer (Figure 5). At days 14 and 28 a distinct layer of tertiary dentine was visible (Figure 6).

PDL: The PDL was comparable to both the external and internal controls at days 0 and 4. The first signs of ankylosis were observed at day 7 in all animals (Figure 5). Invasion of bony trabeculae into the PDL resulted in a decrease in the width of the PDL in the furcation region. By day 14, widespread loss of the PDL was observed in all animals and the PDL in the furcation region had been replaced with dense ankylotic bone (Figure 6). By day 28, only one animal showed bone within the PDL and the other animals demonstrated an intact PDL which was almost indistinguishable from the internal control teeth (Figure 6). The junction between the cementum at the furcation and the newly formed PDL appeared uneven when compared with the internal control and earlier time points, suggesting evidence of resorption of the ankylotic bone. The difference in the percentage of bone within the PDL between the experimental tooth and the internal control was statistically significant at days 7 and 14 (Table 2).

Alveolar bone: The amount of alveolar bone in the furcation region increased at days 7 and 14 as the PDL was replaced with ankylotic bone (Figure 5, 6). There was an increase in the number of empty lacunae in the furcation region as the ankylotic lesion developed; however, by day 28 there was almost complete filling of the lacunae by osteocytes (Figure 6). Multi-nucleated cells were observed near the ankylotic regions at

days 7 and 28. TRAP staining was subsequently carried out to determine the presence of osteoclasts.

Table 2. Percentage of bone in the sampled area of PDL of the experimental tooth

**statistically significant difference when the experimental tooth is compared to the internal control tooth*

Day of sacrifice	% bone in PDL	P value
Day 0	8.7	1.0
Day 4	5.9	1.0
Day 7	24.9	0.033*
Day 14	73.4	<0.0001*
Day 28	21.1	0.17

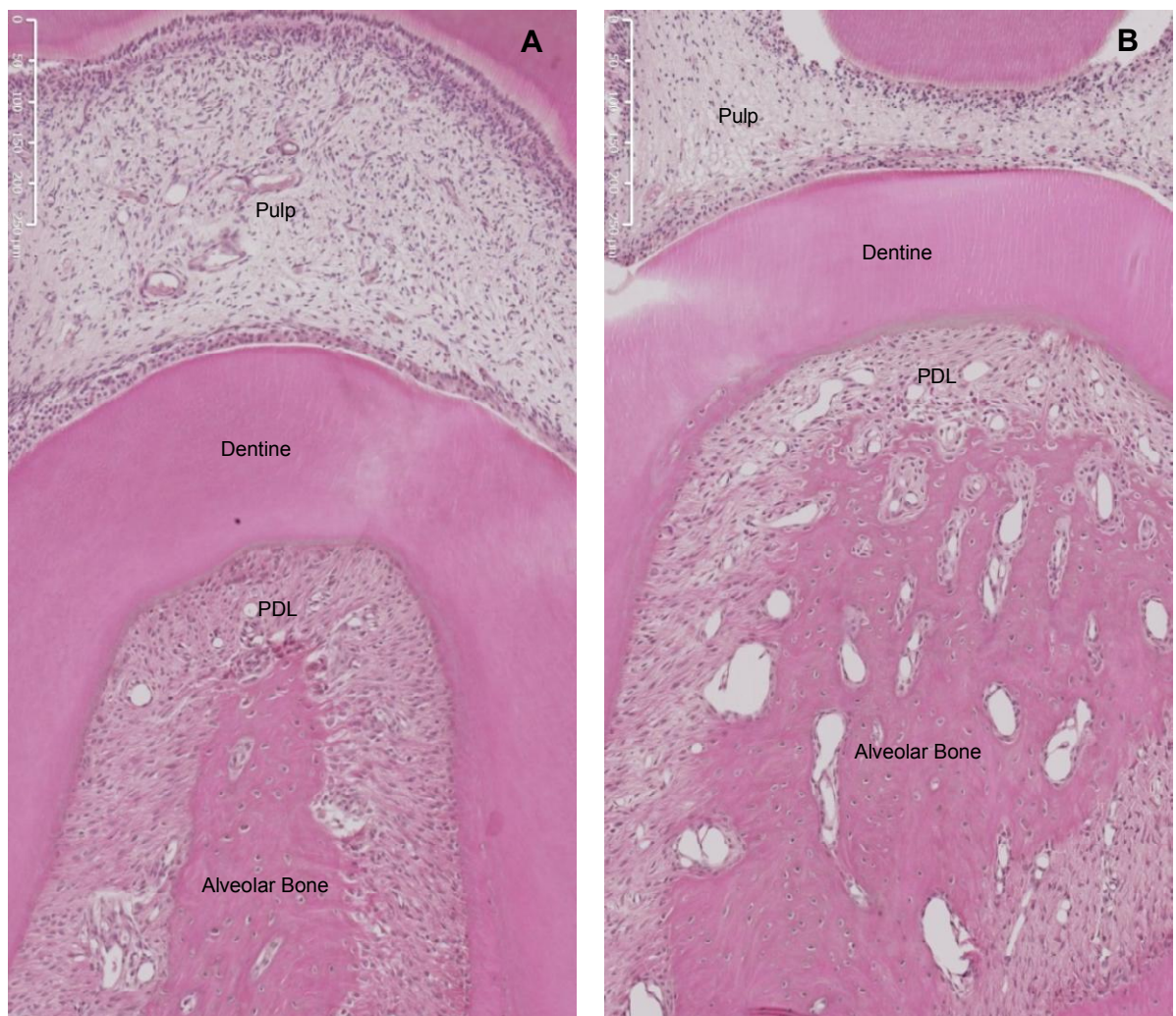


Figure 4. H and E sections of experimental right molar tooth of: (A) external control and (B) day 0 showing intact PDL and no ankylosis (x 10 magnification, ruler 0 - 250µm)

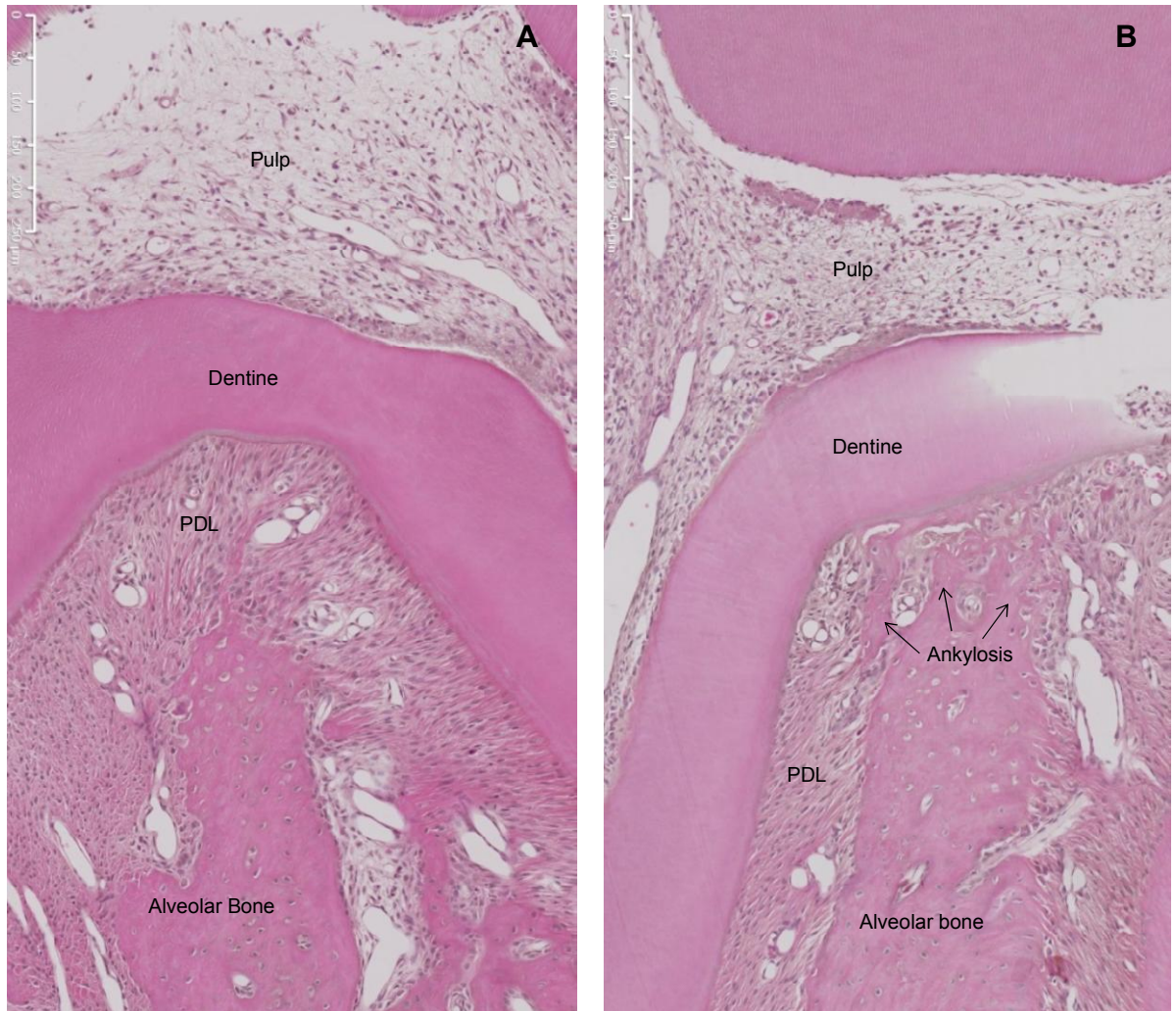


Figure 5. H and E sections of experimental right molar tooth of: (A) day 4 showing intact PDL and no ankylosis and (B) day 7 showing bony trabeculae invading the PDL (x 10 magnification, ruler 0 - 250 μ m)

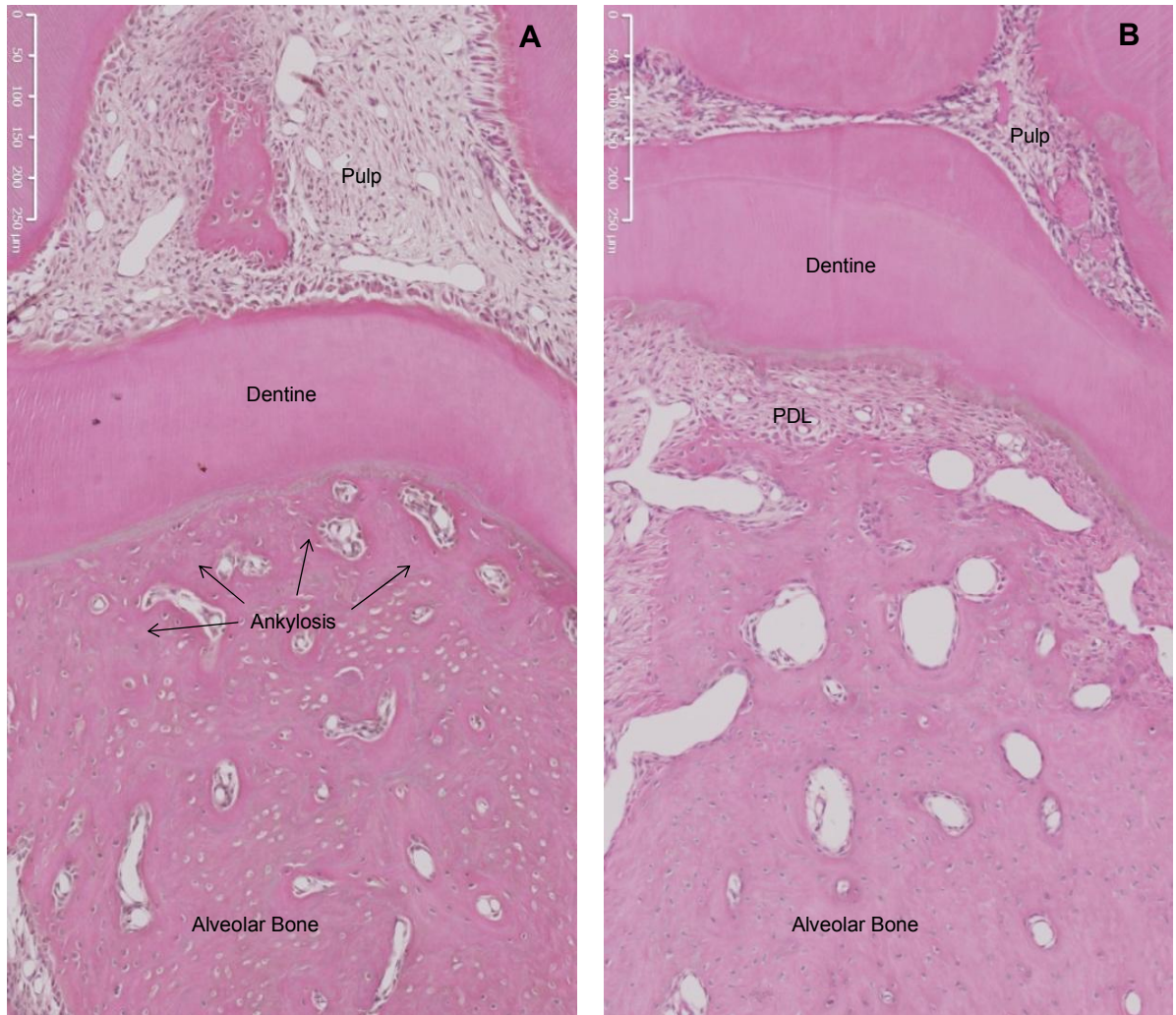


Figure 6. H and E sections of experimental right molar tooth of: (A) day 14 showing complete destruction of the PDL and (B) day 28 showing an intact PDL (x 10 magnification, ruler 0 - 250µm)

Tartrate-resistant acid phosphatase (TRAP) staining

TRAP staining was conducted to determine the presence of osteoclasts. The external control, day 4 and day 7 showed a similar expression of TRAP-positive cells. The TRAP-positive cells were associated with bone surfaces and bone marrow spaces within the alveolar bone and the PDL at the apex of the root with little expression in the furcation region (Figure 7).

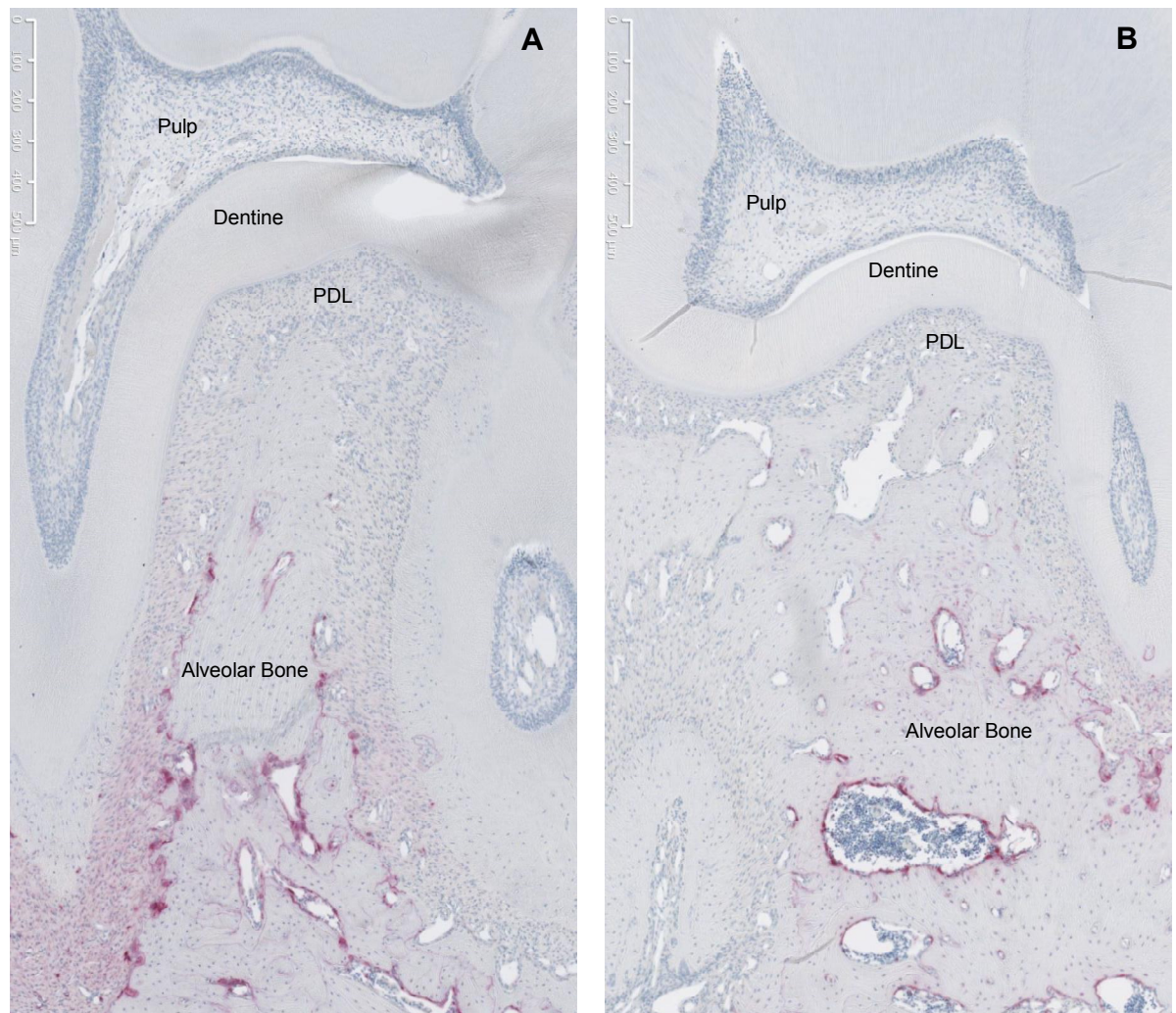


Figure 7. TRAP-positive cells (pink stain) in the external control (A) and the experimental tooth at day 0 (B). (x5 magnification, ruler 0-500 μ m)

At day 7 when the first signs of ankylosis were observed, there was an increase in expression of TRAP-positive cells in the PDL near the ankylotic region (Figure 8). At day 14 when significant ankylosis was present, there were few TRAP-positive cells (Figure 8).

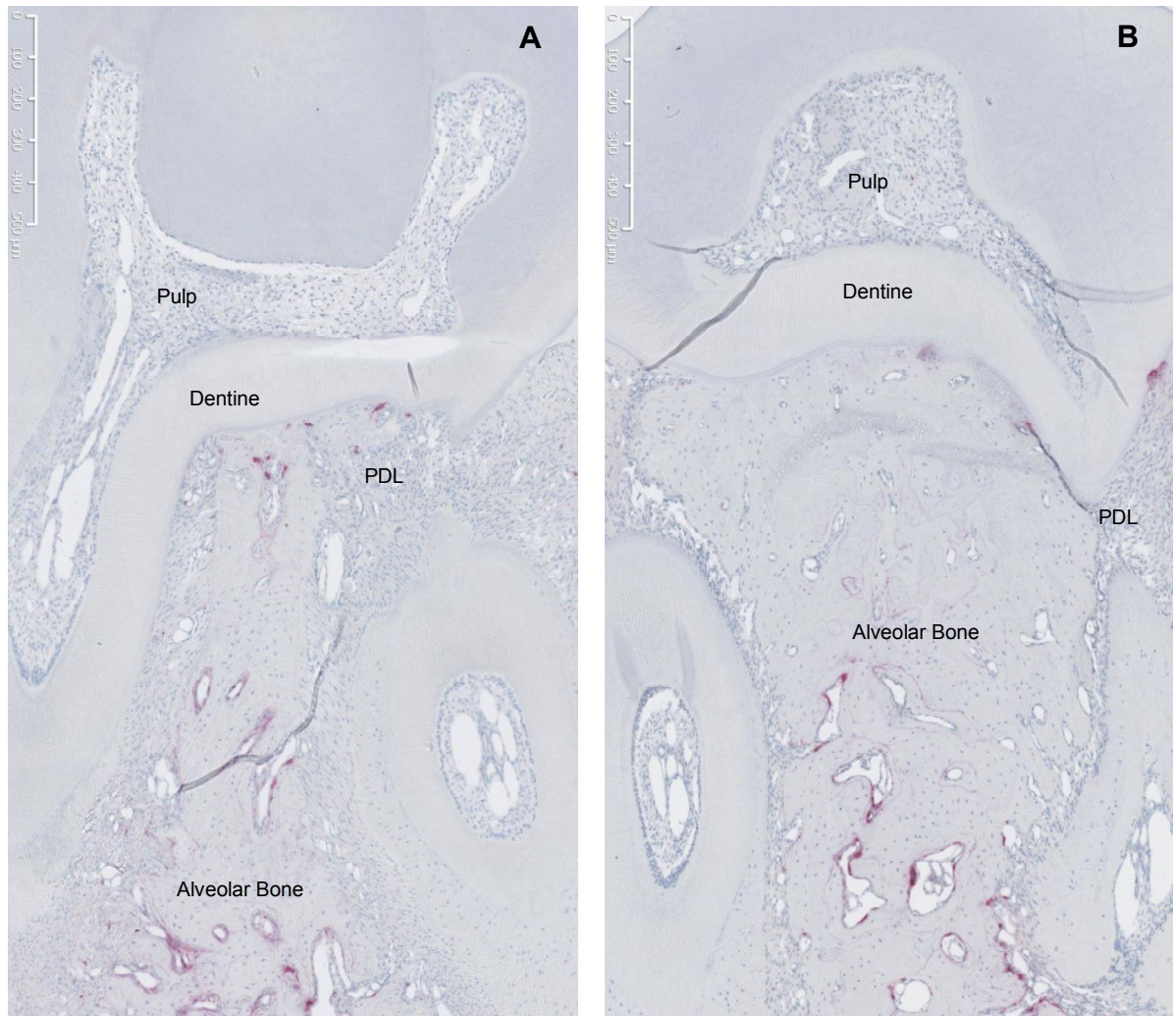


Figure 8. TRAP-positive cells (pink stain) in the experimental teeth at day 7 (A) and day 14 (B). (x5 magnification, ruler 0-500µm)

At day 28, two rats demonstrated complete resolution of the ankylotic region, whilst the remaining rat demonstrated partial resolution. Both of these areas were associated with the presence of TRAP-positive cells in the furcation region of the PDL confirming that resorption of the ankylotic bone took place (Figure 9).

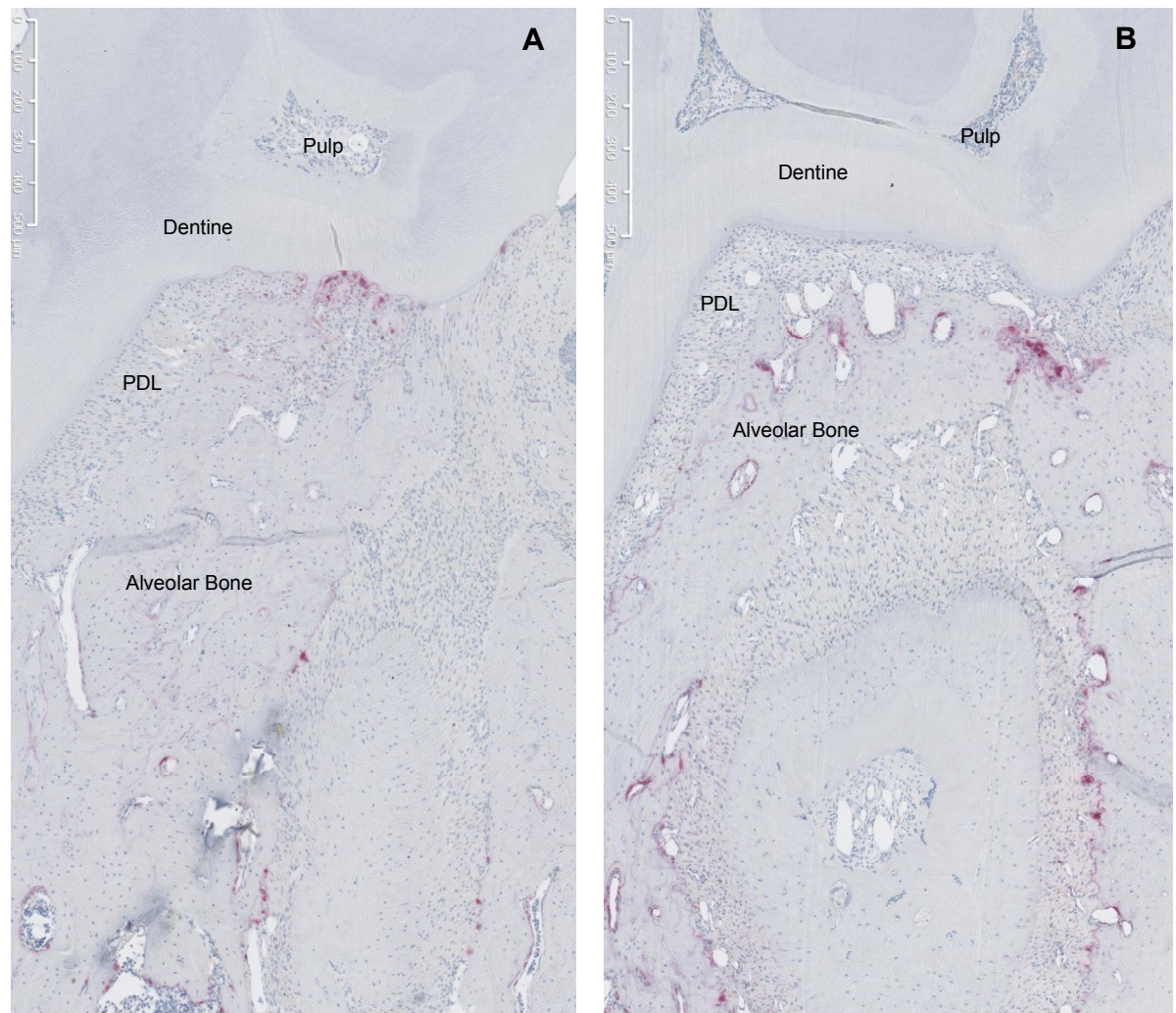
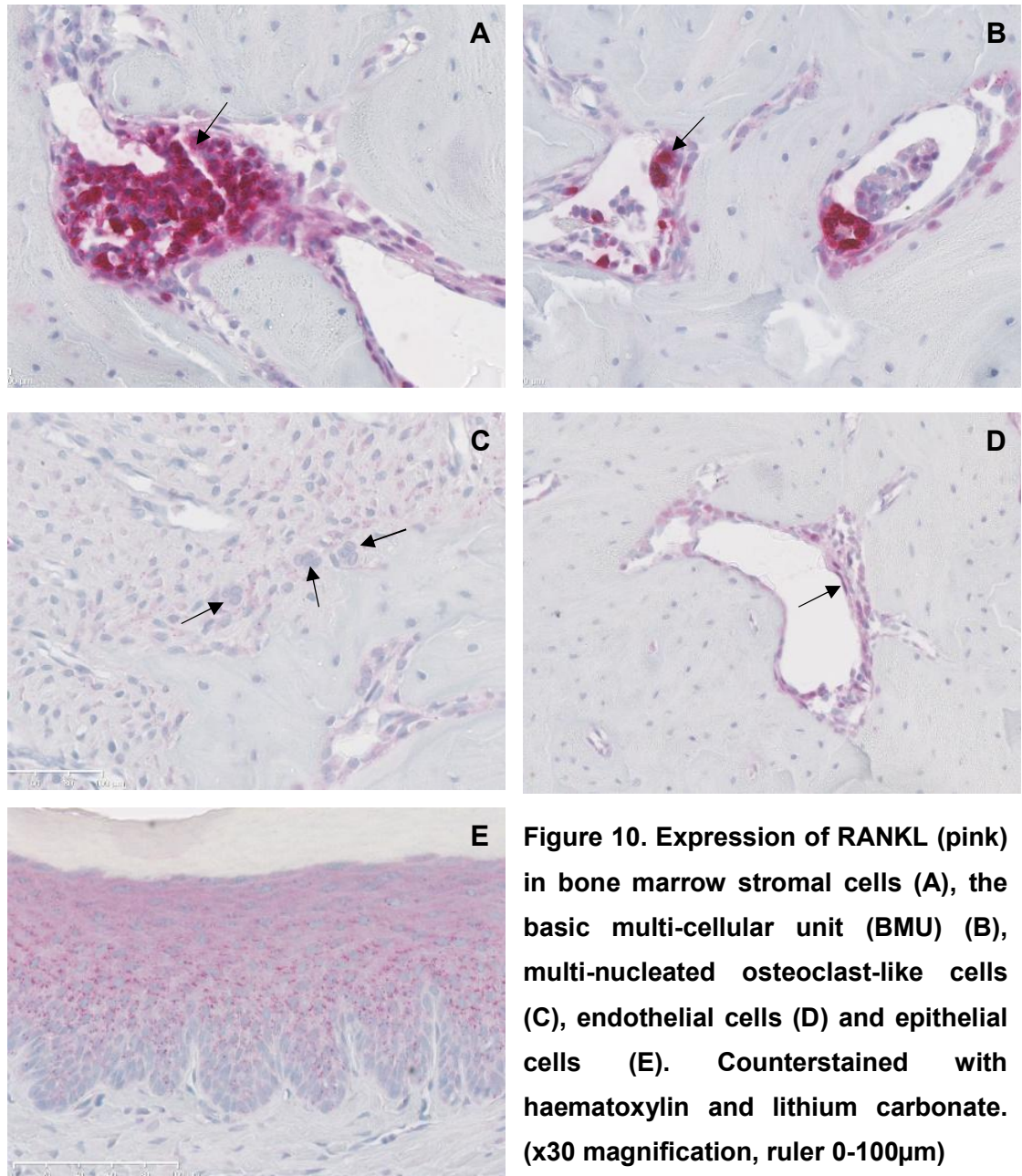


Figure 9. TRAP-positive cells (pink stain) in the experimental teeth at day 28. TRAP-positive cells localized to the area of resolving ankylosis (A) and regenerated PDL (B). (x5 magnification, ruler 0-500µm)

Immunohistochemical detection of RANKL

RANKL was detected in bone marrow stromal cells, osteoblasts and bone lining cells, osteoclasts, endothelial-like cells lining vessels, epithelial cells (Figure 10), odontoblasts (Figure 11) and periodontal fibroblasts (Figure 12).



RANKL expression in the pulp

In the external control animals not subjected to freezing there was a punctate pattern of positive RANKL staining which was confined to the outer layer of odontoblast-like cells only. There was no evidence of positive staining in the inner cell-rich region of the pulp. At this stage, the pulp chamber was large with discrete definition between the outer odontoblast-like layer and the inner cell-rich zone (Figure 11).

At day 0, there was less RANKL staining in the experimental teeth when compared with the internal control tooth but the pulp chamber was still large and the defined odontoblast layer was visible (Figure 11).

At day 4, significant changes were evident in the pulp with the loss of the odontoblast layer and a reduction in overall cellularity. Some RANKL positive cells were present within the remnants of the odontoblast layer but were greatly reduced in number and there was now evidence of RANKL positive cells within the inner region of the pulp (Figure 11).

By day 7, the cellularity had further reduced and there were few RANKL positive cells scattered within the remains of the pulp tissue. This effect was localised to the pulp chamber. The radicular pulp in the tooth root appeared unaffected and resembled the internal control (Figure 11).

At day 14, the appearance of the pulp was variable between animals. Some animals showed calcifications within the pulp chamber and there was an increase in cellularity and positive RANKL expression compared with day 7 (Figure 11).

At day 28, the pulp chamber more closely resembled that of the control with the re-establishment of the outer odontoblast cell layer and positive RANKL staining in this region which was less intense than the internal control. Significant reparative dentine had been laid down and the pulp chambers were smaller in size than the internal controls (Figure 11).

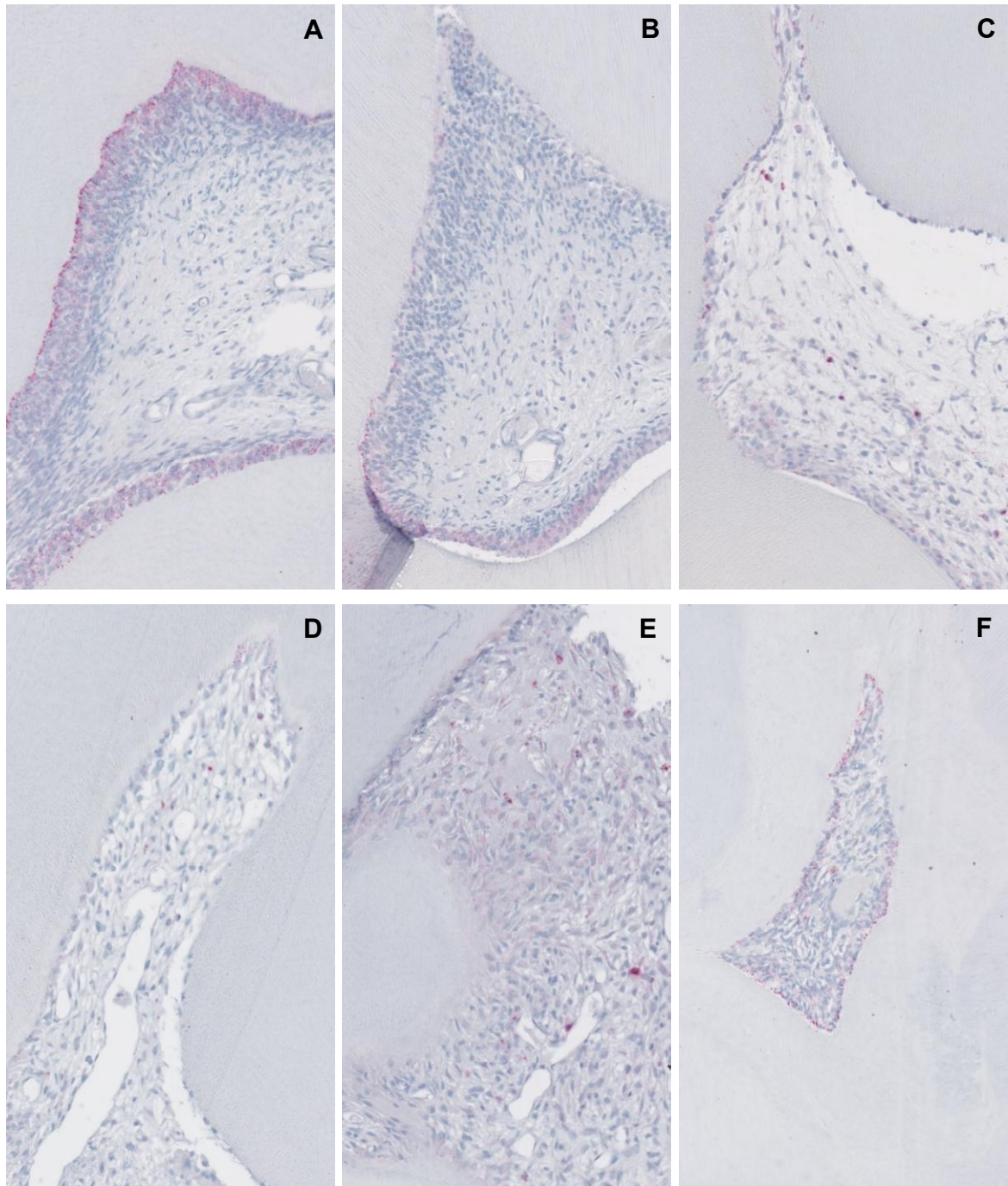


Figure 11. RANKL expression in the pulp of a rat in the experimental teeth: (A) External control, (B) day 0, (C) day 4, (D) day 7, (E) day 14, (F) day 28. RANKL positive cells stain pink, RANKL negative stain blue (haematoxylin counter-stain). (x 20 magnification)

RANKL expression in the periodontal ligament

The periodontal ligament contained cells that stained positive for RANKL. The external control animals and those sacrificed at days 0 and 4 contained a number of fibroblast-like cells showing weak cytoplasmic expression of RANKL. There was also strong punctate expression of RANKL associated with the epithelial rests of Malassez (Figure 12, 13).

At day 7 when ankylosis was first visible, the weak cytoplasmic expression of RANKL in the fibroblast-like PDL remains. ERM were not commonly visualised at this time point (Figure 12).

At day 14, the ankylosis was at its maximum with almost complete obliteration of the PDL. Some small islands remained with similar weak cytoplasmic expression of RANKL similar to the control. No ERM were visible in the experimental teeth with ankylosis but were still found in the internal control tooth (Figure 12).

At day 28, two of the experimental animals demonstrated intact PDL including the presence of ERM, similar in appearance to the controls (Figure 12).

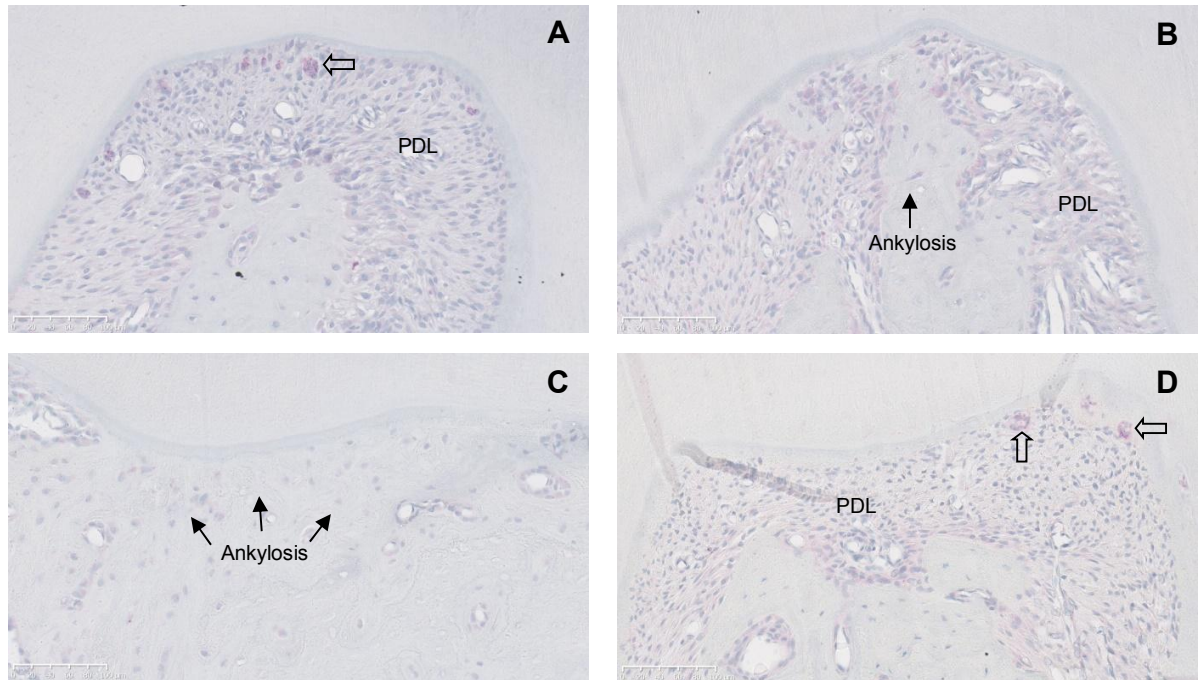


Figure 12. RANKL expression in the PDL of a rat in the experimental teeth: (A) External control (see figure 13 for detail), (B) day 7, (C) day 14, (D) day 28. RANKL positive cells stain pink, RANKL negative cells stain blue (haematoxylin counter-stain). Open arrows indicate ERM. (x20 magnification)

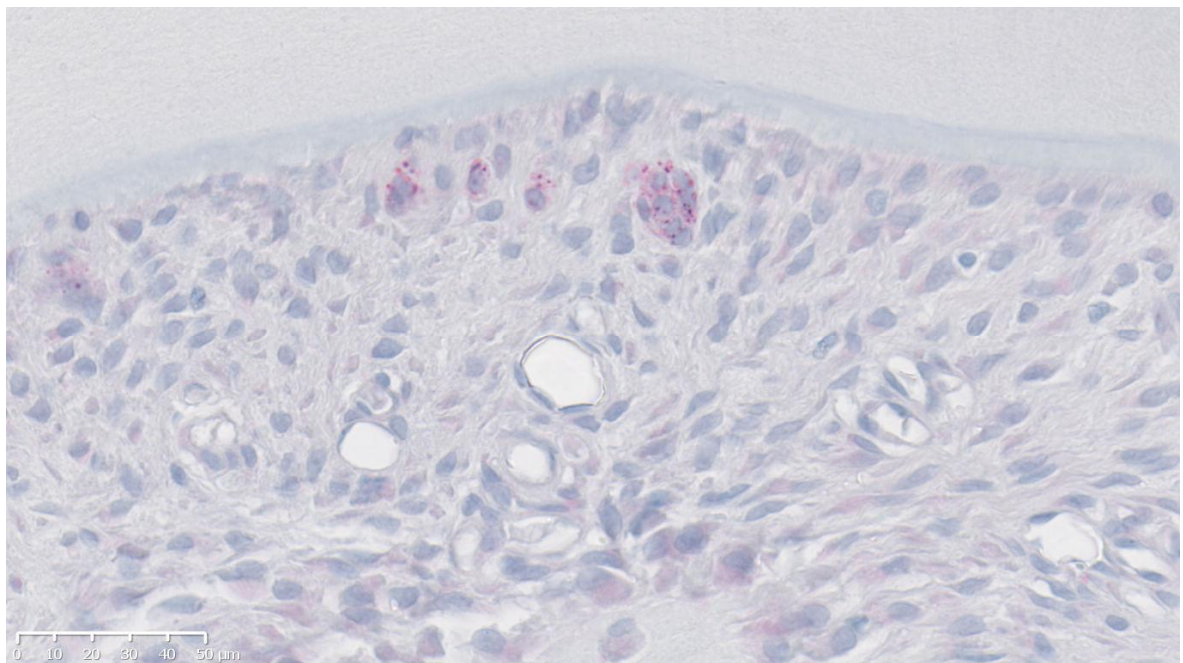


Figure 13. Close up view of Figure 12 to show ERM (x30 magnification)

RANKL expression in the alveolar bone

RANKL mRNA has been demonstrated to be present in osteocytes (Al-Dujaili et al. 2011). However, when staining for the RANKL protein and detecting its presence via immunohistochemistry in the present study, there was no evidence of RANKL positive osteocytes in the alveolar bone at any time point. There was however, strong positive staining for RANKL in the haemopoietic precursor cells within the bone marrow and in the cells lining the blood vessels within the alveolar bone (Figure 14, 15).

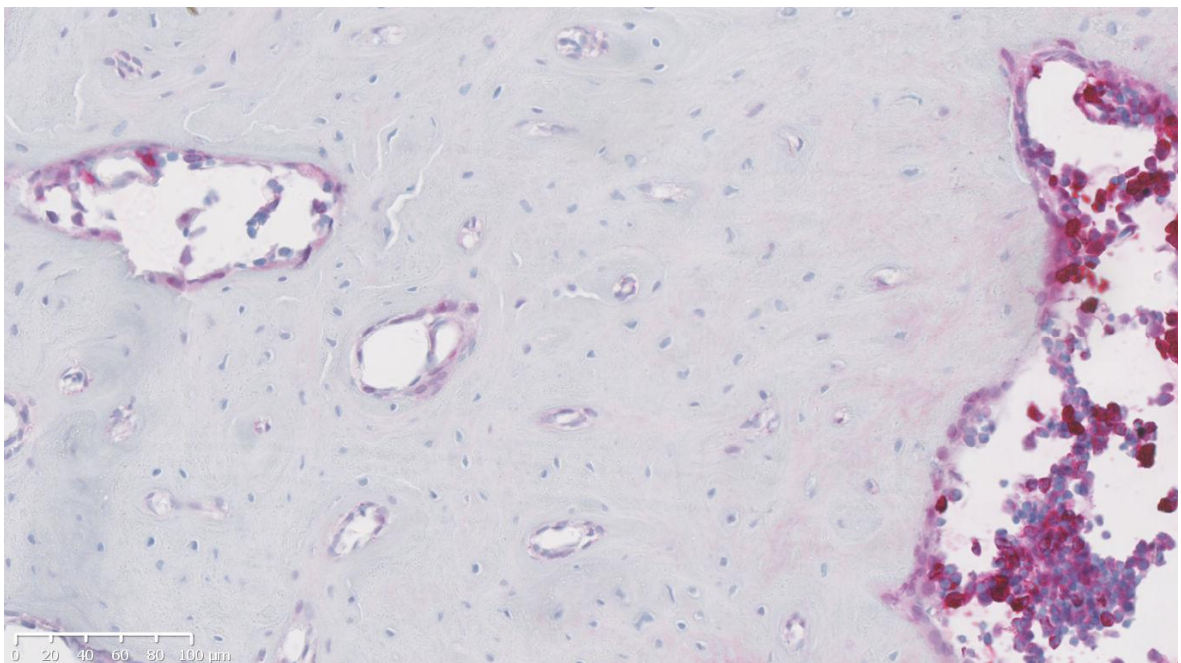


Figure 14. Osteocytes stain negatively for RANKL at day 0. Positive (pink) staining is evident in the lining cells of vessels and within the bone marrow

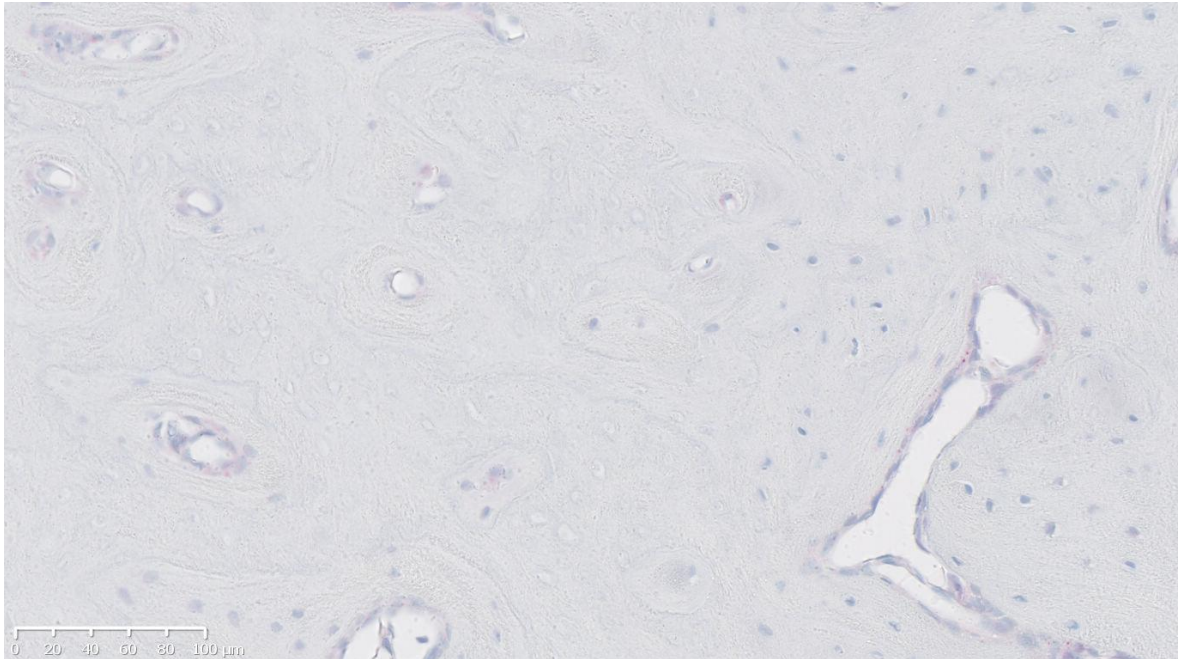


Figure 15. Alveolar bone at day 14 (maximal ankylosis). Empty lacunae are present but osteocytes are negative for RANKL

7.5 Discussion

This investigation used an established experimental model to induce dentoalveolar ankylosis in rats (Dreyer et al. 2000). Seven days after the application of a cold thermal insult signs of ankylosis were present. After 14 days the PDL in the furcation region was completely obliterated. Interestingly, after 28 days two of the three rats showed regeneration of the PDL and were indistinguishable from the controls. This investigation, along with previous research, found that there was no preceding resorption in the development of dentoalveolar ankylosis in this model (Curl et al. 2014). The ankylosis in this model appears to be of the appositional type which occurs when the PDL is replaced by bone without prior resorption of cementum (Andreasen 1980).

In the control animals and at days 0 and 4 prior to development of ankylosis, there were few TRAP-positive osteoclasts in the PDL at the furcation region. At this stage numerous osteoclasts were present in association with vessels and the apical PDL of the rat molar. Once ankylosis began to develop 7 days after the application of the cold insult, some TRAP-positive osteoclasts were evident in the PDL near the region of ankylosis. By day 14, however, there was an absence of osteoclasts in the PDL adjacent to the ankylotic area and in the nearby blood vessels. After 28 days ankylosis remained in one rat but the PDL showed signs of repair and there was an increase in the number of osteoclasts in the PDL bordering the ankylotic area. In the two rats in which the ankylosis had completely resolved, there was still evidence of an increased number of osteoclasts in the furcation region of the PDL compared with controls. This indicated that when the ankylosis was developing there was a lack of osteoclasts and bone formation was favoured. However, it appeared that the reduced number of osteoclasts was not permanent as regeneration of the PDL was associated with the appearance of osteoclasts in the PDL. This may have resulted in resorption of the ankylotic bone, thus allowing the PDL to regenerate. The junction between the newly formed PDL and the cementum at the furcation region appeared uneven when compared with the control teeth and earlier time points. This illustrated that resorption had taken place in both the ankylotic bone and the cementum.

The resolution of the ankylotic lesion may partly be related to the experimental model. The investigated ankylosis was the result of a thermal insult, whereas in a clinical situation, the factors that initiate ankylosis are incompletely understood and may differ from this model. The absence of the thermal insult at the later time points may contribute to the regeneration of the PDL and resolution of the ankylosis.

One of the signalling mechanisms behind this may be RANKL. RANKL is known to stimulate osteoclast differentiation and function. The roles of RANKL include the fusion of osteoclast precursors into multinucleated cells (Lacey et al. 1998), their differentiation into mature osteoclasts (Lacey et al. 1998), their attachment to bone surfaces (O'Brien et al. 2000), their activation to resorb bone (Burgess et al. 1999; Lacey et al. 1998) and

aiding osteoclast survival by avoiding apoptosis (Lacey et al. 2000). A reduction in RANKL expression may lead to a reduction in the number of functioning osteoclasts. When the damaged PDL is repaired following trauma, one of the factors that might influence whether dentoalveolar ankylosis remains or whether bone is resorbed and a new ligament allowed to form, may be the presence of RANKL.

In this investigation, RANKL was detected in osteoblasts and bone lining cells, ERM and fibroblasts, odontoblasts and marrow cells. Recent research has suggested that the osteocyte is a major source of RANKL involved in bone resorption and remodelling (Nakashima et al. 2011; Xiong and O'Brien 2012). In the current investigation, the osteocytes in proximity to the furcation region were destroyed. This was illustrated by the number of empty lacunae, which significantly increased at days 7 and 14 when ankylosis was present. If osteocytes are indeed a major source of RANKL, it could be hypothesised that osteocyte death resulted in a reduction in RANKL expression which may have led to a reduction in osteoclast activation and therefore less bone resorption in the response to the thermal trauma.

Evidence from bone fatigue models suggests that osteocytes produce membrane-bound RANKL in low doses under normal circumstances (Kennedy et al. 2012). What happens after micro-trauma and osteocyte death in regards to RANKL expression is not clear. In vivo research indicates that it is the neighbouring healthy osteocytes that up-regulate RANKL production following trauma (Kennedy et al. 2012), whereas, an in vitro experiment suggested that it is the apoptotic osteocytes that are a source of RANKL (Al-Dujaili et al. 2011). In the current investigation osteocytes were not positive for RANKL. The area of primary examination included a region where a large number of dead osteocytes were present. According to Kennedy et al (2012), apoptotic osteocytes do not produce RANKL. Osteocytes located further away from the area of injury were reported to produce RANKL. This was not observed in the current investigation. There are two possible reasons for this. The osteocytes in the neighbouring region, although not destroyed, may still have had key functions damaged by the hypothermic insult and were not producing RANKL. Another explanation is that the current method of using

immunohistochemistry with a polyclonal antibody and light microscopy was inadequate to detect small but possibly important levels of RANKL in the osteocytes, despite detecting RANKL-positive cells in other tissues such as the pulp, epithelial rests of Malassez and the bone marrow. The polyclonal antibody may not have been specific enough. Previous studies (Kennedy et al. 2012) have detected osteocyte-expressed RANKL in histological sections using fluorescence or have detected the presence of RANKL mRNA (Al-Dujaili et al. 2011).

In health, the PDL must have the capacity to resist induction of osteogenesis through cell signalling systems that “measure” and maintain the PDL width ensuring that the root and alveolar bone remain separate (Melcher 1970; McCulloch 1995). Ankylosis occurs when the PDL is repopulated with cells from a source outside the PDL such as the alveolar bone. The presence of vital PDL cells appears crucial for repair and regeneration of a functional PDL. In the current investigation, the ERM were associated with strong punctate expression of RANKL. ERM were evident in the control animals and at day 0 and 4. They were not evident at day 7 in association with the establishment of ankylosis, even though the majority of the PDL was still intact. At day 28 when the PDL appeared intact ERM were clearly visualised again. It is possible that the presence of the ERM is related to the presence of a normal PDL or ankylosis. Experiments with the re-implantation of teeth after varied periods of extra-oral drying time demonstrated that the presence of a normal PDL over ankylotic repair may be related to the presence of epithelial rests of Malassez (Löe and Waerhaug 1961). The RANKL produced by the ERM might be one of the signalling methods involved in maintenance of the PDL.

There are limitations to the current investigation. Occasionally osteocytes indicated positivity for RANKL but were always in extremely close association to the PDL or vessels. Therefore, it was hard to determine whether these cells were truly osteocytes staining positive for RANKL or whether the plane of section made cells from the vessels and ligament appear to be embedded in the bone. The use of a rat model has advantages in that the PDL is similar to that of humans and there is little genetic

variability between animals. However, as with all animal studies, the data obtained must be viewed with caution before applying the results to humans. The sample size in this study was small with three rats in each group. Repeating the experiment with more rats at each time point will increase the reliability of the findings, particularly related to the possible healing of the ankylotic lesion. Having time points closer together, particularly between days 14 and 28 will also allow for a more detailed analysis of the progression of the ankylosis.

7.6 Conclusions

The development of ankylosis and the subsequent regeneration of the PDL is a complex process controlled by many signalling factors. It is possible that RANKL plays a role in the process, although this investigation did not indicate that osteocyte-derived RANKL is a major factor. However, the following conclusions were drawn:

- 1) The null hypothesis that 'an applied cold insult and subsequent ankylosis does not affect the production of RANKL and that the amount and distribution of RANKL will not be affected', is rejected.
- 2) Changes were observed in the expression of RANKL within the pulp and PDL subsequent to a freezing insult.
- 3) No changes were observed in the expression of RANKL by osteocytes in the alveolar bone subsequent to a freezing insult.
- 4) The difference in the number of empty lacunae between zones indicated that the freezing insult results in the death of osteocytes which coincides with the timing of maximal ankylosis.
- 5) ERM strongly expressed RANKL and their presence or absence may play a role in the regeneration of the PDL following dentoalveolar ankylosis.
- 6) A role of osteocyte-derived RANKL in dentoalveolar ankylosis is not observed in this investigation but cannot be conclusively ruled out. More sensitive detection methods may need to be employed in the future.

7.7 References

- Al-Dujaili, S.A. et al., 2011. Apoptotic osteocytes regulate osteoclast precursor recruitment and differentiation in vitro. *Journal of cellular biochemistry*, 112(9), pp.2412–23.
- Anderson, D.M. et al., 1997. A homologue of the TNF receptor and its ligand enhance T-cell growth and dendritic-cell function. *Nature*, 390(6656), pp.175–9.
- Andreasen, J.O., 1980. A time-related study of periodontal healing and root resorption activity after replantation of mature permanent incisors in monkeys. *Swedish dental journal*, 4, pp.101–110.
- Van Bezooijen, R.L. et al., 2004. Sclerostin is an osteocyte-expressed negative regulator of bone formation, but not a classical BMP antagonist. *The Journal of Experimental Medicine*, 199(6), pp.805–14.
- Bucay, N. et al., 1998. Osteoprotegerin-Deficient Mice Develop Early Onset Osteoporosis and Arterial Calcification. *Genes & development*, 12(9), pp.1260–8.
- Burgess, T.L. et al., 1999. The ligand for osteoprotegerin (OPGL) directly activates mature osteoclasts. *The Journal of cell biology*, 145(3), pp.527–38.
- Curl, L. et al., 2014. A qualitative investigation of RANKL, RANK and OPG in a rat model of transient ankylosis. *Australian Orthodontic Journal*, 30(2), pp.143–151.
- Dreyer, C., Pierce, A. & Lindskog, S., 2000. Hypothermic insult to the periodontium: a model for the study of aseptic tooth resorption. *Endodontics & Dental Traumatology*, 16, pp.9–15.
- Epker, B.N. & Frost, H.M., 1965a. A histological study of remodeling at the periosteal, haversian canal, cortical endosteal, and trabecular endosteal surfaces in human rib. *Anatomical Record*, 152, pp.129-135
- Epker, B.N. & Frost, H.M. 1965b. Correlation of bone resorption and formation with the physical behavior of loaded bone. *Journal of Dental Research*, 44, pp.33-41
- Erausquin, J. & Devoto, F.C., 1970. Alveolodental ankylosis induced by root canal treatment in rat molars. *Oral Surgery*, 30(1), pp.105–116.
- Gu, G. et al., 2005. Death of osteocytes turns off the inhibition of osteoclasts and triggers local bone resorption. *Biochemical and biophysical research communications*, 335(4), pp.1095–101.
- Henriksen, K. et al., 2009. Local communication on and within bone controls bone remodeling. *Bone*, 44(6), pp.1026–33.

- Ikeda, T. et al., 2001. Determination of Three Isoforms of the Receptor Activator of Nuclear Factor- κ B Ligand and Their Differential Expression in Bone and Thymus. *Endocrinology*, 142(4), pp.1419–1426.
- Kearns, A.E., Khosla, S. & Kostenuik, P.J., 2008. Receptor activator of nuclear factor kappa β ligand and osteoprotegerin regulation of bone remodeling in health and disease. *Endocrine reviews*, 29(2), pp.155–92.
- Kennedy, O.D. et al., 2012. Activation of resorption in fatigue-loaded bone involves both apoptosis and active pro-osteoclastogenic signaling by distinct osteocyte populations. *Bone*, 50(5), pp.1115–22.
- Kurata, K. et al., 2006. Bone Marrow Cell Differentiation Induced by Mechanically Damaged Osteocytes in 3D Gel-Embedded Culture. *Journal of Bone and Mineral Research*, 21(4), pp.616–625.
- Kuroi, J., 1981. Infraocclusion of primary molars: an epidemiologic and familial study. *Community Dentistry and Oral Epidemiology*, 9, pp.94–102.
- Lacey, D.L. et al., 1998. Osteoprotegerin ligand is a cytokine that regulates osteoclast differentiation and activation. *Cell*, 93(2), pp.165–76.
- Lacey, D.L. et al., 2000. Osteoprotegerin ligand modulates murine osteoclast survival in vitro and in vivo. *The American journal of pathology*, 157(2), pp.435–48.
- Lin, D. et al., 2000. Storage conditions of avulsed teeth affect the phenotype of cultured human periodontal ligament cells. *Journal of periodontal research*, 35(1), pp.42–50.
- Line, S., Polson, A. & Zander, H., 1974. Relationship between periodontal injury, selective cell repopulation & ankylosis. *Journal of periodontology*, 45(10), pp.725–30.
- Löe, H. & Waerhaug, J., 1961. Experimental replantation of teeth in dogs and monkeys. *Archives of oral biology*, 3(1935), pp.176–84.
- McCulloch, C., 1995. Origins and functions of cells essential for periodontal repair: the role of fibroblasts in tissue homeostasis. *Oral Diseases*, 1, pp.271–278.
- Melcher, A., 1970. Repair of Wounds in the Periodontium of the Rat. Influence of the Periodontal Ligament on Osteogenesis. *Archives of Oral Biology*, 15, pp.1183–1204.
- Mizuno, A et al., 1998. Severe osteoporosis in mice lacking osteoclastogenesis inhibitory factor/osteoprotegerin. *Biochemical and biophysical research communications*, 247(3), pp.610–5.

- Nakashima, T. et al., 2011. Evidence for osteocyte regulation of bone homeostasis through RANKL expression. *Nature medicine*, 17(10), pp.1231–4.
- Noble, B.S. et al., 2003. Mechanical loading: biphasic osteocyte survival and targeting of osteoclasts for bone destruction in rat cortical bone. *American journal of physiology. Cell physiology*, 284(4), pp.C934–43.
- O'Brien, E. a, Williams, J.H. & Marshall, M.J., 2000. Osteoprotegerin ligand regulates osteoclast adherence to the bone surface in mouse calvaria. *Biochemical and biophysical research communications*, 274(2), pp.281–90.
- Poole, K.E.S. et al., 2005. Sclerostin is a delayed secreted product of osteocytes that inhibits bone formation. *FASEB journal*, 19(13), pp.1842–4.
- Simonet, W. et al., 1997. Osteoprotegerin: a novel secreted protein involved in the regulation of bone density. *Cell*, 89(2), pp.309–19.
- Tan, C., 2011. *A qualitative investigation of RANKL, RANK and OPG in a rat model of transient ankylosis*. Honors Project, The University of Adelaide, South Australia
- Tatsumi, S. et al., 2007. Targeted ablation of osteocytes induces osteoporosis with defective mechanotransduction. *Cell metabolism*, 5(6), pp.464–75.
- Theoleyre, S. et al., 2004. The molecular triad OPG/RANK/RANKL: involvement in the orchestration of pathophysiological bone remodeling. *Cytokine & growth factor reviews*, 15(6), pp.457–75.
- Verborgt, O. et al., 2002. Spatial Distribution of Bax and Bcl-2 in Osteocytes After Bone Fatigue: Complementary Roles in Bone Remodeling Regulation? *Journal of Bone and Mineral Research*, 17(5), pp.60–7.
- Wijenayaka, A.R. et al., 2011. Sclerostin stimulates osteocyte support of osteoclast activity by a RANKL-dependent pathway. *PLoS one*, 6(10), p.e25900.
- Xiong, J. et al., 2011. Matrix-embedded cells control osteoclast formation. *Nature medicine*, 17(10), pp.1235–41.
- Xiong, J. & O'Brien, C., 2012. Osteocyte RANKL: new insights into the control of bone remodeling. *Journal of bone and mineral research*, 27(3), pp.499–505.
- Yasuda, et al., 1998. Osteoclast differentiation factor is a ligand for osteoprotegerin/osteoclastogenesis-inhibitory factor and is identical to TRANCE/RANKL. *Proceedings of the National Academy of Sciences of the USA*, 95(7), pp.3597–602.
- Zhao, S. et al., 2002. MLO-Y4 Osteocyte-Like Cells Support Osteoclast Formation and Activation. *Journal of Bone and Mineral Research*, 17(11), pp.2068–2079.

8 ARTICLE 2



Expression of sclerostin in a rat model of dentoalveolar ankylosis following hypothermal insult

Written in the style of European Journal of Orthodontics

8.1 Abstract

Background: Dentoalveolar ankylosis may occur spontaneously or as a sequela to dental trauma and results in an area of bone fusing to the tooth. The understanding of the biological processes behind the formation and repair of this lesion is incomplete. Sclerostin is a protein produced by osteocytes that is known to inhibit bone formation. The present study investigates the expression of sclerostin in a rat model of dentoalveolar ankylosis.

Methods: Dentoalveolar ankylosis was induced in fifteen eight week old Sprague-Dawley rats (5 groups of 3 rats each) by the application of dry ice to the upper right first molar tooth. An additional 3 rats served as untreated controls and the experimental rats were sacrificed at days 0, 4, 7, 14 and 28. Immunohistochemical detection of sclerostin was performed and the number of sclerostin-positive and negative cells as well as the number of empty lacunae representing dead osteocytes were calculated and compared between groups.

Results: When ankylosis was present, there was a statistically significant difference in sclerostin expression between the areas of bone closest to, and farthest away, from the furcation area. There was also a statistically significant increase in the number of empty lacunae due to osteocyte death that coincides with the incidence of maximal ankylosis. There was a non-statistically significant trend towards reduced sclerostin expression at days 7 and 14 followed by a slight increase in expression at day 28. The slight increase in sclerostin expression at day 28 may indicate the establishment of a healing response.

Conclusion: The possible repair of the periodontal ligament (PDL) following trauma is complex and the present study may contribute evidence to the possibility that the osteocyte and sclerostin might have a role in influencing the regeneration of the PDL.

Keywords: sclerostin, ankylosis, dentoalveolar, osteocyte, immunohistochemistry

8.2 Introduction

Osteocytes sense loading stimuli and regulate remodelling and bone turnover processes but little is known about how cells embedded in a mineralised matrix carry out this regulatory role. It has been suggested that mature osteocytes send an inhibitory signal to bone lining osteoblasts to maintain these cells in a quiescent state against their natural tendency to reactivate the remodelling process (Poole et al. 2005). If the emitted signal was sensitive to mechanical loading, the correct balance could be obtained between bone formation and its inhibition. This signal has been identified as sclerostin which is the secreted protein product of the SOST gene. Sclerostin is a negative regulator of osteoblasts which, therefore, inhibits bone formation and appears to be exclusively osteocyte derived (van Bezooijen et al. 2004). It exerts its effects by interfering with Wnt signaling, a process which plays an essential role in the regulation of bone formation (van Bezooijen et al. 2004; Li et al. 2005; Semenov et al. 2005).

A lack of sclerostin in humans results in the rare conditions of sclerosteosis and van Buchem disease (VBD), first described in the 1950's (van Buchem et al. 1955; Truswell 1958). The skeletal manifestations of both diseases are the result of endosteal hyperostosis and are characterised by progressive generalised osteosclerosis. The manifestations are most pronounced in the mandible and skull. Those patients with sclerosteosis have a more severe phenotype compared with patients with van Buchem disease (Moester et al. 2010). Bone biopsies of those affected show increased bone formation including a predominance of active osteoblasts (Moester et al. 2010).

The effects of sclerostin have been shown experimentally by using SOST knock-out mice which show increased radiodensity, bone mineral density, cortical and trabecular volume, bone formation and bone strength (Poole et al. 2005). The main mechanism of action of sclerostin is via its inhibition of the Wnt signalling pathway. Activation of the Wnt signalling pathway results in gene transcription that increases osteoblastic cell differentiation and may also inhibit bone resorption by blocking the receptor activator RANKL/RANK (Jackson et al. 2005). Sclerostin acts to block this pathway by binding to

the cell surface receptors LRP5 and LRP6 which subsequently prevents gene transcription (Li et al. 2005). Sclerostin may also promote apoptosis of osteoblasts, further inhibiting bone growth (Sutherland et al. 2004).

Dentoalveolar Ankylosis

Dentoalveolar ankylosis is defined as the fusing of cementum with alveolar bone (Kuroi, 1981). Ankylosis is commonly found in two clinical situations: those of infra-occlusion which mainly affects deciduous or primary teeth, and in the permanent dentition where it is associated with impaction or external root replacement resorption following trauma and is frequently observed after re-implantation of avulsed permanent teeth. Ankylosed teeth often present at a level below the occlusal plane, a condition referred to as submergence or infra-occlusion. This results from the inability of the ankylosed tooth to follow the normal vertical development of the neighbouring teeth that are continuing to develop and erupt.

Following trauma dentoalveolar ankylosis may occur as part of the repair process. A healthy periodontal ligament has the capacity to resist induction to osteogenesis through cell signalling systems that accurately 'measure' and maintain the PDL width, ensuring separation of the root and alveolar bone (Melcher 1970; McCulloch 1995). Traumatic injury disrupts this homeostasis. Investigations indicate it is the source of the cells that repopulate the PDL space following trauma or injury that determine whether or not ankylosis occurs (Erausquin and Devoto 1970; Lin et al. 2000; Melcher 1970; Line et al. 1974). When the space is repopulated by cells from a source outside the true PDL tissues (alveolar bone, bone marrow or soft connective tissue) osteoclasts and osteogenesis occur, resulting in healing via a dentoalveolar ankylosis.

Infra-occlusion following dentoalveolar ankylosis results in a number of significant sequelae including over-eruption of the opposing tooth. Adjacent teeth can tip towards the ankylosed tooth which may lead to a loss of arch length, space loss, a shift of the dental midline and difficulty with future extraction of the infra-occluded tooth (Messer and Cline 1980; Andlaw 1974; Ponduri et al. 2009). Vertical alveolar growth may also be

hindered (Kjaer et al. 2008). When the ankylosed primary mandibular second molar has no successor, early orthodontic and prosthodontic consultation is recommended. The patient's age, occlusal status and the development and condition of the infra-occluded tooth will influence treatment requirements. Consideration may be given to the maintenance of the ankylosed tooth, prosthetic replacement including implants and orthodontic space closure (Kuroi and Thilander 1984; Ekim and Hatibovic-Kofman 2001).

Sclerostin in Dentistry

Sclerostin has attracted significant attention in the medical field, mainly in its role as a potential therapy for osteoporosis. Antibodies to sclerostin have already been shown to increase the bone formation rate and bone density in rats (Li et al 2009) and, in clinical trials involving healthy postmenopausal women, increased bone formation markers and bone mineral density were observed (Padhi et al. 2011).

Sclerostin appears to affect the alveolar bone and cementum. Sclerostin-deficient mice demonstrated increased mandibular basal bone dimensions and mildly increased cementum thickness (Kuchler et al. 2014). Patients with van Buchem disease have shown little or no sclerostin expression by cementocytes (van Bezooijen et al. 2007). It has been suggested that the resultant hypercementosis produces a tighter junction between the tooth and alveolar bone and may be the reason behind the reported difficulty in extracting teeth (van Bezooijen et al. 2007). However, small sample sizes meant the exact differences in histology could not be precisely determined and sclerostin deficiency in cementocytes was not clearly associated with overt changes in cementum thickness (van Bezooijen et al. 2007). Sclerostin does not appear to produce anomalies in tooth structures such as dentine and the pulp chamber (Kuchler et al. 2014).

Sclerostin expression in alveolar bone appears to be influenced by orthodontic forces. Tensile areas of bone demonstrated a down-regulation of sclerostin and in areas of compression, sclerostin was significantly higher than control sites (Sanmuganathan 2011; Nishiyama et al. 2015). It seems that when significant local strains are sensed by the osteocyte population on the side of tension, sclerostin levels decreased and cells were released from their suppressed Wnt signalling state and new bone was formed. Conversely, on the side of compression, sclerostin levels were increased with continued Wnt signalling suppression, leading to prevention of local bone formation (Sanmuganathan 2011).

A clinical application of sclerostin has been demonstrated by the use of sclerostin-neutralising monoclonal antibody (Scl-Ab) in rats with experimentally induced periodontitis. The application of Scl-Ab resulted in increased alveolar bone volume and density measurements, making the experimental animals comparable to normal, healthy controls (Taut et al. 2013).

To date, no investigations have examined the role of sclerostin in the development of dentoalveolar ankylosis. The aim of the present investigation was to determine if the production and expression of sclerostin is altered during the formation of dentoalveolar ankylosis in a rat model. The null hypothesis states that 'an applied cold insult and subsequent ankylosis does not affect the expression of sclerostin within the alveolar bone of exposed teeth. The amount and distribution of sclerostin will not be affected'.

8.3 Methods and materials

The experimental procedures were reviewed and approved by the University of Adelaide Animal Ethics Committee for a previous study (M-083-2007).

Experimental procedure:

The experimental sample consisted of 18 eight week old, male, Sprague-Dawley rats. Fifteen rats were subjected to a hypothermal insult and 3 rats served as an untreated control. The rats were anaesthetised before the procedure and sacrificed using an intramuscular injection of Hypnorm® (fentanyl citrate 0.315mg/ml and fluanisone 10mg/ml, Janssen-Cilag Ltd., High Wycombe, Buckinghamshire, UK) and Hypnovel® (midazolam hydrochloride 5mg/ml, Roche Products Pty Ltd., Dee Why, Australia). The anaesthetic agents were diluted in a 1:1 ratio with sterile water, combined and administered at a dosage of 2.7ml/kg of body weight. The animals were restrained in a head holding device and underwent a single 10 minute application of dry ice (compressed carbon dioxide gas at -81°C, BOC Gases, Adelaide, Australia) to the occlusal surface of the right maxillary first molar crown in order to produce aseptic necrosis within the PDL and induce ankylosis (protocol developed by Dreyer et al. 2000). The upper left first molar was untreated and provided an internal control.

The rats were sacrificed on days 0, 4, 7, 14 and 28 respectively. The 3 animals in the control group did not undergo hypothermal insult and were also sacrificed on day 0. Following administration of anaesthetic, the rats were sacrificed via intra-cardiac perfusion of 4% paraformaldehyde fixative. On completion of perfusion the maxillae were dissected out and immersed in the same fixative for 24 hours and then stored in phosphate buffered saline (PBS) at pH 7.3 for another 24 hours. Specimens were decalcified using 4% ethylenediaminetetraacetic acid (EDTA) solution and were dehydrated using a graded alcohol series and embedded in paraffin wax. The paraffin blocks were mounted onto a Leitz 1512 Microtome (Leica, Nussloch, Germany) and 5µm sections were cut coronally through the root furcation. Sections were mounted onto aminopropyltriethoxysilane (APTS) coated glass slides.

Randomly selected sections were stained with haematoxylin and eosin (H and E) to check for orientation, identification of ankylotic areas and suitability for immunohistological staining. The preceding experimental protocol and H and E staining was carried out as part of a prior study (Tan et al 2011).

Immunohistochemical detection of sclerostin:

Fifty-four sections were randomly selected from within the region of the furcation as previous research has shown this area to have the most ankylosis (Dreyer et al 2000). Antibody optimisation was performed prior to immunohistological staining to determine the optimal antigen unmasking method and antibody dilution required to achieve minimal background staining and optimal antibody specific staining. Positive control tissue and negative controls were assessed to determine antibody specificity. Omission of the primary antibody provided negative controls. The positive control was the alveolar bone as osteocytes are known to express sclerostin. All staining was performed on the same day.

The sections underwent paraffin removal and were immersed in tris-EDTA buffer (10mM, pH 9.0) in a 65°C water bath for 10 minutes before cooling for 20 minutes. Following washing with 1x PBS three times for 5 minutes the sections were immersed in 0.3% v/v H₂O₂ in PBS/0.1% sodium azide for 20 minutes to block endogenous peroxidase. The sections were again washed in 1x PBS and the primary sclerostin antibody was applied (goat anti-mouse polyclonal SOST/Sclerostin [Cat No. AF1589, RandD Systems, distributed by Bio-Scientific Pty. Ltd., NSW, Australia]) 4µg/ml concentration in 1x PBS/1% BSA. Sections were incubated at room temperature overnight in a wet chamber. The sections were washed again in 1x PBS and the secondary antibody was applied (swine anti-goat Ig's HRP [Ref no. ACI0404, Invitrogen, distributed by Life Technologies Australia Pty Ltd, Victoria Australia] 11.7µg/ml in 1x PBS/1% BSA) for 30 minutes. Sections were washed in PBS and the tertiary antibody was applied (rabbit anti-swine Ig's [Code No. P 0164, Dako Australia Pty. Ltd., NSW, Australia] 13µg/ml concentration in 1x PBS/1% BSA) for 30 minutes. Sections were

washed in 1x PBS before application of AEC (3-Amino-9-ethylcarbazole) substrate chromogen (Cat no. SK-4200, Dako Australia Pty. Ltd., NSW, Australia) for 10 minutes at room temperature with the sections covered and placed in the dark. Sections were then rinsed with MilliQ water, counter-stained with haematoxylin (10 seconds) and lithium carbonate (30 seconds) before final washing with tap water and mounting using Aquamount.

Histomorphometry:

The immuno-stained sections were digitised via a Nanozoomer Slide Scanner 2.0 series (Hamamatsu Photonics K.K. 325-6 Sunayama-cho, Hamamatsu City, Shizuoka) and viewed on a personal computer (Lenovo X220) using the Nanozoomer Digital Pathology (NDP) software. Areas were then defined to enable analysis of the sections.

The periodontal ligament was divided into 5 regions of 0.01mm² at the furcation region and the percentage of bone within the PDL was determined to quantitatively assess the degree of ankylosis viewed at a magnification factor of 20 on the NDP software (Figure 1).

Alveolar bone was delineated into 4 zones with zone 1 closest to the root furcation and zone 4 closest to the root apex (Figure 1). To ensure consistency of the sampling area across numerous sections, the boxes in zone 1 were placed 200 µm from the mid-point of the furcation area of the tooth. Each zone contained 2 boxes of 0.04mm². Counting of sclerostin positive and negative cells as well as empty lacunae was performed at a magnification factor of 20 using Image J software 1.47v (Wayne Rasband, National Institutes of Health, USA).

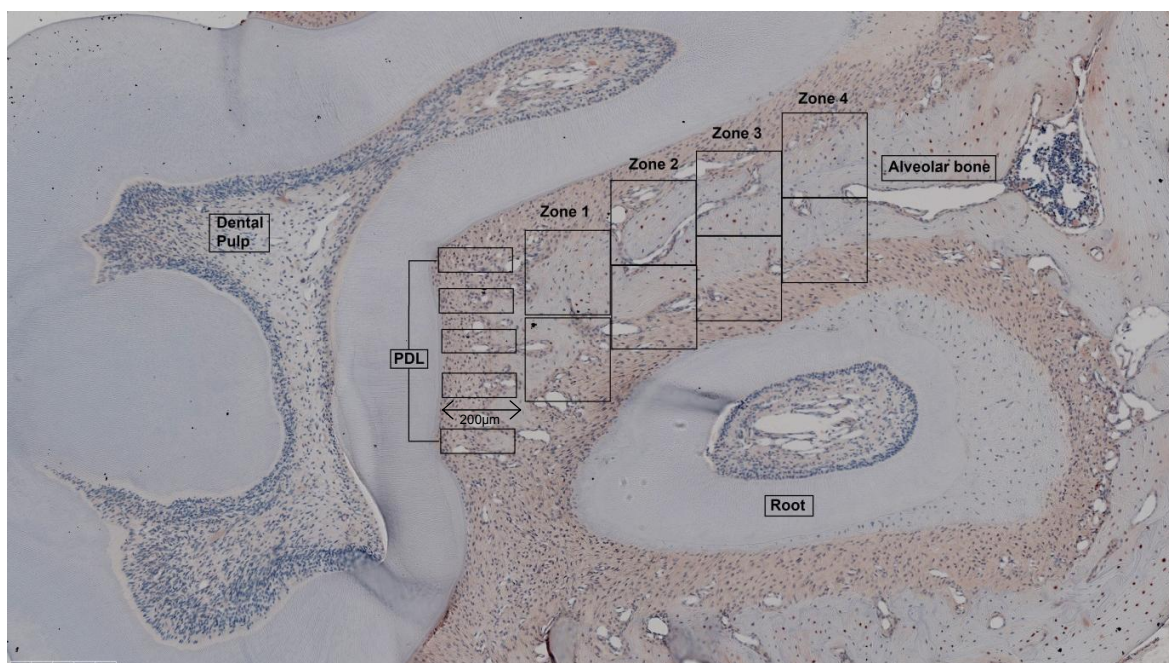


Figure 1. Sampling regions in the rat molar tooth

Statistical analysis:

The data were analysed using SAS 9.3 (SAS Institute Inc., Cary, NC, USA). The distribution of sclerostin in the alveolar bone at varying depths from the furcation, the distribution over time periods and between internal controls and experimental teeth was analysed using a linear mixed effects model. To account for dependency of measurements from the same rat a random effect was also included. The significance level was set at $p < 0.05$.

To assess the reliability of the cell counting, 10% of the sections were randomly selected and re-counted and Intraclass Correlation Coefficients (ICC) were calculated using SAS 9.3 and Stata/SE 13.1 (StataCorp LP).

8.4 Results

Error study

To assess the reliability of the examination of the histological slides 10% of the sections were re-counted (86 of a total 860 sections). Intraclass Correlation Coefficients (ICC) were calculated using Stata and are listed, along with 95% confidence intervals, in Table 1. The ICC describes how strongly units in the same group resemble each other. It is an assessment of consistency or reproducibility of quantitative measurements made by the same observer at a different time (or different observers measuring the same quantity). The ICCs were also calculated in SAS using linear mixed-effects model results:

$$\text{ICC} = \frac{\text{Area Covariance Parameter Estimate}}{(\text{Area Covariance Parameter Estimate} + \text{Residual})}$$

Within this linear mixed-effects model, the outcome was either positive, negative or empty and fixed effect (the predictor) was 'repeat' (i.e. original measurement or repeated measurement). ICCs found using SAS were exactly the same as ICCs found with Stata.

In these models, all of the ICCs were 0.91 and above – an ICC of 1 denotes perfect agreement. This is evidence that the reliability of the same examiner re-examining the rat slides is very high.

Table 1. Intraclass Correlation Coefficients

Type of cell	ICC	95% CI
Positive	0.909	0.865, 0.939
Negative	0.934	0.901, 0.956
Empty lacunae	0.955	0.933, 0.970

Histology

Haematoxylin and eosin stained sections were examined to assess the pulp, periodontal ligament and the alveolar bone. No differences were noted between the experimental tooth at day 0 and the internal control tooth when compared with those of the external control (Figure 2).

Pulp: At days 4 and 7 the experimental tooth showed a distinct reduction in cellularity in the central stromal region and some reduction in thickness and continuity of the odontoblast layer (Figure 3). By day 14, a layer of tertiary dentine was visible and was thicker at day 28. The pulp of the internal control teeth showed no disturbance to its integrity throughout the experimental period (Figure 4).

PDL: At days 0 and 4, the PDL remained intact and comparable to both the external and internal controls. The first signs of ankylosis were evident at day 7 in all animals (Figure 3). The PDL width decreased as a result of bony trabeculae invasion in the furcation region. At day 14, there was widespread loss of the PDL in all animals with dense ankylotic bone taking its place (Figure 4). By day 28, only one animal showed bone within the PDL and the other animals revealed an intact PDL almost indistinguishable from the internal control (Figure 4). There was no change in the PDL of the internal control teeth throughout the experimental period. The difference in the percentage of bone within the PDL between the experimental tooth and the internal control was statistically significant at days 7 and 28 (Table 2).

Alveolar bone: The amount of alveolar bone in the furcation region increased at days 7 and 14 as the PDL was replaced with ankylotic bone (Figure 4). There was a statistically significant increase in the number of empty lacunae in the furcation region as the ankylotic lesion developed (Table 3, 4); however, by day 28, there was almost complete filling of the lacunae by osteocytes (Figure 4).

Table 2. Percentage of bone in the sampled area of PDL of the experimental tooth

**statistically significant difference when the experimental tooth is compared to the internal control tooth*

Day of sacrifice	% bone in PDL	P value
Day 0	8.7	1.0
Day 4	5.9	1.0
Day 7	24.9	0.033*
Day 14	73.4	<0.0001*
Day 28	21.1	0.17

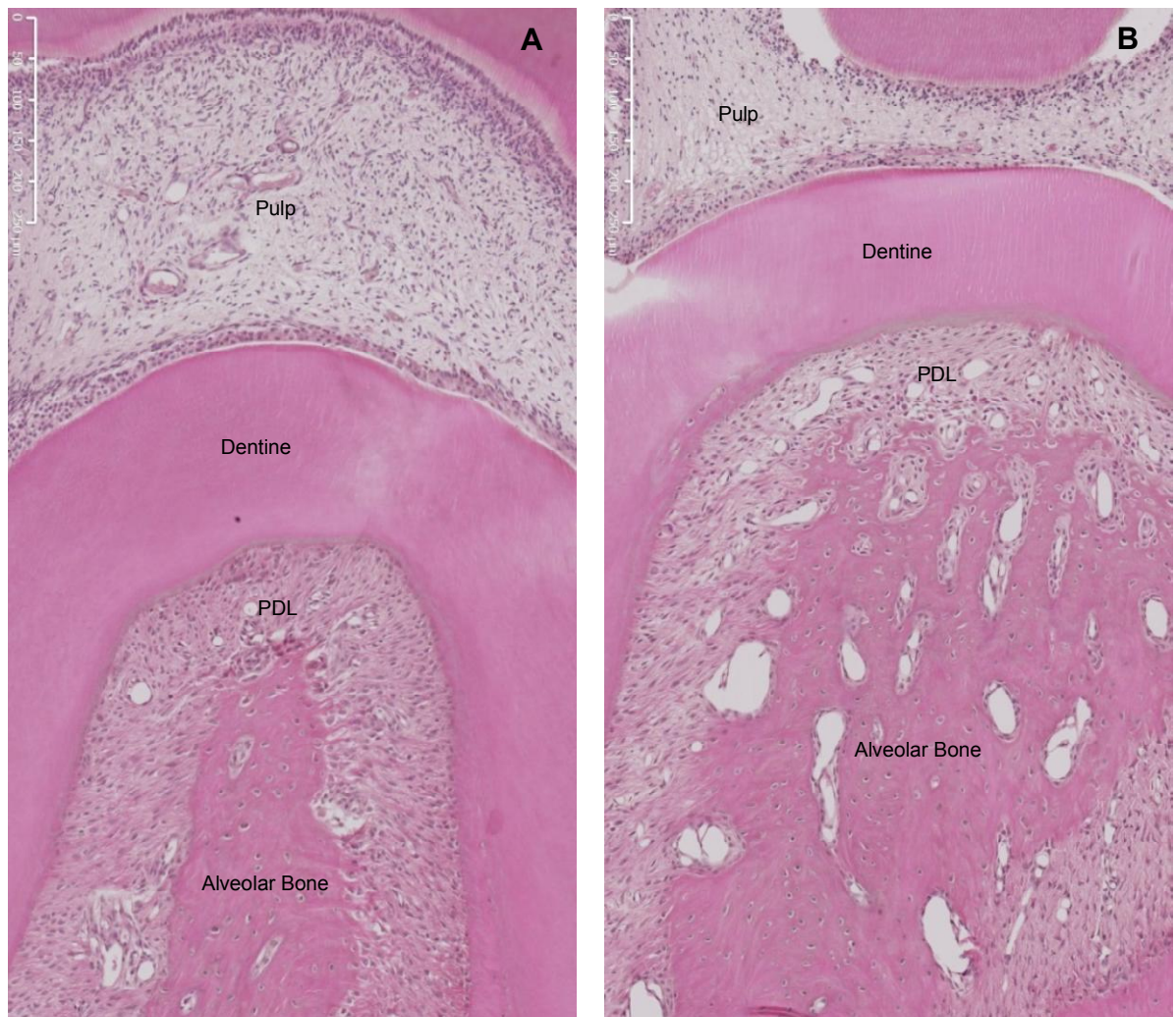


Figure 2. H and E sections of experimental right molar tooth of: (A) external control and (B) day 0 showing intact PDL and no ankylosis (x 10 magnification, ruler 0 - 250µm)

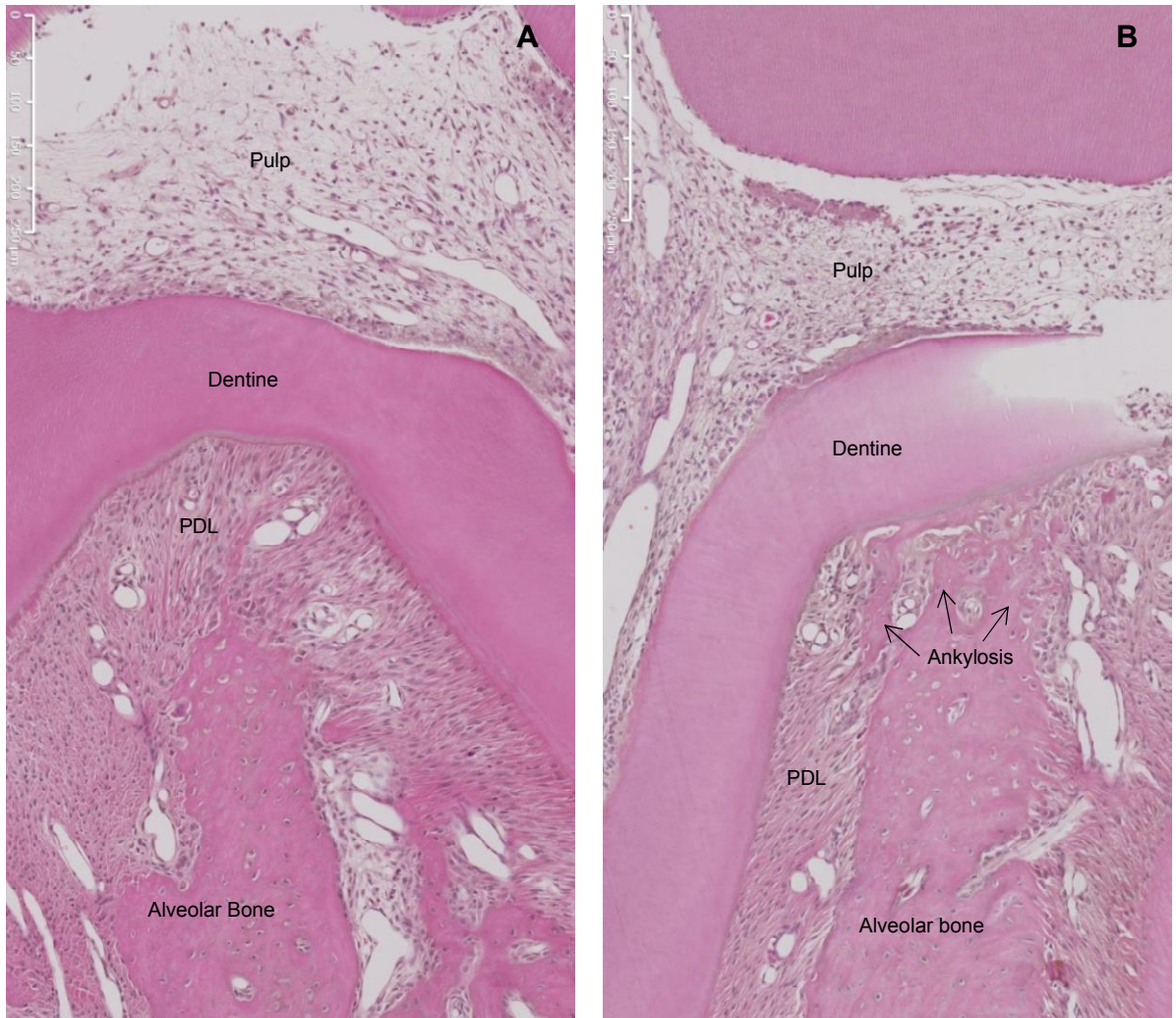


Figure 3. H and E sections of experimental right molar tooth of: (A) day 4 showing intact PDL and no ankylosis and (B) day 7 showing bony trabeculae invading the PDL (x 10 magnification, ruler 0 - 250µm)

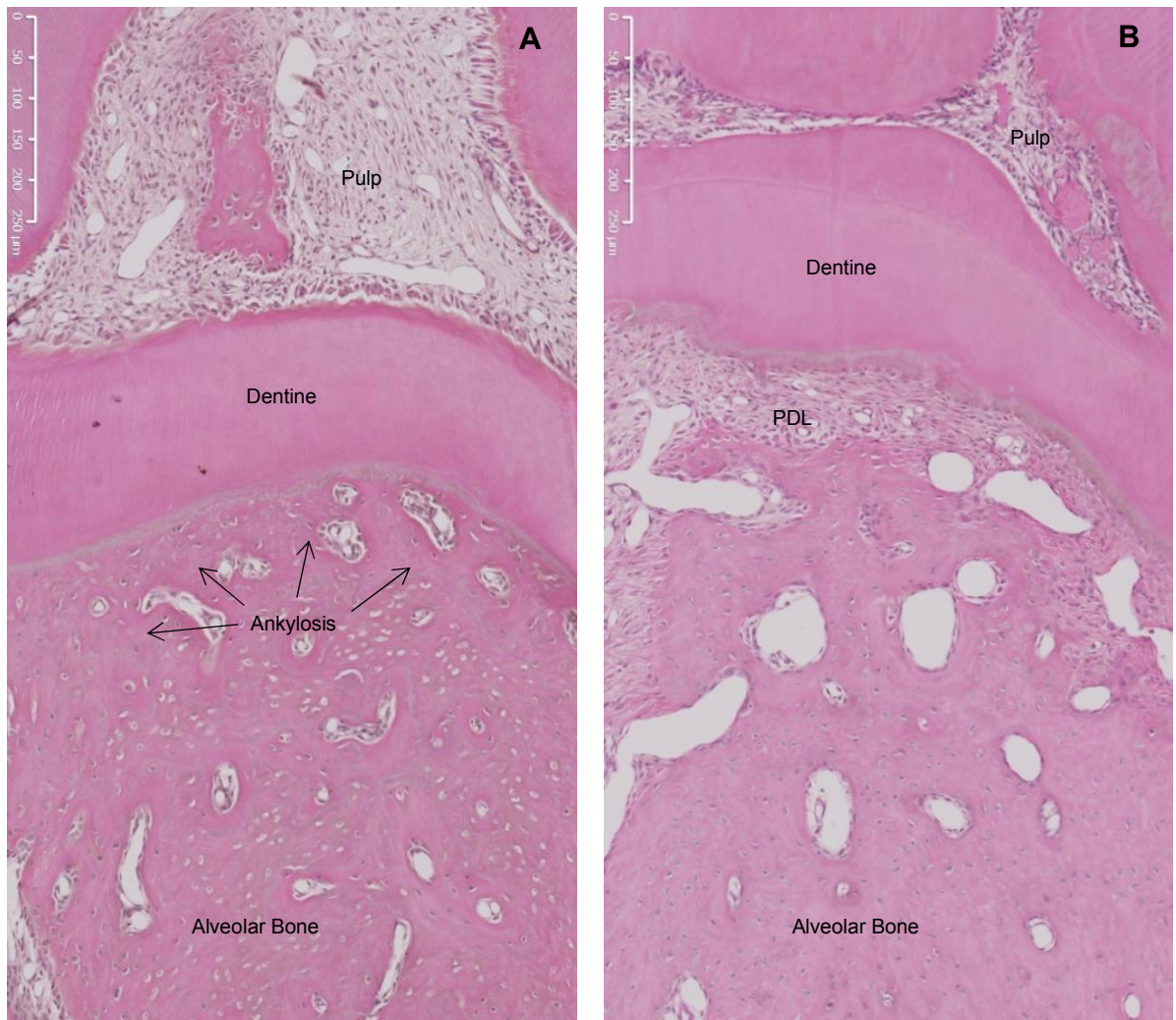


Figure 4. H and E sections of experimental right molar tooth of: (A) day 14 showing almost complete destruction of the PDL and (B) day 28 showing an intact PDL (x 10 magnification, ruler 0 - 250µm)

Immunohistochemical detection of sclerostin

Negative controls:

Positive and negative controls were performed to assess antibody specificity. Negative controls were sections on which the antibody had been omitted. The positive control was the alveolar bone as osteocytes are known to express sclerostin (van Bezooijen et al. 2004).

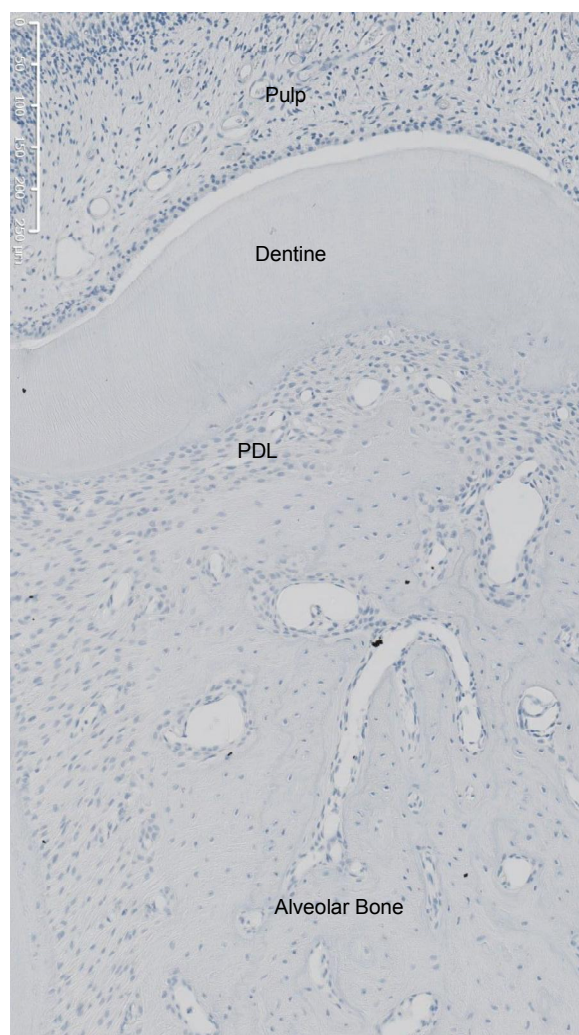


Figure 5. Negative control. Omission of sclerostin antibody. There is an absence of positive sclerostin staining (red) within cells. (x10 magnification, ruler 0-250µm).

Sclerostin expression in the dentoalveolar region:

No sclerostin expression was observed in the pulp. In the PDL, there was some diffuse staining that did not appear to be localised within the cells (Figure 6). Consequently, no further analysis of the pulp and PDL was carried out. Positive expression was observed in cementocytes and osteocytes (Figure 7). Positive staining was localised to the perinuclear region of the cell (Figure 8). In numerous empty lacunae positive sclerostin staining was still observed (Figure 9).

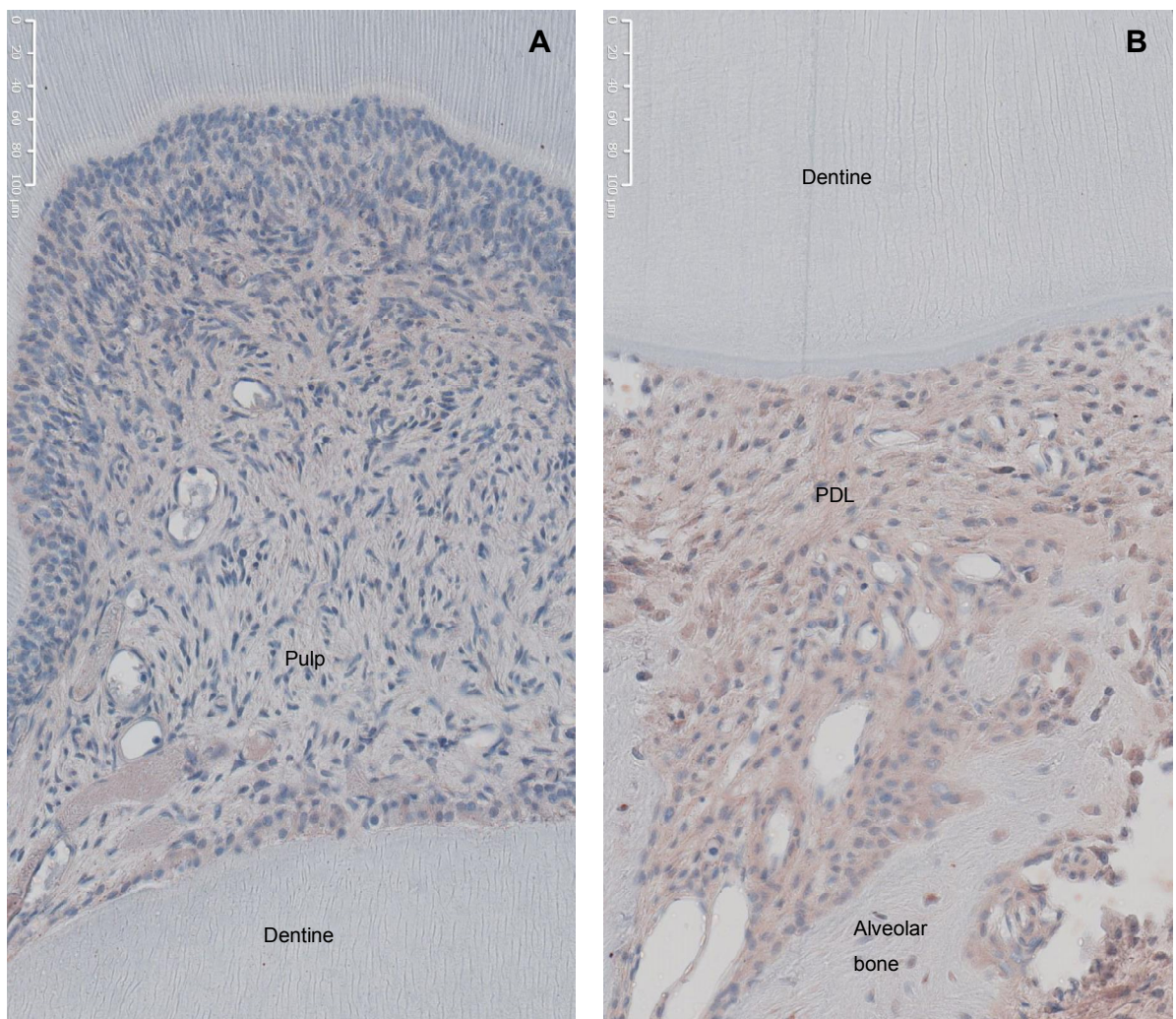


Figure 6. Lack of positive sclerostin expression in (A) pulp and (B) non-specific staining in the PDL. Counterstained with haematoxylin and lithium carbonate (x20 magnification, ruler 0-100µm)

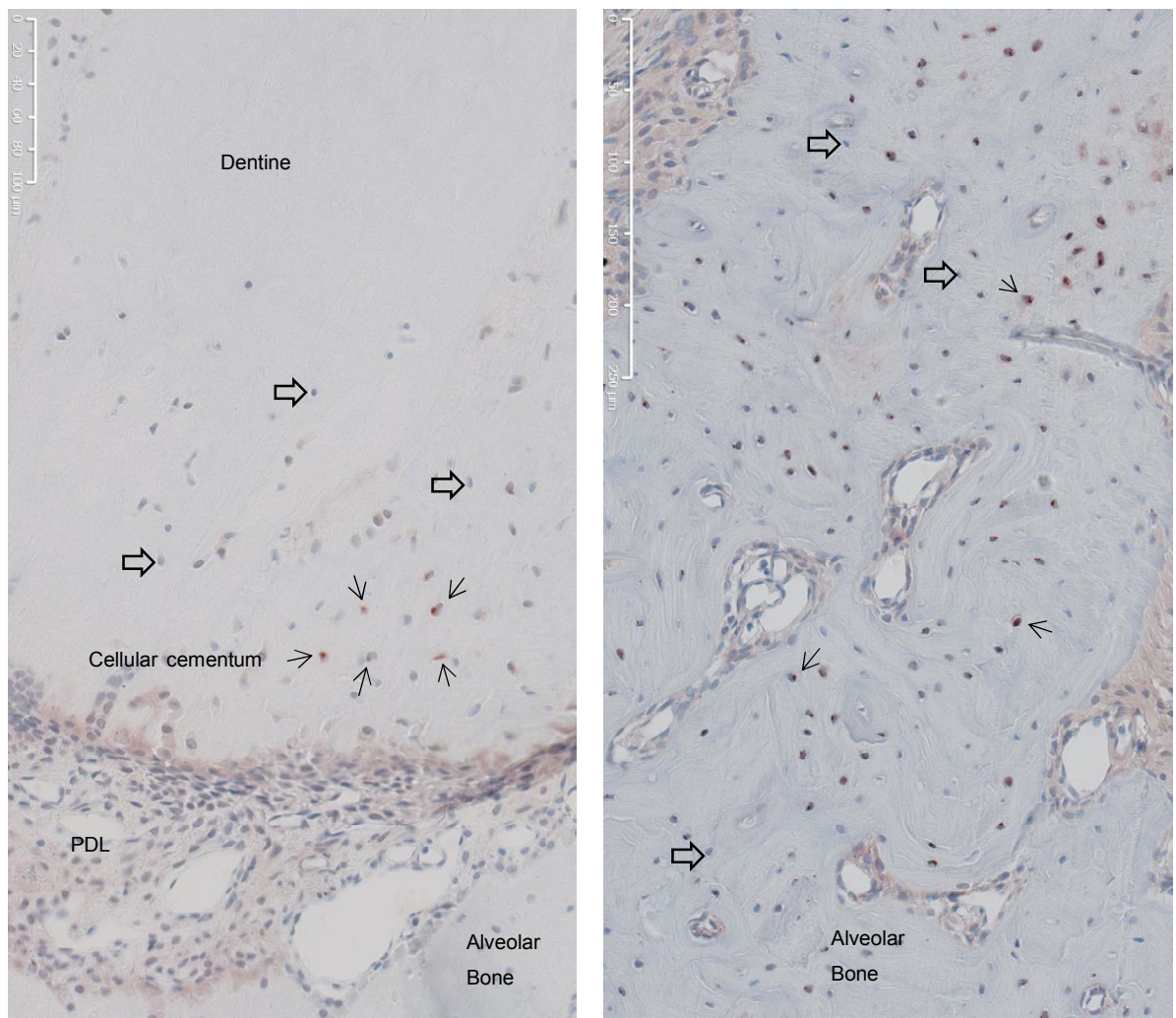


Figure 7. Positive sclerostin expression by: (A) cementocytes and (B) osteocytes. Positive cells stain red, counterstained with haematoxylin and lithium carbonate. Examples of positive staining are indicated by small arrows, negative staining by large arrows (x20 magnification, ruler 0-100μm)

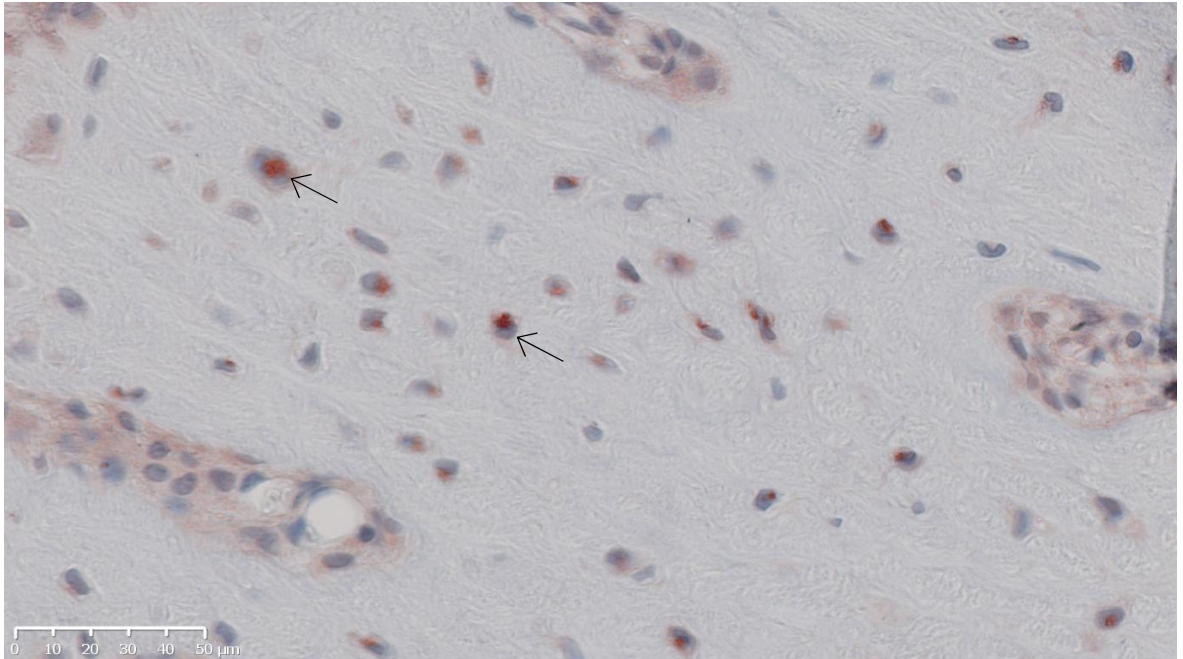


Figure 8. Osteocytes showing positive staining for sclerostin in the perinuclear region (examples indicated by arrows) (x40 magnification, ruler 0-50 μ m)

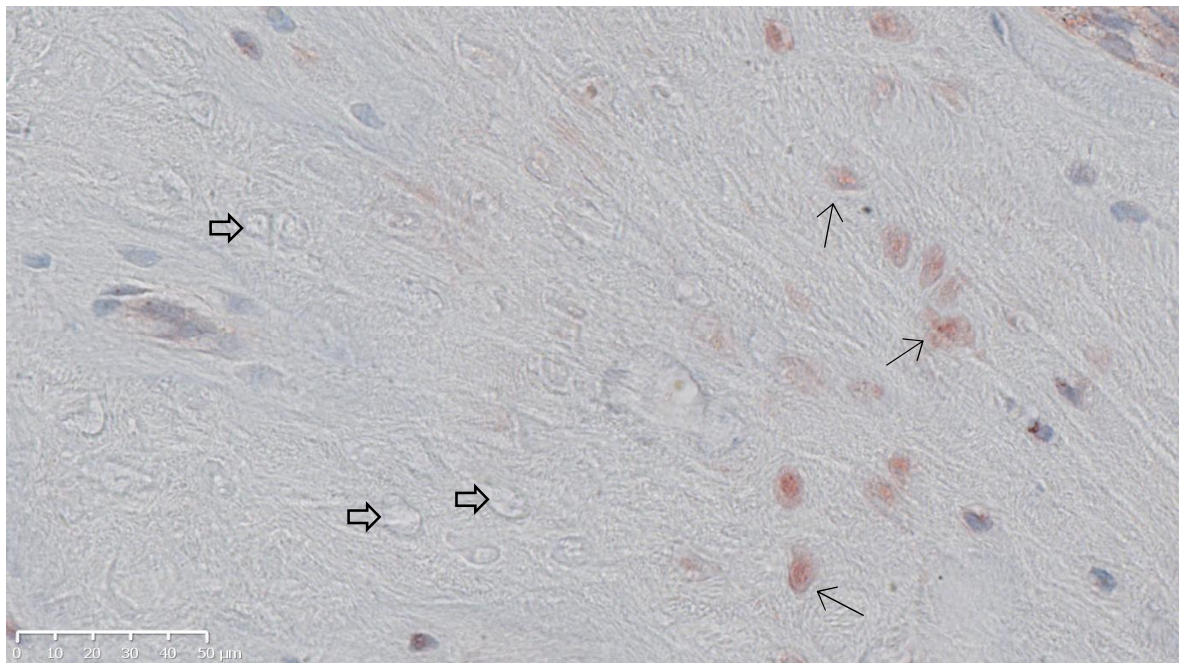


Figure 9. Empty lacunae showing absence (large arrows) and presence of positive sclerostin staining (small arrows) (x40 magnification, ruler 0-50 μ m)

Sclerostin expression in the alveolar bone

Empty lacunae

There was a clear reduction in cellularity at days 7 and 14 when the dentoalveolar ankylosis was maximal (Figure 10). There was an increase in the number of empty lacunae possibly indicating dead osteocytes.

Statistical analysis:

A statistically significant difference in the number of empty lacunae between experimental and internal control teeth (Table 3) was observed at days 7 and 14 which indicated that the cold insult and resulting ankylosis caused osteocyte death. There was also a statistically significant difference ($p < 0.05$) in the number of empty lacunae between experimental and internal control teeth in zone 1 (Table 4) which was the area closest to the furcation. This indicated that the osteocytes closest to the insult were more affected than cells distant to the cold insult (Figure 10).

Table 3. Empty lacunae counts: Interaction of group and day of sacrifice

Day of Sacrifice	Number of empty cells/ mm ²		Adjusted P value
	Experimental side	Internal control side	
External control	0.0	0.0	0.1000
0	0.0	0.0	0.1000
4	2.0	0.2	1.000
7	17.0	0.2	0.0115*
14	16.7	1.1	0.0304*
28	1.9	0.3	1.0000

Table 4. Empty lacunae counts: Interaction of group and zone

Zone	Number of empty cells/ mm ²		Adjusted P value
	Experimental side	Internal control side	
1	14.0	0.4	<0.0001*
2	8.0	0.1	0.393
3	2.5	0.3	1.0000
4	0.5	0.4	1.0000

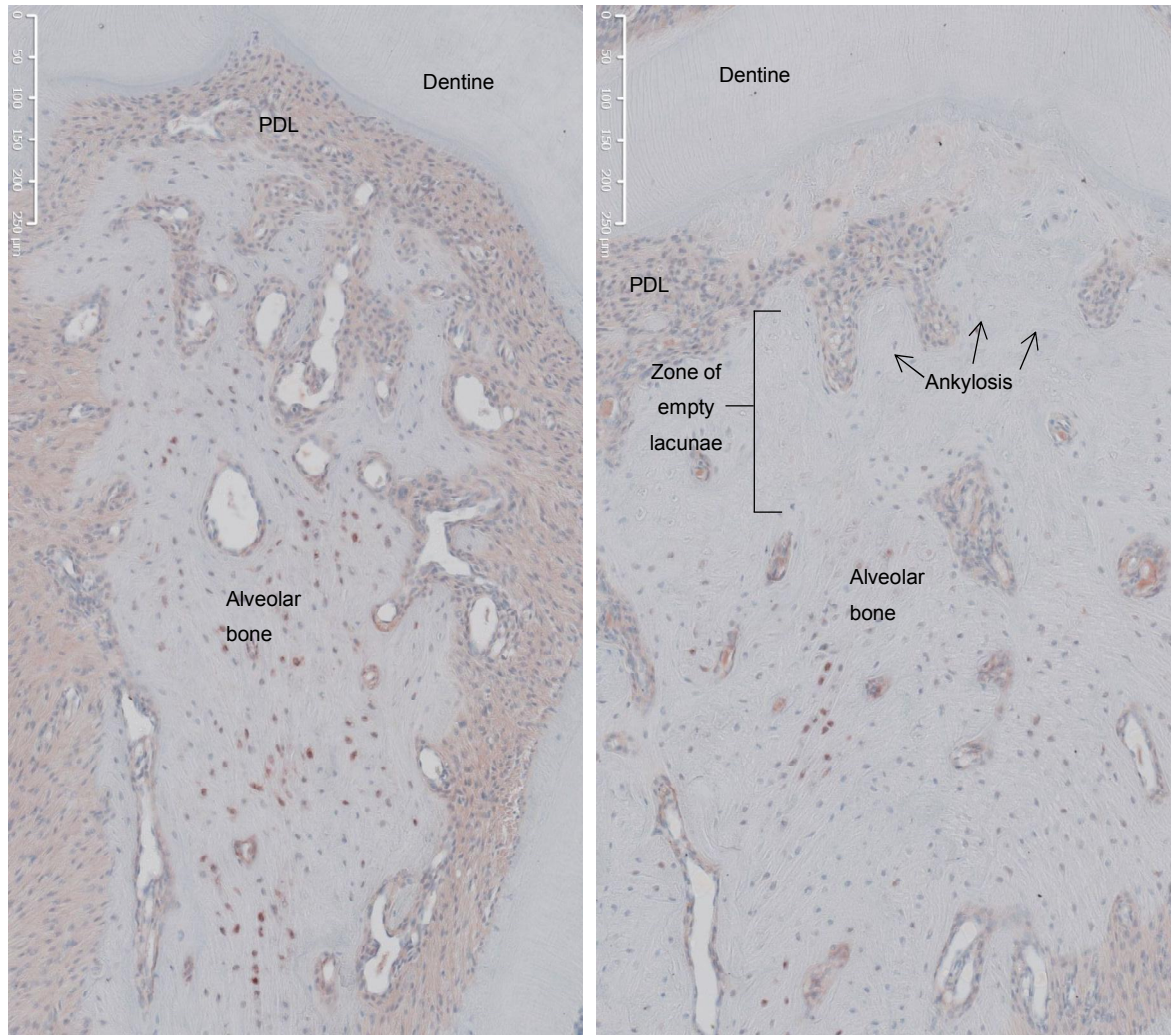


Figure 10. Empty lacunae and lack of osteocytes near the furcation area in an animal sacrificed at day 14 showing significant ankylosis (x 10 magnification, ruler 0 - 250 μ m) Left maxillary molar (internal control) is on the left, Right maxillary molar (Experimental freezing) is on the right.

Sclerostin positive osteocytes

The expression of sclerostin was examined at varying distances from the furcation region. Figure 11 shows the expression of sclerostin in zone 1 (closest to the furcation) at various time points. The most distinctive observation was the reduction in osteocyte numbers in association with the development of the ankylotic lesion (Figure 11D, E).

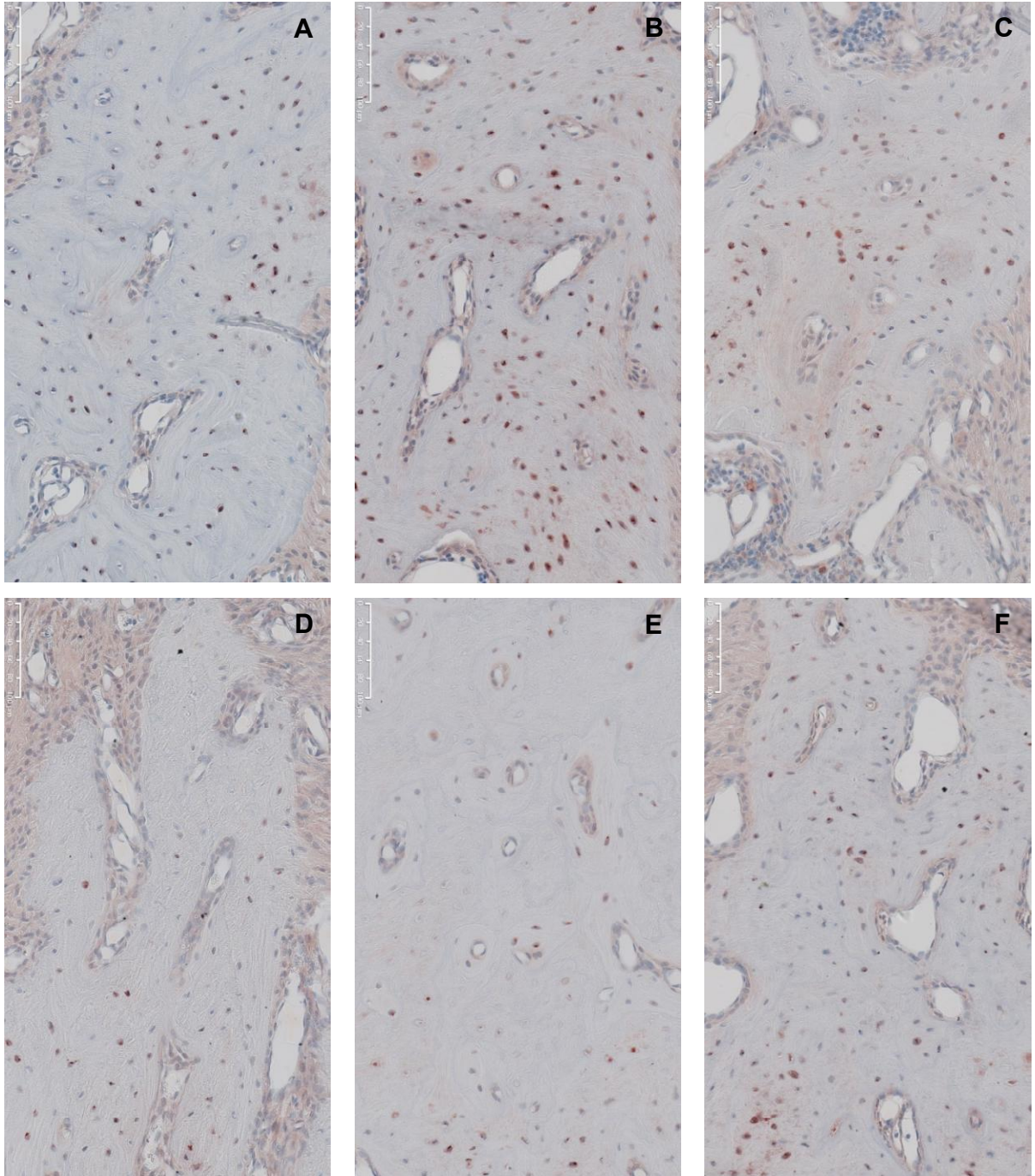


Figure 11. Expression of sclerostin in osteocytes in alveolar bone (zone 1) in the experimental teeth: (A) External control, (B) day 0, (C) day 4, (D) day 7, (E) day 14, (F) day 28. Red indicates sclerostin positive osteocytes, blue indicates sclerostin negative osteocytes (haematoxylin and lithium carbonate counterstain). (x20 magnification, ruler 0-100µm)

Statistical analysis:

The first model (Table 5, 6, 7) looks at the association between sclerostin positive cells (outcome variable) and internal control and experimental sides of the rat, the day of sacrifice and zone. A linear mixed-effects model was used with random effects included in the model to account for clustering. Least square means were calculated for each variable (Table 5). The zone had a statistically significant association with positive cell count (global P value<0.0001) (Table 6)

Table 5. Least squares means for outcome: sclerostin positive cells versus time, zone and side (C= internal control tooth, E= experimental tooth)

Predictor	Zone	Side	Time	Estimate	Standard Error
Time			External control	27.1304	4.7089
Time			Day 0	36.1858	4.7089
Time			Day 4	39.8146	4.7089
Time			Day 7	27.6622	4.7089
Time			Day 14	35.2308	4.7089
Time			Day 28	31.0412	4.7089
Side		C		34.6221	2.4720
Side		E		31.0662	2.4720
Zone	1			27.6761	2.2264
Zone	2			32.3781	2.2264
Zone	3			35.0013	2.2264
Zone	4			36.3212	2.2264

Table 6. Global P values for outcome: sclerostin positive cells vs time, zone and side

Predictor	Global P value
Time	0.3301
Zone	<0.0001*
Side	0.2685

Controlling for the variables, day of sacrifice and side of the rat (experimental vs internal control) there was a statistically significant difference between the least squares means for sclerostin positive cells in zone 1 (closest to furcation) and zone 3 (adjusted P value = 0.0005) and zone 1 and 4 (adjusted P value = <0.0001) after adjusting for multiple comparisons using the Sidak adjustment (Table 7).

Table 7. Differences of Least Squares Means for outcome: positive cells versus zone

Zone	Zone	Cell count estimate	Adjusted P value	Adjusted lower 95% CI	Adjusted upper 95% CI
1	2	-4.7020	0.0626	-9.5514	0.1474
1	3	-7.3252	0.0005*	-12.1746	-2.4758
1	4	-8.6451	<0.0001*	-13.4945	-3.7957
2	3	-2.6232	0.6318	-7.4726	2.2262
2	4	-3.9431	0.1781	-8.7925	0.9063
3	4	-1.3199	0.9784	-6.1693	3.5295

The second model assessed the association between sclerostin positive cells (outcome variable) and side of the rat, day of sacrifice, zone and interaction of side and zone. Least square means were calculated for each variable (Table 8). There was a significant interaction between zone and side when regressed against positive cell count, adjusting for day of sacrifice (interaction P value=0.0033) (Table 9).

Table 8. Least Squares Means for outcome: sclerostin positive cells versus time and zone*side (C=internal control tooth, E=experimental tooth)

Predictor	Zone	Side	Time	Estimate	Standard Error
Time			External control	27.1304	4.7089
Time			Day 0	36.1858	4.7089
Time			Day 4	39.8146	4.7089
Time			Day 7	27.6622	4.7089
Time			Day 14	35.2308	4.7089
Time			Day 28	31.0412	4.7089
Zone*Side	1	C		32.5044	2.9266
Zone*Side	1	E		22.8477	2.9266
Zone*Side	2	C		35.2858	2.9266
Zone*Side	2	E		29.4704	2.9266
Zone*Side	3	C		36.0074	2.9266
Zone*Side	3	E		33.9952	2.9266
Zone*Side	4	C		34.6907	2.9266
Zone*Side	4	E		37.9517	2.9266

Table 9. Global P values for outcome: positive cells versus time and zone*side

Predictor	Global P value
Time	0.3302
Zone	<0.0001*
Side	0.2685
Zone*Side	0.0033*

When controlling for the day of sacrifice, for the experimental tooth of the rats, zone 1 had a mean positive cell count significantly less than zone 3 (adjusted P value=0.0005) as did zones 1 compared with zone 4 (adjusted P value=<0.0001) and zone 2 compared with zone 4 (adjusted P value=0.0277). These results were statistically significant, even when adjusted for multiple comparisons (Table 10). There was no difference in sclerostin positive cell counts for the internal control tooth.

Table 10. Differences of Least Squares Means for outcome: positive cells versus time and zone*side (C=internal control tooth, E=experimental tooth)

Predictor	Zone	Side	Zone	Side	Estimate	Raw P value	Adjusted P value	Adjusted Lower 95% CL	Adjusted Upper 95% CL
Zone*Side	1	C	1	E	9.6567	0.0118	0.2827	-2.3206	21.6341
Zone*Side	1	C	2	C	-2.7813	0.2776	0.9999	-10.8088	5.2461
Zone*Side	1	C	3	C	-3.5030	0.1717	0.9949	-11.5305	4.5245
Zone*Side	1	C	4	C	-2.1863	0.3933	1.0000	-10.2138	5.8412
Zone*Side	1	E	2	E	-6.6228	0.0100	0.2450	-14.6502	1.4047
Zone*Side	1	E	3	E	-11.1475	<.0001	0.0005*	-19.1750	-3.1200
Zone*Side	1	E	4	E	-15.1040	<.0001	<0.0001*	-23.1315	-7.0765
Zone*Side	2	C	2	E	5.8153	0.1284	0.9787	-6.1620	17.7926
Zone*Side	2	C	3	C	-0.7217	0.7780	1.0000	-8.7491	7.3058
Zone*Side	2	C	4	C	0.5950	0.8162	1.0000	-7.4325	8.6225
Zone*Side	2	E	3	E	-4.5247	0.0777	0.8962	-12.5522	3.5027
Zone*Side	2	E	4	E	-8.4812	0.0010	0.0277*	-16.5087	-0.4537
Zone*Side	3	C	3	E	2.0122	0.5984	1.0000	-9.9651	13.9895
Zone*Side	3	C	4	C	1.3167	0.6071	1.0000	-6.7108	9.3442
Zone*Side	3	E	4	E	-3.9565	0.1228	0.9745	-11.9839	4.0710
Zone*Side	4	C	4	E	-3.2609	0.3934	1.0000	-15.2383	8.7164

The third model assessed the interaction of side*time, controlling for zone. The interaction term was not significant (P value=0.2136) (Table 11).

Table 11. Global P values for outcome: sclerostin positive cells versus zone and time*side

Predictor	Global P value
Zone	<0.0001*
Time	0.3301
Side	0.2482
Side*Time	0.2136

Table 12 Positive cell counts: interaction of zone and day of sacrifice, adjusting for group (experimental/control)

Day of Sacrifice	Number of positive cells/mm ²				Estimate (Adjusted 95% CI)	Adjusted P value	Estimate (Adjusted 95% CI)	Adjusted P value	Estimate (Adjusted 95% CI)	Adjusted P value
	Zone 1	Zone 2	Zone 3	Zone 4 (ref)	(Z1 vs Z4)	(Z1 vs Z4)	(Z2 vs Z4)	(Z2 vs Z4)	(Z3 vs Z4)	(Z3 vs Z4)
External control	26.3	25.4	27.3	29.5	-3.2 (-19.6, 13.2)	0.1000	-4.1 (-20.5, 12.3)	1.000	-2.2 (-18.6, 14.2)	1.0000
0	42.3	34.8	32.7	34.9	7.4 (-9.0,23.8)	1.0000	-0.1 (-6.5,16.3)	1.0000	-2.2 (-18.6, 14.3)	1.0000
4	33.0	38.7	43.7	43.8	-10.8 (-27.2,5.6)	0.9758	-5.1 (-21.5, 11.3)	1.0000	-0.1 (-16.5, 16.3)	1.0000
7	17.6	23.8	34.4	34.8	-17.2 (-33.6, -0.7)	0.0260*	-11.0 (-27.4, 5.4)	0.9615	-0.4 (-16.8, 16.0)	1.0000
14	25.5	37.6	34.9	42.9	-17.4 (-33.8, -1.0)	0.0203*	-5.3 (-21.7, 11.1)	1.0000	-8.1 (-24.5, 8.3)	1.0000
28	21.3	34.0	37.0	32.0	-10.7 (-27.1, 5.8)	0.9833	2.0 (-14.4, 18.4)	1.0000	5.0 (-11.4, 21.4)	1.0000

When the interaction between the day of sacrifice and zone, adjusting for the experimental or internal control side) is examined, there was a significant difference in the number of positive sclerostin cells between zones 1 and 4 at day 7 (adjusted P value=0.0260) and day 14 (adjusted P value=0.0203) (Table 12). There was no significant difference at other time points.

8.4.1 Summary of results

In the experimental tooth, sclerostin showed a trend of decreased expression in the alveolar bone closest to the furcation area with zones 1 and 2 showing less sclerostin expression compared with zones 3 and 4. This correlates with the data which revealed more empty lacunae closer to the tooth where the cold insult was applied. When the day of sacrifice was not considered, this difference between zones was not statistically significant. However, when examining the periods displaying maximal ankylosis, there were statistically significant differences between zones 1 and 4 in the experimental tooth on days 7 and 14. In analysing sclerostin expression related to the day of sacrifice, there was a slight decrease up to day 14 followed by a slight increase at day 28. When compared with the internal control tooth, this was not statistically significant.

8.5 Discussion

In the present investigation, the sclerostin protein was detected using immunohistochemistry in osteocytes of the alveolar bone and in cementocytes in cellular cementum. This is in accordance with the literature in which the presence of sclerostin has only been reported in cells embedded within a mineral matrix such as osteocytes (Winkler et al. 2003), cementocytes (Jäger et al. 2010; van Bezooijen et al. 2004) and mineralised hypertrophic chondrocytes in the human growth plate (van Bezooijen et al. 2009). Osteoclasts, as well as osteoblasts and lining cells were negative for sclerostin, consistent with previous research (Poole et al. 2005). SOST mRNA has been demonstrated to be expressed in other tissues particularly during embryogenesis. In humans, these tissues include the heart, aorta, liver and kidney (van Bezooijen 2008).

Sclerostin has been suggested to have a role in tooth development. Clinical manifestations of patients with van Buchem Disease (VBD) and sclerosteosis may include dental anomalies such as malocclusion, hypodontia and delayed tooth eruption although the teeth are usually structurally normal (Stephen et al. 2001). A mouse model has been used to evaluate the possible role of sclerostin in tooth development (Naka and Yokose 2011). Sclerostin was detected in secretory odontoblasts in fetal mouse tooth development and adult mouse morphogenesis. Immunohistochemistry confirmed that the expression of sclerostin was mainly present in the secretory odontoblasts responsible for pre-dentine secretion during the developmental stage. This provided support for the theory that sclerostin regulates odontoblastic function during matrix secretion in unerupted regions of the tooth and that sclerostin may play a physiological role in tooth development (Naka and Yokose 2011). In the current study, using a model of mature rat molars, no sclerostin was detected in the odontoblasts.

In the current study not all osteocytes were positive for sclerostin, even in control animals. This may indicate that sclerostin expression is cell-differentiation dependent. In vitro experiments using human and mouse cells have detected sclerostin only in late-differentiated cells (van Bezooijen et al. 2004). In human bone, sclerostin secretion by osteocytes is a delayed event in which the cells only secrete sclerostin after the onset of mineralisation to inhibit cortical bone formation and osteon infilling by cells of the osteoblast lineage (Poole et al. 2005). The more sclerostin-negative osteocytes were found in an individual osteon, the more likely it was that the osteon was in the process of bone formation. Most new osteocytes were negative for sclerostin staining for at least 16 days. Sclerostin expression in cementocytes was also restricted to those of cellular cementum in mice over 4 weeks old, suggesting a role for sclerostin in cementum homeostasis and possibly regenerative processes but not in early cementogenesis (Lehnen et al. 2012).

Histological examination of the alveolar bone showed that sclerostin was localised to the perinuclear area of the osteocytes and was also present in empty lacunae following osteocyte death after the freezing insult. The presence of sclerostin in the lacunae supports the existing evidence that sclerostin is a secreted protein and its transport may occur extra-cellularly from lacunae to lacunae (van Bezooijen et al. 2004).

The role of sclerostin is to inhibit bone formation and has been reported elsewhere (Winkler et al. 2003; van Bezooijen et al. 2004; Poole et al. 2005). One of the main mechanisms by which sclerostin controls bone formation is via its inhibition of Wnt signalling in which it binds with cell surface receptors LRP5 and LRP6. The result is prevention of transcription of genes required for osteoblast formation (Li et al. 2005). In addition to this, sclerostin has been shown to cause osteoblast apoptosis (Sutherland et al. 2004).

Experimental teeth that developed dentoalveolar ankylosis in the present study showed a significantly higher proportion of empty lacunae in the area of alveolar bone closest to the ankylotic lesion. These empty lacunae were considered to be associated with osteocyte death. If the thermal insult caused osteocyte cell death, it may also be possible that other key functions of the osteocyte are affected in the surviving osteocyte population. A trend towards a decreased expression of sclerostin near the ankylotic region when compared with bone more distant from the site of the injury, was observed. In the normal situation, it appears that the Wnt signalling pathway is usually held in the “off” position in bone due to the high levels of sclerostin produced by osteocytes. The reduction of sclerostin following a cold thermal insult and dentoalveolar ankylosis may result in hyperactivation of the Wnt signalling pathway and increased bone formation. It is this loss of SOST/sclerostin that is responsible for the abnormal bone growth that is seen in sclerosteosis patients (Moester et al. 2010; van Bezooijen 2008).

Of the animals sacrificed at day 28, one rat showed persistence of the ankylotic region, although it was reduced in size compared with animals at day 14. The other animals at day 28 showed no evidence of ankylosis and the histology resembled the internal control tooth. There are possibly two explanations. The seemingly normal animals may not have received the same degree of exposure to the cold insult and never developed ankylosis, but given that every other animal at days 7 and 14 demonstrated significant ankyloses, this possibility is unlikely. The other explanation could be that there is a degree of healing response that has occurred in the two animals. The resolution of the ankylotic lesion may partly be related to the experimental model, in which a thermal insult induced ankylosis. In a clinical situation, the factors that initiate ankylosis are incompletely understood and may differ from this model. The absence of the thermal insult at the later time points may influence the regeneration of the PDL and resolution of the ankylosis.

Dentoalveolar ankylosis has been shown to occur as a repair process following injury to teeth and is commonly seen following trauma (Andreasen 1975; Hecova et al. 2010). In health, the periodontal ligament must have the capacity to resist induction to osteogenesis through cell signalling systems such as the release of cytokines and growth factors that accurately 'measure' and maintain the PDL width, ensuring separation of the root and alveolar bone (Melcher 1970; McCulloch 1995). Traumatic injury disrupts this homeostasis. A number of studies have demonstrated that the source of the cells which repopulate the PDL space following trauma or injury that determine whether ankylosis occurs (Erasquin and Devoto 1970; Lin et al. 2000; Melcher 1970; Line et al. 1974). When the space is repopulated by cells from a source outside the true PDL tissues (such as alveolar bone, bone marrow or soft connective tissue) osteoclasts and osteogenesis occur, resulting in healing via a dentoalveolar ankylosis. Having vital PDL cells present after trauma to the tissue appears crucial for repair and regeneration to a functionally normal PDL. The reduction in sclerostin expression in this model may demonstrate that, in addition to the central role of the cells of the periodontal ligament, the osteocyte may play a role in the tissue which repopulates the defect. With a reduction in sclerostin and activation of the Wnt signalling

pathway, osteoblast production increases and osteoclastogenesis is inhibited via RANK/RANKL. In this situation, osteogenesis predominates over osteoclastogenesis and the bony ankylotic lesion is not removed and the PDL is not given the opportunity to re-establish itself. In those animals that showed regeneration of the PDL, it is possible that a recovery in the production of sclerostin allowed the balance between osteogenesis and osteoclastogenesis to be re-established to normal levels. In this experiment there was a decrease in sclerostin expression up to day 14 followed by a slight increase at day 28. This was not statistically significant when compared with the internal control tooth, however.

The sample size in this study was small with three rats in each group. Repeating the experiment with more rats at each time point may reduce the uncertainty related to the possible healing of the ankylotic lesion. Having time points closer together, particularly between days 14 and 28 will also allow for a more detailed analysis of how the ankylosis progresses.

8.6 Conclusions

The possible repair of the PDL following trauma is complex and the present research may contribute evidence that the osteocyte, as well as being the orchestrator of bone, may extend its control to influencing the regeneration of the PDL. The following conclusions were drawn from this rat model following hypothermal insult:

- 1) Changes were observed in the expression of sclerostin within the alveolar bone subsequent to a freezing insult therefore, the null hypothesis is rejected.
- 2) The difference in the number of empty lacunae between zones indicated that the freezing insult results in the death of osteocytes which coincided with the timing of maximal ankylosis.
- 3) When ankylosis was present, there was a statistically significant difference in sclerostin expression between the areas of bone closest to, and farthest away, from the

furcation area. This suggested that the death of the osteocytes resulted in a reduction in sclerostin expression.

4) There was a non-statistically significant trend towards reduced sclerostin expression over time as sclerostin expression decreased at days 7 and 14 followed by a slight increase in expression at day 28 following hypothermal insult. The slight increase in sclerostin expression at day 28 may indicate the establishment of a healing response.

8.7 References

- Andlaw, R., 1974. Submerged Deciduous Molars. A Review, with Special Reference to the Rationale of Treatment. *Journal of the International Association of Dentistry for Children*, 5, pp.59–66.
- Andreasen, J.O., 1975. Periodontal healing after replantation of traumatically avulsed human teeth. Assessment by mobility testing and radiography. *Acta Odontologica Scandinavica*, 33, pp.325–335.
- Van Bezooijen, R.L. et al., 2004. Sclerostin is an osteocyte-expressed negative regulator of bone formation, but not a classical BMP antagonist. *The Journal of Experimental Medicine*, 199(6), pp.805–14.
- Van Bezooijen, R.L. et al., 2007. Sclerostin expression is absent in cementocytes in teeth and in osteocytes in bone biopsies of patients with Van Buchem disease. *Bone*, 40, pp.s216–2s17.
- Van Bezooijen, R.L. et al., 2009. Sclerostin in mineralized matrices and van Buchem disease. *Journal of dental research*, 88(6), pp.569–74.
- Van Bezooijen, R.L., 2008. SOST/Sclerostin: An Osteocyte-Derived Inhibitor of Bone Formation that Antagonizes Canonical Wnt Signaling. In *Principles of Bone Biology*. pp. 139–152.
- Van Buchem, F., Hadders, H. & Ubbens, R., 1955. An uncommon familial systemic disease of the skeleton: Hyperostosis corticalis generalisata familiaris. *Acta Radiologica*, 44, pp.109–120.
- Dreyer, C., Pierce, A. & Lindskog, S., 2000. Hypothermic insult to the periodontium: a model for the study of aseptic tooth resorption. *Endodontics & Dental Traumatology*, 16, pp.9–15.

- Ekim, S. & Hatibovic-Kofman, S., 2001. A treatment decision-making model for infra-occluded primary molars. *International Journal of Paediatric Dentistry*, 11, pp.340–346.
- Erausquin, J. & Devoto, F.C., 1970. Alveolodental ankylosis induced by root canal treatment in rat molars. *Oral Surgery*, 30(1), pp.105–116.
- Hecova, H. et al., 2010. A retrospective study of 889 injured permanent teeth. *Dental traumatology*, 26(6), pp.466–75.
- Jackson, A. et al., 2005. Gene array analysis of Wnt-regulated genes in C3H10T1/2 cells. *Bone*, 36(4), pp.585–98.
- Jäger, A. et al., 2010. Localization of SOST/sclerostin in cementocytes in vivo and in mineralizing periodontal ligament cells in vitro. *Journal of Periodontal Research*, 45(2), pp.246–54.
- Kjaer, I., Fink-Jensen, M. & Andreasen, J.O., 2008. Classification and sequelae of arrested eruption of primary molars. *International journal of paediatric dentistry*, 18(1), pp.11–7.
- Kuchler, U. et al., 2014. Dental and periodontal phenotype in sclerostin knockout mice. *International Journal of Oral Science*, 6(2), pp.70–6.
- Kuroi, J., 1981. Infraocclusion of primary molars: an epidemiologic and familial study. *Community Dentistry and Oral Epidemiology*, 9, pp.94–102.
- Kuroi, J. & Thilander, B., 1984. Infra-occlusion of Primary Molars with Aplasia of the Permanent Successor. A Longitudinal Study. *The Angle Orthodontist*, 54(4), pp.283–294.
- Lehnen, S.D.M. et al., 2012. Immunohistochemical evidence for sclerostin during cementogenesis in mice. *Annals of Anatomy*, 194(5), pp.415–21.
- Li, X. et al., 2005. Sclerostin binds to LRP5/6 and antagonizes canonical Wnt signaling. *The Journal of biological chemistry*, 280(20), pp.19883–7.
- Li, X. et al., 2009. Sclerostin Antibody Treatment Increases Bone Formation, Bone Mass, and Bone Strength in a Rat Model of Postmenopausal Osteoporosis. *Journal of bone and mineral research*, 24(4), pp.578–588.
- Lin, D.G. et al., 2000. Storage conditions of avulsed teeth affect the phenotype of cultured human periodontal ligament cells. *Journal of periodontal research*, 35(1), pp.42–50.

- Line, S.E., Polson, A.M. & Zander, H.A., 1974. Relationship between periodontal injury, selective cell repopulation and ankylosis. *Journal of periodontology*, 45(10), pp.725–730.
- McCulloch, C., 1995. Origins and functions of cells essential for periodontal repair: the role of fibroblasts in tissue homeostasis. *Oral Diseases*, 1, pp.271–278.
- Melcher, A., 1970. Repair of Wounds in the Periodontium of the Rat. Influence of the Periodontal Ligament on Osteogenesis. *Archives of Oral Biology*, 15, pp.1183–1204.
- Messer, L.B. & Cline, J.T., 1980. Ankylosed primary molars : Results and treatment recommendations from an eight-year longitudinal study. *Pediatric Dentistry*, 2(1), pp.37–47.
- Moester, M.J.C. et al., 2010. Sclerostin: current knowledge and future perspectives. *Calcified tissue international*, 87(2), pp.99–107.
- Naka, T. & Yokose, S., 2011. Spatiotemporal expression of sclerostin in odontoblasts during embryonic mouse tooth morphogenesis. *Journal of Endodontics*, 37(3), pp.340–5.
- Nishiyama, Y. et al., 2015. Changes in the spatial distribution of sclerostin in the osteocytic lacuno-canalicular system in alveolar bone due to orthodontic forces, as detected on multimodal confocal fluorescence imaging analyses. *Archives of Oral Biology*, 60(1), pp.45–54.
- Padhi, D. et al., 2011. Single-dose, placebo-controlled, randomized study of AMG 785, a sclerostin monoclonal antibody. *Journal of bone and mineral research*, 26(1), pp.19–26.
- Ponduri, S., Birnie, D.J. & Sandy, J.R., 2009. Infra-occlusion of secondary deciduous molars - an unusual outcome. *Journal of Orthodontics*, 36, pp.186–189.
- Poole, K.E.S. et al., 2005. Sclerostin is a delayed secreted product of osteocytes that inhibits bone formation. *FASEB journal*, 19(13), pp.1842–4.
- Sanmuganathan, D., 2011. *The role of the osteocyte in orthodontic tooth movement in the rat dento-alveolar complex*. Doctor of Clinical Dentistry thesis. The University of Adelaide, South Australia
- Semënov, M., Tamai, K. & He, X., 2005. SOST is a ligand for LRP5/LRP6 and a Wnt signaling inhibitor. *The Journal of biological chemistry*, 280(29), pp.26770–5.
- Stephen, L.X.G. et al., 2001. Dental and oral manifestations of Sclerostosis. *International Dental Journal*, 51, pp.287–290.

- Sutherland, M.K. et al., 2004. Sclerostin promotes the apoptosis of human osteoblastic cells: a novel regulation of bone formation. *Bone*, 35(4), pp.828–35.
- Tan, C., 2011. *A qualitative investigation of RANKL, RANK and OPG in a rat model of transient ankylosis*. Honors Project, The University of Adelaide, South Australia
- Taut, A.D. et al., 2013. Sclerostin antibody stimulates bone regeneration after experimental periodontitis. *Journal of Bone and Mineral Research*, 28(11), pp.2347–56.
- Truswell, A.S., 1958. Osteopetrosis with syndactyly. A morphological variant of Albers-Schonberg's disease. *The Journal of Bone and Joint Surgery*, 40B(2), pp.209–218.
- Winkler, D.G. et al., 2003. Osteocyte control of bone formation via sclerostin, a novel BMP antagonist. *The EMBO journal*, 22(23), pp.6267–76.

9 CONCLUDING REMARKS

9.1 Conclusions

The development of ankylosis and the subsequent regeneration of the PDL following trauma is a complex issue controlled by a multitude of signalling factors. The following conclusions were drawn from the present study of a hypothermal insult in a rat model.

- 1) A 10 minute application of dry ice to the upper right first molar tooth of a rat induced dentoalveolar ankylosis that led to destruction of the PDL in the furcation region 14 days after application.
- 2) After 28 days there was variation in the appearance of the PDL between animals which may have indicated a possible healing response and biological variation.
- 3) The difference in the number of empty lacunae between zones indicated that the hypothermal insult may result in the death of osteocytes which coincides with the timing of maximal ankylosis.
- 4) Changes were observed in the expression of RANKL within the pulp and PDL subsequent to a hypothermal insult
- 5) ERM strongly expressed RANKL and their presence or absence may play a role in the regeneration of the PDL following dentoalveolar ankylosis.
- 6) No changes were observed in the expression of RANKL by osteocytes in the alveolar bone.
- 7) Changes were observed in the expression of sclerostin within the alveolar bone subsequent to a hypothermal insult. When ankylosis was present, there was a statistically significant difference in sclerostin expression between the areas of bone closest to, and farthest away, from the furcation area.
- 8) There was a non-statistically significant trend towards reduced sclerostin expression over time as sclerostin expression reduced at days 7 and 14 followed by a slight increase in expression at day 28. The slight increase in sclerostin expression at day 28 may indicate the establishment of a healing response.

9.2 Limitations of the study

The rats that were used had been prepared for a previous study. This limited the power of the study as the number of animals was pre-determined. Repeating the experiment with more rats at each time point may reduce the uncertainty related to the possible healing of the ankylotic lesion. The previous preparation of the material also meant that the time periods between the hypothermal insult and sacrifice of the animal was fixed. Having time points closer together, particularly between days 14 and 28 will also allow for a more detailed analysis of the progression of ankylosis.

The antibodies used were polyclonal due to the lack of availability of monoclonal antibodies. This may have affected the specificity of the results.

As with all animal studies, the data obtained must be viewed with caution before applying the results to humans.

9.3 Suggestions for future work:

The most interesting finding in the current study was the apparent healing response 28 days after the hypothermal insult. It was difficult to draw firm conclusions due to the limitations outlined above. If the study were to be repeated, the sample size should be increased with more time points. This would be particularly useful between days 14 and 28 during which time the ankylosis appeared to resolve.

Although this investigation did not detect the presence of osteocyte-derived RANKL, it did detect significant expression of RANKL in the epithelial rests of Malassez. These epithelial rests have the potential to play a central role in dentoalveolar ankylosis and are worthy of further investigation.

Research in the medical field has shown sclerostin to be a highly significant molecule in bone metabolism that is likely to play a role in dentoalveolar ankylosis. Immunohistochemical analysis is limited to the detection of the presence or absence of sclerostin. Further research into the role of sclerostin might engage more sensitive methods to detect the presence of sclerostin mRNA and generating dentoalveolar ankylosis in sclerostin knock-out mice.

10 APPENDICES

10.1 Optimisation of immunohistochemical detection for RANKL and sclerostin

Optimisation was performed prior to immunohistological staining to determine optimal antibody dilution and the antigen retrieval method required to achieve minimal background staining and optimal antibody specific staining. Positive and negative controls were performed to assess antibody specificity.

10.2 Materials Utilised

Tris-EDTA Buffer (10mM Tris Base, 1mM EDTA solution, pH 9.0)

Tris base	1.21g
EDTA	0.37g
MilliQ water	1L

5 x Phosphate Buffered Saline (pH 7.2 – 7.4)

Sodium di-hydrogen orthophosphate	3.93g
Di-sodium hydrogen orthophosphate	15.2g
Sodium chloride	45.0g
MilliQ water	1L

5 x Tris-Phosphate Buffered Saline (pH 7.2-7.4)

Tris base	30.275g
Sodium di-hydrogen orthophosphate	3.93g
Di-sodium hydrogen orthophosphate	15.2g
Sodium chloride	45.0g
MilliQ water	1L

Endogenous Peroxidase Block

NaN ₃ (sodium azide) Labchem, Auburn, Australia	0.1%
H ₂ O ₂	1% (added before use)
In PBS	

1% BSA

1gm Albumin from Bovine Serum (electrophoresis grade), (Sigma Aldrich Pty Ltd, Sydney, Australia)
100mL PBSx1

Tris-HCl (0.2 M pH 8.2)

Tris base	2.42g
MilliQ water	100ml

Ajust pH to 8.2 using HCl

ImmPRESS-AP Anti-Rabbit Ig (alkaline phosphatase) Polymer Detection Kit

Vector Laboratories, USA
Ready-to-use 2.5% normal horse serum blocking solution
Ready to use anti-rabbit Ig
Perform staining procedure at room temperature (20 - 25 °C)
Store at 4 °C

VECTOR Red Alkaline Phosphatase (AP) Substrate Kit

Vector Laboratories, USA

Store at 2-8 °C

Preparation of working solution:

To 5 ml of 100 mM Tris-HCl, pH 8.2 buffer

Add 2 drops (80 µl) of Reagent 1

Add 2 drops (80 µl) of Reagent 2

Add 2 drops (80 µl) of Reagent 3

Mix well before use

AEC (3-Amino-9-ethylcarbazole) substrate chromogen

Dako Australia Pty. Ltd., NSW, Australia

Store at 4°C

Swine anti-goat Ig's HRP

Invitrogen, distributed by Life Technologies Australia Pty Ltd, Victoria Australia

Store in freezer (-5 to -30°C)

Rabbit anti-swine Ig's

Dako Australia Pty. Ltd., NSW, Australia

Store at 2-8°C

Isotype control universal rabbit Ig

N1699

Dako Australia Pty. Ltd, NSW, Australia

Anti-sRANKL antibody

Company	Abcam, United Kingdom.
Catalog number	AB62516
Applications	ELISA, ICC/IF, IHC-P, WB Recommended concentration of 5 µg/ml (human liver)
Description	Rabbit polyclonal to sRANKL
Immunogen	Synthetic peptide (Human) of 14 amino acids from near the centre of sRANKL
Species reactivity	Human, Mouse, Rat
Clonality	Polyclonal
Isotype	IgG
Purity	Immunogen affinity purified
Form	Liquid
Storage buffer:	Preservative: 0.02% Sodium Azide Constituents: PBS
Concentration	1mg/ml
Storage	Store at 4°C. Aliquot and store at -20C long-term.

Goat anti-mouse polyclonal SOST/Sclerostin

Company	RandD Systems, distributed by Bio-Scientific Pty. Ltd., NSW, Australia
Catalog Number	AF1589
Applications	WB, IHC-F Recommended concentration 5-15 µg/ml (frozen mouse embryo)
Description	Goat polyclonal to mouse SOST/Sclerostin
Immunogen	Mouse myeloma cell line NS0-derived recombinant mouse SOST/Sclerostin Gln24-Tyr211 Accession # NP_077769
Species reactivity	Mouse
Clonality	Polyclonal
Isotype	IgG
Purity	Antigen Affinity-purified
Form	Lyophilized from a 0.2 µm filtered solution in PBS with Trehalose
Concentration	Reconstitute at 0.2 mg/mL in sterile PBS.
Storage	Use a manual defrost freezer, avoid repeated freeze-thaw cycles. 12 months from date of receipt, -20 to -70 °C as supplied 1 month 2 to 8 °C under sterile conditions after reconstitution 6 months -20 to -70 °C under sterile conditions after reconstitution.

10.3 Tartrate-resistant acid phosphatase (TRAP) staining protocol

Method

Tatsuo Suda Method

Solutions (to make 100ml)

Naphthol AS-MX phosphate	10mg
N.N-Dimethylformamide	1ml
0.1M Acetate Buffer (pH 5.0)	100ml
Fast Red LB violet salt F3381	60mg
Sodium Tartrate	1.15g

Make just enough volume for all slides you have

Staining solution

Glass Beaker 1:

Dissolve Naphthol AS-MX phosphate in N.N-Dimethylformamide

Once dissolved: Add half 0.1M Acetate Buffer slowly, swirling as adding

Glass Beaker 2:

Dissolve Fast Red LB violet salt F3381 in 0.1M Acetate Buffer (added a little bit at a time)

Combine contents of beakers 1 and 2 using 25-50 ml pipette

Add Sodium Tartrate and stir until dissolved

Check pH of solution – should be ~ pH 5.0

Filter and use immediately

Staining procedure

Dewax slides and rehydrate

Rinse slides 3 times in MilliQ

Place slides in staining chamber with filtered staining solution

Place in 37°C incubator for 30 minutes in the dark

Rinse slides in MilliQ

Counterstain with haematoxylin and lithium carbonate

Mount slides in aqueous mount only

Result

Acid phosphatase activity = red

TRAP cells are counted as positive multi-nucleated cells if more than 3 nuclei

10.4 Immunohistological staining protocol

10.4.1 RANKL

10.4.1.1 Paraffin removal protocol

1. Histolene 1 for 10 minutes
2. Histolene 2 for 10 minutes
3. 100% ethanol for 5 minutes
4. 95% ethanol for 5 minutes
5. Wash twice with MilliQ water and once with Tris-PBS (5 minutes each time)

10.4.1.2 Antigen unmasking protocol

1. Tris-EDTA, pH 9.0, heated to 65°C (water bath)
2. Slides immersed in tris-EDTA for 10 minutes
3. Slides immersed in tris-EDTA left to cool on the bench for 20 minutes
4. Wash 3 times in 1x Tris-PBS for 5 minutes

10.4.1.3 Immunohistological detection method for RANKL

Protocol based on alkaline phosphatase (AP) reaction using the ImPRESS AP reagent kit (Cat No. MP-5401, Vector Laboratories, USA).

Controls

Negative control: Omission of antibody

Positive control: Human liver tissue. This was performed using the initial immunohistochemical detection method (Avidin Biotin Complex) which was subsequently discarded in favour of the AP method.

Procedure - Day 1:

1. PAP (hydrophobic) pen around each section
2. Apply diluted horse blocking serum (yellow bottle in the kit) to all sections
3. Incubate for 30 minutes then remove excess. No wash
4. Application of primary antibody:
 - a. Prepare rabbit polyclonal to sRANKL antibody (ab62516) (Abcam, United Kingdom) 1:500 dilution of 1.00mg/ml in 1x Tris-PBS.
 - b. Apply to all sides except negative controls (omission of antibody)
 - c. Place in wet chamber overnight at room temperature

Procedure - Day 2:

1. Wash in 1x Tris-PBS 3 times for 5 minutes
2. Application of secondary antibody (blue bottle in the kit). Pipette onto slides and leave for 30 minutes at room temperature
3. Wash in 1x Tris-PBS 3 times for 5 minutes
4. Develop colour using Vector® Red (Vector Red Substrate Kit, SK-5100, Vector Laboratories, USA) for 10 minutes at room temperature, covered, in a dark cupboard
5. Wash in MilliQ water 2 times for 5 minutes
6. Counterstain:
 - a. Haematoxylin 10 seconds
 - b. Wash in tap water until water runs clear
 - c. Lithium carbonate 30 seconds
 - d. Wash in tap water
7. Mount cover slips to slides using 1 drop of Aquamount whilst slides are damp

10.4.2 Sclerostin

10.4.2.1 Paraffin removal protocol

1. Histolene 1 for 10 minutes
2. Histolene 2 for 10 minutes
3. 100% ethanol for 5 minutes
4. 95% ethanol for 5 minutes
5. Wash twice with MilliQ water for 5 minutes each time

10.4.2.2 Antigen removal protocol

1. Tris-EDTA, pH 9.0, heated to 65°C (water bath)
2. Slides immersed in tris-EDTA for 10 minutes
3. Slides immersed in tris-EDTA left to cool on the bench for 20 minutes
4. Wash 3 times in 1x PBS for 5 minutes

10.4.2.3 Immunohistological staining method for sclerostin

Double enhancement method

Controls

Negative control: Omission of antibody and normal goat IgG (Cat No. AB-108-C, RandD Systems, distributed by Bio-Scientific Pty. Ltd., NSW, Australia) 1:250 dilution in PBS/BSA

Positive control: Alveolar bone

Procedure - Day 1:

1. PAP (hydrophobic) pen around each section
2. Endogenous peroxidase (EP) block (0.3% v/v H₂O₂ in PBS/0.1% sodium azide) for 20 minutes at room temperature
3. Wash in 1x PBS 3 times for 5 minutes
4. Application of primary antibody:
 - a. Prepare goat anti-mouse polyclonal SOST/Sclerostin (Cat No. AF1589, RandD Systems, distributed by Bio-Scientific Pty. Ltd., NSW, Australia) 1:50 dilution in 1x PBS/1% BSA
 - b. Apply to all sides except negative Place in wet chamber overnight at room temperature

Procedure - Day 2:

1. Wash in 1x PBS 3 times for 5 minutes
2. Application of secondary antibody:
 - a. Swine anti-goat Ig's HRP (Ref no. ACI0404, Invitrogen, distributed by Life Technologies Australia Pty Ltd, Victoria Australia) 1:60 dilution in 1x PBS/1% BSA
 - b. Pipette onto slides and leave for 30 minutes at room temperature
3. Wash in 1x PBS 3 times for 5 minutes
4. Application of tertiary antibody:
 - a. Rabbit anti-swine Ig's (Code No. P 0164, Dako Australia Pty. Ltd., NSW, Australia) 1:100 in 1x PBS/1% BSA
 - b. Pipette onto slides and leave for 30 minutes at room temperature
5. Wash in 1x PBS 3 times for 5 minutes
6. Apply AEC (3-Amino-9-ethylcarbazole) substrate chromogen (Cat no. SK-4200, Dako Australia Pty. Ltd., NSW, Australia) for 10 minutes at room temperature, covered, in a dark cupboard
7. Wash in MilliQ water 2 times for 5 minutes
 - a. Counterstain:
 - b. Haematoxylin 10 seconds
 - c. Wash in tap water until water runs clear
 - d. Lithium carbonate 30 seconds
 - e. Wash in tap water
8. Mount cover slips to slides using 1 drop of Aquamount whilst slides are damp